

Volume 23, Supplement 1 • October 2009  
ISSN: 0892-7790



# JOURNAL OF ENDOUROLOGY

*including Minimally Invasive Uro-Oncology*

**EDITORS:**

Ralph V. Clayman, M.D.

Arthur D. Smith, M.D.

The Official Journal of the  
Endourological Society  
Society for Engineering  
and Urology  
Society of Urologic Robotic  
Surgery

Program and Abstracts



**27<sup>th</sup> WORLD CONGRESS  
of ENDOUROLOGY & SWL**

**WCE 2009**

**October 6–10, 2009**

**Munich, Germany**

Mary Ann Liebert, Inc.  publishers



# Arthur D. Smith Endourology Lectureship

Recognizing creativity and dynamic innovation



2009 Recipient  
Evangelos Liatsikos, MD, PhD

Cook Medical welcomes you to the 27th Annual World Congress of Endourology. We look forward to being a part of this exciting meeting and the productive exchange of new ideas that is the spirit of the World Congress.

Cook is proud to announce this year's recipient of the Arthur D. Smith Endourology Lectureship for creativity and dynamic innovation in the field of endourology. The sixth annual "Arthur" goes to: Evangelos Liatsikos, MD, PhD, Assistant Professor, Department of Urology, Head of the Endourology-Laparoscopy Unit, University of Patras, Greece.


Cook Medical—Dedicated to advancing Endourology worldwide.





## Consider this scenario:

- 50-year-old male
- Right flank pain
- History of hypertension and stone disease
- Surgical history of both percutaneous and ureteroscopic procedures for his stone disease



LMA StoneBreaker™  
Pneumatic Lithotripter



Odyssey 30™  
Holmium Laser System

## You decide.

Visit the Cook Medical booth at WCE to view Christopher's films, labs, history and physical. Choose your treatment plan and compare it to the treatment plans of your colleagues.

# JOURNAL OF ENDOUROLOGY

The Official Publication of the *Endourological Society* • *Society for Engineering and Urology* • *British Society for Endourology* • *Asociación Mexicana de Endourologia* • *Litotricia y Laparoscopia* • *AC, Korean Endourology & ESWL Society* • *Muljibhai Patel Society for Research in Nephro-Urology* • *Associazione Italiana di Endourologia* • *Malaysian Society of Endourology* • *Southern African Endourology Society*

---

## Editors

### Ralph V. Clayman

*University of California, Irvine*  
*Department of Urology*  
333 City Blvd. West  
Suite 2100  
Orange, CA 92868  
714-456-3329  
rc layman@uci.edu

### Arthur D. Smith

*Department of Urology*  
*Long Island Jewish Medical Center*  
New Hyde Park, NY 11040  
718-470-3900  
michelelij@aol.com

---

## Managing Editor

### Gopal H. Badlani

*Wake Forest University Health Sciences*

---

## Editorial Coordinator

### Michele Paoli

*Endourological Society*  
516-520-1224  
michelelij@aol.com

---

## Associate Editors

### Demetrius H. Bagley

*Thomas Jefferson University Hospital*

### Joseph A. Smith, Jr.

*Vanderbilt University*

### Craig A. Peters

*The Children's Hospital*  
Boston

### Glenn M. Preminger

*Duke University Medical Center*

### Christian Chausy

*Stadt Krankenhaus Harlaching, Munich*

### Louis Kavoussi

*The Arthur Smith Institute for Urology*  
New Hyde Park, New York

### John Denstedt

*University of Western Ontario*

### Inderbir S. Gill

*Cleveland Clinic Foundation*

---

## Section Editors

### Controversial Cases in Endourology

#### Brian R. Matlaga

*Johns Hopkins Medical Institutions*

### Evangelos N. Liatsikos

*University of Patras*

### Endourology Surveys

#### Howard Winfield

*University of Iowa Hospitals and Clinics*

### Epochs in Endourology

#### Sakti Das

*University of California at Davis, Sacramento*

### Highlights

#### Jaime Landman

*Columbia University*

### Mantu Gupta

*St. Luke's-Roosevelt Hospital Center*

### Images in Endourology

#### Chandru P. Sundaram

*Indiana University*

### Letters to the Editor

#### Dean G. Assimos

*Wake Forest University Baptist Medical Center*

### New Technologies in Endourology

#### David Duchene

*University of Kansas*

### Stavros Gravas

*University Hospital of Laressa, Greece*

### Dan Stoianovici

*Johns Hopkins Hospital*

### Review Editors

#### Margaret S. Pearle

*University of Texas Southwestern Medical Center*

### Pilar Laguna

*University of Amsterdam*

### Socio-Economics

#### Larry C. Munch

*Indiana University*

### Techniques in Endourology

#### J. Stuart Wolf

*University of Michigan*

### Benjamin R. Lee

*Tulane University*

### Trends in Endourology Practice

#### Glenn S. Gerber

*University of Chicago*

### Tricks of the Trade

#### William K. Johnston, III

*University of Chicago*

---

## Assistant Editors

### Clément-Claude Abbou

*CHU Henri Mondor, France*

### David M. Albala

*Duke University Medical Center*

### Yoshio Aso

*University of Tokyo, Japan*

### Richard Babayan

*Boston University Medical Center*

### Jeffrey Cadeddu

*The University of Texas Southwestern Medical Center*

### Jean De La Rosette

*University of Amsterdam Academic Medical Center*  
*The Netherlands*

### Mahesh Desai

*Muljibhai Patel Urological Hospital, India*

### Stephen Dretler

*Harvard Medical School*

### Gerhard J. Fuchs

*Cedars Sinai Medical Center, Los Angeles*

### Michael Grasso, III

*St. Vincents Medical Center, New York*

### Donald Griffith

*UroCenter of Houston, LLP*

### Bertrand Guillonneau

*Memorial Sloan-Kettering Cancer Center*

### Jorge Gutiérrez Aceves

*University of Guadalajara, Mexico*

### Ashok Hemal

*Wake Forest University*

### Gunter Janetschek

*Universitätsklinik Fur Urologie, Austria*

### Alan Jenkins

*University of Virginia Hospital*

### Gerald H. Jordan

*Eastern Virginia Medical School*

### Adrian Joyce

*St. James University, United Kingdom*

### David Lee

*University of Pennsylvania*

### Michael Marberger

*University of Vienna, Austria*

### Elsbeth M. McDougall

*University of California, Irvine*

### Maurice Stephan Michel

*University of Mannheim, Germany*

### Manoj Monga

*University of Minnesota*

### Stephen Y. Nakada

*University of Wisconsin*

### Robert C. Newman

*University of Florida*

### Yoshinari Ono

*Nagoya University, Japan*

### Jens Rassweiler

*Klinikum Heilbronn, Germany*

### Nelson Rodrigues Netto, Jr.

*University of Campinas Medical Center, Brazil*

### Raju Thomas

*Tulane University, New Orleans*

### David A. Tolley


*Western General Hospital, Scotland*

### Paul J. Van Cangh

*St. Luc University Hospital, Belgium*

### Graham Watson

*Esperance Private Hospital*  
*East Sussex, United Kingdom*

Mary Ann Liebert, Inc.  publishers


www.liebertpub.com





## Consider this scenario:

- 20-year-old male
- Right lower quadrant pain ongoing for six months
- Nausea and vomiting
- No hematuria or fever



LMA StoneBreaker™  
Pneumatic Lithotripter



Odyssey 30™  
Holmium Laser System

## You decide.

Visit the Cook Medical booth at WCE to view Fernando's films, labs, history and physical. Choose your treatment plan and compare it to the treatment plans of your colleagues.

# General Information

## **Mission:**

By virtue of a stringent peer review process, *JOURNAL OF ENDOUROLOGY* seeks to provide the urological community with leading edge, scientifically rigorous studies in minimally invasive and nonincisional urologic surgery. All aspects of endoscopic, laparoscopic, robotic, and image guided procedures as they apply to benign and malignant diseases of the genitourinary tract are central to our mission.

## **Vision:**

Evidence-based endourologic education of the medical community will bring our patients high quality, patient-oriented care providing the most rapid return of their well being.

*JOURNAL OF ENDOUROLOGY* (ISSN: 0892-7790) is published monthly (twelve issues a year) by Mary Ann Liebert, Inc., 140 Huguenot Street, 3rd floor, New Rochelle, NY 10801. Periodicals postage paid at New Rochelle, NY, and at additional mailing offices. **Postmaster:** Send address changes to *JOURNAL OF ENDOUROLOGY*, c/o Subscription Department, Mary Ann Liebert, Inc., 140 Huguenot Street, 3rd floor, New Rochelle, NY 10801. Mailed in Canada under CPC CPM# 40026674.

**Subscriptions** should be addressed to the Publisher and are payable in advance. Rates for subscriptions per volume of 12 issues: USA print \$1314, International print \$1577, USA print and online \$1577, International print and online \$1840, and online only (worldwide) \$1232. Subscriptions begin with the first issue of the current volume. Bulk subscriptions available upon request from the Publisher. No cancellations/refunds can be honored after publication of the first issue. No refunds/returns on single issue purchases.

*JOURNAL OF ENDOUROLOGY* is owned and published by Mary Ann Liebert, Inc. Copyright © 2009 by Mary Ann Liebert, Inc. Printed in the United States of America.

Telephone: (914) 740-2100; fax: (914) 740-2108; e-mail: [info@liebertpub.com](mailto:info@liebertpub.com) Online: [www.liebertpub.com](http://www.liebertpub.com)

**Information for Manuscript Submission** is given in the back of this issue and on our web site: [www.liebertpub.com](http://www.liebertpub.com)

**Business Communications** should be addressed to the Publisher.

**Advertising inquiries** from within the United States or Canada should be addressed to Katharine Cane, Mary Ann Liebert, Inc., 140 Huguenot Street, 3rd floor, New Rochelle, NY 10801. For Europe/Outside the U.S., contact: Hilary Turnbull, imPRESS International Media Ltd., Carrington Kirk, Carrington, Midlothian, EH23 4LR, UK. Telephone: +44-1875-825-700; fax: +44-1875-825-701; e-mail: [hturnbull@impressmedia.com](mailto:hturnbull@impressmedia.com) All advertisements are subject to approval by the Publisher.

**Reprints:** For permission to photocopy 99 copies or less of an article for internal purposes, please request permission and pay the appropriate fee by contacting the Customer Relations Department of the Copyright Clearance Center, Inc., 22 Rosewood Drive, Danvers, MA 01923. Telephone: 978.750.8400; Fax 978.750.4470. If the required number of copies of an article is 100 or more, please contact the Publisher directly for options: Karen Ballen, Reprint Sales Manager, 914.740.2100, Ext. 2194.

**Manuscripts** must be submitted online using the following url: <http://mc.manuscriptcentral.com/endourology>.

All papers, news, comments, opinions, findings, conclusions, or recommendations in *JOURNAL OF ENDOUROLOGY* are those of the author(s), and do not constitute opinions, findings, conclusions, or recommendations of the Journal, its Publisher, and its editorial staff.

*JOURNAL OF ENDOUROLOGY* is indexed in *MEDLINE EMBASE/Excerpta Medica, and Scopus*.

The paper on which *JOURNAL OF ENDOUROLOGY* is printed meets the requirements of ANSI/NISO Z39.48-1992 (Permanence of Paper). Printed on acid-free paper effective with Volume 1, Issue 1, 1987.

*JOURNAL OF ENDOUROLOGY* is a **Journal Club** selection.


Please visit us on the web: [www.liebertpub.com](http://www.liebertpub.com)

Mary Ann Liebert, Inc.  publishers



## Consider this scenario:

- 66-year-old female
- Microhematuria
- Frequency
- Urgency
- Normal cystoscopy and cytology



LMA StoneBreaker™  
Pneumatic Lithotripter



Odyssey 30™  
Holmium Laser System

## You decide.

Visit the Cook Medical booth at WCE to view Katherine's films, labs, history and physical. Choose your treatment plan and compare it to the treatment plans of your colleagues.

# COMMITTEE MEMBERS

## Executive Committee of the Endourological Society

Badlani, Gopal, USA  
*President*

Ono, Yoshinari, Japan  
*Past-President*

van Cangh, Paul, Belgium  
*President-Elect*

Denstedt, John, Canada  
*Treasurer*

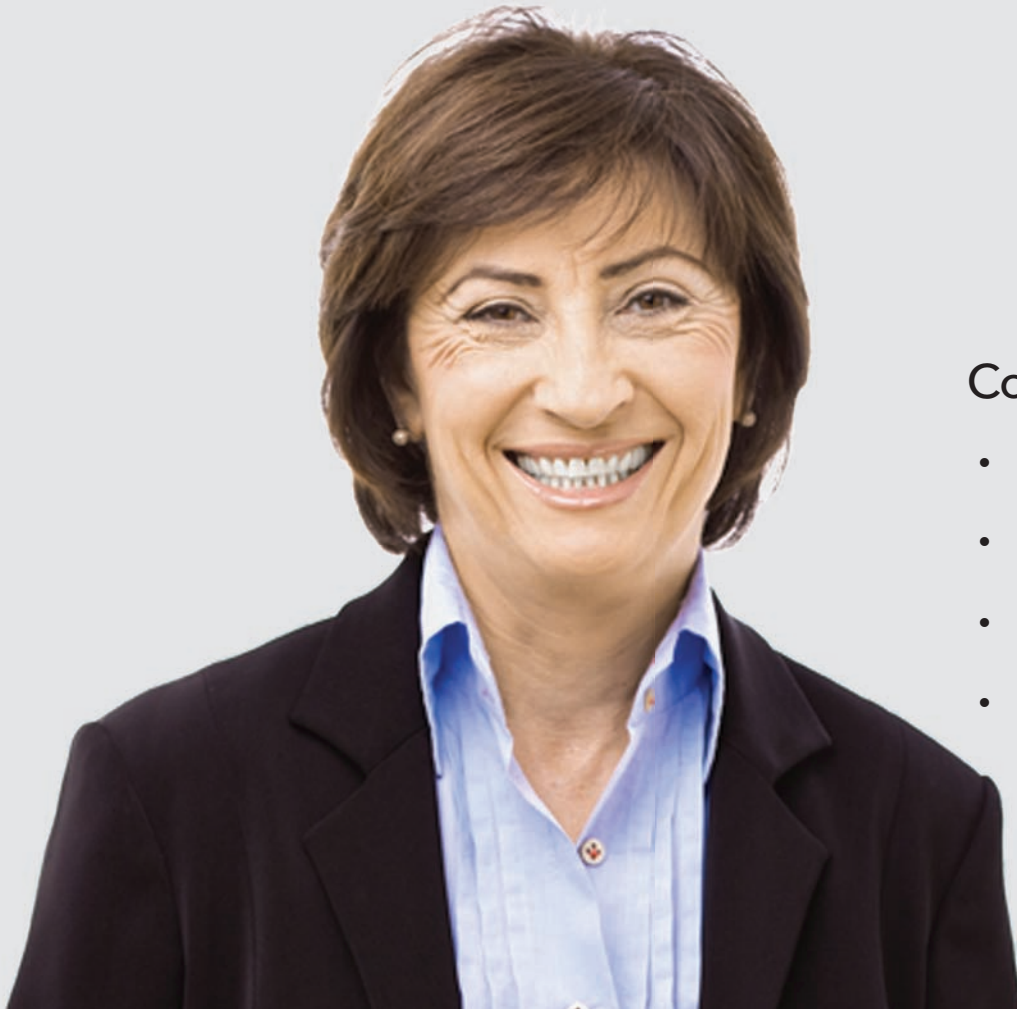Clayman, Ralph, USA  
*Secretary General*

Desai, Mahesh, India  
*Scientific Chairman*

Smith, Arthur, USA  
*Founding President*


Paoli, Michele, USA  
*Executive Secretary*





## Consider this scenario:

- 52-year-old female
- Persistent left flank pain
- Nausea
- History of stone disease



LMA StoneBreaker™  
Pneumatic Lithotripter



Odyssey 30™  
Holmium Laser System

## You decide.

Visit the Cook Medical booth at WCE to view Rebecca's films, labs, history and physical. Choose your treatment plan and compare it to the treatment plans of your colleagues.

## **CONGRESS ORGANIZING COMMITTEE**

Rassweiler, Jens, Heilbronn  
*President*

Chaussy, Christian, Munich  
*Scientific Chairman*

Teber, Dogu, Heilbronn,  
Neumayr, Andreas, Munich  
*Congress Secretaries*

## **GERMAN ORGANIZING COMMITTEE**

Alken, Peter, Mannheim  
Burchardt, Martin, Hannover  
Fornara Paolo, Halle  
Haupt, Gerald, Speyer  
Hofmann, Rainer, Marburg  
Gross, Andreas, Hamburg  
Gschwend, Jürgen, Munich  
Jocham, Dieter, Lübeck  
Knoll, Thomas, Sindelfingen-Böblingen  
Köhrmann, Kai-Uwe, Mannheim  
Kuntz, Rainer, Berlin  
Lahme, Sven, Pforzheim  
Michel, Stefan-Maurice, Mannheim  
Muschter, Rolf, Rotenburg/W  
Stief, Christian, Munich  
Stolzenburg, Jens-Uwe, Leipzig  
Straub, Michael, Munich  
Teber, Dogu, Heilbronn  
Thüroff, Stefan, Munich  
Vögeli, Thomas, Bardenberg  
Wieland, Wolfgang, Regensburg  
Wirth, Manfred, Dresden  
Witsch, Ulrich, Frankfurt

## INTERNATIONAL SCIENTIFIC BOARD

Abbou, Claude, *France*  
Alivizatos, Gerasimos, *Greece*  
Baba, Shiro, *Japan*  
Breda, Guglielmo, *Italy*  
Brehmer, Marianne, *Sweden*  
Castillo Cadiz, Octavio, *Chile*  
Chiu, Allan, *Taiwan*  
De la Rosette, Jean, *Netherlands*  
Erdogru, Tibet, *Turkey*  
Escovar, Paul, *Venezuela*  
Fuchs, Gerhard, *USA*  
Galluci, Michele, *Italy*  
Gill, Inderbir, *USA*  
Guillonneau, Bertrand, *USA*  
Gutierrez Aceves, Jorge, *Mexico*  
Janetschek, Günter, *Austria*  
Joyce, Adrian, *United Kingdom*  
Joseph, Jean, *USA*  
Kavoussi, Louis, *USA*  
Keeley, Frank, *United Kingdom*  
Kim, Hyeon Hoe, *South Korea*  
Kulkarmi, Ravi, *United Kingdom*  
Laguna, Pilar, *Netherlands*  
Lingeman, James, *USA*  
Martov, Alexei, *Russia*  
Matsuda, Tadashi, *Japan*  
Mottrie, Alex, *Belgium*  
Naito, Seiji, *Japan*  
Netto, Nelson, *Brazil*  
Ono, Yoshinari, *Japan*  
Özgök, Yasar, *Turkey*  
Pansadoro, Vito, *Italy*  
Parra, Raul, *USA*  
Patel, Vipul, *USA*  
Piechaud, Thierry, *France*  
Preminger, Glenn, *USA*  
Puppo, Paulo, *Italy*  
Shalhav, Arie, *USA*  
Su, Li-Ming, *USA*  
Sulser, Tullio, *Switzerland*  
Sun, Yinghao, *China*  
Sung, Gyang Tak, *South Korea*  
Tiselius, Hans-Göran, *Sweden*  
Tolley, David, *United Kingdom*  
Traxer, Oliver, *France*  
Tuerk, Ingolf, *USA*  
Van Velthoven, Roland, *Belgium*  
Wong, Michael, *Singapore*

## INVITED FACULTY AND MODERATORS

Abala, David, *USA*  
Abbou, Claude, *France*  
Abreu, Sidney, *Brazil*  
Acetin, Zhia, *Turkey*  
Agarwal, Mayanak, *India*  
Ahlering, Thomas, *USA*  
Ahn, H, *Korea*  
Alcaraz, Antonio, *Spain*  
Aldana, Joel, *Philippine*  
Alivizatos, Gerasimos, *Greece*  
Alken, Peter, *Germany*  
Altug, Ugur, *Turkey*  
Annerstedt, Magnus, *Denmark*  
Arjun, Mallika, *India*  
Aron, Monish, *USA*  
Artibani, Walter, *Italy*  
Assimos, Dean, *USA*  
Auge, Brian, *USA*  
Autorino, Riccardo, *Italy*  
Baba, Shiro, *Japan*  
Babayán, Richard, *USA*  
Babtistussi, M, *Brazil*  
Bach, Thorsten, *Germany*  
Bachmann, Alexander, *Switzerland*  
Badlani, Gopal, *USA*  
Bagley, Demetrius, *USA*  
Baykara, Mehmet, *Turkey*  
Bassiri, Abbas, *Iran*  
Baumert, Hervé, *France*  
Baumhauer, Matthias, *Germany*  
Bayer, Thomas, *Germany*  
Beer, Manfred, *Germany*  
Bergsdorf, Thorsten, *Germany*  
Berkenblit, Robert, *USA*  
Bernardo, Norberto, *Argentina*  
Bhayani, Sam, *USA*  
Bianchi, Gianpaolo, *Italy*  
Bilen, Cenk, *Turkey*  
Binder, Jochen, *Switzerland*  
Bischoff, Werner, *Germany*  
Bjerklund-Johansen, T, *Denmark*  
Blana, A., *Germany*  
Boeckmann, Wieland, *Germany*  
Boonyapanichskul, P, *Thailand*  
Box, Geoffrey, *USA*  
Breda, Alberto, *Spain*  
Breda, Guglielmo, *Italy*  
Brehmer, Marianne, *Sweden*  
Bross, Stephan, *Germany*  
Bub, Peter, *Germany*  
Buchholz, Noor, *United Kingdom*  
Bucuras, Viorel, *Romania*  
Burchardt, Martin, *Germany*  
Burger, Maximillian, *Germany*  
Caddedu, Jeffrey, *USA*  
Canes, David, *USA*  
Carl, Stefan, *Germany*  
Castillo, Octavio, *Chile*  
Castle, Erik, *USA*  
Cathelineau, Xavier, *France*  
Chaussy, Christian, *Germany*  
Cheng, Christopher, *Singapore*  
Celia, Antonio, *Italy*  
Cestari, Andrea, *Italy*  
Chan, Wai-hee Steve, *Hong Kong*  
Chew, Ben, *Canada*  
Chien, Gary, *USA*  
Chiu, Allen, *Taiwan*  
Cheon, Jun, *Korea*  
Clayman, Ralph, *USA*  
Cleveland, Ronald, *USA*  
Conradie, Marius, *South Africa*  
Corcos, J, *Canada*  
Date, Jaydeep, *India*  
Davis, John, *USA*  
Daels, Pedro, *Argentina*  
Defidio, Lorenzo, *Italy*  
Deger, Serdar, *Germany*  
De la Rosette, Jean, *The Netherlands*  
De la Taille, Alexandre, *France*  
Denstedt, John, *Canada*  
De Reijke, Theo, *The Netherlands*  
Desai, Janak, *India*  
Desai, Mahesh, *India*  
Desai, Mihir, *USA*  
Desgrandschamps, Francois, *France*  
De Sio, Marco, *Italy*  
Dhar, Mrinal, *USA*  
Disanto, Vincenzo, *Italy*  
Djavan, Bob, *USA*  
Doehn, Christian, *Germany*  
Echtle, Dieter, *Germany*  
Eisele, Jorge Clavijo, *United Kingdom*  
Elhilali, Mostafa, *Canada*  
Embert, Hugo, *France*  
Emberton, Mark, *United Kingdom*  
Eraky, Ibrahim, *Egypt*  
Erdogru, Tibet, *Turkey*  
Escovar, Paul Jr., *USA*  
Esen, Tarik, *Turkey*  
Equivel, Sandra, *Peru*  
Fahlenkamp, Dirk, *Germany*  
Faul, Peter, *Germany*  
Feitz, Walter, *The Netherlands*

## INVITED FACULTY AND MODERATORS (*Continued*)

Ficarra, Vincenzo, *Italy*  
Fornara, Paolo, *Germany*  
Forssmann, Bernd, *Germany*  
Fortes, Marco, *Brazil*  
Frede, Thomas, *Germany*  
Frohneberg, Dieter, *Germany*  
Fuchs, Gerhard, *USA*  
Fujimoto, Kiyohide, *Japan*  
Gaboardi, Franco, *Italy*  
Gallucci, Michele, *Italy*  
Gangi, Ashfan, *France*  
Ganpule, Arvind, *India*  
Gao, Xiaofeng, *China*  
Geavlete, Petrisor, *Romania*  
Gelet, André, *France*  
Gettmann, Matthew, *USA*  
Gill, Indebir, *USA*  
Gilling, Peter, *New Zealand*  
Goezen, Ali Serdar, *Turkey*  
Goldstein, Marc, *USA*  
Gomez Sancha, Fernando, *Spain*  
Gozzi, Christian, *Germany*  
Grasso, Michael, *USA*  
Gravas, Stavros, *Greece*  
Groh, Reinhard, *Germany*  
Gross, Andreas, *Germany*  
Gschwend, Jürgen, *Germany*  
Guazzoni, Giorgio, *Italy*  
Guillonneau, Bertrand, *USA*  
Guitierrez, Jorge, *Mexico*  
Gumpinger, Rudolf, *Germany*  
Gupta, Mantu, *USA*  
Gupta, Narmanda, *India*  
Gutierrez, Jorge, *Mexico*  
Haber, George-Pascal, *USA*  
Habuchi, T, *Japan*  
Haecker, Axel, *Germany*  
Haferkamp, Axel, *Germany*  
Hagg, Martin, *Germany*  
Hahn, R, *Sweden*  
Hampel, Christian, *Germany*  
Hartung, Rudolf, *Germany*  
Hattori, Ryouhei, *Japan*  
Hatzinger, Martin, *Germany*  
Haupt, Gerald, *Germany*  
Hautmann, Richard, *Germany*  
Hedican, Sean, *USA*  
Hegele, A, *Germany*  
Hemal, Ashok, *USA*  
Henkel, Thomas, *Germany*  
Herrell, Duke, *USA*  
Hirzinger, Gerd, *Germany*  
Ho, Henry, *Singapore*  
Hofmann, Rainer, *Germany*  
Hofmockel, Gerog, *Germany*  
Hohenfellner, Markus, *Germany*  
Honey, John, *Canada*  
Horsch, Reinhold, *Germany*  
Hoznek, Andras, *France*  
Hruza, Marcel, *Germany*  
Hubert, Jaques, *France*  
Humphreys, Mitchell, *USA*  
Huyghes, Eric, *France*  
Janetschek, Gunter, *Austria*  
Jarrett, Thomas, *USA*  
Jewett, Michael, *Canada*  
Jocham, Dieter, *Germany*  
John, Hubert, *Switzerland*  
Jordan, Gerald, *USA*  
Joseph, Jean, *USA*  
Joyce, Adrian, *United Kingdom*  
Juenemann, Klaus-Peter, *Germany*  
Khan, Shamim, *United Kingdom*  
Kandarp, Prahmed, *India*  
Kandasami, Sangam, *India*  
Kaouk, Jihad, *USA*  
Katz, A, *USA*  
Kavoussi, Louis, *USA*  
Kawauchi, Akihiro, *Japan*  
Keeley, Francis, *United Kingdom*  
Kekre, Nitin, *India*  
Kim, Fernando, *USA*  
Kim, Hyeon Hoe, *Korea*  
Kirpekar, Deepak, *India*  
Klein, Jan, *Germany*  
Klingler, Christoph, *Austria*  
Knoll, Thomas, *Germany*  
Koehrmann, Kai Uwe, *Germany*  
Kovac, R, *Hungary*  
Kriegmair, Martin, *Germany*  
Kuang, Wayne, *USA*  
Kulkarni, Ravi, *United Kingdom*  
Kumar, G, *India*  
Kuntz, Rainer, *Germany*  
Kural, Ali Riza, *Turkey*  
Kurian, Abraham, *India*  
Kuczyk, Markus, *Germany*  
Laguna, Pilar, *The Netherlands*  
Lahme, Sven, *Germany*  
Laible, Volker, *Germany*  
Lampel, Alexander, *Germany*  
Landman, Jaime, *USA*  
Larner, Tim, *United Kingdom*  
Lee, Benjamin, *USA*



## INVITED FACULTY AND MODERATORS (*Continued*)

Lee, David, *USA*  
Lee, Tchun Yong, *Korea*  
Leyh, Herbert, *Germany*  
Leveille, Ray, *USA*  
Li, Shu-Keung, *HK China*  
Li, Xun, *China*  
Liatsikos, Evangelos, *Greece*  
Liedl, Bernhard, *Germany*  
Lima, Estevao, *Portugal*  
Lingeman, James, *USA*  
Loch, Tillmann, *Germany*  
Loebelenz, Matthias, *Germany*  
Lopes, Tome, *Portugal*  
Loske, Achim, *Mexico*  
Lottmann, Henri, *France*  
Lutz, Andreas, *Germany*  
Lyng, Raul, *Chile*  
Maheshwari, P, *India*  
Marberger, Michael, *Austria*  
Marcovich, Robert, *USA*  
Martov, Alexei, *Russia*  
Matin, S, *USA*  
Matlaga, Brian, *USA*  
Mamoulakis, Charalambus, *The Netherlands*  
Matsuda, Tadashi, *Japan*  
Mc Ateer, John, *USA*  
Mc Dougall, Elspeth, *USA*  
Melchior, Sebastian, *Germany*  
Melzer, Andreas, *United Kingdom*  
Mendoza, Arturo, *Mexico*  
Menon, Mani, *USA*  
Merseburger, Axel, *Germany*  
Messas, Aurel, *France*  
Micali, Salvatore, *Italy*  
Michel, Maurice-Stephan, *Germany*  
Miller, Kurt, *Germany*  
Monga, Manoj, *USA*  
Montanari, Emanuele, *Italy*  
Moon, Young Tae, *Korea*  
Mottrie, Alex, *Belgium*  
Mueller, Stefan, *Germany*  
Munch, Larry, *USA*  
Munver, Ravi, *USA*  
Muschter, Rolf, *Germany*  
Naito, Seiji, *Japan*  
Nakada, Stephen, *USA*  
Nanke, Ralf, *Germany*  
Negrete, Oscar, *Mexico*  
Neisius, Dietmar, *Germany*  
Netto, Nelson Rodrigues, *Brazil*  
Nyirady, Peter, *Hungary*  
Nutahara, Kikuo, *Japan*  
O'Brien, Tim, *United Kingdom*  
Oktay, Bülent, *Turkey*  
Özgök, Yasar, *Turkey*  
Olbert, Peter, *Germany*  
Ono, Yoshinari, *Japan*  
Ost, Michael, *USA*  
Osther, Palle, *Denmark*  
Pace, Kenneth, *Canada*  
Palou, Jean, *Spain*  
Pansadoro, Vito, *Italy*  
Pansadoro, Alberto, *Italy*  
Parekattil, Sijo, *USA*  
Park, Hyung Keun, *Korea*  
Parra, Raul, *USA*  
Patel, Anup, *United Kingdom*  
Patel, Hiten, *United Kingdom*  
Pautler, Stephen, *Canada*  
Peabody, James, *USA*  
Pearle, Margaret, *USA*  
Perez-Castro, Enrique, *Spain*  
Peters, Craig, *USA*  
Petrut, Bogdan, *Romania*  
Piechaud, Thierry, *France*  
Pinto, Peter, *USA*  
Ponsky, Lee, *USA*  
Porter, James, *USA*  
Preminger, Glenn, *USA*  
Puppo, Paolo, *Italy*  
Pushkar, Dimitri, *Russia*  
Ramalingam, Manidam, *India*  
Raman, Jay, *USA*  
Rane, Abhay, *United Kingdom*  
Rao, Pradeep, *India*  
Rassweiler, Jens, *Germany*  
Reich, Oliver, *Germany*  
Rein, Patrick, *Germany*  
Reuter, Matthias, *Germany*  
Richstone, Lee, *USA*  
Rimington, Peter, *United Kingdom*  
Rioja, Jorge, *Spain*  
Rocco, Bernardo, *Italy*  
Roesch, Wolfgang, *Germany*  
Rothenberger, Karl-Heinz, *Germany*  
Ruszat, R, *Switzerland*  
Sabnis, Ravindra, *India*  
Sahin, Ahmet, *Turkey*  
Salomon, Laurent, *France*  
Santinelli, Flavio, *Argentina*  
Sarica, K, *Turkey*  
Schieffelbein, Frank, *Germany*  
Schiff, Jonathan, *USA*  
Schilling, Albrecht, *Germany*

## INVITED FACULTY AND MODERATORS (*Continued*)

Schilling, David, *Germany*  
Schmeller, Nikolaus, *Austria*  
Schurr, Marc, *Germany*  
Schwartz, B, *USA*  
Schwarzer, Werner, *Germany*  
Scarpa, Roberto, *Italy*  
Scoffone, Cesare, *Italy*  
Seibold, Jörg, *Germany*  
Shalhav, Arie, *USA*  
Shitara, Toshiya, *Japan*  
Shu, Tung, *USA*  
Siegel, Yoram, *Israel*  
Siemer, Stefan, *Germany*  
Sievert, Karl, *Germany*  
Simforoosh, Nasser, *Iran*  
Smith, Arthur, *USA*  
Skolarikos, Andreas, *Greece*  
Soler, Luc, *France*  
Sotelo, René, *Venezuela*  
Staehler, Michael, *Germany*  
Stein, Conrado, *Chile*  
Stenzl, Arnulf, *Germany*  
Steven, L, *Belgium*  
Stief, Christian, *Germany*  
Stifelman, Michael, *USA*  
Stock, Christian, *Germany*  
StoECKle, Michael, *Germany*  
Stoianovic, Dan, *USA*  
Stoller, Marshall, *USA*  
Stolzenburg, Jens-Uwe, *Germany*  
Straub, Michael, *Germany*  
Strup, Stephen, *USA*  
Su, Li-Ming, *USA*  
Subotic, Svetozar, *Germany*  
Sulser, Tullio, *Switzerland*  
Sun, Yinghao, *China*  
Sundaram, Chandru, *USA*  
Sung, Gyung Tak, *Korea*  
Suzuki, Kazuo, *Japan*  
Sweet, Robert, *USA*  
Tailly, Geert, *Belgium*  
Takenaka, A, *Japan*  
Te, Alexis, *USA*  
Teber, Dogu, *Germany*  
Tefekli, Ahmet, *Turkey*  
Terachi, Toshiro, *Japan*  
Tewari, Ash, *USA*  
Thomas, Raju, *USA*

Thüroff, Joachim, *Germany*  
Thüroff, Stefan, *Germany*  
Tiselius, Hans, *Sweden*  
Tolley, David, *United Kingdom*  
Traxer, Olivier, *France*  
Trojan, Lutz, *Germany*  
Tschada, Reinhold, *Germany*  
Tuerk, Ingolf, *USA*  
Tuerk, Christian, *Austria*  
Tunc, Lütfü, *Turkey*  
Tuncay, Omar, *Turkey*  
Ukimura, Osamu, *Japan*  
Valdivia, Jean, *Spain*  
Van Canghai, Paul, *Belgium*  
Van Cleyenbreugel, Ben, *Belgium*  
Van der Poel, Henk, *The Netherlands*  
Van Velthoven, Roland, *Belgium*  
Varshney, Anil, *India*  
Vasavada, Sandip, *USA*  
Villavincencio, Humberto, *Spain*  
Vögeli, Thomas-Alexander, *Germany*  
Volpe, Alessandro, *Italy*  
Wang, David, *USA*  
Watson, Graham, *United Kingdom*  
Wendt-Nordahl, Gunnar, *Germany*  
Wess, Othmar, *Switzerland*  
Westphal, Jens, *Germany*  
Wieland, Wolf Ferdinand, *Germany*  
Wijkstra, Hessel, *The Netherlands*  
Wiklund, Peter, *Sweden*  
Winfield, Howard, *USA*  
Wirth, Manfred, *Germany*  
Witjes, F, *The Netherlands*  
Witt, Jörn, *Germany*  
Witzsch, Ulrich, *Germany*  
Wong, Michael, *Singapore*  
Wu, Guan, *USA*  
Wülfing, Christian, *Germany*  
Yachia, Daniel, *Israel*  
Yalcin, Veli, *Turkey*  
Yeung, C.K., *HK China*  
Yin, Changiun, *China*  
Yip, Sidney, *HK China*  
Zorn, Kevin, *USA*  
Zumbé, Jürgen, *Germany*  
Zwergel, Thomas, *Germany*  
Zwergel, Ulrike, *Germany*

## **SPONSORSHIP**

### **GOLD SPONSORS**

BOSTON SCIENTIFIC MEDIZINTECHNIK GMBH, RATINGEN  
COOK DEUTSCHLAND GMBH, MÖNCHEGLADBACH  
GYRUS MEDICAL GMBH, TUTTLINGEN

OLYMPUS DEUTSCHLAND GMBH, HAMBURG  
KARL STORZ GMBH & CO. KG, TUTTLINGEN  
RICHARD WOLF GMBH, KNITTLINGEN

### **SILVER SPONSORS**

AMS DEUTSCHLAND GMBH, BERLIN  
DORNIER MEDTECH EUROPE GMBH, WESSLING  
EDAP TMS GMBH, FLENSBURG

GE HEALTHCARE BUCHLER GMBH & CO. KG, MÜNCHEN  
INTUITIVE SURGICAL DEUTSCHLAND GMBH, ESSEN  
LUMENIS GMBH, DREIEICH-DREIEICHENHAIN

SIEMENS AG MEDICAL SOLUTION, ERLANGEN  
STARMEDTEC GMBH, STARNBERG

### **BRONZE SPONSORS**

BAYER HEALTH CARE AG, BAYER VITAL, LEVERKUSEN  
COVIDIEN DEUTSCHLAND GMBH, NEUSTADT A.D.DONAU  
FARCO PHARMA GMBH, KÖLN

FRESENIUS KABI AG, BAD HOMBURG V.D.H.  
LISA LASER PRODUCTS OHG, KATLENBURG LINDAU  
NYCOMED DEUTSCHLAND GMBH, KONSTANZ

PNN MEDICAL, HARRISLEE  
ROLLE + ROLLE GMBH + CO. KG, SALZBURG

### **SPONSORS**

AST GMBH, JENA  
ASTELLAS PHARMA GMBH, MÜNCHEN  
HAMMER UND RALL MEDIA GMBH, HEILBRONN  
INNOVATIVE MEDICAL PRODUKTE GMBH, KARLSRUHE  
MMS DEUTSCHLAND GMBH, BOTTROP  
NOVARTIS DEUTSCHLAND GMBH, NÜRNBERG  
OPTIMED GMBH, ETTLINGEN  
Q-MED GMBH, BENSHEIM  
ROCHE DEUTSCHLAND HOLDING GMBH, GRENZACH-WYHLEN  
SANOFI-AVENTIS DEUTSCHLAND GMBH, FRANKFURT  
STORZ MEDICAL AG, CH-TÄGERWILEN  
TAKEDA PHARMA GMBH, AACHEN  
UROMED, PRODUKTE FÜR UROLOGIE, OSTSTEINBEK  
URORAD MEDTECH GMBH, SCHÖMBERG  
WYETH PHARMA GMBH, MÜNSTER

## MESSAGE FROM WCE CONGRESS PRESIDENTS

Dear Colleagues and Friends,

Dear Representatives of the Pharmaceutic and Medical Industry,

Twenty-five years after the last World Congress of Endourology in Germany, organized by Prof. Peter Alken, we are happy to cordially invite you to the wonderful city of Munich for the 27<sup>th</sup> World Congress on Endourology and SWL from **October 6 to 10, 2009**.

**Munich**, as capital of the state of Bavaria, combines its international flair with the sociability and coziness of Bavarian culture. Based on personal knowledge, we want to show you this place with all its cultural facets to make your visit an unforgettable one. The **Westin Grand** has hosted important national and international meetings offering the advantage for delegates to stay almost in the center of the city.

We are proud to provide a **National Organizing Committee** and an **International Scientific Board**, with experts in the field of minimally invasive surgery, endourology, extracorporeal shock wave lithotripsy, and uro-oncology. The Congress will be supported by the Academy of the German Urologists, the German Shock Wave Society, the EAU-section of Uro-technology, and many National Endourology Societies. This allows us to update all technological innovations in the growing field of video-endoscopic surgery and focal therapy in urology.

**Live surgery** (endourologists at work) will be supported by the Departments of Urology, Medical School Rechts der Isar in Munich (Head: Prof. Dr. J. Gschwend), and Klinikum Harlaching (Head: Prof. Dr. C. Chaussy). Traditionally, we will demonstrate endourological techniques, focal therapy, and laparoscopic and robotic assisted surgery, as well as transurethral procedures and ESWL.

**Hands-on courses** focusing on ureteroscopy, laparoscopy, and transurethral techniques will allow beginners to receive training from the experts but will also help experienced urologists improve their surgical skills. Additionally, we provide **masterclasses in endourology** as well as an **interactive virtual training course for laparoscopic radical prostatectomy**, an absolutely new training method based on more than 500 recorded cases of laparoscopic radical prostatectomies.

The well-established **pro-and-con debates** will be integrated to stimulate the discussion of “hot topics” among the delegates. Additionally, during the main session we will invite experts to give **state-of-the-art lectures** on issues challenging the future of our profession, such as robotics, NOTES, and focal therapy.

**Supplementary sessions** organized by the special groups of our society will focus in detail on the problems and perspectives of the respective field (i.e., stents, navigated surgery, training, engineering, and uro-oncology).

Every morning, we will offer **educational courses** run by the well-known international faculty. In smaller groups, delegates will be able to ask questions and discuss their individual problems.

In the tradition of the Endourological Society, we want to minimize parallel sessions in the morning to achieve a concentrated exchange of science and experience. In the afternoon, the audience will be split according to the different topics of **video, oral, and poster sessions**. For dedicated presentations, **videoposter-sessions (V-poster)** are scheduled.

The famous English Garden, situated close to the Sheraton Grand Hotel, will present an excellent stage for the **Fund Run** sponsoring the **Joseph Segura Foundation**.

**In the evening**, delegates and faculty are cordially invited to relax in the atmosphere of the royal history in the **Residence** (Welcome Reception, October 7, 2009), but also experience the famous “Gemütlichkeit” of a Bavarian Beer Festival provided by an original **Octoberfest host** (WCE-evening, October 9, 2009).

Pre- and post-congress tours may allow you to complete your Bavarian experience.

We are looking forward to welcoming you in Munich.

**Jens Rassweiler**

**Christian Chaussy**

27<sup>th</sup> World Congress of Endourology



It is my pleasure to invite you to  
**JOIN US IN CHICAGO FOR THE WCE 2010**  
and stay at the forefront of minimally invasive  
urology while enjoying the windy city.

Learn from international leaders in their fields  
about state-of-the-art old and new concepts,  
groundbreaking research and future directions.

The most experienced surgeons demonstrate their  
art with live cases and step-by-step case reviews.  
Attend focused courses and hands-on labs and  
personally meet the leaders for a small group lunch.

Bring your family with you to the heart of Chicago  
and enjoy all the city has to offer. In addition to the  
WCE social program there will be a multitude  
of accompanying family programs and you can  
extend your stay in Chicago for Labor Day weekend.

**ARIEH L. SHALHAV MD**  
President, 28th WCE



[www.wce2010.com](http://www.wce2010.com)

## SEE YOU IN CHICAGO


Chicago looks great from every angle, whether you're exploring the city's astonishing architecture or joining us on our social events as you find magic in such sparkling attractions as Navy Pier or the House of Blues. Not only the *Windy City*, Chicago is often called the Friendly City; accept the city's warm invitation to explore and experience countless attractions, museums, the millennium park, dining and shopping options or simply enjoy the city's 20 miles of lakefront paths. Chicago awaits!

## IMPORTANT DEADLINES

Early Registration	<b>July 9, 2010</b>
Call for Abstracts	<b>May 14, 2010</b>
Call for Videos	<b>May 7, 2010</b>



# 2009 KARL STORZ LIFETIME ACHIEVEMENT AWARD



*This year's Karl Storz Lifetime Achievement Award Winner is Dr. Peter Alken.*

Dr. Alken was born August 26, 1942 in Berlin and attended both the Free University of Berlin and the University of Vienna from 1962–1969 and received degrees in both Medicine and Chemistry. He received his State Approbation in Medicine for Germany in 1970. Dr. Alken became a qualified and licensed surgeon in 1976 and was on staff at Northwest Hospital in Frankfurt from 1970–1976. He became a qualified and licensed urologist in 1979 and was on staff at University Hospital Mainz from 1976–1987.

## Academic Appointments

Dr. Alken was an Assistant and later an Associate Professor at the University of Mainz. He received these appointments in 1982 and 1983 respectively. In 1987 he was appointed Professor of Urology at the University of Heidelberg and served as the department head and chairman for the Department of Urology, University Clinic Mannheim, Heidelberg Medical School.

## Medical Societies

German Society of Urology (DGU)  
American Urological Association (AUA)  
European Association of Urology (EAU)  
International Society of Urology (SIU)  
European Intra-Renal Surgery Society  
Urological Research Society

Correspond. Member Chilean Soc. of Urology  
Honorary Member European Society of Urology  
Honorary Member Georgian Society of Urology  
Honorary Member German Society of Urology  
Honorary Member Swiss Society of Urology  
Honorary Member Turkish Society of Urology  
Honorary President German Society of Residents in Urology  
Honorary member Working group Urolithiasis DGU

## Official Duties

Board member of the German Society of Urology (International Relations Office)	1997–2003
President Southwestern German Society of Urology	1998
President German Society of Urology (DGU)	2003
Working group minimal invasive Urology DGU	–
Working group Pediatric Urology DGU	–
Working group Surgical Techniques DGU	–
Scientific Committee European Society of Urology (EAU)	1992–2002
Consultant International Relation Office (EAU)	2009–

European Board of Urology:	
National Delegate, Manpower Committee	1998–2001
Advisory Board European Symp. Stone disease	1991–1999
Advisory Board European Urolithiasis Society	1999–2007
Consultant German Research Foundation (DFG)	1996–2003
Scientific Advisory Committee, (EORTC European Organization for Research and Treatment of Cancer)	1998–2006
Commission for Research—University of Heidelberg	1995–1999
Deputy Medical Director Mannheim Hospital	1996
Medical Director Mannheim Hospital	1997–1998

### **Publications**

356 pub med listed publications (9.2009)  
Textbook Urologie Thieme Verlag 1997

### **Editor**

### **Scientific Prize Awards**

International Society of Urol. Endoscopy	1978, 1981
American Urological Association	1982, 1987
German Society of Urology	1982, 1985, 1987, 1995, 1996, 1997, 1998, 1999, 2000, 2001, 2002, 2004 2005, 2006
Ritter von Frisch Award German Society of Urology	2005
World Congress on Endourology and SWL	2000
Southwest-German Society of Urology	1999, 2002, 2004, 2006
Gustav Simon Medal South Western German Society of Urology	2008
C. E. Alken Award	1991
Kabi Pharmacia Award Forum Urodynamicum	1992

Present Position: Retired Head and Chairman  
Dept. Urology University Clinic Mannheim, Heidelberg Medical School  
Theodor-Kutzer-Ufer 1-3 D-68163 Mannheim Germany  
Phone: 0621 383 4953  
Fax: 0621 383 1471  
E-mail: peter.alken@umm.de

## SCIENTIFIC PROGRAM

Tuesday, October 6, 2009

### Society Meetings

14.00–17.30

Atlanta

#### SM1

##### EAU-section of Urotechnology (ESUT)-Session: "Sparing the Nephron"

*Program chairman: G. Breda, Italy*

SM1.1

##### Introduction

*G. Breda, Italy*

##### Nephron sparing laparoscopic surgery

*Moderators: G. Breda, Italy*

*C. Abbou, France*

*P. Fornara, Germany*

SM1.2

##### Laparoscopic renal cooling in partial nephrectomy

*M.S. Michel, Germany*

SM1.3

##### How to reduce ischaemic time in partial nephrectomy

*G. Janetschek, Austria*

SM1.4

##### How to maximize nephron sparing in living donor nephrectomy and subsequent kidney transplant

*A. Breda, Spain*

SM1.5

##### Can robotic surgery spare more nephrons than simple laparoscopy?

*A. Mottrie, Belgium*

##### Sparing the nephron in thermal ablation

*Moderators: F. Keeley, United Kingdom*

*U. Witzsch, Germany*

*A. Breda, Spain*

SM1.6

##### Laparoscopic assisted thermal ablation in renal tumors

*G. Guazzoni, Italy*

SM1.7

##### Percutaneous assisted thermal ablation in renal tumors

*A. Gangi, France*

SM1.8

##### Extracorporeal thermal ablation in renal tumors

*C. Klingler, Austria*

SM1.9

##### Which will be the winner in the short and long run (balancing oncologic/ functional outcome, complications, and costs)?

*M.P. Laguna, The Netherlands*

15.45–16.15

16.15–17.30

##### Coffee Break

##### Sparing the nephron in kidney stones

*Moderators: G. Alivizatos, Greece*

*T. Knoll, Germany*

*H-G. Tiselius, Sweden*

SM1.10

##### How to minimize renal trauma in ESWL

*K-U. Koehrmann, Germany*

SM1.11

##### How to minimize trauma in PCNL

*A. Skolarikos, Greece*

SM1.12

##### How to minimize trauma in RIRS

*M. Brehmer, Sweden*

SM1.13

##### How to manage UPLO and concomitant kidney stones

*A. Skolarikos, Greece*

##### Sparing the nephron in UT-TCC

*Moderators: V. Bucuras, Romania*

*J. Palou, Spain*

*A. Patel, United Kingdom*

SM1.14

##### Imperative conservative management of upper tract TCC

*A. Joyce, United Kingdom*

SM1.15

##### Elective conservative management of upper tract TCC

*D. Tolley, United Kingdom*

SM1.16

##### Enhanced diagnostic and follow up of upper tract TCC

*O. Traxer, France*

14.00–18.00

#### SM2

Sydney	<b>Joint Meeting of Asian Endourology and WCE</b>
	<i>Program chairman: T. Matsuda, Japan</i>
14.00–14.05	<b>The opening remark</b>
SM2.1	<i>M. Desai, India</i>
14.05–14.50	<b>LESS in Asia</b>
	<i>Moderators: S. Baba, Japan</i>
	<i>A. Chiu, Taiwan</i>
SM2.2	<b>LESS for donor nephrectomy</b>
	<i>A. Ganpule, India</i>
SM2.3	<b>LESS for VVF and BPH</b>
	<i>P.P. Rao, India</i>
SM2.4	<b>LESS surgery in Korea</b>
	<i>H.H. Kim, Korea</i>
SM2.5	<b>LESS surgery in Japan</b>
	<i>A. Kawauchi, Japan</i>
SM2.6	<b>LESS Pyeloplasty</b>
	<i>A. Kurian, India</i>
14.50–15.50	<b>Laparoscopic and Robotic surgeries in Asian countries</b>
	<i>Moderators: T.Y. Lee, Korea</i>
	<i>W.S. Chan, Hongkong</i>
	<b>Partial Nephrectomy:</b>
SM2.7	<b>Laparoscopic partial nephrectomy</b>
	<i>C. Yin, China</i>
SM2.8	<b>Robotic partial nephrectomy</b>
	<i>Y. Seo, Korea</i>
	<b>Radical Prostatectomy:</b>
SM2.9	<b>Laparoscopic radical prostatectomy</b>
	<i>T. Terachi, Japan</i>
SM2.10	<b>Robotic radical prostatectomy</b>
	<i>S. Yip, Hongkong</i>
	<b>Radical cystectomy:</b>
SM2.11	<b>Laparoscopic radical cystectomy</b>
	<i>A. Chiu, Taiwan</i>
SM2.12	<b>Robotic radical cystectomy</b>
	<i>G.T. Sung, Korea</i>
15.50–16.10	<b>Coffee Break</b>
16.10–17.00	<b>Endourology in 2009</b>
	<i>Moderators: X. Nianzeng, China</i>
	<i>M. Wong, Singapore</i>
	<b>Tips of safe and rapid PCNL</b>
SM2.13	<b>Tips for PCNL</b>
	<i>X. Li, China</i>
SM2.14	<b>Mini PCNL</b>
	<i>S-K Li, Hongkong</i>
SM2.15	<b>For staghorn calculi</b>
	<i>M. Arjun, India</i>
SM2.16	<b>f-TUL for renal stones</b>
	<i>M. Wong, Singapore</i>
SM2.17	<b>New endourological diagnosis of bladder tumor</b>
	<i>K. Fujimoto, Japan</i>
17.00–17.50	<b>Introduction of Endourological Societies in Asian countries</b>
	<i>Moderators: T. Matsuda, Japan</i>
	<i>G.T. Sung, Korea</i>
SM2.18	<b>Asian Society of Endourology</b>
	<i>M. Desai, India</i>
SM2.19	<b>East Asian Society of Endourology</b>
	<i>S. Naito, Japan</i>
SM2.20	<b>China</b>
	<i>X. Nianzeng, China</i>
SM2.21	<b>India</b>
	<i>D. Kirpekar, India</i>
SM2.22	<b>Hongkong</b>
	<i>W.S. Chan, Hongkong</i>
SM2.23	<b>Japan</b>
	<i>S. Baba, Japan</i>
SM2.24	<b>Korea</b>
	<i>H.H. Kim, Korea</i>

SM2.25	<b>Philippine</b> <i>J. Aldana, Philippine</i>
SM2.26	<b>Singapore</b> <i>M. Wong, Singapore</i>
SM2.27	<b>Taiwan</b> <i>A. Chiu, Taiwan</i>
17.50–18.00	<b>Closing remark</b> <i>T. Matsuda, Japan</i>
14.00–18.00 Barcelona	<b>SM3</b> <b>Joint Meeting of Sociedad latinoamericana de cirugia de invasion minima en Urologia (SOLCIMI) and Confederacion Americana de Urologia (CAU)</b> <i>Program chairman J. Gutierrez, Mexico</i>
14.00–16.00	<b>Endourology/Endourologia</b> <i>Moderator: J. Gutierrez, Mexico</i>
SM3.1	<b>SWL: recommendations to improve clinical results based on physical principles/</b> <i>LEC: recomendaciones para mejorar resultados clínicos basadas en principios físicos</i> <i>A. Loske, Mexico</i>
SM3.2	<b>Expulsive therapy, does it help?/Terapia medica expulsiva, realmente ayuda?</b> <i>G. Preminger, USA</i>
SM3.3	<b>PCNL supine approach, lots of interest after so many years, why?/</b> <i>NLPC abordaje supino, mucho interés después de tantos años, porque?</i> <i>P. Daels, Argentina</i>
SM3.4	<b>Combined approach, when and how?/Abordaje combinado, cuando y como?</b> <i>N. Bernardo, Argentina</i>
SM3.5	<b>Infectious complications after PCNL and Endourology—a nightmare/</b> <i>Complicaciones Infecciosas de NLPCN y Endourología—una pesadilla</i> <i>J. Gutierrez, Mexico</i>
SM3.6	<b>Is there any real innovation in Ureteroscopy?/Existe alguna real innovación en ureteroscopia?</b> <i>G. Fuchs, USA</i>
16.00–16.20	<b>Coffee Break</b>
16.20–18.00	<b>Laparoscopy/Laparoscopia</b> <i>Moderator: R. Sotelo, Venezuela</i>
SM3.7	<b>Management of the small renal mass: observation vs. ablation vs excision/</b> <i>Manejo de masas renales pequeñas: observacion vs. ablacion vs. excision</i> <i>J. Cadeddu, USA</i>
SM3.8	<b>Current status of robotic renal surgery: where are we headed?/</b> <i>Estado actual de la cirugia robotica en cirugia renal, a donde hemos llegado?</i> <i>F. Kim, USA</i>
SM3.9	<b>Robotic pyeloplasty: the end of endopyelotomy?/Pieloplastia robotica;</b> <i>el final de la endopielotomia?</i> <i>R. Leveille, USA</i>
SM3.10	<b>Radical laparoscopic cystectomy; tips and tricks/Cistectomia radical laparoscopica;</b> <i>trucos y secretos</i> <i>O. Castillo, Chile</i>
SM3.11	<b>NOTES and LESS in Urology/NOTES and LESS en Urologia</b> <i>R. Sotelo, Venezuela</i>
	<b>Basic Research Forum</b> <i>Program Chairmen: J. Lingeman, USA</i> <i>J. Denstedt, Canada</i>
14.00–15.30 Klenze	<b>BR1</b> <b>Basic Research Forum: Laparoscopy</b> <i>Moderators: M. Burchardt, Germany</i> <i>D. Lee, USA</i>
14.00–15.30 Holl	<b>BR2</b> <b>Basic Research Forum: Endourology 1</b> <i>Moderators: L. Defidio, Italy</i> <i>R. Hofmann, Germany</i>
14.00–15.30 Garmisch	<b>BR3</b> <b>Basic Research Forum: Urolithiasis</b> <i>Moderators: C. Tuerk, Austria</i> <i>K. Sarica, Turkey</i>
14.00–15.30 Partenkirchen	<b>BR4</b> <b>Basic Research Forum: BPH</b> <i>Moderators: R. Babayan, USA</i> <i>H. Ho, Singapore</i>



16.00–17.30 Klenze	<b>BR5</b> <b>Basic Research Forum: Shock wave lithotripsy</b> <i>Moderators:</i> J. Lingeman, USA J. Thürrhoff, Germany
16.00–17.30 Holl	<b>BR6</b> <b>Basic Research Forum: Endourology II</b> <i>Moderators:</i> R. Sweet, USA J. Denstedt, Canada
16.00–17.30 Garmisch	<b>BR7</b> <b>Basic Research Forum: New Technology</b> <i>Moderators:</i> D. Stoianovic, USA H. Winfield, USA
16.00–17.30 Partenkirchen	<b>BR8</b> <b>Basic Research Forum: Oncology</b> <i>Moderator:</i> P. Puppo, Italy
V-poster Sessions München I 14.00–15.30	<b>VP1</b> <b>Laparoscopy—Kidney I</b> <i>Moderators:</i> C. Bilen, Turkey F. Porpiglia, Italy
München II 14.00–15.30	<b>VP2</b> <b>Reconstructive Laparoscopy 1</b> <i>Moderators:</i> M. Ramalingam, India M. Conradie, South Africa
München I 16.00–17.30	<b>VP3</b> <b>Ureterscopy 1</b> <i>Moderators:</i> M. Sofer, USA B. Petrut, Romania
München II 16.00–17.30	<b>VP4</b> <b>PCNL I</b> <i>Moderators:</i> R. Honey, Canada U. Altug, Turkey

### Wednesday, October 7, 2009

#### Educational Courses

6.30–7.45 Klenze	<b>EC1</b> <b>Laparoscopy &amp; Robotics: The role of simulators</b> <i>Chairman:</i> E. McDougall, USA
6.30–7.45 Holl	<b>EC2</b> <b>Laparoscopy and robotic assisted pediatric Urology</b> <i>Chairman:</i> D. Teber, Germany
6.30–7.45 Atlanta	<b>EC3</b> <b>Laparoscopic and robotic complications—Rare videos and live saving pearls</b> <i>Chairman:</i> R. Sotelo, Venezuela
6.30–7.45 Sidney	<b>EC4</b> <b>New trends in percutaneous nephrolithotomy (PCNL)</b> <i>Chairman:</i> T. Knoll, Germany
6.30–7.45 Barcelona	<b>EC5</b> <b>NOTES in Urology—what you need to know?</b> <i>Chairman:</i> M. Gettman, USA
6.30–7.45 Garmisch	<b>EC6</b> <b>Imaging of Prostate Cancer</b> <i>Chairman:</i> T. de Reijke, The Netherlands

#### Plenary Session

Main Auditorium  
7.45–13.00

10.00–13.00

**P1**  
*Moderators:* G. Badlani, USA  
C. Chaussy, Germany  
J. Rassweiler, Germany

**LC 1**  
**Live-Surgery 1: Kidney and Ureter**  
*Moderators:* M. Grasso, USA  
M. Hohenfellner, Germany  
Y. Siegel, Israel

#### Subplenary Sessions

Atlanta  
10.30–12.00

**SP 1**  
**Surgical Navigation**  
*Chairman:* L-M Su, USA

**Subplenary Session**

Sydney  
10.30–12.00

**SP2****Greenlight (PVP) laser prostatectomy: British channel or TURP cavity?**

Chairmen: *G. Alivizatos, Greece*  
*F. Gomez Sancha, Spain*

**Subplenary**

Atlanta  
12.00–13.00

**SP3****Partial nephrectomy—minimizing ischemic damage**

Chairman: *C. Sundaram, USA*

**Video Session**

Barcelona  
10.30–12.00

**VS1****Benign prostatic hyperplasia/LUTS**

Moderators: *P. Boonyapanichskul, Thailand*  
*B. Octay, Turkey*

**V-poster Sessions**

München I  
10.30–12.00

**VP5****Robotics Kidney**

Moderators: *J. Porter, USA*  
*R. Munver, USA*

München II  
10.30–12.00

**VP6****Education & Simulators**

Moderators: *B. Schwartz, USA*  
*C. Cheng, Singapore*

**Subplenary Sessions**

Sydney  
12.00–13.00

**SP4****Robotic microsurgery**

Chairmen: *S. Parekattil, USA*  
*A. Mottrie, Belgium*

**Podium Sessions**

Klenze  
12.00–13.00

**O1****Training and Learning curve**

Moderators: *P. Fornara, Germany*  
*T. Erdogan, Turkey*

Holl  
12.00–13.00

**O2****Localized Prostate Cancer**

Moderators: *W. Boeckmann, Germany*  
*G. Chien, USA*

**V-poster sessions**

München I  
12.00–13.00

**VP7****Laparoscopy—Kidney 2**

Moderators: *L. Kavoussi, USA*  
*M. Saito, Japan*

München II  
12.00–13.00

**VP8****LESS 1**

Moderators: *L. Richstone, USA*  
*H. Kim, Korea*

**Interactive Virtual Training**

Effner I  
12.00–13.00

**IVT1****Interactive virtual training of laparoscopic radical Prostatectomy**

Chairman: *A. Messas, France*  
Faculty: *H. van der Poel, The Netherlands*

**Subplenary Session/Satellite**

Atlanta  
14.00–15.30

**SP5****Optimized management of superficial TCC**

Chairman: *C. Stief, Germany*

**Video Sessions**

Klenze  
14.00–15.30

**VS2****Female urology and incontinence**

Moderators: *A. Lampel, Germany*  
*N. Kekre, India*

Holl  
14.00–15.30

**VS3****Reconstructive Laparoscopy 1**

Moderators: *N. Simforoosh, Iran*  
*M. Hatzinger, Germany*

Barcelona  
14.00–15.30

**VS4****Laparoscopy—Kidney 1**

Moderators: *M. Stifelman, USA*  
*C. Eisele, United Kingdom*

**V-poster**  
München I  
14.00–15.30

München II  
14.00–15.30

**Moderated Poster Sessions**

Asam II  
14.00–15.30

Effner II  
14.00–15.30

Garmisch  
14.00–15.30

Partenkirchen  
14.00–15.30

**Subplenary Session**

Atlanta  
16.00–17.30

**Video Sessions**

Klenze  
16.00–17.30

Holl  
16.00–17.30

Barcelona  
16.00–17.30

**V-poster**  
München I  
16.00–17.30

München II  
16.00–17.30

**Moderated Poster**

Asam II  
16.00–17.30

Effner II  
16.00–17.30

**VP9**  
**Ureteroscopy 2**

Moderators: M. Grasso, USA  
T. Vögeli, Germany

**VP10**

**Laparoscopy—Prostate 1**

Moderators: C. Eden, United Kingdom  
A. Alcaraz, Spain

**MP1**

**Prostate Cancer Diagnosis & Treatment**

Moderators: T. Loch, Germany  
M. Emberton, UK

**MP2**

**ESWL**

Moderators: G. Haupt, Germany  
A. Loske, Mexico

**MP3**

**Urolithiasis 1**

Moderators: D. Asismos, USA  
L. Tunc, Turkey

**MP4**

**PCNL 1**

Moderators: O. Negrete, Mexico  
R. Honey, Canada

**SP6**

**Hot spots from European Robotic Urology Symposium (ERUS)**

Chairmen: A. Mottrie, Belgium  
W. Artibani, Italy  
R. Gaston, France

**VS5**

**Percutaneous Surgery 1**

Moderators: A. Basiri, Iran  
A. Hoznek, France

**VS6**

**Laparoscopy Kidney 2**

Moderators: S. Abreu, Brazil  
Y. Ono, Japan

**VS7**

**New Technology**

Moderators: R. Thomas, USA  
S. Micali, Italy

**VP11**

**Imaging and new technique**

Moderators: O. Ukimura, Japan  
H. Wijkstra, The Netherlands

**VP12**

**Laparoscopy—Prostate 2**

Moderators: H. John, Switzerland  
G. Vallancien, France

**MP5**

**Bladder Cancer**

Moderators: F. Gaboardi, Italy  
A. Schilling, Germany

**MP6**

**MIS—Kidney and Adrenal**

Garmisch  
16.00–17.30

Moderators: T. Polascik, USA  
M. Hohenfellner, Germany

**MP7**  
**Transurethral Surgery**  
Moderators: W. Bischoff, Germany  
V. Bucuras, Romania

Partenkirchen  
16.00–17.30

**MP8**  
**Ureterorenoscopy**  
Moderators: D. Echtele, Germany  
V. Yalcin, Turkey

Thursday, October 8, 2009  
**Educational Courses**

6.30–7.45  
Klenze

**EC7**  
**Needle ablation on renal cancer**  
Chairman: P. Laguna, The Netherlands

6.30–7.45  
Holl

**EC8**  
**Imaging in Urology**  
Chairman: H. Wijkstra, The Netherlands

6.30–7.45  
Atlanta

**EC9**  
**LESS in Urology—indications and techniques**  
Chairman: J. Kaouk, USA

6.30–7.45  
Sydney

**EC10**  
**Laparoscopic and robotic radical prostatectomy—how to improve early continence**  
Chairman: A. Tewari, USA

6.30–7.45  
Barcelona

**EC11**  
**Ureteroscopy—RIRS**  
Chairman: F. Keeley, United Kingdom

6.30–7.45  
Garmisch

**EC12**  
**Laparoscopic and robotic cystectomy**  
Chairman: P. Wiklund, Sweden

**Plenary Session**  
Main Auditorium  
7.45–13.00

**P2**  
Moderators: R. Clayman, USA  
Y. Ono, Japan

10.00–13.00

**LC 2**  
**Live-Surgery 2: Laparoscopy and Robotics**  
Moderators: A. Hemal, USA  
P. Rimmington, United Kingdom  
A. Stenzl, Germany

**Subplenary Session**  
Atlanta  
10.30–12.00

**SP 7**  
**ESWL—ask the technician and the physician**  
Chairmen: C. Chaussy, Germany  
J. Lingeman, USA  
B. Forssmann, Germany

**Subplenary Sessions**  
Sydney  
10.30–12.00

**SP8**  
**ISUS Meeting**  
Moderators: R. Kulkarni, United Kingdom  
E. Liatsikos, Greece

**Subplenary**  
Barcelona  
10.30–12.00

**SP9**  
**MIS for BPH: why my laser is the best**  
Chairman: R. Muschter, Germany

**V-poster Sessions**  
München I  
10.30–12.00

**VP13**  
**Female Urology**  
Moderators: R. Gaston, France  
S. Bross, Germany

München II  
10.30–12.00

**VP14**  
**BPH 1**  
Moderators: R. Kuntz, Germany  
R. Ruzsat, Switzerland

**Subplenary Session**

Atlanta  
12.00–13.00  
12.00–12.30

**SP10**  
**Controversies in stone management**  
**Flexible URS—Controversies**  
Panel: G. Fuchs, USA  
J. Gutierrez, Mexico  
M.S. Michel, Germany

12.30–13.00

**PCNL—Controversies**  
Panel: M. Gupta, USA  
J.G. Valdivia, Spain  
J. Honey, Canada

**Podium Sessions**

Klenze  
12.00–13.00

**O3**  
**Renal cell carcinoma and upper tract**  
Moderators: O. Castillo, Chile  
H. Winfield, USA

Holl  
12.00–13.00

**O4**  
**Lower urinary tract**  
Moderators: G. Watson United Kingdom  
V. Laible, Germany

**Videoposter**

München I  
12.00–13.00

**VP15**  
**PCNL 2**  
Moderators: L. Munch, USA  
M. Baptistussi, Brazil

**Videoposter**

München II  
12.00–13.00

**VP16**  
**BPH 2**  
Moderators: R. Hartung, Germany  
R. Oberneder, Germany

**Stent-Workshop**

Sydney  
13.00–14.00

**SW 1**  
**News on stents (Allium-Medical)**  
Chairman: D. Yachia, Israel

**Subplenary Session**

Atlanta  
14.00–15.30

**SP11**  
**PCNL—Tips and Tricks**  
Chairman: M. Desai, India

**Video Sessions**

Klenze  
14.00–15.30

**VS8**  
**Laparoscopy—Prostate**  
Moderators: L. Richstone, USA  
S. Deger, Germany

Holl  
14.00–15.30

**VS9**  
**Retroperitoneoscopy**  
Moderators: T. Frede, Germany  
G. Bianchi, Italy

Barcelona  
14.00–15.30

**VS10**  
**Laparoscopy—Bladder**  
Moderators: P. Rimmington, United Kingdom  
X. Cathelineau, France

**V-poster Sessions**

München I  
14.00–15.30

**VP17**  
**Laparoscopy—Kidney 3**  
Moderators: I. Gill, USA  
I. Eraky, Egypt

München II  
14.00–15.30

**VP18**  
**ESWL**  
Moderators: D. Jocham, Germany  
Y.T. Moon, Korea

**Moderated Poster Sessions**

Asam II  
14.00–15.30

**MP9**  
**PCNL II**  
Moderators: M. De Sio, Italy  
T. Esen, Turkey

Effner II  
14.00–15.30

**MP10**  
**Ureteral stones**

*Moderators:* H.G. Tiselius, Sweden  
Y. Özgök, Turkey

Garmisch  
14.00–15.30

**MP11**  
**Robotic Prostate 1**

*Moderators:* J. Davis, USA  
G. Sung, Korea

Partenkirchen  
14.00–15.30

**MP12**  
**Laparoscopic Surgery**

*Moderators:* S. Strup, USA  
K.-H. Rothenberger, Germany

**Supplementary Session**  
Atlanta

16.00–17.30

**SP12 (Satellite)**

**New perspectives in the management of advanced renal cell cancer: Sequential Therapy**

*Chairman:* J. Gschwend, Germany

**Video sessions**

Klenze  
16.00–17.30

**VS11**  
**Transurethral Surgery**

*Moderators:* M. Kriegmair, Germany  
D. Yachia, Israel

Holl  
16.00–17.30

**VS12**  
**Laparoscopy—Kidney 3**

*Moderators:* A. Haferkamp, Germany  
T. Matsuda, Japan

Barcelona  
16.00–17.30

**VS13**  
**Robotics—Kidney**

*Moderators:* S. Bhayani, USA  
A. Kural, Turkey

**V-poster Sessions**

München I  
16.00–17.30

**VP19**  
**New Technology**

*Moderators:* P. Rao, India  
M. Aron, USA

München II  
16.00–17.30

**VP20**  
**Robotics—Prostate**

*Moderators:* J. Peabody, USA  
J. Witt, Germany

**Moderated Poster Sessions**

Asam II  
16.00–17.30

**MP13**  
**Imaging**

*Moderators:* S. Nakada, USA  
S. Naito, Japan

Effner II  
16.00–17.30

**MP14**  
**Laparoscopy—Kidney**

*Moderators:* S. Figenshau, USA  
S. Yip, Hongkong

Garmisch  
16.00–17.30

**MP15**  
**Robotics—Prostate 2**

*Moderators:* H. Ahn, Korea  
J. Binder, Switzerland

Partenkirchen  
16.00–17.30

**MP16**  
**Urolithiasis 3**

*Moderators:* N. Bucholz, United Kingdom  
R. Gumpinger, Germany

**Friday, October 9, 2009**

**Educational Courses**

6.30–7.45

**EC13**

Klenze	<b>Minimally invasive vaginal surgery</b>
6.30–7.45	<i>Chairman: D. Pushkar, Russia</i>
Holl	<b>EC14</b>
	<b>ESWL—Basics and principles</b>
6.30–7.45	<i>Chairman: K.U. Koehrmann, Germany</i>
Atlanta	<b>EC15</b>
	<b>TUR P—How to resect a gram per minute</b>
6.30–7.45	<i>Chairman: R. Hofmann, Germany</i>
Sydney	<b>EC16</b>
	<b>Laparoscopic and robotic adrenal surgery</b>
6.30–7.45	<i>Chairman: G. Guazzoni, Italy</i>
Barcelona	<b>EC17</b>
	<b>Robotic renal surgery</b>
6.30–7.45	<i>Chairman: A. Mottrie, Belgium</i>
Garmisch	<b>EC18</b>
	<b>Robotic radical prostatectomy—how to start</b>
	<i>Chairman: H. van der Poel, The Netherlands</i>
<b>Plenary Session</b>	
Auditorium/Ballroom	
7.45–13.00	
	<b>P3</b>
	<i>Moderators: P. van Cangh, Belgium</i>
	<i>N. Netto, Brazil</i>
10.00–13.00	<b>LC 3</b>
	<b>Live-Surgery 3: MIS for prostate</b>
	<i>Moderators: Y. Sun, China</i>
	<i>M. Elhilali, Canada</i>
	<i>T. Sulser, Switzerland</i>
<b>Subplenary Session</b>	
Atlanta	
10.30–12.00	<b>SP13</b>
	<b>Society of Urologic Robotic Surgery (SURS)</b>
	<b>Session: The Latest in Robotic Surgery</b>
	<i>Chairmen: J. Joseph, USA</i>
	<i>A. Hemal, USA</i>
	<i>Moderators: M. Annerstadt, Denmark</i>
	<i>S. Matin, USA</i>
	<i>E. Castle, USA</i>
<b>Subplenary Session</b>	
Sydney	
10.30–12.00	<b>SP 14</b>
	<b>How to improve ESWL results</b>
	<i>Chairman: J. Lingeman, USA</i>
<b>Video Session</b>	
Barcelona	
10.30–12.00	<b>VS14</b>
	<b>Robotics—Prostate</b>
	<i>Moderators: P. Parra, USA</i>
	<i>S. Siemer, Germany</i>
<b>V-poster Sessions</b>	
München I	
10.30–12.00	<b>VP21</b>
	<b>LESS II</b>
	<i>Moderators: A. Rane, United Kingdom</i>
	<i>M. Desai, USA</i>
München II	
10.30–12.00	<b>VP22</b>
	<b>Laparoscopy—Adrenal and Kidney</b>
	<i>Moderators: G. Kumar, India</i>
	<i>T. Jarrett, USA</i>
Subplenary Session	
Atlanta	
12.00–13.00	<b>SP15</b>
	<b>How to improve potency after laparoscopic and</b>
	<b>robotic radical prostatectomy</b>
	<i>Chairman: T. Ahlering</i>
<b>Subplenary Session</b>	
Sydney	
12.00–13.00	<b>SP16</b>
	<b>News for incontinence</b>
	<i>Moderators: G. Badlani, USA</i>
	<i>N. Kekre, India</i>
<b>Podium Sessions</b>	
Klenze	
12.00–13.00	<b>O5</b>
	<b>Upper urinary tract</b>

Holl 12.00–13.00	<i>Moderators:</i> D. Bagley, USA P. Kandarp, India
<b>V-poster Sessions</b> München I 12.00–13.00	<b>O6</b> <b>Bladder and Prostate Cancer</b> <i>Moderators:</i> M. Galluci, Italy A. Stenzl, Germany
München II 12.00–13.00	<b>VP23</b> <b>Endoscopy</b> <i>Moderators:</i> J. R. Andersen, Denmark C. Wülfing, Germany
<b>Interactive Virtual Training</b> Effner I 12.00–13.00	<b>VP24</b> <b>Pediatrics</b> <i>Moderators:</i> W. Rösch, Germany J. Seybold, Germany
<b>Subplenary Session</b> Atlanta 14.00–15.30	<b>IVT2</b> <b>Interactive virtual training of laparoscopic radical Prostatectomy</b> <i>Chairman:</i> A. Messas, France <i>Faculty:</i> H. van der Poel, The Netherlands
<b>Video Sessions</b> Klenze 14.00–15.30	<b>SP 17</b> <b>NOTES—group session</b> <i>Chairman:</i> M. Gettman, USA
Holl 14.00–15.30	<b>VS15</b> <b>Reconstructive Laparoscopy</b> <i>Moderators:</i> M. Menon, USA S. Baba, Japan
Barcelona 14.00–15.30	<b>VS16</b> <b>Robotics—Bladder</b> <i>Moderators:</i> P. Wiklund, Sweden G. Wu, USA
<b>V-poster Sessions</b> München I 14.00–15.30	<b>VS17</b> <b>Laparoscopy—Urolithiasis</b> <i>Moderators:</i> J. Desai, India J. Cresswell, United Kingdom
München II 14.00–15.30	<b>VP25</b> <b>Laparoscopy—Bladder</b> <i>Moderators:</i> F. Porpiglia, Italy G. Haber, USA
<b>Moderated Poster Sessions</b> Asam II 14.00–15.30	<b>VP26</b> <b>PCNL 3</b> <i>Moderators:</i> E. Montanari, Italy B. Auge, USA
Effner II 14.00–15.30	<b>MP17</b> <b>Robotics—Kidney</b> <i>Moderators:</i> M. Bhandari, USA F. Kim, USA
Garmisch 14.00–15.30	<b>MP18</b> <b>Miscellaneous</b> <i>Moderators:</i> R. Leveilee, USA R. Horsch, Germany
Partenkirchen 14.00–15.30	<b>MP19</b> <b>Laparoscopy &amp; Robotics—Upper urinary tract</b> <i>Moderators:</i> R. Nadler, USA Z. Acetin, Turkey
	<b>MP20</b> <b>Laparoscopy—Kidney 2</b> <i>Moderators:</i> M. Galluci, Italy J. Cheon, Korea



## Subplenary Sessions

Atlanta  
16.00–17.30

Sydney  
16.00–17.30

## Video Sessions

Klenze  
16.00–17.30

Holl  
16.00–17.30

Barcelona  
16.00–17.30

## V-Poster

München I  
16.00–17.30

München II  
16.00–17.30

Assam II  
16.00–17.30

Effner II  
16.00–17.30

Garmisch  
16.00–17.30

Partenkirchen  
16.00–17.30

Saturday, October 10, 2009

## Educational Courses

6.30–7.45  
Klenze

6.30–7.45  
Holl

6.30–7.45  
Atlanta

6.30–7.45  
Sydney

6.30–7.45  
Barcelona

### SP18

#### Nightmares in Endourology

Chairman: *M.S. Michel, Germany*

### SP19

#### Update of 2nd International Meeting on Focal Therapy: Tulips from Amsterdam

Chairman: *J. de la Rosette, The Netherlands*

### VS18

#### Laparoscopy—Kidney

Moderators: *M. Desai, USA*  
*H. Villavicencio, Spain*

### VS19

#### Laparoscopy—Adrenal

Moderators: *K. Suzuki, Japan*  
*R. Sotelo, Venezuela*

### VS20

#### Reconstructive Laparoscopy 3

Moderators: *R. Thomas, USA*  
*G. Breda, Italy*

### VP27

#### Laparoscopy—Kidney 4

Moderators: *J. Date, India*  
*M. Beer, Germany*

### VP28

#### Miscellaneous

Moderators: *N. Simforoosh, Iran*  
*M. Hruza, Germany*

### MP21

#### Pediatrics and Upper tract

Moderators: *W. Feitz, The Netherlands*  
*J. Steven, Belgium*

### MP22

#### Endourology for nephrolithiasis

Moderators: *M. Stoller, USA*  
*A. Sahin, Turkey*

### MP23

#### Lower urinary tract

Moderators: *T. Sulser, Switzerland*  
*H.J. Keller, Germany*

### MP24

#### Endourology—upper urinary tract

Moderators: *T. Lopes, Portugal*  
*A. Hegele, Germany*

### EC19

#### Female Urology: Tips and Tricks of Minimally Invasive therapy

Chairman: *G. Badlani, USA*

### EC20

#### HIFU for prostate cancer

Chairman: *W. Wieland, Germany*

### EC21

#### How to learn HoLEP

Chairman: *P. Gilling, New Zealand*

### EC22

#### Laparoscopic and robotic reconstructive surgery

Chairman: *H. Winfield, USA*

### EC23

#### Management of large renal tumors

Chairman: *G.T. Sung, Korea*

6.30–7.45  
Garmisch  
**EC24**  
**MIS in transplants**  
Chairman: C. Cheng, Singapore

**Plenary Session**  
Auditorium/Ballroom  
7.45–13.00

**P4**  
Moderators: J. Rassweiler, Germany  
C. Chaussy, Germany  
A. Shalav, USA

### Hands-on Education and Masterclasses

#### Masterclasses in Endourology

Wednesday, October 7, 2009

Asam I  
14.00–15.30

**MC1 (Cook)**  
**Endourology I**  
Course Directors: M. Wong, Singapore  
A. Joyce, United Kingdom

Effner I  
14.00–15.30

**MC2 (Boston Scientific)**  
**Advances in Ureterscopy—From Theory to Practice**  
Course Director: D. Bagley, USA

Asam I  
16.00–17.30

**MC3 (Cook)**  
**Endourology III**  
Course Directors: M. Wong, Singapore  
A. Joyce, United Kingdom

Effner I  
16.00–17.30

**MC4 (Olympus)**  
**LESS—Laparo-Endoscopic-Single-Site Surgery: Advances in a new technique**  
Course Directors: J.U. Stolzenburg, Germany  
I. Gill, USA  
E. Barret, France

#### Masterclasses in Endourology

Thursday, October 8, 2009

Asam I  
14.00–15.30

**MC5 (Cook)**  
**Endourology V**  
Course Directors: G. Fuchs, USA  
J. Gutierrez, Mexico

Effner I  
14.00–15.30

**MC6 (Boston Scientific)**  
**PCNL—Prone, supine or both—different approach for a successful outcome**  
Course Directors: D. Tolley, United Kingdom

Asam I  
16.00–17.30

**MC7 (Cook)**  
**Endourology VII**  
Course Directors: G. Fuchs, USA  
J. Gutierrez, Mexico

Effner I  
16.00–17.30

**MC8 (Olympus)**  
**Endourologic diagnosis & stone management: What is new?**  
Course Directors: O. Traxer, France  
A. Patel, United Kingdom  
M. Pearle, USA  
A. Martov, Russia

#### Masterclasses in Endourology

Friday, October 9, 2009

Asam I  
14.00–15.30

**MC9 (Cook)**  
**Endourology IX**  
Course Directors: N. Bernado, Argentina  
A. Joyce, United Kingdom

Effner I  
14.00–15.30

**MC10 (Boston Scientific)**  
**Endourology X—Hospitality**  
Course Director: D. Tolley, United Kingdom  
G. Preminger, USA

Asam I  
16.00–17.30

**MC11 (Cook)**  
**Endourology XI**  
Course Directors: N. Bernado, Argentina  
A. Joyce, United Kingdom

Effner I  
16.00–17.30

**MC12 (Olympus)**  
**Plasma Vaporization & TURis: An update from longterm users**  
Course Directors: A. Patel, United Kingdom  
A. Bachmann, Switzerland  
O. Reich, Germany  
B. van Cleynebreugel, Belgium

**Hands-on training sessions**

Wednesday, October 7, 2009

Fischer  
14.00–17.00**HOT LAP1**Course Directors: *J. Klein, Germany*  
*T. Frede, Germany***Hands-on training**

Gärtner

**HOT URS1**Course Directors: *O. Traxer, France*  
*S. Lahme, Germany***Hands-on training**

Bürklein

**HOT TUR1**Course Directors: *R. Muschter, Germany*  
*H. Leyh, Germany***Hands-on training sessions**

Thursday, October 8, 2009

Fischer  
14.00–17.00**HOT LAP2**Course Directors: *J. Klein, Germany*  
*O. Castillo, Chile***Hands-on training**

Gärtner

**HOT URS2**Course Directors: *O. Traxer, France*  
*C. Tuerk, Austria***Hands-on training**

Bürklein

**HOT TUR2**Course Directors: *H. Leyh, Germany*  
*V. Bucuras, Romania***Hands-on training sessions**

Friday, October 9, 2009

Fischer

**HOT LAP3**Course Directors: *J. Klein, Germany*  
*L. Salomon, France***Hands-on training**

Gärtner

**HOT URS3**Course Directors: *O. Traxer, France*  
*A. Patel, United Kingdom***Hands-on training**

Bürklein

**HOT TUR3**Course Directors: *H. Leyh, Germany*  
*R. Muschter, Germany*

## Abstract Index

### TUESDAY, OCTOBER 6

#### BR1: LAPAROSCOPY

14:00–15:30 hr

**BR1-01** TANDEM TWO DIMENSIONAL VERSUS THREE DIMENSIONAL VIEWING IN LEARNING CURVE FOR EX VIVO SKILL ACQUISITION FOR LAPAROENDOSCOPIC SINGLE SITE SURGERY (LESS)  
S. Kommu, T. Finnigan, D. Carlidge, A. Golash, C. Luscombe, S. (sarg)—United Kingdom

**BR1-02** THE IMPACT OF A DUAL-FOCUS SYSTEM ON THE LEARNING CURVE FOR EX VIVO SKILL ACQUISITION IN A LAPAROENDOSCOPIC SINGLE-SITE SURGERY (LESS) PLATFORM  
S. Kommu, T. Finnigan, A. Chakravarti, A. Golash, C. Luscombe, C. Eden—United Kingdom

**BR1-03** THE EFFECT OF A NOVEL HEMOSTATIC AGENT, ANKAFERD BLOODSTOPPER® (ABS), ON RENAL TUBULAR APOPTOSIS IN RAT PARTIAL NEPHRECTOMY MODEL  
E. Huri, T. Akgül, M. Astarci, H. Üstün, C. Germiyanoglu—Turkey

**BR1-04** HISTOLOGICAL EVALUATION OF RENAL TUMORS AFTER HYPERTONIC SALINE SOLUTION PERFUSION IN A KIDNEY REDUCTION MODEL FOR LAPAROSCOPIC SURGERY  
J. Manzano, E. Vicari, F. Lima, V. Ortiz, C. Andreoni

**BR1-05** IRREVERSIBLE ELECTROPORATION (IRE): A NOVEL METHOD FOR RENAL TISSUE ABLATION  
C. Tracy, W. Kabbani, J. Cadeddu—USA

**BR1-06** PRELIMINARY INVESTIGATIONS WITH IRREVERSIBLE ELECTROPORATION IN IN-VIVO PORCINE KIDNEYS  
R. Leveillee, N. Salas, C. Moore, M. Jorda, M. Sierra, J. Shields

**BR1-07** SURGICAL MANAGEMENT OF RENAL MASSES: TECHNOLOGY VERSUS ONCOLOGY  
J. Miller, A. Benson, T. Tarter, B. Schwartz—United States

**BR1-08** COMPARISON OF THE FREEHAND® ROBOTIC CAMERA HOLDER TO HUMAN ASSISTANTS DURING THE ENDOSCOPIC EXTRAPERITONEAL RADICAL PROSTATECTOMY (EERPE)—A PROSPECTIVE RANDOMIZED STUDY OF 50 CASES  
J. Stolzenburg, T. Franz, M. Do, K. Turner, E. Liatsikos

**BR1-09** ROLE OF ULTRASOUND GUIDED TRANSVERSUS ABDOMINIS PLANE (USTAP) BLOCK IN ANALGESIC SUPPLEMENTATION FOR LAPAROSCOPIC RADICAL PROSTATECTOMY—PRELIMINARY FINDINGS

S. Kommu, A. Crosby, Z. Hashim, A. Golash, C. Luscombe, A. Augustine—United Kingdom

**BR1-10** DYNAMIC CAMERA AND INSTRUMENT MOVEMENT DURING MINIMALLY INVASIVE UROLOGICAL SURGERY—NEED FOR A STANDARD PLATFORM FOR COMMUNICATION  
S. Kommu, T. Finnigan, A. Chakravarti, A. Golash, C. Luscombe, S. (sarg)—United Kingdom

#### BR2: ENDOUROLOGY I

14:00–15:30 hr

**BR2-01** FLOUROSCOPIC ORGAN AND TISSUE SPECIFIC RADIATION EXPOSURE BY SEX AND BMI DURING URETEROSCOPY  
N. Krupp, R. Bowman, B. Hill, K. Ebrahimi, J. Smith, D. Baldwin—USA

**BR2-02** EVALUATION OF SIX HOLMIUM:YAG OPTICAL FIBERS FOR URETEROSCOPY: WHAT'S NEW IN 2009?  
B. Knudsen, J. Teichman

**BR2-03** DESTRUCTION OF STONES IN THE KIDNEY, BLADDER AND URETER WITHOUT HARMING CATHETER AND BASKET MATERIAL USING AN INNOVATIVE LOW-ENERGY LASER SHOCKWAVE MODE  
J. Neymeyer, T. Wülfing, C. Bäcker, A. Apostolidis, M. Beer

**BR2-04** FEMTOSECOND LASER LITHOTRIPSY  
J. Teichman, J. Qiu, R. Kuranov, A. Mcelroy, T. Wang, T. Milner

**BR2-05** INSTANTLY PHASE-II TUBELESS MINI-PERCUTANEOUS NEPHROLITHOTOMY (REPORT OF 54 CASES)  
Z. xiao-feng, L. Fu-lin, Jun—China

**BR2-06** MICROCT INVESTIGATION OF THE STONES TAKEN FROM PERCUTANEOUS NEPHROLITHOTOMY AND URETEROSCOPIC STONE SURGERY WITH SOUND WAVE OR PNEUMATIC LIHTOTRIPTERS  
E. Huri, I. Tatar, C. Germiyanoglu, T. Karakan, H. Çelik, O. Ersoy—Turkey

**BR2-07** IN VIVO DETERMINATION OF URINARY STONE COMPOSITION USING DUAL ENERGY COMPUTED TOMOGRAPHY WITH ADVANCED POST-IMAGE ACQUISITION DATA PROCESSING  
D. Zilberman, M. Lipkin, M. Ferrandino, D. Boll, D. Albala, G. Preminger—USA

**BR2-08** CALCIUM PHOSPHATE STONE MORPHOLOGY: PLAIN RADIOGRAPHIC FINDINGS AND INTEROBSERVER VARIABILITIES  
H. Tokgoz, O. Turksoy, A. Yildiz, I. Unal, B. Erol, S. Toparli

**BR2-09** HYDROFLOTATION MAGNETIC AIDED ENDOLUMENAL NAVIGATION—PRELIMINARY PLATFORM IN EX-VIVO SETTING FOR THE NEXT PARADIGM IN MINIMALLY INVASIVE UROLOGICAL SURGERY  
S. Kommu—United Kingdom

**BR2-10** CHANGING IN THE FUNCTIONAL ACTIVITY OF MEGAURETER AFTER ITS ENDOSCOPIC TREATMENT IN CHILDHOOD  
Z. Sabirzianova—Russia

**BR4: BPH**  
14:00–15:30 hr

**BR4-01** A PORCINE HEART TISSUE MODEL FOR 2 MICRON CONTINUOUS WAVE LASER ENDOSCOPIC TECHNIQUE TRAINING  
G. Zhu, K. Zhang—China

**BR4-02** HISTOTRIPTY OF THE PROSTATE FOR BPH: TRANSLATION FROM CANINE TO HUMAN  
W. Roberts, J. Wheat, T. Hall—USA

**BR4-03** STANDARDIZED EX-VIVO COMPARISON OF THE 120 W VS. THE 70 W THULIUM:YAG 2 MICRON LASER: ABLATION CAPACITY, HAEMOSTASIS AND TISSUE EFFECTS  
F. Wezel, N. Huck, A. Häcker, A. Gross, M. Michel, T. Bach—Germany

**BR4-04** CAN MULTICHANNEL URODYNAMICS PREDICT OUTCOME OF MEDICAL OR SURGICAL MANAGEMENT IN MEN WITH BENIGN PROSTATIC HYPERPLASIA? RESULTS OF A PROSPECTIVE STUDY ON 100 PATIENTS  
M. Agarwal, P. Ranjan, S. Singh, R. Mavuduru, A. Mandal—India

**BR4-05** INTRODUCTION OF THE MULTI-DISCIPLINARY DIOLAS LFD 3000 LASER FOR THE EFFECTIVE TREATMENT OF BPH (BENIGN PROSTATE HYPERPLASIA), STONES, STRICTURES AND CONDYLOMATA  
J. Neymeyer, T. Wülfing, W. Abdul-wahab al-ansari, C. Bäcker, A. Apostolidis, M. Beer

**BR4-06** ABLATION OF THE PROSTATE USING A HIGH POWER DIODE LASER (940 NM, 250 W)—PRELIMINARY CLINICAL DATA WITH 3 MONTHS FOLLOW-UP  
F. De marco, M. Rheinwald, T. Bayer—Italy

**BR4-07** HOLMIUM LASER ENUCLEATION (HOLEP) USING A LOW ENERGY LASER DEVICE COMPARED TO TRANSURETHRAL RESECTION OF THE PROSTATE (TUR-P)  
M. Kanout, M. Prescher, W. Strohmaier

**BR4-08** DEVELOPMENT OF LASER SURGERY IN BPH. A CRITICAL STATEMENT OF A NEW TECHNIQUE  
M. Loebelenz, D. Bakolas, P. Bischoff-kalb—Germany

**BR4-09** MODIFIED TRANSURETHRAL RESECTION BEFORE HIGH INTENSITY FOCUSED ULTRASOUND (RHIFU) EFFICACY AND SIDE EFFECTS: EXPERIENCE & ANALYSIS OF 1.000 CASES  
S. Thueroff, A. Neumayr, M. Bosl, H. Kiel, W. Steil, C. Chaussy

**BR4-10** ENUCLEATION OF THE PROSTATE WITH THE 2-M CONTINUOUS WAVE THULIUM LASER IN DIFFERENT EXPERIENCED SURGEONS  
C. Netsch, K. Oberhagemann, A. Gross—Germany

**BR6: ENDOUROLOGY II**  
14:00–15:30 hr

**BR6-01** THE CLINICAL ANALYSIS OF FACTORS AFFECTING BLEEDING DURING MINIMALLY INVASIVE PERCUTANEOUS NEPHROLITHOTOMY  
Z. xiao-feng, L. Fu-lin, Ri-hai—China

**BR6-02** THE EFFICACY OF LEVOBUPIVACAINE INFILTRATION TO NEPHROSTHOMY TRACT IN COMBINATION WITH INTRAVENOUS PARACETAMOL ON POSTOPERATIVE ANALGESIA IN PERCUTANEOUS NEPHROLITHOTOMY PATIENTS  
O. Gokten, H. Kilicarslan, H. Dogan, G. Turker, Y. Kordan—Turkey

**BR6-03** ANATOMIC RATIONALE FOR PERCUTANEOUS NEPHROLITHOTOMY IN THE PRONE AND PRONE-FLEXED POSITIONS  
A. Ray, D. Chung, K. Pace, R. Honey

**BR6-04** NON-CONTACT INFRARED TEMPERATURE MEASUREMENT OF ULTRASONIC LITHOTRIPTY HANDPIECES—AN IN VITRO COMPARISON OF COMMONLY USED LITHOTRIPTY DEVICES  
C. Keil, P. Olbert, F. Brüning, L. Skrobek, R. Hofmann—Deutschland

**BR6-05** COMPARATIVE EVALUATION OF INERTIAL FORCES GENERATED BY ULTRASONIC LITHOTRIPTYORS  
B. Knudsen

**BR6-06** CLOSED EXTERNAL END DOUBLE J CATHETER AS A NEPHROSTENT IN PYELOPLASTY FOR VERY SMALL CHILDREN WITH URETERO-PELVIC JUNCTION OBSTRUCTION  
S. Rabani—Iran

**BR6-07** THE POLYSCOPE®—A MODULAR DESIGN, SEMI-DISPOSABLE FLEXIBLE URETERORENOSCOPE SYSTEM  
M. Bader, S. Walther, Y. Hocaoglu, C. Gratzke, C. Stief, O. Reich—Germany

**BR6-08** RESISTANCE TO EXTRINSIC COMPRESSION AND MAINTENANCE OF INTRALUMINAL FLOW IN COIL REINFORCED STENTS (SILHOUETTE® SCAFFOLD DEVICE): AN IN VITRO STUDY  
R. Miyaoka, K. Hendlin, M. Monga

**BR6-09** DURABILITY OF THE NEXT-GENERATION FLEXIBLE FIBEROPTIC URETEROSCOPES: A RANDOMIZED PROSPECTIVE MULTI-INSTITUTIONAL CLINICAL TRIAL  
B. Knudsen, R. Miyaoka, K. Shah, T. Turk, R. Pedro, M. Monga

**BR6-10** LOW DOSE CT FOR FOLLOW-UP OF UROLITHIASIS—ITS EFFECTIVENESS IN THE SETTINGS OF THE UROLOGY CLINIC  
D. Zilberman, M. Lipkin, M. Ferrandino, D. Frush, E. Paulson, G. Preminger—USA

### **VP1: LAPAROSCOPY-KIDNEY 1**

14:00–15:30 hr

**VP1-01** LAPAROSCOPIC PARTIAL NEPHRECTOMY FOR RENAL TUMORS GREATER THAN 4 CM: A COMPARATIVE STUDY  
D. Lifshitz, S. Shikanov, T. Deklaj, M. Katz, K. Zorn, A. Shalhav

**VP1-02** LAPAROSCOPIC CRYOABLATION OF SMALL RENAL MASSES  
K. Sahadevan, J. Dominguez, P. Mehrotra, R. Marsh, P. Johnson

**VP1-03** TUMOR IN SOLITARY KIDNEY: LAPAROSCOPIC PARTIAL NEPHRECTOMY VERSUS LAPAROSCOPIC CRYOABLATION  
G. Haber, S. Crouzet, M. Lee, K. Kamoi, J. Kaouk, G. Inderbir—USA

**VP1-04** PREDICTING FACTOR FOR RENAL FUNCTION DECREASE AFTER LAPAROSCOPIC PARTIAL NEPHRECTOMY  
K. Kamoi, S. Crouzet, G. Haber, A. Kawachi, T. Miki, I. Gill—Japan

**VP1-05** SEALED BLADDER CUFF TECHNIQUE DURING LAPAROSCOPIC NEPHROURETERECTOMY UTILIZING THE LIGASURE™ ELECTROSURGICAL DEVICE: LABORATORY AND CLINICAL EXPERIENCE

S. Herrell, E. Lambert, H. Altamar, L. Schacter, G. Moeckel, N. Miller

**VP1-06** LAPAROSCOPIC PARTIAL NEPHRECTOMY AT BOSTON MEDICAL CENTER: A SINGLE SURGEON'S EXPERIENCE AND OUTCOMES  
R. Dickstein, S. Ganick, M. Geltzeiler, R. Babayan, D. Wang—USA

**VP1-07** IS THERE A SELECTION BIAS BETWEEN SURGEONS IN CHOOSING LAPAROSCOPIC NEPHRON-SPARING SURGERIES FOR SMALL RENAL MASSES?  
R. Bhavsar, N. Hamilton, T. Yoost, H. Clarke, J. Picard, S. Savage—United States

**VP1-08** LAPAROSCOPIC PARTIAL NEPHRECTOMY WITH SEGMENTAL RENAL ARTERY CLAMPING  
Y. Changjun

**VP1-09** HEMOSTASIS BY USING THE ARGON BEAM COAGULATION (ABC) WITHOUT CLAMPING RENAL ARTERY IS SUFFICIENT IN SOLITARY PERIPHERAL T1A RENAL TUMORS TREATED WITH LAPAROSCOPIC NEPHRON SPARING SURGERY (NSS)  
O. Sanli, T. Mut, T. Tefik, M. Ortac, F. Ozcan, Nane—Turkey

**VP1-10** RUNNING SUTURE DURING LPN: WHICH ARE THE ADVANTAGES? RESULTS OF A COMPARATIVE STUDY  
F. Porpiglia, C. Fiori, R. Bertolo, S. Grande, I. Morra, R. Scarpa

**VP1-11** "NO CLAMP NO SUTURE" LAPAROSCOPIC PARTIAL NEPHRECTOMY FOR SMALL EXOPHYTIC RENAL TUMORS  
G. Simone, M. Ferriero, R. Papalia, S. Guaglianone, E. Forastiere, M. Gallucci

**VP1-12** LAPAROSCOPIC RADICAL NEPHRECTOMY: SINGLE CENTRE EXPERIENCE IN 128 CASES  
R. Regensburg, A. Kooistra, P. Dom

**VP1-13** LAPAROSCOPIC PARTIAL NEPHRECTOMY: A SINGLE CENTER EVOLVING EXPERIENCE  
D. Lifshitz, S. Shikanov, T. Deklaj, M. Katz, K. Zorn, A. Shalhav

**VP1-14** OPEN VERSUS LAPAROSCOPIC PARTIAL NEPHRECTOMY FOR HILAR TUMORS  
D. Snow, G. Haber, K. Kamoi, M. Lee, S. Crouzet, I. Gill—USA

**VP1-15** LAPAROSCOPIC MANAGEMENT OF STAGE- T3B RENAL CELL CARCINOMA  
M. Chiruvella

**VP1-16** LAPAROENDOSCOPIC SINGLE-SITE RADICAL NEPHRECTOMY FOR LOCALIZED RENAL CELL CARCINOMA: COMPARISON WITH CONVENTIONAL LAPAROSCOPIC SURGERY  
Y. Park, S. Lee, J. Ku, H. Jeong, C. Kwak, H. Kim

**VP1-17** SURGICAL MARGINS AFTER LAPAROSCOPIC PARTIAL NEPHRECTOMY: EXPERIENCE OF A SINGLE SURGEON  
F. Porpiglia, C. Fiori, R. Bertolo, I. Morra, S. Grande, R. Scarpa

**VP1-18** LAPAROSCOPIC NEPHRONE-SPARING SURGERY: PERI-OPERATIVE RESULTS IN RELATION TO TUMOUR SIZE  
F. Porpiglia, C. Fiori, R. Bertolo, R. Scarpa

**VP1-19** RETROSPECTIVE COMPARISON OF THE LONG-TERM RESULT OF RETROPERITONEOSCOPIC VERSUS OPEN NEPHROURETERECTOMY FOR UPPER URINARY TRACT TRANSITIONAL CELL CARCINOMA  
W. Xiaoqing

**VP1-20** EXPERIENCE WITH LAPAROSCOPIC PARTIAL NEPHRECTOMY WITHOUT VASCULAR CLAMPING  
O. Stakhovskiy, N. Benoist, M. Galiano, X. Cathelineau, F. Rozet, G. Vallancien—France

**VP2: LAPAROSCOPY RECONSTRUCTION**  
14:00–15:30 hr

**VP2-01** INTRA-OPERATIVE COMPLICATIONS OF LAPAROSCOPIC PYELOPLASTY AND TIPS AND TRICKS OF MANAGEMENT  
A. Patel, V. Jain, A. Ganpule, R. Sabnis, V. Muthu, M. Desai—India

**VP2-02** FLEXIBLE PNEUMOCYSTOSCOPY FOR RETROGRADE DOUBLE J STENTING DURING LAPAROSCOPIC PYELOPLASTY  
C. Fiori, F. Porpiglia, A. Distasio, S. Grande, R. Scarpa—Italy

**VP2-03** LAPAROSCOPY ASSISTED AUGMENTATION CYTOPLASTY (FIRST EXPERIENCES)  
F. Yalcinkaya, F. Demirel, U. Altug, M. Topcuoglu, C. Murat

**VP2-04** LAPAROSCOPIC TREATMENT OF URINARY LITHIASIS  
M. Conradie—South Africa

**VP2-05** LONG TERM FOLLOW UP OF LAPAROSCOPIC PYELOPLASTY: A SINGLE CENTRE EXPERIENCE  
R. Kapoor, R. Bansal, R. Maheshwari, A. Mandhani, A. Srivastava, M. Ansari—India

**VP2-06** IS AN EXTERNAL DRAIN NECESSARY AFTER LAPAROSCOPIC PYELOPLASTY?  
T. Schuster, E. Ohmann, K. Sternberg, K. Shahrouf, T. Averch

**VP2-07** UPDATE REPORT OF LAPAROSCOPIC MODIFIED HELLSTROM TECHNIQUE FOR MANAGING URETEROPELVIC JUNCTION OBSTRUCTION DUE TO LOWER POLE CROSSING VESSELS

A. Nouralizadeh, N. Simforoosh, A. Basiri, A. Tabibi, M. Soltani, H. Kilani—Iran

**VP2-08** LAPAROSCOPIC PYELOPLASTY USING HELLSTROM TECHNIQUE IN A 6-YEAR-OLD BOY WITH URETEROPELVIC JUNCTION OBSTRUCTION BY CROSSING VESSELS ASSOCIATED WITH HORSESHOE KIDNEY  
N. Masumori, K. Nishinaka, Y. Kunishima, T. Tanaka, N. Itoh, T. Tsukamoto—Japan

**VP2-09** LAPAROSCOPIC EXTENDED PYELITHOTOMY WITH PYELOPLASTY  
M. Ramalingam—India

**VP2-10** LAPAROSCOPIC UNDIVERSION FROM ILEAL CONDUIT TO ILEOCYSTOPLASTY  
M. Ramalingam, K. Senthil, M. Ganapathy pai—India

**VP2-11** MULTI-INSTITUTIONAL EXPERIENCE WITH LAPAROSCOPIC URETEROLYSIS IN THE TREATMENT OF URETEROPELVIC JUNCTION OBSTRUCTION  
T. Schuster, K. Sternberg, K. Shahrouf, R. Munver, T. Averch

**VP2-12** LAPROSCOPIC SCARDINO-PRINCE PYELOPLASTY FOR LONG SEGMENT URETEROPELVIC JUNCTION OBSTRUCTION-SINGLE CENTER EXPERINCE  
S. Bhat, G. Kumar—India

**VP2-13** LAPAROSCOPIC PYELOPLASTY: ARE THERE PREDICTORS FOR FAILURE?  
N. Hamilton, V. Trang, R. Jansen, S. Savage

**VP2-14** LAPAROSCOPIC URETEROLITHOTOMY: A MINIMALLY INVASIVE SECOND LINE TREATMENT  
G. Simone, C. Leonardo, R. Papalia, S. Guaglianone, M. Ferriero, M. Gallucci

**VP2-15** LAPAROSCOPIC URETEROLITHOTOMY FOR IMPACTED PROXIMAL URETERIC STONES  
A. Abusamra, A. Al-sayad—Kingdom of Saudi Arabia

**VP2-16** LAPAROSCOPIC PYELOPLASTY LONG-TERM FUNCTIONAL OUTCOME: MINIMUM 10-YEAR FOLLOW-UP  
M. Atalla, A. Herati, J. Cho, L. Kavoussi—USA

**VP2-17** LAPAROSCOPIC PYELOPLASTY FOR URETEROPELVIC JUNCTION OBSTRUCTION: KITASATO EXPERIENCE IN CONSECUTIVE 100 CASES  
D. Ishii, M. iwamura, H. Sasamoto, M. Nishi, S. Baba—Japan

**VP2-18** REOPERATIVE LAPAROSCOPIC RECONSTRUCTION FOR RECURRENT URETEROPELVIC JUNCTION OBSTRUCTION AFTER OPEN PYELOPLASTY  
S. Corvin, G. Bromberger, A. Nicklas, C. Antwerpen, H. Hammerl—Germany

**VP2-19** URETEROENTERIC ANASTOMOTIC STRICTURE: NOVEL USE OF A CUTTING BALLOON DILATOR

U. Boylu, M. Oommen, M. Raynor, B. Lee, R. Thomas—USA

**VP2-20** MICROLAPAROSCOPIC 2-MM HYBRID LAPAROSCOPIC PYELOPLASTY: A NEW COMPETITOR

D. Herrell, N. Miller, H. Altamar, E. Lambert—Tennessee USA

**BR3: UROLITHIASIS**

16:00–17:30 hr

**BR3-01** CYSTINURIA IN EUROPE: FIRST RESULTS OF AN NEWLY ESTABLISHED MULTICENTRE DATABASE

T. Knoll, D. Jocham, J. Rassweiler, J. De la rosette, G. Wendt-nordahl, P. Alken

**BR3-02** ACUTE EFFECTS OF URETERAL STONE ON URETERAL DYNAMICS IN A PORCINE MODEL: AN IN-VIVO STUDY COMPARING THE EFFECTS IN A SOLITARY KIDNEY VERSUS URETERAL STONE IN THE THE PRESENCE OF A NORMAL CONTRALATERAL KIDNEY

R. Venkatesh, N. Das, S. Labarbera, G. Baca, A. Tawfik, R. Figenschau—USA

**BR3-03** VITAMIN D RECEPTOR GENE ALW I, FOK I, APA I, AND TAQ I POLYMORPHISMS IN PATIENTS WITH URINARY STONES

I. Seo, J. Lee, S. Park, J. Rim

**BR3-06** HORMONAL PROFILES IN URINARY STONE DISEASE

A. Basiri, N. Shakhssalim, M. Azadvari, B. Golestan, M. Parvin, H. Zaki—Islamic Republic of Iran

**BR3-07** SEVERE HYPEROXALURIA AFTER ROUX-EN-Y GASTRIC BYPASS (RYGB): A TWO-YEAR LONGITUDINAL PROSPECTIVE STUDY

B. Duffey, S. Alanee, C. Kriedberg, B. Hinck, A. Moeding, M. Monga—United States

**BR3-08** ROLE OF METABOLIC SYNDROME COMPONENTS IN UROLITHIASIS

M. Binbay, E. Yuruk, T. Akman, A. Singh, A. Muslumanoglu, A. Tefekli—Turkey

**BR3-09** ETHYLENE GLYCOL-INDUCED HYPEROXALURIA INCREASES PLASMA AND RENAL TISSUE ASYMMETRICAL DIMETHYLARGININE LEVELS IN RATS: A NEW PATHOGENETIC LINK IN HYPEROXALURIA-INDUCED DISORDERS

F. Yencilek, H. Aydýn, N. Mutlu, N. Comunoglu, H. Koyuncu, K. Sarýca

**BR3-10** POLYMORPHISMS IN CALCITONIN RECEPTOR EXON ONE AND THEIR ASSOCIATION WITH CALCIUM OXALATE STONE FORMATION

N. Shakhssalim, A. Basiri, M. Hushmand, H. Pakmanesh, M. Azadvari, A. Kashi—Islamic Republic of Iran

**BR5: SWL**

16:00–17:30 hr

**BR5-01** IMPROVED STONE PHANTOMS FOR SHOCK WAVE LITHOTRIPSY

M. Lipkin, D. Zilberman, M. Ferrandino, G. Preminger, E. Esch, P. Zhong—USA

**BR5-02** A NEW ACOUSTIC LENS DESIGN FOR PRODUCING AN IDEALIZED PRESSURE WAVEFORM WITH LOW PEAK PRESSURE AND BROAD BEAM SIZE IN ELECTROMAGNETIC SHOCK WAVE LITHOTRIPTERS

P. Zhong

**BR5-03** THE LITHOTRIPSY TABLE HEIGHT: A NOVEL PREDICTOR OF OUTCOME IN EXTRACORPOREAL SWL

E. Ossandon, P. Recabal, C. Acevedo, J. Flores, F. Marchant, O. Storme

**BR5-04** IN VITRO RESPIRATORY MOTION MODEL FOR LITHOTRIPTER BEAM WIDTH ASSESSMENT

D. Zilberman, M. Lipkin, G. Sankin, N. Smith, G. Preminger, P. Zhong—USA

**BR5-05** ULTRASOUND GUIDED SWL OF KIDNEY STONES WITH AN EXTERNAL TRANSDUCER: DO VARIANCES IN TISSUE SOUND SPEED CAUSE IMAGE DISTORTIONS WHICH AFFECT THE ACCURACY OF STONE TARGETING?

T. Bayer, C. Bohris, R. Gumpinger

**BR5-06** PAIN PERCEPTION DURING SHOCK WAVE LITHOTRIPSY (SWL): DOES IT CORRELATE WITH PATIENT AND STONE CHARACTERISTICS?

H. Tokgoz, V. Hanci, O. Turksoy, B. Erol, B. Akduman, A. Mungan

**BR5-07** EXTRACORPOREAL SHOCK WAVES FOR PAIN RELIEF—HYPOTHESIS OF A NEURAL WORKING MECHANISM

O. Wess—Switzerland

**BR5-08** SIEMENS MODULARIS WITH C PLUS SHOCKHEAD: EFFECTIVE, SENSIBLE LITHOTRIPSY OF RENAL AND URETERAL CALCULI

G. Mathes, L. Mathes

**BR5-09** EXTRACORPOREAL SHOCK WAVE LITHOTRIPSY AND SHORT TERM RENAL INJURY: MULTIVARIATE ANALYSIS OF THE VARIABLES POTENTIALLY INVOLVED

M. Sighinolfi, S. Micali, S. De stefani, M. Rivalta, F. Annino, G. Bianchi



**BR5-10** SLOW SHOCK WAVE RATE AND “PAUSE-PROTECTION” PROTOCOLS REDUCE RENAL INJURY IN ESWL

J. Mcateer, A. Evan, B. Connors, R. Handa, P. Blomgren, J. Lingeman—USA

**BR7: NEW TECHNOLOGY**

16:00–17:30 hr

**BR7-01** A NOVEL CATHETER USING A PETAL-SHAPED CROSS-SECTIONAL DESIGN: AN EXPERIMENTAL STUDY IN RABBITS

S. Yinghao, Z. Qinsong, Z. Zhensheng, X. Chuanliang, L. Wenbin, Y. Yongwei

**BR7-02** PORCINE MODEL FOR ULTRASOUND GUIDED PERCUTANEOUS NEPHROLITHOTOMY

T. Zhou, Y. Sun, X. Gao—China

**BR7-03** USE OF A NOVEL SPLITTED SIDE AMPLATZ SHEATH FOR FACILITATING STONE REMOVAL IN PERCUTANEOUS NEPHROLITHOTOMY

D. Irani—Iran

**BR7-04** USE OF A NOVEL CONE TIP METALLIC DILATOR FOR ONE SHOT DILATATION OF NEPHROSTOMY TRACT IN PERCUTANEOUS NEPHROLITHOTOMY

D. Irani, E. Ghanbarifard—Iran

**BR7-05** NOVEL IN VITRO MODEL FOR STUDYING URETERAL STENT-INDUCED CELL INJURY

D. Lange, C. Elwood, S. Seney, K. Summers, B. Chew, P. Cadieux

**BR7-06** IDENTIFICATION OF CONDITIONING FILM COMPONENTS ON INDWELLING URETERAL STENTS AND THEIR ROLE IN BACTERIAL ADHESION

D. Lange, C. Elwood, A. Crowe, R. Miyaoka, M. Monga, B. Chew

**BR7-07** THIRD GENERATION CRYOSURGERY FOR PROSTATE CANCER—COMBINED EXPERIENCE OF 3 EUROPEAN CENTERS

U. Witzsch, D. Greene, T. Johansen

**BR7-08** IMAGE GUIDANCE IN ROBOT ASSISTED PROSTATECTOMY

S. Thompson, G. Penney, P. Dasgupta, D. Hawkes—United Kingdom

**BR7-09** SURFACE-BASED REGISTRATIONS IN ROBOTIC IMAGE-GUIDED KIDNEY SURGERY

H. Altamar, R. Ong, C. Glisson, R. Galloway, S. Herrell

**BR7-10** A COMPARATIVE STUDY BETWEEN AN IMPROVED NOVEL AIR CUSHION SENSOR AND A WHEELED PROBE FOR MINIMALLY INVASIVE SURGERY

D. Zbyszewski, K. Althoefer, H. Liu, L. Seneviratne, B. Challacombe, P. Dasgupta

**BR8: ONCOLOGY**

16:00–17:30 hr

**BR8-01** EVALUATION OF A NEW BIOPSY FORCEPS FOR THE UPPER URINARY TRACT TRANSITIONAL CARCINOMA (UUT-TCC)

D. Legervand, S. Alqahtani, M. Sibony, B. Merlet, O. Traxer—France

**BR8-02** NARROW BAND IMAGING (NBI) VS WHITE LIGHT ENDOSCOPIC IMAGING (WL) FOR DETECTION OF THE UPPER URINARY TRACT UROTHELIAL TUMORS (UUT-UT)

O. Traxer, S. Alqahtani, B. Geavlete—France

**BR8-03** NARROW BAND IMAGING (NBI) FOR THE DETECTION OF RESIDUAL/RECURRENT CANCEROUS TISSUE DURING SECOND TRANSURETHRAL RESECTION (TUR) OF NEWLY DIAGNOSED NON MUSCLE INVASIVE HIGH GRADE BLADDER CANCER

P. Puppo, C. Introini, F. Germinale, F. Bertolotto, A. Naselli—Italy

**BR8-04** INTRAVESICAL  $\alpha$ -RADIOIMMUNOTHERAPY OF HUMAN UROTHELIAL CARCINOMA IN AN ORTHOTOPIC XENOGRAFT MOUSE MODEL

M. Autenrieth, B. Pfost, C. Seidl, J. Gschwend, R. Senekowitsch-schmidtke—Germany

**BR8-05** MITOMYCIN DELIVERED IN HYDROGEL DELAYS BLADDER CANCER DEVELOPMENT

Y. Hou, C. Wang, J. Hu, J. Lu—China

**BR8-06** COMBINED REPETITIVE LOCAL CHEMO-HYPERThERMIA (SYNERGO<sup>®</sup>) FOR NON MUSCLE INVASIVE TRANSITIONAL CELL BLADDER CANCER (NMIBC)

F. Hasner, S. Thueroff, C. Chaussy

**BR8-07** HIGH RESOLUTION OPTICAL COHERENCE TOMOGRAPHY (OCT) ON HUMAN BLADDER CANCER AND PRE-CANCER STAGES

G. Joachim, J. Bornemann, B. Hermes, F. Spöler, R. Knüchel-clark, G. Jakse—Germany

**BR8-08** DIFFUSION-WEIGHTED(DW) MRI IN PATIENTS SELECTED FOR RADICAL CYSTECTOMY: DETECTION RATE OF PELVIC LYMPH NODE METASTASES

R. Papalia, G. Simone, S. Guaglianone, M. Ferriero, E. Forastiere, M. Gallucci

**BR8-09** MEASURING IMMUNE RESPONSES IN PROSTATE CANCER

R. Viney, G. Priti, P. Searle, E. Porfiri

**BR8-10** MULTIDETECTOR CT RENAL ANGIOGRAPHY FOR PREOPERATIVE EVALUATION OF LAPAROSCOPIC RADICAL NEPHRECTOMY  
R. Zeng, Y. Sun, X. Gao—China

**VP3: URETEROSCOPY 1**  
16:00–17:30 hr

**VP3-01** THE ROLE OF URETEROSCOPY IN RETROPERITONEAL OR PELVIC NON UROLOGIC MALIGNANCIES  
B. Petrut, F. Nechita, B. Tintila, S. Popescu, A. Irimie

**VP3-02** RETROGRADE CONSERVATIVE TREATMENT OF UPPER URINARY TRACT TRANSITIONAL CELL CARCINOMA: IS A 9.6 W MAXIMUM POWER HOLMIUM:YAG LASER SUFFICIENT TO OBTAIN A COMPLETE TUMOR ABLATION?  
L. Ruggera, P. Beltrami, A. Aloisi, F. Zattoni—Italy

**VP3-03** LONG-TERM USE OF DOUBLE IPSILATERAL INTERNAL STENTS FOR THE TREATMENT OF EXTRINSIC MALIGNANT OBSTRUCTION OF THE URETER  
M. Sofer, G. Lidawi, H. Matzkin, A. Greenstein

**VP3-04** MULTICENTER EXPERIENCE WITH METALLIC URETERAL STENTS FOR MALIGNANT AND BENIGN CHRONIC URETERAL OBSTRUCTION  
B. Knudsen, A. Modi, C. Ritch, R. Walsh, J. Landman, M. Gupta

**VP3-05** USE OF TANDEM DOUBLE J STENTS IN THE MANAGEMENT OF RECURRENT URETERAL STENOSIS AFTER KIDNEY TRANSPLANT  
R. Miyaoka, O. Duran-castro, S. Alanee, M. Monga, D. Hunter

**VP3-06** URETEROSCOPIC MANAGEMENT OF RENAL CALCULI IN SPECIAL SITUATIONS  
A. Xavier, K. De juan, R. Brites, F. Chagas dos santos, Á. M. figueiredo f<sup>2</sup> facs, J. Travassos—São Paulo

**VP3-07** URETEROSCOPIC MANAGEMENT FOR SYMPTOMATIC PARAPELVIC RENAL CYST  
S. Hosseini, A. Basiri, V. Najjaran tousi, M. Mohammadi sichani—Iran

**VP3-08** PRESTENTED VERSUS NON-PRESENTED URETERORENOSKOPIC STONE EXTRACTION: A RETROSPECTIVE STUDY  
B. Goossens, L. Van wynsberge, S. Füller, A. Lampel—Deutschland

**VP3-09** WHAT IS THE APPROPRIATE LENGTH OF URETERAL ACCESS SHEATH FOR FLEXIBLE URETEROSCOPY OF PROXIMAL URETERAL STONES?  
J. Teichman, L. Chang kit—Canada

**VP3-10** COST ANALYSIS OF FLEXIBLE URETERORENOSCOPY AFTER 630 INTERVENTIONS

P. Liske, P. Ober, Y. Aguilar, V. Zimmermanns, S. Lahme—Germany

**VP3-11** HOLMIUM:YAG LASER LITHOTRIPSY WITH SEMIRIGID URETERORENOSCOPE FOR TREATMENT OF URETERAL CALCULI (REPORT OF 1432 CASES)  
Z. Wu, Q. Ding, H. Jiang, P. Gao, J. Geng, Y. Zhang—China

**VP3-12** HOLMIUM LASER LITHOTRIPSY WITH FLEXIBLE URETEROSCOPE FOR UPPER URINARY TRACT CALCULI (REPORT OF 36 CASES)  
Z. xiao-feng, Da-zhi, J. Bo—China

**VP3-13** CLINICAL AUDIT OF FLEXIBLE URETERORENOSCOPY FOR LOWER POLE STONES IN A MAJOR UK STONE UNIT  
S. Graham, C. Nathaniel, S. Longhorn, R. Smith, T. Philp, S. Choong

**VP3-14** UPPER URETERAL CALCULUS: IS THERE A ROLE FOR SEMI RIGID URETEROSCOPY?  
V. Ramakrishnan, J. Murugesan, A. Ganapathy, K. Kailasam, B. Bansal

**VP3-15** URETEROSCPY DURING PREGNANCY WITH FOLLOW THE WIRE TECHNIQUE  
E. Ehab rifat tawfik

**VP3-16** PULSE FREQUENCY, ENERGY AND LENGTH INFLUENCE THE EFFECTIVENESS OF HOLMIUM:YAG LASER LITHOTRIPSY  
F. Wezel, C. Hammes, P. Krombach, A. Häcker, M. Michel, T. Bach—Germany

**VP3-17** URETEROSCOPIC LASER FRAGMENTATION IN THE FIRST LINE TREATMENT OF LARGE RENAL CALCULI  
S. Patel, S. Kommu, A. Jain, T. Green, A. Blacker

**VP3-18** THE ROLE OF FLEXIBLE URETERORENOSCOPY IN THE TREATMENT OF LOWER POLE RENAL STONES  
S. Willis, N. Smith, N. Hegarty, J. Glass, K. Thomas

**VP3-19** BILATERAL URETEROSCOPY ASSESSMENT AND OUTCOME  
E. Ehab rifat tawfik

**VP3-20** FLEXIBLE URETERORENOSCOPY WITH HOLMIUM LASER (6 YEARS SINGLE CENTRE EXPERIENCE)  
O. Traxer, S. Alqahtani, D. Legraverand, M. Ndoeye, M. Demesmeaker—France

**VP4: PCNL-I**  
16:00–17:30 hr

**VP4-01** PERCUTANEOUS NEPHROLITHOTOMY CAN BE PERFORMED SAFELY IN PATIENTS WHO HAVE PURULENT FLUID AT INITIAL PUNCTURE  
A. Unsal, C. Kara, B. Resorlu, I. Cicekbilek

**VP4-02** SUPRA VS. INFRA-COSTAL PCNL IN THE MODERN ERA  
K. Pace, D. Ghiculete, S. Pace, A. Ray, R. Honey—Canada

**VP4-03** SUPINE PERCUTANEOUS NEPHROLITHOTOMY WITH SUPRACOSTAL ACCESS: IS IT SAFE?  
F. Vicentini, E. Chedid neto, E. Mazzucchi, A. Danilovic, G. Ebaid, M. Srougi

**VP4-04** MINI-PNL VS. CONVENTIONAL “TUBE” PNL: IS THERE ANY BENEFIT FOR THE PATIENT?  
T. Knoll, F. Wezel, M. Michel, G. Wendt-nordahl

**VP4-05** MINIMALLY LNVASIVE PERCUTANEOUS NEPHROLITHOTOMY FOR TREATMENT OF UPPER URINARY TRACT CALCULI IN OBESE PATIENTS  
Z. xiao-feng, L. Min, X. hui—China

**VP4-06** THE CANADIAN STONEBREAKER TRIAL: A RANDOMIZED, MULTICENTRE TRIAL COMPARING THE LMA STONEBREAKER AND THE SWISS LITHOCLAST DURING PERCUTANEOUS NEPHROLITHOTOMY  
B. Chew, R. Paterson, O. Arsovska, D. Lange, D. Beiko, R. Honey, K. Pace

**VP4-07** KIDNEY-URETERAL-BLADDER CALCULUS –WHOLE URINARY TRACT STONE WITH 7 YRS RETAINED DJ STENT: MANAGED ENDOUROLOGICALLY  
T. Haresh

**VP4-08** PERCUTANEOUS NEPHROLITHOTOMY: NEPHROSTOMY OR TUBELESS OR TOTALLY TUBELESS?  
M. Istanbuluoglu, T. Cicek, B. Ozturk, M. Gonen, H. Ozkardes—Turkey

**VP4-09** PERCUTANEOUS NEPHROLITHOTOMY IN HORSE-SHOE KIDNEYS  
I. Aridogan, V. Izol, Y. Bayazit, Z. Tansug, S. Zeren—Turkey

**VP4-10** ENDOUROLOGICAL TREATMENT OF CALYCEAL DIVERTICULUM STONES— INDICATIONS AND RESULTS  
Y. Aguilar, P. Liske, V. Zimmermanns, S. Lahme

**VP4-11** PERCUTANEOUS NEPHROLITHOTOMY FOR STONES IN PATIENTS WITH HORSESHOE KIDNEY: A SINGLE-CENTRE EXPERIENCE  
A. Unsal, C. Kara, B. Resorlu, I. Cicekbilek—Turkey

**VP4-12** FLOUROSCOPIC PCNL ACCESS BY A UROLOGIST, THROUGH A MENTORED TRAINING PROGRAMME. A SERVICE EVALUATION STUDY  
A. Mangera, S. Mehta, F. Salim, J. Hall—England

**VP4-13** MINIMAL INVASIVE PCNL IN OLDER PATIENTS – ANALYSIS OF OUTCOME AND MORBIDITY IN 57 CONSECUTIVE PATIENTS AGED 70 AND ABOVE. DEPARTMENT OF UROLOGY, SILOAH ST.TRUDPERT HOSPITAL, PFORZHEIM, GERMANY  
V. Zimmermanns, P. Liske, P. Ober, S. Lahme

**VP4-14** EFFECT OF THE STONE AND PATIENT RELATED PARAMETERS ON TIME DURATION OF PERCUTANEOUS NEPHROLITOTOMY OPERATION AND THE LENGTH OF HOSPITALIZATION: ANALYSIS OF 1466 PATIENTS  
T. Akman, E. Sari, M. Binbay, K. Tepeler, A. Muslumanoglu, A. Tefekli—Turkey

**VP4-15** MINIPERC EXPERIENCE IN PEDIATRIC STONE DISEASE  
L. Günay, C. Bilen, B. Tan, K. Inci, E. Ozden, S. Elhaj—Turkey

**VP4-16** USE OF ABSORBABLE GELATIN SPONGE AS AN ADJUNCT TO “TOTALLY TUBELESS PERCUTANEOUS NEPHROLITHOTOMY”  
R. Kapoor, R. Maheshwari, A. Mandhani—India

**VP4-17** SURGICAL SKILLS LAB FOR PERCUTANEOUS RENAL ACCESS TRAINING: CONTENT VALIDATION COMPARISON BETWEEN LIVE PORCINE AND SIMULATION MODEL  
S. Mishra, A. Kurien, A. Ganpule, V. Muthu, R. Sabnis, M. Desai—India

**VP4-18** PCNL VS. MINI-PCNL FOR RENAL STONES < 4CM  
C. Hammes, F. Wezel, A. Haecker, M. Michel, T. Bach—Germany

**VP4-19** THE MINI-PERCUTANEOUS NEPHROLITHOTOMY FOR THE TREATMENT OF UPPER URINARY TRACT CALCULI IN CHILDREN (REPORT OF 73 CASES)  
Z. xiao-feng, Y. Yuan-hu, Xiao-ning—China

**VP4-20** IN GOOD ALTERNATIVE FOR THE TREATMENT OF LARGE UPPER URETER STONES: PERCUTANEOUS NEPHROURETEROLITHOTOMY  
M. Istanbuluoglu, T. Cicek, B. Ozturk, H. Ozkardes—Turkey

## WEDNESDAY, OCTOBER 7

**VP5: ROBOTICS KIDNEY**  
10:30–12:00 hr

**VP5-01** ROBOT-ASSISTED LAPAROSCOPIC PARTIAL NEPHRECTOMY: RESULTS OF FIRST 50 CASES WITH ANALYSIS OF LEARNING CURVE  
G. De naeyer, M. Sangalli, P. Schatteman, P. Carpentier, E. Fonteyne, A. Mottrie

**VP5-02** ROBOT ASSISTED PARTIAL NEPHRECTOMY: EARLY OUTCOMES IN 150 PATIENTS  
E. Weise

**VP5-03** TRANSITION FROM LAPAROSCOPIC TO ROBOTIC PARTIAL NEPHRECTOMY: THE LEARNING CURVE FOR AN EXPERIENCED LAPAROSCOPIC SURGEON  
H. Lavery, A. Small, R. Mark, D. Samadi, M. Palese—USA

**VP5-04** ROBOT ASSISTANCE INCREASES THE UTILIZATION OF LAPAROSCOPIC NEPHRON SPARING SURGERY FOR TREATMENT OF RENAL MASSES  
E. Weise

**VP5-05** RISKY BUSINESS? DETERMINATION OF SATINSKY CLAMP SAFETY ZONE TO ROBOTIC ARM DURING ROBOTIC PARTIAL NEPHRECTOMY  
A. Bowen, M. Raynor, U. Boylu, B. Lee

**VP5-06** MATCHED COMPARISON OF ROBOTIC PARTIAL NEPHRECTOMY AND LAPAROSCOPIC PARTIAL NEPHRECTOMY FOR COMPLEX RENAL MASSES  
L. Dulabon, J. Finkelstein, M. Lipkin, M. Stifelman—USA

**VP5-07** LAPAROSCOPIC VS. ROBOT-ASSISTED PARTIAL NEPHRECTOMY: A PROSPECTIVE HEAD-TO-HEAD COMPARISON OF TECHNIQUES  
R. Munver, J. Uberoi, J. Yates—United States

**VP5-08** NEW TECHNOLOGY CHANGES PRACTICE PATTERNS: THE CASE OF ROBOTIC SURGERY AND MANAGEMENT OF RENAL MASSES  
A. Weizer, J. Montgomery, W. Roberts, J. Wolf, Jr., D. Miller, K. Hafez

**VP5-09** ROBOTIC PYELOPLASTY—INITIAL EXPERIENCE  
C. Wagner, A. Schütte, J. Witt—Germany

**VP5-10** ROBOTIC ADRENALECTOMY: SURGICAL TECHNIQUE AND OUTCOMES  
L. Yeung, H. Atalah, S. Parekattil, L. Su—USA

**VP5-11** RADIOFREQUENCY ABLATION-ASSISTED ROBOTIC LAPAROSCOPIC PARTIAL NEPHRECTOMY WITHOUT RENAL HILAR VESSEL CLAMPING VERSUS LAPAROSCOPIC PARTIAL NEPHRECTOMY: A COMPARISON OF PERIOPERATIVE OUTCOMES  
S. Wu, D. Viprakasit, N. Smith, P. Kent, D. Rebuck, R. Nadler—USA

**VP5-12** COMPARISON OF ROBOTIC ASSISTED AND PURE MICROSURGICAL VASOVASOSTOMY  
S. Parekattil, H. Atalah, M. Cohen

**VP5-13** ROBOTIC ASSISTED MICROSURGICAL DENERVATION OF THE SPERMATIC CORD FOR CHRONIC TESTICULAR PAIN  
S. Parekattil, H. Atalah, M. Cohen

**VP5-14** ROBOTIC ASSISTED MICROSURGICAL VARICOCELECTOMY  
S. Parekattil, H. Atalah, M. Cohen

**VP5-15** ROBOTIC ASSISTED TRANSPERITONEAL DISMEMBERED PYELOPLASTY: OUR EXPERIENCE  
F. Annino, A. Beato, C. De carne, S. De stefani, S. Micali, G. Bianchi

**VP5-16** NOVEL MICRO DOPPLER PROBE FOR ROBOTIC MICROSURGICAL PROCEDURES  
S. Parekattil, sijo j., H. Atalah, M. Cohen

**VP5-17** ROBOTIC-ASSISTED SURGERY FOR INVASIVE BLADDER CANCER: CAN THE LYMPH NODE DISSECTION MATCH THE BENCHMARKS OF OPEN SURGEONS?  
J. Davis, A. Kamat, B. Grossman, C. Dinney—USA

**VP5-18** ROBOTIC-ASSISTED LAPAROSCOPIC RADICAL CYSTECTOMY WITH ORTHOTOPIC ILEAL NEOBLADDER: AN INITIAL SINGLE CENTER STUDY OF 18 PATIENTS  
L. Young goo, S. Ha jeong, C. Sang hoon, L. Yong seong

**VP5-19** ROBOT-ASSISTED LAPAROSCOPIC RADICAL CYSTECTOMY WITH ORTHOTOPIC BLADDER SUBSTITUTION: THE INITIAL KOREAN EXPERIENCE  
K. Young hwii

**VP5-20** THE FEASIBILITY OF ROBOT-ASSISTED LAPAROSCOPIC RADICAL CYSTECTOMY WITH PELVIC LYMPHADENECTOMY: FROM THE VIEWPOINT OF EXTENDED PELVIC LYMPHADENECTOMY  
K. Seok ho

## **VP6: EDUCATION AND SIMULATORS** 10:30–12:00 hr

**VP6-01** OPTIMAL ROBOTIC UROLOGICAL TRAINING PROGRAMMES—TOP TEN INDICES  
S. Kommu, T. Finnigan, D. Carlidge, S. Hamid, Z. Hashim, S. (sarg)—United Kingdom

**VP6-02** AN ASSESSMENT OF THE PHYSICAL IMPACT OF A COMPLEX SURGICAL TASK ON SURGEONS: COMPARISON BETWEEN OPEN, LAPAROSCOPIC AND ROBOTIC TECHNIQUES  
O. Elhage, P. Dasgupta, A. Shortland

**VP6-03** IS THERE A MODEL TO TEACH AND PRACTICE RETROPERITONEOSCOPIC NEPHRECTOMY?

M. Hisano, J. Colombo Jr, R. Duarte, C. Passerotti, A. Brito, M. Srougi—Brazil

**VP6-04** THE MODIFIED TERMINOLOGIA ANATOMICA OF THE NERVE SPARING LAPAROSCOPIC RADICAL PROSTATECTOMY: IMPORTANT LANDMARKS OF THE PROCEDURE RELATED WITH FUNCTIONAL ANATOMY  
E. Huri, I. Tatar, M. Sargon, C. Germiyanoglu, R. Basar—Turkey

**VP6-05** HOW MANY CASES ARE REQUIRED TO DEVELOP COMPETENCY FOR LAPAROSCOPIC RADICAL NEPHRECTOMY PROCEDURES?  
K. Yoo, S. Jeon, K. Han, I. Seo, J. Lim, Y. Ono

**VP6-06** TRANSPERITONEAL VERSUS RETROPERITONEAL PARTIAL NEPHRECTOMY IN A PORCINE MODEL: DIFFERENT OUTCOMES FOR BEGINNERS  
M. Hisano, D. Ikejiri, L. Oliveira, R. Duarte, J. Colombo Jr, M. Srougi—Brazil

**VP6-07** LAPAROENDOSCOPIC SINGLE SITE (LESS) SURGICAL TOOLBOX: INSTRUMENTS, SCOPES, AND PORTS  
G. Haber, W. White, S. Crouzet, J. Talarico, R. Goel, J. Kaouk—USA

**VP6-08** URETERAL STENTING FOR FELINE URETERAL OBSTRUCTIONS: A POTENTIAL MODEL FOR PEDIATRIC DISEASE  
A. Berent, C. Weisse, D. Bagley—USA

**VP6-09** ASSESSMENT OF FACE AND CONTENT VALIDITY OF A VIRTUAL REALITY LAPAROSCOPIC TRANSPERITONEAL NEPHRECTOMY TRAINER  
S. Kolla, D. Pick, M. Louie, B. Argun, R. Sweet, E. Mcdougall

**VP6-10** USEFULNESS OF THE SWINE MODEL FOR TRAINING IN ENDOUROLOGICAL INTERVENTIONS  
F. Soria, M. Delgado, M. Pamplona, J. Uson, F. Sanchez

**VP6-11** NATURAL ORIFICE TRANSLUMENAL ENDOSCOPIC SURGERY (NOTES) TOOLBOX: INSTRUMENTS, SCOPES, AND PORTS  
G. Haber, S. Crouzet, W. White, J. Talarico, S. Brethauer, J. Kaouk—USA

**VP6-12** NEW COMBINED APPROACH VERSUS STANDARD TECHNIQUE IN METALLIC URETERAL STENTING. EXPERIMENTAL STUDY IN SWINE  
F. Soria, M. Delgado, L. Rioja, M. Blas, J. Uson, F. Sanchez—Spain

**VP6-13** THE IMPACT OF LAPAROSCOPIC FELLOWSHIP PROGRAMME OVER A SIGNIFICANT LAPAROSCOPIC NEPHRECTOMY EXPERIENCE  
O. Sanli, T. Tefik, T. Mut, H. Issever, D. Teber, J. Rassweiler—Turkey

**VP6-14** TRAINING OF UPPER URINARY TRACT ENDOSCOPY—EXPERIENCE WITH A NEW MODEL USING PORCINE URINARY TRACT  
P. Liske, P. Ober, Y. Aguilar, V. Zimmermanns, S. Lahme—Germany

**VP6-15** LAPAROSCOPIC RADICAL PROSTATECTOMY: IMPACT OF LEARNING CURVE ON OPERATIVE AND PATHOLOGIC OUTCOMES FOLLOWING LAPAROSCOPIC UROLOGY TRAINING  
T. Erdogru, A. Ciftcioglu, M. Baykara—Turkey

**VP6-16** HYBRID NATURAL ORIFICE TRANSLUMENAL ENDOSCOPIC SURGERY (NOTES) FOR NEPHRECTOMY WITH STANDARD LAPAROSCOPIC INSTRUMENTS. EXPERIENCE IN A CANINE MODEL  
A. Aminsharifi, A. Taddayun, S. Shakeri, M. Hashemi, M. Abdi

**VP6-17** INTENSIVE TRAINING COURSE IN LAPAROSCOPIC RADICAL PROSTATECTOMY  
A. Garcia segui, E. Bercowsky u, C. Ballesteros, R. Valero, W. Husband, J. Moanack—Spain

**VP6-18** LEARNING CURVE OF LAPAROSCOPIC RADICAL PROSTATECTOMY IN A BRAZILIAN NON-UNIVERSITARY PUBLIC HOSPITAL:DIFFICULTIES AND POSSIBILITIES  
L. Curcio, A. Cunha, J. Renteria, M. Marinho, R. Freire, G. Di biase—Brazil

**VP6-19** THE USE OF EX VIVO SIMULATORS AND AN ANIMAL MODEL FOR TRAINING IN PERCUTANEOUS NEPHROSTOMY  
F. Soria, M. Delgado, M. Pamplona, V. Gonzalez, J. Uson, F. Sanchez

**VP6-20** DEFINING A LEARNING CURVE IN LAPAROSCOPIC SIMPLE PROSTATECTOMY  
F. Heldwein, R. Sanchez-salas, E. Barret, M. Galiano, X. Cathelineau, G. Vallancien—France

## **VS1: BENIGN PROSTATIC HYPERPLASIA/LUTS** 10:30–12:00 hr

**VS1-01** THULEP—THULIUM LASER ENUCLEATION OF THE PROSTATE  
F. Imkamp, T. Herrmann

**VS1-02** HOLMIUM LASER ENUCLEATION OF PROSTATE: TECHNICAL DETAILS FROM A TRAINEE'S PERSPECTIVE  
H. Shah, H. Sodha, V. Kumar, M. Bansal

**VS1-03** TRANSURETHRAL HOLMIUM LASER DEROFING OF PROSTATIC ABSCESS  
H. Shah, A. Khandkar, H. Sodha, M. Bansal, V. Kumar

**VS1-04** HOLMIUM LASER INCISION OF BLADDER NECK FOR POST-PROSTATECTOMY BLADDER NECK STENOSIS

H. Shah, A. Khandkar, V. Kumar, M. Bansal

**VS1-05** REMOVAL OF THE BROKEN CERAMIC BEAK OF TUR-RESECTOSCOPE FROM URETHRA—AN AMAZING AND TROUBLESOME EVENT

H. Ersoy, L. Sagnak, M. Ates, N. Karakoyunlu, U. Ozok, H. Topaloglu—Turkey

**VS1-06** ENDOSCOPIC REALIGNMENT AND SUBSEQUENT SURGICAL REPAIR OF TOTAL MEMBRANOUS URETHRA RUPTURE FOR PELVIC TRAUMA

R. Scarpa, M. Poggio, C. Scoffone, C. Cracco, M. Cossu, S. Grande—Italy

**VS1-07** LAPAROSCOPIC TRANSVESICAL ADENOMECTOMY

B. Oktay, H. Vuruskan—Turkey

**VS1-08** SIGNIFICANT ADVANCEMENTS IN THE TREATMENT OF BPH (BENIGN PROSTATE HYPERPLASIA): PHOTOSELECTIVE VAPORIZATION OF THE PROSTATE USING TREATMENT MODE LFD 3000 VS. 80 W PVP GREENLIGHT

J. Neymeyer, T. Wülfing, W. Abdul-wahab al-ansari, A. Apostolidis, M. Beer

**VS1-09** SINGLE-PORT LAPAROSCOPIC TRANSVESICAL ADENOMECTOMY

B. Oktay, H. Vuruskan—Turkey

**VS1-10** A NOVEL TECHNIQUE FOR IDENTIFICATION OF DIVERTICULUM DURING ROBOT ASSISTED BLADDER DIVERTICULECTOMY

A. Kural, F. Atug, I. Tufek, H. Akpınar, S. Aksit—Turkey

**O1: TRAINING AND LEARNING CURVE**

12:00–13:00 hr

**O1-01** TRAINING OF MODIFIED TUR BEFORE ROBOTIC HIGH INTENSITY FOCUSED ULTRASOUND (RHIFU): COMPARISON OF RESULTS AFTER KNOWLEDGE TRANSFER

V. Solovov, S. Thueroff, A. Neumayr, S. Dvoynikov, C. Chaussy, M. Vozdvishensky—Russia

**O1-02** SUBAQUATIC ANTI GRAVITY MICROENVIRONMENT (SAGM) BASIC SKILLS TASKING USING A LAPAROENDOSCOPIC SINGLE-SITE SURGERY (LESS) UROLOGICAL TRAINING PLATFORM

S. Kommu, D. Cartlidge, Z. Hashim, A. Golash, C. Luscombe, S. (sarg)—United Kingdom

**O1-03** TRANSURETHRAL BLADDER ACCESS (TUBA) FOR NATURAL ORIFICE TRANSLUMENAL ENDOSCOPIC SURGERY (NOTES) IN A PORCINE MODEL

H. Kübler, A. Schneider, D. Wilhelm, A. Meining, J. Gschwend, H. Feussner

**O1-04** THE IMPORTANCE OF THE EXPERIENCE OF SURGICAL TEAM ON THE OPERATIVE AND ONCOLOGIC RESULTS OF LAPAROSCOPIC RADICAL PROSTATECTOMY

T. Erdogan, M. Ucar, O. Celik, T. Ipekci, I. Duman, S. Altınova, M. Baykara—Turkey

**O1-05** ROBOTIC-ASSISTED LAPAROSCOPIC SKILLS DEVELOPMENT: FORMAL VERSUS INFORMAL TRAINING

A. Benson, B. Kramer, M. Boehler, C. Schwind, B. Schwartz

**O1-06** ANALYSIS OF COMPLICATIONS OF LAPAROSCOPIC PARTIAL NEPHRECTOMY IN A CONTEMPORARY SERIES FROM A LAPAROSCOPY DEDICATED CENTER

N. Benoist, O. Stakhovskiy, E. Barret, M. Galiano, X. Cathelineau, G. Vallancien—France

**O1-07** IS LAPAROSCOPIC PARTIAL NEPHRECTOMY EQUIVALENT TO THE OPEN PROCEDURE? 5 YEARS ONCOLOGIC AND FUNCTIONAL OUTCOMESOF A PROSPECTIVE STUDY IN 250 CASES  
F. Greco, S. Wagner, M. Hoda, A. Hamza, P. Fornara**O1-08** A STRATIFICATION SYSTEM FOR PREDICTING SUITABILITY FOR DAYCASE LAPAROSCOPIC UPPER URINARY TRACT UROLOGICAL SURGERY

S. Kommu, A. Chakravarti, T. Finnigan, C. Luscombe, A. Golash—United Kingdom

**O1-09** SEXUAL FUNCTION AFTER LAPAROSCOPIC ASSISTED TENSION-FREE VAGINAL MESH FOR SURGICAL CORRECTION OF PELVIC ORGAN PROLAPSE

Toyohiko Watanabe\*, Miyabi Inoue, Ayano Ishii, Toyoko Yamato, Katsutoshi Uematsu, Katsumi Sasaki, Yasuyuki Kobayashi, Shinya Uehara, Takashi Saika, Yasutomo Nasu, Hiromi Kumon, Okayama, Japan

**O1-10** THE PERSONAL HISTORY OF A FAR TOO SHORT PROFESSIONAL CAREER IN MINIMAL-INVASIVE UROLOGICAL SURGERY

H. Weber, X. Krah, A. Schneider, K. Miller, D. Froheberg, R. Hautmann

**VP7: LAPAROSCOPY-KIDNEY 2**

12:00–13:00 hr

**VP7-01** EXPERIENCE WITH 830 CONSECUTIVE LAPAROSCOPIC DONOR NEPHRECTOMIES: A CALL FOR USING A STANDARDIZED CLASSIFICATION OF COMPLICATIONS

A. Breda, J. Harper, J. Leppert, J. Veale, A. Gritsch, P. Schulam

**VP7-02** COMPARATIVE OUTCOMES OF THE OPEN, HAND ASSISTED AND FULL LAPAROSCOPIC LIVING DONOR NEPHRECTOMY

W. Kongchareonsombat—Thailand

**VP7-03** LAPAROSCOPIC DONOR NEPHRECTOMY AT A SINGLE INSTITUTION ; KITASATO EXPERIENCE IN CONSECUTIVE 45 CASES

D. Ishii, M. Iwamura, K. Tabata, K. Yoshida, S. Baba

**VP7-04** TRANSPERITONEAL VERSUS RETROPERITONEAL LAPAROSCOPIC LIVING DONOR NEPHRECTOMY: COMPARISON OF TWO PROCEDURES REGARDING CLINICAL OUTCOME AND COMPLICATION RATE

M. Saito, N. Tsuchiya, S. Narita, Y. Horikawa, S. Satoh, T. Habuchi

**VP7-05** RIGHT-SIDED LAPAROSCOPIC DONOR NEPHRECTOMY-INITIAL EXPERIENCE OF SINGLE CENTER

D. Perlin, I. Alexandrov, G. Zolotarev, K. Kargin—Russia

**VP7-06** RETROSPECTIVE COMPARISON OF LAPAROSCOPIC PARTIAL NEPHRECTOMY AND LAPAROSCOPIC RENAL CRYOABLATION FOR SMALL

G. Haramis, J. Rosales, Z. Okhunov, K. Badani, M. Gupta, J. Landman—USA

**VP7-07** RETROPERITONEOSCOPIC RADICAL NEPHRECTOMY VERSUS OPEN RADICAL NEPHRECTOMY: ONCOLOGIC LONG TERM RESULTS FOR LOCALIZED RENAL CELL CARCINOMA <7 CM

A. Feicke, R. Strebel, G. Müller, A. Bachmann, T. Sulser, T. Hermanns

**VP7-08** PROSPECTIVE MINIMALLY INVASIVE APPROACH TO MANAGEMENT OF SMALL RENAL MASSES: EVIDENCE OF SIGNIFICANT INTERVAL GROWTH OR SIZE GREATER THAN 3 CM PRIOR TO INTERVENTION

R. Carey, T. Hakky

**VP7-09** PERIOPERATIVE OUTCOMES IN LAPAROSCOPIC PARTIAL NEPHRECTOMY FOR HILAR TUMORS: COMPARING OFF-CLAMP SURGERY TO COMPLETE HILAR CONTROL

A. Srinivasan, S. Saluja, L. Richstone, L. Kavoussi, A. George, H. Amin

**VP7-10** PERIOPERATIVE OUTCOMES OF LAPAROSCOPIC PARTIAL NEPHRECTOMY STRATIFIED BY BODY MASS INDEX: DOES MINIMAL INVASIVE SURGERY MAKE A DIFFERENCE?

A. S. herati, A. Srinivasan, A. George, S. Saluja, L. Richstone, L. Kavoussi

**VP7-11** LAPAROSCOPIC UPPER POLE HEMINEPHROURETERECTOMY IN CHILDREN: THE HEILBRONN EXPERIENCE

A. Gözen, T. Kalogeropoulos, L. Tunc, F. Yencilek, J. Rassweiler, D. Teber—Germany

**VP7-12** LAPAROSCOPIC APPROACH IN DIFFICULT SECONDARY NEPHRECTOMY CASES

M. Arslan, T. Degirmenci, M. Yuksel, B. Gunlusoy, S. Minareci, A. Ayder—Turkey

**VP7-13** LAPAROSCOPIC TRANSPERITONEAL AND RETROPERITONEAL NEPHRECTOMY: THE LARGEST ONE CENTER STUDY FROM TURKEY

M. Arslan, T. Degirmenci, M. Yuksel, B. Gunlusoy, S. Minareci, A. Ayder—Turkey

## **VP8: LESS-I**

12:00–13:00 hr

**VP8-01** LAPAROENDOSCOPIC SINGLE SITE (LESS) SURGERY: INITIAL 100 PATIENTS

M. Desai, A. Berger, M. Aron, R. Brandina, R. Sotelo, I. Gill

**VP8-02** OPERATIVE EXPRIENCE AND SHORT-TERM OUTCOMES OF LAPAROENDOSCOPIC SINGLE-SITE SURGERY (LESS) PYELOPLASTY: A MULTI-INSTITUTIONAL STUDY

M. Schwartz, C. Tracy, S. Rais-bahrami, M. Desai, J. Cadeddu, L. Richstone—USA

**VP8-03** LAPAROENDOSCOPIC SINGLE SITE (LESS) DONOR NEPHRECTOMY: FEASIBILITY AND TECHNIQUE

M. Atalla, S. Andonian, A. Herati, S. Rais-bahrami, L. Richstone, L. Kavoussi—USA

**VP8-04** INITIAL EXPERIENCE OF LESS IN THE TREATMENT OF BENIGN ADRENAL ADENOMA

B. Jeong, D. Han, S. Jeon, Y. Park, H. Kim

**VP8-05** STANDARD VERSUS SINGLE PORT LAPAROSCOPIC PARTIAL NEPHRECTOMY: COMPARATIVE OUTCOMES

W. White, G. Haber, R. Goel, S. Crouzet, M. White, J. Kaouk

**VP8-06** A COMPARISON OF PERIOPERATIVE OUTCOMES BETWEEN TRANSUMBILICAL SINGLE-PORT ACCESS AND CONVENTIONAL LAPAROSCOPIC RENAL CYST MASUPIALIZATION

J. Choi, D. Han, B. Jeong, S. Seo, S. Jeon, H. Lee



**VP8-07** LAPARO-ENDOSCOPIC SINGLE SITE (LESS) MANAGEMENT OF BENIGN UROLOGIC DISEASES  
S. Permpongkosol, C. Leenanupunth

**VP8-08** SINGLE PORT LAPAROSCOPIC SURGERY: CUMULATIVE OUTCOMES WITH OVER 100 CASES  
W. White, R. Goel, G. Haber, S. Crouzet, M. White, J. Kaouk

**VP8-09** RETROPERITONEAL LAPAROENDOSCOPIC SINGLE-SITE SURGERY IN UROLOGY: INITIAL EXPERIENCE  
T. Oh, D. Ryu, J. Kwon, H. Jung

**VP8-10** TRANSUMBILICAL LAPAROENDOSCOPIC SINGLE-SITE (U-LESS) NEPHRECTOMY: INITIAL EXPERIENCE  
G. Wu, J. Marshall, D. Golijanin, E. Singer, H. Rashid—USA

**VP8-11** SINGLE PORT LAPAROSCOPIC SURGERY IN THE OBESE POPULATION: FEASIBILITY AND COMPARATIVE OUTCOMES  
M. White, W. White, G. Haber, R. Goel, S. Crouzet, J. Kaouk

**VP8-12** LAPAROENDOSCOPIC SINGLE-SITE SIMPLE NEPHRECTOMY: INITIAL EXPERIENCE IN BRAZIL  
E. Metrebian, F. Lima, T. Pinheiro, F. Beltrame, V. Ortiz, C. Andreoni—Brazil

**VP8-13** PROSPECTIVE EVALUATION OF SINGLE SITE LAPAROSCOPIC RADICAL AND PARTIAL NEPHRECTOMY  
I. Derweesh, J. Silberstein, W. Bazzi, M. Talamini, C. Kane, S. Horgan

## **MP1: PROSTATE DIAGNOSIS AND TREATMENT**

14:00–15:30 hr

**MP1-01** EARLY DETECTION OF PROSTATE CANCER IN PATIENT WITH PROSTATIC SPECIFIC ANTIGEN LEVELS OF 2.5 TO 4.0 NG/ML  
S. Shah—India

**MP1-02** DOES MAXIMAL PERCENT OF CORE BIOPSY POSITIVE FOR PROSTATE CANCER CORRELATE TO PREDICTORS OF DISEASE RECURRENCE?  
M. Lux, T. Greene, E. Erturk, J. Joseph—USA

**MP1-03** PROSTATE BRACHY THERAPY: COMPLICATIONS, PROGNOSTIC FACTORS, SEXUAL FUNCTION AND RESULTS FROM 300 CASES  
A. Rempelakos, A. Marketakis, A. Papas, T. Arvanitakis, E. Koutsiaris, A. Thanos

**MP1-04** IS THE PSA NADIR AFTER HIFU TREATMENT OF LOCALIZED PROSTATE CANCER DEPENDENT ON THE GENERATION OF HIFU TREATMENT DEVICE?  
R. Ganzer, H. Fritsche, W. Wieland, A. Blana

**MP1-05** FOCAL THERAPY WITH HIFU FOR PROSTATE CANCER IN THE ELDERLY: A FEASIBILITY STUDY WITH 10 YEARS FOLLOW-UP  
A. Benchikh, E. Barret, R. Sanchez-salas, D. Prapotnich, X. Cathelineau, G. Vallancien—France

**MP1-06** EXPERIENCE OF TRANSRECTAL HIGH-INTENSITY FOCUSED ULTRASOUND IN THE TREATMENT OF LOCALIZED PROSTATE CANCER  
K. Goto, T. Hayashi, Y. Inoue, M. Hayashi

**MP1-07** HIGH INTENSITY FOCUSED ULTRASOUND (HIFU) FOR THE TREATMENT OF LOCAL RECURRENCE OF PROSTATIC CANCER AFTER RADICAL PROSTATECTOMY: EVALUATION WITH TISSUE RESONANCE INTERACTION METHOD PROBE (TRIMPROB<sup>®</sup>) AND COMBINATION OF ENDORECTAL MRI AND SPECTROSCOPY  
B. Carlo

**MP1-08** HIGH-INTENSITY FOCUSED ULTRASOUND (HIFU) VS RADICAL PROSTATECTOMY IN LOCALIZED PROSTATE CANCER: IS POSSIBLE TO SAVE ERECTILE FUNCTION?  
B. Carlo

**MP1-09** LONG TERM CANCER-SPECIFIC SURVIVAL FOR MEN FOLLOWED MORE THAN 10 YEARS AFTER PROSTATE CRYOABLATION  
P. Cheetham, A. Katz—USA

**MP1-10** OUTCOMES OF HORMONE NAIVE HIGH-RISK PROSTATE CANCER PATIENTS TREATED WITH THIRD GENERATION PROSTATE CRYOTHERAPY  
P. Cheetham, A. Katz—USA

**MP1-11** FOCAL PRIMARY CRYOTHERAPY FOR PROSTATE CANCER: EARLY OUTCOME DATA FOR LOW RISK PATIENTS  
P. Cheetham, A. Katz—USA

**MP1-12** AFRICAN AMERICAN MEN HAVE LOWER RATE OF CASTRATE RESISTANT PROSTATE CANCER ON PRIMARY LHRH AGONIST THERAPY  
P. Sassani, J. Blumberg, J. Gleason, C. Cheetham, S. Williams, G. Chien

**MP1-13** INCIDENTAL PROSTATIC ADENOCARCINOMAS IN TURP OVER A 12 MONTH PERIOD  
S. Pereira, D. Martinho, R. Rodrigues, T. Mendonça, C. Soares, H. Correia—Portugal

**MP1-14** ROBOTIC-ASSISTED LAPAROSCOPIC RADICAL PROSTATECTOMY IN PATIENTS WITH PROSTATE CANCER WITH HIGH RISK FEATURES: PREDICTORS OF FAVORABLE PATHOLOGIC OUTCOME  
R. Munver, J. Yates, M. Gross, D. Golombos, J. Uberoi, I. Sawczuk—United States

**MP1-15** NERVE-SPARING ROBOTIC-ASSISTED LAPAROSCOPIC RADICAL PROSTATECTOMY: COMPLIANCE WITH A POSTOPERATIVE PENILE REHABILITATION PROGRAM

J. Yates, D. Shin, D. Golombos, M. Gross, I. Sawczuk, R. Munver—United States

**MP1-16** HAS PRIMARY PROSTATE CANCER THERAPY AN EFFECT ON TUMOR AGGRESSIVENESS IN CASE OF TUMOR RECURRENCE?

S. Thueroff, F. Hasner, K. Herzog, R. Nanieva, C. Chaussy

**MP1-17** IS PREOPERATIVE CYSTOSCOPY WARRANTED FOR PATIENTS UNDERGOING ROBOTIC-ASSISTED LAPAROSCOPIC RADICAL PROSTATECTOMY?

J. Yates, M. Gross, D. Golombos, I. Sawczuk, R. Munver—United States

**MP1-18** A LONG-TERM RETROSPECTIVE REVIEW OF PROSTATE CANCER TREATMENT EFFECTS ON LOWER URINARY TRACT SYMPTOMS

J. Durbin, S. Stroup, B. Auge, J. L'esperance—USA

**MP1-19** A PROSPECTIVE COMPARATIVE STUDY FOR SURGICAL OUTCOMES OF HYBRID RADICAL PROSTATECTOMY AND MINI-LAP RETRO PUBIC PROSTATECTOMY

T. Saika, T. Tsushima, Y. Kobayashi, R. Arata, Y. Nasu, H. Kumon

**MP1-20** DELAYED INFECTION OF A PELVIC LYMPHOCELE FOLLOWING ROBOTIC RADICAL PROSTATECTOMY AND PELVIC LYMPHADENECTOMY: TWO CASES

M. Tremp, T. Sulser, H. Seifert—Switzerland

**MP2: ESWL**

14:00–15:30 hr

**MP2-01** ESWL IN THE HORSESHOE-SHAPED KIDNEY

A. Palmieri, A. Maletta, F. Mangiapia, C. Imbimbo, N. Longo, V. Mirone

**MP2-02** THE DORNIER COMPACT DELTA II UIMS: VERSATILITY AND PERFORMANCE COMBINED

G. Tailly

**MP2-03** ESWL FOR AN ANNULAR CALCULUS AT THE SITE OF A PYELOPLASTY: A CASE REPORT

A. Ashish patil—India

**MP2-04** COMPLICATIONS FOLLOWING USE OF THE DORNIER COMPACT DELTA ELECTROMAGNETIC LITHOTRIPTOR

J. Mobley iii, A. Stewart, M. Brewer, F. Klein, W. White—USA

**MP2-05** THE IMPACT OF SHOCK WAVE RATE ON SHOCK WAVE LITHOTRIPSY (SWL) EFFICIENCY

A. Jamshaid, S. Biyabani, M. Ather—Pakistan

**MP2-06** 15 YEARS OF EXPERIENCE WITH SHOCK WAVE LITHOTRIPSY (SWL) IN PATIENTS WITH HORSESHOE KIDNEY (HSK)

A. Ray, D. Ghiculete, R. Honey, K. Pace

**MP2-07** LONG-TERM EFFECTS OF EXTRACORPOREAL SHOCK WAVE LITHOTRIPSY IN PEDIATRIC POPULATION

K. Villányi, L. Farkas, C. Pusztai, J. Székely

**MP2-08** A PROSPECTIVE RANDOMIZED STUDY COMPARING 60 VERSE 120 SHOCK WAVES PER MINUTES FOR INDUCED TRAUMA INJURY IN EXTRACORPOREAL SHOCK WAVE LITHOTRIPSY

A. Lo, D. Gohel, N. Lee, C. Ng

**MP2-09** IMPACT OF BMI ON EXTRACORPOREAL SHOCK WAVE TREATMENT FOR KIDNEY STONES—RESULTS FOR 3RD GENERATION LITHOTRIPTERS

G. Hatiboglu, V. Popeneciu, M. Kurosch, S. Pahernik, A. Haferkamp, M. Hohenfellner—Germany

**MP2-10** CLINICAL EVALUATION OF A NOVEL ELECTROHYDRAULIC LITHOTRIPTOR

A. Krambeck, S. Handa, J. Mcateer, T. Soergel, A. Evan, J. Lingeman—United States

**MP2-11** SERIAL EXTRACORPOREAL SHOCKWAVE LITHOTRIPSY (ESWL): THE EFFICACY, SAFETY AND PATIENT SATISFACTION WITH TREATMENT IN A BUSY TERTIARY REFERRAL STONE CENTRE

K. Moraitis, T. El-husseiny, Z. Maan, A. Papatsoris, J. Masood, N. Buchholz

**MP2-12** LONG TERM OUTCOME OF PERINEPHRIC HEMATOMAS COMPLICATING SHOCKWAVE LITHOTRIPSY (SWL)

A. Cooper, A. Chachashvilli, I. Sabler, E. Lang, Y. Siegel

**MP2-13** PRIMARY TREATMENT ESWL IS BEST VALUE

E. Havranek, M. Hanna, A. Shamusddin, J. Ramsay

**MP2-14** RE-ADMISSION AND INTERVENTION RATES POST ESWL

O. Gilleard, D. Allen, M. Hanna, A. Shamsuddin, J. Ramsay

**MP2-15** LOW FREQUENCY SHOCK WAVE ESWL IMPROVES RENAL PELVIS STONE DISINTEGRATION IN THE PIG MODEL

A. Neisius, J. Wöllner, R. Gillitzer, C. Hampel, J. Thüroff

**MP2-16** MANAGEMENT OF OBESE PATIENTS WITH RENAL STONES: PRELIMINARY RESULTS OF SWL IN A MODIFIED LATERAL POSITION

S. Gravas, A. Karatzas, V. Tzortzis, M. Melekos

**MP2-17** THE EVALUATION OF EFFECTIVENESS OF COMPUTED TOMOGRAPHY FOR SUCCESSFUL RATE OF SWL IN URINARY STONE DISEASE

L. Kyoungtaek, D. Kim, S. Park, Y. Kim, H. Park, T. Lee

**MP2-18** SUBCAPSULAR HEMATOMA AS A COMPLICATION OF SWL: EXPERIENCE WITH THE STORZ SLX-F2 LITHOTRIPTER

R. Leistner, C. Mendez probst, L. Nott, H. Razvi—Canada

**MP2-19** PREDICTIVE VALUE OF STONE DENSITY BY HOUNSFIELD UNIT (HU) ON UN ENHANCED COMPUTED TOMOGRAPHY IN SUCCESSFUL STONE FRAGMENTATION BY EXTRACORPOREAL SHOCK WAVE LITHOTRIPSY (ESWL)

M. Ather, A. Jamshaid

**MP2-20** MEASUREMENT OF STONE HOUNSFIELD UNIT (HU)—DOES IT MATTER DURING EXTRACORPOREAL SHOCKWAVE LITHOTRIPSY (ESWL)

R. Sabnis, K. Shah, A. Kurien, M. Desai

### **MP3: UROLITHIASIS 1**

14:00–15:30 hr

**MP3-01** UROLITHIASIS IN THE ELDERLY

J. Mccarthy, R. Norman—Canada

**MP3-02** THE METABOLIC SYNDROME AND URIC ACID NEPHROLITHIASIS

Y. Seo, K. Shim, J. Huh, J. Park—Korea

**MP3-03** ANALYSIS OF 24-HOUR URINE PARAMETERS AS PREDICTOR FOR AGE OF ONSET OF CYSTINE STONE FORMATION

N. Miller, E. Lambert, H. Altamar, S. Herrell

**MP3-04** OUT PATIENT URETEROSCOPY: EVALUATION OF COMPLICATION AND CAUSES OF HOSPITALIZATION 2 YEARS EXPERIENCE IN IMAM REZA HOSPITAL

M. Darabi mahboub, K. Tavakkoli tabassi, A. Naderi—Iran

**MP3-05** CHARACTERISTICS OF METABOLIC RISK FACTORS IN UROLITHIASIS PATIENTS WITH FAMILY HISTORY

Y. Ha, Y. Kim, W. Jung, E. Kim, D. Kim, Y. Jeon

**MP3-06** THE RELATIONSHIP OF METABOLIC SYNDROME WITH UROLITHIASIS IN A SCREENED POPULATION

T. Kang, J. Park, J. Park, J. Hong, H. Park—Korea

**MP3-07** HETEROGENEITY IN THE REPORTING OF DISEASE CHARACTERISTICS AND TREATMENT OUTCOMES IN STUDIES EVALUATING TREATMENTS FOR NEPHROLITHIASIS

E. Hyams, A. Bruhn, M. Lipkin, O. Shah—USA

**MP3-08** THE IN-VITRO CRYSTALLIZATION OF MELAMINE AND ITS EFFECT ON CALCIUM OXALATE CRYSTALLIZATION

C. Ng, N. Poon, A. Lo, M. Gohel

**MP3-09** SERUM TESTOSTERONE MAY BE AN INDEPENDENT RISK FACTOR FOR CALCIUM OXALATE UROLITHOGENESIS

J. Watson, A. Shrewsbury, S. Taghechian, J. Pattaras, C. Ritenour, K. Ogan—USA

**MP3-10** DOES POTASSIUM CITRATE THERAPY INCREASE THE PHOSPHATE CONTENT OF STONES?

M. Ferrandino, C. Donnally, J. Raman, K. Sakhaee, M. Pearle, G. Preminger

**MP3-11** THE COMBINED EFFECT OF OMEGA-3 FATTY ACIDS EICOSAPENTAENOIC ACID AND DOCOSAHEXAENOIC ACID IN THE MANAGEMENT OF IDIOPATHIC HYPERCALCIURIA DEPARTMENT OF UROLOGIC SURGERY, UNIVERSITY OF MINNESOTA, MINNEAPOLIS, MINNESOTA, USA \*DIETARY SERVICES UMMC

O. Ortiz-alvarado, C. Kriedberg, R. Miyaoka, A. Moeding\*, M. Stessman\*, M. Monga

**MP3-12** PYRIDOXINE SUPPLEMENTATION FOR THE MEDICAL MANAGEMENT OF IDIOPATHIC HYPEROXALURIA DEPARTMENT OF UROLOGIC SURGERY, UNIVERSITY OF MINNESOTA, MINNEAPOLIS, MINNESOTA, USA \*DIETARY SERVICES, UMMC FAIRVIEW

O. Ortiz-alvarado, C. Kriedberg, R. Miyaoka, A. Moeding\*, M. Stessman\*, M. Monga

**MP3-13** DESIGNING 'PATIENT CENTRED CARE' FOR CYSTINURICS: THE EXPERIENCE OF A NEW SPECIALIST MULTI-DISCIPLINARY CLINIC

K. Thomas, A. Doherty, M. Kabia, J. Glass, T. Doulton, G. Rottenberg—UK

**MP3-14** GLOBAL CHANGES IN KIDNEY STONE PREVALENCE AND INCIDENCE

D. Assimos, V. Romero

**MP3-15** CURRENT DIETARY IMPACT ON THE MANAGEMENT FOR UROLITHIASIS DEPARTMENT OF UROLOGIC SURGERY, UNIVERSITY OF MINNESOTA, MINNEAPOLIS, MINNESOTA, USA \*DIETARY SERVICES, UMMC FAIRVIEW

O. Ortiz-alvarado, M. Stessman\*, R. Miyaoka, C. Kriedberg, A. Moeding\*, M. Monga

**MP3-16** ACCURACY OF IDENTIFICATION OF PATIENTS WITH URINARY CALCULI THROUGH ADMINISTRATIVE RECORDS: A DATA VALIDATION STUDY

M. Semins, J. Berkowitz, B. Matlaga—USA

**MP3-17** METABOLIC CHARACTERISTICS OF PATIENTS WHO USE TUBE FEEDING AS THEIR PRIMARY DIETARY SOURCE  
E. Gnessin, S. Handa, J. Lingeman—United States

**MP3-18** ASSESSMENT OF IMPROVEMENT IN S CREATININE FOLLOWING DEFINITIVE TREATMENT OF UROLITHIASIS IN PATIENTS WITH RENAL INSUFFICIENCY  
T. Haresh, J. Vivek, K. Sushi, A. Jitendra, S. Moteria, S. Sudhir

**MP3-19** URINARY CANDIDIASIS WITH SEPSIS AFTER ENDOUROLOGIC SURGERY: PATHOGENESIS AND TREATMENT OF A RARE AND SEVERE COMPLICATION  
I. Kartalas goumas, G. Cordima, B. Mangiarotti, F. Longo, E. Inneo, E. Montanari

**MP3-20** FACTORS RESPONSIBLE FOR UROSEPSIS FOLLOWING PERCUTANEOUS NEPHROLITHOTOMY: ROLE OF NITROFURANTOIN PROPHYLAXIS  
S. Bag, S. Kumar, A. Mandal, N. Taneja, U. Mete, S. Singh—India

**MP4: PCNL 1**  
14:00–15:30 hr

**MP4-01** SPINAL ANESTHESIA FOR PERCUTANEOUS NEPHROLITHOTOMY VIA INTERCOSTAL PUNCTURE  
S. Mousavi-bahar, B. Borzouei, S. Amirhassani—Iran

**MP4-02** CHANGES IN RENAL PRESSURE WITH URETERAL CATHETERS AND ANTIRETROPULSION DEVICES DURING PERCUTANEOUS NEPHROLITHOTOMY  
B. Chew, B. Poh, L. Jonat, D. Lange—Canada

**MP4-03** TWO CONTEMPORARY SERIES OF PERCUTANEOUS TRACT DILATION FOR PNL  
C. Mamoulakis, J. Rioja, F. Wezel, M. Michel, P. Alken, J. De la rosette—Netherlands

**MP4-04** A RANDOMIZED TRIAL OF INTERCOSTAL NERVE BLOCK FOLLOWING PCNL (PERCUTANEOUS NEPHROLITHOTOMY)  
R. Honey, D. Ghiculete, A. Ray, K. Pace—Canada

**MP4-05** ALMOST TOTALLY TUBELESS PERCUTANEOUS NEPHROLITHOTOMY: REPLACING THE DOUBLE-J STENT BY AN EXTERNALIZED URETERAL CATHETER  
P. Recabal, F. Marchant, E. Ossandon, O. Storme, J. Roman, R. Ledezma—Chile

**MP4-06** REMOVING THE STENT VIA A FLANK TETHER—OUR EXPERINCE DURING TUBELESS PCNL  
D. Bodiwala, A. Colquhoun, P. Butterworth—UK

**MP4-07** COMPARISON OF THE INCIDENCE AND COMPOSITION OF UPPER TRACT AND LOWER TRACT CALCULI IN PATIENTS WHO HAVE UNDERGONE URINARY DIVERSION  
N. Miller, E. Lambert, H. Altamar, S. Herrell

**MP4-08** THE EFFECTS OF HALF-SALINE AS AN IRRIGATION FLUID ON SERUM SODIUM IN PERCUTANEOUS NEPHROLITHOTOMY  
A. Tabibi, M. Mohammadi sichani, A. Kashi

**MP4-09** LIMITS OF MINIATURIZATION IN PNL—A THEORETICAL MODEL  
H. Hentschel, M. Hentschel, V. Janitzky, T. Weirich—Germany

**MP4-10** THE PRESENCE OF SPINE PATHOLOGIES DOES NOT AFFECT THE OUTCOME OF PERCUTANEOUS NEPHROLITHOTOMY  
C. Kara, B. Resorlu, E. Ozyuvali, A. Unsal

**MP4-11** SINGLE CENTER EVALUATION OF POST-OPERATIVE COMPLICATIONS DETECTED BY COMPUTERIZED TOMOGRAPHY FOLLOWING PERCUTANEOUS NEPHROLITHOTOMY  
E. Gnessin, S. Handa, J. Lingeman—United States

**MP4-12** THE ROLE OF PERCUTANEOUS NEPHROLITHOTOMY IN THE TREATMENT OF PREGNANCY RELATED RENAL CALCULI  
E. Gnessin, A. Krambeck, S. Handa, J. Lingeman—United States

**MP4-13** THE UTILITY OF PELVI-CALYCEAL MUCOSA BIOPSIES DURING PERCUTANEOUS NEPHROLITHOTOMY (PCNL)  
A. Mathew, A. Kurien, R. Sabnis, M. Desai

**MP4-14** PERCUTANEOUS NEPHROLITHOTOMY IN CHILDREN  
I. Aridogan, N. Satar, Y. Bayazit, V. Izol, O. Karsli, S. Zeren—Turkey

**MP4-15** COMBINATION OF PNEUMATIC AND ULTRASONIC LITHOTRIPTER IN PERCUTANEOUS NEPHROLITHOTOMY  
L. Tahmaz, S. Bedir, M. Zor, H. Topac, M. Dayanc

**MP4-16** EFFICACY OF NOVEL COAXIAL OCCLUSION DEVICE TO PREVENT STONE MIGRATION DURING PERCUTANEOUS NEPHROLITHOTOMY (PCNL)  
M. Gupta, M. Rothberg, M. Wosnitzer—United States

**MP4-17** THE SAFETY OF TUBELESS PERCUTANEOUS NEPHROLITHOTOMY BASED ON IMMEDIATE POSTOPERATIVE NONCONTRAST COMPUTED TOMOGRAPHY  
J. Choi, H. Kim, D. Han, B. Jeong, S. Seo, S. Jeon—South Korea

**MP4-18** PROSPECTIVE RANDOMIZED TRIAL OF NEPHROSTOMY TRACT CLOSURE USING FLOSEAL VS. FASCIAL STITCH VS. COPE LOOP FOLLOWING PERCUTANEOUS NEPHROLITHOTRIPTY

R. Li, H. Lee, D. Pick, M. Louie, E. Mcdougall, R. Clayman—CA

**MP4-19** COLON POSITION IN VENTRAL AND INTERMEDIATE DORSAL DECUBITUS (VALDIVIA)

G. Mariano sebastian, N. Billordo peres, P. Garcia marchiñena, M. Sinclair, J. Ocantos, P. Daels

**MP4-20** PREOPERATIVE ADMINISTRATION OF ETHAMSYLATE: REDUCES BLOOD LOSS ASSOCIATED WITH PERCUTANEOUS NEPHROLITHOTOMY? A PROSPECTIVE RANDOMIZED STUDY

O. Negrete-pulido, M. Marnes, J. Gutierrez-aceves

## **O2: LOCALIZED PROSTATE CANCER**

14:00–15:30 hr

**O2-02** CLASSIFICATION AND TRENDS OF COMPLICATIONS IN 2500 ROBOTIC-ASSISTED RADICAL PROSTATECTOMIES

K. J palmer, R. Ferreira coelho, B. Rocco, S. Chauhan, G. Coughlin, V. Patel—US

**O2-03** LONG-TERM ONCOLOGICAL FOLLOW-UP AFTER LAPAROSCOPIC RADICAL PROSTATECTOMY: THE HEILBRONN EXPERIENCE

M. Hruza, B. Flinspach, M. Schulze, D. Teber, J. Rassweiler—Germany

**O2-04** COMPARISON OF PSA RECURRENCE BETWEEN HIGH RISK AND LOW RISK DISEASE GROUPS IN A ROBOTIC PROSTATECTOMY COHORT

A. Caire, M. Lipkin, D. Zilberman, M. Ferrandino, R. Thomas, D. Albala

**O2-05** TIME TO FAILURE AFTER SINGULAR TREATMENT OF PROSTATE CANCER BY HIGH-INTENSITY FOCUSED ULTRASOUND (HIFU)

D. Pfeiffer, C. Cellarius, C. Netsch, A. Gross—Germany

**O2-06** PSA NADIR DEVELOPMENT AFTER LOCAL THERAPY BY ROBOTIC HIGH INTENSITY FOCUSED ULTRASOUND THERAPY (RHIFU) OF T1-2 PROSTATE CANCER

A. Neumayr, S. Thueroff, R. Nanieva, W. Steil, C. Leeser, C. Chaussy

**O2-07** BIOCHEMICAL AND BIOPSY OUTCOMES FOLLOWING RADICAL HIGH INTENSITY FOCUSED ULTRASOUND (HIFU) OF PREVIOUSLY UNTREATED PROSTATE CANCER (PCA)

C. Robertson, R. Ganzer, J. Ward, S. Brown, X. Rébillard, A. Blana—USA

**O2-08** PROSTATE CARCINOMA—LONG TERM RESULTS OF FUNCTIONAL OUTCOME AFTER INTERSTITIAL BRACHYTHERAPY AND RADICAL PROSTATECTOMY—A 13 YEAR FOLLOW UP

T. Lingenfelder, E. Heinrich, C. Bolenz, F. Wenz, M. Michel, L. Trojan

**O2-09** A MULTICENTER EVALUATION OF THE INITIAL PHASE OF ROBOT ASSISTED RADICAL PROSTATECTOMY (RALP): CORRELATION TO LAPAROSCOPIC PREVIOUS KNOWLEDGE

T. Herrmann, R. Rabenalt, J. Witt, A. Georgiou, J. Stolzenburg, M. Burchardt—Germany

**O2-10** NOTES RADICAL PROSTATECTOMY: EVOLUTION OF THE TECHNIQUE

M. Humphreys, J. Sauer, A. Krambeck, J. Lingeman, E. Castle, P. Andrews

**O2-11** BILATERAL NERVE-SPARING EXTRAPERITONEAL RADICAL PROSTATECTOMY: POTENCY RATES

<sup>1</sup>Mr. José Travassos <sup>2</sup>Mr. Augusto Xavier <sup>3</sup>Mr. Álvaro M. Figueiredo F° Facs <sup>4</sup>Mrs. Kelly de Juan

## **VP10: LAPAROSCOPY PROSTATE-1**

14:00–15:30 hr

**VP10-01** THE IMPACT OF PROSTATE SIZE ON LAPAROSCOPIC RADICAL PROSTATECTOMY

M. Baptistussi, M. Morihisa, E. Gewher, A. Martins—Brasil

**VP10-02** EXTRAPERITONEAL LAPAROSCOPIC RADICAL PROSTATECTOMY : ONCOLOGIC AND FUNCTIONAL RESULTS REGARDING 175 CASES

M. Baptistussi, M. Morihisa, E. Gewher, A. Martins—Brasil

**VP10-03** THE ROLE OF LAPAROSCOPIC RADICAL PROSTATECTOMY (LRP) IN THE MULTIMODAL TREATMENT OF HIGH RISK PROSTATE CANCER (HRPCA): PRELIMINARY EXPERIENCE ON 25 CASES

U. Anceschi, C. Anceschi, M. Gaffi, F. D'amico, C. Molinari, M. Lentini—Italy

**VP10-04** A COMPARISON OF OUTCOMES FOR INTERFASCIAL AND INTRAFASCIAL NERVE-SPARING RADICAL PROSTATECTOMY

J. Stolzenburg, P. Kallidonis, M. Do, A. Dietel, R. Rabenalt, E. Liatsikos

**VP10-05** LONGER PRESERVATION OF MEMBRANOUS URETHRA IMPROVED URINARY CONTINENCE IN LAPAROSCOPIC RADICAL PROSTATECTOMY: THE INITIAL RESULTS

X. Gao, X. Pu

**VP10-06** LAPAROSCOPIC RADICAL PROSTATECTOMY FOR PATIENTS WITH GLEASONS 8–10 +/- PSA >20

A. Arora, C. Eden

**VP10-07** FEASIBILITY OF LAPAROSCOPIC RADICAL PROSTATECTOMY FOLLOWING TOTAL EXTRAPERITONEAL(TEP) MESH INGUINAL HERNIA REPAIR

A. Arora, C. Eden

**VP10-08** COMPARATIVE EVALUATION OF ULTRASONIC SCISSORS VERSUS ENERGY-FREE DISSECTION DURING NERVE-SPARING ENDOSCOPIC EXTRAPERITONEAL RADICAL PROSTATECTOMY

E. Liatsikos, P. Kallidonis, A. Dietel, M. Do, T. Haefner, J. Stolzenburg—Greece

**VP10-09** EXPERIENCES OF CONTINENCE-PRESERVING IN LAPAROSCOPIC RADICAL PROSTATECTOMY

L. Ma, Y. Huang, G. Wang, C. Xiao, X. Hou, K. Hong

**VP10-10** SUTURELESS DORSAL VEIN LIGATION DURING LAPAROSCOPIC RADICAL PROSTATECTOMY

M. Kilciler, L. Tahmaz, S. Bedir, H. Guler, M. Dayanc

**VP10-11** OBESE AFRICAN AMERICANS WITH DIAGNOSTIC PSA

D. Albala, M. Lipkin, A. Caire, L. Sun, T. Polascik, J. Moul—USA

**VP10-12** MODIFIED APICAL DISSECTION OF THE PROSTATE IMPROVES EARLY CONTINENCE IN LAPAROSCOPIC RADICAL PROSTATECTOMY: TECHNIQUE AND INITIAL RESULTS

X. Gao, X. Pu, J. Qiu

**VP10-13** ENDOSCOPIC EXTRAPERITONEAL RADICAL PROSTATECTOMY AFTER PREVIOUS TURP: ONCOLOGICAL AND FUNCTIONAL OUTCOMES OF 100 CASES

E. Liatsikos, M. Do, P. Kallidonis, A. Dietel, A. Al aown, J. Stolzenburg—Greece

**VP10-14** LAPAROSCOPIC RADICAL PROSTATECTOMY: MINIMUM 5 YEAR FOLLOWUP OF THE FIRST UK CASES

A. Arora, C. Eden

**VP10-15** THE EFFECT ON CONTINENCE OF PRESERVING THE BLADDER NECK IN ENDOSCOPIC EXTRAPERITONEAL RADICAL PROSTATECTOMY

E. Liatsikos, P. Kallidonis, M. Do, A. Dietel, T. Haefner, J. Stolzenburg—Greece

**VP10-16** EXPERIENCES OF CONTINENCE-PRESERVING IN LAPAROSCOPIC RADICAL PROSTATECTOMY

L. Ma, Y. Huang, G. Wang, X. Hou, K. Hong, J. Lu—China

**VP10-17** MINIMALLY INVASIVE MANAGEMENT OF POSTOPERATIVE BLEEDING AFTER RADICAL PROSTATECTOMY: TRANSARTERIAL EMBOLIZATION

C. Jeong, Y. Park, C. Kwak, J. Ku, H. Jeong, H. Kim

**VP10-18** EVALUATION OF A NEW VALVE-LESS TROCAR FOR UROLOGIC LAPAROSCOPY

M. Atalla, A. Herati, S. Andonian, S. Rais-bahrami, L. Kavoussi—USA

**VP10-19** EARLY EXPERIENCE WITH EXTRAPERITONEAL TRANSVESICAL ADENOMECTOMY FOR BENIGN PROSTATIC HYPERPLASIA

M. Hisano, F. Vicentini, M. Chaib, M. Pinheiro, M. Gotto, R. Shin—Brazil

**VP10-20** THE IMPACT OF TIME-LAG IN THE LEARNING CURVE FOR EX VIVO SKILL ACQUISITION FOR LAPAROENDOSCOPIC SINGLE SITE SURGERY (LESS) VESICourethRAL ANASTOMOSIS

S. Kommu, D. Carlidge, A. Chakravarti, A. Golash, C. Luscombe, S. (sarg)—United Kingdom

## **VP9: URETEROSCOPY 2**

14:00–15:30 hr

**VP9-01** URETEROSCOPIC MANAGEMENT OF THE STONE IN CALYCEAL DIVERTICULUM

E. Bercowskyu, A. Garcia segui, I. Gomez fernandez, M. Gascon mir—Spain

**VP9-02** THE PRESENCE OF ISCHEMIA IN BENIGN URETERAL STRICTURES MAY AFFECT SUCCESS OF HOLMIUM LASER ENDOURETEROTOMY

E. Gnessin, O. Yossepowitch, R. Holland, P. Livne, D. Lifshitz—Israel

**VP9-03** IS A SAFETY WIRE NECESSARY DURING ROUTINE FLEXIBLE URETEROSCOPY?

R. Dickstein, B. Harnisch, R. Babayan, D. Wang—USA

**VP9-04** FLEXIBLE URETEROSCOPY WITH HOLMIUM.YAG LASER LITHOTRIPSY FOR TREATMENT OF RENAL STONES

Z. Wu, Q. Ding, H. Jiang, P. Gao, Y. Zhang—China

**VP9-05** URETERORENOSCOPIC INCISION WITH HOLMIUM:YAG LASER FOR TREATMENT OF URETERAL / URETEROPELVIC JUNCTION OBSTRUCTION

Z. Wu, Q. Ding, H. Jiang, P. Gao, Y. Zhang—China

**VP9-06** COMPARISONS OF MINIMAL INVASIVE SURGERIES FOR URETERAL OBSTRUCTIONS: ENDOURETEROPYELOTOMY, ACUCISE ENDOURETEROPYELOTOMY, AND LAPAROSCOPIC URETEROPYELOPLASTY

H. Dong youp, K. Ill sang, S. Ill young, S. Ill young, J. Hee jong

**VP9-07** EXTRARENAL MANIPULATIONS FOR RETROGRADE INTRARENAL SURGERY (RIRS) USING SEMIRIGID URS AND PNEUMATIC LITHOTRIPSY: A NOVEL CONCEPT  
T. Haresh

**VP9-08** INCIDENTAL STONES IN LIVING KIDNEY DONORS: BENCH URETEROSCOPY MAXIMISING THE DONOR POOL  
J. Olsburgh, K. Thomas, J. Smith, L. Burnapp, G. Koffman—UK

**VP9-09** MINIMALLY INVASIVE MANAGEMENT OF URETERAL INJURIES SECONDARY TO OBSTETRIC AND GYNAECOLOGIC SURGERY  
M. Gargouri, M. Teyeb, S. Sallami, F. Turki, Y. Nouria, A. Horchani—Tunisia

**VP9-10** URETEROSCOPIC MANAGEMENT OF LARGE INTRARENAL CALCULI—A COMPARISON OF TECHNIQUES  
D. Bagley, N. Leone, S. Hubosky, A. Mariani—USA

**VP9-11** ENDOSCOPIC TREATMENT OF MULTIPLE URETERAL FIBROEPITHELIAL POLYPS BY HOLMIUM YAG LASER RESECTION  
H. Zakoji, T. Mochiduki, S. Kira, T. Nomura, I. Araki, M. Takeda—Japan

**VP9-12** LONG TERM EFFICACY OF HOLMIUM:YAG LASER ENDOURETEROTOMY FOR LONG URETERAL STRICTURES  
N. Andriopoulos, N. Pardalidis, E. Kosmaoglou—Greece

**VP9-13** URETEROSCOPY IN PROXIMAL URETERAL CALCULI: EXPERIENCE ON 1238 CASES  
R. Multescu, D. Georgescu, B. Geavlete, P. Geavlete—Romania

**VP9-14** NEW LESS INVASIVE TECHNOLOGIES IN RENAL CALCULI MANAGEMENT. SCIENTIFIC RESEARCH INSTITUTE OF UROLOGY, MOSCOW  
R. Fatikhov, D. Merinov, E. Borisenko

**VP9-15** PRIMARY AND SECONDARY RETROGRADE INTRA-RENAL SURGERY (RIRS) FOR RENAL STONES IN PATIENTS WITH LARGE STONE BURDEN  
W. Au, S. Chu, P. Tam—China

**VP9-16** DISTAL ENDOSCOPIC URETEROLITHOTOMY DURING PREGNANCY: EXPERIENCE IN 21 CASES  
O. Castillo, I. Vidal-mora, G. Rubio, A. Foneron, R. Campos, M. Feria—Flores

**VP9-17** NO MATTER OF SIZE: URETEROSCOPIC STONE TREATMENT IN OBESE PATIENTS  
K. Oberhagemann, C. Netsch, T. Bach, A. Gross—Germany

**VP9-18** URETEROSCOPIC STONE TREATMENT OF LOWER POLE CALCULI

K. Oberhagemann, C. Netsch, T. Bach, A. Gross—Germany

**VP9-19** URS: WHERE IS THE STONE?  
K. Oberhagemann, C. Netsch, T. Bach, A. Gross—Germany

**VP9-20** ANTEGRADE URETEROSCOPY FOR MANAGING OF URETERAL STONES IN TRANSPLANTED KIDNEYS  
S. Hosseini, A. Tabibi, A. Noor-alizadeh—Iran

## **VS2: FEMALE UROLOGY AND INCONTINENCE**

14:00–15:30 hr

**VS2-01** LAPAROSCOPIC TREATMENT OF OVARIAN VEIN SYNDROME  
A. Celia, G. Zeccolini, G. Breda

**VS2-02** LAPAROSCOPIC SACROCOLPOPEXY FOR GRADE IV PELVIC ORGANS PROLAPSE WITH ASSOCIATED BILATERAL PYELOCALICIAL DILATATION  
L. Curcio, R. Guida, F. Bastos, A. Cunha, J. Renteria, G. Di biase—Brazil

**VS2-03** ROBOTIC-ASSISTED LAPAROSCOPIC SACROUTEROPEXY FOR PELVIC ORGAN PROLAPSE IN CLASSICAL BLADDER EXSTROPHY  
A. Benson, B. Kramer, P. McKenna, B. Schwartz—United States

**VS2-04** TECHNIQUE OF ROBOT ASSISTED VEISCOVAGINAL FISTULA REPAIR (NOTE: THIS ABSTRACT IS ACCOMPANIED BY A VIDEO)  
H. Atalah, C. Vincent, L. Morgan, L. Su—USA

**VS2-05** OPTIMIZING RESULTS OF SUBURETHRAL SLING OPERATIONS AMONG FEMALES USING SUBURETHRAL HYALURONIC ACID INJECTIONS  
J. Neymeyer, W. Abdul-wahab al-ansari, S. Kassin, M. Beer—Berlin

**VS2-06** SILK LIGATURE TECHNIQUE OF SPERMATIC VESSEL MASS LIGATION-DIVISION DURING BILATERAL LAPAROSCOPIC VARICOCECTOMY FOR INFERTILITY  
E. Arada, P. Fausto, R. Arada—Philippines

**VS2-07** SPLENOGONADAL FUSION: AN UNUSUAL CAUSE OF AN ASCENDING TESTIS AND LAPAROSCOPIC SOLUTION  
O. Ziyilan, O. Sanli, A. Atar, T. Tefik, M. Karadeniz, H. Ander

**VS2-08** OPTIMIZING RESULTS OF SUBURETHRAL SLING OPERATIONS AMONG MALES USING SUBURETHRAL HYALURONIC ACID INJECTIONS  
J. Neymeyer, W. Abdul-wahab al-ansari, S. Kassin, M. Beer—Berlin

**VS2-09** BLADDER EROSION OF TENSION-FREE VAGINAL TAPE: REMOVAL BY STANDARD TRANSURETHRAL RESECTION

M. Baykara, O. Celik, S. Yucel, T. Erdogru

**VS2-10** TAPE RESECTION FOLLOWING TRANSOBTURATOR TAPE (TOT) OPERATION FOR STRESS URINARY INCONTINENCE

C. Gurbuz, S. Gungor, B. Guner, O. Arikan, T. Caskurlu—Turkey

**VS3: RECONSTRUCTIVE LAPAROSCOPY 1**

14:00–15:30 hr

**VS3-01** LAPAROSCOPIC URETERO-URETEROSTOMY FOR RETROCAVAL URETER

P. Ranjan, K. Shah, A. Ganpule, M. Virmani, R. Sabnis, M. Desai

**VS3-02** LAPAROSCOPIC ANDERSON-HYNES PYELOPLASTY USING CONTOUR INJECTION STENT IN URETEROPELVIC JUNCTION (UPJ) OBSTRUCTION

G. Franco, S. Antonio, R. Ai ling, G. Antonio maria, P. Francesco, I. Giacomo piero—Italy

**VS3-03** URETERIC REIMPLANTATION BY LESS: COSMESIS MAINTAINED!

S. Mishra, M. Desai, A. Kurien, A. Ganpule, R. Sabnis, M. Desai—India

**VS3-04** LAPAROSCOPIC CIRCUNCAVAL URETERAL REPAIR CONCOMITANT WITH LAPAROSCOPIC-GUIDED NEPROSCOPY FOR CALCULI EXTRACTION

L. Curcio, B. Caçado, A. Cunha, J. Renteria, F. Gusmão, G. Di biase

**VS3-05** EXTRAPERITONEAL LAPAROSCOPIC PIELOPASTY (ELP) FOR URETEROPELVIC JUNCTION OBSTRUCTION (UPJO) IN HORSESHOE KIDNEY

U. Anceschi, G. Grosso, A. Amici, C. Torcia

**VS3-06** CAN OUR NEW TECHNIQUE LAPAROSCOPIC STEPWISE-CUT DOUBLE INITIAL KNOT PYELOPLASTY OVERCOME SOME DIFFICULTIES OF PYELOPLASTY?

Y. Ozgok, M. Ates, M. Hoscan, S. Basal, M. Zor, M. Dayanc—Turkey

**VS3-07** LAPAROSCOPIC URETERAL REIMPLANTATION FOR THE MANAGEMENT OF URETEROVAGINAL FISTULA AFTER TOTAL ABDOMINAL HYSTERECTOMY WITH BILATERAL SALPINGO-OOPHORECTOMY

V. Tugcu, E. Sonmezay, N. Gurbuz, A. Tasci—Turkey

**VS3-08** DISMEMBERED RETROPERITONEOSCOPIC PYELOPLASTY FOR THE TREATMENT OF SYMPTOMATIC URETEROPELVIC JUNCTION OBSTRUCTION WITH CROSSING VESSELS TRANSPOSITION OF URETER NECESSARY?

S. Subotic, A. Gözen, T. Bayer, R. Gumpinger, J. Rassweiler—Germany

**VS3-09** LAPAROSCOPIC BILATERAL DISMEMBERED PYELOPLASTY IN CHILDREN:3-PORT TECHNIQUE

A. Basiri, M. Asl zare, S. Hosseini, H. Djaladat

**VS3-10** ROBOT ASSISTED LAPAROSCOPIC PYELOPLASTY FOR RIGHT RENAL DOUBLE SYSTEM

F. Porpiglia, C. Fiori, I. Morra, R. Bertolo, R. Scarpa

**VS4: LAPAROSCOPY—KIDNEY 1**

14:00–15:30 hr

**VS4-01** SINGLE INCISION LAPAROSCOPIC RENAL CRYOSURGERY

U. Boylu, M. Oommen, R. Thomas, B. Lee—USA

**VS4-02** ROBOTIC-ASSISTED LAPAROSCOPIC PARTIAL NEPHRECTOMY FOR HILAR LESIONS: LESSONS LEARNED

L. Dulabon, P. Mufarrij, E. Hyams, M. Stifelman—USA

**VS4-03** USE OF COLD SCALPEL IN LAPAROSCOPIC PARTIAL NEPHRECTOMY

R. Sotelo, E. Di grazia, R. De andrade, D. Ramirez, O. Carmona, D. Canes—Venezuela

**VS4-04** LAPAROSCOPIC PARTIAL NEPHRECTOMY FOR FOREIGN BODY SIMULATING RENAL CANCER

R. Sanseverino, G. Napodano, O. Intilla, U. Di mauro, M. Iacone—Italy

**VS4-05** SIMPLIFICATION OF THE LAPAROSCOPIC PARTIAL NEPHRECTOMY TECHNIQUE

M. Baptistussi, E. Gewher, M. Morihisa

**VS4-06** EVOLUTION OF LAPAROSCOPIC PARTIAL NEPHRECTOMY

A. Berger, R. Brandina, M. Aron, R. Stein, M. Desai, I. Gill

**VS4-07** LAPARO-ENDOSCOPIC SINGLE SITE (LESS) NEPHRECTOMY FOR BENIGN AND INFLAMMATORY CONDITIONS

S. Permpongkosol, C. Leenanupunth

**VS4-08** LAPAROSCOPIC REPAIR OF NEPHROPTOSIS WITHOUT KNOT USE

L. Curcio, A. Cunha, J. Renteria, R. Freire, F. Gusmão, G. Di biase—Brazil

**VS4-09** COMBINED LAPAROSCOPIC TRANSPIELIC BALLISTIC LITHOTRIpsy AND RENAL CYST ABLATION

G. Pini, S. Micali, M. Sighinolfi, F. Annino, S. De stefani, G. Bianchi

**VS4-10** URETEROSCOPIC MANAGEMENT FOR SYMPTOMATIC PARAPELVIC RENAL CYST

A. Basiri, S. Hosseini, V. Najjaran tousi, M. Mohammadi sichani, M. Asl zare



**MP5: BLADDER CANCER**

16:00–17:30 hr

**MP5-01** COMPARING EFFICACY OF BCG THERAPY AND CAUTERIZATION OF TUMOR VERSUS BCG THERAPY WITHOUT CAUTERIZATION IN SUPERFICIAL BLADDER CANCER  
S. Falahatkar, A. Roshani, Ghanbari, S. Asadi, M. Akbarpour, N. Khaki

**MP5-02** COMPARISON OF SURGICAL OUTCOME BETWEEN LAPAROSCOPIC AND OPEN RADICAL CYSTECTOMY FOR BLADDER CANCER: SAPPORO CITY GENERAL HOSPITAL EXPERIENCE  
T. Seki, M. Miura, T. Suzuki, H. Sasaki, T. Mochizuki, H. Harada—Japan

**MP5-03** LAPAROSCOPIC RADICAL CYSTECTOMY (LRC): SHORT TERM OPERATIONAL AND ONCOLOGICAL OUTCOMES  
O. Sanli, T. Tefik, E. Salabas, E. Aliyev, O. Aytac, T. Esen—Turkey

**MP5-04** ROBOTIC EXTENDED PELVIC LYMPHADENECTOMY FOR BLADDER CANCER: INITIAL EXPERIENCE WITH GREATER NODAL YIELD  
H. Lavery, R. Abaza—USA

**MP5-05** LAPAROSCOPIC RADICAL CYSTECTOMY AND DETENIAL SIGMOID COLON ORTHOTOPIC NEOBLADDER FOR CHILDREN BLADDER RHABDOMYOSARCOMA (REPORT OF TWO CASES)  
X. Kai—People's Republic of China

**MP5-06** CLINICAL PATHWAY FOR EARLY DISCHARGE AFTER ROBOTIC CYSTECTOMY  
A. White, R. Abaza—USA

**MP5-07** AN AUDIT OF LASER ABLATION OF UPPER TRACT TRANSITIONAL CELL CARCINOMA; A SAFE AND EFFECTIVE TREATMENT IN LOW GRADE DISEASE?  
S. Graham, P. Gurung, S. Longhorn, R. Smith, T. Philp, S. Choong

**MP5-08** HAND-ASSISTED LAPAROSCOPIC RADICAL CYSTECTOMY WITH EXTRACORPOREAL URINARY DIVERSION  
S. Jung, M. Gil, S. Kim, J. Ha, S. Yoon, J. Chung

**MP5-09** OVERCOMING THE UROTHELIAL BARRIER: THE EFFECT OF CHITOSAN ON URETERAL INTRALUMINAL DRUG ADMINISTRATION AND PERISTALSIS  
D. Pick, S. Shelkovernikov, N. Canvasser, M. Louie, E. Mcdougall, R. Clayman—CA

**MP5-10** OBESITY DOES NOT AFFECT THE SURGICAL AND ONCOLOGIC OUTCOMES OF ROBOTIC ASSISTED RADICAL CYSTECTOMY  
U. Boylu, M. Oommen, M. Raynor, B. Lee, R. Thomas—USA

**MP5-11** ONCOLOGIC OUTCOMES OF ROBOTIC ASSISTED RADICAL CYSTECTOMY  
U. Boylu, M. Oommen, B. Lee, R. Thomas—USA

**MP5-12** LEG ENDOSCOPIC GROIN LYMPHADENECTOMY FOR GENITOURINARY CANCER (LEG PROCEDURE)  
V. Master, K. Ogan, D. Kooby, W. Hsiao, K. Delman—USA

**MP5-13** ROBOTIC-ASSISTED LAPAROSCOPIC RADICAL CYSTECTOMY (RARC) WITH EXTRACORPOREAL URINARY DIVERSION: INITIAL EXPERIENCE  
S. Jung, M. Gil, S. Kim, J. Ha, S. Yoon, J. Chung

**MP5-14** OUTCOMES OF ENDOSCOPIC RADICAL CYSTECTOMY WITH EXTRACORPOREAL ILEAL CONDUIT  
G. Sung, T. Kim, K. Moon, W. Cho—Korea

**MP5-15** THE USE OF FLUORESCENCE IN SITU HYBRIDIZATION (FISH) TESTING IN PATIENTS WITH KNOWN UPPER TRACT TRANSITIONAL CELL CARCINOMA  
J. Johannes, E. Nelson, B. Lepchuk, M. Bibbo, D. Bagley—USA

**MP5-16** INTERMEDIATE-TERM EFFICACY OF INTRA-URETERAL BCG AND INTERFERON-ALPHA 2B FOR UPPER TRACT UROTHELIAL CARCINOMA  
L. Wang, J. Decastro, G. Hruby, J. Mckiernan, M. Benson, G. Mantu

**MP5-17** OPEN VERSUS ROBOT-ASSISTED RADICAL CYSTECTOMY: COMPARISON OF EARLY OUTCOMES AND COST  
J. Mandeville, S. Tsai, A. Sorcini, J. Libertino, D. Canes, A. Moinzadeh—USA

**MP5-18** COCULTURE OF BLADDER UROTHELIUM AND BLADDER ACELLULAR MATRIX SHEET  
Y. Haichao, X. Hanbiao, T. Shengping—China

**MP5-19** NOTES APPROACH TO MANAGEMENT OF INADVERTENT SPLENIC, ENTERAL AND BLADDER INJURIES  
S. Parekattil, sijo j., C. Fyock, H. Atalah, L. Su, C. Forsmark, M. Wagh

**MP5-20** SOME EXPERIENCES OF LAPAROSCOPIC RADICAL CYSTECTOMY WITH ORTHOTOPIC STUDER NEOBLADDER  
L. Ma, Y. Huang, X. Hou, G. Wang, L. Zhao, K. Hong

**MP6: MIS—KIDNEY AND ADRENAL**

16:00–17:30 hr

**MP6-01** INITIAL EXPERIENCE WITH CRYOABLATION FOR RENAL ANGIOMYOLIPOMA

J. Sausville, K. Suson, H. Richard, M. Phelan

**MP6-02** USE OF RENAL TISSUE FOR THE INVESTIGATION OF TISSUE SPECIFIC PHARMOCDELIVERY SYSTEMS

J. Durbin, P. Oh, S. Stroup, J. L'esperance, B. Auge, J. Schnitzer

**MP6-03** DURABLE ONCOLOGIC OUTCOMES FOLLOWING RADIOFREQUENCY ABLATION (RFA): EXPERIENCE FROM TREATING 243 SMALL RENAL MASSES OVER 7.5 YEARS

C. Tracy, J. Raman, C. Donnally, C. Trimmer, J. Cadeddu—USA

**MP6-04** COMPARISON OF PERCUTANEOUS RADIOFREQUENCY AND CRYOABLATION FOR THE TREATMENT OF SMALL RENAL MASSES

K. Ebrahimi, P. Mahdavi, C. Tenggardjaja, L. Nicolay, J. Smith, D. Baldwin—USA

**MP6-05** A PROSPECTIVE RANDOMIZED COMPARISON OF TRADITIONAL LESS TO NEEDLESCOPIC-ASSISTED LAPAROSCOPIC NEPHRECTOMY IN THE PORCINE MODEL

D. Baldwin, L. Nicolay, R. Bowman, N. Mehr, K. Ebrahimi, F. Jellison

**MP6-06** PERCUTANEOUS CRYOABLATION FOR LARGE RENAL MASSES

Z. Okhunov, J. Landman, B. Shingleton

**MP6-07** EVOLUTION OF SURGICAL THERAPY FOR RENAL MASSES: A

P. Sountoulides, M. Louie, D. Pick, A. Dash, E. Mcdougall, R. Clayman—CA

**MP6-08** LAPAROSCOPIC ADRENALECTOMY FOR PATIENTS WITH ALDOSTERONE-PRODUCING MICROADENOMA: PROPOSAL OF NEW CLASSIFICATION OF PRIMARY ALDOSTERONISM

S. Ishidoya, Y. Kawasaki, A. Ito, F. Satoh, T. Ishibashi, Y. Arai—Japan

**MP6-09** ADRENO-CORTICAL CANCER: OPEN OR LAPAROSCOPIC SURGERY?

C. Fiori, F. Porpiglia, F. Daffara, M. Terzolo, A. Angeli, R. Scarpa—Italy

**MP6-10** THE LONG-TERM SAFETY AND EFFICACY OF RADIOFREQUENCY ABLATION OF RENAL TUMOR INCLUDING 6 MONTHS FOLLOW UP BIOPSY

W. Cho, T. Kim, D. Kim, G. Sung, J. Chung—Korea

**MP6-11** ACTIVE SURVEILLANCE OF RENAL CORTICAL NEOPLASM

J. Rosales araujo, J. Moreno, A. Perez-lanzac, J. Mckiernan, K. Badani, J. Landman

**MP6-12** RATIONALE FOR A LESS AGGRESSIVE THERAPY FOR SMALL RENAL TUMORS

M. Tsivian, V. Mouraviev, M. Kimura, D. Albala, C. Robertson, T. Polascik—USA

**MP6-13** COMPLICATIONS AFTER LAPAROSCOPIC AND PERCUTANEOUS RENAL CRYOABLATION

V. Chen, M. Tsivian, D. Zilberman, R. Nelson, D. Albala, T. Polascik

**MP6-14** EFFECTS OF THE RENAL COLLECTING SYSTEM ON MICROWAVE ABLATION OF RENAL TISSUE

N. Salas, C. Moore, J. Zaias, J. Shields, V. Bird, R. Leveillee—USA

**MP6-15** COMPARISON OF PERCUTANEOUS AND LAPAROSCOPIC RENAL CRYOABLATION FOR SMALL

Z. Okhunov, A. Pérez-lanzac de lorca, J. Rosales, K. Badani, B. Shingleton, J. Landman

**MP6-16** ACTIVE SURVEILLANCE OF RENAL CORTICAL NEOPLASM

J. Rosales araujo, J. Moreno, A. Perez-lanzac, K. Badani, J. Mckiernan, J. Landman—USA

**MP6-17** THE USE OF SINGLE LUNG HIGH-FREQUENCY OSCILLATING VENTILATION DURING PERCUTANEOUS RENAL CRYOTHERAPY

R. Li, M. Louie, J. Rinehart, A. Wong, E. Mcdougall, R. Clayman

**MP6-18** PER-OPERATIVE HISTOLOGICAL NEEDLE BIOPSIES OF SMALL RENAL TUMORS PERFORMING LAPAROSCOPIC ABLATIVE SURGERY

H. Van der zee, B. Lagerveld

**MP6-19** INTERMEDIATE-TERM OUTCOMES OF RENAL CRYOABLATION: THE WASHINGTON UNIVERSITY EXPERIENCE

B. Benway, J. Landman, M. Gardner, C. Chen, S. Bhayani, R. Figenshau—USA

**MP6-20** ANALYSIS OF LOCAL RELAPSE AFTER LAPAROSCOPIC AND PERCUTANEOUS CRYOABLATION FOR RENAL TUMORS

M. Tsivian, B. Shingleton, V. Mouraviev, B. Wynia, J. Mayes, T. Polascik

**MP7: TRANSURETHRAL SURGERY**

16:00–17:30 hr

**MP7-01** TRANSURETHRAL RESECTION IN INTRAMURAL URETERAL STENOSIS TREATMENT

P. Geavlete, R. Multescu, D. Georgescu, B. Geavlete—Romania

**MP7-02** SECOND TURB IN NON MUSCLE INVASIVE BLADDER CANCER—EXPERIENCE ON 400 CASES  
P. Geavlete, D. Georgescu, B. Geavlete—Romania

**MP7-03** HAL FLUORESCENCE CYSTOSCOPY AND TURB: A BETTER CHANCE FOR PATIENTS WITH NON-MUSCLE INVASIVE BLADDER TUMORS?  
B. Geavlete, R. Multescu, D. Georgescu, M. Jecu, P. Geavlete—Romania

**MP7-04** PROSTATIC URETHRAL DIAMETER AS A POTENTIAL NON-INVASIVE MEASURE OF OBSTRUCTION: A COMPUTATIONAL FLUID DYNAMICS SIMULATION STUDY  
Y. Siang lin, H. Chin tiong, L. Heow pueh—Singapore

**MP7-05** BLADDER NECK STRICTURE AFTER TRANSURETHRAL PROSTATECTOMY (TURP) ASSESSMENT OF RISK FACTORS  
R. Mahdavi zafarghandi, D. Arab, M. Mahdavi zafarghandi—Iran

**MP7-06** EXPERIENCE WITH A LONG-STANDING METALLIC STENT IN MANAGEMENT OF MALIGNANT URETERAL OBSTRUCTION A. D'ADDESSI, M. RACIOPPI, F. PINTO, PF. BASSI DEPARTMENT OF UROLOGY. CATHOLIC UNIVERSITY SCHOOL OF MEDICINE, ROME, ITALY  
A. D'addressi, M. Racioppi, F. Pinto, P. Bassi

**MP7-07** FLUORESCENCE ENHANCED CYSTOSCOPY AND TRANSURETHRAL RESECTION OF BLADDER CANCER IMPROVE THE QUALITY OF RESECTION, ACCURACY OF STAGING AND PATIENTS CARE  
G. Joachim, A. Makris, K. Durt, G. Jakse

**MP7-08** OPTIMIZATION OF CONTINUOUS URETHRAL BLADDDER IRRIGATION BY ADDITION OF EXTRA INFLOW THROUGH A SUPRAPUBIC CATHETER  
R. Norman, L. Connor

**MP7-09** A COMPARATIVE STUDY OF URINE CYTOLOGY AND FLUORESCENCE IN SITU HYBRIDIZATION (FISH) FOR DETECTING UROTHELIAL CARCINOMA OF UPPER URINARY TRACT  
W. Kim, H. Kim, J. Choi, S. Seo, S. Jeon, B. Jeong

**MP7-10** NARROW BAND IMAGING CYSTOSCOPY IMPROVES THE DIAGNOSTIC WORKUP FOR NON-MUSCLE INVASIVE BLADDER CANCER  
E. Cauberg, S. Kloen, M. Visser, J. De la rosette, M. Babjuk, T. De reijke—The Netherlands

**MP7-11** TRANSURETHRAL HOLMIUM LASER LITHOTRIPSY IN THE TREATMENT OF VESICAL CALCULUS  
J. Lu, C. Wang, Y. Hou, Q. Chen, J. Hu

**MP7-12** RETROGRADE ENDOURETHROTOMY WITH HOLMIUM :YAG LASER FOR TREATMENT OF URETHRAL STRICTURES  
Z. Wu, Q. Ding, H. Jiang, P. Gao, Y. Zhang—China

**MP7-13** INSTILLATION THERAPY AFTER ENDOSCOPIC TREATMENT OF UPPER URINARY TRACT TRANSITIONAL CELL CANCER VIA VESICO-URETERAL REFLUX?  
G. Wendt-nordahl, P. Honeck, T. Knoll

**MP7-14** VIRTUAL TRANSURETHRAL RESECTION (TUR) OF THE BLADDER TRAINING FOR NOVICE UROLOGISTS  
S. Kruck, J. Bedke, S. David, C. Schwentner, A. Stenzl, K. Sievert

**MP7-15** FLUORESCENCE CYSTOSCOPY WITH HEXAMINOLEVULINATE IN BLADDER CANCER: OUR EXPERIENCE  
P. Massimiliano, C. Cracco, C. Scoffone, M. Cossu, S. Grande, R. Scarpa

**MP7-16** A RANDOMISED SINGLE-BLIND COMPARISON OF THE EFFECTIVENESS OF THE HIGH-LEVEL DISINFECTANTS TRISTEL FUSION (CHLORINE DIOXIDE) AND CIDEX OPA (ORTHO-PHTHALDEHYDE) FOR USE WITH FLEXIBLE CYSTOSCOPES: RATIONALE AND STUDY DESIGN  
P. Gillling, R. Reuther, M. Fraundorfer, C. Frampton, M. Lockhart, M. Addidle

**MP7-17** FOLLOW-UP EVALUATION OF A GENITOURINARY SKILLS TRAINING CURRICULUM FOR MEDICAL STUDENTS  
A. Kaplan, S. Kolla, P. Sountoulidis, O. Kaufmann, R. Clayman, E. Mcdougall

**MP7-18** COMPARISON OF RE-RESECTION RATES FOR NEW G3PT1 BLADDER CANCER, IN PATIENTS RANDOMISED TO INITIAL BLUE LIGHT OR WHITE LIGHT RESECTION: 1 YEAR FOLLOW UP DATA  
D. Wilby, B. Chappell, E. Ray, K. Chatterton, T. O'brien

**MP7-19** THE USE OF KTP LASER FOR ABLATION OF SMALL, SUPERFICIAL TRANSITIONAL CELL CARCINOMA OF BLADDER IN OUTPATIENT, OFFICE SETTING  
M. Siddiqui, J. Grocela, W. Mcdougal, K. Alvi, S. Psutka, S. Tabatabaei

**MP7-20** A NOVEL TECHNIQUE FOR UPPER TRACT HEXYLAMINOLAEVULINATE BLUE LIGHT FLUORESCENCE FACILITATES UPPER TRACT CIS DIAGNOSIS  
E. Havranek, D. Hrouda, J. Ramsay, A. Shamsuddin—United Kingdom

**MP8: URETERORENOSCOPY**

16:00–17:30 hr

**MP8-01** FLEXIBLE RETROGRADE URETEROSCOPY/  
HOLMIUM LASER LITHOTRIPSY FOR THE  
TREATMENT OF RENAL STONES MEASURING 2-3CM:  
A MULTI-INSTITUTIONAL EXPERIENCE

E. Hyams, J. Uberoi, R. Munver, O. Shah—USA

**MP8-02** THE DIFFICULT URETER: WHAT  
IS THE INCIDENCE OF PRE-STENTING?

R. Cetti, S. Keoghane—UK

**MP8-03** URETEROSCOPY AND LITHOTRIPSY  
OF URETERAL CALCULI: STENTED VS.  
NON-STENTED, A RANDOMIZED CLINICAL TRIAL  
(PRELIMINARY REPORT)

M. Hosseini, K. Tamaddon, A. Aminsharifi, A. Aryafar,  
A. Yousefi, A. Hassanpour—Iran

**MP8-04** COMPARISON OF A REDUCED  
AND STANDARD FLUOROSCOPIC PROTOCOL  
DURING URETEROSCOPIC LITHOTRIPSY

G. Agarwal, D. Greene, C. Tenggardjaja, R. Bowman,  
K. Ebrahimi, D. Baldwin—USA

**MP8-05** OPTIMIZING RETROGRADE FLEXIBLE  
URETEROSCOPY FOR UPPER URINARY TRACT  
PATHOLOGY

R. Multescu, B. Geavlete, D. Georgescu,  
P. Geavlete—Romania

**MP8-06** THE EXPERIENCE OF USE URETERAL  
ACCESS SHEATHS IN TRANSURETHRAL  
PYELOCALICOLITHOTRIPSY. SCIENTIFIC RESEARCH  
INSTITUTE OF UROLOGY, MOSCOW, RUSSIAN  
FEDERATION

R. Fatikhov, D. Merinov, E. Borisenko

**MP8-07** RETROGRADE URETEROPYELOSCOPIC  
TREATMENT OF LARGE UPPER URINARY TRACT  
AND STAGHORN CALCULI WITH AQUAGUIDE

M. Araki, S. Uehara, T. Watanabe, T. Saika, Y. Nasu, H. Kumon

**MP8-08** SUITABILITY AND INDICATION OF  
URETEROPYELOSCOPY BASED ON RADIOGRAPHIC  
FINDINGS AND URINE CYTOLOGY FOR DETECTION  
OF UPPER URINARY TRACT CARCINOMA

A. Takao, T. Saika, S. Uehara, K. Monden, T. Watanabe,  
H. Kumon

**MP8-09** PREDICTORS FOR NEGATIVE  
URETEROSCOPY IN THE MANAGEMENT  
OF UPPER URINARY TRACT STONE DISEASE

R. Dickstein, J. Manger, R. Babayan, D. Wang—USA

**MP8-10** LARGE URETERAL FIBROEPITHELIAL  
POLYPS CAN BE TREATED ENDOSCOPICALLY USING  
HOLMIUM:YAG LASER

C. Kara, B. Resorlu, E. Sahin, A. Unsal—Turkey

**MP8-11** EFFICACY OF URETEROLITHOTRIPSY WITH  
THE STONEBREAKER™ SYSTEM

A. Leventis, S. Leontis, L. Leonardopoulos, G. Sakelariou,  
D. Georgoulas, A. Rempelakos

**MP8-12** COMPARATIVE EVALUATION  
OF PNEUMATIC VERSUS HOLMIUM:YAG  
LASER LITHOTRIPSY FOR IMPACTED URETERAL  
STONES

M. Binbay, A. Singh, A. Tepeler, T. Akman, A. Muslumanoglu,  
A. Tefekli

**MP8-13** THE PEDITROL IRRIGATION SYSTEM  
FOR URETERORENOSCOPY—OUR EXPERIENCE

S. Umranikar, R. Kulkarni, P. Kumar, K. Patil

**MP8-14** PROSPECTIVE STUDY OF 630  
CONSECUTIVE FLEXIBLE URETERORENOSCOPES  
(FURS) OF THE UPPER URINARY TRACT

P. Ober, P. Liske, Y. Aguilar, S. Lahme—Germany

**MP8-15** CAN FLEXIBLE URETERORENOSCOPY  
(FURS) BE RECOMMENDED IN THE TREATMENT  
OF STONE MASSES GREATER THAN 100MM<sup>2</sup>  
IN THE UPPER URINARY TRACT?

P. Ober, V. Zimmermanns, P. Liske, S. Lahme

**MP8-16** THE IMPACT OF ACCESS SHEATHS  
ON STONE FREE RATES AFTER URETEROSCOPY:  
THE PRELIMINARY RESULTS OF A CANADIAN  
MULTICENTRE RANDOMIZED CONTROLLED TRIAL

C. Mendez probst, L. Nott, D. Beiko, B. Chew, T. Wollin,  
H. Razvi—Canada

**MP8-17** ENDOSCOPIC MANAGEMENT OF  
RETAINED FOREIGN BODIES FOLLOWING  
FLEXIBLE URETERORENOSCOPY FOR RENAL  
CALCULI THE STONE CENTRE, DEPARTMENT  
OF UROLOGY, DARENT VALLEY HOSPITAL,  
KENT, UK

A. Sahai, H. Marsh, J. Palmer, S. Sriprasad

**MP8-18** “PUSH-PULL”—A GOOD OPTION  
FOR LARGE BULK UPPER URETERAL STONES

A. Kurien, L. Sinha, A. Patel, S. Mishra, R. Sabnis, M. Desai

**MP8-19** THE NEED FOR INTRODUCER  
SHEATHS FOR URETERIC ACCESS: A COMPARATIVE  
STUDY BETWEEN OLD GENERATION FIBRE-  
OPTIC FLEXIBLE URETEROSCOPES AND THE  
NEW INVISIO DUR-D DIGITAL FLEXIBLE  
URETEROSCOPE

T. El-husseiny, S. Nesar, Z. Maan, A. Papatsoris, J. Masood,  
N. Buchholz—UK

**MP8-20** PERCUTANEOUS ANTEGRADE  
URETEROSCOPY AN EFECTIVE PROCEDURE FOR  
REMOVING IMPACTED UPPER AND MID URETERIC  
STONES

M. Baptistussi, M. Morihisa, E. Gewher, A. Martins—Brasil

**VP11: IMAGING AND NEW TECHNIQUE**

16:00–17:30 hr

**VP11-01** EVALUATION OF ACUTE RENAL COLIC: A COMPARISON OF NONCONTRAST CT VERSUS 3 TESLA NONCONTRAST HASTE MR UROGRAPHY

M. Semins, M. Bohlman, W. Hosek, J. Berkowitz, B. Matlaga—USA

**VP11-02** IDENTIFYING URIC ACID STONES USING DUAL-ENERGY COMPUTED TOMOGRAPHY: FIRST DIAGNOSTIC PERFORMANCE EVALUATION IN PATIENTS

M. Kozomara, P. Stolzmann, H. Scheffel, S. Leschaka, M. Müntener

**VP11-03** INTRA-OPERATIVE SELECTIVE RENAL ARTERY BALLOON OCCLUSION DURING LAPAROSCOPIC RADICAL NEPHRECTOMY—DEMONSTRATION OF THE TECHNIQUE

S. Kommu, M. Nayeemuddin, C. Luscombe, A. Golash, J. Asquith, D. West—United Kingdom

**VP11-04** CLINICAL OBSERVATION OF MALE VOIDING USING DYNAMIC MAGNETIC RESONANCE IMAGING: A PRELIMINARY STUDY OF BLADDER OUTLET OBSTRUCTION

Y. Siang lin, H. Chin tiong, L. Heow pueh—Singapore

**VP11-05** DIGITAL VIDEO FLEXIBLE URETEROSCOPY: GYRUSACMI/OLYMPUS INVISIO®DUR®-D TWELVE MONTH FAILURE AND REPAIR EXPERIENCE

B. Knudsen, M. Ferraro, K. Shah

**VP11-06** A PROSPECTIVE RANDOMIZED EVALUATION OF LAPAROSCOPIC DOPPLER TECHNOLOGY FOR HILAR DISSECTION DURING MINIMALLY INVASIVE PARTIAL NEPHRECTOMY

E. Hyams, P. Mufarrij, M. Perlmutter, M. Stifelman—USA

**VP11-07** EARLY DETECTION OF LOCAL AND NODAL RECURRENCES FOLLOWING RADICAL PROSTATECTOMY BY USING THE INTEGRATED 18F-CHOLINE PET-CT

G. Simone, R. Papalia, S. Guaglianone, M. Ferriero, E. Forastiere, M. Gallucci

**VP11-08** UPDATE ON PSA-NADIR PREDICTING TREATMENT FAILURE AFTER HIGH-INTENSITY FOCUSED ULTRASOUND (HIFU) OF LOCALIZED PROSTATE CANCER—APPLICATION OF THE STUTTGART FAILURE CRITERIA

R. Ganzer, H. Fritsche, W. Wieland, A. Blana

**VP11-09** COMBINED USING OF LAPAROSCOPIC AND FLOROSCOPING IMAGING TO PERFORM NEPHROLITHOTOMY IN A PATIENT WHO HAS RETRORENAL COLON; A NEW TECHNIC

F. Demirel, F. Yalcinkaya, M. Cakam, B. Kara, U. Altug

**VP11-10** RISK OF TRACT RECURRENCES FOLLOWING PERCUTANEOUS RESECTION FOR UPPER TRACT UROTHELIAL CARCINOMA: CLINICAL, PATHOLOGIC AND RADIOLOGIC EVALUATION

B. Irwin, A. Berger, R. Brandina, R. Stein, S. Shah, M. Desai—USA

**VP11-11** INITIAL EXPERIENCE WITH THE FREEHAND™ ROBOTIC CAMERA HOLDER IN LAPAROSCOPIC UROLOGY

D. Sharma, C. Brown, C. Kouriefs, H. Sood, P. Grange, H. Patel—UK

**VP11-12** STANDARDIZED LINEAR PORT PLACEMENT FOR LAPAROSCOPIC UROLOGIC SURGERY: EXPERIENCE WITH 1264 CASES

J. Harper, J. Leppert, A. Breda, P. Schulam

**VP11-13** RADIOFREQUENCY ASSISTED LAPAROSCOPIC PARTIAL NEPHRECTOMY: A NOVEL ALTERNATIVE IN TREATMENT OF SMALL RENAL MASSES

J. Diaz, I. Pinto, A. Hornig, C. Sandoval—Chile

**VP11-14** EVALUATION OF A NOVEL DISSECTING SUCTION IRRIGATOR INSTRUMENT

D. Pick, J. Lee, M. Louie, E. Mcdougall, R. Clayman, J. Landman—CA

**VP11-15** APPLICATION OF RADIOFREQUENCY INTERSTITIAL TUMOR ABLATION(RITA) IN “NO CLAMP—NO SUTURE” LAPAROSCOPIC PARTIAL NEPHRECTOMY

R. Papalia, G. Simone, M. Ferriero, S. Guaglianone, E. Forastiere, M. Gallucci

**VP11-16** A NOVEL TECHNIQUE FOR LARGE, MULTIPLE URETERIC STONE: ANTEGRADE FLUSH & RETROGRADE URS

T. Haresh

**VP11-17** LAPAROSCOPIC COLD KNIFE: A NEW INSTRUMENT FOR URETERAL INCISION

S. Guven, M. Kilinc, D. Yuksel, L. Tunc, S. Basal, Y. Ozgok

**VP11-18** REPEATED TRANSURETHRAL RESECTION AND INTRAVESICAL BCG FOR EXTENSIVE SUPERFICIAL TRANSITIONAL CELL CARCINOMA OF THE BLADDER: A REPORT OF 106 CASES

S. Sallami, S. Ben rhouma, H. Mohamed, Y. Nouria, A. Horchani

**VP11-19** CRITERIA TO PREDICT SUCCESSFUL STONE TREATMENT UTILIZING A DISPOSABLE FLEXIBLE URETEROSCOPE

P. Lowry—Texas

**VP11-20** COMPUTATIONAL FLUID DYNAMICS MODELS OF URINE FLOW THROUGH URETEROPELVIC JUNCTION (UPJ) OBSTRUCTIONS  
J. Sumfest

**VP12: LAPAROSCOPY PROSTATE-2**  
16:00–17:30 hr

**VP12-01** A PROSPECTIVE, NON-RANDOMIZED SINGLE-SURGEON STUDY TRIAL COMPARING EXTRAPERITONEAL LAPAROSCOPIC INTRAFASCIAL NERVE-SPARING VERSUS OPEN RETROPUBIC INTRAFASCIAL NERVE-SPARING RADICAL PROSTATECTOMY: SURGICAL TRAUMA AND FUNCTIONAL OUTCOMES  
F. Greco, S. Wagner, O. Reichelt, M. Hoda, A. Hamza, P. Fornara

**VP12-02** HIGH RISK PROSTATE CANCER IN LAPAROSCOPICALLY TREATED LOCALIZED PROSTATE CARCINOMA  
R. Sanchez-salas, F. Bianco Jr, X. Cathelineau, F. Rozet, E. Barret, G. Vallancien—France

**VP12-03** INTRAFASCIAL NERVE SPARING ROBOT-ASSISTED LAPAROSCOPIC RADICAL PROSTATECTOMY: OUR INITIAL EXPERIENCE  
F. Porpiglia, C. Fiori, M. Lucci chiarissi, M. Manfredi, S. Grande, R. Scarpa

**VP12-04** EXTRAPERITONEOSCOPIC INTRAFASCIAL NERVE SPARING PROSTATECTOMY: ONCOLOGIC AND FUNCTIONAL OUTCOMES  
F. Porpiglia, C. Fiori, M. Manfredi, M. Lucci chiarissi, S. Grande, R. Scarpa

**VP12-05** LAPAROSCOPIC RADICAL PROSTATECTOMY (REPORTED OF 110 CASES)  
Y. Changjun

**VP12-06** ANATOMICAL RECONSTRUCTION OF THE CONTINENCE MECHANISM FOLLOWING LAPAROSCOPIC RADICAL PROSTATECTOMY  
A. Ghazi, R. Zimmermann, A. Schfler, G. Janetschek—Austria

**VP12-07** EVALUATION OF EARLY CONTINENCE AFTER ENDOSCOPIC EXTRAPERITONEAL RADICAL PROSTATECTOMY  
J. Stolzenburg, M. Nicolaus, M. Do, A. Dietel, E. Liatsikos

**VP12-08** LAPAROSCOPIC RADICAL PROSTATECTOMY IS FEASIBLE AND EFFECTIVE IN FIT SENIOR ADULTS WITH HIGH RISK LOCALIZED PROSTATE CANCER  
R. Sanchez-salas, X. Cathelineau, F. Rozet, E. Barret, M. Galiano, G. Vallancien—France

**VP12-09** LAST 50 LAPAROSCOPIC RADICAL PROSTATECTOMY (OF A SERIES OF MORE THAN 400 PATIENTS) VS FIRST 50 ROBOT-ASSISTED LAPAROSCOPIC RADICAL PROSTATECTOMY: OUR RESULTS  
F. Porpiglia, C. Fiori, M. Lucci chiarissi, M. Manfredi, S. Grande, R. Scarpa

**VP12-10** RETROGRADE NERVE-SPARING LAPAROSCOPIC RADICAL PROSTATECTOMY TECHNIQUE THAT MIMICS OPEN SURGERY AND ITS ONCOLOGICAL RESULTS  
A. Garcia segui, E. Bercowsky u, R. Matheus, H. Yaime, R. Valero, A. Lopez—Spain

**VP12-11** LAPAROSCOPIC “SINGLE KNOT—SINGLE RUNNING SUTURE” VESICO-URETHRAL ANASTOMOSIS WITH RESTORATION OF POSTERIOR RABDOSPHYNCTER  
G. Simone, S. Guaglianone, R. Papalia, A. Bove, E. Forastiere, M. Gallucci

**VP12-12** KNOTLESS ANASTOMOSIS DURING LAPAROSCOPIC RADICAL PROSTATECTOMY  
M. Kilciler, L. Tahmaz, S. Bedir, H. Guler, M. Dayanc

**VP12-13** LIMITED AND EXTENDED PELVIC LYMPHADENECTOMY IN ROBOTIC RADICAL PROSTATECTOMY: CONCLUSIONS FROM 195 CASES  
H. John, N. Engel, D. Bergstein, B. Fischer, J. Fehr

**VP12-14** URINARY CONTINENCE AFTER VIDEOLAPAROSCOPIC RADICAL PROSTATECTOMY BASED ON ANATOMICAL LANDMARKS  
J. Travassos, A. Xavier, Á. M. figueiredo fº facs, K. De juan—Brazil

**VP12-15** NO-SUTURE X SUTURE IN LAPAROSCOPIC RADICAL PROSTATECTOMY  
J. Travassos, A. Xavier, Á. M. figueiredo fº facs, F. Chagas dos santos, R. Brites, K. De juan—Brazil

**VP12-16** EXTRAPERITONEAL LAPAROSCOPIC RADICAL PROSTATECTOMY: CLINICAL EXPERIENCE AND LEARNING CURVE OF 103 CASES  
S. Jung, H. Chung, J. Park, E. Hwang, C. Im, D. Kwon—South Korea

**VP12-17** EXTRAPERITONEAL APPROACH FOLLOWING TRANSPERITONEAL SEMINAL VESICLE DISSECTION IN LAPAROSCOPIC RADICAL PROSTATECTOMY  
M. Kawakita, G. Kawa, H. Kinoshita, T. Matsuda—Japan

**VP12-18** LAPAROSCOPIC SIMPLE PROSTATECTOMY: LONG TERM RESULTS  
F. Porpiglia, C. Fiori, B. Cavallone, S. Grande, R. Scarpa

**VP12-19** INTERFASCIAL MICROPNEUMATIC BALLOON AIDED TISSUE PLANAR FLUID DISSECTION DURING LAPAROSCOPIC RADICAL PROSTATECTOMY – PRELIMINARY CONCEPT  
S. Kommu, C. Eden, F. Mumtaz, A. Golash, C. Luscombe, J. Emtage—United Kingdom

**VP12-20** POSITIVE MARGINS AFTER LAPAROSCOPIC RADICAL PROSTATECTOMY (LRP): WHAT ARE THE INFLUENCING FACTORS?  
M. Baptistussi, M. Morihisa, E. Gewher, A. Martins—Brasil

**VS5: PERCUTANEOUS SURGERY 1**  
16:00–17:30 hr

**VS5-01** TUBELESS PERCUTANEOUS NEPHROLITHOTOMY: OPERATIVE STEPS AND RESULTS  
A. Elnahas I. Eraky—Egypt

**VS5-02** A NOVEL 5 PART PERCUTANEOUS ACCESS NEEDLE WITH GLIDEWIRE (5-PANG) TECHNIQUE FOR FASTER PERCUTANEOUS NEPHROLITHOTOMY: OUR INITIAL EXPERIENCE  
A. Ashish patil—India

**VS5-03** X-RAY FREE PERCUTANEOUS NEPHROLITHOTOMY IN SUPINE POSITION WITH ULTRASOUND GUIDANCE  
A. Basiri, M. Mohammadi sichani, A. Moradi vadjargah

**VS5-04** SETTING NEW FRONTIERS IN PEDIATRIC PCNL LESS THAN 2 YEARS: MINIPERC, MINI INSTRUMENT TECHNIQUE  
R. Patel, S. Mishra, A. Ganpule, R. Sabnis, M. Desai

**VS5-05** SUPINE PERCUTANEOUS NEPHROLITHOTOMY IN HORSESHOE KIDNEY  
M. De sio, R. Autorino, C. Quattrone, D. Sorrentino, M. D'armiento—Italy

**VS5-06** PERFORMING PERCUTANEOUS NEPHROLITHOTOMY IN THE PRONE-FLEXED POSITION: TECHNIQUE AND BENEFITS  
A. Ray, K. Pace, R. Honey—Canada

**VS5-07** HEMOSTATIC GELATIN MATRIX SANDWICH: AN EFFECTIVE AND MINIMALLY INVASIVE TECHNIQUE TO CONTROL BLEEDING FOLLOWING PERCUTANEOUS NEPHROLITHOTOMY  
G. Lamberton, C. Tenggardjaja, F. Jellison, G. Huang, W. Millard II, D. Baldwin—USA

**VS5-08** THE USE OF HOLMIUM LASER DURING PERCUTANEOUS NEPHROLITHOTRIPTY  
A. Kural, H. Akpınar, I. Tufek, F. Atug, S. Aksit—Turkey

**VS5-09** THE TECHNIQUE OF PERCUTANEOUS NEPHROLITHOLAPAXY IN SUPINE POSITION

V. Bucuras, R. Bardan, C. Jude, C. Comsa, M. Georgiadis—Romania

**VS5-10** SUPINE PERCUTANEOUS NEPHROLITHOTOMY  
A. Hoznek, S. Esquivel, K. De laet, A. De la taille, L. Salomon, C. Abbou

**VS6: LAPAROSCOPY—KIDNEY 2**  
16:00–17:30 hr

**VS6-01** USE OF A NOVEL HEMOSTATIC AGENT IN LAPAROSCOPIC PARTIAL NEPHRECTOMY  
I. Yavascaoglu, F. Gasanov, H. Dogan, H. Vuruskan, B. Oktay—Turkey

**VS6-02** KNOTLESS INTRAPERITONEAL LEFT LAPAROSCOPIC PARTIAL NEPHRECTOMY  
M. Kilciler, L. Tahmaz, S. Bedir, H. Guler, E. Oral, M. Dayanc

**VS6-03** LAPAROSCOPIC PARTIAL NEPHRECTOMY FOR TUMORS NEAR THE RENAL HILUM: A TECHNIQUE FOR PRE-EMPTIVE ANATOMIC DISSECTION AND VASCULAR CONTROL  
A. Goh, S. Matin—USA

**VS6-04** LAPAROSCOPIC PARTIAL NEPHRECTOMY FOR HILAR TUMOUR  
F. Porpiglia, C. Fiori, R. Bertolo, M. Manfredi, M. Lucci, R. Scarpa

**VS6-05** LAPAROSCOPIC PARTIAL NEPHRECTOMY WITH PARENCHYMAL HAEMOSTASIS WITH TACHOSIL APPLICATION  
R. Sanseverino, O. Intilla, G. Napodano, U. Di mauro, T. Realfonso—Italy

**VS6-06** LAPAROENDOSCOPIC SINGLE SITE (LESS) PARTIAL NEPHRECTOMY WITH COMPLETE HILAR CONTROL  
A. George, M. Atalla, S. Andonian, A. Srinivasan, L. Richstone—USA

**VS6-07** A COMPLETE LAPAROSCOPIC NEPHROURETERECTOMY WITH BLADDER CUFF EXCISION  
A. Ghazi, R. Zimmermann, A. Schfler, G. Janetschek—Austria

**VS6-08** LAPAROSCOPIC HEMINEPHROURETERECTOMY (HNUT) FOR URETERAL DUPLICATION WITH VAGINAL ECTOPY  
U. Anceschi, A. Amici, C. Torcia, L. La vecchia, F. Peris

**VS6-09** RETROPERITONEAL LAPAROSCOPIC LEFT RADICAL NEPHRECTOMY INVOLVING RENAL VEIN TUMOR THROMBUS  
W. Lv, G. Hao, J. Xiao—China PR

**VS6-10** LASERVAPORISATION: TREATMENT OF AN AV-MALFORMATION IN THE RENAL PELVIS  
A. Saljoughi, M. Kuczyk, S. Waalkes, T. Bach, A. Groos, T. Herrmann

## THURSDAY, OCTOBER 8

### VP13: FEMALE UROLOGY

10:30–12:00 hr

**VP13-01** GENTIOURINARY TRACT EROSION OF MINIMALLY INVASIVE TECHNIQUES COMPARED TO OPEN ANTI-INCONTINENCE SURGICAL APPROACHES AND THEIR MANAGEMENT  
F. Sharifiaghdas, N. Mortazavi

**VP13-02** EFFECT OF REPEATED BOTULINUMTOXIN-A INJECTIONS IN A PATIENT WITH LUMBOSACRAL SPINA BIFIDA AND SEVERE NEUROGENIC BLADDER DYSFUNCTION—A CASE REPORT  
R. Steiner, P. Honeck, G. Wendt-nordahl, T. Knoll—Germany

**VP13-03** LAPAROSCOPIC SACROCOLPOPEXY USING TITANIZED POLYPROPYLENE MESH—INITIAL EXPERIENCES WITH THE FIRST 10 PATIENTS—  
M. HATZINGER, D. VÖGE, M. LÖHR, M. SOHN  
DEPARTMENT OF UROLOGY, MARKUSHOSPITAL, FRANKFURT, GERMANY  
H. Martin, D. Vöge, M. Löhr, M. Sohn

**VP13-04** TRANSVESICOSCOPIC REPAIR OF VESICOVAGINAL FISTULA  
S. Devaraju, A. Guntaka, R. Nerli, M. Reddy—India

**VP13-05** SINGLE PORT LAPAROSCOPIC SACRAL COLPOPEXY: INITIAL OPERATIVE EXPERIENCE AND COMPARATIVE OUTCOMES  
W. White, R. Goel, G. Haber, M. Swartz, R. Rackley, J. Kaouk

**VP13-06** LAPAROSCOPIC TRANSURETEROURETEROSTOMY WITH ILEAL CONDUIT IN RADIATION INDUCED VESICOVAGINAL FISTULA  
M. Ramalingam, K. Senthil, M. Pai

**VP13-07** MINIMALLY INVASIVE APPROACH TO UROGYNECOLOGIC FISTULA: OUR EXPERIENCE  
A. Guntaka, S. Devaraju, R. Nerli, M. Reddy—India

**VP13-08** LAPAROSCOPIC SACROCOLPOPEXY: INITIAL EXPERIENCE IN 10 CASES  
O. Castillo, F. Sepulveda, I. Vidal-mora, A. Foneron, G. Rubio, R. Campos

**VP13-09** LAPAROSCOPIC COLPOSACROPEXY WITH BIOMESH (PELVISOFT®) IN THE TREATMENT OF PELVIC ORGAN PROLAPSE  
S. Corvin, C. Antwerpen, G. Bromberger, H. Hammerl, M. Ulbrich—Germany

**VP13-10** LAPAROSCOPIC VESICOVAGINAL FISTULA REPAIR: 9 CASES  
I. Vidal-mora, O. Castillo, F. Sepúlveda, G. Rubio, A. Foneron, R. Campos

**VP13-11** LAPAROSCOPIC VESICOVAGINAL FISTULA REPAIR  
J. Diaz, R. Rizzo, A. Pabon, I. Pinto, C. Sandoval, A. Hornig—Chile

**VP13-12** TECHNICAL NUANCES IN THE LAPAROSCOPIC REPAIR OF VESICOVAGINAL AND UTEROVAGINAL FISTULAE  
M. Agarwal, S. Singh, R. Mavuduru, A. Mandal—India

**VP13-13** EFFECT OF LAPAROSCOPIC REPAIR OF VESICOVAGINAL FISTULA  
W. Dongwen, C. Xiaoming, G. Jinxi, X. Yunfa, X. Yunfa, L. Xuezhi

**VP13-14** COMPARISON OF OPEN, LOCAL AND LAPAROSCOPIC VARICOCECTOMY ACCORDING TO OPERATION TIME, COST, SPERMOGRAM AND COMPLICATIONS  
A. Shamsa, L. Mohamadi, M. Abolbashari, M. Shakeri, S. Shamsa

**VP13-15** EXPERIENCE WITH LAPAROSCOPIC “CLIPLESS” BILATERAL VARICOCECTOMY WITH MASS LIGATION-DIVISION OF SPERMATIC VESSELS USING SILK 1-0  
E. Arada iii, P. Fausto—Philippines

**VP13-16** LAPAROSCOPIC CONTROLLED AND ASSISTED PERCUTANEOUS TRANSPERITONEAL ENDOSCOPIC EXTRACTION OF RENAL COLLECTING SYSTEM STONE CALCULI  
M. Baptistussi, M. Morihisa, E. Gewher, A. Martins

**VP13-17** RETROPERITONEOSCOPIC PYELOPLASTY: OUR EXPERIENCE: ABOUT 28 CASES  
Y. Nouira, Y. Kallel, A. Dahmani, S. Sallami, Z. Fitouri, A. Horchani

**VP13-18** UPPER URINARY TRACT LAPAROSCOPY IN OBESE PATIENT  
R. Maghsoudi, P. Shadpour, K. Mehravaran

**VP13-19** COMPARING RENAL CELL CARCINOMA TUMOR SIZE WITH PATHOLOGICAL GRADE: A CONTEMPORARY 10 YEAR EXPERIENCE  
J. Jamal, E. Kwon, J. Fracchia, R. Sosa—USA

**VP13-20** LAPAROSCOPIC DISMEMBERED PYELOPLASTY FOR TREATMENT OF RETROCAVAL URETER: 2 YEARS FOLLOWUP IN 12 PATIENTS  
X. Gao, J. Qiu, X. Pu



**VP14: BPH 1**

10:30–12:00 hr

**VP14-01** BIPOLAR VERSUS MONOPOLAR TRANSURETHRAL RESECTION OF THE PROSTATE: A META-ANALYSIS OF RANDOMIZED CLINICAL TRIALS

C. Mamoulakis, D. Ubbink, M. Laguna, J. De la rosette—Netherlands

**VP14-02** FACE AND CONTENT VALIDATION FOR TRANSURETHRAL RESECTION OF PROSTATE ON URO TRAINER: IS IT WORTHWHILE?

S. Mishra, A. Kurien, A. Ganpule, R. Patel, R. Sabnis, M. Desai—India

**VP14-03** VAPOENUCLEATION OF THE PROSTATE. EFFICACY AND COMPLICATIONS DURING AN INTERMEDIATE FOLLOW-UP INTERVAL LONGER THAN 12 MONTHS

T. Bach, C. Netsch, A. Haecker, T. Herrmann, M. Michel, A. Gross

**VP14-04** OPTIMAL TREATMENT OF BPH (BENIGN PROSTATE HYPERPLASIA) USING A MULTI-DISCIPLINARY DIOLAS LFD 3000 LASER FOR PHOTOSELECTIVE VAPORIZATION OF THE PROSTATE

J. Neymeyer, T. Wülfing, W. Abdul-wahab al-ansari, A. Apostolidis, M. Beer

**VP14-05** HIGH POWER 120 W THULIUM LASER FOR VAPO-RESECTION AND VAPO-ENUCLEATION OF PROSTATE. OUR EXPERIENCE

S. Mattioli, A. Picinotti, M. Sbragi, M. Sabatino

**VP14-06** ENERGY DELIVERY REGARDING PROSTATE VOLUME IN GREEN LIGHT LASER (KTP, 120-W) VAPORISATION OF THE PROSTATE

C. Yee, A. Wong, M. Ng, S. Mak, H. Cheung, S. Hou—China

**VP14-07** HOLMIUM LASER ENUCLEATION OF THE PROSTATE: NON-MENTOR-AIDED LEARNING CURVE

C. Jeong, M. Cho, J. Bae, S. Oh

**VP14-08** THE LEARNING CURVE OF 120-W PHOTOSELECTIVE VAPORIZATION OF THE PROSTATE FOR BENIGN PROSTATIC HYPERPLASIA

Y. Zang, Y. Shan, B. Xue, D. Yang

**VP14-09** EXPERIENCE IN HOLEP (HOLMIUM LASER ENUCLEATION OF PROSTATE) IN A SMALL UROLOGICAL INPATIENT WARD (BELEGABTEILUNG) WITH AURIGA XL

J. Bubeck—Deutschland

**VP14-10** BIPOLAR ENDOSCOPIC ENUCLEATION IN THE MANAGEMENT OF PATIENTS WITH BIG BENIGN PROSTATIC ENLARGEMENT

S. Chan, Y. Chiu, M. Yiu

**VP14-11** TM:YAG LASER PROSTATECTOMY INTERMEDIATE-TERM RESULTSIN SUBGROUPS  $\geq 75$  YEARS AND  $\geq$  ASA 3

T. Bach, C. Netsch, A. Haecker, M. Michel, T. Herrmann, A. Gross—Germany

**VP14-12** GREENLIGHT HPST<sup>TM</sup> LASER PHOTOSELECTIVE VAPORIZATION

PROSTATECTOMY FOR BPH—2 YEAR FOLLOW UP

E. Heinrich, T. Meyer, G. Wendt-nordahl, T. Bach, M. Michel, A. Haecker—Germany

**VP14-13** HOLEP: TECHNIQUE IS MORE IMPORTANT THAN POWER

R. Reuther, P. Gilling, M. Fraundorfer, D. Bell

**VP14-14** LITHIUM TRIBORATE-LASER VAPORISATION OF THE PROSTATE USING THE 120W HIGH PERFORMANCE SYSTEM (HPS) LASER: HIGH PERFORMANCE ALL THE WAY?

L. Hefermehl, D. Strebelt, O. Gross, T. Sulser, H. Seifert, T. Hermanns

**VP14-15** TRANSURETHRAL BIPOLAR PROSTATE BENIGN HYPERPLASIA RESECTION: LONG-TERM RESULTS. SCIENTIFIC RESEARCH INSTITUTE OF UROLOGY. MOSCOW. RUSSIAN FEDERATION

E. Borisenko, D. Merinov, R. Fatikhov

**VP14-16** COMBINATION OF TRANSURETHRAL RESECTION AND PHOTOSELECTIVE VAPORIZATION FOR THE TREATMENT OF HIGH VOLUME PROSTATE

F. Aksit, A. Kural, H. Akpinar, I. Tufek, F. Atug

**VP14-17** BIPOLAR TURP- DOES IT SCORE OVER MONOPOLAR TURP? DR. ULHAS SATHAYE SAHAYOG SPECIALITY HOSPITAL, JAMNAGAR, INDIA

U. Sathaye

**VP14-18** INCIDENTAL PROSTATE CANCER REVISITED: EARLY OUTCOMES OF PT1A AND PT1B AFTER HOLEP

M. Humphreys, R. Nunez, P. Andrews

**VP14-19** PRELIMINARY OUTCOMES OF SHORT-TERM INDWELLING URETHRAL CATHETER AFTER TRANSURETHRAL RESECTION OF THE PROSTATE

Y. Ozgok, M. Ates, E. Kaya, M. Hoscan, S. Basal, M. Dayanc—Turkey

**VP14-20** GREENLIGHT HPS LASER PHOTOSELECTIVE VAPORIZATION PROSTATECTOMY (PVP) FOR SYMPTOMATIC BENIGN PROSTATIC HYPERPLASIA (BPH): INTERMEDIATE OUTCOMES

K. Strom, M. Spaliviero, C. Wong—USA

**O3: RENAL CELL CARCINOMA AND UPPER TRACT**

12:00–13:00 hr

**O3-01** RENAL CELL CARCINOMA WITH MACROSCOPIC LEVEL I TUMOR THROMBUS EXTENSION IN TO THE RENAL VEIN: OUR 7 CASES EXPERIENCE

O. Castillo, R. Campos, I. Vidal-mora, A. Foneron, G. Rubio, M. Feria—Flores

**O3-02** LESS RADICAL AND PARTIAL NEPHRECTOMY: INITIAL EXPERIENCE

J. Watson, E. Barret, R. Sanchez-salas, F. Rozet, X. Cathelineau, G. Vallancien—France

**O3-03** LAPAROSCOPIC CRYOABLATION OF RENAL MASSES: WHICH LESIONS FAIL?

T. Yoost, N. Hamilton, H. Clarke, T. Keane, S. Savage—United States

**O3-04** HAND-ASSISTED LAPAROSCOPIC LIVING-DONOR NEPHRECTOMY VERSUS OPEN SURGERY: EVALUATION OF SURGICAL TRAUMA AND LATE GRAFT FUNCTION IN 82 PATIENTS

F. Greco, A. Hamza, S. Wagner, M. Hoda, A. Inferrera, P. Fornara

**O3-05** INTRACORPOREAL RETRACTION DURING SINGLE PORT TRANSUMBILICAL LAPAROSCOPIC SURGERY

A. Mikhail, A. Figueroa, L. Bryant, K. Tamaddon, J. Yew, L. Maynes

**O3-06** THE EXPERIENCES IN LAPAROSCOPIC URETEROLITHOTOMY: MULTICENTRIC ANALYSIS OF CASES, BASED ON “TURKUROLAP GROUP”

E. Huri, E. Basok, Ö. Ugurlu, C. Gürbüz, T. Akgül, Y. Ozgok—Turkey

**O3-07** THE TECHNIQUE AND SKILL IMPROVEMENT OF LAPAROSCOPIC LIVE DONOR NEPHRECTOMY VIA RETROPERITONEAL APPROACH (WITH 150 CASES REPORT)

L. Ma, L. Zhao, X. Hou, G. Wang, K. Hong, Y. Liu—China

**O3-08** FAST-TRACK LAPAROSCOPIC NEPHRECTOMY-THE NEED FOR TEAMWORK

L. Lund, M. Jønler, M. Jakobsen, J. Dich—Denmark

**O3-09** THE ANALYSIS OF RISK FACTORS AFFECTING MINI-PERCUTANEOUS NEPHROLITHOTOMY (MPCNL) FOR OLDER THAN 70 YEARS AND THE CORRESPONDING STRATEGY (REPORT OF 34 CASES)

Z. Xiao-feng, L. Da-zhi, L. Yun-feng—China

**O3-10** CHANGING TRENDS IN THE USE OF URETEROSCOPIC INSTRUMENTS FROM 1996 TO 2008

D. Bagley, N. Leone, M. Garcia-roig—USA

**VP15: PCNL-2**

12:00–13:00 hr

**VP15-01** PERCUTANEOUS NEPHROLITHOTOMY IN MALFORMED KIDNEYS: SINGLE-CENTER EXPERIENCE

L. Tahmaz, M. Zor, Y. Ozgok, S. Bedir, S. Basal, M. Dayanc

**VP15-02** MINIPERCUTANEOUS NEPHROLITHOTOMY (MPCNL) AND MINIPERCUTANEOUS NEPHROLITHOLAPAXY (MIP) USING THE PERC’N’CIRCLE ATRAUMATIC BASKET: A RETROSPECTIVE ANALYSIS OVER 2-YEARS EXPERIENCE

U. Anceschi, C. Molinari, C. Anceschi, M. Gallucci

**VP15-03** CURABLE DISEASE IN THE INCURABLE

M. Nuttall, N. Smith, R. Dasgupta, K. Thomas, J. Glass

**VP15-04** COMPARISONS OF PERCUTANEOUS NEPHROLITHOTOMY WITH MINIPERC AND ADULT-TYPE NEPHROSCOPE IN PEDIATRIC KIDNEY STONES

O. Tanriverdi, M. Kendirci, M. Kadihasanoglu, M. Sýlay, M. Aydin, C. Miroglu

**VP15-05** LOW-RISK FOR COLONIC INJURIES DURING SUPINE VERSUS PRONE PERCUTANEOUS NEPHROLITHOTOMY: WHICH IS THE RATIONALE?

L. Ruggera, P. Beltrami, F. Zattoni—Italy

**VP15-06** PERCUTANEOUS NEPHROLITHOTOMY IN HORSESHOE KIDNEYS: THE AEGEAN EXPERIENCE

A. Skolarikos, A. Tefekli, B. Apostolis, M. Binbay, A. Muslumanoglu, D. Charalambas—Turkey

**VP15-07** TUBELESS PERCUTANEOUS NEPHROLITHOTOMY TECHNICAL ASPECTS AND FUNCTIONAL OUTCOME. ABOUT 39 CASES

K. Yousri, N. Yassine, B. Ms, F. Zouhair, H. Mohamed, H. Ali

**VP15-08** FLEXIBLE CYSTOSCOPE ASSISTED PCNL IN TREATING COMPLICATED RENAL CALCULI

G. Wang

**VP15-09** A TECHNIQUE FOR PERCUTANEOUS ACCESS TO NON-DILATED PELVICALICEAL SYSTEM: ARTIFICIAL URETERAL OCCLUSION

B. Seckin, E. Aydur, M. Kilciler, I. Yildirim, H. Irkilata

**VP15-10** DOES TAMSULOSIN CHANGE THE MANAGEMENT OF PROXIMALLY LOCATED URETERAL STONES? A COMPREHENSIVE STUDY

F. Yencilek, S. Erturhan, H. Koyuncu, O. Canguven, C. Goktas, K. Sarýca

**VP15-11** DAYCASE AND 23-HOUR STAY URETEROSCOPIC LASER FRAGMENTATION FOR LARGE RENAL CALCULI

S. Patel, S. Kommu, A. Jain, T. Green, A. Blacker

**VP15-12** RENAL STONES TREATMENT BY PERCUTANEOUS NEPHROLITHOTOMY (PCNL)

M. Baptistussi, M. Morihisa, E. Gewher, A. Martins—Brasil

**VP15-13** THE FACTORS ASSOCIATED WITH FEVER FOLLOWING PERCUTANEOUS NEPHROLITHOTOMY: PRELIMINARY RESULTS OF A PROSPECTIVE CLINICAL STUDY

T. Akman, M. Binbay, R. Aslan, E. Sari, A. Muslumanoglu, A. Tefekli—Turkey

**VP16: BPH-2**

12:00–13:00 hr

**VP16-01** PHOTO-SELECTIVE 532 NANOMETER GREENLIGHTTM LASER VAPORIZATION IS A SAFE AND EFFICACIOUS ENDOSCOPIC TREATMENT OPTION FOR LARGE (GREATER THAN 90 CC) OBSTRUCTING PROSTATES

S. Psutka, M. Siddiqui, S. Tabatabaei

**VP16-02** BIPOLAR ELECTROSURGICAL ENUCLEATION OF THE PROSTATE: TECHNICAL PROGRESS AND EARLY CLINICAL EXPERIENCE OF A NOVEL TECHNIQUE

J. Mandeville, R. Roth, A. Mourtzinis—USA

**VP16-03** HOW TO DEAL WITH BLADDER OUTLET OBSTRUCTION (BOO) AND LOWER URINARY TRACT SYMPTOMS (LUTS) CAUSED BY BENIGN PROSTATIC HYPERPLASIA (BPH) OF RELATIVE SMALL VOLUME?

C. Xiaoming, W. Dongwen

**VP16-04** POST-HOLMIUM LASER ENUCLEATION OF THE PROSTATE (HOLEP): AN MRI ANATOMICAL STUDY

M. Humphreys, R. Nunez, W. Eversman

**VP16-05** THE LATEST TRANSURETHRAL OPERATION, TUEB (TRANSURETHRAL ENUCLEATION WITH BIPOLAR), IN THE TREATMENT OF PROSTATES LARGER THAN 50ML

K. Nakagawa, H. Kono, E. Kikuchi, H. Nagata, A. Miyajima, M. Oya—Japan

**VP16-06** PHOTOSELECTIVE VAPORIZATION OF THE PROSTATE (PVP) USING THE GREENLIGHT LASER VERSUS TRANSURETHRAL PROSTATECTOMY (TURP): A COMPARING COST ANALYSIS

E. Liatsikos, P. Kallidonis, I. Kyriazis, A. Alaown, N. Maniadakis—Greece

**VP16-07** VAPOENUCLEATION OF THE PROSTATE WITH THE 70 WATT AND 120 WATT 2-M CONTINUOUS WAVE THULIUM LASER IN LARGE GLANDS

C. Netsch, K. Oberhagemann, T. Bach, H. Ho, A. Gross—Germany

**VP16-08** LOW POWER (25-40W) TRANSURETHRAL LASER ENUCLEATION OF THE PROSTATE ( TULP ) VERSUS MONOPOLAR TURP: A MATCHED PAIR ANALYSIS

M. Roder, M. Schulze, A. Scolarikos, J. Rassweiler

**VP16-09** ENCRUSTED, FORGOTTEN URETERAL STENTS: REVIEW OF APPROACH, COMPLICATIONS AND MANAGEMENT

A. Colon-herdman, D. Bagley

**VP16-10** URETERORENOSCOPY WITH A DOUBLE CHANNEL URETERORENOSCOPE: FIRST RESULTS

T. Horn, C. Lux, J. Gschwend, M. Straub

**VP16-11** PERCUTANEOUS MANAGEMENT OF UPPER-TRACT TRANSITIONAL CELL CARCINOMA

J. Diaz, I. Pinto, A. Hornig, C. Sandoval—Chile

**VP16-12** COMBINED WATER-JET DISSECTOR AND NEEDLE-KNIFE FOR EN-BLOC-RESECTION OF UROTHELIAL CARCINOMA OF THE BLADDER? AN EX-VIVO STUDY IN PIG BLADDERS

H. Fritsche, F. Eder, R. Ganzer, W. Wieland, S. Denzinger, M. Burger

**VP16-13** STONE DISEASE AND STRESS

R. Miyaoka, O. Ortiz-alvarado, C. Kriedberg, S. Alanee, M. Monga

**MP10: URETERAL STONES**

14:00–15:30 hr

**MP10-01** COMPARISON OF URETEROSCOPY AND EXTRACORPOREAL SHOCK WAVE LITHOTRIPSY IN THE TREATMENT OF DISTAL URETERAL CALCULI IN CHILDREN: A MULTICENTERIC RANDOMIZED CLINICAL TRIAL

A. Basiri, S. Zare, F. Sharifiaghdas, A. Tabibi, A. Aminsharifi, H. Ahmadnia

**MP10-02** MEDICAL EXPULSION THERAPY: A SURVEY OF PRACTICE PATTERNS OF PRIMARY CARE PROVIDERS AND UROLOGISTS

S. Stroup, J. L'esperance, K. Stroup, B. Auge—USA

**MP10-03** RIGID URETEROSCOPY CAN BE USED AS A FIRST LINE TREATMENT FOR THE MANAGEMENT OF DISTAL URETERAL CALCULI IN CHILDREN

C. Kara, B. Resorlu, M. Bayindir, A. Unsal

**MP10-04** SURGICAL MANAGEMENT OF URETERAL STONES DURING PREGNANCY A 10 YEARS EXPERIMENT

M. Mohamad zadeh rezaie—Iran

**MP10-05** OPTIMIZED MANAGEMENT OF URINARY STONE DISEASE IN THE PREGNANT POPULATION

W. White, N. Zite, J. Gash, W. Thompson, F. Klein—USA

**MP10-06** CALCIUM OXALATE NEPHROLITHIASIS: URINARY "MEDIUM SIZE PEPTIDES" ANALYSIS USING MICROBCA PROTEIN ASSAY D'ADESSI A., BONGIOVANNI L., VITTORI M., SACCO E., BASSI PF. DEPARTMENT OF UROLOGY, CATHOLIC UNIVERSITY SCHOOL OF MEDICINE, ROME, ITALY  
A. D'addressi, L. Bongiovanni, M. Vittori, E. Sacco, P. Bassi

**MP10-07** ENDOUROLOGICAL MANAGEMENT OF A SERIES OF SEVERELY ENCRUSTED AND RETAINED URETERAL STENTS D'ADESSI A., FOSCHI N., VITTORI M., RACIOPPI M., BASSI PF. DEPARTMENT OF UROLOGY, CATHOLIC UNIVERSITY SCHOOL OF MEDICINE, ROME, ITALY  
A. D'addressi, N. Foschi, M. Vittori, M. Racioppi, P. Bassi

**MP10-08** OBESITY AND THE TREATMENT OF NEPHROLITHIASIS: A SYSTEMATIC REVIEW OF THE LITERATURE AND META-ANALYSIS  
E. Hyams, L. Dulabon, O. Shah—USA

**MP10-09** TREATMENT OF THE PROXIMAL URETERAL STONES WITH RIGID URETEROSCOPE  
M. Baptistussi, M. Morihisa, E. Gewher, A. Martins—Brasil

**MP10-10** URETERAL STONE LOCATION AT TIME OF EMERGENCY ROOM PRESENTATION IN PATIENTS WITH COLIC  
B. Eisner, A. Reese, S. Sheth, M. Stoller—MA

**MP10-11** STONE COMPOSITION DIFFERENCES IN SYNCHRONOUS BILATERAL RENAL CALCULI  
Kyoko Sakamoto, Thomas Will, Alex Acosta-Miranda, Thomas Turk

**MP10-12** THE NATURAL HISTORY OF STONE FRAGMENTS FOLLOWING URETEROSCOPY  
A. Macejko, V. Bhalani, P. Ramos, D. Rebeck, R. Nadler

**MP10-13** THE ACCORDION DEVICE FOR LIMITING URETERAL RETROGRADE STONE MIGRATION: INITIAL BRAZILIAN EXPERIENCE  
A. Mitre, C. Gromatzky, G. Ebaid, F. Dénes, C. Pagotto, V. Pagotto—Brazil

**MP10-14** THE STONE BREAKER® LITHOTRIPTER FOR STONE FRAGMENTATION: OUR PRELIMINARY RESULTS  
F. Cauda—Italy

**MP10-15** CLINICAL CHARACTERISTICS OF THE IMPACTED DISTAL URETERAL STONE SMALLER THAN 5MM  
J. Lim, E. Hwang, Y. Kim, D. Han, Y. Kim, C. Sul—Korea

**MP10-16** CURRENT MEDICAL TREATMENT OF UROLITHIASIS: CONTEMPORARY THERAPY AND ITS EFFICACY DEPARTMENT OF UROLOGIC SURGERY,

UNIVERSITY OF MINNESOTA, MINNEAPOLIS, MINNESOTA, USA \*DIETARY SERVICES, UMMC FAIRVIEW  
O. Ortiz-alvarado, M. Stessman\*, C. Kriedberg, R. Miyaoka, M. Monga, A. Moeding\*

**MP10-17** STONE VOLUME—A PREDICTOR OF SPONTANEOUS URETERAL STONE PASSAGE  
I. Sternberg, I. Kafka, I. Vardi, I. Leibovitch

**MP10-18** USE OF MEDICAL EXPULSIVE THERAPY (MET) IN ACUTE UROLITHIASIS IN A SINGLE EMERGENCY ROOM SETTING  
D. Kaplon, K. Babaian, S. Nakada—wi USA

**MP10-19** STATINS AND THE RISK OF UROSEPSIS AFTER ENDOUROLOGICAL PROCEDURES  
J. Eswara, B. Chapin, D. Sacco

**MP10-20** TREATMENT OF PROXIMAL URETERAL STONES SUCCESS RATES AND FINANCIAL COST OF TREATMENT WITH ESWL INSITU OR AFTER PUSH BACK THE STONE  
R. Mahdavi zafarghandi, M. Mahdavi zafarghandi—Iran

## **MP11: ROBOTIC PROSTATE 1**

14:00–15:30 hr

**MP11-01** RAPID IMPLEMENTATION OF A ROBOTIC PROSTATECTOMY PROGRAM IN A LARGE HMO SETTING  
H. Jung—USA

**MP11-02** THE INCIDENCE OF LYMPHOCELES AFTER ROBOTIC-ASSISTED PELVIC LYMPH NODE DISSECTION  
M. Patel, K. J palmer, S. Chauhan, R. Ferreira coelho, B. Rocco, V. Patel—US

**MP11-03** POSITIVE SURGICAL MARGINS AND THEIR LOCATIONS FOLLOWING ROBOT ASSISTED LAPAROSCOPIC PROSTATECTOMY: A MULTI-INSTITUTIONAL STUDY  
S. Chauhan, G. Coughlin, M. Patel, R. Coelho, K. Palmer, V. Patel

**MP11-04** CORRELATION OF BLADDER NECK LOCATION ON CYSTOGRAM PREDICTS EARLY RETURN OF CONTINENCE FOLLOWING ROBOTIC RADICAL PROSTATECTOMY  
U. Boylu, M. Pinsky, B. Richardson, R. Thomas, B. Lee—USA

**MP11-05** CONTINENCE AND POTENCY IN ELDERLY FOLLOWING ROBOTIC RADICAL PROSTATECTOMY  
S. Shikanov, V. Desai, A. Razmaria, D. Lifshitz, G. Zagaja, A. Shalhav—USA

**MP11-06** PERI-OPERATIVE PREDICTORS OF BEING PAD-FREE AT 12 MONTHS FOLLOWING ROBOTIC-ASSISTED LAPAROSCOPIC PROSTATECTOMY  
T. Deklaj, A. Razmaria, S. Shikanov, D. Lifshitz, A. Shalhav, G. Zagaja—USA

**MP11-07** ARE PATIENTS' EXPECTATIONS MET AFTER ROBOTIC ASSISTED RADICAL PROSTATECTOMY?

A. Razmaria, S. Shikanov, D. Lifshitz, K. Zorn, G. Zagaja, A. Shalhav—USA

**MP11-08** MEDIAN LOBE IN ROBOTIC PROSTATECTOMY: BLADDER NECK RECONSTRUCTION AND PELVIC DRAIN NOT ROUTINELY REQUIRED

H. Martinez-suarez, A. White, R. Abaza—USA

**MP11-09** IMPROVED OUTCOMES FOLLOWING ROBOT-ASSISTED RADICAL PROSTATECTOMY: TECHNIQUE AND/OR EXPERIENCE?

J. Davis—USA

**MP11-10** POSTERIOR RECONSTRUCTION OF RECTOURETHRALIS MUSCLE PRIOR TO URETHROVESICAL ANASTOMOSIS IMPROVES EARLY RETURN OF CONTINENCE IN PATIENTS UNDERGOING ROBOTIC ASSISTED RADICAL PROSTATECTOMY

U. Boylu, M. Pinsky, B. Richardson, R. Thomas, B. Lee—USA

**MP11-11** PREDICTORS OF POSITIVE SURGICAL MARGIN IN ROBOTIC ASSISTED RADICAL PROSTATECTOMY

U. Boylu, M. Pinsky, B. Lee, R. Thomas—USA

**MP11-12** TECHNIQUES FOR EARLY RECOVERY OF CONTINENCE IN PATIENTS WITH ROBOTIC-ASSISTED PROSTATECTOMY

G. Sung, T. Kim—Korea

**MP11-13** A COMPARISON OF ROBOTIC ASSISTED VERSUS PURE LAPAROSCOPIC RADICAL PROSTATECTOMY: A SINGLE SURGEON EXPERIENCE

K. Tae hyo, G. Sung, W. Cho, W. Lee—Korea

**MP11-14** ASSESSMENT OF LYMPH NODE YIELD IN ROBOTIC ASSISTED PROSTATECTOMY AND OPEN RADICAL PROSTATECTOMY IN THE CONTEMPORARY ERA

M. Truesdale, P. Cheetham, D. Lee, K. Badani—USA

**MP11-15** LYMPH NODE YIELDS WITH PELVIC LYMPHADENECTOMY DURING ROBOTIC-ASSISTED LAPAROSCOPIC RADICAL PROSTATECTOMY ARE HIGHER THAN WITH OPEN RADICAL RETROPUBIC PROSTATECTOMY

E. Trabulsi, T. Chandrasekar, F. Lee, P. Mccue, C. Lallas, A. Colon—USA

**MP11-16** ROBOTIC-ASSISTED LAPAROSCOPIC PROSTATECTOMY: FUNCTIONAL AND ONCOLOGIC OUTCOMES WITH A MINIMUM 12 MONTH FOLLOW-UP

H. Lavery, F. Nabizada-pace, J. Carlucci, D. Samadi—USA

**MP11-17** ROBOT ASSISTED PROSTATECTOMY: A SINGLE CENTRE EXPERIENCE OF 1000 CASES

D. Porres, A. Schuette, C. Wagner, V. Zugor, J. Witt

**MP11-18** REDUCTION OF PT3 POSITIVE SURGICAL MARGINS IN ROBOT-ASSISTED LAPAROSCOPIC RADICAL PROSTATECTOMY: DOES THE APPLICATION OF PARTIN NOMOGRAM OFFER A MEANINGFUL RESULT?

J. Jeong, E. Choi, D. Kang, I. Kim—USA

**MP11-19** ROBOTIC-ASSISTED LAPAROSCOPIC RADICAL PROSTATECTOMY OPERATIVE DETAILS UND FUNCTIONAL OUTCOME

J. Wöllner, A. Neisius, G. Wöllner, R. Gillitzer, J. Thüroff, C. Hampel—Germany

**MP11-20** OUTCOMES OF ROBOTIC ASSISTED LAPAROSCOPIC PROSTATECTOMY IN PATHOLOGICAL ADVANCED LOCALIZED (PT3) PROSTATE CANCER IN 1700 PATIENTS

Y. El douaihy

**MP12: LAPAROSCOPIC SURGERY**

14:00–15:30 hr

**MP12-01** LAPAROSCOPIC RADICAL PROSTATECTOMY (9 CASES)

L. Chaozhao, H. Zongyao, Z. Jun, Z. Xiansheng, F. Song—China

**MP12-02** INCREASED POSITIVE SURGICAL MARGIN RATE OF LAPAROSCOPIC RADICAL PROSTATECTOMIES PERFORMED IN JULY AND AUGUST

J. Page, R. Unnikrishnan, S. Strup

**MP12-03** EFFECTS OF ELEVATED BMI ON PERIOPERATIVE CLINICAL AND PATHOLOGICAL OUTCOMES FOLLOWING LAPAROSCOPIC RADICAL PROSTATECTOMY

J. Page, D. Davenport, M. Paszek, C. Lagrange, B. Dusseault, S. Strup—USA

**MP12-04** EXTENDED PELVIC LYMPHADENECTOMY DURING RADICAL PROSTATECTOMY-- IS IT WORTHWHILE?

A. Arora, C. Eden

**MP12-05** FINAL OUTCOME OF PATIENTS WITH PROSTATE CANCER SUITABLE FOR ACTIVE SURVEILLANCE BUT TREATED SURGICALLY

A. Arora, C. Eden

**MP12-06** IS LAPAROSCOPIC RENAL DENERVATION THE TREATMENT OF CHOICE FOR 'LOIN PAIN-HAEMATURIA SYNDROME (LPHS)': EXPERIENCE FROM SCOTLAND

D. Clark, B. Somani, N. Kadi, N. Townell

**MP12-07** VALVE-LESS TROCAR REDUCES CARBON DIOXIDE ABSORPTION DURING LAPAROSCOPY COMPARED TO CONVENTIONAL TROCARS

A. Herati, S. Andonian, S. Rais-bahrami, A. K. srinivasan, L. Richstone, L. R. kavoussi—United States

**MP12-08** OPTIMUM TEMPERATURE FOR COLD ISCHEMIA: PRELIMINARY RESULTS ON A PORCINE MODEL

G. Schoeppler, E. Klippstein, A. Häcker, L. Trojan, P. Alken, M. Michel

**MP12-09** THE MOST EFFECTIVE COOLING METHOD FOR INDUCING HYPOTHERMIA: COMPARISON OF 4 DIFFERENT TECHNIQUES INCLUDING A NOVEL GEL-LIKE MATERIAL

G. Schoeppler, J. Hell, A. Häcker, L. Trojan, P. Alken, M. Michel

**MP12-10** A COMPARATIVE ASSESSMENT OF LAPAROSCOPIC AND MICROSURGERY OPERATIONS IN PATIENTS WITH BILATERAL VARICOCELE

Z. Kadirov, N. Savitsky, V. Musienko

**MP12-11** SUBCUTANEOUS EMPHYSEMA AFTER LAPAROSCOPIC EXTRAPERITONEAL INGUINAL HERNIA REPAIR

S. Soleymani

**MP12-12** COMPARATIVE ASSESSMENT OF LAPAROSCOPIC SINGLE SITE SURGERY INSTRUMENTS TO CONVENTIONAL LAPAROSCOPIC IN LABORATORY SETTING

J. Stolzenburg, P. Kallidonis, M. Do, A. Dietel, T. Haefner, E. Liatsikos

**MP12-13** TRAINING IN URO-LAPAROSCOPY: LIGHTS AND SHADOWS

R. Autorino, R. Stein, M. De sio, R. Damiano, E. Lima, J. Kaouk—USA

**MP12-14** USE OF FOOT GEL PADS IMPROVES OPERATING ROOM STAFF COMFORT DURING LAPAROSCOPIC RENAL SURGERY

J. Rosales araujo, J. Moreno, D. Lee, Z. Okhunov, K. Badani, J. Landman—USA

**MP12-15** ASSESSMENT OF RENAL DAMAGE FOLLOWING WARM ISCHEMIA TIME DURING LPN: RESULTS OF A PROSPECTIVE STUDY

F. Porpiglia, C. Fiori, R. Bertolo, B. Cavallone, D. Vaccino, R. Scarpa

**MP12-16** TRANSPERITONEAL LAPAROSCOPIC DECORTICATION OF SIMPLE RENAL CYST USING CONVENTIONAL MONOPOLAR DEVICE: TWO YEARS OF OUR EXPERIENCE WITH 15 PATIENTS

A. Tuncel, O. Aydin, Y. Aslan, V. Nalcacioglu, M. Balci, A. Atan—Turkey

**MP12-17** URO-ONCOLOGIC SURGERY IN JEHOVAH'S WITNESS PATIENTS

L. Jones, L. Deane

**MP12-18** LAPAROSCOPIC RADICAL NEPHRECTOMY – A DECADE SPECIFIC COMPARATIVE OUTCOMES ANALYSIS

S. Kommu, Z. Hashim, D. Cartlidge, T. Finnigan, C. Luscombe, A. Golash—United Kingdom

**MP12-19** PAIN ASSESSMENT AFTER RADICAL RETROPUBIC VS EXTRAPERITONEAL LAPAROSCOPIC RADICAL PROSTATECTOMY-A PROSPECTIVE TRIAL

T. Vögeli, I. Akbarov, M. Lehnhardt

**MP12-20** THE INFLUENCE OF POSITIVE APICAL MARGINS ON BIOCHEMICAL RECURRENCE FOLLOWING LAPAROSCOPIC RADICAL PROSTATECTOMY: COMPARISON WITH NON-APICAL POSITIVE MARGINS

S. Hong, U. Ha, S. Kang, T. Hwang—Korea

**MP9: PCNL 2**

14:00–15:30 hr

**MP9-01** BILATERAL SINGLE PROCEDURE PERCUTANEOUS NEPHROLITHOTOMY

R. Multescu, V. Cauni, V. Mirciulescu, E. Alexandrescu, B. Geavlete, P. Geavlete—Romania

**MP9-02** COMPARISON OF PCNL WITH OPEN SURGERY IN PATIENTS WITH RENAL STAGHORN STONES

S. Falahatkar, Z. Panahandeh, Sourati, M. Akbarpour, N. Khaki

**MP9-03** PNL: IS IT THE FIRST CHOICE FOR MANAGEMENT OF STAGHORN STONES. PREDICTIVE VALUES OF SUCCESS

M. Badreldin, T. Abdelbaky, K. Salah, A. Gamal—Egypt

**MP9-04** EVALUATION OF THE LEARNING CURVE FOR PERCUTANEOUS NEPHROLITHOTOMY

S. Ziaee, M. Mohammadi sichani, A. Kashi

**MP9-05** PCNL IN PATIENTS WITH PREVIOUS HISTORY OF RENAL SURGERY

M. Rahmani, M. Darabi mahboub

**MP9-06** PERCUTANEOUS NEPHROLITHOTOMY IS A SAFE AND EFFECTIVE PROCEDURE EVEN IN PATIENTS WITH NON-OPAQUE RENAL STONES

C. Kara, B. Resorlu, U. Oguz, A. Unsal—Turkey

**MP9-07** PERCUTANEOUS NEPHROLITHOTOMY FOR TREATMENT OF ENCRUSTED URETERAL STENTS: A MULTICENTER STUDY

B. Eisner, M. Kurtz, B. Matlaga, O. Shah, E. Hyams, V. Pais Jr, J. Page, R. Venkatesh, O. Arsovska, R. Patterson, B. Chew

**MP9-08** POST-PCNL FEVER: PROSPECTIVE ANALYSIS OF PRE-OPERATIVE URINE, RENAL PELVIC URINE, AND STONE CULTURES  
R. Korets, R. Walsh, M. Gupta—USA

**MP9-09** THE IMPACT OF PERCUTANEOUS NEPHROLITHOTOMY IN SOLITARY FUNCTIONING KIDNEY WITH CHRONIC KIDNEY DISEASE (CKD)  
A. Kurien, R. Baishya, S. Mishra, A. Ganpule, R. Sabnis, M. Desai

**MP9-10** PERCUTANEOUS NEPHROLITHOTOMY IN PATIENTS WITH PREVIOUS OPEN NEPHROLITHOTOMY: BALLOON DILATATION VERSUS AMPLATZ DILATATION FOR NEPHROSTOMY TRACT DILATATION  
S. Bedir, L. Tahmaz, M. Zor, H. Topac, M. Dayanc

**MP9-11** METANALYSIS OF COMPLICATIONS OF PERCUATNEOUS NEPHROLITHOTOMY  
G. Pareek, S. Patel, G. Haleblian

**MP9-12** PERCUTANEOUS NEPHROLITHOTOMY FOR URINARY MATRIX CALCULI  
L. Tahmaz, M. Zor, S. Basal, I. Karabuga, H. Topac, M. Dayanc

**MP9-13** PERCUTANEOUS NEPHROLITHOTOMY WITH THE PATIENT IN SUPINE-SLOPE POSITION TO TREAT THE UPPER URINARY TACT UROLITHIASIS(52 CASES)  
H. Zongyao, L. Chaozhao, Z. Xiansheng, Z. Jun, F. Song

**MP9-14** PERCUTANEOUS NEPHROLITHOTOMY IN SOLITARY KIDNEY STONE DISEASE  
I. Aridogan, Y. Bayazit, V. Izol, D. Abat, Z. Tansug, S. Zeren—Turkey

**MP9-15** PERCUTANEOUS MANAGEMENT OF STAGHORN CALCULI IN HORSESHOE KIDNEYS. A MULTI -INSTITUTIONAL EXPERIENCE  
P. Kallidonis, E. Liatsikos, A. Al aown, J. Stolzenburg, O. Traxer, A. Smith

**MP9-16** THE PREDICTIVE FACTORS FOR THE SUCCESS AND COMPLICATION RATES IN PERCUTANEOUS NEPHROLITHOTOMY: EVALUATION OF 409 PROCEDURES AT A SINGLE CENTER  
O. Tanriverdi, M. Kendirci, M. Kadihasanoglu, M. Sýlay, M. Taskiran, C. Miroglu

**MP9-17** TWELVE YEARS OF EXPERIENCE IN PERCUTANEOUS NEPHROLITHOTOMY FROM A SINGLE CENTER  
I. Aridogan, Y. Bayazit, N. Satar, S. Doran, Z. Tansug, S. Zeren—Turkey

**MP9-18** PERCUTANEOUS NEPHROLITHOTRIPSY (PCNL) FOR PATIENTS WITH PREVIOUS OPEN RENAL SURGERY: IS THERE ANY PROGNOSTIC FACTOR?  
S. Ben rhouma, S. Sallami, M. Basli, N. Yassine, A. Horchani

**MP9-19** THE ADVANTAGES OF THE PERCUTANEOUS NEPHROLITHOTOMY IN SUPINE POSITION (THE VALDIVIA TECHNIQUE). PERSONAL EXPERIENCE  
V. Bucuras, R. Bardan, A. Muresan, C. Balarie, C. Comsa, M. Georgiadis

**MP9-20** OUTPATIENT PERCUTANEOUS NEPHROLITHOTOMY: IS IT SAFE AND FEASIBLE  
M. Baptistussi, M. Morihisa, E. Gewher, A. Martins—Brasil

#### **04: LOWER URINARY TRACT**

14:00–15:30 hr

**04-01** ENDOSCOPIC TREATMENT OF VESICoureTRAL REFLUX BY COLLAGEN IN CHILDREN (15 YEARS EXPERIENCE)  
I. Babanin, I. Kazanskaya, Z. Sabirzianova—Russia

**04-02** THE FEASIBILITY OF HIGH RESOLUTION OPTICAL COHERENCE TOMOGRAPHY TO DETECT UROCYSTITIS CYSTICA IN HUMAN BLADDER  
J. Bornemann, G. Joachim, F. Spöler, A. Naami, R. Knüchel-clark, G. Jakse—Germany

**04-03** MAXIMISING THE POTENTIAL OF PHOTODYNAMIC DIAGNOSIS (PDD) IN THE MANAGEMENT OF BLADDER CANCER  
K. Thomas, D. Wilby, T. O'brien—UK

**04-04** VIRTUAL URETROSCOPY: NORMAL ANATOMY, VARIANTS & CLINICAL IMPACT  
E. Ehab rifat tawfik, A. Moustafa

**04-05** THULIUM LASER ENUCLEATION OF THE PROSTATE 5 YEAR RESULTS  
G. Watson, P. Verma—UK

**04-06** THULIUM: YAG VAPOENUCLEATION IN PATIENTS WITH LARGE PROSTATES (>100 G)  
K. Harrer, C. Netsch, A. Gross, A. Häcker, M. Michel, T. Bach

**04-07** ENUCLEATION OF THE PROSTATE WITH THE 2-M CONTINUOUS WAVE THULIUM LASER IN DIFFERENT EXPERIENCED SURGEONS  
C. Netsch, K. Oberhagemann, A. Gross—Germany

**04-08** SALVAGE CRYOABLATION OF PROSTATE CANCER USING 17 G CRYONEEDLE TECHNOLOGY 7 YEAR GERMAN EXPERIENCE  
U. Witzsch, G. Voss, E. Becht

**04-09** CRYOABLATION OF PRIMARY LOCALIZED PROSTATE CANCER USING 17 GAUGE CRYONEEDLES TECHNOLOGY 7 YEAR EUROPEAN EXPERIENCE  
U. Witzsch, E. Becht, G. Voss

**04-10** THE HOLMIUM LASER IN OPERATIVE TREATMENT OF PEYRONIE'S DISEASE  
A. Assubayev, A. Bayzhanov, B. Shalekenov, E. Kuandykov, T. Anafin, S. Shalekenov

**VP17: LAPAROSCOPY-KIDNEY 3**

14:00–15:30 hr

**VP17-01** A NOVEL BRIDGING TECHNIQUE TO FACILITATE DEVELOPMENT OF LAPAROENDOSCOPIC SINGLE SITE SURGICAL SKILLS  
D. Baldwin, K. Ebrahimi, P. Mahdavi, R. Bowman, F. Jellison, L. Nicolay

**VP17-02** WIDENING THE PLANE OF DISSECTION IN LAPAROSCOPIC SIMPLE NEPHRECTOMY FOR SYMPTOMATIC NON-FUNCTIONING KIDNEYS KEEPING IN MIND THE HIDDEN UPPER TRACK UROTHELIAL MALIGNANCY  
A. Kurien, A. Mathew, S. Mishra, A. Ganpule, R. Sabnis, M. Desai

**VP17-03** NOTES AND LESS LAPAROSCOPIC SIMPLE NEPHRECTOMY WITH THE USE OF STANDARD LAPAROSCOPIC INSTRUMENTS. INITIAL EXPERIENCE IN 4 CASES  
I. Vidal-mora, O. Castillo, A. Foneron, R. Campos, G. Rubio, M. FERIA-FLORES

**VP17-04** 800 LAPAROSCOPIC PARTIAL NEPHRECTOMIES: A SINGLE-SURGEON SERIES  
I. Gill, K. Kamoi, M. Aron, R. Brandina, A. Berger, M. Desai

**VP17-05** APPLICATION OF SUTURELESS LAPAROSCOPIC PARTIAL NEPHRECTOMY TECHNIQUE BASED ON PREOPERATIVE AND INTRAOPERATIVE PARAMETERS  
S. Stroup, J. L'esperance, B. Auge, C. Choe, A. L'esperance, I. Derweesh—USA

**VP17-06** RETROPERITONOSCOPIC NEPHRECTOMY IN NON-FUNCTIONED ATROPHIC KIDNEY: PRELIMINARY RESULTS OF 10 CASES  
E. Huri, T. Akgül, T. Karakan, C. Germiyanoglu—Turkey

**VP17-07** HEM-O-LOK CLIPS: A RELIABLE AND COST-EFFECTIVE METHOD OF VASCULAR CONTROL DURING LAPAROSCOPIC NEPHRECTOMY  
R. Kapoor, R. Maheshwari, S. R, A. Srivastava, M. Ansari, A. Mandhani—India

**VP17-08** BILATERAL SYNCHRONOUS RENAL MASSES: 21 YEAR EXPERIENCE IN 260 PATIENTS  
R. Brandina, M. Simmons, A. Berger, M. Desai, M. Aron, I. Gill

**VP17-09** IMPLEMENTATION EVOLUTION OF TRANSPERITONEAL LAPAROSCOPIC PARTIAL NEPHRECTOMY IN SUTURE/BOLSTER TECHNIQUE. INITIAL RESULTS  
T. Herrmann, M. Burchardt, S. Kruck, M. Kuczyk, U. Nagele—Germany

**VP17-10** LAPAROSCOPIC PARTIAL NEPHRECTOMY: A NEW ERA?  
F. Porpiglia, C. Fiori, R. Bertolo, I. Morra, R. Scarpa

**VP17-11** LAPAROSCOPIC RADICAL NEPHRECTOMY FOR RENAL CELL CARCINOMA: ONCOLOGIC OUTCOMES AT 10 YEARS OR MORE  
A. Berger, R. Brandina, M. Aron, M. Desai, L. Kavoussi, I. Gill

**VP17-12** LAPAROSCOPIC NEPHROURETERECTOMY FOR UPPER TRACT TRANSITIONAL CELL CARCINOMA: RESULTS OF A SINGLE CENTER EXPERIENCE  
O. Castillo, A. Foneron, I. Vidal-mora, R. Campos, G. Rubio, G. Rubio—Chile

**VP17-13** INFLUENCE OF OBESITY UPON LAPAROSCOPIC RADICAL NEPHRECTOMY  
H. Dong youp, K. Ill sang, S. Ill young, J. Hee jong

**VP17-14** OFF-CLAMP LAPAROSCOPIC PARTIAL NEPHRECTOMY: THE ULTIMATE STRATEGY FOR RENAL PROTECTION  
A. Herati, A. K. Srinivasan, A. K. George, S. S. Saluja, L. Richstone, L. R. Kavoussi—United States

**VP17-15** CONTEMPORARY OUTCOMES OF OPEN VERSUS LAPAROSCOPIC PARTIAL NEPHRECTOMY: IMPACT OF THE 'EARLY UNCLAMPING' TECHNIQUE  
K. Kamoi, M. Aron, M. Desai, R. Brandina, A. Berger, I. Gill

**VP17-16** RETROPERITONEAL LAPAROSCOPIC PARTIAL NEPHRECTOMY: THE LEARNING CURVE OF SINGLE SURGEON  
O. Kyung-jin, K. Young-jung, N. Deok-hyun, P. Kwangsung, R. Soo-bang, K. Dong-deuk—Korea

**VP17-17** COOLING AND MAINTENANCE OF LOW TEMPERATURE IN RETROPERITONEOSCOPIC PARTIAL NEPHRECTOMY USING ICE STICKS  
N. Ioritani, M. Aizawa, S. Matsuura, A. Takeuchi, T. Kudo

**VP17-18** LAPAROSCOPIC PARTIAL NEPHRECTOMY: IMPACT OF RESECTED VOLUME ON RENAL FUNCTION OUTCOME  
F. Bagheri, C. Pusztai, J. Székely, Z. Szabó, I. Buzogány, L. Farkas

**VP17-19** LAPAROSCOPIC NEPHRECTOMY FOR XANTHOGRANULOMATOUS PYELONEPHRITIS  
M. Lopes de lima, J. Moro, R. Berti, N. Rodrigues netto Jr., P. César rodrigues palma

**VP17-20** CONTEMPORARY OUTCOMES OF OPEN VERSUS LAPAROSCOPIC NEPHROURETERECTOMY: CASE-MATCHING ANALYSIS  
J. Soh, A. Kawauchi, K. Kamoi, N. Hirahara, Y. Naitoh, T. Miki—Japan



**VP18: ESWL**

14:00–15:30 hr

**VP18-01** HISTOTRIPTY EROSION OF URINARY STONES

W. Roberts, A. Duryea, A. Maxwell, J. Wheat, Z. Xu, C. Cain—USA

**VP18-02** COMPARISON OF THE ANALGESIC EFFECTS OF DEXKETOPROFEN AND DICLOFENAC DURING SHOCKWAVE LITHOTRIPTY: A RANDOMIZED, DOUBLE-BLIND CLINICAL TRIAL

H. Tokgoz, S. Yurtlu, V. Hanci, O. Turksoy, B. Erol, B. Akduman

**VP18-03** THE EVALUATION OF THE EFFICACY OF EXTRACORPORAL LITHOTRIPTY IN PATIENTS REFERRED TO LITHOTRIPTY CENTERS IN MASHHAD

R. Taghavi, M. Darabi mahboub, R. Mahdavi zafarghandi, K. Tavakkoli tabassi—Iran

**VP18-04** PANCREATIC SWL: DOES IT PROVIDE SUBJECTIVE RELIEF OF SYMPTOMS AND PREVENT MAJOR SURGERY?

N. Hamilton, M. Mcintyre, S. Savage, C. Lawrence, T. Keane

**VP18-05** THE USE OF ETHYL CHLORIDE FOR PAIN CONTROL DURING EXTRACORPOREAL SHOCK WAVE LITHOTRIPTY

J. Heretis, V. Adamopoulos, U. Vergetaki, T. Karagounis, M. Venieri, F. Sofras—Greece

**VP18-06** EXTRACORPOREAL SHOCK WAVE LITHOTRIPTY IN PEDIATRIC PATIENTS: OUR EXPERIENCE USING THE EMSE 220 F-XP LITHOTRIPTY

J. Heretis, D. Glaritis, G. Daskalopoulos, K. Makatounaki, M. Metaxari, F. Sofras—Greece

**VP18-07** INITIAL EXPERIENCE WITH A NEW DUAL-SHOCKWAVE LITHOTRIPTY IN THE MANAGEMENT OF UPPER URINARY TRACT CALCULI

J. Abbaraju, A. Sahai, F. Anjum, S. Madaan, H. Marsh, S. Sriprasad—United Kingdom

**VP18-08** URETERAL STENT DURING EXTRACORPOREAL SHOCK WAVE LITHOTRIPTY: WHICH ROLE?

M. Sighinolfi, S. Micali, A. Beato, S. De stefani, G. Pini, G. Bianchi

**VP18-09** CLEARANCE OF LOWER POLE KIDNEY STONES USING FOCUSED ULTRASOUND TECHNOLOGY

A. Shah, B. Cunitz, W. Lu, M. Sorensen, L. Crum, M. Bailey

**VP18-10** HOLMIUM LASERLITHOTRIPTY FOR URETERIC CALCULI: PREDICTIVE FACTORS FOR COMPLICATIONS

M. Baptistussi, M. Morihisa, E. Gewher, A. Martins—Brasil

**VP18-11** THE ADVANTAGES OF NEW TURKISH MADE COMBINED LITHOTRIPTY, WITH INTEGRATED, ADJUSTABLE ASPIRATOR FOR PERCUTANEOUS LITHOTRIPTY

R. Saglam, Z. Tokatli, M. Safak, A. Kabakci—Turkey

**VP18-12** STONE CONE VERSUS NITINOL TIPLESS DORMIA BASKET TO AVOID PROXIMAL STONE MIGRATION

E. Ehab rifat tawfik

**VP18-13** RENAL FUNCTION RECOVERY FOLLOWING PERCUTANEOUS NEPHROSTOMY

S. Mohan, R. Jordan, H. Mohd tarmidzi, K. Subramonian—UK

**VP18-14** TELESCOPIC VERSES ONE -SHOT DILATION TECHNIQUE FOR TRACT CREATION IN PERCUTANEOUS NEPHROLITHOTOMY

A. Jitendra, R. Dipak

**VP18-15** HIGH POWER HOLMIUM LASER IN PERCUTANEOUS NEPHROLITHOTOMY FOR IMPACTED PROXIMAL URETERAL STONES

T. Zhou, X. Gao, Y. Sun—China

**VP18-16** TREATMENT OF LARGE UPPER URETER STONE : ANALYSIS OF 97 PATIENTS IN SINGLE HOSPITAL

S. Yoon, K. Lee, T. Kim, K. Kim, H. Jung—South Korea

**VP18-17** FLEXIBLE URETEROSCOPY FOR A LARGER AND MORE COMPLEX STONE BURDEN: AN ANALYSIS OF THE COST OF EQUIPMENT MAINTAINENCE

P. Lowry, T. Ruddell, K. Sam—Texas

**VP18-18** STEINSTRASSE AFTER ESWL: THERAPEUTIC RECOMMENDATIONS ABOUT 157 CASES

S. Sallami, S. Ben rhouma, D. Nizar, M. Weld sidi mohamed, Y. Noura, A. Horchani

**VP18-19** THE DEVELOPMENT OF STEINSTRASSE AFTER EXTRACORPOREAL SHOCKWAVE LITHOTRIPTY (ESWL): IS IT A PREDICTABLE COMPLICATION?

B. Sami, S. Sallami, B. Mohamed, Y. Noura, A. Horchani, B. Nawfel

**VP18-20** THE RELEVANCE OF COUPLING GEL VISCOSITY FOR EFFICIENT ENERGY COUPLING IN SWL

T. Bergsdorf, C. Chaussy, S. Thueroff—Germany

**VS10: LAPAROSCOPY BLADDER**

14:00–15:30 hr

**VS10-01** RETAINED PROSTATE CAPSULE AND EJACULATORY FUNCTION TOTAL BLADDER RESECTION OF LAPAROSCOPIC, ILEAL NEOBLADDER SURGERY

C. Lin—China

**VS10-02** LAPAROSCOPIC RESECTION OF BLADDER DIVERTICULUM IN FEMALE WITH PREPERITONEAL APPROACH

R. Sanseverino, U. Di mauro, G. Napodano, O. Intilla, T. Realfonso—Italy

**VS10-03** SINGLE PORT LAPAROSCOPIC AUGMENTATION ENTEROCYSTOPLASTY

R. Sotelo, B. Cuomo, O. Carmona, R. De andrade, D. Canes, I. Gill—Venezuela

**VS10-04** ISOBARIC LAPAROSCOPIC RADICAL CYSTOPROSTATECTOMY WITH THE LAPARO-TENSER SYSTEM

A. Granata, A. Gregori, F. Scieri, A. Salvaggio, A. Romanò, F. Gaboardi

**VS10-05** LAPAROSCOPIC RADICAL CYSTECTOMY WITH EXTRACORPOREAL URINARY DIVERSION:

S. Shah—India

**VS10-06** EXTENDED LYMPHADENECTOMY IN BLADDER CANCER IN A WOMAN

A. Celia, G. Zeccolini, G. Bredasan bassiano hospital—Italy

**VS10-07** LAPAROSCOPIC RADICAL CYSTECTOMY: ULUDAG UNIVERSITY EXPERIENCE

I. Yavascaoglu, K. Gokcen, H. Dogan, Y. Kordan, H. Vuruskan, B. Oktay—Turkey

**VS10-08** VIDEO TECHNIQUE OF THE NOTES APPROACH TO MANAGEMENT OF INADVERTENT SPLENIC, ENTERAL AND BLADDER INJURIES

S. Parekattil, J. Sijo, C. Fyock, H. Atalah, L. Su, C. Forsmark, M. Wagh—USA

**VS10-09** LAPAROSCOPIC RADICAL CYSTECTOMY WITH EXTRACORPOREAL ILEAL CONDUIT FOR MUSCLE INVASIVE BLADDER CANCER IN KASHMIR

M. Khan—India

**VS10-10** LESS TRANSVESICAL BLADDER CUFF EXCISION

R. Sotelo, D. Ramirez, O. Carmona, Z. Pascal, B. Irwin, I. Gill—Venezuela

**VS8: LAPAROSCOPY—PROSTATE**

14:00–15:30 hr

**VS8-01** LAPAROSCOPIC RADICAL PROSTATECTOMY USING LOW ENERGY SOURCE GIVING EARLY CONTINENCE AND BETTER POTENCY: INTIAL EXPERIENCE OF 52 CASES

S. Shah

**VS8-02** LAPAROSCOPIC RADICAL PROSTATECTOMY (LRP) PERFORMED BY MINIMUM EFFECTIVE TREATMENT (MET)

G. Franco, S. Antonio, R. Ai ling, G. Antonio maria, G. Andrea—Italy

**VS8-03** HAEMOSTASIS DURING NERVE-SPARING ENDOSCOPIC EXTRAPERITONEAL RADICAL PROSTATECTOMY (EERPE)

J. Stolzenburg, M. Do, P. Kallidonis, G. Hellawell, T. Haefner, E. Liatsikos

**VS8-04** NATURAL ORIFICE TRANSLUMENAL ENDOSCOPIC SURGICAL RADICAL PROSTATECTOMY (NOTES- RP) IN THE CANINE MODEL

A. Krambeck, M. Humphreys, P. Andrews, J. Lingeman—USA

**VS8-05** NERVE-SPARING LAPAROENDOSCOPIC SINGLE SITE (LESS) RADICAL PROSTATECTOMY

M. Atalla, S. Andonian, L. Kavoussi, L. Richstone

**VS8-06** SEEING THE LIGHT—ENDOSCOPIC-ASSISTED LAPAROSCOPIC RADICAL PROSTATECTOMY— A NOVEL TECHNIQUE TO AID IN BLADDER NECK AND APICAL DISSECTION?

M. Preston, J. Wiesenthal, A. Abuhajar, D. Hickling, J. Watterson, B. Blew—Canada

**VS8-07** RANDOMIZED STUDY AND SURGICAL TECHNIQUE ON ISOBARIC LAPAROSCOPIC RADICAL PROSTATECTOMY WITH THE “LAPARO-TENSER” SYSTEM

A. Granata, F. Scieri, A. Salvaggio, G. Incarbone, F. Pietrantuono, F. Gaboardi—Italy

**VS8-08** BLADDER NECK CONTRACTURES RELATED TO THE USE OF HEM-O-LOK CLIPS IN LAPAROSCOPIC RADICAL PROSTATECTOMY

C. Gurbuz, S. Gungor, B. Guner, T. Caskurlu

**VS9: RETROPERITONEOSCOPY**

14:00–15:30 hr

**VS9-01** EXPERIMENTAL HYBRID TRANSVAGINAL RETROPERITONEOSCOPIC NEPHRECTOMY

M. Hisano, F. Hondo, J. Giordano-nappi, R. Duarte, P. Sakai, M. Srougi—Brazil

**VS9-02** TIPS AND TRICKS OF RETROPERITONOSCOPIC URETEROLITHOTOMY: SHOULD BE DONE FOR IMPACT URETER STONES: VIDEO

E. Huri, T. Akgül, T. Karakan, C. Germiyanoglu—Turkey

**VS9-03** SINGLE PORT LAPAROSCOPIC RETROPERITONEAL RADICAL NEPHRECTOMY

Y. Ozgok, S. Basal, S. Bedir, M. Hoşcan, A. Gur, A. Avci

**VS9-04** NOTES TRANSVAGINAL RETROPERITONEOSCOPY—A NEW FLEXIBLE RETROPERITONEAL ACCESS FOR RENAL AND ADRENAL SURGERY—REPORT OF THE FIRST CASE  
L. Curcio, R. Zorron, D. Leal, E. Kanaan, I. Cabral—Brazil

**VS9-05** LAPAROSCOPIC BILATERAL RPLND IN STAGE 2B TESTIS TUMOR  
A. Basiri, H. Djaladat, M. Mohammadi sichani, M. Asl zare

**VS9-06** SINGLE TROCAR SURGERY—PRELIMINARY RETROPERITONEOSCOPIC EXPERIENCE  
G. Pini, S. Micali, M. Sighinolfi, M. Rivalta, S. De stefani, G. Bianchi

**VS9-07** RETROPERITONEOSCOPIC HYBRID-LESS URETEROLITHOTOMY  
G. Pini, S. Micali, M. Sighinolfi, F. Cianci, F. Annino, G. Bianchi

**VS9-08** VIDEO ABSTRACT: LAPAROSCOPIC RETROPERITONEAL LYMPH NODE DISSECTION (LRPLND) FOR HIGH RISK PEDIATRIC PATIENTS WITH PARA-TESTICULAR RHABDOMYOSARCOMA  
J. Tomaszewski, D. Sweeney, A. Mohamed, L. Kavoussi, M. Ost

**VS9-09** RETROPERITONEOSCOPIC APPROACH IN THE TREATMENT OF URINARY FISTULA AFTER RIGID ENDOSCOPIC URETEROLITHOTRIPTY FOR UPPER URETERAL STONE  
M. Tobias-machado, E. Starling, C. Gromatzki, C. Bautzer, F. Ferro, E. Wroclawski

**VS9-10** A SYSTEMATIC TECHNIQUE FOR LAPAROSCOPIC SUPERFICIAL INGUINAL LYMPH NODE DISSECTION—DEVELOPING THE POSTERIOR AND ANTERIOR PLANES INDIVIDUALLY  
J. Montgomery, A. Weizer—USA

### **MP13: IMAGING**

16:00–17:30 hr

**MP13-01** IMAGING CHARACTERISTICS OF RENAL CRYOLESIONS: 2 YEAR FOLLOW-UP  
D. Kaplon, S. Hedican, F. Lee, L. Hinshaw, S. Nakada

**MP13-02** EVALUATION OF AFFECTED RENAL FUNCTION USING RENAL SCINTIGRAPHY AFTER LAPAROSCOPIC PARTIAL NEPHRECTOMY  
K. Tatsugami, K. Kuroiwa, A. Yokomizo, M. Eto, S. Naito

**MP13-03** CRITICAL ANALYSIS OF THE USE OF PREOPERATIVE IMAGING STUDIES FOR PATIENTS UNDERGOING ROBOTIC-ASSISTED LAPAROSCOPIC RADICAL PROSTATECTOMY: IS PRACTICE CONSISTENT WITH PUBLISHED GUIDELINES?  
J. Yates, G. Dakwar, I. Sawczuk, R. Munver—United States

**MP13-04** TOTAL RADIATION EXPOSURE DURING AN ACUTE STONE EVENT IN INSURED AND UNINSURED PATIENTS  
D. Greene, J. Chamberlin, C. Tenggardjaja, F. Jellison, K. Huynh, D. Baldwin—USA

**MP13-05** DOES LOW DOSE CT PREDICT URETERAL STONE SIZE?  
C. Tenggardjaja, F. Jellison, F. Almaguel, J. Smith, T. Kelly, D. Baldwin—USA

**MP13-06** IMPACT OF THE DIFFERENCE IN TUMOR SIZE MEASURED ON IMAGING AND FINAL PATHOLOGY ON PARTIAL NEPHRECTOMY OUTCOMES  
U. Boylu, M. Hopkins, M. Pinsky, A. Tracey, B. Lee—USA

**MP13-07** THE ROLE OF ABDOMINAL IMAGING IN THE EVALUATION OF PATIENTS FOLLOWING ROBOT-ASSISTED LAPAROSCOPIC RADICAL PROSTATECTOMY  
T. Feng, J. Yohannan, J. Berkowitz, M. Allaf

**MP13-08** MINIMALLY INVASIVE MANAGEMENT WITH PERCUTANEOUS EMBOLIZATION EXPERIENCE IN TWELVE PATIENTS WITH RENAL INJURY  
H. Ahn, S. Kim, J. Choi, S. Kim, H. Im, Y. Kim—Korea

**MP13-09** MULTI-CENTER ANALYSIS OF POST-OPERATIVE CT FINDINGS FOLLOWING PERCUTANEOUS NEPHROLITHOTOMY  
M. Semins, B. Chew, M. Humphreys, N. Miller, O. Shah, B. Matlaga—USA

**MP13-10** UNENHANCED SPIRAL CT-ASSISTANT LOCALIZATION COMBINED WITH C-ARM IN COMPLEX RENAL STONE TREATMENT BY MINIMALLY PERCUTANEOUS NEPHROLITHOTOMY (MPCNL)  
L. Jiang—China

**MP13-11** MORPHOMETRIC ANALYSIS OF THE URETEROPELVIC JUNCTION USING AN IMAGE ANALYSIS SOFTWARE  
A. Mathew, A. Kurien, S. Mishra, V. Muthu, R. Sabnis, M. Desai

**MP13-12** PERCUTANEOUS ULTRASOUND-GUIDED RADIOFREQUENCY ABLATION OF RENAL TUMORS  
I. Camargo, J. Del cura, R. Zabala, I. Iriarte, A. Loizaga, M. Unda

**MP13-13** APPLICATION AND LONG TERM EFFICACY OF MAG3-F0 RENAL SCAN TO DEFINE FUNCTIONALITY AND SUCCESS IN LAPAROSCOPIC PYELOPLASTY  
R. Leveillee, V. Bird, J. Bracho ii, M. Aziz, G. Sfakianakis, M. Georgiou

**MP13-14** IMAGING OF THE URETEROPELVIC JUNCTION OBSTRUCTION WITH MDCT AND DESIGNATION OF THE SURGICAL PLAN

C. Kalogeropoulou, P. Kallidonis, I. Kyriazis, A. Al aown, J. Stolzenburg, E. Liatsikos—Greece

**MP13-15** PRELIMINARY INVESTIGATIONS OF COMPUTED TOMOGRAPHIC (CT) THERMOMETRY DURING PERCUTANEOUS CT-GUIDED RENAL TUMOR TREATMENT

R. Leveillee, N. Salas, C. Moore, L. Zhang, S. Peairs, D. Gustafson—USA

**MP13-16** USE OF INTRAOPERATIVE DOPPLER ULTRASOUND TO FACILITATE IDENTIFICATION OF CROSSING VESSEL DURING ROBOTIC AND LAPAROSCOPIC PYELOPLASTY

S. Parekattil, J. Sijo, B. Canales, H. Atalah, L. Su

**MP13-17** MR GUIDED LASER INDUCED THERMOTHERAPY (LITT) OF THE KIDNEY

S. Vallo, S. Zangos, D. Jonas, W. Bentas—Germany

**MP13-18** NON DESTRUCTIVE EX VIVO URINARY STONE COMPOSITION ANALYSIS USING COHERENT-SCATTER COMPUTED TOMOGRAPHY

C. Mendez probst, L. Nott, J. Denstedt, I. Cunningham—Canada

**MP13-19** PREVALENCE OF NEPHROLITHIASIS IN AN ASYMPTOMATIC SCREENING POPULATION: ADDITIONAL FINDINGS ON VIRTUAL COLONOSCOPY

S. Stroup, J. Durbin, G. Patino, D. Lacey, J. L'esperance, B. Auge—USA

**MP13-20** ACUTE CHANGES IN THE RENAL RESISTIVE INDEX IN A SOLITARY KIDNEY WITH A URETERAL STONE: A COMPARATIVE IN VIVO PORCINE STUDY

R. Venkatesh, S. Labarbera, N. Das, G. Baca, R. Figenshau, A. Tawfik—USA

**MP14: LAPAROSCOPY—KIDNEY 1**  
16:00–17:30 hr

**MP14-01** MALE VERSUS FEMALE LAPAROSCOPIC PARTIAL NEPHRECTOMY: IS THERE A DIFFERENCE?

H. Jung—USA

**MP14-02** LAPAROSCOPY-ASSISTED PARTIAL NEPHRECTOMY THROUGH A SMALL INCISION

O. Kamihira, Y. Yoshikawa, A. Fukatu, K. Kimura, Y. Moriya, O. Matuura—Japan

**MP14-03** A RANDOMIZED, DOUBLE-BLINDED TRIAL OF KETOROLAC IN ADDITION TO NARCOTIC PATIENT-CONTROLLED ANALGESIA (PCA) FOLLOWING LAPAROSCOPIC DONOR NEPHRECTOMY

K. Pace, D. Ghiculete, R. Honey—Canada

**MP14-04** COMPARISON OF INVASIVENESS BETWEEN TRANSPERITONEAL AND RETROPERITONEAL APPROACHES IN LAPAROSCOPIC NEPHRECTOMY BY MEASURING CIRCULATING CYTOKINES

S. Narita, T. Kumazawa, M. Saito, Y. Horikawa, N. Tsuchiya, T. Habuchi

**MP14-05** HIGH OPEN CONVERSION RATE IN LAPAROSCOPIC RENAL ABLATIVE SURGERY IS LIMITED WITH 20 CASES

O. Sanli, T. Tefik, M. Ortac, S. Karakus, F. Ozcan, H. Issever—Turkey

**MP14-06** PERIOPERATIVE OUTCOMES OF THE MANAGEMENT OF RENAL TUMORS IN THE ELDERLY

A. Herati, A. K. george, S. S. saluja, A. K. srinivasan, M. A. vira—United States

**MP14-07** COMPARISON OF CONVALESCENCE AND POSTOPERATIVE PAIN USING VARIOUS HAND PORT INCISION LOCATIONS

D. Kaplon, S. Hedican, S. Nakada—wi USA

**MP14-08** PROLONGING THE POST-OP LENGTH OF STAY FOLLOWING LAPAROSCOPIC NEPHRECTOMY. A CAUTIONARY TALE ON THE INTRODUCTION OF AN INTEGRATED CARE PATHWAY

A. Stewart, R. Khafagy, G. Lewis, J. Barrie, J. Cartledge—UK

**MP14-09** RETROPERITONEAL APPROACH IS ADVANTAGEOUS TO TRANSPERITONEAL APPROACH IN TERMS OF OPERATIVE TIME; BLOOD LOSS AND LENGTH OF HOSPITAL STAY FOR LAPAROSCOPIC NEPHRECTOMIES

T. Tefik, O. Sanli, T. Mut, A. Atar, E. Aliyev, Nane

**MP14-10** IS LAPAROSCOPIC NEPHRECTOMY INDICATED IN NONFUNCTIONING GIANT HIDRONEPHROTIC KIDNEYS?

M. Arslan, T. Degirmenci, B. Gunlusoy, S. Minareci, A. Ayder—Turkey

**MP14-11** CRYOABLATION OF SMALL RENAL MASSES IN SOLITARY KIDNEYS

Z. Okhunov, M. Ordenez, J. Rosales, B. Shingleton, J. Landman

**MP14-12** IMPACT OF WARM ISCHEMIA ON RENAL FUNCTION FOLLOWING LAPAROSCOPIC PARTIAL NEPHRECTOMY: A MULTICENTER STUDY

S. Shikanov, D. Lifshitz, S. Matin, J. Landman, J. Wolf, Jr., A. Shalhav—USA

**MP14-13** PROSPECTIVE COMPARISON OF LAPAROSCOPIC RADICAL NEPHRECTOMY (LRN) VERSUS OPEN RADICAL NEPHRECTOMY (ORN)

O. Sanli, T. Tefik, M. Ortac, S. Karakus, F. Kucukdurmaz, T. Esen—Turkey

**MP14-14** VIDEO ASSISTED MINILAPAROTOMY NEPHRON SPARING SURGERY FOR CHALLENGING CASES OF RENAL TUMORS IN A SOLITARY KIDNEY  
S. Lee, K. Koo, H. Jeon, S. Yang, W. Han

**MP14-15** PREDICTING ONCOLOGICAL OUTCOMES IN PATIENTS UNDERGOING LAPAROSCOPIC NEPHROURETERECTOMY  
M. Lee, G. Haber, K. Kamoi, D. Snow, J. Kaouk, I. Gill—USA

**MP14-16** OUTCOMES OF LAPAROSCOPIC RADICAL SURGERY FOR RENAL AND UPPER URINARY TRACT MALIGNANCIES IN PATIENT WITH END-STAGE RENAL DISEASE  
K. Hirai, F. Sato, M. Imagawa, Y. Tasaki, N. Nasu, H. Mimata—Japan

**MP14-17** LAPAROSCOPIC RESECTION OF LOCAL RECURRENCE FOLLOWING PRIOR RADICAL NEPHRECTOMY FOR CLINICALLY LOCALIZED RENAL CELL CARCINOMA: PERIOPERATIVE OUTCOMES AND INITIAL OBSERVATIONS  
M. Allaf, J. Berkowitz

**MP14-18** CHANGES IN RENAL FUNCTION AFTER LAPAROSCOPIC PARTIAL NEPHRECTOMY WITH TEMPORARY RENAL ISCHEMIA  
Y. Komai, G. Kawa, N. Takizawa, N. Oguchi, H. Kinoshita, T. Matsuda—Japan

**MP14-19** LAPAROSCOPIC RADICAL NEPHROURETERECTOMY: RESULTS OF A MULTICENTRIC ITALIAN STUDY  
F. Porpiglia, A. Celia, L. Luciani, C. Terrone, G. Guazzoni, P. Parma

**MP14-20** COMPARISON OF EFFECTS OF OPEN AND LAPAROSCOPIC PARTIAL NEPHRECTOMY ON RENAL FUNCTION  
Y. Funahashi, R. Hattori, T. Yamamoto, O. Kamihira, M. Gotoh

## **MP15: ROBOTIC PROSTATE 2**

16:00–17:30 hr

**MP15-01** USE OF A FLEXIBLE CO<sub>2</sub> LASER FIBER FOR PRECISE DISSECTION OF NEUROVASCULAR BUNDLE DURING ROBOTIC ASSISTED LAPAROSCOPIC PROSTATECTOMY  
M. Rothberg, C. Ritch, P. Cheetham, J. Landman, K. Badani—USA

**MP15-02** EFFECT OF BONY PELVIC DIMENSIONS MEASURED VIA PREOPERATIVE MAGNETIC RESONANCE IMAGING ON PERFORMING ROBOT-ASSISTED LAPAROSCOPIC PROSTATECTOMY  
S. Hong, S. Jeong, S. Byun, H. Park, S. Doo, S. Lee—Korea

**MP15-03** ANTERIOR VERSUS POSTERIOR APPROACH TO SEMINAL VESICLE DISSECTION DURING ROBOTIC ASSISTED LAPAROSCOPIC PROSTATECTOMY  
E. Coronato, J. Singh, P. Ginsberg, J. Jaffe, J. Harmon

**MP15-04** PERCEPTIONS OF ROBOTIC SURGERY AMONGST PATIENTS TREATED WITH ROBOT ASSISTED RADICAL PROSTATECTOMY  
M. Lerner, R. Bowens, S. Lucas, M. Koch, C. Sundaram

**MP15-05** DOES PREOPERATIVE 3.0 TESLA MRI CONTRIBUTE IN TREATMENT OF HIGH-RISK PROSTATE CANCER?  
U. Boylu, O. Sartor, B. Lee, R. Thomas—USA

**MP15-06** PRE-OPERATIVE URINARY FUNCTION INFLUENCES PATIENT REPORTED SATISFACTION AND REGRET FOLLOWING ROBOTIC RADICAL PROSTATECTOMY  
D. Lee, M. Truesdale, K. Badani, P. Cheetham—USA

**MP15-07** SIGNIFICANCE OF PROSTATE SIZE ON PATHOLOGICAL OUTCOMES IN PATIENTS UNDERGOING ROBOTIC ASSISTED LAPAROSCOPIC PROSTATECTOMY  
A. Akhavan, J. Carlucci, F. Nabizada-pace, P. Muntner, D. Samadi—USA

**MP15-08** COMPARISON OF FUNCTIONAL OUTCOMES BETWEEN ROBOT-ASSISTED RADICAL PROSTATECTOMY AND RADICAL RETROPUBIC PROSTATECTOMY: A SINGLE SURGEON EXPERIENCE  
T. Kang, J. Park, C. Song, J. Hong, H. Park, H. Ahn

**MP15-09** PATTERN OF COMPLICATIONS AFTER ROBOT-ASSISTED LAPAROSCOPIC RADICAL PROSTATECTOMY: AN ANALYSIS BASED ON THE CLAVIEN CLASSIFICATION SYSTEM  
J. Jeong, E. Choi, T. Mueller, M. Ercolani, I. Kim—USA

**MP15-10** THE EFFECT OF OBESITY ON INTRAOPERATIVE OUTCOMES DURING ROBOT-ASSISTED RADICAL PROSTATECTOMY (RARP)  
S. Sharma, J. Stern, B. Meredith, M. Nguyen, D. Eun, D. Lee

**MP15-11** SURGEON PERCEPTION IS NOT A GOOD PREDICTOR OF PERIOPERATIVE OUTCOMES IN ROBOT-ASSISTED RADICAL PROSTATECTOMY (RARP)  
S. Sharma, J. Stern, B. Meredith, M. Nguyen, C. Schwab, D. Lee

**MP15-12** STAGING IMPLICATIONS OF ANTERIOR PROSTATIC FAT PAD EXCISION DURING ROBOT-ASSISTED LAPAROSCOPIC RADICAL PROSTATECTOMY  
J. Jeong, S. Lamba, M. Ercolani, I. Kim—USA

**MP15-13** INITIATING A ROBOTIC UROLOGY PROGRAM WITH OPTIMAL ONCOLOGIC EFFICACY; IMPACT OF MENTORSHIP ON POSITIVE SURGICAL MARGINS IN ROBOTIC RADICAL PROSTATECTOMY  
A. Kural, F. Atug, I. Tufek, H. Akpinar, V. Patel, A. Mottrie

**MP15-14** TANDEM-ROBOT ASSISTED LAPAROSCOPIC RADICAL PROSTATECTOMY (T-RALP) TO IMPROVE THE NEUROVASCULAR BUNDLE VISUALIZATION: A FEASIBILITY STUDY  
M. Han, B. Trock, D. Petrisor, C. Kim, D. Stoianovici

**MP15-15** EXTREMELY LARGE PROSTATE SIZE MATTERS FOR FUNCTIONAL OUTCOMES FOLLOWING ROBOTIC ASSISTED RADICAL PROSTATECTOMY  
B. Hollenbeck, R. Hedgepeth, S. Zhang, T. Skolarus—USA

**MP15-16** HYPOTHERMIC NERVE SPARING ROBOTIC RADICAL PROSTATECTOMY: IMPACT ON EARLY CONTINENCE FOR MEN AGED 70 OR GREATER  
T. Ahlering, D. Finley, K. Osann, A. Chang, R. Santos, D. Skarecky—USA

**MP15-17** IMMEDIATE SURGICAL OUTCOMES OF ROBOT-ASSISTED LAPAROSCOPIC RADICAL CYSTECTOMY: COMPARATIVE ANALYSIS WITH THE OPEN PROCEDURE  
T. Kim, T. Kwon, E. Yoo, Y. Park, H. Kim, J. Kim—Korea

**MP15-18** ROBOTIC-ASSISTED LAPAROSCOPIC RADICAL PROSTATECTOMY IN THE MORBIDLY OBESE PATIENT: IS THERE A SIZE LIMIT?  
J. Yates, M. Gross, D. Golombos, I. Sawczuk, R. Munver—United States

**MP15-19** A COMPARISON OF OUTCOMES AMONG MEN WITH AND WITHOUT URINE LEAKS AFTER ROBOTIC-ASSISTED LAPAROSCOPIC RADICAL PROSTATECTOMY  
D. Rebuck, D. Kim, R. Rico, J. Meeks, K. Perry, R. Nadler

**MP15-20** EVALUATION OF THE SAFETY OF PERIOPERATIVE ENOXAPARIN ADMINISTRATION IN PATIENTS UNDERGOING ROBOTIC-ASSISTED LAPAROSCOPIC RADICAL PROSTATECTOMY  
J. Yates, J. Uberoi, I. Sawczuk, D. Golombos, M. Gross, R. Munver—United States

**MP16: UROLITHIASIS 2**

16:00–17:30 hr

**MP16-01** REMOVAL OF ASYMPTOMATIC IPSILATERAL RENAL STONES FOLLOWING RIGID URETEROSCOPY FOR URETERAL STONES  
H. Ahmadnia, A. Yarmohamadi, M. Imani, M. Shokhian

**MP16-02** HAND ASSISTED URETEROSCOPY IN URETERAL AND PYELIC STONE TREATMENT

P. Geavlete, R. Multescu, D. Georgescu, B. Geavlete—Romania

**MP16-03** HYPERKALEMIA DOES NOT NEED CORRECTION PRIOR TO PERCUTANEOUS NEPHROSTOMY (PCN) IN OBSTRUCTED HYDRONEPHROSIS (OHN)  
B. Somani, H. Gupta, S. Bramwell, A. Todd

**MP16-04** KIDNEY FUNCTION IS DECREASED AFTER TREATMENT OF SILENT URETERAL STONE  
F. Vicentini, L. Borges, E. Mazzucchi, E. Chedid neto, A. Brito, M. Srougi

**MP16-05** A “CUBIC STONE”: L-SHAPED KIDNEY COMPLICATED BY CALCULOSIS AND HYDRONEPHROSIS  
M. Malta almeida, J. Teixeira bessa, A. Vommaro mendes, J. Milfont, M. Fortes, J. Callijão araujo—Brazil

**MP16-06** IMPACT OF PERCUTANEOUS NEPHROLITHOTOMY ON RENAL FUNCTION DURING FIRST FEW DAYS AFTER SURGERY  
A. Nouraliadeh, M. Mohammadi sichani, A. Kashi, M. Kamranmanesh

**MP16-07** IS OPEN URINARY STONE SURGERY DEAD?  
R. De lima favaretto, M. Augusto elias de mattos, M. Jose bruschini rodrigues netto, N. Rodrigues netto junior—Brazil

**MP16-08** UNKNOTTING A KNOTTED ZEBRA WIRE IN THE URETER: A USEFUL TECHNIQUE INVENTED  
A. Ashish patil—India

**MP16-09** CONTRALATERAL URETEROSCOPY PERFORMED AT TIME OF PERCUTANEOUS NEPHROLITHOTOMY: A UNIQUE EVALUATION OF STONE FREE RATES  
A. Krambeck, S. Handa, J. Lingeman—United States

**MP16-10** PROFILE OF THE BRUSHITE STONE FORMER  
A. Krambeck, S. Handa, F. Coe, A. Evan, J. Lingeman—United States

**MP16-11** STONEMAG: IMPROVED BINDING TIMES PERMIT MAGNETIZATION OF STONE FRAGMENTS FOR “REAL-TIME” REMOVAL WITH ENDOSCOPIC PLATFORMS  
C. Tracy, S. Mcleroy, B. Gnade, M. Pearle, J. Cadeddu—USA

**MP16-12** METABOLIC STONES: HOW RELIABLE ARE STONE ANALYSIS RESULTS?  
A. Krambeck, N. Khan, M. Jackson, J. Lingeman, J. Williams Jr—United States

**MP16-13** A NOVEL DEVICE TO REDUCE TIME REQUIRED IN IRRIGATION MANAGEMENT DURING SEMI-RIGID URETEROSCOPIC LITHOTRIPSY  
J. Ditrolio, M.D., M. Lasalle, M.D., R. Bhalla, M.D.—USA

**MP16-14** THE COMPARISON BETWEEN TWO GROUPS OF PATIENTS UNDER OPERATION AND LITHOTRIPSY DUE TO URINARY TRACT STONES FROM THE ASPECT OF EPIDEMIOLOGIC PARAMETERS DURING YEARS 2003-2006 ADMITTED AT UROLOGY DEPARTMENT OF I.R HOSPITAL  
R. Taghavi, K. Tavakkoli tabassi, R. Mahdavi zafarghandi, M. Darabi mahboub—Iran

**MP16-15** PERCUTANEOUS NEPHROSTOMIC TREATMENT OF UPPER URINARY TRACT FUNGAL BALL COMPLICATING HYDRONEPHROSIS  
H. Chen, W. Xue, J. Pan, M. Cao, Y. Chen, Y. Huang

**MP16-16** LATERAL DECUBITUS POSITION PERCUTANEOUS ENDOUROLOGICAL PROCEDURES IN HIGH RISK PATIENTS  
T. El-husseiny, K. Moraitis, Z. Maan, P. Saunders, J. Masood, N. Buchholz

**MP16-17** THE NEW INVISIO® DUR-D “CHIP-ON-THE-TIP” URETEROSCOPES – EVALUATION OF CHANGES IN PHYSICAL PROPERTIES OVER TIME  
T. El-husseiny, K. Moraitis, Z. Maan, M. Birch, J. Masood, N. Buchholz

**MP16-18** COST-EFFECTIVENESS OF ANTI-RETROPULSION DEVICES FOR URETEROSCOPIC PNEUMATIC LITHOTRIPSY  
E. Olweny, B. Eisner, M. Stoller

**MP16-19** HYDROXYPROLINE-INDUCED HYPEROXALURIA USING ACIDIFIED AND TRADITIONAL DIETS IN THE PORCINE MODEL  
D. Kaplon, T. Crenshaw, K. Penniston, S. Nakada

**MP16-20** THE IMPACT OF METABOLIC RISK MANAGEMENT ON RECURRENCE OF URINARY STONES: 9 -YEAR AKDENIZ UNIVERSITY EXPERIENCE  
M. Baykara, Y. Akin, T. Erdogru, A. Danisman, S. Yucel—Turkey

## **VP19: NEW TECHNOLOGY**

16:00–17:30 hr

**VP19-01** FOUNTAIN TECHNIQUE FOR FRAGMENT EVACUATION AFTER PULVERISATION OF LARGE BLADDER CALCULI  
A. Ashish patil—India

**VP19-02** A SAFE AND EFFICIENT TECHNIQUE FOR INITIAL ACCESS TO INTRAPERITONEAL LAPAROSCOPY  
A. Ghazi a., R. Zimmermann, A. Schfler, G. Janetschek

**VP19-03** THE APPLICATION OF "ENDO-LAP" APPROACH IN UROLOGY DISEASES  
S. Chan, Y. Chiu, S. Lam

**VP19-04** NOTES TRANSVAGINAL NEPHRECTOMY: INITIAL CLINICAL EXPERIENCE  
W. White, G. Haber, R. Goel, S. Crouzet, S. Brethauer, J. Kaouk

**VP19-05** LAPAROSCOPIC PARTIAL NEPHRECTOMY VS LAPAROSCOPIC ABLATIVE THERAPY: A COMPARISON OF SURGICAL AND FUNCTIONAL OUTCOMES IN A MATCHED COHORT  
K. Kiriluk, S. Shikanov, K. Zorn, G. Steinberg, A. Shalhav, D. Lifshitz—USA

**VP19-06** LAPAROSCOPIC PORTSITE ASSISTED (TRANSPORTAL) ILEAL URETER  
M. Ramalingam, K. Senthil, M. Pai

**VP19-07** 8-YEAR OUTCOMES OF RENAL CRYOTHERAPY  
M. Aron, K. Kamoi, R. Brandina, A. Berger, I. Gill, M. Desai

**VP19-08** SCARLESS MICROPORT AUGMENTED RESTORATION OF TRIANGULATION (SMART) SURGERY: A NEW SURGICAL PARADIGM  
D. Baldwin, D. Greene, N. Krupp, P. Mahdavi, J. Chamberlin, K. Ebrahimi

**VP19-09** PERCUTANEOUSCYSTOLITHOTOMY BY RETROGARDE APPROACH  
S. Sakhal, B. Samadzade, A. Bardide, M. Moradi, M. Omidvar, H. Karami

**VP19-10** TRANSMESOCOLIC APPROACH TO LAPAROSCOPIC PYELOLITHOTOMY  
M. Ramalingam, K. Senthil, M. Pai

**VP19-11** PURE NOTES NEPHRECTOMY: FROM THE CADAVER MODEL TO THE FIRST SUCSSEFUL CLINICAL CASE  
M. Aron, A. Berger, M. Desai, R. Brandina, I. Gill, R. Sotelo

**VP19-12** INTRA-OPERATIVE SELECTIVE RENAL ARTERY BALLOON OCCLUSION DURING LAPAROSCOPIC RADICAL NEPHRECTOMY  
S. Kommu, M. Nayeemuddin, A. Golash, C. Luscombe, J. Asquith, D. West—United Kingdom

**VP19-13** AN ENDOSCOPIC TRANSVESICAL ANASTAMOSIS: REALIZATION OF NATURAL ORIFICE SUTURING TECHNIQUES  
M. Humphreys, J. Sauer, P. Andrews

**VP19-14** RENAL VESSEL SHIELDING IN LAPAROSCOPIC RENAL MASS CRYOTHERAPY (VIDEO ABSTRACT)  
A. Benson, B. Schwartz—United States

**VP19-15** INTERMEDIATE FOLLOW-UP OF RENAL MASSES TREATED BY LAPAROSCOPIC CRYOABLATION  
C. Mamoulakis, P. Beemster, S. Mehmedovic, H. Wijkstra, J. De la rosette, M. Laguna

**VP19-16** RENAL LAPAROENDOSCOPIC SINGLE-SITE SURGERY (LESS) WITHOUT ACCESSORY TROCARS: A SINGLE INSTITUTION EXPERIENCE  
S. Rais-bahrami, A. Herati, S. Montag, M. Atalla, L. Kavoussi, L. Richstone

**VP19-18** TUMOR SIZE AND ENDOPHYTIC GROWTH PATTERN AFFECT RECURRENCE RATES AFTER LAPAROSCOPIC RENAL CRYOABLATION  
M. Tsivian, C. Lyne, V. Mouraviev, J. Mayes, M. Kimura, T. Polascik

**VP19-19** LAPAROSCOPIC AND PERCUTANEOUS RENAL CRYOABLATION HAVE COMPARABLE MID-TERM ONCOLOGIC OUTCOMES  
M. Tsivian, V. Chen, M. Ferrandino, R. Nelson, D. Albala, T. Polascik

**VP19-20** OUTCOMES OF HIGH INTENSITY FOCUSED ULTRASOUND (HIFU) IN THE TREATMENT OF LOCALIZED PROSTATE CANCER  
R. Sanseverino, O. Intilla, G. Napodano, A. Campitelli, U. di mauro, R. Angrisani—Italy

**VP20: ROBOTICS-PROSTATE**  
16:00–17:30 hr

**VP20-01** PERIURETHRAL SUSPENSION STITCH DURING ROBOTIC-ASSISTED LAPAROSCOPIC RADICAL PROSTATECTOMY: DESCRIPTION OF THE TECHNIQUE AND CONTINENCE OUTCOMES  
R. Ferreira coelho, K. J palmer, S. Chauhan, B. Rocco, M. B. Patel, V. Patel—US

**VP20-02** SALVAGE ROBOTIC-ASSISTED LAPAROSCOPIC PROSTATECTOMY (SRALP) FOR RADIORECURRENT PROSTATE CANCER: MULTI-INSTITUTIONAL OUTCOMES  
M. B. Patel, R. Ferreira coelho, R. Ferrigni, E. Castle, T. Ahlering, V. Patel

**VP20-03** HYPOTHERMIC ROBOTIC RADICAL PROSTATECTOMY: IMPACT ON CONTINENCE  
T. Ahlering, D. Finley, K. Osann, A. Chang, R. Santos, D. Skarekcy—USA

**VP20-04** RECTOURINARY FISTULA AFTER PRIMARY AND REPEATED HIFU FOR PROSTATE CANCER. PREVALENCE AND SURGICAL MANAGEMENT  
C. Cellarius, D. Pfeiffer, C. Netsch, H. Boehme, E. Gross, A. Gross

**VP20-05** ROBOT-ASSISTED LAPAROSCOPIC RADICAL PROSTATECTOMY. RESULT OF OUR FIRST 100 CASES  
B. Alessandra, F. Annino, C. De carne, S. Micali, S. De stefani, G. Bianchi

**VP20-06** QUALITY IMPROVEMENTS IN ROBOTIC PROSTATECTOMY: THE EFFECT OF TECHNICAL CHANGES ON ONCOLOGIC AND FUNCTIONAL OUTCOMES  
H. Lavery, F. Nabizada-pace, J. Carlucci, D. Samadi—USA

**VP20-07** HIGH VOLUME, FELLOWSHIP-TRAINED SINGLE SURGEON ROBOTIC-ASSISTED LAPAROSCOPIC RADICAL PROSTATECTOMY EXPERIENCE: 350 CASES IN 30 MONTHS  
R. Carey, T. Hakky

**VP20-08** IMPACT OF ROBOTIC TRAINING ON SURGICAL AND PATHOLOGIC OUTCOMES DURING ROBOT-ASSISTED LAPAROSCOPIC RADICAL PROSTATECTOMY  
E. Kwon, H. Jung, T. Bautista, S. Williams, G. Chien—USA

**VP20-09** OCCURRENCE OF BLADDER OUTLET OBSTRUCTION (BOO) AFTER SINGLE HIFU TREATMENT OF THE PROSTATE  
C. Netsch, D. Pfeiffer, C. Cellarius, A. Gross—Germany

**VP20-10** POSITIVE SURGICAL MARGINS DURING ROBOTIC-ASSISTED LAPAROSCOPIC PROSTATECTOMY: THE EFFECT OF LOCATION UPON EXTENT  
H. Lavery, F. Nabizada-pace, J. Carlucci, D. Samadi—USA

**VP20-11** TUMOR PERCENTAGE INVOLVEMENT PREDICTS PROSTATE SPECIFIC ANTIGEN RECURRENCE AFTER RADICAL PROSTATECTOMY ONLY IN MEN WITH SMALL PROSTATES  
D. Albala, M. Lipkin, M. Uhlman, T. Polascik, L. Sun, J. Moul—USA

**VP20-12** SINGLE PORT ROBOTIC RADICAL PROSTATECTOMY  
R. Goel, W. White, G. Haber, S. Crouzet, J. Kaouk

**VP20-13** ROBOTIC-ASSISTED SALVAGE RADICAL PROSTATECTOMY AFTER FAILED HIFU AND IMRT  
R. Carey, T. Hakky—USA

**VP20-14** SHORT-TERM ASSESSMENT OF THE ONCOLOGIC SAFETY OF ROBOTIC PROSTATECTOMY IN PREOPERATIVELY HIGH-RISK PATIENTS  
H. Lavery, F. Nabizada-pace, J. Carlucci, D. Samadi—USA

**VP20-15** OBSTACLES IN THE INITIAL PHASE OF ROBOT ASSISTED RADICAL PROSTATECTOMY (RARP)—A PROSPECTIVE ANALYSIS OF THE FIRST 75 CASES. DEPARTMENT OF UROLOGY, SILOAH ST.TRUDPERT HOSPITAL, PFORZHEIM, GERMANY  
V. Zimmermanns, P. Ober, J. Sommer, S. Lahme

**VP20-16** ROBOTIC SINGLE PORT SUPRAPUBIC TRANSVEISCAL ENUCLEATION OF THE PROSTATE (R-STEP): INITIAL EXPERIENCE  
K. Fareed, W. White, G. Haber, R. Goel, S. Crouzet, J. Kaouk—USA



**VP20-17** USE OF ENSEAL<sup>®</sup> DURING ROBOTIC PROSTATECTOMY PEDICLE CONTROL: COLD IRRIGATION TO MINIMIZE LATERAL THERMAL INJURY

K. Zorn, M. Katz, A. Razmaria, G. Zagaja, A. Shalhav, H. Alhamadie—USA

**VP20-18** LAPAROSCOPIC AND ROBOTIC UROLOGICAL SURGERY – EVOLVING ANATOMICAL KNOWLEDGE OF THE PROSTATE

S. Kommu, Z. Hashim, A. Golash, C. Luscombe, C. Eden, S. (sarg)—United Kingdom

**VP20-19** FEASIBILITY OF ROBOT-ASSISTED INTRACORPOREAL LAPAROSCOPIC ILEAL CONDUIT URINARY DIVERSION

M. Sangalli, G. De naeyer, P. Schatteman, P. Carpentier, E. Fonteyne, A. Mottrie—Belgium

**VP20-20** ROBOTIC-ASSISTED LAPAROSCOPIC INGUINAL HERNIA REPAIR WITH DUAL-LAYER POLYPROPYLENE MESH DURING ROBOTIC-ASSISTED LAPAROSCOPIC CYSTECTOMY

J. Marshall, J. Gordetsky, E. Singer, D. Golijanin, H. Rashid, G. Wu—USA

**VS11: TRANSURETHRAL SURGERY**

16:00–17:30 hr

**VS11-01** STUBBORN STRICTURES—IS LASER ABLATION THE ANSWER? DR. ULHAS SATHAYE SAHAYOG SPECIALITY HOSPITAL JAMNAGAR 361001 INDIA

U. Sathaye

**VS11-02** FLUORESCENCE CYSTOSCOPY WITH HEXAMINOLEVULINATE IN THE DIAGNOSIS OF BLADDER CANCER: OUR EXPERIENCE

M. Poggio, C. Scoffone, C. Cracco, M. Cossu, S. Grande, R. Scarpa—Italy

**VS11-03** GREEN LIGHT HPS 120 W LASER IN BPH – ROMANIAN EXPERIENCE

B. Geavlete, G. Nita, V. Mirciulescu, P. Geavlete—Romania

**VS11-04** HOLMIUM:YAG LASER EPILATION OF URETHRAL DIVERTICULAR HAIR

D. Beiko, S. Pierre, M. Leonard—Canada

**VS11-05** OPTICAL URETHROTOMY UNDER CORPUS SPONGIOSUM BLOCK

M. Ather, A. Zehri, Z. Alam

**VS11-06** ENDOSCOPIC MANAGMENT OF ADULT ORTHOTOPIC URETEROCELE AND ASSOCIATED CALCULI WITH HOLMIUM LASER: EXPERIENCE WITH 23 PATIENTS OVER 6 YEARS

H. Shah, V. Kumar, A. Khandkar, S. Kharodawala, H. Sodha, M. Bansal

**VS11-07** EX VIVO MODELS FOR TRAINING IN ENDOUROLOGY

A. Celia, G. Zeccolini, G. Breda

**VS11-08** A NEW SELF-EXPANDING FULLY COVERED REMOVABLE URETERAL STENT IN IRRADIATION INDUCED BILATERAL URETERAL OBSTRUCTION

R. BAISHYA, P. RANJAN, V. MUTHU, G. BADLANI, D. YACHIA, M. R. DESAI MULJIBHAI PATEL UROLOGICAL HOSPITAL. NADIAD—INDIA  
D. Yachia

**VS11-09** URETEROSCOPIC HOLMIUM LASER ENDOPYELOTOMY FOR URETEROPELVIC JUNCTION STENOSIS AFTER PYELOPLASTY

M. Baptistussi, E. Gewher, M. Morihisa

**VS12: LAPAROSCOPY—KIDNEY 3**

16:00–17:30 hr

**VS12-01** COMBINED ENDOSCOPIC AND LAPAROSCOPIC TREATMENT OF BILATERAL STAGHORN UROLITHIASIS IN A HORSESHOE KIDNEY

M. Poggio, C. Scoffone, F. Porpiglia, M. Cossu, C. Cracco, R. Scarpa—Italy

**VS12-02** LAPAROSCOPIC RENAL CYST RESECTION AND PERCUTANEOUS NEPROLITHOTRIPSY IN RENAL CYST AND NEPROLITHIASIS IN THE SAME KIDNEY

V. Yalcin, E. Coskuner, B. Ozkan—Turkey

**VS12-03** NEPHROURETERECTOMY WITH ENDOSCOPIC URETERAL DESINSERTION IN THE TREATMENT OF UPPER URINARY TRACT TUMORS—EXPERIENCE ON 150 CASES

P. Geavlete, E. Constantinescu, D. Georgescu, G. Nita, V. Cauni, B. Geavlete—Romania

**VS12-04** PURE LAPAROSCOPIC RADICAL NEPHRECTOMY WITH RENAL VEIN TUMOR THOMBECTOMY

B. Chung

**VS12-05** PURE LAPAROSCOPIC MANAGEMENT OF RENAL CELL CARCINOMA WITH INFERIOR VENA CAVAL THROMBUS

W. Lv, G. Hao, J. Xiao—China PR

**VS12-06** PEDIATRIC ROBOTIC ASSISTED LAPAROSCOPIC NEPHROURETERECTOMY

A. Chawla, P. Noh—USA

**VS12-07** ROBOTIC-ASSISTED NEPHROURETERECTOMY WITHOUT PATIENT REPOSITIONING

A. Weizer, J. Montgomery—USA

**VS12-08** FIVE-PORT COMPLETE ROBOTIC-ASSISTED LAPAROSCOPIC NEPHROURETERECTOMY WITH BLADDER CUFF REMOVAL

G. Wu, D. Golijanin, E. Singer, E. Erturk, J. Joseph, H. Rashid—USA

**VS12-09** RENAL CELL CARCINOMA DWELLING UPON A SIMPLE RENAL CYST WALL

Y. Ozgok, M. Ates, M. Hoscan, O. Istanbuluoglu, S. Basal, M. Zor—Turkey

**VS12-10** A SAFE AND EFFICIENT TECHNIQUE FOR INITIAL ACCESS TO INTRAPERITONEAL LAPAROSCOPY

A. Ghazi, R. Zimmermann, A. Schfler, G. Janetschek—Austria

**VS7: NEW TECHNOLOGY**

16:00–17:30 hr

**VS7-01** NATURAL ORIFICE TRANSLUMENAL ENDOSCOPIC SURGERY (NOTES) PARTIAL NEPHRECTOMY IN PORCINE MODEL

B. Lee, U. Boylu, M. Oommen, R. Thomas, V. Joshi—USA

**VS7-02** NATURAL ORIFICE TRANSLUMENAL ENDOSCOPIC SURGERY (NOTES) ACCESS: TRANSVESICAL, TRANSVAGINAL, TRANSCOLONIC, AND TRANSGASTRIC

G. Haber, J. Talarico, S. Crouzet, K. Litwak, S. Brethauer, J. Kaouk—USA

**VS7-03** HISTOTRIPTY ABLATION OF THE PROSTATE

J. Wheat, T. Hall, C. Hempel, J. Fowlkes, C. Cain, W. Roberts—United States

**VS7-04** NOTES TRANSVAGINAL NEPHRECTOMY: INITIAL CLINICAL EXPERIENCE

J. Kaouk, W. White, R. Goel, S. Crouzet, S. Brethauer, G. Haber—USA

**VS7-05** TRANSVAGINAL HYBRID NOTES NEPHRECTOMY USING A MULTI-CHANNEL PORT

R. Sotelo, O. Carmona, D. Ramirez, D. Canes, Desai, I. Gill—Venezuela

**VS7-06** ISOBARIC LAPAROSCOPIC RADICAL CYSTECTOMY IN WOMEN WITH THE “LAPARO-TENSER” ABDOMINAL WALL LIFTING SYSTEM

A. Granata, F. Pietrantuono, G. Incarbone, A. Gregori, A. Romanò, F. Gaboardi—Italy

**VS7-07** VIDEO PRESENTATION: STEREOTACTIC PERCUTANEOUS CRYOABLATION FOR RENAL TUMORS

G. Haber, S. Crouzet, E. Remer, K. Kamoi, W. White, J. Kaouk—USA

**VS7-08** UPPER URINARY TRACT ENDOUROLOGICAL TRAINING ON EX-VIVO PORCINE MODEL

A. Celia, G. Zeccolini, G. Breda

**VS7-09** A NOVEL URETERIC STENT FOR TUBELESS PCNL: AN INITIAL CLINICAL EXPERIENCE

H. Shah, S. Kharodawala, H. Sodha, V. Kumar, A. Khandkar, M. Bansal

**VS7-10** COMPUTER ASSISTED LAPAROSCOPIC SIMULATOR (UROBOX) WITH SELF ADJUSTABLE TRAINING PROGRAM DEPENDING ON TRAINEE’S PROGRESSION ON THE LEARNING CURVE—PRELIMINARY RESULTS

B. Petrut, F. Nechita, B. Tintila, A. Man, A. Muresan, I. Coman

**FRIDAY, OCTOBER 9**

**VP21: LESS-II**

10:30–12:00 hr

**VP21-01** PAIRED CONVENTIONAL-ARTICULATING VERSUS DUAL ARTICULATING AND DUAL CONVENTIONAL INSTRUMENTS IN EX VIVO SUTURING IN LAPAROENDOSCOPIC SINGLE SITE SURGERY (LESS)

S. Kommu, D. Carlidge, T. Finnigan, A. Chakravarti, C. Luscombe, A. Golash—United Kingdom

**VP21-02** ACCESS AND UTILITY OF A LAPAROENDOSCOPIC SINGLE-SITE SURGERY (LESS) TRAINING PLATFORM AMONG TRAINEES INTERESTED IN LAPAROSCOPIC UROLOGICAL SURGERY

S. Kommu, A. Chakravarti, A. Golash, C. Luscombe, A. Rane, S. (sarg)—United Kingdom

**VP21-03** INTACT SUTURING USING SONOSCOPIC INSTRUMENT MANIPULATION IN LAPAROENDOSCOPIC SINGLE-SITE SURGERY (LESS)

S. Kommu, I. Persad, I. Lewis, A. Forde, C. Ramjit, S. (sarg)—United Kingdom

**VP21-04** INTERNET BASED INFORMATION FOR LAPAROENDOSCOPIC SINGLE-SITE SURGERY (LESS) AND NOTES IN UROLOGY

V. Koo, S. Kommu, A. Chakravarti, A. Golash, C. Luscombe, S. (sarg)—United Kingdom

**VP21-05** LAPAROENDOSCOPIC SINGLE-SITE SURGERY (LESS) HOTSPOT TRAINING MODULE IN UROLOGY—A LOW COST APPROACH

S. Kommu, A. Chakravarti, A. Rane, T. Finnigan, A. Golash, C. Luscombe—United Kingdom

**VP21-06** LAPAROENDOSCOPIC SINGLE SITE SURGERY (LESS): INITIAL EXPERIENCE USING CONVENTIONAL DEVICES

J. Diaz, R. Rizzo, A. Pabon, I. Pinto, C. Sandoval, A. Hornig—Chile

**VP21-07** LAPARO-ENDOSCOPIC SINGLE-SITE SURGERY (LESS): INITIAL EXPERIENCE IN RENAL SURGERY

H. Kübler, M. Autenrieth, T. Maurer, J. Gschwend

**VP21-08** LAPAROENDOSCOPIC SINGLE SITE (LESS) DONOR NEPHRECTOMY: MULTI-INSTITUTIONAL EXPERIENCE OF 42 CASES

M. Desai, A. Ganpule, S. Adonian, I. Gill, L. R, L. Richestone

**VP21-09** TRANSUMBILICAL LAPAROENDOSCOPIC SINGLE SITE (LESS) SURGERY IN UROLOGY: INITIAL EXPERIENCE

Y. Bayazit, I. Aridogan, D. Abat, O. Karsli, N. Satar, S. Doran

**VP21-10** EMBRYONIC NATURAL ORIFICE TRANSUMBILICAL ENDOSCOPIC SURGERY (ENOTES) IN UROLOGY USING SILS PORT: INITIAL EXPERIENCE

M. Arslan, T. Degirmenci, M. Yuksel, B. Gunlusoy, S. Minareci, A. Ayder—Turkey

**VP21-11** ROBOTIC ASSISTED RADICAL CYSTECTOMY: ONCOLOGIC AND FUNCTIONAL OUTCOMES AT UP TO 5 YEARS

O. Elhage, B. Challacombe, F. Ismail, P. Rimington, S. Khan, P. Dasgupta

**VP21-12** SINGLE-INCISION UMBILICAL LAPAROSCOPIC NEPHRECTOMY: EARLY EXPERIENCE AT THE UNIVERSITY OF ILLINOIS AT CHICAGO

L. Jones, L. Deane

**VP21-13** SINGLE PORT TRANSUMBILICAL DISMEMBERED PYELOPLASTY

A. Mikhail, A. Figueroa, L. Bryant, K. Tamaddon, J. Yew, G. Chien

**VP21-14** SINGLE-INCISION LAPAROSCOPIC SURGERY IN UROLOGY: RETROPERITONEAL APPROACH

M. Arslan, T. Degirmenci, M. Yuksel, S. Minareci, A. Ayder—Turkey

**VP21-15** PROSPECTIVE COMPARISON OF SINGLE SITE AND TRADITIONAL LAPAROSCOPY FOR UPPER URINARY TRACT SURGERY: INITIAL OUTCOMES

I. Derweesh, W. Bazzi, E. Godebu, J. Silberstein, R. Im, K. Sakamoto

**VP21-16** THE TECHNIQUE AND SKILL IMPROVEMENT OF LAPAROSCOPIC LIVE DONOR NEPHRECTOMY VIA RETROPERITONEAL APPROACH (WITH 150 CASES REPORT)

L. Ma, L. Zhao, X. Hou, G. Wang, K. Hong, Y. Liu

**VP21-17** RETROPERITONEAL LAPAROSCOPIC NEPHRON-SPARING SURGERY FOR RENAL TUMOR (REPORT OF 50 CASES)

L. Ma, Y. Huang, J. Lu, K. Hong, G. Wang, L. Zhao

**VP21-18** LAPAROSCOPIC PARTIAL VS. RADICAL NEPHRECTOMY: COMPARISON OF LONG-TERM FUNCTIONAL OUTCOMES

B. Benway, J. Cabello, S. Bhayani—USA

**VP21-19** RETROPERITONEOSCOPIC DONOR NEPHRECTOMY : OUTCOME OF 500 CASES

P. Modi, J. Rizvi, B. Pal

**VP21-20** INICIAL EXPERIENCE IN UROLOGICAL LAPAROENDOSCOPIC SINGLE-SITE SURGERY (LESS)

Hugo Bermudez, Rodrigo Ledesma, Oscar Storme, Conrado Stein, Mr. Raul Valdeventol, Pablo Bernier—Chile

**VP22: LAPAROSCOPY—ADRENAL AND KIDNEY**

10:30–12:00 hr

**VP22-01** LAPAROSCOPIC ADRENALECTOMY FOR ADRENAL TUMORS LARGER THAN 5 CM: AN OUTCOME ANALYSIS

G. Arvind, R. Sharma, R. Sabnis, V. Muthu, A. Kurien, M. Desai

**VP22-02** SURGICAL OUTCOME OF SIMULTANEOUS LAPAROSCOPIC BILATERAL ADRENALECTOMY IN A SINGLE INSTITUTE

Y. Kawasaki, S. Ishidoya, A. Ito, Y. Arai—Japan

**VP22-03** LAPAROSCOPIC ADRENALECTOMY FOR PHEOCHROMOCYTOMA IN THE PRESENCE OF A HORSESHOE KIDNEY

J. Yates, N. Patel, J. Uberoi, R. Munver—United States

**VP22-04** ROBOTIC-ASSISTED LAPAROSCOPIC PARTIAL ADRENALECTOMY FOR ADRENAL ADENOMAS

J. Yates, J. Uberoi, R. Munver—United States

**VP22-05** LAPAROSCOPIC ADRENALECTOMY—THE INDIAN EXPERIENCE

G. Kumar, S. Bhat—India

**VP22-06** COMPARISON ADRENALECTOMY TECHNIQUES: LATERAL TRANSPERITONEAL AND PRONE RETROPERITONEAL APPROACHES

Z. Okhunov, A. De lorca, D. Lee, J. Lee, J. Landman—United States

**VP22-07** LAPAROSCOPIC ADRENALECTOMY WITH 10MM LIGASURE

G. Simone, S. Guaglianone, R. Papalia, M. Ferriero, E. Forastiere, M. Gallucci

**VP22-08** LAPAROSCOPIC ADRENALECTOMY FOR ADRENOCORTICAL CARCINOMA IN 12 CASES

O. Castillo, I. Vidal-mora, F. Sepulveda, R. Campos, A. Foneron, G. Rubio

**VP22-09** LAPAROSCOPIC TRANSPERITONEAL ADRENALECTOMY: EXPERIENCE IN 308 CASES  
O. Castillo, I. Vidal-mora, R. Campos, G. Rubio, A. Foneron, F. Sepulveda

**VP22-10** LAPAROSCOPIC SYNCHRONOUS BILATERAL ADRENALECTOMY  
A. Foneron, O. Castillo, G. Rubio, I. Vidal-mora, R. Campos, M. Feria-flores—Chile

**VP22-11** BILATERAL PHEOCHROMOCITOMA: BILATERAL SYNCHRONIC LAPAROSCOPIC ADRENALECTOMY IN 9 CASES  
O. Castillo, G. Rubio, I. Vidal-mora, A. Foneron, R. Campos, M. Feria-flores

**VP22-12** LAPAROSCOPIC ADRENALECTOMY FOR SUSPECTED METASTASIS OF THE ADRENAL GLANDS: OUR EXPERIENCE  
A. Foneron, O. Castillo, I. Vidal-mora, R. Campos, G. Rubio, M. Feria-flores—Chile

**VP22-13** IS RETROPERITONEAL LAPAROSCOPIC ADRENALECTOMY SAFE AND EFFECTIVE IN OBESE PATIENTS?  
Y. Hou, C. Wang—China

**VP22-14** THE LARGEST ONE CENTER LAPAROSCOPIC ADRENALECTOMY STUDY FROM TURKEY: TRANSPERITONEAL AND RETROPERITONEAL APPROACHES  
M. Arslan, T. Degirmenci, B. Gunlusoy, S. Minareci, A. Ayder—Turkey

**VP22-15** THE FEASIBILITY OF LAPAROENDOSCOPIC SINGLE-SITE NEPHRECTOMY: INITIAL EXPERIENCE USING HOME-MADE SINGLE-PORT DEVICE  
Y. Park, H. Jeon, W. Han, K. Rha, H. Jeong, H. Kim

**VP22-16** URETERAL COMPLICATIONS IN RECIPIENTS FOLLOWING LIVING LAPAROSCOPIC DONOR NEPHRECTOMY: A FOCUS ON SURGICAL TECHNIQUE  
J. Harper, A. Breda, A. Gritsch, J. Veale, J. Singer, P. Schulam

**VP22-17** CONTEMPORARY EXPERIENCE WITH LAPAROSCOPIC RADICAL NEPHRECTOMY FOR RENAL CORTICAL NEOPLASMS  
M. Rothberg, K. Badani, M. Gupta, J. Mckiernan, J. Landman

**VP22-18** IS XL NONABSORBABLE POLYMER LIGATION CLIP FOR LAPAROSCOPIC RENAL VEIN CONTROL THE SAFER?  
M. Arslan, E. Aksoy, S. Minareci, A. Ayder—Turkey

**VP22-19** REGISTRATIONS FOR IMAGE-GUIDED MINIMALLY INVASIVE KIDNEY SURGERY  
H. Altamar, R. Galloway, R. Ong, C. Glisson, S. Herrell—USA

**VP22-20** MULTICENTER COMPARISON OF INTERMEDIATE ONCOLOGIC OUTCOMES OF LAPAROSCOPIC PARTIAL NEPHRECTOMY AND RENAL CRYOABLATION  
S. Stroup, J. Malcolm, J. L'esperance, R. Wake, M. Fabrizio, I. Derweesh

**VS14: ROBOTIC—PROSTATE**  
10:30–12:00 hr

**VS14-01** TECHNIQUES FOR POTENCY PRESERVATION DURING ROBOTIC-ASSISTED RADICAL PROSTATECTOMY (RALP)—VIDEO  
K. J. Palmer, R. Ferreira coelho, S. Chauhan, B. Rocco, M. B. Patel, V. Patel—US

**VS14-02** MODIFIED POSTERIOR RECONSTRUCTION OF THE RHABDOSPHINCTER: APPLICATION TO ROBOTIC ASSISTED LAPAROSCOPIC PROSTATECTOMY (VIDEO)  
B. Rocco, R. Ferreira coelho, K. J. Palmer, S. Chauhan, V. Patel, G. Coughlin

**VS14-03** ROBOTIC-ASSISTED LAPAROSCOPIC RADICAL PROSTATECTOMY: TIPS AND TRICKS  
K. J. palmer, S. Chauhan, R. Ferreira coelho, B. Rocco, G. Coughlin, V. Patel—US

**VS14-04** MANAGEMENT OF A LARGE MEDIAN LOBE DURING ROBOT ASSISTED RADICAL PROSTATECTOMY  
R. Dickstein, A. Weinberg, D. Wang, R. Babayan—USA

**VS14-05** DOUBLE PIG-TAIL STENTING OF THE URETERS: TECHNIQUE FOR SECURING THE URETERAL ORIFICES DURING ROBOTIC-ASSISTED RADICAL PROSTATECTOMY FOR LARGE MEDIAN LOBES  
Y. El douaihy

**VS14-06** PRESERVATION OF ACCESSORY PUDENDAL ARTERY IN ROBOT ASSISTED LAPAROSCOPIC RADICAL PROSTATECTOMY OPERATION  
A. Kural, F. Atug, I. Tufek, H. Akpınar, S. Aksit—Turkey

**VS14-07** TENSION- AND ENERGY-FREE ROBOTIC ASSISTED LAPAROSCOPIC RADICAL PROSTATECTOMY: APPLICATION DURING THE LEARNING CURVE  
F. Annino, A. Beato, C. De carne, S. Micali, S. De stefani, G. Bianchi

**VS14-08** TECHNIQUE OF ROBOTIC-ASSISTED LAPAROSCOPIC SIMPLE PROSTATECTOMY (VIDEO)  
V. Patel, R. Ferreira coelho, K. J. Palmer, S. Chauhan, M. B. Patel—US

**VS14-09** ROBOT-ASSISTED EXCISION OF A MULLERIAN CYST WITH ANASTOMOSIS OF THE VAS DEFERENS TO THE SEMINAL VESICLE

R. Sotelo, R. De andrade, O. Carmona, J. Astigueta, O. Moreira—Venezuela

**05: UPPER URINARY TRACT**

12:00–13:00 hr

**05-01** EXTRACORPOREAL SHOCK WAVE LITHOTRIpsy (ESWL) IN THE MANAGEMENT OF INFANT UROLITHIASIS

M. Dönmez, O. Kaygisiz, S. Tekgöl—Turkey

**05-02** EXPERIENCE IN PERCUTANEOUS NEPHROLITHOTOMY IN 47 INFANTS WITH MELAMINE-RELATED UPPER URINARY CALCULI

J. Li, W. Hu, B. Yang, X. Huang, X. Wang—China

**05-03** SUPINE VS PRONE PERCUTANEOUS NEPHROLITHOTRIpsy (PCNL): A RETROSPECTIVE ANALYSIS ON 65 PROCEDURES

U. Anceschi, C. Molinari, C. Anceschi, M. Gallucci

**05-04** PERCUTANEOUS NEPHROLITHOTOMY (PCNL) UNDER SPINAL ANESTHESIA (SA) WITH MARCAINE

S. Rabani—Iran

**05-05** MINIMAL INVASIVE PCNL IN THE TREATMENT OF NEPHROLITHIASIS – ANALYSIS OF EFFICIENCY AND MORBIDITY AFTER 443 CONSECUTIVE PATIENTS. DEPARTMENT OF UROLOGY, SILOAH ST. TRUDPERT HOSPITAL, PFORZHEIM, GERMANY

V. Zimmermanns, P. Liske, C. Hofmann, S. Lahme

**05-06** MULTI TRACT TUBELESS MINIMAL INVASIVE PNL (MIP) WITH HAEMOSTATIC GELATINE MATRIX SEALANTS IN STAGHORN STONES

T. Herrmann, D. Schilling, F. Imkamp, C. Von klot, U. Walcher, U. Nagele—Germany

**05-07** OUTCOME OF PERCUTANEOUS MANAGEMENT OF STAGHORN CALCULI: CAN ACCESS NUMBER BE PREDICTED?

T. Akman, E. Sari, M. Binbay, E. Yuruk, A. Muslumanoglu, A. Tefekli—Turkey

**05-08** PERCUTANEOUS NEPHROLITHOTOMY IN AUTOSOMAL DOMINANT POLYCYSTIC KIDNEY DISEASE PATIENTS; THE HIGHEST EFFECT, THE LEAST MORBIDITY

M. Khorrami, M. Sarrafian, K. Nouri mahdavi, F. Tadaion, F. Farahini isfahani

**05-09** PERCUTANEOUS NEPHROLITHOTOMY IN HORSESHOE KIDNEYS: FACTORS AFFECTING STONE-FREE RATES

A. Skolarikos, A. Tefekli, A. Bisas, M. Binbay, A. Muslumanoglu, C. Deliveliotis—Turkey

**05-10** THE ROLE OF FLEXIBLE URETERORENOSCOPY WITH HOLMIUM LASER IN TREATING RENAL STONE MORE THAN 2 CM: NEW ERA

S. Alqahtani, D. Legraverand, M. Ndoye, J. Rode, B. Merlet, O. Traxer—France

**06: BLADDER AND PROSTATE CANCER**

12:00–13:00 hr

**06-01** IN BLOC LAPAROSCOPIC RADICAL CYSTECTOMY AND NEPHROURETERECTOMY FOR UPPER AND LOWER TRANSITIONAL TUMORS

O. Castillo, I. Vidal-mora, A. Foneron, R. Campos, G. Rubio, F. Sepulveda

**06-02** LAPAROSCOPIC RADICAL CYSTECTOMY WITH EXTRACORPOREALLY ILEAL Y-SHAPED ORTHOTOPIC NEOBLADDER CONSTRUCTED WITH NONABSORBABLE MECHANICS SUTURE: OUR INITIAL EXPERIENCE

O. Castillo, R. Campos, I. Vidal-mora, A. Foneron, G. Rubio, M. Feria-flores

**06-03** IS STRICT PERIOPERATIVE BOWEL MANAGEMENT IN LAPAROSCOPIC SURGERY FOR UPPER ABDOMINAL CAVITY IMPORTANT?

H. Yanaihara, H. Sakamoto, M. Matsushima, M. Horinaga, Y. Nakahira, H. Asakura—Japan

**06-04** ONCOLOGIC RESULTS FOR EXTRAPERITONEAL VERSUS TRANSPERITONEAL RADICAL PROSTATECTOMY

R. Sanchez-salas, F. Bianco, X. Cathelineau, F. Rozet, E. Barret, G. Vallancien—France

**06-05** INTERMEDIATE TO LONG-TERM ONCOLOGIC OUTCOME FOLLOWING LAPAROSCOPIC RADICAL PROSTATECTOMY FOR CLINICALLY LOCALIZED PROSTATE CANCER

A. Mortezaei, M. Baumgartner, T. Hermanns, T. Sulser, H. Seifert

**06-06** PROSPECTIVE RANDOMIZED TRIAL TO EVALUATE THE INFLUENCE OF THE BLADDER NECK SUSPENSION ON EARLY CONTINENCE AFTER RADICAL PROSTATECTOMY

J. Stolzenburg, M. Nicolaus, M. Do, A. Dietel, E. Liatsikos

**06-07** PERI-CATHETER PAD USE IMMEDIATELY POST-OP AS A NOVEL PREDICTOR OF EARLY RETURN OF URINARY CONTINENCE AFTER ROBOTIC PROSTATECTOMY

D. Lee, P. Cheetham, M. Truesdale, K. Badani—USA

**O6-08** NEOADJUVANT ANDROGEN SUPPRESSION IN HIGH INTENSITY FOCUSED ULTRASOUND THERAPY FOR LOCALIZED PROSTATE CANCER  
W. Kim, S. Jeon, J. Choi, H. Kim, B. Jeong, S. Seo

**O6-09** THE SECOND STEP IN VITRO TRIAL OF ANKAFERD BLOODSTOPPER: COMPARISON WITH THE OTHER HEMOSTATIC AGENTS, GLUBRAN 2, FLOSEAL AND CELOX  
E. Huri, T. Akgül, O. Yucel, M. Astarci, H. Üstün, C. Germiyanoglu—Turkey

**O6-10** NEPHROSTOMY FOR MALIGNANT URINARY TRACT OBSTRUCTION. IS IT WORTH IT?  
R. Jordan, H. Mohd tarmidzi, S. Mohan, K. Subramonian—UK

**VP23: ENDOSCOPY**

12:00–13:00 hr

**VP23-01** BIPOLAR TRANSURETHRAL RESECTION IN SALINE OF BLADDER CANCER: OUTCOME AND COMPLICATION RATES AFTER THE FIRST 480 CASES  
P. Puppo, C. Introiini, F. Germinale, F. Bertolotto, A. Naselli—Italy

**VP23-02** THE EFFICACY OF PLASMAKINETIC ENERGY IN TRANSURETHRAL RESECTION OF BLADDER TUMOUR: THE MIDTERM REPORT OF SERIES  
E. Huri, T. Akgül, S. Özcan, C. Germiyanoglu—Turkey

**VP23-03** ENDOSCOPIC MANAGEMENT OF UPPER-TRACT TRANSITIONAL-CELL CARCINOMA  
S. Martin martin, J. Torrecilla garcia-ripoll, F. Trueba arguiñarena, R. Calvo gonzalez, E. Valseo herguedas, E. Fernandez del busto

**VP23-04** TIPS FOR INTRACORPOREAL PLACEMENT OF URETERAL STENTS  
J. Marshall, A. Cardin, H. Rashid, G. Wu

**VP23-05** ENDOPYELOTOMY: A PROSPECTIVE ANALYSIS OF LONG TERM EFFICACY  
V. Ramakrishnan, J. Murugesan, S. Ramamurthy, A. Ganapathy, K. Kailasam

**VP23-06** BALLOON DILATATION OF URETHRAL STRICTURES VIA FLEXIBLE CYSTOSCOPES  
G. Watson, R. Ali—UK

**VP23-07** LOCALIZED PRIMARY AMYLOIDOSIS OF THE LOWER URINARY TRACT  
A. Mathew, A. Kurien, R. Sabnis, M. Desai

**VP23-08** ANTEGRAD BALLOON DILATATION IN THE TREATMENT OF URETEROVESICAL STENOSIS IN PATIENT WITH PREVIOUSLY UNDERGONE URETEROCUTANEOSTOMY AND URETERAL STENOSIS DUE TO UNSPECIFIED ETIOLOGIES  
L. Tahmaz, M. Zor, S. Bedir, S. Basal, I. Karabuga, M. Dayanc

**VP23-09** SAFE RESECTION OF BLADDER TUMORS WITH PLASMA KINETIC ENERGY  
I. Yildirim, S. Basal, H. Irkilata, M. Zor, S. Goktas, M. Dayanc

**VP23-10** THE EFFICACY AND SAFETY OF THE BART'S MODIFIED VALDIVIA POSITION FOR SIMULTANEOUS ANTEROGRADE AND RETROGRADE URINARY TRACT ACCESS  
K. Moraitis, Z. Maan, T. El-husseiny, A. Papatsoris, J. Masood, N. Buchholz

**VP23-11** BLADDER SPHINCTER VERGE URETHRAL PRESSURE AND IMPACT ON PAIN SCORES IN MEN UNDERGOING FLEXIBLE CYSTOSCOPY  
S. Kommu, A. Golash, C. Luscombe, S. Liu, M. Saxby, J. Emtage—United Kingdom

**VP23-12** FLEXIBLE CYSTOSCOPIC AIDED MINIBALLOON TISSUE DISSECTION—PRELIMINARY EXPERIENCE IN EX VIVO SETTING USING A LAPAROENDOSCOPIC SINGLE-SITE SURGERY (LESS) PLATFORM  
S. Kommu, I. Lewis, A. Forde, I. Persad, C. Ramjit, S. (sarg)—United Kingdom

**VP23-13** ENDOUROLOGIC MANAGEMENT OF SEVERELY ENCRUSTED RETAINED URETERAL STENTS  
K. Skrepetis, G. Stathouros, I. Efthimiou, E. Trimis, I. Gialas

**VP24: PEDIATRICS**

12:00–13:00 hr

**VP24-01** RETROGRADE URETERAL ACCESS AFTER CROSS-TRIGONAL URETERAL REIMPLANTATION: A STRAIGHTFOWARD TECHNIQUE  
J. Palmer, K. Hubert, R. De castro—USA

**VP24-02** GIANT URETERAL FIBROEPITHELIAL POLYP CAUSING BLADDER OUTLET OBSTRUCTION  
A. Chawla, P. Noh

**VP24-03** THE VALIDITY OF THE PRACTICAL APPLICATION OF U-LESS (UMBILICAL LAPARO-ENDOSCOPIC SINGLE PORT SURGERY) VARICOCECTOMY FOR PATIENTS WHO HAVE BILATERAL VARICOCELE  
S. Park, J. Nam, T. Kim, W. Lee, H. Park

**VP24-04** TRANSUMBILICAL LAPAROENDOSCOPIC SINGLE-SITE NEPHROURETERECTOMY IN A CHILD  
Y. Bayazit, I. Aridogan, D. Abat, N. Satar, S. Doran

**VP24-05** LONG TERM RESULTS OF ENDOSKOPIC SUBURETERAL INJECTION FOR THE TREATMENT OF VESICoureTERAL REFLUX IN CHILDREN—POLYDIMETHYLSILOXAN VS DEXTRANOMER/HYALORONIC ACID COPOLYMER  
A. Lusch, F. Wezel, W. Shah, M. Riccabona, M. Michel

**VP24-06** URETEROSCOPY AND PNEUMATIC LITHOTRIPSY IN TREATMENT OF URETERAL CALCULI IN CHILDREN

M. Tan, U. Karaoglan, S. Sozen, H. Biri, N. Deniz, I. Bozkirli—Turkey

**VP24-07** TRANSUMBILICAL LAPAROENDOSCOPIC SINGLE-SITE (LESS) NEPHRECTOMY IN A CHILD WITH CALCULOUS PYONEPHROSIS

Y. Bayazit, I. Aridogan, D. Abat, O. Karsli, N. Satar, S. Doran

**VP24-08** LAPAROSCOPIC DIAGNOSIS AND TREATMENT OF CRYPTORCHIDISM

M. Baptistussi, M. Morihisa, E. Gewher, A. Martins—Brasil

**VP24-09** URETEROSCOPY IN INFANTS AND YOUNG CHILDREN: INDICATIONS AND OUTCOMES

M. Baptistussi, M. Morihisa, E. Gewher, A. Martins—Brasil

**VP24-10** LAPAROSCOPIC CORRECTION OF VESICoureteral REFLUX: EXPERIENCE IN 42 PEDIATRIC PATIENTS

I. Vidal-mora, O. Castillo, R. Campos, G. Rubio, A. Foneron, F. Sepúlveda, F. Sepúlveda

**VP24-11** LAPAROSCOPIC MANAGEMENT OF THE ADULT NONPALPABLE TESTICLE

I. Yildirim, S. Basal, H. Irkilata, M. Zor, E. Oral, M. Dayanc

**VP24-12** APPLICATION OF LAPAROSCOPIC SURGERY IN UROLOGY(A REPORT OF 110 CASES)

X. Hanbiao, Y. Haichao, T. Shengping, Y. Weizhong—China

**MP17: ROBOTICS—KIDNEY**

14:00–15:30 hr

**MP17-01** ROBOTIC KIDNEY SURGERY IN PATIENTS WITH PREVIOUS ABDOMINAL SURGERY: FEASIBILITY AND PERIOPERATIVE OUTCOMES

M. Patel, A. Bhandari, E. Kheterpal, A. Pichurko, M. Menon, C. Rogers—USA

**MP17-02** ROBOTIC PARTIAL NEPHRECTOMY FOR RENAL TUMORS GREATER THAN 4 CM

M. Patel, R. Laungani, A. Shrivastava, E. Kheterpal, M. Menon, C. Rogers

**MP17-03** ROBOTIC LAPAROENDOSCOPIC SINGLE SITE SURGERY USING GELPORT AS THE ACCESS PLATFORM

R. Stein, W. White, R. Goel, B. Irwin, G. Haber, J. Kaouk

**MP17-04** DOES TRAINING ON A VIRTUAL REALITY ROBOTIC SIMULATOR IMPROVE PERFORMANCE ON THE DAVINCI SURGICAL SYSTEM?

M. Lerner, M. Ayalew, S. Lucas, W. Peine, C. Sundaram—USA

**MP17-05** INITIAL EXPERIENCE WITH ROBOT-ASSISTED NEPHRECTOMIES: COMPARISON WITH LAPAROSCOPIC AND HAND-ASSISTED LAPAROSCOPIC APPROACHES

M. Lerner, S. Popp, T. Gardner, C. Sundaram—USA

**MP17-06** ROBOT-ASSISTED LAPAROSCOPIC PARTIAL NEPHRECTOMY PRACTICE PATTERNS: THE DA VINCI™ SURGICAL SYSTEM FACILITATES ADOPTION OF MINIMALLY INVASIVE PARTIAL NEPHRECTOMY

R. Munver, J. Uberoi, J. Yates—United States

**MP17-07** ROBOTIC OR MANUAL GUIDED HIGH INTENSITY FOCUSED ULTRASOUND?

S. Thueroff, A. Neumayr, H. Kiel, C. Chaussy

**MP17-08** COMPARISON OF ROBOTIC-ASSISTED VERSUS CONVENTIONAL LAPAROSCOPIC PYELOPLASTY FOR PATIENTS WITH URETEROPELVIC JUNCTION OBSTRUCTION: A SINGLE CENTER STUDY BY TWO SURGEONS

R. Leveillee, J. Bracho ii, M. Aziz, V. Bird

**MP17-09** CONTRASTING THE DAVINCI SI AND THE DAVINCI S ROBOT SURGICAL SYSTEMS: WHAT IS NEW?

C. Wong, K. Strom, M. Spaliviero—USA

**MP17-10** COMPLICATIONS OF ROBOT-ASSISTED PARTIAL NEPHRECTOMY: THE LEARNING CURVE FOR ADOPTION OF A NEW TECHNOLOGY

R. Munver, J. Yates, J. Uberoi—United States

**MP17-11** ROBOTIC PARTIAL NEPHRECTOMY: CUMULATIVE SINGLE CENTER EXPERIENCE

W. White, G. Haber, R. Goel, S. Crouzet, J. Kaouk

**MP17-12** EARLY RESULTS OF ROBOTIC LYMPHADENECTOMY FOR RENAL CELL CARCINOMA: INITIAL PATIENT SERIES

R. Abaza—USA

**MP17-13** INITIAL SERIES OF ROBOTIC NEPHRECTOMY WITH VENA CAVAL TUMOR THROMBECTOMY

R. Abaza—USA

**MP17-14** ROBOT-ASSISTED PARTIAL NEPHRECTOMY FOR RENAL CELL CARCINOMA: COMPARISON OF SURGICAL OUTCOME WITH LAPAROSCOPIC PARTIAL NEPHRECTOMY

T. Kang, C. Song, J. Hong, H. Ahn—Korea

**MP17-15** COMPARISON OF SURGICAL OUTCOMES OF OPEN, LAPAROSCOPIC, AND ROBOTIC PARTIAL NEPHRECTOMY

U. Boylu, M. Pinsky, A. Tracey, M. Hopkins, R. Thomas, B. Lee—USA

**MP17-16** COMPARISON OF THE RENAL FUNCTIONS AFTER OPEN, LAPAROSCOPIC, AND ROBOTIC PARTIAL NEPHRECTOMY  
U. Boylu, M. Pinsky, M. Hopkins, A. Tracey, B. Lee—USA

**MP17-17** MARGIN ANALYSIS OF ROBOT ASSISTED PARTIAL NEPHRECTOMY AND LAPAROSCOPIC PARTIAL NEPHRECTOMY  
A. Wang, S. Bhayani—USA

**MP17-18** COMPARISON OF LAPAROSCOPIC VERSUS ROBOTIC ASSISTED PARTIAL NEPHRECTOMY: ONE SURGEONS EARLY EXPERIENCE  
J. Mandeville, J. Delong, A. Moinzadeh—USA

**MP17-19** CLINICAL PATHWAY FOR DISCHARGE ON POSTOPERATIVE DAY ONE AFTER ROBOTIC PARTIAL NEPHRECTOMY  
R. Abaza—USA

**MP17-20** NON-CLAMPING VERSUS RENAL HILAR CLAMPING ROBOTIC AND LAPAROSCOPIC PARTIAL NEPHRECTOMY  
S. Parekattil, Sijo j., H. Atalah, L. Su

**MP18: MISCELLANEOUS**  
14:00–15:30 hr

**MP18-01** INHIBITORY EFFECT OF TOTAL EXTRACT OF SAFFRON ON CELL LINE OF ADENOCARCINOMA OF THE KIDNEY  
H. Ahmadnia, J. Tavakol afshari, A. Yarmohamadi, A. Malaekhe ghochani, A. Borok—Iran

**MP18-02** A PROSPECTIVE STUDY OF THE EFFICACY AND TOLERABILITY OF AMBULATORY HOLMIUM LASER ABLATION OF RECURRENT NON-MUSCLE-INVASIVE TRANSITIONAL CELL CARCINOMA WITH FLEXIBLE CYSTOSCOPE UNDER LOCAL ANAESTHESIA  
D. Macdonald, R. Jones, H. Syed—United Kingdom

**MP18-03** BILATERAL SINGLE-STAGE LAPAROSCOPIC ADRENALECTOMY IN CUSHING'S SYNDROME-SAFE, EFFECTIVE AND CURATIVE  
S. Bhat, G. Kumar—India

**MP18-04** ENHANCED "TUMOR PERFUSION" DOES NOT TRANSLATE INTO INCREASED FREEZE TIME DURING PERCUTANEOUS CT-GUIDED RENAL CRYOTHERAPY  
P. Sountoulides, M. Louie, D. Pick, S. Said, E. Mcdougall, R. Clayman—CA

**MP18-05** SECONDARY VESICAL AMYLOIDOSIS—RARE CAUSE OF MASSIVE HEMATURIA  
S. Pereira, D. Martinho, M. Melo, A. Romão, T. Leitão, H. Correia—Portugal

**MP18-06** MEN II SYNDROME: A DANGEROUS COMBINATION OF RARE DISEASES  
G. Kumar, S. Bhat—India

**MP18-07** LOCAL ANAESTHETIC HOLMIUM LASER ABLATION OF SUPERFICIAL TRANSITIONAL CELL TUMOUR RECURRENCES IN PATIENTS WITH SIGNIFICANT CO-MORBIDITY  
D. Wilby, G. Zisengwe, N. Smith, K. Thomas—UK

**MP18-08** PRELIMINARY INVESTIGATIONS WITH IRREVERSIBLE ELECTROPORATION IN IN-VIVO PORCINE KIDNEYS FOR RENAL TUMOR TREATMENT  
R. Leveillee, N. Salas, C. Moore, M. Jorda, M. Sierra, J. Shields—33136

**MP18-09** COMPARISON OF THE ROBOTIC CAMERA HOLDER FREEHAND® TO THE CONVENTIONAL IMAGING AT THE NERVE SPARING ENDOSCOPIC EXTRAPERITONEAL RADICAL PROSTATECTOMY (NSEERPE)—A PROSPECTIVE STUDY WITH 50 CASES  
J. Stolzenburg, T. Franz, K. Turner, M. Do, P. Kallidonis, E. Liatsikos

**MP18-10** BIOIMPEDANCE BODY COMPOSITION ANALYSIS PREDICTS HISTOPATHOLOGY OF SMALL RENAL CORTICAL NEOPLASMS  
J. Rosales araujo, J. Moreno, G. Haramis, Z. Okhunov, K. Badani, J. Landman—USA

**MP18-11** EVALUATION OF APPLIED LAPAROSCOPIC UROLOGY COURSE USING VALIDATED CHECKLIST  
S. Guven, C. Gurbuz, A. Gözen, L. Tunc, F. Saracoglu, Y. Ozgok

**MP18-13** DOES THE PRESENCE OF ROBOTIC SURGERY AFFECT DEMOGRAPHICS IN PATIENTS CHOOSING TO UNDERGO RADICAL PROSTATECTOMY? A MULTI-CENTER CONTEMPORARY ANALYSIS  
P. Cheetham, D. Lee, S. Brewster, M. Truesdale, K. Badani—USA

**MP18-14** CHARACTERIZATION OF RENAL ISCHEMIA USING DLP® HYPERSPECTRAL IMAGING: A COMPARISON OF ARTERY-ONLY OCCLUSION (AO) VERSUS ARTERY AND VEIN OCCLUSION (AV)  
C. Tracy, R. Francis, E. Wehner, J. Smith, J. Cadeddu, K. Zuzak—USA

**MP18-15** THE USE OF SPRAYED TISSEEL (FIBRINOGEN, APROTININ AND THROMBIN) AS THE SOLE HEMOSTATIC AGENT IN PORCINE LAPAROSCOPIC PARTIAL NEPHRECTOMY  
D. Pick, S. Kolla, M. Louie, J. Tongson-ignacio, E. Mcdougall, R. Clayman—CA



**MP18-16** LAPAROENDOSCOPIC SINGLE-SITE (LESS) VERSUS CONVENTIONAL LAPAROSCOPIC DONOR NEPHRECTOMY

S. Rais-bahrami, A. Herati, M. Atalla, S. Andonian, L. Richstone, L. Kavoussi—USA

**MP18-17** EXTREMELY LARGE PROSTATE SIZE MATTERS FOR FUNCTIONAL OUTCOMES FOLLOWING ROBOTIC ASSISTED RADICAL PROSTATECTOMY

T. Skolarus, S. Zhang, B. Hollenbeck

**MP18-18** THE USE OF PATIENT-CONTROLLED ANALGESIA AT 60 VERSE 120 SHOCKS PER MINUTS IN EXTRACORPORPOERAL SHOCK WAVE LITHOTRIPSY

A. Lo, N. Lee, C. Ng

**MP18-19** WHAT ABOUT THE QUALITY OF RANDOMIZED CLINICAL TRIALS PRESENTED AT THE WCE MEETING?

R. Autorino, M. De sio, R. Stein, C. Quattrone, D. Sorrentino, J. Kaouk—USA

**MP18-20** CONTINUOUS PROCEDURE BASED ASSESSMENT: FROM SURGICAL TRAINING TO LEARNING TO BE A SURGEON IN THE NEW ERA OF THE EUROPEAN WORKING TIME DIRECTIVE

C. Brown, D. Sharma, C. Kouriefs, A. Haq, H. Patel, P. Grange—UK

**MP19: LAPAROSCOPY AND ROBOTICS—UPPER URINARY TRACT**

14:00–15:30 hr

**MP19-01** PARALLEL INCISION EXTRAVESICAL REIMPLANTATION IN LAPAROSCOPIC ROBOTIC-ASSISTED URINARY RECONSTRUCTION—THE “BARRY/MITCHELL” REIMPLANT

J. Sumfest

**MP19-02** ROBOTIC ASSISTED LAPAROSCOPIC DISMEMBERED PYELOPLASTY (RALDP) FOR PRIMARY AND SECONDARY URETEROPELVIC JUNCTION OBSTRUCTION (UJO): A MULTI-INSTITUTIONAL EXPERIENCE

M. B. Patel, R. Ferreira coelho, R. Munver, V. Bird, R. Leveilee, V. Patel—US

**MP19-03** PREDICTORS OF OUTCOME OF URETEROPELVIC JUNCTION OBSTRUCTION (UPJO) FOLLOWING MINIMALLY INVASIVE RECONSTRUCTION BASED ON PERIOPERATIVE CHARACTERISTICS

A. Goh, M. Kim, R. Link—USA

**MP19-04** PERIOPERATIVE OUTCOMES OF LAPAROSCOPIC AND ROBOTIC SINGLE PORT SURGERY

R. Goel, W. White, G. Haber, S. Crouzet, R. Stein, J. Kaouk

**MP19-05** HOW USEFUL IS CLAVIEN CLASSIFICATION SYSTEM IN ENDOSCOPIC RESECTION OF PROSTATIC ADENOMA?

I. Efthimiou, S. Kazoulis, G. Chrisanthacopoulos, G. Skrepetis, I. Christoulakis—Greece

**MP19-06** COMPARISON OF SURGICAL APPROACHES TO URETEROPELVIC JUNCTION OBSTRUCTION: PERCUTANEOUS ENDOPYELOTOMY VERSUS OPEN DISMEMBERED PYELOPLASTY

A. Unsal, C. Kara, M. Bayindir, B. Resorlu—Turkey

**MP19-07** THE SURGICAL STRATEGY FOR THE IATROGENIC URETERAL TRAUMA COMPLICATING UPPER TRACT OBSTRUCTION

J. Pan, W. Xue, H. Chen, Q. Chen, Y. Chen, Y. Huang

**MP19-08** INFLUENCE OF PROLONGED URETERAL STENT DRAINAGE OF THE UPPER URINARY TRACT ON RENAL FUNCTIONAL CAPACITY

A. Chepurov, S. Zenkov, I. Mamaev, E. Pronkin

**MP19-09** ROBOTIC VERSUS OPEN URETERAL REIMPLANTATION FOR DISTAL URETER BENIGN STRICTURE DISEASE

S. Kozinn, J. Mandeville, K. Hamawy, A. Sorcini, D. Canes, A. Moinzadeh—USA

**MP19-10** EARLY EXPERIENCE OF ROBOT-ASSISTED LAPAROSCOPIC PYELOPLASTY

J. Lee, I. Seo, D. Han, J. Rim, I. Mun, Y. Chae—Korea

**MP19-11** RETROGRADE BALLON DILATATION OF PELVI-URETERIC OBSTRUCTION IN PATIENTS WITH IMPAIRED GENERAL CONDITION

K. Skrepetis, K. Tzelepis, I. Efthimiou, G. Stathouros, P. Kalomiris—Greece

**MP19-12** ANATOMICAL KNOWLEDGE ACQUISITION TRAINING MODULE BASED ON ROBOT ASSISTED RADICAL PROSTATECTOMY

S. Kommu, Z. Hashim, C. Eden, A. Golash, C. Luscombe, S. (sarg)—United Kingdom

**MP19-13** DOSE THE EARLY LIGATION OF THE URETER DURING SURGERY REDUCE THE RISK OF BLADDER RECURRENCE AFTER NEPHROURETERECTOMY FOR UPPER TRACT TRANSITIONAL CELL CARCINOMA?

Y. Kobayashi, T. Saika, S. Uehara, T. Watanabe, Y. Nasu, H. Kumon

**MP19-14** THE USE OF ENDOPROSTHESIS IN THE MANAGEMENT OF IATROGENIC URETERIC STRICTURES OR FISTULA CAUSED BY SURGERY COMPLICATIONS

J. Torrecilla garcía-ripoll, S. Martín martín, J. Trueba arguiñarena, S. Alonso menéndez, M. López pedreira, E. Fernández del busto—Spain

**MP19-16** COMPARISON OF OPTICAL RESOLUTION WITH DIGITAL AND STANDARD FIBEROPTIC URETERORENOSCOPES IN AN IN VITRO MODEL

K. Nutahara, T. Shishido, T. Okegawa, E. Higashihara—Japan

**MP19-17** BIPOLAR PERCUTANEOUS RESECTION OF RENAL CYSTS AND CALYCEAL DIVERTICULA: AN INTERMEDIATE-TERM ANALYSIS

R. Korets, M. Lee, K. Xavier, M. Gupta—USA

**MP19-19** THE FACTORS AFFECTING NON-UROLOGIC POSTOPERATIVE COMPLICATIONS AFTER A LAPAROSCOPIC SURGERY IN UROLOGIC AREA

J. Lee, S. Lee, H. Lee, J. Kim, S. Jeon

**MP19-20** COMPARISON OF MALIGNANCY IN COMPLEX CYSTIC VERSUS SOLID SMALL RENAL MASSES

V. Ta, S. Wu, D. Rebuck, K. Perry, N. Smith, R. Nadler

**MP19-21** CORRELATION OF GFR TO NEPHRON LOSS IN LIVING RENAL DONORS

J. Page, S. Strup—USA

**MP19-22** HISTOTRIPTY OF RENAL VX-2 TUMOR IN A RABBIT MODEL: FEASIBILITY

J. Wheat, T. Hall, K. Wojno, C. Cain, W. Roberts—USA

**MP20: LAPAROSCOPIC—KIDNEY 2**

14:00–15:30 hr

**MP20-01** MICROPARTICULATE ICE SLURRY FOR RENAL HYPOTHERMIA: LAPAROSCOPIC PARTIAL NEPHRECTOMY IN A PORCINE MODEL

S. Shikanov, M. Wille, M. Large, A. Razmaria, D. Lifshitz, A. Shalhav—USA

**MP20-02** EXTRAPERITONEAL LAPAROSCOPIC RETROPERITONEAL RADICAL LYMPHADENECTOMY IN 3 CASES

Y. Changjun

**MP20-03** RISK FACTORS FOR PERSISTENT HYPERTENSION AFTER LAPAROSCOPIC ADRENALECTOMY IN PATIENTS WITH ALDOSTERONE PRODUCING ADENOMA

T. Kwon, T. Kim, E. Yoo, Y. Park, J. Kim, H. Kim—Korea

**MP20-04** IMPACT OF LYMPH NODE DISSECTION ON DISEASE-FREE SURVIVAL IN PATIENTS WITH UROTHELIAL CARCINOMA OF THE RENAL PELVIS; COMPARISON BETWEEN LAPAROSCOPIC AND OPEN SURGERY

Y. Matsukawa, R. Hattori, Y. Yoshino, O. Kamihira, T. Kinukawa, M. Gotoh

**MP20-05** SIMULTANEOUS TRANSPERITONEAL AND RETROPERITONEAL HAND-ASSISTED LAPAROSCOPIC NEPHROURETERECTOMY WITH BLADDER CUFF EXCISION

S. Jung, M. Gil, S. Kim, J. Ha, S. Yoon, J. Chung—South Korea

**MP20-06** LAPAROSCOPIC LYMPHADENECTOMY FOR NODAL RECURRENCE FOLLOWING RADICAL PROSTATECTOMY: THE ROLE OF INTEGRATED 18F-CHOLINE PET-CT

G. Simone, R. Papalia, S. Guaglianone, A. Bove, E. Forastiere, M. Gallucci

**MP20-07** FACTORS AFFECTING BLOOD LOSS DURING PARTIAL NEPHRECTOMY

U. Boylu, A. Tracey, M. Pinsky, M. Hopkins, R. Thomas, B. Lee—USA

**MP20-08** CONTEMPORARY SURGICAL MANAGEMENT AND RESULTS OF EXTRA-ADRENAL PHEOCHROMOCYTOMA: THE ROLE OF OPEN AND LAPAROSCOPIC APPROACHES

E. Metrebian, T. Pinheiro, F. Lima, F. Messetti, V. Ortiz, C. Andreoni

**MP20-09** ONCOLOGIC OUTCOMES OF SURGICAL MARGIN POSITIVE PATIENTS FOLLOWING PARTIAL NEPHRECTOMY

M. Pinsky, U. Boylu, A. Tracey, M. Hopkins, B. Lee—USA

**MP20-10** COMPARISON OF LAPAROSCOPIC AND OPEN PARTIAL NEPHRECTOMY IN T1A RENAL CELL CARCINOMAS: A MULTICENTER ANALYSIS IN KOREA

S. Byun, S. Kang, T. Kwon, I. Seo, T. Hwang, K. Rha

**MP20-11** EVALUATION ROBOTIC-ASSISTED LAPAROSCOPIC ADRENALECTOMY: OUR FIRST EXPERIENCE OF 10 PATIENTS

L. Yong seong, S. Ha jeong, C. Sang hoon, L. Young goo

**MP20-12** EVALUATION OF THE SAFETY OF PERIOPERATIVE ENOXAPARIN ADMINISTRATION IN PATIENTS UNDERGOING ROBOTIC-ASSISTED LAPAROSCOPIC RADICAL PROSTATECTOMY

J. Yates, J. Uberoi, I. Sawczuk, D. Golombos, M. Gross, R. Munver—United States

**MP20-13** DELAYED HEMORRHAGE AFTER LAPAROSCOPIC PARTIAL NEPHRECTOMY: FREQUENCY AND ANGIOGRAPHIC FINDINGS

S. Montag, C. Seideman, A. Rastinehad, M. Vira, L. Richstone, L. Kavoussi

**MP20-14** EARLY EXPERIENCE WITH LAPAROSCOPIC SURGERY OF TWO YOUNG UROLOGISTS  
F. Vicentini, M. Hisano—Brazil

**MP20-15** PERIOPERATIVE AND ONCOLOGICAL EVALUATION OF 4 DIFFERENT APPROACHES FOR RADICAL PROSTATECTOMY: PERINEAL, OPEN, LAPAROSCOPIC AND ROBOTIC  
C. Andreoni, R. Natalin, C. Paiva, C. Utida, V. Ortiz

**MP20-16** PRELIMINARY ONCOLOGIC OUTCOME OF LAPAROSCOPIC ADRENALECTOMY FOR ISOLATED ADRENAL METASTASIS  
R. Papalia, G. Simone, S. Guaglianone, A. Bove, E. Forastiere, M. Gallucci

**MP20-17** THE EFFECT OF TRAINING PERIOD TO SUCCESS AND COMPLICATION RATES OF LAPAROSCOPIC PROCEDURES  
U. Altug, F. Yalcinkaya, F. Demirel, M. Topcuoglu

**MP20-18** COMPARISON OF LAPAROSCOPY TRAINING USING THE BOX TRAINER VERSUS THE VIRTUAL TRAINER  
Y. Mohammadi, M. Lerner, A. Sethi, S. Lucas, C. Sundaram—USA

**MP20-19** LAPAROSCOPIC RENAL SURGERY (LRS) IN PATIENTS UNDER HEMODIALYSIS TREATMENT: NO PROBLEM  
O. Sanli, T. Tefik, A. Atar, T. Mut, M. Tunc, C. Özsoy—Turkey

**MP20-20** HOMODYNAMIC CHANGES AFTER RETROPERITONEAL CO<sub>2</sub> INSUFFLATION FOR POSTERIOR RETROPERTONEOSCOPIC ADRENALECTOMY  
S. Soleymani

## **VP25: LAPAROSCOPY—BLADDER**

14:00–15:30 hr

**VP25-01** A NEW APPROACH FOR OPTIMAL EXPOSURE DURING LYMPH NODE DISSECTION FOR LAPAROSCOPIC RADICAL CYSTECTOMY  
A. Ghazi, R. Zimmermann, A. Schfler, G. Janetschek—Austria

**VP25-02** LAPAROSCOPIC RADICAL CYSTECTOMY WITH DETENIAL SIGMOID COLON ORTHOTOPIC NEOBLADDER: EXPERIENCE WITH 100 CASES  
X. Kai—People's Republic of China

**VP25-03** LAPAROSCOPIC-ASSISTED RADICAL CYSTECTOMY: LATE COMPLICATIONS AND ONCOLOGIC RESULTS AT MID-TERM FOLLOW UP  
F. Porpiglia, C. Fiori, B. Cavallone, M. Manfredi, M. Lucci chiarissi, R. Scarpa

**VP25-04** LAPAROSCOPIC RADICAL CYSTECTOMY WITH EXTENDED PELVIC LYMPHADENECTOMY(REPORTED OF 25 CASES)  
Y. Changjun

**VP25-05** LAPAROSCOPIC RADICAL CYSTECTOMY: OUR RESULTS AFTER 91 CONSECUTIVES PATIENTS  
O. Castillo, I. Vidal-mora, A. Foneron, G. Rubio, R. Campos, F. Sepulveda

**VP25-06** LAPAROSCOPIC CYSTECTOMY WITH TOTALLY INTRACORPOREAL MAINZ POUCH II RESERVOIR  
O. Castillo, R. Campos, I. Vidal-mora, A. Foneron, G. Rubio, M. Feria-flores

**VP25-07** DIVERSION-RELATED COMPLICATIONS AFTER LAPAROSCOPIC AND OPEN RADICAL CYSTECTOMY  
R. Brandina, A. Berger, A. Bosco, I. Gill, S. Campbell

**VP25-08** LAPAROSCOPIC RADICAL CYSTECTOMY. SINGLE INSTITUTIONAL EXPERIENCE  
D. Nakano, F. Sato, Y. Hirata, H. Mimata—Japan

**VP25-09** LAPAROSCOPIC RADICAL CYSTECTOMY WITH URINARY DIVERSION THROUGH A 4 CM MINI-INCISION  
Y. Bayazit, I. Aridogan, O. Karsli, D. Abat, N. Satar, S. Doran

**VP25-10** LAPAROSCOPIC BOARI FLAP FOR DISTAL URETERAL INJURIES  
J. Diaz, R. Riffo, I. Pinto, A. Pabon, C. Sandoval, A. Hornig—Chile

**VP25-11** LAPAROSCOPIC TOTAL CYSTECTOMY IN INTERSTITIAL CYSTITIS: 5 CASES  
O. Castillo, I. Vidal-mora, R. Campos, A. Foneron, G. Rubio, F. Sepulveda

**VP25-12** THE MODIFICATION OF LAPAROSCOPIC RADICAL CYSTECTOMY WITH ILEAL CONDUIT  
L. Ma, Y. Huang, X. Hou, G. Wang, L. Zhao, C. Xiao

**VP25-13** SOME EXPERIENCES OF LAPAROSCOPIC RADICAL CYSTECTOMY WITH ORTHOTOPIC STUDER NEOBLADDER  
L. Ma, Y. Huang, X. Hou, L. Zhao, K. Hong, Y. Liu—China

**VP25-14** LAPAROSCOPIC RADICAL CYSTECTOMY WITH ORTHOTOPIC ILEAL NEOBLADDER FOR CANCER: EXPERIENCE OF 164 CASES WITH 6 YEARS  
J. Huang, T. Lin, C. Zhang, K. Xu, C. Jiang, H. Huang—China

**VP25-15** MANAGEMENT OF POST-OPERATIVE COMPLICATIONS IN LAPAROSCOPIC RADICAL CYSTECTOMY: A REPORT OF 164 CASES  
J. Huang, C. Zhang, T. Lin, C. Jiang, K. Xu, Z. Guo—China

**VP25-16** COMPARISON OF LAPAROSCOPIC AND OPEN RADICAL CYSTECTOMY WITH ORTHOTOPIC ILEAL NEOBLADDER: PRELIMINARY REPORT OF A PROSPECTIVE RANDOMIZED CONTROL STUDY  
J. Huang, T. Lin, C. Zhang, K. Xu, C. Jiang, Z. Guo—China

**VP25-17** LAPAROSCOPIC URETERO-VESICAL REIMPLANTATION WITH “SPLIT-NIPPLE” TECHNIQUE  
J. Huang, X. Li, C. Zhang, T. Lin, K. Xu, X. Yin—China

**VP25-18** LAPAROSCOPIC RETROPERITONEAL LYMPH NODE DISSECTION WITH THERAPEUTIC INTENT IN MEN WITH CLINICAL STAGE I NONSEMINOMATOUS GERM CELL TUMORS  
T. Guzzo, J. Berkowitz, M. Gonzalgo, M. Allaf

**VP25-19** A SAFE AND EFFICIENT TECHNIQUE FOR INITIAL ACCESS TO INTRAPERITONEAL LAPAROSCOPY  
A. Ghazi a., R. Zimmermann, A. Schfler, G. Janetschek

**VP25-20** CAN PEROPERATIVE COMPLICATION RATES DICTATE THE DIFFICULTY OF RETROPERITONEOSCOPIC PROCEDURES  
A. Tepeler, A. Tefekli, T. Aktoz, M. Binbay, M. Baykal, A. Müslümanoğlu

**VP26: PCNL 3**  
14:00–15:30 hr

**VP26-01** SEQUENTIAL FLEXIBLE PERCUTANEOUS AND URETEROSCOPIC APPROACH IN STAGHORN CALCULI  
R. Multescu, B. Geavlete, V. Cauni, V. Mirciulescu, D. Georgescu, P. Geavlete—Romania

**VP26-02** OUTCOMES OF COMPLETE SUPINE PCNL AND PRONE PCNL ACCORDING TO BODY MASS INDEX  
S. Falahatkar, M. Akbarpour, A. Afshari moghaddam, A. Enshaie

**VP26-03** COMPARISON OF EFFICACY AND COMPLICATIONS OF GENERAL AND SPINAL ANESTHESIA IN PERCUTANEOUS NEPHROLITHOTOMY  
S. Mehrabi, M. Akbartabar—Iran

**VP26-04** PERCUTANEOUS NEPHROLITHOTOMY (PCNL) FOR RENAL CALCULI OF MORE THAN 5CM  
A. Ashish patil—India

**VP26-05** PERCUTANEOUS STONE SURGERY UTILIZING TUBELESS TECHNIQUE WITH FIBRIN SEALANT: REPORT OF OUR FIRST 100 CASES  
J. Durbin, S. Stroup, J. L’esperance, B. Auge

**VP26-06** ENDOUROLOGICAL TREATMENT OF PYELOGENIC CYST: SELECTION CRITERIA AND TECHNICAL DETAILS FOR SPECIFIC APPROACH  
A. Tasca, F. Paolo, G. Benedetto, E. Bratti, E. Scremin, F. Nigro—Italy

**VP26-07** PCNL IN SINGLE KIDNEY PATIENTS: TEN YEAR EXPERIENCE  
M. Darabi mahboub, R. Taghavi, M. Rahmani—Iran

**VP26-08** PERCUTANEOUS NEPHROLITHOTOMY (PCNL) IN PATIENTS WITH SPINAL DEFORMITIES  
I. Kartalas goumas, H. Yasser, P. Bernardini, E. Itri, A. Del nero, E. Montanari

**VP26-09** PCNL UNDER REGIONAL ANAESTHESIA—A STUDY OF 750 CASES DR. ULHAS SATHAYE SAHAYOG SPECIALITY HOSPITAL, JAMNAGAR, INDIA  
U. Sathaye

**VP26-10** FULL-HD DIGITAL TECHNOLOGY IN PERCUTANEOUS APPROACH OF PYELOCALICEAL LITHIASIS  
B. Geavlete, V. Mirciulescu, R. Multescu, P. Geavlete—Romania

**VP26-11** PREVIOUS OPEN NEPHROLITHOTOMY: DOES IT AFFECT TUBELESS PERCUTANEOUS NEPHROLITHOTOMY (PCNL) EFFICACY AND SAFETY?  
B. Lojanapiwat—Thailand

**VP26-12** COMPARISON THE RESULTS AND COMPLICATIONS BETWEEN STANDARD AND TUBELESS PCNL  
M. Darabi mahboub, R. Taghavi, J. Sadidi, N. Akbari—Iran

**VP26-13** MANAGEMENT OF NEPHROLITHIASIS IN AUTOSOMAL DOMINANT POLYCYSTIC KIDNEYS  
A. Patel, Baishya, A. Ganpule, M. V, R. Sabnis, M. Desai

**VP26-14** LOWER POLE FLUOROSCOPIC-GUIDED PERCUTANEOUS RENAL ACCESS: WHICH CALYX IS POSTERIOR?  
B. Eisner, J. Cloyd, M. Stoller—MA

**VP26-15** PERCUTANEOUS NEPHROLITHOTOMY(PCNL): COMPARISON OF ALKEN TELESCOPIC AND ONE-SHOT METALIC CONE-TIP DILATOR  
M. Hosseini, A. Aminsharifi, A. Aryafar, D. Hosseini niashiran—Iran

**VP26-16** RESULTS OF PERCUTANEOUS NEPHROLITHOTOMY (PCNL) OF UPPER CALICES WITH SUBCOSTAL ACCESS  
M. Rahmani, M. Darabi mahboub

**VP26-17** WISDOM OF DOING TUBELESS PCNL: RANDOMIZED PROSPECTIVE CONTROLLED STUDY OF EARLY REMOVAL OF EXTERNAL BODY TUBES VS. TUBELESS PCNL  
S. Mishra, A. Kurien, A. Ganpule, V. Muthu, R. Sabnis, M. Desai

**VP26-18** PERCUTANEOUS NEPHROLITHOTOMY IN PATIENTS WITH THE HORSESHOE KIDNEY  
S. Zenkov, A. Nemenova, K. Berestennikov—Russia

**VP26-19** MANAGEMENT OF COMPLETE URETEROPELVIC OBSTRUCTIONS WITH ANTEGRAD PERCUTANEOUS TECHNIQUE

S. Bedir, M. Zor, L. Tahmaz, M. Kilciler, Y. Ozgok, M. Dayanc

**VP26-20** MINI-INVASIVE TREATMENT OF CALCULOSIS IN URINARY RENO-URETERAL MALFORMATIONS: OUR EXPERIENCE

A. Scavuzzo, M. Puglisi, A. Costa, M. Falsaperla, A. Bonaccorsi, A. Saita—Italy

**VS15: RECONSTRUCTIVE LAPAROSCOPY 2**

14:00–15:30 hr

**VS15-01** ROBOTIC URETEROILEAL ANASTOMOSIS REVISION

R. Abaza—USA

**VS15-02** ROBOTIC NEPHROURECTOMY WITH PARTIAL DUODENECTOMY FOR INVASIVE URETERAL TUMOR

R. Abaza—USA

**VS15-03** ROBOTIC URETERAL MITROFANOFF: A MINIMALLY INVASIVE ALTERNATIVE TO TRADITIONAL APPENDICOVESICOSTOMY

E. Kheternal, M. Patel, R. Laungani, N. Pokala, M. Menon, E. Jack

**VS15-04** LAPARO-ENDOSCOPIC SINGLE SITE (LESS) LAPAROSCOPIC SURGERY IN RE-OPERATIVE PYELOPLASTY

S. Permpongkosol, C. Ieenanupunth

**VS15-05** ROBOT-ASSISTED TAPERED URETERAL REIMPLANTATION FOR CONGENITAL MEGAURETER

A. Goh, R. Link—USA

**VS15-06** ROBOT ASSISTED LAPAROSCOPIC PYELOPLASTY FOR RIGHT RENAL DOUBLE SYSTEM

F. Porpiglia, C. Fiori, R. Bertolo, I. Morra, R. Scarpa

**VS15-07** ROBOT ASSISTED DISTAL URETERECTOMY AND PSOAS HITCH FOR BENIGN AND MALIGNANT URETERAL DISEASE (THIS ABSTRACT IS ACCOMPANIED BY A VIDEO)

H. Atalah, C. Vincent, L. Su—USA

**VS15-08** TRANSMESOCOLIC ROBOT-ASSISTED PYELOPLASTY

G. Bianchi, G. Pini, F. Annino, S. Micali, A. Beato, S. De stefani

**VS15-09** VIDEOLAPAROSCOPIC CORRECTION OF RETRO-CAVA URETER

M. Baptistussi, E. Gewher, M. Morihisa

**VS15-10** ROBOTIC ASSISTED LAPAROSCOPIC RESECTION OF A PELVIC MASS INVADING THE LEFT DISTAL URETER

F. Atug, A. Kural, H. Akpinar, S. Aksit, I. Tufek—Turkey

**VS16: ROBOTICS—BLADDER**

14:00–15:30 hr

**VS16-01** ROBOT-ASSISTED LAPAROSCOPIC RADICAL CYSTOPROSTATECTOMY: TOTALLY INTRACORPOREAL STUDER NEOBLADDER

N. Pardalidis, N. Andriopoulos, E. Kosmaoglou—Greece

**VS16-02** EXTRAPERITONEAL RETROGRADE ROBOT ASSISTED RADICAL PROSTATECTOMY: DUPLICATION OF THE OPEN GOLD STANDARD

M. Lux, J. Joseph—USA

**VS16-03** ROBOTIC-ASSISTED TOTAL—INTRACORPOREAL LAPAROSCOPIC RADICAL CYSTECTOMY AND ILEAL CONDUIT URINARY DIVERSION

G. Wu, D. Golijanin, E. Singer, H. Rashid—USA

**VS16-04** ROBOT ASSISTED ANTERIOR EXENTERATION FOR INVASIVE BLADDER CANCER IN A FEMALE PATIENT

M. Sangalli, G. De naeyer, P. Schatteman, P. Carpentier, E. Fonteyne, A. Mottrie

**VS16-05** RARE INDICATIONS OF ROBOTIC SURGERY SYSTEM IN UROLOGY

S. Mattia nicola, G. De naeyer, P. Schatteman, P. Carpentier, E. Fonteyne, A. Mottrie

**VS16-06** ROBOT-ASSISTED LAPAROSCOPIC INTRACORPOREAL ILEAL CONDUIT

S. Mattia nicola, G. De naeyer, P. Schatteman, P. Carpentier, E. Fonteyne, A. Mottrie

**VS16-07** ROBOTIC ASSISTED EXTENDED LYMPH NODE DISSECTION

R. Goel, C. Sebastien, W. White, G. Haber, S. Campbell, J. Kaouk—Ohio

**VS16-08** ROBOTIC-ASSISTED LAPAROSCOPIC EXTENDED LYMPH NODE DISSECTION FOR BLADDER CANCER

A. George, M. Atalla, A. Srinivasan, M. Vira, L. Richstone—USA

**VS16-09** A TECHNIQUE FOR INTRACORPOREAL BOWEL HARVESTING AND STAPLED ANASTOMOSIS FOR URINARY DIVERSION AFTER CYSTECTOMY

J. Montgomery, A. Weizer—USA

**VS16-10** ROBOTIC ASSISTED RADICAL CYSTECTOMY

R. Goel, S. Crouzet, W. White, G. Haber, J. Kaouk

**VS17: LAPAROSCOPY—UROLITHIASIS**

14:00–15:30 hr

**VS17-01** ROBOTIC PYELOPLASTY WITH PYELOTOMY

R. Brandina, M. Lee, A. Berger, J. Kaouk, A. Monish, R. Stein

**VS17-02** LAPAROSCOPIC ANATROPHIC NEPHROLITHOTOMY FOR THE MANAGEMENT OF COMPLEX STAGHORN CALCULI  
K. Kijvikai

**VS17-03** REMOVAL OF DISRUPTED NEPHROSTOMY TUBE AND URETERAL STENT VIA PERCUTANEOUS WAY IS A SAFE AND EFFICIENT METHOD  
A. Kural, S. Aksit, H. Akpınar, I. Tufek, F. Atug—Turkey

**VS17-04** LAPAROSCOPIC PYELOLITHOTOMY  
G. Franco, P. Francesco, G. Antonio maria, R. Ai ling, S. Antonio—Italy

**VS17-05** BACKSTOP(TM) TO PREVENT RETROPULSION DURING THE TREATMENT OF URETERAL CALCULI  
A. Ray, K. Pace, R. Honey—Canada

**VS17-06** LAPAROSCOPIC PYELOPLASTY WITH RENAL STONES EXTRACTION WITH FLEXIBLE NEPHROSCOPY  
R. Sanseverino, G. Napodano, O. Intilla, U. Di mauro, T. Realfonso

**VS17-07** LAPAROENDOSCOPIC SINGLE SITE PYELOLITHOTOMY IN HORSESHOE KIDNEY USING A HOMEMADE SINGLE-PORT DEVICE  
D. Kim, Y. Yoon, S. Park, J. Lee, T. Lee, H. Park

**VS17-08** LAPAROSCOPIC PYELOLITHOTOMY IN THE TREATMENT OF PELVIC CALCULI WITHIN A HORSESHOE KIDNEY  
A. Tepeler, A. Tefekli, T. Aktoz, M. Baykal, A. Muslumanoglu

**VS17-09** TREATMENT OF URETERAL LITHIASIS IN PREGNANT WOMEN AND USE OF LONG-TERM CATHETER  
M. Baptistussi, E. Gewher, M. Morihisa

**VS17-10** ROBOTIC-ASSISTED PYELOLITHOTOMY  
R. Figenshau, T. Roytman, B. Benway, A. Desai, T. Christensen, M. Gardner

**MP21: PEDIATRIC AND UPPER TRACT**  
16:00–17:30 hr

**MP21-01** BILATERAL CRYPTORCHIDISM IN SILVER-RUSSELL SYNDROME: THE FIRST EXPERIENCE OF LAPAROSCOPIC ORCHIOPEXY  
K. Yoo, S. Jeon, J. Lee, J. Kim

**MP21-02** THE ENDOSCOPIC THERAPY FOR MELAMINE-ASSOCIATED UROLITHIASIS IN CHILDREN. DEPARTMENT OF UROLOGY, FIRST AFFILIATED HOSPITAL OF GANNAN MEDICAL UNIVERSITY, JIANGXI PROVINCIAL MODERN TREATMENT CENTER OF UROLITHIASIS, GANZHOU, JIANGXI, 341000, CHINA  
Z. xiao-feng, Y. Yuan-hu, X. Ri-hai—China

**MP21-03** EFFECT OF UNILATERAL ORCHIECTOMY ON CONTRALATERAL TESTICULAR DAMAGE IN UNILATERAL TESTICULAR TORSION  
S. Paick, H. Kim, M. Baek, Y. Lho, B. Lee, H. Choi—Korea

**MP21-04** PERCUTANEOUS MANAGEMENT OF NEPHROLITHIASIS IN CHILDREN AND ADOLESCENTS WITH SPINAL CORD LESION  
B. Gayed, M. Smaldone, K. Shahrour, K. Sternberg, A. Mohamed, M. Ost

**MP21-05** INCIDENCE OF URINARY TRACT INFECTIONS IN CHILDREN AFTER SUCCESSFUL CORRECTION OF VESICoureTERAL REFLUX: COMPARISON OF ENDOSCOPIC INJECTION AND OPEN SURGERY  
O. Tanriverdi, M. Sýlay, M. Kadihasanoglu, H. Sirin, K. Horasanli, C. Miroglu

**MP21-06** THE EFFECT OF RESTRICTIVE BARIATRIC SURGERY ON KIDNEY STONE RISK FACTORS  
M. Semins, S. Donahue, K. Steele, J. Asplin, J. Berkowitz, B. Matlaga—USA

**MP21-07** THE PRELIMINARY RESULTS OF TREATMENT OUTCOMES ON 60 VERSE 120 SHOCK WAVES PER MINUTES IN AN ELECTROCONDUCTIVE LITHOTRIPTOR  
A. Lo, M. Gohel, K. Wong, C. Ng

**MP21-08** MULTIPLE ANEURYSMS IN PATIENTS WITH CHRONIC RENAL FAILURE UNDERGOING ANGIO-EMBOLISATION FOR BLEEDING FOLLOWING PERCUTANEOUS RENAL INTERVENTION: WHAT ARE WE DEALING WITH?  
R. Mavuduru, D. Sarkar, S. Singh, M. Agarwal, A. Lal, A. Mandal—India

**MP21-09** CONTEMPORARY EXPERIENCE IN THE MANAGEMENT OF ANGIOMYOLIPOMA  
M. Jorge, J. Rosales, Z. Okhunov, J. Landman, J. Mckiernan, K. Badani—USA

**MP21-10** PERCUTANEOUS MANAGEMENT OF RENAL AND PERINEPHRIC ABSCESES  
T. Haresh, V. Joshi

**MP21-11** LATE DIAGNOSIS AND TREATMENT OF RENAL PSEUDOANEURYSM IN PEDIATRIC PATIENT: COMPLICATION OF PERCUTANEOUS NEPHROLITHOTOMY  
M. Istanbuluoglu, E. Yildirim, T. Cicek, B. Ozturk

**MP21-12** UNSATISFACTORY SCREENING OF URINE WITH THE NEXT GENERATION URINE FLOW CYTOMETER (UF-1000I) FOR SIGNIFICANT BACTERIURIA  
G. Bonkat, M. Rieken, A. Feike, S. Wyler, T. Gasser, A. Bachmann

**MP21-13** ANALYSIS OF INFECTIOUS STONES: VARIABILITY OF LABORATORY ANALYSIS

A. Krambeck, N. Khan, M. Jackson, J. Lingeman, J. Williams Jr—United States

**MP21-14** ENDOSCOPIC MANAGEMENT OF PLASTIC FOREIGN BODY DURING PERCUTANEOUS NEPHROLITHOTOMY

S. Guven, A. Ozturk, O. Kilic, U. Ozdemir, M. Piskin, M. Kilinc

**MP21-15** PERCUTANEOUS NEPHROLITHOTOMY UNDER SPINAL ANESTHESIA IN TREATMENT OF STAGHORN CALCULI

S. Mousavi-bahar, B. Borzouei, H. Babolhaeji—Iran

**MP21-16** RENAL ACCESS BY UROLOGIST OR RADIOLOGIST DURING PERCUTANEOUS NEPHROLITHOTOMY

J. Tomaszewski, M. Smaldone, S. Jackman, T. Averch

**MP21-17** THE RADIO GRAPHIC APPEARANCE OF THE CALCULI IN PUT FILM & ITS EFFECTS ON THE RESULT OF EXTRA CORPOREAL SHOCK WAVE LITHOTRIPSY

M. Etafy

**MP21-18** CLOSED EXTERNAL END DOUBLE J CATHETER AS A NEPHROSTENT IN PYELOPLASTY FOR VERY SMALL CHILDREN WITH URETERO-PELVIC JUNCTION OBSTRUCTION

S. Rabani—Iran

**MP21-19** SIMILARITIES AND DIFFERENCES BETWEEN TWO DIFFERENT CENTERS IN PERCUTANEOUS NEPHROLITHOTOMY FOR LARGE STONES IN HORSESHOE KIDNEYS

A. Skolarikos, A. Tefekli, A. Bisas, E. Sari, A. Muslumanoglu, C. Deliveliotis—Turkey

**MP21-20** THE COMPARISON OF DIGITAL AND CONVANTIONAL FLEXIBLE URETERORENOSCOPY OUTCOMES

M. Binbay, A. Muslumanoglu, E. Yuruk, T. Akman, F. Ozgor, A. Tefekli—Turkey

**MP22: ENDOUROLOGY FOR NEPHROLITHIASIS**

16:00–17:30 hr

**MP22-01** THE MODIFIED AMPLATZ PCNL SHEATH – INITIAL EXPERIENCE

S. Umranikar, P. Kumar, R. Kulkarni, E. Bellamy, P. Rao, M. Kulkarni

**MP22-02** NON-CONTACT INFRARED TEMPERATURE MEASUREMENT OF ULTRASONIC LITHOTRIPSY PROBES – A COMPARISON OF 3 DIFFERENT LITHOTRIPTERS DURING PERCUTANEOUS NEPHROLITHOLAPAXY (PCNL)

C. Keil, P. Olbert, A. Hegele, A. Schrader, R. Hofmann

**MP22-03** PCNL IN PATIENTS IN PATIENTS WHO PREVIOUSLY UNDERWENT OPEN STONE SURGERY

T. Hareh, J. V d j, K. Sushil, S. Moteria, A. Jitendra

**MP22-04** A RANDOMIZED PLACEBO CONTROL TRIAL TO STUDY THE IN VIVO EFFECT OF A CHINESE HERB, SHI WAI, IN MALE URINARY STONE FORMER

C. Ng, K. Ip, N. Poon, D. Gohel

**MP22-05** ORDNANCE GELATINE AS AN IN VITRO TISSUE SIMULATION SCAFFOLD FOR SWL RESEARCH

C. Mendez probst, M. Vanjecek, P. Cadieux, H. Razvi

**MP22-06** ENDOSCOPIC GUIDED PERCUTANEOUS ACCESS DURING PERCUTANEOUS NEPHROLITHOTOMY: IS IT OF ANY CLINICAL ADVANTAGE?

S. Beck, N. Jain, A. Kaplan, G. Box, R. Clayman, E. Mcdougall—USA

**MP22-07** COMPARISON OF MEDICARE REIMBURSEMENT FOR TREATMENT OF LARGE SOLITARY RENAL CALCULI BY URETEROSCOPY AND PCNL

J. Johannes, N. Leone, S. Hubosky, D. Bagley—USA

**MP22-08** OSTEOPONTINE GENE POLYMORPHISM IN TURKISH UROLITHIASIS PATIENTS

E. Sönmezay, V. Tugcu, N. Gurbuz, A. Bitkin, T. Tarhan, A. Tasci

**MP22-09** PERCUTANEOUS APPROACH FOR THE MANAGEMENT OF FORGOTTEN AND FRAGMENTED J-STENTS

L. Tahmaz, S. Bedir, M. Zor, S. Basal, I. Karabuga, M. Dayanc

**MP22-10** EXTRAPERITONEAL LAPAROSCOPY-ASSISTED PERCUTANEOUS NEPHROLITHOTOMY IN A PATIENT WITH OSTEOGENESIS IMPERFECTA

L. Tahmaz, S. Basal, M. Zor, Y. Ozgok, M. Kilciler, M. Dayanc

**MP22-11** URIC ACID STONE FORMERS—NEED TO UPDATE PROTOCOLS FOR METABOLIC EVALUATION?

H. Joshi, N. Baban, J. Greenwood—UK

**MP22-12** SURROUNDING FLUID ENVIRONMENT IMPACTS STONE FRAGMENTATION RATE: AN IN VITRO MODEL USING A HARD ARTIFICIAL CALCULUS

C. Mendez probst, M. Vanjecek, P. Cadieux, H. Razvi—Canada

**MP22-13** PERCUTANEOUS ACCESS FOR INTRARENAL SURGERY : THE LEARNING CURVE

O. Negrete-pulido, M. Molina-torres, A. Loske, J. Gutierrez-aceves

**MP22-14** COMPARATIVE STUDY THE CLINICAL VALUE OF SINGLE B-MODE ULTRASOUND AND B-MODE ULTRASOUND COMBINED COLOR DOPPLER ULTRASOUND IN THE GUIDANCE OF MINI-INVASIVE PERCUTANEOUS NEPHROLITHOTOMY (M-PCNL) TO DECREASE THE HEMORRHAGIC COMPLICATIONS

X. Gao, M. Lu, X. Pu

**MP22-15** MINIMALLY INVASIVE PERCUTANEOUS NEPHROLITHOTOMY(MPNL) IN TREATMENT OF CALCULI IN HORSESHOE KIDNEY

A. Jitendra, R. Dipak

**MP22-16** TUBELESS PERCUTANEOUS RENAL SURGERY IN SUPINE POSITION: INITIAL EXPERIENCE AND COMPARISON WITH NON TUBELESS TECHNIQUE

S. Benjamin, F. Vargas, F. Araya, J. De la torre, P. Valdevenito, E. Maldonado—Chile

**MP22-17** UNIQUE SCORING SYSTEM FOR SELECTING A LITHOTRIPTER

M. Hanna, M. Medhat, R. Prem

**MP22-18** DOES THE PRESENCE AND SEVERITY OF HYDRONEPHROSIS HAVE AN IMPACT ON THE OUTCOMES OF PERCUTANEOUS NEPHROLITHOTOMY PROCEDURES?

O. Tanriverdi, M. Kendirci, M. Kadihasanoglu, M. Aydin, H. Sirin, C. Miroglu

**MP22-19** NOVEL USE OF A COAXIAL FILM-BASED OCCLUSION DEVICE FOR OPTIMAL ACCESS DURING PERCUTANEOUS NEPHROLITHOTOMY

M. Gupta, M. Rothberg, M. Wosnitzer—United States

**MP22-20** PERCUTANEOUS NEPHROLITHOTRIpsy (PCNL) FOR PATIENTS WITH PREVIOUS OPEN RENAL SURGERY: IS THERE ANY PROGNOSTIC FACTOR?

S. Ben rhouma, S. Sallami, M. Basli, A. Horchani, Y. Nouria

### **MP23: LOWER URINARY TRACT**

16:00–17:30 hr

**MP23-01** PATIENT-REPORTED OUTCOMES AFTER POLYDIMETHYLSILOXANE INJECTION IN MALE PATIENTS WITH POSTOPERATIVE STRESS URINARY INCONTINENCE

D. Tienforti, E. Sacco, F. Pinto, M. Racioppi, M. Gardi, P. Bassi

**MP23-02** EVALUATION OF LONG-TERM RESULTS OF BOTULINUM-A TOXIN INJECTIONS INTO THE DETRUSOR MUSCLE FOR IDIOPATHIC OVERACTIVE BLADDER SYNDROME (OAB)

C. Frohme, Z. Varga, A. Schrader, P. Olbert, R. Hofmann, A. Hegele—Germany

**MP23-03** EFFICACY OF REPEATED BOTULINUM TOXIN TYPE A (BTX-A) INJECTIONS INTO THE BLADDER MUSCLE DUE TO IDIOPATHIC OVERACTIVE BLADDER SYNDROME (OAB)

C. Frohme, Z. Varga, A. Schrader, P. Olbert, R. Hofmann, A. Hegele—Germany

**MP23-04** IS THE EXTENSOR DIGITORUM BREVIS TEST USEFUL IN PREDICTING RESISTANCE TO TREATMENT WITH BOTULINUM TOXIN-A IN PATIENTS WITH OVERACTIVE BLADDER?

P. Sangster, V. Kalsi, A. Sahai, C. Cordivari, C. Fowler, P. Dasgupta—UK

**MP23-05** TREATMENT OF MODERATE TO SEVERE FEMALE STRESS URINARY INCONTINENCE WITH THE ADJUSTABLE CONTINENCE THERAPY DEVICE (ACT) AFTER FAILED SURGICAL REPAIR

P. Sassani, S. Aboseif, J. Gleason, E. Franke, S. Nash, J. Slutsky—USA

**MP23-06** URINARY OUTCOMES FOLLOWING PHOTOSELECTIVE VAPORIZATION OF THE PROSTATE (PVP)

J. Wei, N. Casanova, R. Jackson, L. Wallner, R. Dunn

**MP23-07** SIS(SUBMUCOSAL INTESTINAL SUINE) FOR THE TREATMENT OF URINARY STRESS INCONTINENCE IN OBESE WOMEN

M. Baptistussi, M. Morihisa, E. Gewher, A. Martins—Brasil

**MP23-08** GOSERELIN ACETATE COMBINED PKRP FOR BENIGN PROSTATIC HYPERPLASIA IN PATIENTS WITH HIGH SURGICAL RISK

W. Xue, J. Pan, H. Chen, Q. Chen, Y. Chen, Y. Huang

**MP23-09** PROGRESSION OF SURGICALLY TREATED BPH PATIENTS WITH RENAL INSUFFICIENCY

T. Haresh

**MP23-10** ABLATIVE EFFICIENCY OF LITHIUM TRIBORATE LASER VAPORISATION AND CONVENTIONAL TRANSURETHRAL RESECTION OF THE PROSTATE: A COMPARISON USING TRANSRECTAL THREE-DIMENSIONAL ULTRASOUND VOLUMETRY

L. Hefermehl, D. Strebhel, O. Gross, T. Sulser, H. Seifert, T. Hermanns—Switzerland

**MP23-11** TEMPRO BIPOLAR RADIO FREQUENCY THERMAL TREATMENT FOR CHRONIC PROSTATITIS: INITIAL RESULTS CH. BECK, A. BECK, DORTMUND, GERMANY

C. Beck, A. Beck—Germany

**MP23-12** EVALUATION OF EFFICACY AND SAFETY OF KTP PHOTOSELECTIVE VAPORIZATION OF THE PROSTATE FOR THE TREATMENT OF BENIGN PROSTATIC HYPERPLASIA: THE 3-YEAR RESULTS

Y. Seungok, J. Tae young, L. Jeongki, K. Yun beom



**MP23-13** SIMULTANEOUS SURGICAL TREATMENT OF BENIGN PROSTATIC HYPERPLASIA AND INGUINAL HERNIA (REPORT OF 182 CASES)

C. Xiaoming, W. Dongwen, L. Chun

**MP23-14** SAFETY AND EFFICACY OF GREENLIGHT LASER VAPORIZATION OF THE PROSTATE IN PATIENTS WITH ONGOING ORAL ANTICOAGULATION—LONG-TERM RESULTS AFTER MORE THAN 700 INTERVENTIONS

M. Rieken, G. Bonkat, S. Wyler, T. Gasser, A. Bachmann—Switzerland

**MP23-15** SELF-EXPANDING STENT INSERTION FOR RECURRENT BULBAR URETHRAL STRICTURES: UP TO 15-YEAR FOLLOW-UP

M. Sercelik, I. Bozkurt, K. Zengin, K. Oskay, O. Yigitbasi—Turkey

**MP23-16** ELECTROSPUN POLYMER SCAFFOLDS—NOT AN IDEAL MATERIAL FOR BLADDER AND URETHRAL SUBSTITUTION IN A RABBIT MODEL

D. Pick, S. Kolla, J. Gelman, M. Louie, E. Mcdougall, R. Clayman—CA

**MP23-17** CHANGES OF VOIDING SYMPTOMS DUE TO LONG-TERM URETERAL DOUBLE-J STENTING

J. Lim, Y. Kim, E. Hwang, S. So, D. Han, E. Kim

**MP23-18** SUPRACERVICAL ROBOTIC ASSISTED SACROCOLPOPEXY AND ROBOTIC HYSTERECTOMY AS TREATMENT FOR PELVIC ORGAN PROLAPSE: PRELIMINARY RESULTS

A. Benson, B. Kramer, E. Nelson, B. Schwartz—United States

**MP23-19** BUILDING A BETTER BLADDER: PRESSURE-FLOW URODYNAMIC STUDIES IN CADAVERIC ORTHOTOPIC NEOBLADDERS

A. George, A. Herati, A. Srinivasan, L. Kavoussi, M. Vira, L. Richstone—USA

## **MP24: ENDOUROLOGY—UPPER URINARY TRACT**

16:00–17:30 hr

**MP24-01** URETEROSCOPIC INSTRUMENT DAMAGE; EXPERIENCE AFTER 5,500 URETEROSCOPIES

P. Geavlete, D. Georgescu, R. Multescu, B. Geavlete—Romania

**MP24-02** “CHIP ON A STICK” TECHNOLOGY—FIRST ROMANIAN EXPERIENCE

P. Geavlete, R. Multescu, V. Mirciulescu, B. Geavlete—Romania

**MP24-03** DRILLING THROUGH THE IMPACTION: POSSIBLE USE OF AN ATHERECTOMY DRILLING DEVICE FOR UROLITHIASIS

D. Lifshitz, A. Razmaria, S. Shikanov, A. Shalhav, K. Zorn

**MP24-04** CREATION OF A FLUID CHAMBER WITH THE ACCORDION DEVICE INCREASES FRAGMENTATION DURING URETERAL ESWL: IN VITRO AND EX VIVO RESULTS

J. Ditrolio, m.d., P. Ciccone, m.d., M. Lasalle, m.d., R. Bhalla, m.d.—USA

**MP24-05** COMPARATIVE EVALUATION OF EFFICACY OF USE TAMSULOCIN AND/OR TAMSULOCIN PLUS DEXAMETAZON FOR EXPLUSIVE THERAPY OF DISTAL URETERAL CALCULI AFTER EXTRA CORPORAL SHOCK WAVE LITHOTRIPSY (ESWL)

R. Mahdavi zafarghandi, M. Mahdavi zafarghandi—Iran

**MP24-06** CAN THE ACCORDION STONE DEVICE ASSIST IN UPPER URETERAL ESWL? PILOT CLINICAL EXPERIENCE WITH A NOVEL USE OF THE DEVICE?

R. David

**MP24-07** MULTI-INSTITUTIONAL ONE YEAR FOLLOW UP EXPERIENCE WITH THE RESONANCE™ METALLIC STENT FOR THE MANAGEMENT OF EXTRINSIC URETERAL OBSTRUCTION

C. Allam, D. Soderdahl, R. Marcovich, J. Hernandez—USA

**MP24-08** A MONTH WITH A DOUBLE-J STENT: THE SHORT TERM MORBIDITY AND OUTCOMES OF URETERIC STENTING

T. Haresh

**MP24-09** THE EFFECT OF PROTAMINE SULFATE ON PORCINE URETERAL PERMEABILITY

D. Pick, S. Shelkovnikov, M. Louie, A. Kaplan, E. Mcdougall, R. Clayman—CA

**MP24-10** ECIRS (ENDOSCOPIC COMBINED INTRA-RENAL SURGERY) FOR UROLITHIASIS IN GALDAKAO-MODIFIED SUPINE VALDIVIA POSITION: OUR EXPERIENCE

C. Scoffone, P. Massimiliano, C. Cracco, M. Cossu, S. Grande, R. Scarpa—Italy

**MP24-11** IRRIGATION FLOW DIFFERENCES IN FLEXIBLE URETEROSCOPES OF THE NEWEST GENERATION

S. Kruck, J. Bedke, D. Schilling, K. Sievert, A. Stenzl, U. Nagele

**MP24-12** URETERIC STENTS AND THE ELECTRONIC REGISTRY: DO THEY WORK?

A. Patel, R. Zakri, N. Shrotri

**MP24-13** A VALIDATED QUESTIONNAIRE STUDY COMPARING STENT-RELATED SYMPTOMS BETWEEN CONVENTIONAL JJ STENTS AND A NOVEL THERMO-EXPANDABLE SEGMENTAL URETERIC METAL STENT

D. Patel, Z. Maan, T. El-husseiny, A. Papatsoris, J. Masood, N. Buchholz—UK

**MP24-14** PARALLEL METALLIC AND POLYMERIC URETERAL STENTING FOR URETEROENTERIC STRICTURE

M. Wuerstle, J. Gleason, G. Chien—USA

**MP24-15** THE EFFECT OF TAMSULOSIN ON EXPULSION OF URETERAL STONES AFTER EXTRACORPOREAL SHOCK WAVE LITHOTRIPSY

Y. Seungok, L. Jeongki, J. Tae young, K. Yun beom

**MP24-16** URETERAL METAL STENTS: TEN YEARS EXPERIENCE FOR THE TREATMENT OF MALIGNANT URETERAL OBSTRUCTION

P. Kallidonis, K. Katsanos, D. Karnabatidis, I. Kyriazis, A. Al aown, E. Liatsikos

**MP24-17** EVALUATION OF THE EFFECT OF ENDEAVOR DRUG ELUTING STENT IN THE PORCINE URETER

P. Kallidonis, I. Kyriazis, A. Al aown, S. Spiliopoulos, C. Kalogeropoulou, E. Liatsikos

**MP24-18** THE CAPABILITY OF ANTIRETROPULSION DEVICES TO REDIRECT FLUID IRRIGATION DURING URETEROSCOPY

B. Chew, B. Poh, L. Jonat, D. Lange—Canada

**MP24-19** INTRAOPERATIVE STENTING OF THE UPPER URINARY TRACT IS NOT NECESSARY AFTER RESECTION OF THE URETERIC ORIFICE DURING TUR-B

A. Neisius, R. Gillitzer, S. Keber, C. Hampel, J. Thüroff—Germany

**MP24-20** ABILITY OF ANTIRETROPULSION DEVICES TO PREVENT INTRARENAL PRESSURE RISE IN EX VIVO PORCINE MODEL

M. Rothberg, L. Suh, M. Gupta—USA

**VP27: LAPAROSCOPY—KIDNEY 4**

16:00–17:30 hr

**VP27-01** OUTCOME OF RENAL FUNCTION IN RETOROPERITONEAL LAPAROSCOPIC PARTIAL NEPHRECTOMY WITH ICE SLUSH COOLING

T. Aoyagi, A. Sazawa, T. Harabayashi, S. Maruyama, N. Shinohara, K. Nonomura—Japan

**VP27-02** LAPAROSCOPIC NEPHROURETERECTOMY FOR UPPER URINARY TRACT TRANSITIONAL CELL CARCINOMA: LONG-TERM ONCOLOGIC OUTCOMES

S. Ha, Y. Park, J. Ku, H. Jeong, C. Kwak, H. Kim

**VP27-03** LAPAROSCOPIC PARTIAL NEPHRECTOMY BY CLINICAL STAGE: COMPARING OFF-CLAMP VERSUS COMPLETE HILAR-CONTROL

S. Rais-bahrami, A. Herati, A. George, S. Andonian, L. Richstone, L. Kavoussi

**VP27-04** LAPAROSCOPIC PARTIAL NEPHRECTOMY – LEARNING CURVE FOR INITIAL 87 CASES

Y. Naitoh, A. Kawauchi, K. Kamoi, J. Soh, F. Hongo, T. Miki

**VP27-05** MANAGEMENT OF POSITIVE SURGICAL MARGIN DURING THULIUM LASER ASSISTED LAPAROSCOPIC PARTIAL NEPHRECTOMY

Y. Bayazit, I. Aridogan, D. Abat, A. Aytutuldu, S. Erdogan, S. Doran

**VP27-06** LAPAROENDOSCOPIC SINGLE-SITE (LESS) PARTIAL NEPHRECTOMY VIA AN UMBILICAL APPROACH WITHOUT ACCESSORY PORTS

S. Rais-bahrami, M. Schwartz, A. Herati, M. Atalla, L. Kavoussi, L. Richstone

**VP27-07** LONG TERM EXPERIENCE WITH LAPAROSCOPIC PARTIAL NEPHRECTOMY FOLLOWING SUPERSELECTIVE TRANSARTERIAL EMBOLIZATION

G. Simone, R. Papalia, A. Bove, S. Guaglianone, E. Forastiere, M. Gallucci

**VP27-08** MULTICENTER EXPERIENCE WITH NON-ISCHEMIC LAPAROSCOPIC PARTIAL NEPHRECTOMY UTILIZING HABIB 4X™ BIPOLAR RADIOFREQUENCY ABLATION COAGULATOR

I. Derweesh, M. Allaf, J. Berkowitz, H. Atalah, S. Stroup, S. Parekattil

**VP27-09** LAPAROSCOPIC PARTIAL NEPHRECTOMY USING A MICROWAVE TISSUE COAGULATOR FOR T1 RENAL CELL CARCINOMA

N. Tanaka, K. Fujimoto, Y. Hirao—Japan

**VP27-10** TRANSPERITONEAL LAPAROSCOPIC NEPHRECTOMY FOR GIANT HYDRONEPHROSIS

M. Baptistussi, M. Morihisa, E. Gewher, A. Martins—Brasil

**VP27-11** LAPAROSCOPICALLY ASSISTED PERCUTANEOUS NEPHROLITHOTRIPSY IN SPECIAL CASES

M. Baptistussi, M. Morihisa, E. Gewher, A. Martins—Brasil

**VP27-12** THE RESULTS OF LAPAROSCOPIC NEPHRON SPARING SURGERY /NSS/ IN PATIENTS WITH KIDNEY CANCER

M. Baptistussi, M. Morihisa, E. Gewher, A. Martins—Brasil

**VP27-13** CREATING AN OBJECTIVE ASSESSMENT OF SURGEON PROFICIENCY FOR THE HILAR DISSECTION DURING LAPAROSCOPIC NEPHRECTOMY

E. Mcdougall, H. winfield, R. Sweet, C. Sundaram, M. Desai, S. Shichman

**VP27-14** DOES THE PRESENCE OF URINARY STONE DISEASE AFFECT THE PEROPERATIF AND POSTOPERATIVE COMPLICATION RATES OF LAPAROSCOPIC SIMPLE NEPHRECTOMY?

A. Tefekli, A. Tepeler, T. Akman, M. Binbay, M. Baykal, A. Müslümanoğlu

**VP27-15** SELECTIVE ARTERIAL EMBOLIZATION (SAE) PRIOR TO LAPAROSCOPIC PARTIAL NEPHRECTOMY (LPN) AS FIRST-LINE TREATMENT OF SYMPTOMATIC RENAL ANGIOMYOLIPOMA (AML)  $\geq 4$  CM: A RETROSPECTIVE ANALYSIS ON 18 CASES

U. Anceschi, A. Amici, C. Torcia, F. Peris, S. Lauretti—Italy

**VP27-16** THE ONLY SIGNIFICANT PARAMETER ASSOCIATED WITH DECREASED COMPLICATION RATES IN LAPAROSCOPIC NEPHRECTOMY: SURGEON'S EXPERIENCE

O. Sanli, T. Tefik, T. Mut, S. Karakus, M. Ortac, M. Tunc

**VP27-17** SINGLE-CENTER COMPARISON OF STANDARD LAPAROSCOPIC SURGERY AND HAND-ASSISTED LAPAROSCOPIC SURGERY IN TREATMENT OF RENAL MASSES

R. Leveillee, M. Aziz, J. Bracho ii, J. Shields, V. Bird

**VP27-18** IS IT POSSIBLE TO COMPLETE LAPAROSCOPIC SIMPLE AND RADICAL NEPHRECTOMY WITHOUT OPEN CONVERSION?

A. Kural, M. Tuna, H. Akpýnar, C. Öbek, F. Atuo, Ý. Tüfek—Türkiye

**VP27-19** RETROPERITONEAL LAPAROSCOPIC RADICAL NEPHRECTOMY FOR RENAL CELL CARCINOMA:REPORT OF 88 CASES

C. Xiaoming, W. Dongwen, Z. Xuhui

**VP27-20** LAPAROSCOPIC-ASSISTED CRYABLATION FOR RENAL CANCER IS NEFRONSPARING

L. Lund, M. Jønler, L. Pedersen, J. Abrahamsen

## **VP28: MISCELLANEOUS**

16:00–17:30 hr

**VP28-01** TREATMENT OF PARACALYCEAL CYST AND SECONDARY LITHIASIS WITH A SINGLE-SESSION LAPAROSCOPIC AND PERCUTANEOUS APPROACH

G. Caddeo, P. Usai, A. De lisa

**VP28-02** LARGE BLADDER STONE: PERCUTANEOUS SUPRAPUBIC CYSTOLITHOTRIPSY(PCCL) OR TRANSURETHRAL CYSTOLITHOTRIPSY(TUCL)?

M. Hosseini, A. Aryafar, A. Aminsharifi, A. Yousefi, R. Inaloo, A. Hassanpour—Iran

**VP28-03** MULTIMODAL THERAPEUTIC APPROACHES TO FORGOTTEN URETERAL STENTS

S. Rabani—Iran

**VP28-04** A RETROSPECTIVE STUDY FOR UROLOGIC COMPLICATIONS AFTER TRANSURETERAL LITHOTRIPSY (TUL) PROCEDURE IN 100 PATIENTS REFERED TO IMAM REZA HOSPITAL

M. Darabi mahboub, R. Taghavi, M. Namjoo—Iran

**VP28-05** COMPLICATIONS AND CONVERSIONS OF LAPAROENDOSCOPIC SINGLE-SITE SURGERY (LESS): MULTI-CENTER EXPERIENCE RESULTS FROM THE NOTES WORKING GROUP

B. Irwin, J. Cadeddu, C. Tracy, F. Kim, W. Molina, A. Rane, C. Sundaram, J. Raybourn iii, I. Gill, L. Kavoussi, R. Lee, M. Desai—USA

**VP28-06** PERCUTANEOUS NEPHROSTOMY (PCN) BY UROLOGIST

M. Hosseini, A. Aminsharifi, A. Aryafar, S. Ezatzadegan, M. Pakfetrat—Iran

**VP28-07** CLIPLESS LAPAROSCOPIC RETROPERITONEAL LYMPH NODE DISSECTION USING BIPOLAR ELECTROCOAGULATION FOR SEALING LYMPHATIC VESSELS; INITIAL SERIES

N. Simforoosh, H. Nasseh, P. Masoudi, M. Asle zare, S. Ghohestani, R. Eshratkha—Iran

**VP28-08** SURGICAL TECHNIQUE OF TRANSURETHRAL ENUCLEATION OF INTRAMURAL BLADDER LEIOMYOMAS

K. Polyzois, I. Galanos, C. Georgiou, I. Fokitis—Greece

**VP28-09** OUR EXPERIENCE OF ANTEGRADE MINIMUM INCISION ENDOSCOPIC SURGERY OF PROSTATE CANCER

T. Hosoi, H. Uchida, N. Takahashi, F. Murakami, K. Suzuki—Japan

**VP28-10** SINGLE PERCUTANEOUS ACCESS UNDER ENDOSCOPIC CONTROL FOR MANAGEMENT OF LARGE BLADDER STONES

E. Erkan, V. Sacak, G. Toktas, S. Ozkan, M. Demiray, E. Unluer

**VP28-11** PERCUTANEOUS RESECTION OF RENAL PELVIS UROTHELIAL CARCINOMA

G. Simone, M. Ferriero, R. Papalia, S. Guaglianone, E. Forastiere, M. Gallucci

**VP28-12** IS BACTERIURIA IN PATIENTS WITH NEPHROSTOMY TUBE AND COMPLETE OBSTRUCTION OF THE URETER LIMITED ONLY TO UPPER URINARY TRACT SYSTEM?

C. Toutziaris, P. Gritsios, V. Adamou, A. Giakoumelos, K. Hatzimouratidis

**VP28-13** LAPAROSCOPIC MANAGEMENT OF SYNTHETIC MESH EROSIONS OF THE BLADDER

J. Ma, A. S. herati, A. K. george, M. A. atalla, L. Richstone, L. R. kavoussi—United States

**VP28-14** PERCUTANEOUS CYSTOLITHOTOMY FOR CALCULI IN RECONSTRUCTED BLADDERS: THE UCLA EXPERIENCE

A. Breda, M. Mossangen, J. Harper, J. Leppert, P. Schulam, B. Churchill

**VP28-15** LONG-TERM RESULTS OF IMMEDIATE ENDOSCOPIC REALIGNEMENT OF COMPLETE POSTERIOR URETHRAL DISRUPTION

M. Sofer, A. Beri, H. Matzkin, I. Kaver

**VP28-16** ANTI-RETROPULSION DEVICES INCREASE STONE FRAGMENTATION EFFICIENCY WITH HOLMIUM:YAG LASER LITHOTRIPSY

B. Chew, L. Jonat, D. Lange, R. Paterson, J. Teichman

**VP28-17** URETEROSCOPICALLY ASSISTED TOTALLY LAPAROSCOPIC APPENDICULOVESICOSTOMY

A. Aminsharifi, R. Niroomand, A. Eslahi

**VP28-18** A CONTINUUM BASED APPROACH FOR SKILL ACQUISITION FOR DORSAL VEIN LIGATION USING THE LAPAROENDOSCOPIC SINGLE SITE SURGERY (LESS) PLATFORM

S. Kommu, T. Finnigan, A. Chakravarti, A. Golash, C. Luscombe, S. (sarg)—United Kingdom

**VP28-19** DRAINAGE OF SYMPTOMATIC HYDRONEPHROSIS IN PATIENS WITH LOCAL ADVANCED PROSTATE CANCER

C. Netsch, A. Beeck, T. Bach, A. Gross—Germany

**VP28-20** PROSPECTIVE COMPARISON OF STANDARD VERSUS TUBELESS MINI-PNL

G. Wendt-nordahl, F. Wezel, M. Michel, T. Knoll—Germany

**VS13: ROBOTICS—KIDNEY**

16:00–17:30 hr

**VS13-01** ROBOTIC-ASSISTED PARTIAL NEPHRECTOMY FOR TREATMENT OF RENAL TUMORS (VIDEO)

R. Ferreira coelho, K. J palmer, S. Chauhan, B. Rocco, M. Patel, V. Patel—US

**VS13-02** ROBOTIC PARTIAL NEPHRECTOMY FOR COMPLEX AND HILAR LESIONS

A. Bowen, B. Lee, M. Oommen, M. Raynor, U. Boylu—USA

**VS13-03** ROBOT ASSISTED LAPAROSCOPIC PARTIAL NEPHRECTOMY (RALPN) AND DOUBLE SLIDING WECK-CLIP RENORRAPHY TECHNIQUE: A CASE PRESENTATION

H. Akpinar, I. Tufek, F. Atug, S. Aksit, A. Kural—Turkey

**VS13-04** ROBOTIC PARTIAL NEPHRECTOMY: EARLY UNCLAMPING TECHNIQUE

B. Lee, M. Oommen, M. Raynor U. Boylu,—USA

**VS13-05** INJURY OF RENAL ARTERY DURING ROBOTIC PARTIAL NEPHRECTOMY

Y. Yoon, D. Kim, J. Lee, S. Park, H. Moon, T. Lee

**VS13-06** ROBOTIC-ASSISTED PARTIAL NEPHRECTOMY FOR PRESUMPTIVE T1B RENAL CELL CARCINOMA

A. Weizer, J. Montgomery

**VS13-07** SELECTIVE SEGMENTAL ARTERIAL CLAMPING FOR ROBOT-ASSISTED PARTIAL NEPHRECTOMY: ILLUSTRATION OF TECHNIQUE

B. Benway, S. Bhayani, R. Figenshau

**VS13-08** SINGLE-INCISION ROBOTIC SURGERY (SIRS) FOR RADICAL NEPHRECTOMY: ILLUSTRATION OF TECHNIQUE

B. Benway, R. Figenshau, S. Bhayani—USA

**VS13-09** T1B PARTIAL NEPHRECTOMY: ROBOTIC APPROACH WITH THE WASHINGTON UNIVERSITY TECHNIQUE

A. Wang, R. Figenshau, B. Benway, S. Bhayani

**VS13-10** ROBOTIC PARTIAL NEPHRECTOMY FOR RENAL HILAR MASSES

M. Patel, R. Laungani, A. Shrivastava, E. Kheterpal, M. Menon, C. Rogers—USA

**VS18: LAPAROSCOPY—KIDNEY**

16:00–17:30 hr

**VS18-01** LAPAROSCOPIC DONOR NEPHRECTOMY: OUR PRELIMINARY RESULTS

I. Yavascaoglu, H. Dogan, E. Gursoy, Y. Kordan, H. Vuruskan, B. Oktay—Turkey

**VS18-02** BRIDGING TECHNIQUE FOR LESS DONOR NEPHRECTOMY

D. Puder, K. Ebrahimi, C. Tenggardjaja, F. Jellison, L. Nicolay, D. Baldwin—USA

**VS18-03** LAPROENDOSCOPIC SINGLE SITE(LESS) DONOR NEPHRECTOMY

G. Arvind, D. Dhawan, A. Kurien, V. Muthu, R. Sabnis, M. Desai—India

**VS18-04** LAPAROENDOSCOPIC SINGLE SITE (LESS) PFANNENSTIEL DONOR NEPHRECTOMY

S. Andonian, M. Atalla, A. Herati, S. Rais-bahrami, L. Richstone, L. Kavoussi—USA

**VS18-05** LAPAROENDOSCOPIC SINGLE SITE (LESS) DONOR NEPHRECTOMY: ALTERNATIVE USE OF THE GELPORT DEVICE

A. Patel, W. White, G. Haber, R. Goel, S. Crouzet, J. Kaouk

**VS18-06** LAPAROSCOPIC RENAL TRANSPLANTATION (LRT): A NEW CHALLENGE  
A. Rosales, J. Salvador, G. Urdaneta, S. Esquena, M. Montlleó, H. Villavicencio—Spain

**VS18-07** ROBOTIC RADICAL NEPHRECTOMY FOR COMPLEX RENAL MASSES  
M. Patel, R. Laungani, E. Kheterpal, A. Pichurko, M. Menon, C. Rogers—USA

**VS18-08** LAPAROENDOSCOPIC SINGLE-SITE (LESS) RADICAL NEPHRECTOMY: INITIAL CLINICAL EXPERIENCE  
S. Jung, J. Park, E. Hwang, C. Im, D. Kwon—South Korea

**VS18-09** TECHNIQUE OF LAPAROSCOPIC ENDOSCOPIC SINGLE SITE SURGERY (LESS) RADICAL NEPHRECTOMY  
J. Stolzenburg, P. Kallidonis, G. Hellawell, M. Do, A. Dietel, E. Liatsikos

**VS18-10** SINGLE PORT ACCESS FOR SIMPLE NEPHRECTOMY IN NON FUNCTIONING RENAL UNITS—AN EVOLVING CONCEPT  
P. Ranjan, D. Dhawan, R. Baishya, A. Ganpule, M. Desai, M. Desai

**VS19: LAPAROSCOPY—ADRENAL**  
16:00–17:30 hr

**VS19-01** LAPAROSCOPIC ADRENALECTOMY: ULUDAG UNIVERSITY EXPERIENCE  
I. Yavascaoglu, Y. Kordan, H. Dogan, M. Danisoglu, H. Vuruskan, B. Oktay—Turkey

**VS19-02** LAPAROSCOPIC ADRENALECTOMY FOR LARGE ADRENAL MASSES  
R. Sotelo, A. Branco, M. Miranda, R. De andrade, O. Carmona, D. Canes—Venezuela

**VS19-03** LAPAROSCOPIC RESECTION OF PERIADRENAL PARAGANGLIOMA  
A. Tuncel, Y. Aslan, O. Han, S. Seckin, A. Atan

**VS19-04** LAPAROSCOPIC ADRENALECTOMY OF LARGE (>7CM), HYPERVASCULAR PHEOCHROMOCYTOMA  
N. Hamilton, S. Savage—United States

**VS19-05** LAPAROSCOPIC MANAGEMENT FOR EXTRA-ADRENAL PHEOCHROMOCYTOMA IN FOUR DIFFERENT CASES  
T. Pinheiro, E. Metrebián, F. Sepúlveda, F. Messeti, V. Ortiz, C. Andreoni

**VS19-06** ROBOTIC ADRENALECTOMY: SURGICAL TECHNIQUE AND OUTCOMES (THIS ABSTRACT IS ACCOMPANIED BY A VIDEO)  
H. Atalah, L. Yeung, P. Sijo, L. Su—USA

**VS19-07** SYNCHRONOUS TWIN TRACK PCNL  
R. Sabnis, G. Arvind, A. Shetty, V. Muthu, M. Desai—India

**VS19-08** PERCUTANEOUS CHOLECYSTOLITHOTOMY: A CASE FOR FULGURATION OF THE GALL BLADDER WALL  
S. Andonian, A. Rastinehad, A. Smith, D. Siegel—USA

**VS19-09** COMBINED PERCUTANEOUS ANTEGRADE & URETEROSCOPIC RETROGRADE APPROACH IN THE TREATMENT OF TOTAL URETERAL DISRUPTION AND URETEROVAGINAL FISTULA AFTER TOTAL LAPAROSCOPIC HYSTERECTOMY  
H. Shah, A. Khandkar, H. Sodha, S. Kharodawala, M. Bansal

**VS19-10** ROBOTIC DIVERTICULECTOMY IN A PEDIATRIC PATIENT (THIS IS ACCOMPANIED BY A VIDEO)  
M. Erhard, N. Le—USA

**VS20: RECONSTRUCTIVE LAPAROSCOPY 3**  
16:00–17:30 hr

**VS20-01** DISMEMBERED RETROPERITONEOSCOPIC PYELOPLASTY FOR THE TREATMENT OF SYMPTOMATIC URETEROPELVIC JUNCTION OBSTRUCTION IN A 12 YEAR OLD BOY WITH DUPLICATED COLLECTING SYSTEM  
S. Subotic, A. Gözen, T. Bayer, R. Gumpinger, J. Rassweiler—Germany

**VS20-02** STENTLESS ROBOT ASSISTED LAPAROSCOPIC DISMEMBERED PYELOPLASTY  
M. Lerner, C. Sundaram—USA

**VS20-03** INDIVIDUALIZED MANAGEMENT OF URETEROPELVIC JUNCTION OBSTRUCTION DURING ROBOT ASSISTED LAPAROSCOPIC DISMEMBERED PYELOPLASTY  
M. Lerner, C. Sundaram—USA

**VS20-04** LAPAROSCOPIC REPAIR OF RETROCAVAL URETER  
O. Sanli, T. Tefik, O. Aytac, E. Salabas, M. Karadeniz, C. Özsoy

**VS20-05** ROBOT ASSISTED PYELOPLASTY FOR URETEROPELVIC JUNCTION OBSTRUCTION  
I. Tufek, H. Akpınar, F. Atug, S. Aksit, A. Kural—Turkey

**VS20-06** IATROGENIC DIAPHRAGMATIC LESION: LAPAROSCOPIC REPAIR  
A. Celia, G. Zeccolini, G. Breda

**VS20-07** TRANSPERITONEAL LAPAROSCOPIC  
RETROCAVAL URETER CORRECTION

G. Franco, P. Francesco, G. Andrea, S. Antonio, I. Giacomo  
piero—Italy

**VS20-08** TRANSUMBILICAL LAPAROSCOPIC  
(NOTUS) PYELOPLASTY WITH STANDARD  
INSTRUMENTATION

B. Dauster, L. Dorea, C. Pugas, P. Furtado, M. Fucs—Brazil

**VS20-09** MANAGEMENT OF CROSSING VESSELS  
(AND OTHER FINDINGS) DURING ROBOTIC  
PYELOPLASTY

U. Boylu, B. Lee, R. Thomas—USA

**VS20-10** ROBOTIC REDO PYELOPLASTY  
IN THE PEDIATRIC POPULATION  
(ACCOMPANIED BY A VIDEO)

M. Erhard, N. Le—USA

## BR1: LAPAROSCOPY

### BR1-01 TANDEM TWO DIMENSIONAL VERSUS THREE DIMENSIONAL VIEWING IN LEARNING CURVE FOR EX VIVO SKILL ACQUISITION FOR LAPAROENDOSCOPIC SINGLE SITE SURGERY (LESS)

S. Kommu, T. Finnigan, D. Cartlidge, A. Golash, C. Luscombe, S. (sarg)—United Kingdom

**Background:** The inherent steep learning curve of working in a 3-Dimensional (3D) field with 2-Dimensional (2D) visual feedback is one of the main drawbacks in skill acquisition during laparoscopic urological surgery (LUS). We previously reported on the impact of simultaneous use of 2D and 3D visual feedback on the skill acquisition of a complex LUS step i.e. dorsal vein complex (DVC) ligation and vesicourethral anastomosis (VUA). We found that the coupling of 2D and 3D views, during the preliminary acquisition of the skills among trainees, narrows the learning curve in performing a DVC and VUA in the ex-vivo setting (Journal of Endourology. November 2008: A1–A310). LESS (Laparoendoscopic Single-Site Surgery) has recently been successfully utilised in performance of several urological procedures. The preliminary consensus, however, is that it demands technical expertise with a narrow margin for error than conventional LUS. Herein, we aim to identify the impact of the concept of Tandem 2-Dimensional versus 3-Dimensional viewing in the learning curve for ex vivo skill acquisition for Laparoendoscopic Single-Site Surgery (LESS) DVC and VUA.

**Methods:** A box model was fitted with an R-Port™ and camera. Articulated and conventional instruments were used to demonstrate basic exercises (e.g. glove pattern cutting, loop stacking and suturing) and advanced exercises (DVC ligation and VUA). This kit can be made at home with readily available raw materials. The kit comprises the LESS platform. The study involved 4 novices of which 2 were put into (GpA) and two into (GpB). GpA used a conventional 2D system with a single monitor and GpB used a module, which allowed real-time dynamic 2D views to be alternated with 3D views. An introductory tutorial of basic instrument handling and suturing was given to the candidates. The target tasks were based on an ex-vivo Level-3 Model for DVC and VUA (Kommu et al. J Endourol. Oct 2007:A1–A292). The time for the trainees to acquire the skill for target competence as judged by expert laparoscopic surgeons was tallied and the progress monitored.

**Results:** The results involved the LESS platform only. The candidates from GpB acquired target competence for DVC 2.3 times quicker than GpA candidates who used conventional 2D views. Similarly, GpB acquired target competence for VUA 2.8 times quicker than for GpA.

**Conclusion:** Tandem 2D alternating with 3D views helps to narrow the learning curve for the target skill acquisition for ex vivo DVC ligation and VUA in the LESS platform. The tandem movements allow the trainee to familiarise with the instrument to target task interplay. Once the initial skill is achieved, the trainee can switch to the 2D mode as dictated by the demands of the live human case. The Tandem 2D coupling with 3D approach using the

LESS platform could be a useful and cost-effective supplementary tool in training programmes. The system could be set up with minimal cost in training units without the financial exploits of commercial kits.

### BR1-02 THE IMPACT OF A DUAL-FOCUS SYSTEM ON THE LEARNING CURVE FOR EX VIVO SKILL ACQUISITION IN A LAPAROENDOSCOPIC SINGLE-SITE SURGERY (LESS) PLATFORM

S. Kommu, T. Finnigan, A. Chakravarti, A. Golash, C. Luscombe, C. Eden—United Kingdom

**Background:** Traditionally, for the development of optimal laparoscopic urological skills, the trainee practiced on a box model with a single camera and monitor giving a solitary view. In a previous study (Proceedings of the AUA Annual Meeting. Journal of Urology. 2008.) we applied a Dual-Focus System, which incorporated two views in performing a single task. We then tested the impact of this ‘Two-View’ or Dual-Focus System on the learning curve for vesicourethral anastomosis (VUA) and dorsal vein complex (DVC) ligation in laparoscopic radical prostatectomy. We found that the Dual-Focus approach allowed targeted skill acquisition for VUA and DVC ligation approximately two times quicker than the traditional single monitor system. Laparoendoscopic Single-Site Surgery (LESS) has recently been successfully utilised in performance of several urological procedures. The preliminary consensus, however, indicates that LESS requires technical expertise with an even narrower margin for error than conventional laparoscopic surgery. Herein, we applied the Dual-Focus System to decipher its impact on skill acquisition using the LESS platform for VUA in the ex vivo setting.

**Methods:** A LESS platform consisting of a box model (DIY-LTK™) was fitted with a multichannel single port (R-Port™). The visual feedback was either via a single camera/monitor system or a dual camera/monitor system (Dual-Focus) as previously described (Kommu et al. Journal of Endourology. November 2008: 1–340). The Dual-Focus approach involved placement of cameras at strategic angles in relation to the target task thus giving different visual perspectives of a given task. Autonomy™ Laparo-Angle™ Instruments from Cambridge Endo were used for this module. The target task was ex vivo VUA. The VUA task was based on a Level-3 model using the continuum based approach (J Endourol. 2007, 21(s1): A1–A292.). Four novices to laparoscopy were enrolled. Two were tutored and allowed to practice the task of VUA using the LESS Single Camera System and the other two used the LESS Dual-Focus System. The times for target task completion were tallied. These were assessed by expert laparoscopic urological surgeons. Specific patterns of eye movements, in relation to each of the monitors, were recorded and observed.

**Results:** The Dual-Focus System allowed skill acquisition towards the target task of VUA 3.3 times quicker than with the Single Camera/Monitor System. As a separate parameter, once the target

task skill set was achieved, the former allowed completion of a VUA with a speed of 1.8 times quicker than with the other mode. Candidates who used the Dual-Focus System were noted to have initial random and haphazard eye movements for approximately the first 90 minutes of practice. Following this initial 'Visual Adjustment Period', distribution of eye movements appeared to be well coordinated between the two monitors. The candidates using the Single Monitor System did not exhibit a Visual Adjustment Period. However, their task performance was noticeably slower during the test period.

**Conclusion:** The application of the Dual-Focus System, using the LESS platform for targeted skill acquisition i.e. ex vivo vesicourethral anastomosis, allowed for skill acquisition to be achieved over three times quicker than with the Single Monitor System. Furthermore, once this initial skill was achieved, the Dual-Focus System allowed the actual task to be completed approximately twice as fast as with the other mode. With current evolution of LESS and its rapid uptake, there is a potential use for the application of the Dual-Focus approach for skill acquisition. This should be explored as a supplementary tool to current modes of training in programmes.

### **BR1-03 THE EFFECT OF A NOVEL HEMOSTATIC AGENT, ANKAFERD BLOODSTOPPER® (ABS), ON RENAL TUBULAR APOPTOSIS IN RAT PARTIAL NEPHRECTOMY MODEL**

E. Huri, T. Akgül, M. Astarci, H. Üstün, C. Germiyanoglu—Turkey

**Background:** Partial nephrectomy is now acceptable approach for the management of localized small renal tumors. Bleeding and ischemic renal damage due to warm ischemia may decrease renal function. We investigated the effect of a novel hemostatic agent Ankbaferd (ABS), on renal tubular apoptosis and also on expressions of endothelial (eNOS) inducible nitric oxide synthase (iNOS) and apoptosis protease-activating factor-1 (Apaf-1) in the ipsilateral kidney after an experimentally formed partial nephrectomy in a rat model.

**Methods:** Twenty-four Wistar; divided into four groups. Group I (GI), partial nephrectomy (PN) with hilar control as conventional technique, Group II (GII), conventional technique with ABS, Group III (GIII), ABS application to renal parenchyma, Group IV (GIV), partial nephrectomy and ABS were performed without hilar control. At first month, all rats were sacrificed and nephrectomy materials were examined histopathologically.

**Results:** In GI, apoptotic cells were determined in 20% with iNOS, 20% eNOS, 10% Apaf-1. The percentages for GII, 10%, 20%, 5%, for GIII, 40%, 50%, 30%, for GIV, 5%, 5%, 3%, consecutively. Mean values were shown in Table 1. In GII, III, IV, there were no significant decrease in apoptotic cells to which ABS applied. The most percentage of apoptosis was shown in GIII accompanying with significant inflammation. The least percentage was determined in GIV, non warm ischemia group.

**Conclusion:** ABS that has a valuable hemostatic effect in rat partial nephrectomy, could vary apoptotic cells in different types of partial nephrectomy models.

### **BR1-04 HISTOLOGICAL EVALUATION OF RENAL TUMORS AFTER HYPERTONIC SALINE SOLUTION PERFUSION IN A KIDNEY REDUCTION MODEL FOR LAPAROSCOPIC SURGERY**

J. Manzano, E. Vicari, F. Lima, V. Ortiz, C. Andreoni

**Background:** Previous study was developed to evaluate the reduction in the total kidney volume and incisions using a 5% saline solution (SS) perfusion in a porcine model. The present study evaluated the possibility of changes in the histological evaluation after perfusion in malignant disease.

**Methods:** The study included 20 cases of renal tumors, that were removed intact after radical nephrectomy. A slice of the tumor (fat, capsule, tumor and kidney) was taken before perfusion for histological evaluation. Following, 500cc of 5SS was infused through the renal artery. The first 20cc drained from the vein was aspirated and sent to cytology evaluation. The entire kidney with the rest of the tumor was fixed in formol and sent for histological assessment. The studied parameters were histological type, Furhman grade, architectural standard, hyalinization and necrosis, and microvascular invasion.

**Results:** Conventional renal cell carcinoma was found in 90 % of the cases (18/20), 1 case of chromophobic renal carcinoma and onther case with rhabdoidy and oncocyctic components. The most usual grade was 2 of Furhman with necrosis and hyalinization. There were no histological differences before and after kidney perfusion with 5SS in all cases. All cytological analysis from the vein were negative for neoplastic cells.

**Conclusion:** Renal perfusion with 5SS neither changed the histological evaluation nor malignant cells could be found coming from the renal vein. The present result allows renal perfusion in renal tumors for renal shrinkage during laparoscopic radical nephrectomy to significantly reduce abdominal incision for extraction.

### **BR1-05 IRREVERSIBLE ELECTROPORATION (IRE): A NOVEL METHOD FOR RENAL TISSUE ABLATION**

C. Tracy, W. Kabbani, J. Cadeddu—USA

**Background:** Irreversible electroporation creates nano-scale pores within cellular membranes as a consequence of an electric field across the cell, resulting in athermal cellular death. Previous liver experiments demonstrated precise areas of cellular death, with relative sparing of vascular and biliary structures. We report the initial results using this technology in porcine kidneys.

**Methods:** Eight female Yorkshire pigs underwent a series of laparoscopic ablations using either monopolar or bipolar IRE (Angiodynamics, Queensbury, NY). Animals were sacrificed between 10 minutes and 14 days following ablation and kidneys were harvested for gross and histologic analysis, including NADH staining for cellular viability.

**Results:** 24 total ablations were performed and all animals lived until sacrifice without complications. Initial gross lesions were diffusely hemorrhagic, decreasing progressively in size (30–40%) to small white scars over the 14 day period. Immediately following IRE, ablated tissue was characterized by diffuse tubular desquamation, eosinophilia, and nuclear pyknosis, with absence of cellular viability by NADH. By seven days, there was diffuse cellular necrosis with early peripheral granulation changes, and by 14 days there was marked tissue granulation, chronic inflammation, and dystrophic calcification with early fibrosis and cellular contraction. Initial patchy urothelial injury and ulceration demonstrated signs of repair and viability by 14 days.

**Conclusion:** Renal IRE in the porcine kidney leads to predictable histologic changes characteristic of cellular death within 1hr of ablation, with relative urothelial sparing. Further animal studies are warranted to determine safety and efficacy of this novel ablation technology.



### BR1-06 PRELIMINARY INVESTIGATIONS WITH IRREVERSIBLE ELECTROPORATION IN IN-VIVO PORCINE KIDNEYS

R. Leveillee, N. Salas, C. Moore, M. Jorda, M. Sierra, J. Shields

**Background:** Introduction Irreversible Electroporation (IRE) is a minimally-invasive treatment modality that uses an electric field induced by high voltage direct current pulses to induce nanopores in the cell membranes and ultimately cell death. The purpose of this investigation was to assess the feasibility of IRE for renal tissue treatment in-vivo.

**Methods:** Methods Eleven Yorkshire pigs ranging between 40–56 kg were treated with the Nanoknife™ IRE system under general anesthesia with muscular blockade (pancuronium) through a midline incision and survived 0 to 18 days. After euthanasia, the kidneys were harvested and evaluated grossly and histologically. The voltage to inter-probe distance ratio at cortex and medulla and survival times were varied for two monopolar probes. The voltage was varied for one bipolar probe.

**Results:** Results Congestion, hemorrhage, and cell death were observed within and up to 5 mm outside of the grossly observed lesion. Dystrophic calcification was observed within 11 to 18 days. Lesion volumes were indistinct between cortex ( $0.06\text{--}2.28\text{ cm}^3$  @ 0 days;  $1.10\text{--}1.65\text{ cm}^3$  @ 11 days) and medulla ( $0.37\text{--}1.66\text{ cm}^3$  @ 0 days;  $1.65\text{--}3.14\text{ cm}^3$  @ 11 days). Lesion volumes decreased from one ( $6.3 \pm 2.0\text{ cm}^3$ ) to ten ( $2.0 \pm 1.2\text{ cm}^3$ ) days. Pulse disruptions occurred with bipolar probes resulting in inconsistent lesion volumes.

**Conclusion:** Conclusions IRE is a novel ablation modality that can create lesions of various sizes in renal tissue under a variety of parameters. Cell death is achieved within 18 days with preservation of gross architecture. Continued investigation is warranted to achieve optimal treatment parameters in the kidney.

### BR1-07 SURGICAL MANAGEMENT OF RENAL MASSES: TECHNOLOGY VERSUS ONCOLOGY

J. Miller, A. Benson, T. Tarter, B. Schwartz—United States

**Background:** Surgical treatment for renal masses has been shown to depend more on surgeon preference than patient or tumor characteristics. This suggests fundamental differences in the perspectives of urologic oncologists and laparoscopists. We hypothesize a coordinated approach involving a urologic oncologist and laparoscopist may reduce the impact of “surgeon factors”. We analyzed the coordinated practice pattern of two surgeons at a single academic institution and report patient outcomes for open radical nephrectomy (ORN), open partial nephrectomy (OPN), laparoscopic radical nephrectomy (LRN), and laparoscopic partial nephrectomy (LRN).

**Methods:** Demographic, clinical and pathologic characteristics were compiled from patient records. Results were compared between treatment groups using nonparametric ANOVA.

**Results:** From January 2004 to January 2008 120 patients underwent treatment for presumed renal malignancy by two surgeons. All minimally invasive procedures were performed by a fellowship-trained laparoscopist. All open surgeries were performed by one urologist who performs no laparoscopy. Demographics were similar between groups. Eighty-two patients (68%) were managed with laparoscopy. Patients undergoing ORN were more likely symptomatic than other groups ( $p < 0.001$ ). Patients undergoing ORN or LRN had significantly larger tumors than those undergo-

ing OPN, or LPN ( $p < 0.001$ ). Tumor stage and grade were highest among patients undergoing ORN ( $p < 0.001$ ), and the positive margin rate was also significantly higher ( $p < 0.001$ ). Hospital stay was shortest among the minimally invasive and nephron-sparing groups ( $p < 0.001$ ). Complications were not statistically different between the groups.

**Conclusion:** A coordinated approach to the treatment of renal masses involving both a urologic oncologist and endourologist may reduce the impact of “surgeon factors” on the type of surgery performed.

### BR1-08 COMPARISON OF THE FREEHAND® ROBOTIC CAMERA HOLDER TO HUMAN ASSISTANTS DURING THE ENDOSCOPIC EXTRAPERITONEAL RADICAL PROSTATECTOMY (EERPE)—A PROSPECTIVE RANDOMIZED STUDY OF 50 CASES

J. Stolzenburg, T. Franz, M. Do, K. Turner, E. Liatsikos

**Background:** With about 450 operations per year, endoscopic extra peritoneal radical prostatectomy (EERPE) is the standard surgical therapy of the organ-confined prostate cancer in our centre. Erroneous camera movements and communication problems with the camera holder are troublesome during this demanding procedure. Ideally the surgeon should operate the camera himself, but feasibility studies are poorly reported.

**Methods:** We compared the use of a robotic camera holder (Freehand®, ProSurgics, Bracknell, United Kingdom), controlled by head movements of the surgeon and a foot pedal, with a human camera holder in a series of EERPE ( $n = 25$  per group). The total operative time, time for each surgical step, number of camera movements, number of movement errors, number of times the lens was cleaned, blood loss, integrity of the anastomosis (cystogram) and margin status were compared and analyzed by Students t-test.

**Results:** The number of camera movements (129.2 versus 160.5;  $p < 0.001$ ), movement errors (3.54 vs. 6.72;  $p < 0.001$ ) and lens cleaning events (3.13 vs. 5.56;  $p = 0.005$ ) were significantly lower in the Freehand® group than the human camera holder group. There were no significant differences in the operative time (84 min 33 s vs. 83 min 32 s,  $p = 0.775$ ), blood loss (220 ml vs. 219 ml,  $p = 0.977$ ), positive margins (both 5%) or incidence of urine leak (1 patient in each group).

**Conclusion:** Use of the Freehand® robotic camera holder allows the surgeon to control the laparoscope and reduces camera errors. The laparoscopic picture was clear and stable. The device is safe to use and does not prolong the operative time or adversely affect complication rates.

### BR1-09 ROLE OF ULTRASOUND GUIDED TRANSVERSUS ABDOMINIS PLANE (USTAP) BLOCK IN ANALGESIC SUPPLEMENTATION FOR LAPAROSCOPIC RADICAL PROSTATECTOMY—PRELIMINARY FINDINGS

S. Kommu, A. Crosby, Z. Hashim, A. Golash, C. Luscombe, A. Augustine—United Kingdom

**Background:** Ultrasound Guided Transversus Abdominis Plane (USTAP) Block is a new regional anaesthetic technique that aims to block the abdominal neural afferents by instillation of local anaesthetic into the neurofascial tissue plane that lies between the transversus abdominis and internal oblique musculature. We conducted a preliminary evaluation of the analgesic efficacy of this approach for Laparoscopic Radical Prostatectomy (LRP) as compared to other modes of pain control.

**Methods:** Forty men undergoing LRP were enrolled in this prospective study. Patients were given different modes of analgesics. Group 1 (n = 15) had general anaesthetic alone (GA), Group 2 (n = 5) had GA and Epidural. Group 3 (n = 13) had GA and PCA and Group 4 (n = 7) had USTAP. USTAP involved a bilateral neurofascial plane injection of Bupivacaine® between the transversus abdominis and internal oblique muscles. All four groups received patient requested acetaminophen and non-steroidal anti-inflammatory drug in the postoperative period as required. Each patient was assessed by a blinded investigator upon recovery, 60 min and 24 h postoperatively. Postoperative visual analogue scale pain scores were tallied based on a ten point score. [GA-General Anaesthetic; PCA-Patient Controlled Analgesia].

**Results:** The number of patients requiring morphine in the first 24 hours was GA [7/15 = 47%], Epidural. [5/5 = 100%], GA + PCA [13/13 = 100%] and GA + USTAP [1/7 = 14%]. Mean postoperative visual analogue scale (VAS) pain scores at 60 minutes were between 0 and 1 for all groups with no significant difference in pain in the first 60 minutes of recovery. At 24 hours, mean VAS pain scores were GA [3.5 (range 0–5)]; GA + Epi. [3.0 (range 1–5)]; GA + PCA [2.0 (range 1–3)] and GA + USTAP [1.2 (range 0–2)]. There were no complications associated with the USTAP block. In rank order the patients who had the highest pain quotients were GA, GA + Epidural, GA + PCA and GA + USTAP.

**Conclusion:** USTAP Block significantly reduced postoperative morphine consumption in the first 24 Hours and patients in the USTAP had the least pain scores when compared with other modes of analgesics. There were no complications associated with the USTAP block. Ultrasound Guided Transversus Abdominis Plane (USTAP) Block offers satisfactory analgesic effect for the target patients undergoing LRP and appears to be safe. The role of USTAP in LRP and other minimally invasive urological procedures should be explored further.

#### **BR1-10 DYNAMIC CAMERA AND INSTRUMENT MOVEMENT DURING MINIMALLY INVASIVE UROLOGICAL SURGERY—NEED FOR A STANDARD PLATFORM FOR COMMUNICATION**

S. Kommu, T. Finnigan, A. Chakravarti, A. Golash, C. Luscombe, S. (sarg)—United Kingdom

**Background:** Communication is an important tool in all aspects of task completion especially when a team effort is involved. Minimally Invasive Urological Surgery (MIUS) has inherent challenges making optimal communication skills vital. The entire team needs to communicate well. Communication is particularly important between the operating surgeon and human camera driver and/or

active assistant. Several ad hoc terminologies are used by both operating surgeon and assistant causing confusion and suboptimal task completion. Terms such as ‘move up’ or ‘get in’ are just two examples of the non standardised language used in MIUS causing redundant movements, confusion and often frustration. We identified standard terminology that causes the least error when the operating surgeon issues a verbal command requesting a particular movement by the human camera driver and/or active assistant. We tested this terminology and propose its use as a useful means of clear communication.

**Methods:** We first identified common words used in the English language that indicate key movements involving movement of a camera or instrument(s) along a three dimensional plane of axis. Ten randomly chosen candidates, 5 medical and 5 nonmedical, ranging age 18–55 yrs were introduced to a box kit with a camera device. A fluorescent object was placed suspended in the box. Candidates were commanded randomly with a series of ad hoc statements and task completion was graded as (a) Correct Task for Intended Command [CTIC], (b) Incorrect Task for Intended Command [ITIC] and (c) Unsure about Intended Command [UIC]. We identified several commands that consistently led to correct task completion. We also identified those that caused one to be unsure. The CTIC’s were tallied and tested on a further 10 candidates 5 medical and 5 nonmedical, ranging age 22–57 yrs.

**Results:** There was no difference in command response between medical and nonmedical candidates. The terminologies which gave the highest scores for CTIC were identified as the commands that are most accurately executed with minimal confusion and/or error. For camera movement to a particular area on the X-axis, the command was ‘move view to head’ or ‘move view to foot’ depending on target zone. For camera movement to a particular area on the Y-axis, the command was ‘move view to roof’ or ‘move view to floor’. For camera movement to a particular area on the Z-axis, the command was ‘move view into patient’ or ‘move view away from patient’. For the latter ‘zoom in’ and ‘zoom out’ respectively was equally effective. When issuing a command, starting with the word ‘move’ leads to less error. Feedback from candidates indicated that an even more optimal mode of communication would be to follow a command with a reason for the command e.g. ‘move camera to head so I can see the upper pole of the kidney’.

**Conclusion:** We propose that the simple commands for movement of camera during Minimally Invasive Urological Surgery outlined should be used for optimal communication between surgeon and camera man and/or active assistant. In the era of mentorship, vistorship and global networking among laparoscopic and robotic urological surgeons the need for a standard platform for communication is evident.

## BR2: ENDOUROLOGY I

### BR2-01 FLOUROSCOPIC ORGAN AND TISSUE SPECIFIC RADIATION EXPOSURE BY SEX AND BMI DURING URETEROSCOPY

N. Krupp, R. Bowman, B. Hill, K. Ebrahimi, J. Smith, D. Baldwin—USA

**Background:** Although the radiation exposures for CT and plain film imaging have been characterized, the tissue radiation levels received during fluoroscopy have not been well described. The purpose of this study was to determine if tissue radiation exposure during conventional ureteroscopy differed by gender or increased body mass index (BMI).

**Methods:** Eight human cadavers were obtained. A mean ureteroscopic fluoroscopy time of 145 seconds (retrospectively collected 2003–2006) was utilized. All fluoroscopy was performed using a GE, 9900 Elite C-arm. Fluoroscopy time was simulated for left ureteroscopy. Radiation exposure was measured using Thermo Fisher Scientific thermoluminescent dosimeters at ipsilateral cornea, anterior and posterior skin, bilateral lung bases, kidneys, ureters, gonads and the bladder. The dosage was compared in relation to laterality, BMI and gender. The Mann-Whitney and Wilcoxon Signed Ranks Test were used for comparison with  $p < 0.05$  considered significant.

**Results:** Radiation dose was significantly lower in contralateral organs (kidney, ureter, lung) ( $p < 0.05$ ) and for BMI  $< 30$  ( $p < 0.05$ ). However, with BMI  $> 30$  exposure difference by organ was not seen (all  $p > 0.05$ ). There was significantly higher mean bilateral gonadal dose in female cadavers (2.6 mSv) compared to males (0.33 mSv;  $p = 0.03$ ). Maximum exposure was to the posterior skin with doses as high as 15.9 mSv which is equivalent to 520 PA chest X-rays.

**Conclusion:** Non-targeted organs received less radiation exposure as expected, except with BMI  $> 30$  where contralateral organs received a similar dose. Gonadal doses in females were significantly higher. Fluoroscopy contributes a significant amount of radiation and steps should be taken to minimize patient exposure during ureteroscopy.

### BR2-02 EVALUATION OF SIX HOLMIUM:YAG OPTICAL FIBERS FOR URETEROSCOPY: WHAT'S NEW IN 2009?

B. Knudsen, J. Teichman

**Background:** Prior study has shown that holmium:YAG laser fiber performance differs among manufacturers. This study was designed to determine the performance and threshold for failure of six newly available holmium:YAG laser fibers from Cook Medical and Fibertech GmbH.

**Methods:** Six different commercial available fibers were evaluated: two were supplied by Fibertech and have core sizes of 272 and 365 microns respectively with non-tapered connectors. Four fibers were supplied by Cook Medical (OptiLite™) and have core sizes of 150, 200, 273, and 365 microns respectively. The OptiLite™ 150 and 200 micron fibers have tapered connectors, while the 273 and 365 micron fibers have non-tapered connectors. All fibers were evaluated for flexibility, threshold for failure during bend testing with laser activation, and true fiber diameter. Flexibility was measured by maximally deflecting a Stryker FlexVision U-500 ureteroscope with the fiber in the working channel. The diameter of each fiber was mea-

sured by digital micrometer. Failure threshold was assessed by bending the fibers to 180 degrees beginning with a radius of 1.25 cm. A Lumenis VersaPulse 100 W holmium:YAG laser was operated at 1.2 J and 10 Hz for 1 minute or until fiber fracture. The bend radius was reduced in 0.25 cm increments and the testing repeated until a minimum bend radius of 0.5 cm was reached or until the fiber failed. Baseline energy transmission was measured by recording the mean of 50 pulses (0.5 J, 10 Hz) prior to bend testing and repeated after each bend test trial. Three fibers samples of each model were tested for a total of 18 fibers.

**Results:** The Cook OptiLite™ 150 had lower energy transmission compared to all other fibers tests ( $p < 0.01$ ) but was the most flexible. The remaining five fibers demonstrated no difference in energy transmission at initial testing. Baseline deflection of the endoscope with no fiber in the channel was 265°. The OptiLite™ 150 was the most flexible fiber and deflected 262°, followed by the OptiLite™ 200 (255°), the OptiLite™ 273 (240°), the FiberTech 272 (236°), the FiberTech 365 (188°) and the OptiLite™ 365 (186°). The OptiLite™ 273 did not fail during bend testing with laser activation while the OptiLite™ 365 failed at the largest bend radius (1.25 cm) ( $p < 0.01$ ). Comparing fibers of similar core size, the Cook OptiLite™ 273 was smaller in diameter, more flexible, and less likely to fail when activated in a bent configuration ( $p < 0.01$ ) compared to the FiberTech 272. Conversely, the FiberTech 365 was smaller in diameter, more flexible, and failed at a tighter bend radius ( $p < 0.01$ ) as compared to the Cook OptiLite™ 365.

**Conclusion:** Commercially available holmium:YAG laser fibers continue to differ significantly in their performance characteristics. The Cook OptiLite™ 150 had the worst energy transmission suggesting loss at the connector.

### BR2-03 DESTRUCTION OF STONES IN THE KIDNEY, BLADDER AND URETER WITHOUT HARMING CATHETER AND BASKET MATERIAL USING AN INNOVATIVE LOW-ENERGY LASER SHOCKWAVE MODE

J. Neymeyer, T. Wülfing, C. Bäcker, A. Apostolidis, M. Beer

**Background:** Using conventional systems for stone destruction such as Lithotripters, Ho:YAG lasers and alike is proven to have significant disadvantages regarding efficacy and intra-operative complications. Regarding lasers, in particular the negative effect of induced energy on sensitive material such as metal baskets or catheters are to be mentioned. Our aim was to demonstrate the first effective and flexible method of stone destruction without such side effects in the OR.

**Methods:** This study included a total of 10 patients that have undergone treatment of stones in kidney, bladder and ureter. For intraoperative fixation of the stones, regular metal baskets were used. In two cases, the destruction of stones sticking to a catheter was required. Depending on the stone consistency, the multidisciplinary laser DIOLAS LFD 3000 was switched between a set of programs for effectively destroying the targeted material.

**Results:** Highly interesting results were achieved in particular using a newly developed low-energy treatment program that has proven to induce no negative effect on sensitive material such as metal baskets or catheters. Even a direct contact with aforementioned elements did not have destructive impact. Still, the targeted stones were destroyed successfully.

**Conclusion:** The new treatment method enabled by the laser DIOLAS LFD 3000 opens up a whole range of future improvements in the destruction of stones. Further results will be published in the following months.

#### BR2-04 FEMTOSECOND LASER LITHOTRIPSY

J. Teichman, J. Qiu, R. Kuranov, A. Mcelroy, T. Wang, T. Milner

**Background:** Light emitted from a near infrared (800 nm wavelength, 140 fs duration) femtosecond laser is capable of plasma induced ablation of various materials. We tested feasibility of femtosecond laser lithotripsy.

**Methods:** Human calculi of greater than 90% calcium oxalate monohydrate (COM), cystine, and magnesium ammonium phosphate hexahydrate (MAPH) were hydrated and targeted with femtosecond laser light in vitro. Ablation crater diameter and depth were measured using spectral domain optical coherence tomography. The size of ejected debris was characterized by optical microscopy. Ablation dynamics were visualized with a pump-probe imaging technique and correlated to pressure transients measured by a polyvinylidene fluoride needle hydrophone. Stone retropulsion was monitored by high speed camera.

**Results:** Ablation craters resulting from femtosecond laser irradiation were observed for all calculi compositions. Largest ablation volumes were achieved on CYST stones. Crater diameter and depth varied from tens of microns to several hundred microns when 1000 femtosecond pulses were applied to calculi. Debris size was in the micron range. Pump-probe imaging showed that debris ejection occurred after separation of a shock wave from the central plasma. Peak pressure transients were <2 bars, indicating that photomechanical forces were not responsible for calculi ablation. No retropulsion was observed, even for stone mass as small as 0.04 g.

**Conclusion:** Femtosecond laser radiation can ablate urinary calculi of soft and hard compositions through a plasma-mediated mechanism without retropulsion. Size of debris fragments are smaller than those produced in Ho:YAG lithotripsy. Retropulsion does not occur for the parameters tested.

#### BR2-05 INSTANTLY PHASE-II TUBELESS MINI-PERCUTANEOUS NEPHROLITHOTOMY (REPORT OF 54 CASES)

Z. Xiao-feng, L. Fu-lin, Jun—China

**Background:** To evaluate the feasibility and safety of instantly phase-II tubeless mini-percutaneous nephrolithotomy (MPCNL).

**Methods:** The data of 54 cases receiving instantly phase-II tubeless MPCNLs were summarized retrospectively. All the nephrostomy tubes were removed at the postoperative time of 12 h ~ 24 h in case of no obvious haematuria, urinary tract infection and unnecessary second endoscopic examination. The double-J tubes were placed to guarantee sufficient internal drainage, and removed after a month. The cases were compared with those receiving tubeless MPCNLs, and those who were subjected to traditional MPCNLs with placement of a nephrostomy tube. The parameters including the operative time, degree of hydronephrosis, renal function, level of hemoglobin, transfusion requirement, analgesia requirement, hospital-stay time, complications, success rate and cost were analyzed.

**Results:** Instantly phase-II tubeless MPCNLs were performed successfully on 54 cases. The patients who underwent instantly phase-II tubeless MPCNLs and tubeless MPCNLs needed less analgesia, hospital-stay time and cost than those receiving traditional MPCNL ( $P < 0.05$ ). No statistically significant difference

was found in the operative time, degree of hydronephrosis, renal function, decreasing of hemoglobin, transfusion requirement, complications and success rate among the three groups ( $P > 0.05$ ). No obviously urinary tract infection, urinous infiltration and perinephric urinary cyst occurred during follow-up.

**Conclusion:** Instantly phase-II tubeless MPCNL appeared to be feasible, safe, and effective. Compared with the traditional MPCNL, it showed less pain, shorter clinical convalescence and less cost; while compared with the tubeless MPCNL, it avoided the hemorrhagic risk.

#### BR2-06 MICROCT INVESTIGATION OF THE STONES TAKEN FROM PERCUTANEOUS NEPHROLITHOTOMY AND URETEROSCOPIC STONE SURGERY WITH SOUND WAVE OR PNEUMATIC LITHOTRIPTERS

E. Huri, I. Tatar, C. Germiyanoglu, T. Karakan, H. Çelik, O. Ersoy—Turkey

**Background:** We tried to observe ultrastructural characteristics of the stones, which were taken from percutaneous nephrolithotomy with ultrasonic lithotripter and ureteroscopic stone surgery with pneumatic lithotripter, with MicroCT imaging.

**Methods:** The patients, who had a renal or ureter stone diagnosis and were recommended one of the endoscopic surgery techniques, were included in this study. After surgery, the stones were investigated by microCT as three groups. Group 1 was PNL and ultrasonic lithotripsy, group 2 was USS and pneumatic lithotripsy and group 3 was stone removal without using lithotripter as a control.

**Results:** All samples were scanned using microfocus CT scanner (SkyScan 1174, SkyScan, Aartselaar, Belgium) and the scanning procedure was completed using 50 kV X-ray tube voltage, 800  $\mu$ A anode current, 3 degree rotation step, resulting in a pixel size of 10–18  $\mu$ m. These digital data were further elaborated by a reconstruction software (NRecon) for attenuation measurement and 3D model creation software (CTan) for surface rendering. We determined internal structures of the stones according to their attenuation values and found one third of them were homogenous. We observed that heterogeneity increased stone fragility because of apatite crystals and radiolucent voids and it facilitated stone comminution with ultrasonic or pneumatic lithotripters.

**Conclusion:** We confirmed our morphological data with scanning electron microscopy.

#### BR2-07 IN VIVO DETERMINATION OF URINARY STONE COMPOSITION USING DUAL ENERGY COMPUTED TOMOGRAPHY WITH ADVANCED POST-IMAGE ACQUISITION DATA PROCESSING

D. Zilberman, M. Lipkin, M. Ferrandino, D. Boll, D. Albala, G. Preminger—USA

**Background:** Characterization of urolithiasis using non-invasive methods can potentially affect clinical management. To date, diagnostic imaging with computed tomography (CT) cannot reliably differentiate stone composition, despite its high sensitivity and specificity for stone detection. Recently, in vitro assessments of Dual Energy CT (DECT) have shown significant results in assessing urinary stone composition. This study aims to assess the ability of DECT to predict stone composition in vivo using post-image acquisition data processing.

**Methods:** Following IRB approval, patients scheduled to undergo ureteroscopic or percutaneous management of urinary calculi and who had pre-operative indication to undergo CT imaging were of-

ferred DECT. All enrolled patients had stones harvested at the time of surgical management and analyzed via infrared spectroscopy. A fellowship trained radiologist analyzed the DECT and attempted to predict urinary stone composition prior to surgical intervention and stone analysis using a post-processing algorithm (Uslope).

**Results:** Seventeen patients have been enrolled and analyzed. Infrared spectroscopy demonstrated stone composition in these patients to include 2 patients with 100% uric acid, 2 patients with  $\geq 90\%$  struvite, 1 patient with 60% brushite and 12 patients with  $\geq 60\%$  mixed calcium oxalate monohydrate/dihydrate and/or calcium phosphate. DECT employed prior to surgical removal and chemical analysis accurately predicted all major stone components in this cohort.

**Conclusion:** Dual Energy CT appears to accurately predict the major components of urinary stone composition in vivo. This in vivo assessment may permit optimization of the pretreatment clinical strategy. Additional work to distinguish types of calcium based urinary stones and to corroborate these findings is indicated.

### BR2-08 CALCIUM PHOSPHATE STONE MORPHOLOGY: PLAIN RADIOGRAPHIC FINDINGS AND INTEROBSERVER VARIABILITIES

H. Tokgoz, O. Turksoy, A. Yildiz, I. Unal, B. Erol, S. Toparli

**Background:** Visual appearance of pure calcium phosphate (CaP) urinary stones by its morphology from plain radiographs (KUB) were investigated.

**Methods:** We reviewed patients with urinary stone disease who underwent stone surgery. Among cases with crystallographically analyzed stones; 60 patients with pure CaP renal or ureteral stones (greater than 1 cm) were selected. Two endourologists and a uroradiologist familiar with the radiographic patterns of different types of pure stones were invited separately, to evaluate pretreatment KUB.

**Results:** Four different radiographic patterns were identified mainly with the assistance of previous studies. Smooth edged, homogenous stones with denser opacity were included in Group 1. Stones with irregular edges and stippled border were included in Group 2. Relatively uniform stones with radial striations and moderate density were decided to form Group 3. Calculi with the least radiodensity and loosely aggregated with a lacy structure were included in Group 4. Overall, 68.9% of CaP calculi were included in Groups 1 and 2 by all participants. Best concordance between endourologists and the uroradiologist was demonstrated in the evaluation of smaller calculi ( $<150\text{ mm}^2$ ).

**Conclusion:** On KUB, CaP urinary calculi were mostly seen as dense relatively homogenous stones and sometimes with stippled borders. With the increase in pretreatment stone size, interobserver and interdisciplinary variabilities increased.

### BR2-09 HYDROFLotation MAGNETIC AIDED ENDOLUMENAL NAVIGATION—PRELIMINARY PLATFORM IN EX-VIVO SETTING FOR THE NEXT PARADIGM IN MINIMALLY INVASIVE UROLOGICAL SURGERY

S. Kommu—United Kingdom

**Background:** Navigation of endolumenal devices such as image rendering capsules have been described for diagnostic purposes in the animal, and more recently, the human models. In urology, the ureter is a prime luminal structure that often needs to be explored for diagnostic and therapeutic purposes. Whereas ureteroscopy, conventional imaging and extracorporeal therapies are useful tools in

many instances, there is a paucity of atraumatic and real-time navigation systems to aid in diagnostic and therapeutic procedures involving the ureters and renal pelvis. A novel device using a flotation mechanism in a water filled environment was developed and its navigation achieved with magnetic aided guidance. The device was tested for propulsion and real-time control in the ex-vivo setting.

**Methods:** An Endolumenal Bionic Worm (EBW) with a magnetic core was developed and introduced into synthetic lumens (SL) and supermarket chicken luminal structures. The later involved the gastrointestinal luminal tissue of supermarket chicken i.e. the ex-vivo equivalent of a ureter ureteric substitute lumens (USL). The device was successfully placed in an axis of a wired skeletal platform and its propulsion controlled by magnetic guidance. The natural peristaltic movement of the ureter poses further hindrance to endolumenal navigation. Endolumenal levitation was achieved in this model by utilising hydroflotation thus obviating the need for levitation and tangent stabilization that require complex computer-aided feedback control systems. The lumens were filled with water and both ends secured to prevent leakage. Navigation was graded by (a) achievement of the EBW in propulsion to premarked sites (b) ability to remain static when required and (c) trauma to the USL. The structures were observed under the microscope for breach following the exercises. Navigation was observed in 10 SLs and 10 USLs.

**Results:** The EBW was successfully steered using the magnetic guidance system with hydroflotation. The navigation system allowed premarked targets to be reached and permitted the device to remain static at sites as required. Observation of endolumenal surfaces did not reveal evidence of trauma in either model.

**Conclusion:** Hydroflotation Magnetic Aided Endolumenal Navigation (HMAEN) of a micro device was achieved endolumenally with targeted real-time control and with no observed trauma to the structures. HMAEN can be used to guide devices like the EBW to permit diagnostic ureteroscopy, biopsy of ureteric and renal pelvis lesions thus ushering the platform for the next paradigm in endolumenal urological procedures. Studies are currently underway for stone ablation via the EBW in the ex-vivo setting.

### BR2-10 CHANGING IN THE FUNCTIONAL ACTIVITY OF MEGAURETER AFTER ITS ENDOSCOPIC TREATMENT IN CHILDHOOD

Z. Sabirzianova—Russia

**Background:** Congenital ureteral dilatation may be caused by functional disorders of ureteral musculature. There are many reports about endoscopic treatment of nonobstructive megaurether, using different kinds of internal stents for it. The reasons of the effectiveness of such treatment evaluated insufficient. We suppose that stenting changes peristaltic activity of wide ureter and thus is restored urodynamics of upper urinary tract.

**Methods:** we used ultrasound for assessing peristaltic activity of distal part of megaureter before stenting and after it. For assessing quality and quantity of contractile function we counted frequency of megaureter contractions per minute and amplitude of the ureteric emptying (%).

**Results:** 90 children with onside or doubleside nonobstructive megaureter were treating by the placement of internal stents for a month (126 ureters). Before stenting 78 of them showed weak contractile activity (1–2 contractions per minute, amplitude each of them was about 10%). 48 megaureters had save contractile activity (6–8 contractions per minute with amplitude 85–90%) before stenting. Right after stents removing (the next day) save

contractions became poor. But through the few months we saw increasing of amplitude to 50% and frequency to 3–4 per minute in all megaureters, which were weak contractions at first. Megaureters with save contractile function as a rule became narrow, so they can't be founded on the ultrasound.

**Conclusion:** possibly that the restoration of urodynamic of upper urinary tract in stenting megaureter occurs as a result the stimulation of the contracting activity of the wide ureter.

## BR3: UROLITHIASIS

### BR3-01 CYSTINURIA IN EUROPE: FIRST RESULTS OF A NEWLY ESTABLISHED MULTICENTRE DATABASE

T. Knoll, D. Jocham, J. Rassweiler, J. de la Rosette, G. Wendt-Nordahl, P. Alken

**Background:** Cystinuria (CU) leads to recurrent urinary stone formation. Preventive measures rarely achieve long-term control. Aim of this study was to establish a European database that allows for analysis of current treatment modalities and to develop new therapies.

**Methods:** European Intra-Renal Surgery Society (EIRSS) members were asked to complete mailed questionnaires. All patients regularly seen were collected and recorded in a SQL database. Assessed parameters included: Age, family history, age at diagnosis, gene analysis, stone recurrences, history of interventional therapy, history and current medical/dietary stone prevention, functional data (blood and 24-hrs-urine lab, renal scintigraphy).

**Results:** 83 patients entered the database since October 2006. So far, 11 centres from six countries do participate (Germany, Austria, Italy, Great Britain, Sweden and The Netherlands). Mean age was 31.7 yrs. (6–72), gender ratio was 1.4:1 male/female. Only 6 patients had CU family history. Long-term f/u was available for most pat. with mean f/u of 22 yrs. (0–35). Stone formation rate is 0.58 stones/pat./year. First dx was made at mean age of 19 yrs. Current stone preventive measures were: none (2/83), diuresis only (3/83), alkalinization (44/83), ascorbic acid (12/83), tiopronin (32/83) and captopril (1/83). Multiple procedures were performed in all pat. (mean/pat.): 7.2 SWL, 2.1 PNL, 2.6 URS, 0.7 open/lap. 2 patients underwent nephrectomy, 1 patient received a transplant kidney. Gene analysis was performed only in one patient.

**Conclusion:** This new multicentre database may contribute to a better understanding of pathophysiological mechanisms and to improve therapeutic approaches to optimize the management of cystinuria. The low number of cystinuria family history could indicate a high rate of spontaneous mutations. Gene analyses have to clarify this issue and could—after correlation with clinical data—be supportive in predicting the course of cystinuria. The common interventional therapies as well as the high rate of tiopronin and controversial drugs (e.g. ascorbic acid) underline the need for an optimization of treatment algorithms.

### BR3-02 ACUTE EFFECTS OF URETERAL STONE ON URETERAL DYNAMICS IN A PORCINE MODEL: AN IN-VIVO STUDY COMPARING THE EFFECTS IN A SOLITARY KIDNEY VERSUS URETERAL STONE IN THE PRESENCE OF A NORMAL CONTRALATERAL KIDNEY

R. Venkatesh, N. Das, S. Labarbera, G. Baca, A. Tawfik, R. Figenschau—USA

**Background:** Acute changes in ureteral activity following ureteral stone obstruction in a solitary kidney is not clear. We studied the acute changes in ureteral dynamics including renal resistive index from stone obstruction in a solitary kidney. This was compared with a non-obstructed (unilateral and bilateral) system. Understanding the above changes may be important clinically in the pharmacologic or surgical management of patients with ureteral stone obstruction.

**Methods:** We studied ureteral peristalsis, intrapelvic pressure (IPP) and renal resistive index (RI) in 24 female domestic pigs divided into 4 groups. Group 1: Controls with bilateral kidneys and no stone, Group 2: animals with a ureteral stone with normal contralateral system, Group 3: animals with solitary kidney but no ureteral stone, Group 4: animals with ureteral stone in a solitary kidney. Peristalsis was studied by a magneto-resistive sensor and EMG electrodes deployed on the extraluminal ureteral surface exposed through a lumbotomy incision. The IPP was measured by a pressure transducer in the renal pelvis and RI (arterial) by Duplex ultrasound. In the solitary kidney group, laparoscopic nephrectomy was performed before studying the contralateral ureter with and without a stone. Ureteral dynamics including urine output was recorded before and for 5 hours after placement of an appropriate sized stone in the proximal ureter. The intravenous fluid infusion was kept at a standard rate of 5 ml/kg/hour for all animals. Stone movement was monitored using digital fluoroscopy. The medians of the above activity parameters were compared between different groups.

**Results:** There was no significant differences in the average urine output in animal groups (135–150 mls/hr) except in the solitary kidney with ureteral stone group (95 mls/hr). There was increase in the median rate of peristalsis in animals with ureteral stone, both in the unilateral and bilateral systems (10–13.5/10 min.) compared to those without ureteral stone (8/10 min). The median IPP during peristalsis was higher in the ureteral stone animal groups, both in the solitary and bilateral systems (9–11 cm H<sub>2</sub>O), compared to those without the ureteral stone (4–5 cm H<sub>2</sub>O) ( $p < 0.05$ ). However, there was no significant difference in the IPP between the animals with ureteral stone in the solitary kidney vs. normal contralateral kidney. There was an initial decrease (first 2 hours) in the median arterial RI following nephrectomy (0.56) and also following stone placement (0.56) in pigs with normal contralateral kidney. However, there was no significant change in the RI following stone placement in a solitary kidney.

**Conclusion:** In the above acute study, there was increase in the median intrapelvic pressure and peristaltic rate in animals with ureteral stone in a solitary kidney or with normal contralateral kidney. However, in animals with ureteral stone in a solitary kid-

ney, there was no significant increase in IPP compared to those having ureteral stone with normal contralateral kidney. Also, there was no significant change in the arterial resistive index in animals with and without a ureteral stone in a solitary kidney system.

### BR3-03 VITAMIN D RECEPTOR GENE ALW I, FOK I, APA I, AND TAQ I POLYMORPHISMS IN PATIENTS WITH URINARY STONES

I. Seo, J. Lee, S. Park, J. Rim

**Background:** Urinary stones are a multi-factorial disease that includes genetic factors. To identify the candidate genes associated with urinary stones, I evaluated vitamin D receptor (VDR) gene polymorphisms and haplotype frequency in Korean patients.

**Methods:** A normal control group of 535 healthy subjects and 278 patients with urinary stones were evaluated. One hundred and two patients among 125 patients, who presented stone samples, had calcium stones on chemical analysis. The VDR gene Alw I, Fok I, Apa I, and Taq I polymorphisms were evaluated using the polymerase chain reaction-restriction fragment length polymorphism analysis. Allelic and genotypic frequencies were calculated to identify associations in both groups. The haplotype frequencies of the VDR gene polymorphisms for multiple loci were also determined.

**Results:** For the VDR gene Alw I, Fok I, Apa I, and Taq I polymorphisms, there was no statistically significant difference between the patients with urinary stones and the healthy controls. There was also no statistically significant difference between the patients with calcium stones and the healthy controls. A novel haplotype (Ht 4; CTTT) was identified in 13.5% of the patients with urinary stones and in 8.3% of the controls ( $p=0.001$ ). The haplotype frequencies were significantly different between the patients with calcium stones and the controls ( $p=0.004$ ).

**Conclusion:** The VDR gene Alw I, Fok I, Apa I, and Taq I polymorphisms do not appear to be a candidate for genetic markers for urinary stones in Korean patients. However, the novel haplotype of the VDR gene polymorphisms for multiple loci might be a candidate genetic marker.

### BR3-06 HORMONAL PROFILES IN URINARY STONE DISEASE

A. Basiri, N. Shakhssalim, M. Azadvari, B. Golestan, M. Parvin, H. Zaki—Islamic Republic of Iran

**Background:** This study was performed to explore the role of hormones contributing to stone formation in idiopathic calcium stone disease.

**Methods:** 106 active recurrent idiopathic calcium stone former men and another 109 randomly selected men with no history of stone as the controls at the same age range between 30–55 years old included in our study. All cases and controls in our study were divided in two groups of high risk and low risk based on quartiles and normal range of urinary metabolites. All cases and controls stratified in quartiles based on the urinary excretion of calcium, oxalate, citrate, and phosphate, and then, urinary risk levels for stone formation were calculated.

**Results:** The mean of the serum estradiol, testosterone, PTH, calcitonin levels, and the estradiol to testosterone ratio did not show any significant differences in the cases versus the controls. According to urinary risks exertion grouping, these hormones had no significant differences in all groups too. The mean of serum vitamin D was significantly higher in cases than the controls

( $126.68 \pm 39.84$  pmol/lit versus  $93.12 \pm 34.50$  pmol/lit,  $P$  value  $<0.001$ ). Also the mean was significantly higher in hypercalciuric patients than in others. It was significantly higher in the high risk patients (the fourth quartile, with 24 hrs urinary Ca  $>245.5$  mg/24 hr). The mean of vitamin D level did not influence oxalate, citrate and phosphate exertions.

**Conclusion:** Vitamin D seems to play the most important role as a hormonal stone risk factor in recurrent stone formers, and it can induce hypercalciuria.

### BR3-07 SEVERE HYPEROXALURIA AFTER ROUX-EN-Y GASTRIC BYPASS (RYGB): A TWO-YEAR LONGITUDINAL PROSPECTIVE STUDY

B. Duffey, S. Alanee, C. Kriedberg, B. Hinck, A. Moeding, M. Monga—United States

**Background:** The objective of this study is to conduct the first long-term prospective study of the progression of hyperoxaluria following RYGB.

**Methods:** We conducted a prospective study of 21 morbidly obese adults scheduled to undergo RYGB between 12/05 and 4/07. Patients provided 24-hour urine collections and dietary recalls 1 week prior to and at 3 months, 1 year and 2 years after RYGB. Primary outcomes were changes in 24-hour urinary oxalate excretion and calcium oxalate relative supersaturation (SS CaOx) from baseline to 2 years post-RYGB.

**Results:** The cohort consisted of 21 patients, 5 (24%) men and 16 (76%) women. Mean preoperative age and BMI were  $48.2 \pm 10.5$  yrs (range; 25–64 yrs) and  $50.5 \pm 9.1$  kg/m<sup>2</sup> (range; 39.7–66.6 kg/m<sup>2</sup>) respectively. Urinary oxalate excretion significantly increased following RYGB ( $33 \pm 9$  mg/day vs.  $63 \pm 29$  mg/day,  $p=0.0002$ ). Multivariate analysis did not identify any preoperative patient characteristic that correlated significantly with the magnitude of change in oxalate excretion. Eleven (52%) patients developed de novo hyperoxaluria. Each increase in age by year was predictive of developing de novo hyperoxaluria (OR = 1.162, CI 1.002–1.347,  $p=0.046$ ). The SS CaOx was unchanged at two years ( $1.73 \pm 0.67$  vs.  $2.20 \pm 2.07$ ,  $p=0.27$ ). Significant decreases in calcium ( $227 \pm 115$  mg/day vs.  $108 \pm 96$  mg/day,  $p<0.0001$ ), uric acid ( $628 \pm 293$  mg/day vs.  $510 \pm 186$  mg/day,  $p=0.045$ ) and citrate ( $696 \pm 397$  mg/day vs.  $421 \pm 298$  mg/day,  $p=0.003$ ) were observed. Magnesium excretion increased compared to baseline ( $105 \pm 31$  mg/day vs.  $139 \pm 76$  mg/day,  $p=0.042$ ). Urinary pH and volume as well as recorded dietary intakes were unchanged.

**Conclusion:** RYGB is associated with a long-term increase in urinary oxalate excretion. Though SS CaOx rises early following RYGB, at 2 years the predominant abnormality that persists is hyperoxaluria—raising the potential risk of oxalate nephropathy.

### BR3-08 ROLE OF METABOLIC SYNDROME COMPONENTS IN UROLITHIASIS

M. Binbay, E. Yuruk, T. Akman, A. Singh, A. Muslumanoglu, A. Tefekli—Turkey

**Background:** Components of metabolic syndrome, such as obesity, hypertension, and diabetes, are thought to be associated with urolithiasis, but limited published large-scale study has examined the association between metabolic syndrome and urolithiasis. We evaluated the relation between metabolic syndrome components and urolithiasis in a nationwide survey.

**Methods:** A representative sample of 2468 persons aged between 18–70 years in 33 provinces of Turkey was enrolled in the cross-sectional study conducted with a professional investigation company. Participants were evaluated with face to face interviews by medical faculty students. Participants with urolithiasis history (Group 1) were compared participants without urolithiasis history (Group 2) in terms of hypertension, diabetes, body-mass index (BMI), waist size and trouser size using chi-square tests.

**Results:** Of the 2468 participants, 274 (11.1%) reported history of urinary stone disease diagnosed by a physician. The percentage of hypertension in participants with urolithiasis was significantly higher than participants without urolithiasis (16.9% & 34.3%,  $p:0.000$ , OR:3.0). In group 1, 14.2% and in group 2, 9% of participants had diabetes ( $p:0.001$ , OR: 1.83). The mean BMI was 27.2 and 25.2, respectively ( $p:0.01$ ). Participants with a BMI  $>30$  had a 2.2 times fold increased risk of having urolithiasis. Moreover, mean waist size was significantly greater in participants with urolithiasis ( $p:0.000$ ). Those with waist size  $>100$  cm had a 1.87 times fold increased risk of having urolithiasis. The mean trouser size was also significantly bigger in stone formers ( $p:0.003$ ).

**Conclusion:** Metabolic syndrome components are effective factors that play role on the development of urolithiasis.

### BR3-09 ETHYLENE GLYCOL-INDUCED HYPEROXALURIA INCREASES PLASMA AND RENAL TISSUE ASYMMETRICAL DIMETHYLARGININE LEVELS IN RATS: A NEW PATHOGENETIC LINK IN HYPEROXALURIA-INDUCED DISORDERS

F. Yencilek, H. Aydın, N. Mutlu, N. Comunoglu, H. Koyuncu, K. Sarýca

**Background:** Pathogenesis of kidney stones is still elusive. There are some evidence that hyperoxaluria may effect vascular endothelium and many studies link renal stones to atherosclerosis. Besides renal vascular endothelial cells have been shown to regulate proximal tubule epithelial cell function. The aim of this study was to determine the effect of hyperoxaluria on plasma and tissue levels of assymmetrical dimethyl arginine (ADMA) levels. Secondary aim was to determine the effect of verapamil on ADMA levels.

**Methods:** A total of 42 Sprague Dowley rats have been included into study. Group IA, B and C: Hyperoxaluria-induced group where ethylene glycol was used for 2-week period. Group IIA, B and C: Hyperoxaluria + verapamil group; ethylene glycol for 14-day and verapamil for 28-day period. Group III: Control group; No specific medication but distilled water. Blood samples were ob-

tained at 24 hour and at the end of study and kidney samples obtained at 24-hour, 7-day and 28 day periods for histopathologic evaluation.

**Results:** Plasma ADMA levels increased early in hyperoxaluric group ( $p=0.0002$ ). The effect retained at the end of the study period ( $p=0.01$ ). There was no increase in ADMA levels in verapamil group in short and long term. Hyperoxaluria induced significantly dense staining pattern in renal tissue ADMA ( $p=0.01$ ) compared to controls. ADMA staining was not different than controls in verapamil administered group.

**Conclusion:** Increase in both systemic and local tissue ADMA may help to explain the pathogenetic mechanisms of hyperoxaluria induced disorders such as nephrolithiasis and atherosclerosis.

### BR3-10 POLYMORPHISMS IN CALCITONIN RECEPTOR EXON ONE AND THEIR ASSOCIATION WITH CALCIUM OXALATE STONE FORMATION

N. Shakhssalim, A. Basiri, M. Hushmand, H. Pakmanesh, M. Azadvari, A. Kashi—Islamic Republic of Iran

**Background:** To explore the role of calcitonin receptor (CALCR) polymorphism with susceptibility to calcium stone formation in active recurrent stone formers.

**Methods:** 106 male recurrent stone formers with at least 2 episodes of stone recurrence within the past 5 years were compared with 101 sex and age matched controls. Genomic DNA was extracted from leucocytes and amplified by polymerase chain reaction. Sequencing of exon 1 was done by forward and backward primers. In case a polymorphism was identified the remaining samples were analyzed by single-strand conformation polymorphism.

**Results:** Two polymorphisms not previously reported were identified: 1) G to A heterozygous polymorphism (GA) in a noncoding region in exon 1 and 2) G insertion (Gins) at nucleotide number 18350655 in the adjacent interon region. GA and Gins were observed in 61 (58%) and 45 (42%) patients in the case group versus zero and 28 (28%) patients in the control group respectively. ( $p < 0.001$ ,  $p = 0.03$ ) Mean  $\pm$  SD of urinary calcium and oxalate in people with and without GA polymorphism were  $226 \pm 116$  vs.  $174 \pm 87$  mg/24 h and  $0.44 \pm 0.17$  vs.  $0.38 \pm 0.17$  mmol/24 h (both  $p < 0.05$ ). This polymorphism was also related to urinary citrate excretion, serum Vitamin D and total calcium levels.

**Conclusion:** The two reported mutations have association with idiopathic recurrent calcium stone disease. The GA polymorphism is also related to serum and urinary levels of calcium. These results support the role of CALCR in calcium stone formation.

## BR4: BPH

### BR4-01 A PORCINE HEART TISSUE MODEL FOR 2 MICRON CONTINUOUS WAVE LASER ENDOSCOPIC TECHNIQUE TRAINING

G. Zhu, K. Zhang—China

**Background:** To develop and evaluate a porcine heart tissue model for 2 micron continuous wave laser endoscopic technique training.

**Methods:** Defrozen porcine heart was used as the training tissue model and fixed in the training box. 10 junior surgeons without laser benign prostatic hyperplasia (BPH) treatment experience were involved in the evaluation training study. The training program was in two stages. In each stage, the trainees used 26 French laser resectoscope and performed laser resection and vaporization of left ventricle chorda tendineae cordis separately. The continuous irrigation with physiologic saline solution ensured good visibility.



Before the first stage and the 2nd stage of the training, the trainee was trained with theory and technique by an experienced trainer. Time consumed in each technique and sum of resection and vaporization time was recorded for further analysis.

**Results:** The model had plentiful space in porcine left ventricle for precise resection and vaporization technique training. The two stage training was conducted smoothly without risk event. The first stage resection time, vaporization time and sum of resection and vaporization time were  $166.3 \pm 93.9$  s,  $224.1 \pm 80.8$  s,  $390.4 \pm 145.0$  s; The second stage resection time, vaporization time and sum of resection and vaporization time were  $74.7 \pm 27.5$  s,  $104.8 \pm 27.7$  s,  $179.5 \pm 46.2$  s. Compared with the first stage, there was significant improvement in terms of resection time, vaporization time and sum of resection and vaporization time ( $p < 0.001$ ) in the 2nd stage.

**Conclusion:** The establishment and application of defrozen porcine heart as the 2 micron continuous wave laser endoscopic technique animal tissue training model is feasible.

#### BR4-02 HISTOTRIPSY OF THE PROSTATE FOR BPH: TRANSLATION FROM CANINE TO HUMAN

W. Roberts, J. Wheat, T. Hall—USA

**Background:** Histotripsy is an extracorporeal ablative technology that utilizes microsecond pulses of intense ultrasound (<1% duty cycle) to produce nonthermal, mechanical fractionation of targeted tissue. We have previously demonstrated the safety and efficacy of prostate histotripsy ablation in a chronic in-vivo canine model as a therapy for BPH. This presentation will address the obstacles (tissue and anatomic differences) encountered in translating histotripsy from canine to human.

**Methods:** 1) To evaluate histologic differences, two canine and three human fresh prostates were treated with histotripsy (200,000 pulses to a  $1 \text{ cm}^3$  volume) in the right lobe of the prostate. Structural and cellular damage was histologically compared between the species. 2) To evaluate the suitability of delivering acoustic energy to the prostate through the perineum, CT image data from 16 de-identified male patients were examined. Target locations at the prostate apex, mid-prostate, and base were marked. From these points, 881 uniformly spaced rays were back-projected outside the body. Rays encountering high density tissue (bone or transrectal imaging probe) were considered to be blocked. The fraction of unblocked rays placed at each location represented the percentage of transducer surface area available for that target point.

**Results:** 1) Human prostates had greater stromal content whereas canine prostates were predominantly glandular. Despite this difference, a clear well defined area of cellular fractionation (including both stromal and glandular elements) was noted in both human and canine tissues. 2) The available transducer aperture was 99.6%, 94.4%, and 77.0% for target locations at the prostate apex, mid-prostate, and base respectively.

**Conclusion:** Histotripsy is a promising non-invasive technology with significant potential for treatment of BPH. Despite histologic differences between human and canine prostate glands, histotripsy can produce tissue fractionation and cellular destruction in prostates of both species. Computer modeling indicates that sufficient acoustic energy can be delivered through the perineum to all regions of the human prostate to induce cavitation. Further studies with human cadavers are underway to validate these findings.

#### BR4-03 STANDARDIZED EX-VIVO COMPARISON OF THE 120 W VS. THE 70 W THULIUM:YAG 2 MICRON LASER: ABLATION CAPACITY, HAEMOSTASIS AND TISSUE EFFECTS

F. Wezel, N. Huck, A. Häcker, A. Gross, M. Michel, T. Bach—Germany

**Background:** The Thulium:YAG laser vaporization and enucleation are established methods in the surgical therapy of BPH. The recently introduced 120 W Thulium:YAG laser was compared against the established 70 W Thulium:YAG laser in a standardized ex-vivo setting.

**Methods:** Ablative properties, bleeding rate and depth of tissue necrosis were evaluated using the established ex-vivo model of the isolated blood-perfused porcine kidney. Laser energy of the 2 micron continuous wave Thulium:YAG laser (RevoLix™, Lisa laser products, Katlenburg, Germany) was delivered using a  $550 \mu\text{m}$  and an  $800 \mu\text{m}$  bare-ended fibre. The results of the 120 W laser were compared to the already established 70 W device. After staining (HE, NADH) of the renal tissue, depth of tissue necrosis was determined.

**Results:** Using higher power output, the rate of vaporized tissue increased from  $9.80 \pm 3.03$  g/10 min at 70 W to  $16.41 \pm 5.2$  g/10 min at 120 W using the  $550 \mu\text{m}$  fibre at comparable amount of energy applied ( $42.01 \pm 0.18$  kJ vs.  $42.17 \pm 0.06$  kJ, respectively). The total amount of ablated tissue using the  $800 \mu\text{m}$  fibre was lower compared to the 550 micron fibre. Despite increasing power output, bleeding rate remained stable in both groups. Histological examination using HE staining indicated the coagulation zone, whereas NADH staining revealed an underlying zone of necrotic tissue without significant difference of depth between the 70 W and the 120 W device.

**Conclusion:** The 120 Watt Thulium:YAG laser offers significantly higher ablation rates compared to the 70 Watt device. However, bleeding rate and depth of tissue necrosis did not differ significantly at increased energy output.

#### BR4-04 CAN MULTICHANNEL URODYNAMICS PREDICT OUTCOME OF MEDICAL OR SURGICAL MANAGEMENT IN MEN WITH BENIGN PROSTATIC HYPERPLASIA? RESULTS OF A PROSPECTIVE STUDY ON 100 PATIENTS

M. Agarwal, P. Ranjan, S. Singh, R. Mavuduru, A. Mandal—India

**Background:** To elucidate whether preoperative urodynamic variables can predict the outcome of treatment of BPH.

**Methods:** Treatment-naive men with benign prostatic hyperplasia were enrolled and underwent multichannel urodynamics before commencement of medical (alpha-blocker and/or 5-alpha reductase inhibitor) or surgical (transurethral resection/holmium laser enucleation/open prostatectomy) management. Patients with other diseases affecting lower urinary tract function (e.g. diabetes mellitus, parkinson's disease, cerebrovascular accident, etc.) were excluded. Outcomes of treatment were analyzed by percentage changes in the International Prostate Symptom-Score (IPSS), storage symptoms, voiding symptoms and QOL index, before and after treatment.

**Results:** Out of 100 men enrolled, 39 underwent surgical management and 61, medical. Data of 73 (34 surgical and 39 medical) was available for final analysis. Improvement in subjective outcome variables and urodynamics parameters was more in the surgical group compared to medical group. In the former, improvement in all the subjective outcome variables was significantly

better in patients without detrusor underactivity (DUA), with or without bladder outlet obstruction (BOO) compared to group having DUA coupled with absence of BOO. In the medical therapy group no urodynamic variables predicted the improvement in the outcome variables. We present novel definition for detrusor overactivity-index (DOI) which was found to correlate better with storage symptoms and improvement in QOL-index than the existing definition of DOI.

**Conclusion:** In men with BPH undergoing surgery (and not medical management), extent of improvement in symptoms and QOL can be predicted by urodynamic factors like DUA, BOO and our novel DOI.

#### **BR4-05 INTRODUCTION OF THE MULTI-DISCIPLINARY DIOLAS LFD 3000 LASER FOR THE EFFECTIVE TREATMENT OF BPH (BENIGN PROSTATE HYPERPLASIA), STONES, STRICTURES AND CONDYLOMATA**

J. Neymeyer, T. Wülfing, W. Abdul-wahab Al-ansari, C. Bäcker, A. Apostolidis, M. Beer

**Background:** Currently available laser systems for the disciplines of Urology and Urogynecology are focused on single indications that limit the surgeons' range of treatments. The newly developed, multi-disciplinary laser DIOLAS LFD 3000 is the first device available that includes a much broader range of indications. Our aim was to show how effectively BPH, Stones, Strictures and Condylomata can be treated with just one device.

**Methods:** This study included a total of 25 patients who suffered from BPH, 10 patients having Stones and 4 undergoing a combination of both treatments. In two cases, strictures needed to be treated. Additionally, 5 cases of the removal of condylomata were undertaken. All treatments were realized by using one single laser device using specific programs and, depending on the indication, bare and sidefire fibers. A range of important indicators such as IPSS, QoL, PSA, maximal flow rate (Qmax) and post-voiding residual volume (Vres) were evaluated for comparison with established techniques available.

**Results:** For the photoselective vaporization of prostate tissue, obtained results have shown that the DIOLAS LFD 3000 achieves much better results than other systems currently available. In particular aspects such as inflammations, pain and residual urine improved significantly. Most important was the surgeon's ability to switch between the various programs for treating BPH, strictures and other indications depending on the situation at stake.

**Conclusion:** The versatility of the new laser has proven to be the most important advantage for surgeon, patient and hospital. Both investment and level of complexity in the OR could be lowered significantly by relying on a single device that covers the most important indications for laser treatment occurring in Urology and Urogynecology. To conclude, it can be said that the DIOLAS LFD 3000 has proven itself to be effective in daily clinical use and implies better handling at lower costs.

#### **BR4-06 ABLATION OF THE PROSTATE USING A HIGH POWER DIODE LASER (940NM, 250 W)—PRELIMINARY CLINICAL DATA WITH 3 MONTHS FOLLOW-UP**

F. De marco, M. Rheinwald, T. Bayer—Italy

**Background:** Most diode lasers for the treatment of benign prostatic hyperplasia (BPH) operate on wavelengths in the near infrared. The light of these devices is absorbed in both hemoglobin and water which is assumed to provide for good hemostasis and

good tissue ablation rates. We present our first preliminary data on the use of a diode laser with 3 months (mo) follow up.

**Methods:** Since June 2008, a diode laser (Medilas D UroBeam, Dornier MedTech, Wessling, Germany) operating at 940 nm and emitting a maximum power of 250 W in continuous wave (cw) mode was applied for treating BPH in consecutive patients. Patients with prior surgical treatment and prostate volumes larger than 100 g were excluded from this series. After operation, we saw the patients at 1 and 3 mo.

**Results:** 26 patients have reached 3 mo of follow-up so far. Mean (range of) age of the patients was 74.5 (65 to 82) years; pre-operative TRUS volume: 44.6 (14 to 98) ml. 2/26 patients suffered from acute urinary retention, and 20/26 were on alpha-blockers and 7/26 on anticoagulants when presenting for intervention. No patient experienced peri-operative bleeding. After the operation, catheter time was at a mean of 1.48 (1 to 3) days, and patients stayed in the hospital for a mean of 3.69 (3 to 5) days. Maximum flow rate increased from (pre-op) 9.01 (5.7 to 13) ml to 17.61 ml (1 mo) and 17.06 ml (3 mo); IPSS dropped from 20.33 (10 to 30) to 8.61 and 8.60; post-void urine from 85.24 (40 to 270) ml to 27.83 ml and 27.20 ml.

**Conclusion:** The treatment of BPH with the high power diode laser in continuous wave mode at 250 W provides good clinical outcome regarding peri-operative bleeding and post-operative IPSS, maximal flow rate and residual urine in the follow-up overseen so far. Further studies with longer follow-up are needed to confirm these data.

#### **BR4-07 HOLMIUM LASER ENUCLEATION (HOLEP) USING A LOW ENERGY LASER DEVICE COMPARED TO TRANSURETHRAL RESECTION OF THE PROSTATE (TUR-P)**

M. Kanout, M. Prescher, W. Strohmaier

**Background:** Up to now, TUR-P is the gold standard for the surgical treatment of benign prostatic obstruction (BPO). To reduce morbidity, a large number of alternative treatment modalities has been developed during the last years. HoLEP results in durable voiding improvement since it removes tissue. Using a low energy laser—which can also be used for other indications—offers treatment on reasonable economic conditions. Therefore we compared HoLEP with standard TUR-P.

**Methods:** 50 patients with BPO were treated with HoLEP. We used the Auriga XL holmium laser (StarMedTec, Starnberg, Germany), a low energy device which can be used for other indications (e.g. stone therapy) as well. The energy setting was 2.2J (40 W) at a frequency of 18 Hz. HoLEP was performed using a 24 Ch. laser resectoscope (Karl Storz Tuttlingen, Germany) with a 600 µm glass fibre. For comparison, 50 patients with the same prostate volume and age (matched pairs) undergoing standard TUR-P were studied. The following parameters were determined: uroflowmetry (UF), volume of the prostate, weight of the resected tissue, catheterization time (CT), haemoglobin (Hb), transfusion rate.

**Results:** The following table shows our results: Hb preg/dlHb post g/dlProst.vol.mlRes.weightgUF preg/dlUF postg/dlRU premlRU postmlCTdHoLEP14.1 +- 1.312.7 +- 1.546 +- 3129 +- 2311 +- 921 +- 9170 +- 21918 +- 461.9 +- 0.2TUR-P14.0 +- 1.911.9 +- 1.946 +- 3131 +- 23 6 +- 621 +- 17199 +- 21313 +- 422.6 +- 0.6 The transfusion rate was 0 % for the HoLEP and 4 % for the TUR-P group (p ≤ 0.05)

**Conclusion:** HoLEP using a low energy laser device is a safe and effective treatment modality which is comparable to TUR-P con-

cerning voiding parameters, but superior concerning blood loss and transfusion rate. Since the device can be used for other indications as well it offers minimal-invasive treatment for a reasonable price.

#### **BR4-08 DEVELOPMENT OF LASER SURGERY IN BPH. A CRITICAL STATEMENT OF A NEW TECHNIQUE**

M. Loebelenz, D. Bakolas, P. Bischoff-kalb—Germany

**Background:** Laser surgery of BPH is done more and more with several laser systems, methods and different energy. We present our experiences in clinical application and the development of the method.

**Methods:** Since October 2006, 185 patients with bladder outlet obstruction due to benign prostate enlargement underwent laser surgery in three series with the new Biolitec diode laser. The patients were from 41 to 80 years old, size of prostate was between 20 and 80 ml measured by rectalsonographie. The preoperative uroflow was between 3 and 18 ml/s.

**Results:** The first 65 patients were treated with a frequency of 980 nm. The application was done in side-fire technique as a vaporization (up to 120 watt). In most of these patients vaporisation was not sufficient, so a small TURP was done immediately after vaporisation. All the patients had a severe urgency over 4 to 6 weeks after surgery. In the second series we treated 78 patients with the same system in the new technique of vapo-resection. Energy was reduced to 50–70 Watt. Immediate TURP was not longer performed. The severe urgency was clearly reduced. Voiding results were similar to TURP. In the third series with immediately 42 patients a new laser system with a combination of 980 and 1470 nm was introduced. In most of the patients we do now laser enucleation or sometimes vapo-resection. The new wavelength reduces the side effects again and we had best results comparable or better to TURP.

**Conclusion:** Laser vaporization 980 nm is not effective and seems to result in persisting urge incontinence. This technique is no more performed. The 980 nm vapo-resection is effective. The new combination system 980/1470 nm reduces side-effects to a minimum and brings very good results.

#### **BR4-09 MODIFIED TRANSURETHRAL RESECTION BEFORE HIGH INTENSITY FOCUSED ULTRASOUND (RHIFU) EFFICACY AND SIDE EFFECTS: EXPERIENCE & ANALYSIS OF 1.000 CASES**

S. Thueroff, A. Neumayr, M. Bosl, H. Kiel, W. Steil, C. Chaussy

**Background:** Robotic high intensity focused ultrasound (rHIFU) coagulates prostate cancer (PCA) of all stages. It is limited by big adenomas, prostatic calcifications, middle lobes or prostatic abscesses, by bladder neck stenosis or -tumor infiltration. Previous TUR creates a standard anatomic situation and prevents successive bladder neck stenosis by HIFU induced shrinkage of prostatic volume to 5 cc.

**Methods:** 1.005 TURP&HIFU in biopsy proven prostate cancer (5/00-10/08) have been registered prospectively. Classical electroresection (TUR), since 07 Videoplasmaresection (TURis) have been performed with Iglesias technique and/or trocar-cystostomy.

Resection was radical, leaving only the peripheral zone (~20 cc) forming an extralarge bladder neck as radical resection ventrally. Controls pre-/intra- and postoperatively by transrectal ultrasound (TRUS) optimized resection mode. If resection weight >40 g was estimated preoperatively, HIFU was performed one month before HIFU allowing prostate to shrink. rHIFU (Ablatherm® EDAP-Lyon, France, 3 MHz) was performed as complete HIFU treatment of the entire gland.

**Results:** Prostatic volume was 34 cc (6–181 cc) initially. It was reduced by 14 gr (1–116) before HIFU to 20 cc (5–65) before HIFU dose was applied with 662 lesions (95–1235) in 152 min (37–280). There was no case of transfusion! Residual prostatic volume after 6 months was 7 cc (3–25). PSA (ng/ml) was reduced by TUR only from 4.1 to 1.8 in T1–2 and 17.6 to 4 in T3–4 PCa. HIFU afterwards reduced PSA Nadir to 0.1.

**Conclusion:** TUR before rHIFU standardizes each prostate-independent from size, form, calcifications or micro- or macro abscesses. It enables complete HIFU treatments, lowers post HIFU infection, tissue sludge and stricture rates, increases efficacy and lowers PSA level.

#### **BR4-10 ENUCLEATION OF THE PROSTATE WITH THE 2-M CONTINUOUS WAVE THULIUM LASER IN DIFFERENT EXPERIENCED SURGEONS**

C. Netsch, K. Oberhagemann, A. Gross—Germany

**Background:** Thulium:YAG (Tm:YAG) VapoEnucleation has been introduced as an alternative to Holmium laser enucleation of the prostate assuming a steeper learning curve of the procedure. We prospectively evaluated resident's learning curve for Tm:YAG VapoEnucleation in comparison with two experienced surgeons.

**Methods:** Tm:YAG VapoEnucleation was performed in 94 patients by 3 surgeons, an expert in Tm:YAG VapoEnucleation (A, 52 patients), a surgeon with TURP experience (B, 22 patients), and a resident (C, 20 patients) without any experience in TURP/Tm:YAG VapoEnucleation. Tm:YAG VapoEnucleation was realized with a 120 watt 2 μm continuous wave thulium:YAG laser (RevoLix®). Mean enucleation/morcellation efficiency and mean % of resected tissue were analysed and compared.

**Results:** Mean prostatic volume was  $26.6 \pm 9.57$  cc in surgeon C and was significantly lower than that of surgeon A ( $51.37 \pm 27.24$ ;  $p=0.001$ ) and B ( $53.14 \pm 32.23$ ;  $p=0.007$ ). Enucleation efficiency was  $1.34 \pm 0.7$  (A),  $0.71 \pm 0.39$  (B) and  $0.19 \pm 0.11$  (C) gm per minute and differed significantly between each surgeon ( $p=0.000$ ). There was no significant difference in mean percentage of resected tissue between each surgeon. Morcellation efficiency was  $1.44 \pm 1.3$  (C) gm per minute in surgeon C and was significantly lower than that of surgeon A ( $2.93 \pm 1.69$ ;  $p=0.033$ ) and B ( $3.15 \pm 1.75$ ;  $p=0.029$ ). Morcellation ( $r=0.55$ )/enucleation efficiency ( $r=0.82$ ) correlated significantly with resected tissue weight in surgeon A ( $p=0.000$ ).

**Conclusion:** Our preliminary data suggest reasonable efficiency of Tm:YAG VapoEnucleation on each level of experience. However, previous experience in classical TURP is obviously beneficial.

## BR5: SWL

### BR5-01 IMPROVED STONE PHANTOMS FOR SHOCK WAVE LITHOTRIPSY

M. Lipkin, D. Zilberman, M. Ferrandino, G. Preminger, E. Esch, P. Zhong—USA

**Background:** BegoStone plaster has been used as a stone phantom material for shock-wave lithotripsy (SWL) research because of its physical similarity to calcium oxalate monohydrate. However, human stones vary in composition and physical properties. The purpose of this study was to develop a BegoStone phantom that would closely mimic the properties of other types of human stones. The ratio of BegoStone powder to water was varied and the tensile strength, longitudinal wave speed, and transverse wave speeds were measured for the resulting samples.

**Methods:** BegoStone powder was mixed water in varying ratios (15:3, 15:4, 15:5, 15:6). The samples molded into 5 mm×10 mm cylindrical stones and subsequently sectioned for either acoustic or tensile testing. Tensile strength was determined using a diametral compression fixture on a universal testing machine. Longitudinal and wave speeds were determined by measuring the propagation time of an ultrasound pulse in a sample of known thickness.

**Results:** The phantom tensile strength decreased as the powder: water ratio decreased (15:3–7 MPa, 15:4–5 MPa, 15:5–3.8 MPa, 15:6–3.2 MPa). Longitudinal wave speeds decreased with increased water (15:3–8.2·10<sup>6</sup> Kg/m<sup>2</sup> s, 15:4–6.4·10<sup>6</sup> Kg/m<sup>2</sup> s, 15:5–5.2·10<sup>6</sup> Kg/m<sup>2</sup> s, 15:6–4.9·10<sup>6</sup> Kg/m<sup>2</sup> s) with transverse wave speed following a similar trend (15:3–4.6·10<sup>6</sup> Kg/m<sup>2</sup> s, 15:4–3.5·10<sup>6</sup> Kg/m<sup>2</sup> s, 15:5–3.1·10<sup>6</sup> Kg/m<sup>2</sup> s, 15:6–2.8·10<sup>6</sup> Kg/m<sup>2</sup> s).

**Conclusion:** The range of physical properties produced with powder to water ratios of 15:3 to 15:6 matches those of human kidney stones. A stone phantom possessing the physical and acoustic properties similar human kidney stones can be produced with different BegoStone powder to water ratios: 15:3 phantoms have properties similar to COM and brushite, 15:5 ratio possess properties similar to uric acid, while 15:6 has similar properties to struvite stones.

### BR5-02 A NEW ACOUSTIC LENS DESIGN FOR PRODUCING AN IDEALIZED PRESSURE WAVEFORM WITH LOW PEAK PRESSURE AND BROAD BEAM SIZE IN ELECTROMAGNETIC SHOCK WAVE LITHOTRIPTERS

P. Zhong

**Background:** A new acoustic lens for the Siemens Modularis shock wave lithotripter has been developed to produce an idealized pressure waveform with low peak pressure and broad beam size.

**Methods:** In situ pulse superposition principle was used to design a new acoustic lens for the Modularis to truncate the second compressive wave while enlarging simultaneously the beam size produced by the original acoustic lens. The acoustic fields associated with the original and new lenses were characterized using a FOPH-500. Stone comminution tests were performed using BegoStone phantoms both in vitro in a 15-mm tube holder and in vivo in a swine model.

**Results:** At acoustic pulse energy of 42 mJ, the Modularis with the new lens produces a peak positive pressure of 41 MPa, compared to 47 MPa by the original lens. In addition, using the new lens the

second compressive peak in the pressure waveform is significantly reduced and the –6 dB beam size is enlarged by 43%. After 2000 shocks, in vitro stone comminution produced by the original and new lenses are 100% and 99% at the lithotripter focus, and 49.7 ± 15.0% and 75.3 ± 8.74% ( $p < 0.001$ ) at 10 mm off axis. The corresponding values in vivo (with stone initially placed at focus) are 63.4 ± 17.4% for the original lens and 83.3 ± 8.5% for the new lens ( $p < 0.01$ ).

**Conclusion:** Using the new acoustic lens design, the Modularis lithotripter can produce an acoustic field with lower peak pressure and broader beam size, leading to significantly improved stone comminution in vivo.

### BR5-03 THE LITHOTRIPSY TABLE HEIGHT: A NOVEL PREDICTOR OF OUTCOME IN EXTRACORPOREAL SWL

E. Ossandon, P. Recabal, C. Acevedo, J. Flores, F. Marchant, O. Storme

**Background:** Success of extracorporeal Shockwave Lithotripsy (SWL) relies on many factors. Skin to stone distance has been stated to predict outcome. We test the hypothesis that the Lithotripsy table height (LTH) correlates to the real skin to stone distance. The objective was to evaluate the LTH as predictor of outcome in SWL.

**Methods:** Fifty-six patients undergoing ESWL for radiopaque stones were enrolled in a prospective cohort study between October 2007 and July 2008. All procedures were performed using a Modulith SLX (Karl Storz<sup>®</sup>) Lithotripter. Patient weight, height and age; stone location and size; number and intensity of shock waves delivered, radiation exposure and the LTH used were recorded. One month post-procedure a KUB was obtained. Patients were divided in two groups; Group 1: stone free or clinically insignificant residual fragments (CIRF; <4 mm) and Group 2: residual stones (fragments >4 mm). Multivariate analysis was performed and a ROC curve was constructed using SPSS v15.0 and STATA.

**Results:** After one month follow-up, the overall success rate (absence of clinically significant fragments) was 83.9% ( $n = 47$ ). Both groups were comparable in terms of stone size ( $p = 0.45$ ); location ( $p = 0.77$ ) and BMI ( $p = 0.32$ ). Radiation exposure time was higher if the LTH < 235 ( $p = 0.02$ ). LTH was the only independent predictor of outcome in the multivariate analysis ( $p = 0.029$ ). The ROC curve showed an Area under the Curve = 0.791. A LTH of 218 or higher predicts success with 91.4% sensitivity. Patients with LTH < 218 have 6.5 greater probability of residual stones.

**Conclusion:** LTH is an independent predictor of outcome in SWL. LTH is inversely proportional to the skin-to-stone distance. Patients with lower LTH present a less effective shockwave conduction, therefore worse stone fragmentation and clearance. Patients with LTH < 218 should be considered for endourologic procedures.

### BR5-04 IN VITRO RESPIRATORY MOTION MODEL FOR LITHOTRIPTER BEAM WIDTH ASSESSMENT

D. Zilberman, M. Lipkin, G. Sankin, N. Smith, G. Preminger, P. Zhong—USA

**Background:** Accurately representing in vivo renal stone distribution in vitro requires considerations for both stone spreading and

respiration movement. From a rigorous in vitro model, shockwave lithotripter efficacy can be confidently assessed pre-animal study. Recent investigations have examined the adverse effects of respiration on fragmentation efficiency and offered stone targeting as a solution. This work shows improvement from in situ acoustic lens modification of an extracorporeal electromagnetic lithotripter for beam width enhancement and flattened acoustic energy density profile.

**Methods:** Motor-controlled SI-mimicking motion of a membrane-capped cylindrical holder ( $\varnothing 14$  mm) for 12.5 mm displacement range and 12 breath cycles/min was implemented with clinically relevant inhalation and exhalation pauses. Small ( $<0.2$  mm/cycle) displacement randomization ensured no synchronization between motion and shocking. Two electromagnetic lithotripters of matched acoustic energies and varying focal plane beam widths were tested at 2000 shocks and 1 Hz pulse repetition frequency in degassed water using  $\varnothing 10$  mm spherical BegoStone samples.

**Results:** The electromagnetic source with 1.4 times wider beam width produced 92% comminution efficiency ( $<2.0$  mm) compared to 83% for the more tightly focused lithotripter. Student's t-test gives a P-value less than 0.01. Static focal tests produced statistically similar comminution for the two sources.

**Conclusion:** Widening of an electromagnetic lithotripter's focal beam and flattening of its acoustic energy density profile can benefit stone comminution efficiency in vitro under conditions mimicking normal human respiratory motion. Integration of respiratory motion, both regular and irregular, with more geometrically complex stone holders may further our understanding of clinically relevant lithotripter parameters.

#### **BR5-05 ULTRASOUND GUIDED SWL OF KIDNEY STONES WITH AN EXTERNAL TRANSDUCER: DO VARIANCES IN TISSUE SOUND SPEED CAUSE IMAGE DISTORTIONS WHICH AFFECT THE ACCURACY OF STONE TARGETING?**

T. Bayer, C. Bohris, R. Gumpinger

**Background:** Besides X-ray, ultrasound is standard for SWL monitoring. The ultrasound transducer is either integrated within the lithotripter shock wave device (inline transducer) or is external and guided e.g. by an isocentric holder. It is investigated, whether the low sound speed of fatty tissue could lead to image scaling errors resulting in incorrect stone positioning such that disintegration is affected.

**Methods:** In a clinical study, fifteen patients with kidney stones were treated with a Dornier Sigma FarSight. This lithotripter was equipped with both an inline and an external transducer. They were operated alternately to check for inconsistencies, which would indicate ultrasound image distortions. In addition, the ultrasound paths from the transducer to the SWL focus were analyzed for error estimation.

**Results:** The comparison of the stone positions obtained from an inline and an external transducer showed very good agreement, although that approach suffered from some practical difficulties, resulting in measurement imprecision. The sound path analysis showed that the lengths through fatty tissue were too short to result in significant image distortion. The body mass index ranged between 20 and 31 kg/m<sup>2</sup>, which covered a typical range of patients treated by ultrasound guided SWL. Pixel movement in the B-mode image or Doppler hit/miss monitoring are additional indicators for correct stone positioning.

**Conclusion:** Within the study group, no image scaling errors due to sound speed variances were observed which could be clinically relevant for SWL.

#### **BR5-06 PAIN PERCEPTION DURING SHOCK WAVE LITHOTRIPSY (SWL): DOES IT CORRELATE WITH PATIENT AND STONE CHARACTERISTICS?**

H. Tokgoz, V. Hanci, O. Turksoy, B. Erol, B. Akduman, A. Mungan

**Background:** The purpose of this study was to investigate the correlation of various clinical parameters (number of shock wave lithotripsy [SWL] session, body mass index [BMI], patient age, gender and stone characteristics) with the pain perception during SWL procedure.

**Methods:** According to our inclusion criteria, a total of 88 patients who underwent 165 SWL sessions for renal or ureteral stones in our institution were included. The degree of pain perception during the procedure was evaluated with 10-point visual analog scale.

**Results:** A significant p value was reached when a cut-off value for stone burden, was taken as 100 mm<sup>2</sup>. Mean pain scores during the SWL procedures were affected by gender and the number of SWL session. However, it was not affected by laterality, patient age, BMI, and location of stone.

**Conclusion:** it seems that patient comfort is better during a first SWL session for renal or ureteral stones with stone burden of less than 100 mm<sup>2</sup>. In addition, severity of pain during a SWL treatment may be better tolerated in male population.

#### **BR5-07 EXTRACORPOREAL SHOCK WAVES FOR PAIN RELIEF—HYPOTHESIS OF A NEURAL WORKING MECHANISM**

O. Wess—Switzerland

**Background:** Shock waves in urology are not only used for fragmentation of urinary stones but also for chronic pain diseases such as chronic pelvic pain syndrome (CPPS). The Aetiology of the disease is unknown but hypothesized to be based on neurobiology. There are numerous chronic pain syndromes in medical fields such as orthopaedics/rheumatology or cardiology, also successfully treated by extracorporeal shock wave treatment (ESWT). The working mechanism of ESWT is not completely known, although several prospective randomized and blinded studies proof the efficacy of ESWT.

**Methods:** Chronic pain without underlying anatomical disorder is looked at as pathological control function of memory or "pathological conditioned reflex". Reflexes are considered as engraved memory traces linking afferent sensory input with efferent motor response. This feature can be described by associative memory functions of the nervous system. Some conditioned reflexes may cause inappropriate or "pathological reactions". Consequently, a circulus vitiosus of pain sensation and muscle and/or vessel contraction is generated when pain becomes chronic (pain spiral).

**Results:** A new theory of chronic pain is developed on the basis of a neuro-holographic brain model. It explains how ESWT may delete pathologic memory traces by hyperstimulation, resulting in real and permanent pain relief.

**Conclusion:** In a generalized manner, the concept of associative memory functions may help to understand conditioning as a learning process and explain ESWT as an efficient method for treatment of chronic pain. This concept may open the door for

numerous new treatment approaches to chronic pain and some disorders of the nervous system.

### **BR5-08 SIEMENS MODULARIS WITH C PLUS SHOCK-HEAD: EFFECTIVE, SENSIBLE LITHOTRIPSY OF RENAL AND URETERAL CALCULI**

G. Mathes, L. Mathes

**Background:** Analyze outcomes of renal and ureteral stone Extracorporeal Shock Wave Lithotripsy (ESWL) using the Siemens MODULARIS system with the C Plus shockhead (focal width 10 mm, penetration depth 140 mm, and the ability to vary shock-wave delivery rate between 1.0, 1.5, or 2.0 Hz).

**Methods:** 291 stones (105 renal and 186 ureteral) were treated with the device. Stone diameter ranged from 5–20 mm (average 10.4 mm). Follow-up was obtained in all cases.

**Results:** 78% of all ureteral stones were completely cleared after one lithotripsy session. 74% of all renal stones were completely resolved after one session. For stones equal to or smaller than 10 mm, single session ESWL stone-free rates were 86% for renal and 79% for ureteral calculi. Repeat ESWL was done in 9% of cases, and alternative treatments in 8%.

**Conclusion:** The Siemens MODULARIS lithotripter with C Plus shockhead has demonstrated and improved the success rate of ESWL. The treatment of renal and ureteral stones is effective, with a retreatment rate of 9%.

### **BR5-09 EXTRACORPOREAL SHOCK WAVE LITHOTRIPSY AND SHORT TERM RENAL INJURY: MULTIVARIATE ANALYSIS OF THE VARIABLES POTENTIALLY INVOLVED**

M. Sighinolfi, S. Micali, S. De stefani, M. Rivalta, F. Annino, G. Bianchi

**Background:** Early and late potential renal injuries after extracorporeal shock wave lithotripsy (SWL) are still debated; the aim of this study is to evaluate urinary protein/creatinin rate (expression of renal damage) before and after SWL treatment.

**Methods:** We have prospectively enrolled 55 subjects with renal stones (stone location: caliceal in 42 and pelvic in 13 patients). Five subjects presented with a slight acute renal failure. All the patients were submitted to SWL with Dornier Lithotripter S-XXP. One hour before and approximately 3–4 hours after the treatment, urinary standard analysis and urinary protein/creatinin rate were assessed. Data were inserted in a statistical data base and chronological changes in those parameters were evaluated with respect to: patients' age, basal serum creatinine, co-morbidities, n° and frequencies of shock waves (SW), stone fragmentation.

**Results:** Urinary protein/creatinin rate before SWL was normal in 34 patients ( $0.3 \pm 0.8$ ). After the treatment, 39/55 patients pre-

sented a pathological impairment of such value ( $p = 0.000$ ). Contextually, urinary pH and microscopical haematuria were significantly increased after SWL. An improve in prot/creaU, was found to be related to SW frequency (0.001) and stone fragmentation (0.00). In a logistic regression model, SW frequency seems to be the variable predicting best kidney injuries: slow shock wave rate (60 SW/min) seems to increase protein/creatinin rate thus impairing renal function. Conversely, 60 SW/min are significantly related to a better stone fragmentation.

**Conclusion:** Reno-protection during SWL still remains a topic of interest due to the widespread diffusion of the treatment. Despite the use of low SW rate has been recently recommended in International Literature in order to improve stone fragmentation, our experience may arise some uncertainties about the use and safety of such recommendation.

### **BR5-10 SLOW SHOCK WAVE RATE AND "PAUSE-PROTECTION" PROTOCOLS REDUCE RENAL INJURY IN ESWL**

J. Mcateer, A. Evan, B. Connors, R. Handa, P. Blomgren, J. Lingeman—USA

**Background:** Success rates in ESWL have not kept pace with technical advances, and adverse effects continue to be a great concern—particularly recent clinical evidence that papillary injury leads to long-term effects. Therefore, we have looked for ways to reduce acute renal injury by improving the technique of SW delivery.

**Methods:** The pig model was used to assess renal injury in response to SW's delivered using a Dornier-HM3 lithotripter. The lower pole calyx was targeted and SW's were administered at different SW-rates (30, 60, 120 SW/min) or by various power ramping protocols in which 100 SW's at 12–24 kV were followed by 2000 SW's at 24 kV with or without a brief pause between the two steps. At 4 hr kidneys were processed for morphological quantitation of the lesion (% functional renal volume).

**Results:** Treatment at 30 or 60 SW/min significantly reduced lesion size compared to 120 SW/min (0.08%FRV at 30 SW/min versus 4.6% at 120 SW/min,  $p < 0.005$ ; and 0.42%FRV at 60 SW/min versus 3.93% at 120 SW/min,  $P = 0.011$ ). The lesion was also reduced when the initial dose was followed by a 3-min pause (0.39%FRV when starting at 12 kV, versus 0.09% at 18 kV, versus 0.51% at 24 kV).

**Conclusion:** Slow SW-rate, as shown in prospective clinical trials to improve stone breakage outcomes, also reduces acute injury to the kidney. Step-wise delivery of SW's can likewise be used to reduce injury, and inclusion of a brief pause in treatment ("pause-protection") is effective regardless of the power setting of the initial SW dose. (NIH-DK43881).

## **BR6: ENDOUROLOGY II**

### **BR6-01 THE CLINICAL ANALYSIS OF FACTORS AFFECTING BLEEDING DURING MINIMALLY INVASIVE PERCUTANEOUS NEPHROLITHOTOMY**

Z. xiao-feng, L. Fu-lin, Ri-hai—China

**Background:** To investigate the factors affecting bleeding during minimally invasive percutaneous nephrolithotomy (MPCNL).

**Methods:** Data were collected prospectively of 360 patients undergoing 390 MPCNL procedures from September 2008 to May

2009. All the patients excluded hematological system diseases were performed by the same surgical team. Various patient-related factors including age, body mass index, hypertension, diabetes, hepatic or renal insufficiency, urinary infection and the operating surgery, renal parenchymal thickness and stones sizes were investigated. The intraoperative factors included the calix of entry, operative complications, mature nephrostomy tract, multiple tracts, operative time and operative staging. The association of the factors with blood loss was analyzed using stepwise multivariate regression analysis. Blood loss was estimated based on the decreasing of the concentration of hemoglobin in the peripheral blood during MPCNLs. Results All the cases were successful and no server bleeding occurred. The average blood loss was  $181.7 \pm 75.2$  ml and the average operation time was  $81.5 \pm 25.33$  min. The average total blood loss was  $169.8 \pm 69.6$  ml for single and  $204.5 \pm 87.5$  ml for multiple. Significant complications occurred in 32 patients, including pelvic wall tear in 4, ureter wall tear in 9 and infundibular tear in 16.

**Results:** All the cases were successful and no server bleeding occurred. The average blood loss was  $181.7 \pm 75.2$  ml and the average operation time was  $81.5 \pm 25.33$  min. The average total blood loss was  $169.8 \pm 69.6$  ml for single and  $204.5 \pm 87.5$  ml for multiple. Significant complications occurred in 32 patients, including pelvic wall tear in 4, ureter wall tear in 9 and infundibular tear in 16.

**Conclusion:** The operative complications, renal parenchymal thickness, multiple tracts, operative time, stones sizes, operative staging were the most factors affecting the bleeding. Avoiding the operative complications, decreasing the tracts, shortening the operative time and selecting operative staging all can reduce the risk of bleeding.

#### BR6-02 THE EFFICACY OF LEVOBUPIVACAINE INFILTRATION TO NEPHROSTHOMY TRACT IN COMBINATION WITH INTRAVENOUS PARACETAMOL ON POSTOPERATIVE ANALGESIA IN PERCUTANEOUS NEPHROLITHOTOMY PATIENTS

O. Gokten, H. Kilicarslan, H. Dogan, G. Turker, Y. Kordan—Turkey

**Background:** To evaluate the efficacy of intraoperative local anesthetic infiltration in combination with intravenous paracetamol infusion on postoperative pain management for percutaneous stone surgery.

**Methods:** Patients were randomized into three groups including 20 cases in each. In first group (Group SP), 20 ml saline was infiltrated through the nephrostomy tract intraoperatively and this was followed by intravenous paracetamol ( $4 \times 1$  gr) infusion postoperatively. In second group (Group LP), 20 ml of 0, 25% Levobupivacaine infiltration to the nephrostomy tract + postoperative paracetamol infusion. The third group (Group LS) 20 ml of 0, 25% Levobupivacaine infiltration + postoperative IV saline infusion. In the postoperative period, pain status of patients were evaluated in the recovery unit (hour 0) and in the ward at postoperative 2, 4, 6, 8, 12 and 24 hours by using the visual analogue scale (VAS). In patients who did not completely respond medication ( $VAS \geq 3$ ), meperidine 1 mg/kg intramuscular was given as an additional “rescue” analgesic. The patient satisfaction from the postoperative analgesia management was assessed by 5 points scale.

**Results:** There was no statistically significant difference between 3 groups regarding the demographic characteristics. Our findings revealed that in group LP, the amount and frequency of opioid used

was lesser, VAS score was lower, time period until full mobilization was shorter and patient satisfaction score was higher when compared to the other 2 groups.

**Conclusion:** Levobupivacaine infiltration through the nephrostomy tract in combination with intravenous paracetamol infusion was shown to be safe and efficacious as an analgesia method following PNL.

#### BR6-03 ANATOMIC RATIONALE FOR PERCUTANEOUS NEPHROLITHOTOMY IN THE PRONE AND PRONE-FLEXED POSITIONS

A. Ray, D. Chung, K. Pace, R. Honey

**Background:** Percutaneous nephrolithotomy (PCNL) is commonly performed in the prone position. Knowledge of renal anatomy and the relationship of adjacent organs are essential to minimize patient morbidity and iatrogenic organ injury. We present the anatomical basis for a prone-flexed modification to patient positioning.

**Methods:** An anatomical survey was conducted using triphasic computed tomography with the patient in supine, prone and prone-flexed positions. Simulated nephrostomy access was used to estimate the risk of organ injury. Intra-operative bony landmarks were used to measure kidney displacement with changes in patient positioning.

**Results:** For upper pole punctures, the liver and spleen were more medially situated, and thus more likely to be injured with supine positioning, compared with either prone or prone-flexed positioning ( $p < 0.001$ ). In contrast, for lower pole punctures, the colon was more medially situated in the prone and prone-flexed positions compared to supine ( $p < 0.001$ ). With prone-flexed positioning, the left kidney was displaced lower than the right in 92.3% of cases. Compared to conventional prone positioning, the prone-flexed modification increased the distance from the posterior iliac crest to the 12th and 11th ribs by 2.9cm and 3.0cm, respectively ( $p < 0.0001$ ). For access in the most superior calyx, this could have converted puncture above the 11th rib to one above the 12th rib in 5 of 11 patients (45.5%).

**Conclusion:** Prone-flexed positioning is a simple modification that provides improved access to the upper pole and more mobility for lower pole PCNL. This position is well tolerated and has several advantages over other patient positions.

#### BR6-04 NON-CONTACT INFRARED TEMPERATURE MEASUREMENT OF ULTRASONIC LITHOTRIPSY HANDPIECES—AN IN VITRO COMPARISON OF COMMONLY USED LITHOTRIPSY DEVICES

C. Keil, P. Olbert, F. Brüning, L. Skrobek, R. Hofmann—Deutschland

**Background:** Ultrasonic lithotripters are used during PCNL for the fragmentation and removal of renal calculi. This work presents a real time method for comparing temperatures of the handpiece using different ultrasonic lithotripters.

**Methods:** In an experimental in vitro setup 4 different ultrasonic lithotripters (US3/EMS, Vario/EMS, LUS2/Olympus, Cyberwand/Gyrus/ACMI) were activated within a 24 Fr. Wolf-Nephroskop for 15 minutes. Temperature at the handpieces was measured using an infrared thermo camera (Fluke Ti20) at 1, 2, 5, 10 and 15 min. Continuous irrigation and suction was applied during the whole procedure (suction: 120 ml/min). To simulate realistic treatment an artificial stone was used during lithotripsy.

**Results:** A rise in handpiece temperature could be traced in both EMS devices. A plateau of constant temperatures was reached after 10 minutes. Maximum temperatures were 58.1°C (US3) and 42.1°C (Vario). Interrupting the suction after 15 minutes at the Vario the temperature rose to 106.8°C after 2 minutes. No rise in temperature could be measured using the LUS2. The ultrasonic probe of the Cyberwand broke after 4 minutes at a temperature of 50.1°C.

**Conclusion:** This in vitro experimental setup allows an objective measurement of temperatures during lithotripsy. Highest temperatures could be measured using US3 and Cyberwand whereas the LUS2 showed no rise in temperature. An interruption of suction has to be avoided, because critical temperatures are reached in less than 2 minutes.

### BR6-05 COMPARATIVE EVALUATION OF INERTIAL FORCES GENERATED BY ULTRASONIC LITHOTRIPTORS

B. Knudsen

**Background:** Prior study has shown that handheld ultrasonic lithotriptors differ in performance. The Boston Scientific (BSci) LithoClast® Ultra, BSci LithoClast® Select with Vario handpiece, and the Olympus/ACMI Cyberwand are amongst the latest generation of ultrasonic lithotriptors. This study tests the hypothesis that inertial forces (g-force) vary amongst different ultrasonic handpieces when evaluated with an accelerometer.

**Methods:** Eight handpieces were evaluated including two US3 (LithoClast® Ultra) handpieces, three Vario handpieces (LithoClast® Select) and three Cyberwand handpieces using a simulated lithotripsy fixture incorporated a Bego stone phantom. An accelerometer was placed under the stone phantom and measurements recorded with data acquisition hardware as the ultrasound device was brought into contact with the stone. The US3 and Vario handpieces were tested using a LithoClast® Select generator set at 100% power and 100 duty. Only the ultrasound mode was tested. The Cyberwand handpiece was tested on a Cyberwand generator using the "large stone" setting. Three trials were performed for each handpiece.

**Results:** The overall mean inertial force generated by the handpieces was greatest for the Vario (64.04 g), followed by the US3 (56.01 g) and the Cyberwand (20.25 g). There was variability amongst the different samples of each handpieces. The two US3 handpieces each generated a mean inertial force of 56.01 and 60.41 g's respectively. The three Vario handpieces tested each generated a mean inertial force of 56.25, 66.17, and 68.34 g's respectively. The three Cyberwand handpieces generated a mean inertial force of 14.76, 16.48, and 20.30 g's respectively. All values are statistically significant ( $p < 0.01$ ).

**Conclusion:** The US3, Vario, and Cyberwand ultrasonic handpieces differed in the inertial forces generated during fragmentation of a Bego stone phantom. Individual handpieces within the same model line also varied in performance. The Vario handpiece generated the greatest mean inertial force, followed by the US3 handpiece, and then the Cyberwand handpiece.

### BR6-06 CLOSED EXTERNAL END DOUBLE J CATHETER AS A NEPHROSTENT IN PYELOPLASTY FOR VERY SMALL CHILDREN WITH URETERO-PELVIC JUNCTION OBSTRUCTION

S. Rabani—Iran

**Background:** Uretero-Pelvic Junction Obstruction (UPJO) is a common congenital anomaly that may need pyeloplasty to prevent

renal function deterioration. The purpose of this study was to describe a modified use of jj stent catheter in pyeloplasty for very small children with UPJO.

**Methods:** A series of 12 children between 3 and 10 months, underwent stenting open pyeloplasty. In each patient a 6 french Foley catheter was placed within the bladder, with one ml sterile methylene blue, and then the catheter was clamped during the operation time. During a dismembered pyeloplasty, a small (3F) double j stent was placed through the flank into renal pelvis, passing the flank skin, muscles and entering via lower pole posteriorly to pass the anastomosis and entering the ureter and urinary bladder, confirmed by observing methylene blue within the wound the external end of the jj catheter was doubled up and sutured to the flank skin and then removed 4 weeks later.

**Results:** No procedure related complication(s) such as extravasation, infection and stent displacement was seen. The duration of follow up was 6 months to 3 years (the median follow-up time was 13 months).

**Conclusion:** This method of stenting pyeloplasty is easily tolerated and causes no need for endoscopic removal of the catheter, is an invaluable technique of pyeloplasty with stenting in very small children and needs no external appliance.

**Key words:** upjo, pyeloplasty, double j stent.

### BR6-07 THE POLYSCOPE®—A MODULAR DESIGN, SEMI-DISPOSABLE FLEXIBLE URETERORENOSCOPE SYSTEM

M. Bader, S. Walther, Y. Hocaoglu, C. Gratzke, C. Stief, O. Reich—Germany

**Background:** The widespread use of flexible ureterorenoscopes (FUR) for diagnosis and management of upper urinary tract diseases is, among others, limited by a high frequency of damage with consequent costs and intermitted failure of the device. The object of this study was to present a new, modular design, semi-disposable flexible ureterorenoscope and to assess its value based on our initial experience.

**Methods:** The Polyscope® system consists of a detachable flexible ureterorenoscope system available in 8.0 F and 5.5 F with separated optic, working/irrigation (8.0 F: 1.2 mm diameter, 5.5 F: 0.63 mm), illumination and steering channels. Due to this separation, handling related breakdown, like laser related damage of the working channel or the distal scope tip, is confined to the disposable insertion catheter only. Coupled in the optic channel, hermetically closed by a piece of diamond glass, the optical system never encounters the patient. For the 8 F device two reusable optical systems consisting of 0.55 mm diameter optical fibres with 10.000 pixels and angles of view of 70° and 120° are available. The optical system of the 5.5 F instrument consists of a 0.25 mm fibre with 6.000 pixels and an angle of view of 70°. The ocular, the light cable and the camera head are mounted outside the sterile field on a four joint arm near the operating table making the scope lightweight and easy to handle. Angles of maximum active deflection were measured ex vivo and in vitro and the maximum irrigation flow was measured ex vivo. The clinical performance was evaluated in 40 patients for the management of intrarenal calculi.

**Results:** For the 8.0 F Polyscope®, the maximum deflection angle with an empty working channel is as much as 225°, with an inserted 220 µm laser fibre or a 1.4 F Dormia basket deflection angles as much as 180°. The steering is possible in one direction only, but the torsional stiffness from the hand held to the tip averages 1:1. Preliminary clinical results showed complete intrarenal access in



38 of 40 patients with a stone-free rate of 87.5% after 4 weeks in the 38 patients were overall access was achieved. In 5 patients the Polyscope<sup>®</sup> catheter had to be exchanged intraoperatively due to breakage of the steering mechanism in the handheld.

**Conclusion:** The development of a modular design, semi-disposable flexible ureterorenoscope with a reusable optical system might diminish the disadvantages of common FURs like their vulnerability with consecutively high repair frequencies and running costs. Further development and initial multicenter studies will determine its clinical value and extension in the nearer future.

#### **BR6-08 RESISTANCE TO EXTRINSIC COMPRESSION AND MAINTENANCE OF INTRALUMINAL FLOW IN COIL REINFORCED STENTS (SILHOUETTE<sup>®</sup> SCAFFOLD DEVICE): AN IN VITRO STUDY**

R. Miyaoka, K. Hendlin, M. Monga

**Background:** To evaluate the Silhouette<sup>®</sup> Scaffold Device, a coil reinforced ureteral stent, in regards to its resistance to extrinsic compression and ability to simultaneously maintain intraluminal flow and compare results to the Cook Amplatz 10.2Fr stent.

**Methods:** Four 8Fr Silhouette<sup>®</sup> stents were evaluated for radial compression using an MTS Micro Bionix Testing System, Testworks II software, 5N load cell, vibration isolation table, and socket set screws with rounded caps. Compression was exerted in 0.2 mm increments with 100-second hold time intervals between compressions until a maximum load cell of 5N was reached. Simultaneous intraluminal flow determinations were made. Three trials were performed for each stent. The Young's modulus, E, was calculated from each trial using the engineering stress. Flow rates were compared to the Cook Amplatz 10.2Fr stent.

**Results:** Overall average E was  $28856 \pm 2592$  kPa (95%CI 27447–30265). The Amplatz inner lumen was larger than the Scaffold by 0.125 mm. Baseline flow rate for the Amplatz stent was superior to the Silhouette stent (1.089 vs. 0.660 ml/s,  $p=0.001$ ). However, intraluminal flow decreased with compression at different rates and the flows became similar at 1 mm compression for the Silhouette and 2 mm compression for the Amplatz (0.599 vs. 0.6145 ml/s).

**Conclusion:** The 8Fr Silhouette<sup>®</sup> Scaffold Device proved able to maintain inner flow despite increasing extrinsic compression. This resistance was much higher than previously tested stents and uniform along the shaft. Cook Amplatz 10.2Fr stent has a higher baseline flow, but flow drops at a rate 3 times faster than the Scaffold stent.

#### **BR6-09 DURABILITY OF THE NEXT-GENERATION FLEXIBLE FIBEROPTIC URETEROSCOPES: A RANDOMIZED PROSPECTIVE MULTI-INSTITUTIONAL CLINICAL TRIAL**

B. Knudsen, R. Miyaoka, K. Shah, T. Turk, R. Pedro, M. Monga

**Background:** To evaluate the durability of four next-generation flexible ureteroscopes in a randomized, multi-institutional, prospective study.

**Methods:** Patients at three institutions were randomized to one of four flexible ureteroscopes: the Wolf Viper, Olympus URF-P5, Gyrus-ACMI DUR-8 Elite (DUR-8E), and Stryker FlexVision U-500. Each center utilized one scope from each manufacturer until it needed major repair (primary endpoint). Intraoperative data

included total time of use, number of scope insertions through an access sheath, working time in the lower pole, number of insertions and total time for accessory instrumentation in the working channel, number of laser insertions through the working channel and total laser energy used.

**Results:** A total of 175 patients were randomized. The DUR-8E experienced early catastrophic failure (10 or less cases) at all 3 sites, however this also occurred at one site each for the Stryker and Wolf scopes. The DUR-8E required major repair after the fewest average number of cases (5.3), the lowest average total time of usage (108 minutes), the fewest insertions through an access sheath (20.3), the shortest duration of laser firing (31.3 minutes), the shortest instrument in the working channel time (22.7 minutes). As such, due to variation in durability within manufacturers, no differences could be demonstrated. Visibility ratings for the Wolf Viper were significantly better than the DUR-8E ( $p=0.034$ ) and the Stryker FlexVision ( $p=0.038$ ).

**Conclusion:** The Wolf Viper, Olympus URF-P5 and Stryker FlexVision U-500 flexible ureteroscopes appear comparable with regards to durability. However, larger prospective registry-based studies are needed to document significant differences between them.

#### **BR6-10 LOW DOSE CT FOR FOLLOW-UP OF UROLITHIASIS—ITS EFFECTIVENESS IN THE SETTINGS OF THE UROLOGY CLINIC**

D. Zilberman, M. Lipkin, M. Ferrandino, D. Frush, E. Paulson, G. Preminger—USA

**Background:** Non-contrast helical CT is the gold standard for detection of urolithiasis. However due to the risk of increased radiation exposure, its routine use in the follow-up of patients with recurrent nephrolithiasis may not be optimal. The goal of this study is to evaluate whether a low dose protocol CT scan can provide the same information as standard CT for follow up of recurrent stone forming patients.

**Methods:** Sixty-two consecutive patients with suspected urolithiasis were investigated with unenhanced renal stone 16-MDCT with a tube current of 160 mA. Electronic “noise” was then introduced into the images to simulate levels of 130, 100, and 70 mA, corresponding to a 19%, 38%, and 56% reduction in radiation dose. Three endourology fellowship trained urologists interpreted the original and simulated scans in a blinded manner. Films were reviewed for number and location of stones. A score of 1–10 was used to rate ease of image reading in the abdomen, bony pelvis, and level of confidence in diagnosis.

**Results:** Overall, 248 sets of images, for the 62 patients were reviewed. Increasing difficulty was observed with the lowest dose CT when reviewing the bony pelvis area. The level of confidence in diagnosis did not significantly change and remained high at 9–10. All stones >2 mm were detected in the urinary tract, including those within the bony pelvis.

**Conclusion:** A significant reduction in radiation dose may provide adequate diagnostic imaging for the follow-up of urolithiasis patients. Confirmation of these findings and the minimal required radiation dose needs to be determined.

## BR7: NEW TECHNOLOGY

### BR7-01 A NOVEL CATHETER USING A PETAL-SHAPED CROSS-SECTIONAL DESIGN: AN EXPERIMENTAL STUDY IN RABBITS

S. Yinghao, Z. Qinsong, Z. Zhensheng, X. Chuanliang, L. Wenbin, Y. Yongwei

**Background:** To compare the physical properties between a novel urethral catheter using a petal-like cross-section design and the conventional catheter, and validate the feasibility of the new catheter in a rabbit model.

**Methods:** A novel type of catheter was made of a petal-like cross-section design and clinically common medical silicone. Forty-eight male New Zealand white rabbits were anaesthetized and equally randomized into two groups: group A, where a novel F8 catheter was indwelled in the rabbit urethra, and group B, where a conventional urethral catheter was used. The animals in both groups were equally sacrificed at day 3, 6, 9 and 12 of catheterization. The urethral inflammatory reaction and stimulus-response were observed and evaluated by urine WBC count, light microscopy, histological analysis, TUNEL test and cystourethroscopy.

**Results:** These two types of catheters caused different inflammatory reaction to the rabbits' urethras. Group A showed fewer urine WBC count, milder histological inflammatory reaction, lower apoptotic index and better results of cystourethroscopy than that in group B, judging from examinations at day 3, 6, 9 and 12.

**Conclusion:** Compared with the conventional urethral catheter, the novel one functioned better in the rabbit urethra with less catheter-related inflammatory reaction, suggesting that the improvement of catheter configuration in this way had its promising advantages. A clinical study is on the way.

### BR7-02 PORCINE MODEL FOR ULTRASOUND GUIDED PERCUTANEOUS NEPHROLITHOTOMY

T. Zhou, Y. Sun, X. Gao—China

**Background:** Ultrasound as a guide tool for percutaneous nephrolithotomy (PCNL) has become more and more popular but is lack of effective training model. In this study we developed a porcine model for PCNL training and investigated the effectiveness of such a training model.

**Methods:** A porcine model was developed as below. The adult female domestic pig (approximately 45 kg) fed a standard laboratory diet were used. Under inhalational anesthesia (isoflurane 1.5%), cystoscopy was performed to indwell the ureteral catheter. Then in prone position, the kidney was punctured under the guide of ultrasound after the administration of furosemide and subsequently 24Fr percutaneous tract was developed. Twenty urologists had initial experience of PCNL (10 patients) were randomly divided into two groups. Each urologist in the group I accepted model training and practiced four porcine kidneys during training. No urologist in the group II had model training. Subsequently each urologist undertook PCNL for 4 patients with complete staghorn calculi. The success rate of puncture and tract development between the two groups was compared.

**Results:** After furosemide administration, the collecting system was dilated and easily identified by ultrasound. All the porcine kidneys could be used for ultrasound guided percutaneous puncture

and tract development. In group I the successful puncture was higher than that in group II (36/40 versus 21/40,  $p < 0.05$ ). In group I the successful tract development was also higher than that in group II (32/40 versus 18/40,  $p < 0.05$ ).

**Conclusion:** Porcine can be used as an effective training model for ultrasound guided PCNL. It can make ultrasound guided PCNL learning curve easy, especially for initial learners.

### BR7-03 USE OF A NOVEL SPLITTED SIDE AMPLATZ SHEATH FOR FACILITATING STONE REMOVAL IN PERCUTANEOUS NEPHROLITHOTOMY

D. Irani—Iran

**Background:** Whereas conventional percutaneous nephrolithotomy (PCNL) achieves a high stone-free rate albeit with some surgical risk, decreasing the time of this procedure by shortening the time of intracorporeal lithotripsy and stone retrieval, reduces the complications. Herein we present surgical procedure of PCNL, by means of a special Amplatz sheath designed by the author, step by step.

**Methods:** A rigid 24F nephroscope was used for PCNL. After puncture of the kidney under x-ray guide, a single step dilatation was performed and a 27F Amplatz sheath was placed then another 27F softer Amplatz sheath was splitted longitudinally from one side by a surgical blade and was inserted to the renal calyx via the former Amplatz sheath then the former Amplatz sheath was removed and stones or stone particles larger than one centimeter were retrieved via this Amplatz sheath.

**Results:** In 60 patients PCNL was done using this splitted side Amplatz sheath. The average stones or stone particles size retrieved via this Amplatz sheath was 15 mm in biggest diameter (range, 13–19 mm). The mean of stone size treated was 3 cm. The average operating time was 35 minutes. Overall stone free rate was 90%. Hemorrhages requiring a blood transfusion occurred in 5%. Prerenal fluid collection was detected in 5% in early post operative sonography but no febrile pyelonephritis was observed.

**Conclusion:** Use of this novel splitted side Amplatz sheath in PCNL, decreases overall complications by decreasing the time of procedure due to decreasing the time of intracorporeal lithotripsy and increasing the size of stones or stone particles retrieved via this Amplatz sheath.

### BR7-04 USE OF A NOVEL CONE TIP METALIC DILATOR FOR ONE SHOT DILATATION OF NEPHROSTOMY TRACT IN PERCUTANEOUS NEPHROLITHOTOMY

D. Irani, E. Ghanbarifard—Iran

**Background:** The creation of nephrostomy access tract is a fundamental step of percutaneous nephrolithotomy (PCNL), dilatation of tract is usually achieved with multiple incremental flexible exchange dilators of Amplatz type, metallic telescoping dilators of Alken type or a balloon. Also one shot dilatation of nephrostomy tract with a 27 to 30 F flexible Amplatz dilator is well accepted in PCNL. Herein we present our experience using a self designed metallic cone tip dilator for one shot dilatation of nephrostomy tract in PCNL step by step.

**Methods:** A rigid 24F nephroscope was used for PCNL. After puncture of the kidney under x-ray control and insertion of guide wire, the first dilator of Alken telescopic dilators was passed to the calyx on the guide wire in order to prevent kinking of the guide wire then our self design cone tip metallic dilator was used as a one shot dilator to dilate the nephrostomy tract in a single step.

**Results:** During the last 3 years, 900 consecutive PCNL was done using this dilator as our initial dilatation modality. Nephrostomy tract dilatation was successful in all of the patients irrespective of history of previous ipsilateral renal surgery and prerenal fibrosis. There was no cost for dilator and all of the procedure was done with the same dilator. Average radiation exposure time was 45 second. Hemorrhages requiring a blood transfusion occurred in 4%. Average operating time was 35 minutes. Colon injury was seen in 0.22% (two patients). No febrile pyelonephritis was observed.

**Conclusion:** Use of our novel cone tip metallic dilator for one shot dilatation of nephrostomy tract in PCNL, is safe and effective. It's main advantages are decreasing the cost, no failure rate and also decreasing the time of radiation exposure and total operative time and does not increase patient morbidity.

#### **BR7-05 NOVEL IN VITRO MODEL FOR STUDYING URETERAL STENT-INDUCED CELL INJURY**

D. Lange, C. Elwood, S. Seney, K. Summers, B. Chew, P. Cadieux

**Background:** Ureteral stents are frequently placed following urological procedures to maintain ureteral patency. Despite their effectiveness, stents are associated with urinary tract complications that can significantly add to patient morbidity. We present a unique in vitro model that suggests inflammation triggered by stent-mediated mechanical injury to the urinary tract may be a contributing factor for these complications.

**Methods:** In this study, T24 bladder and A498 kidney cell line monolayers were mechanically interfaced with segments of either Percuflex Plus® (Boston Scientific) or Triumph® stents (Percuflex that elutes the anti-inflammatory triclosan, Boston Scientific) One cm stent segments were rotated at regular intervals while in contact with the cell monolayers. The resulting expression profiles of several pro-inflammatory cytokines and growth factors were analyzed.

**Results:** Following cell injury by the Percuflex stent, supernatants of both cell lines demonstrated significantly increased levels of IL-6, IL-8, b-FGF and PDGF-bb. A498 cells also showed increased TNF-a levels. The triclosan-eluting stent abrogated the pro-inflammatory cytokine increases, while its effects on growth factors varied.

**Conclusion:** This study suggests that stent-related symptoms may be, at least in part, due to a local inflammatory response from epithelial damage caused by the physical movement of the stent. Future stent design should take these inflammatory responses into account and consider the use of more biocompatible materials or a stent that elutes an anti-inflammatory drug.

#### **BR7-06 IDENTIFICATION OF CONDITIONING FILM COMPONENTS ON INDWELLING URETERAL STENTS AND THEIR ROLE IN BACTERIAL ADHESION**

D. Lange, C. Elwood, A. Crowe, R. Miyaoka, M. Monga, B. Chew

**Background:** One of the most common problems associated with indwelling ureteral stents is the adhesion of bacteria to the device surface, facilitated by the formation of a conditioning film shortly

after insertion. We believe that the conditioning films of patients contain a subset of common urinary proteins to which bacteria adhere.

**Methods:** With institutional ethics approval, Polaris stents (Boston Scientific) removed from patients were analyzed for adherent proteins. Stent biofilms were scraped using a sterile scalpel blade and re-suspended in minimal protein solubilization buffer (7M urea, 2M thiourea, 25 mM triethylammonium biocarbonate, 0.2% CHAPS and 0.2% SDS with a protease inhibitor cocktail). The levels of total protein were determined for each sample via Bradford Assay and 5µg were run on a 12% SDS-Polyacrylamide gel. Protein was extracted from gel pieces via gel trypsin digestion and analyzed using Quadrupole Time of Flight Mass Spectrometry.

**Results:** In total, 79 unique proteins were identified on the 60 stents sampled, the ten most common of which are cytokeratin 2 (79%), cytokeratin 1 (71%), cytokeratin 10 (64%), S100A9 (calcium binding protein) (64.3%), cytokeratin 9 (57%), S100A8 (calcium binding protein) (57%), cytokeratin 19 (50%), cytokeratin 8 (50%), Fibrinogen alpha chain (43%), Fibrinogen beta chain (43%), Fibrinogen gamma chain (43%), and Immunoglobulin gamma chain (43%).

**Conclusion:** Of the ten most commonly found proteins, 83% are known binding sites for bacteria. We believe that the key to preventing bacterial adhesion and biofilm formation to indwelling ureteral devices is preventing the deposition of these proteins that act as bacterial anchors—the first step is to identify them.

#### **BR7-07 THIRD GENERATION CRYOSURGERY FOR PROSTATE CANCER—COMBINED EXPERIENCE OF 3 EUROPEAN CENTERS**

U. Witzsch, D. Greene, T. Johansen

**Background:** The technical advances of 3rd generation cryosurgery have produced a minimally-invasive treatment for primary and salvage prostate cancer patients with excellent outcomes and acceptable morbidity. A pan-European approach has led to the development of a Proctoring system and standardisation of the technique of prostate cryosurgery and an agreed treatment protocol across the major European Cryosurgery sites.

**Methods:** The combined results from 3 major European Cryosurgery centres were analysed to give detailed outcomes of 440 patients (pts.) with a maximum follow-up of 7 years and a median follow-up of 36 months. Mean age was 66.05 years. 228 pts had no previous therapy and 212 were salvage cases including 120 radiation failures. 137 pts. were classified low risk (favourable) according to D'Amico classification and 183 intermediate or high risk (unfavourable). Patients were treated with third generation cryotherapy devices SeedNet or Presice (Galil-Medical, Israel). Depending on the length of the prostate needles generating short or long iceballs were used.

**Results:** 36 pts. (8.1%) died, 6 of those due to prostate cancer (1.4%). 32 pts. (7.3%) underwent a second cryotherapy. 70 pts. (15.9%) showed progression of prostate cancer. 4 salvage pts created a fistula. Mean procedure time including learning curve and life cases at workshops was 129 minutes. Progression was seen in the 4% of the favourable and 25% of the unfavourable primary pts. In the salvage group a total of 23% showed progression of disease. This was 37% in the radiation failure group, 17% in the unfavourable group and 18% (only two pts.) in the favourable group. 11.1% underwent a transurethral necrosis removal due to obstructive voiding symptoms. 4.3% of pts are incontinent. Only

about one third of the pts. are sexually active before the cryotherapy. Two thirds out of the sexually active group lost their erectile function at one year.

**Conclusion:** This combined analysis from the three major European centres of Cryosurgery is the largest series of 3rd generation prostate cancer cryosurgery patients yet analysed. The results give a indication of the success rate and the morbidity and is a clear indication of the place of cryosurgery in the management of prostate cancer patients. These data will allow us to counsel patients with greater knowledge and accuracy about their expected outcomes and success from a valuable minimally-invasive technology.

### **BR7-08 IMAGE GUIDANCE IN ROBOT ASSISTED PROSTATECTOMY**

S. Thompson, G. Penney, P. DasGupta, D. Hawkes—United Kingdom

**Background:** We present an image guidance system for robot assisted radical prostatectomy and the results of patient trials. We propose to align preoperative MRI to the patient immediately prior to surgery using tracked ultrasound of the pelvic bone. By tracking and calibrating the robot endoscope it is possible to overlay the MRI image onto the surgeon's view through the endoscope. System accuracy has been determined experimentally with each of the following sources of error quantified: 1. Segmentation of pelvic bone. 2. Registration using ultrasound. 3. Optical tracking through surgical drapes. 4. Equipment calibration errors.

**Methods:** Experiments to determine the system accuracy were performed using 3 cadavers and a customised plastic pelvis phantom. A preliminary system has been used to collect data on two patients. More cases are pending where the full system will be trialled.

**Results:** The results of the phantom and cadaver studies give a system accuracy of 7 mm. Based on the results of the patient trials this appears sufficient to give the surgeon a useful overlay image.

**Conclusion:** The patient trials indicate the full system should be practical for use in robot assisted prostatectomy. By overlaying MRI information onto the surgical scene the surgeon is able to rapidly identify correspondence between the MRI and the video image, enabling better intra-operative decision making and hence improved patient outcomes.

### **BR7-09 SURFACE-BASED REGISTRATIONS IN ROBOTIC IMAGE-GUIDED KIDNEY SURGERY**

H. Altamar, R. Ong, C. Glisson, R. Galloway, S. Herrell

**Background:** We explored the effectiveness of the da Vinci robot system and instruments for surface acquisition and registrations. Additionally, we sought to determine if using regions of high curvature reduce the required surface coverage for currently utilized surface-based registration methods.

**Methods:** Kidney phantoms were imaged using helical CT. An initial point-based alignment using four anatomical points on the kidney surface was performed for two kidney model phantoms. This initial alignment was followed by an iterative closest point (ICP) registration using 100% of the robot surface points, including fiducial targets. Surface acquisition was performed by tracking a

stylus (the robotic instrument) in order to align robotic and image coordinate spaces. Regions of high curvature were then chosen and quality metrics were re-evaluated.

**Results:** The registration error, given by the target registration error (TRE) and closest point distances, was calculated for the initial alignment and subsequent ICP registration. The mean, standard deviation and maximal TRE for initial point-based alignments were 6.8 mm, 4.8 mm, and 15.1 mm and 9.1 mm, 3.6 mm, and 12.5 mm for phantoms 1 and 2, respectively. The same metrics for TRE using ICP registration were 2.7 mm, 1.9 mm, and 4.5 mm and 4.7 mm, 2.7 mm, and 11.1 mm. The mean, standard deviation, and maximal closest point distance for point-based registration were 4.3 mm, 2.9 mm, and 18.4 mm and 2.6 mm, 1.9 mm, and 4.0 mm for phantoms 1 and 2, respectively. Using ICP, these values were 1.3 mm, 0.6 mm, and 3.0 mm and 2.3 mm, 1.0 mm, and 3.8 mm.

**Conclusion:** The registration error decreased when the ICP registration was used and this method of rigid surface registration may represent a viable method of transforming the pre-operative CT to the kidney in robot space. Using between 10 and 20% of the robot-tracked kidney surface with highest curvature yields only slightly higher registration error than using 100%.

### **BR7-10 A COMPARATIVE STUDY BETWEEN AN IMPROVED NOVEL AIR CUSHION SENSOR AND A WHEELED PROBE FOR MINIMALLY INVASIVE SURGERY**

D. Zbyszewski, K. Althoefer, H. Liu, L. Seneviratne, B. Challacombe, P. DasGupta

**Background:** A notable drawbacks of minimally invasive surgery (MIS) is the loss of tactile feedback as direct access to the surgical site prevents the surgeon from specific tissue palpation which can result in operative error.

**Methods:** We propose a comparative study between an improved novel air cushion tactile sensor and a wheeled indentation probe. The aforementioned devices are proposed for rapidly locating abnormalities for soft tissue during MIS. The former device consists of an optically based sensor with a 7.8 mm sphere "floating" on a cushion of air at the tip of a shaft. The latter probe is an 8 mm wide and 8 mm in diameter wheel mounted to a force/torque sensor. A continuous rolling indentation technique over the surface of soft tissue is employed for both sensors. Stiffness variations in viscoelastic materials that are detected during the rolling indentations are illustrated by stiffness maps which can be used for tissue diagnosis.

**Results:** The probes were tested by having to detect three embedded nodules in a silicone phantom. Each probe was attached to a robotic manipulator and was rolled over the silicone phantom in parallel paths. The readings of each sensor generated a stiffness map of the silicone phantom. The results show that both sensors detected reliably the areas of variable stiffness by identifying accurately the location of each nodule.

**Conclusion:** These probes have the potential to be used in MIS as they could provide surgeons with information on the mechanical properties of soft tissue consequently enhancing the haptic feedback.

## BR8: ONCOLOGY

### BR8-01 EVALUATION OF A NEW BIOPSY FORCEPS FOR THE UPPER URINARY TRACT TRANSITIONAL CARCINOMA (UUT-TCC)

D. Legervand, S. Alqahtani, M. Sibony, B. Merlet, O. Traxer—France

**Background:** To evaluate the Biopsy quality for the upper tract urothelial tumors with new biopsy forceps (Bigopsy cook Medical) in comparing with classic biopsy forceps (Piranha Boston Scientific).

**Methods:** We evaluated 15 patients with upper urinary tract transitional cell carcinoma (UUT-TCC) who underwent tumor biopsy and treatment endoscopically. Indications for treatment included a solitary kidney, bilateral disease, modest renal insufficiency, and/or other significant comorbidities. All the biopsies were obtained by Piranha Biopsy Forceps and the Bigopsy Biopsy Forceps for every patient. All the specimens were been analyzed blindly by a single pathologist to determine the best specimen for each patient.

**Results:** From our data we found 6 females and 9 males. The age of patient range from 60 to 90 years with mean  $\pm$  SD ( $77.9 \pm 7.6$ ). The tumor location was found to be in renal pelvis (8), renal pelvis and upper calyx (2), middle calyx (1), lower and middle calyx (1), lower and upper calyx (1), upper third ureter (1), middle third ureter (2). One patient with no valid biopsies whether obtained by the classic or the new forceps. Among these 14 patients, all of the histopathology results of the biopsies performed by the (Bigopsy cook Medical) were better in 9 patients (60%) or equal in 5 patients (33.3%) comparing to the (Piranha Boston Scientific) especially for the stage of the tumor.

**Conclusion:** Our study demonstrates the advantage of this new forceps (Bigopsy Cook Medical) and we strongly recommend it for the evaluation of the (UUT-TCC) especially in case of conservative treatment. **Key words:** ureterorenoscopy, upper urinary tract transitional cell carcinoma, biopsy.

### BR8-02 NARROW BAND IMAGING (NBI) VS WHITE LIGHT ENDOSCOPIC IMAGING (WL) FOR DETECTION OF THE UPPER URINARY TRACT UROTHELIAL TUMORS (UUT-UT)

O. Traxer, S. Alqahtani, B. Geavlete—France

**Background:** The conservative treatment of the (UUT-UT) needs a high quality of endoscopic exploration in order to visualize all the existing tumors. Our aim is to evaluate the advantage of using the NBI for detecting the upper urinary tract urothelial tumors.

**Methods:** From June 2008 to January 2009, 27 patients with (UUT-UT) underwent conservative treatment using flexible ureterorenoscopy with holmium laser. Check ureterorenoscopy was performed in 14 patients as follow-up and initial tumor treatment in 13 patients. The endoscopic exploration were done by using the white light and then by the NBI. We used the Olympus URF-V with digital sensor (Charge-couple device) CCD and integrated NBI function. The biopsies were performed in case of suspected lesions.

**Results:** The NBI increases the detection rate of the urothelial tumors precisely better than the white light (WL). The tumor edges

and its vascularity were been clearer by using the NBI. The NBI allows us to detect 4 non-visualized tumors (23.5%) in 3 patients, which were not visualized by the white light and to identify precisely the tumor edges in 2 patients which was not well defined by the white light.

**Conclusion:** The NBI is an efficient diagnostic method to detect (UUT-UT) comparing to the white-light (WL). We recommend it systemically for the treatment of the (UUT-UT).

**Key words:** narrow band imaging, upper urinary tract urothelial tumors.

### BR8-03 NARROW BAND IMAGING (NBI) FOR THE DETECTION OF RESIDUAL/RECURRENT CANCEROUS TISSUE DURING SECOND TRANSURETHRAL RESECTION (TUR) OF NEWLY DIAGNOSED NON MUSCLE INVASIVE HIGH GRADE BLADDER CANCER

P. Puppo, C. Introini, F. Germinale, F. Bertolotto, A. Naselli—Italy

**Background:** NBI is an optical technology that increases contrast between blood vessels and mucosa. Our aim was to find out if the NBI technology is able to detect high grade cancerous lesions missed with the white light at the time of second TUR.

**Methods:** Consecutive patients with newly diagnosed non muscle invasive high grade bladder cancer were enrolled in a prospective observational study. Patients with incomplete resection or absence of muscle tissue in the specimen were excluded. About 1 month after the first TUR, NBI cold cup biopsies were taken from areas suspicious for urothelial cancer at the end of an extensive white light second TUR protocol including 1) resection of the scar of the primary tumor 2) resection of any overt or suspected urothelial lesions 3) 6 random cold cup biopsies of healthy mucosa.

**Results** 47 consecutive patients were recruited after giving written consent in 2008. Age ranged from 49 to 83, median was 62; 39 were males and 8 females. A total of 9 patients (19%) were found with macroscopic or microscopic non muscle invasive high grade urothelial cancer whereas 1 patient was reassessed as having a muscle invasive disease by mean of the white light second TUR plus the 6 random biopsies. NBI biopsies were taken in 40/47 patients and allowed to detected 6 more patients with high grade cancerous tissue (13%). In all 16/47 patients (34%) were found with residual/recurrent cancer by mean of our extensive protocol of second transurethral resection followed by NBI biopsies.

**Conclusion:** Adding NBI biopsies at the end of an extensive second transurethral resection protocol in patients with newly diagnosed non muscle invasive high grade bladder cancer may lead to the identification of otherwise missed patients with high grade residual/recurrent urothelial carcinoma.

### BR8-04 INTRAVESICAL $\alpha$ -RADIOIMMUNOTHERAPY OF HUMAN UROTHELIAL CARCINOMA IN AN ORTHOTOPIC XENOGRAFT MOUSE MODEL

M. Autenrieth, B. Pfof, C. Seidl, J. Gschwend, R. Senekowitsch-schmidtke—Germany

**Background:** A recurrence rate of nearly 80% after transurethral resection (TUR) of urothelial carcinoma due to disseminated

tumour cells is still a major problem in therapy of bladder carcinoma. Therefore, new therapeutic strategies are urgently needed. The aim of this study was to establish an orthotopic human bladder carcinoma mouse model using the EGFR-overexpressing bladder carcinoma cell line EJ 28-luc and to evaluate therapeutic efficacy of intravesically instilled Bi-213-anti-EGFR-MAb by bioluminescence imaging (BLI).

**Methods:** Urinary bladders of female anesthetized swiss nu/nu mice were catheterized and urothelial lesions were set by electrocautery.  $2 \times 10^6$  human bladder carcinoma cells, stably transfected with firefly-luciferase (EJ28-luc), were inoculated intravesically. Tumour-bearing mice received 0.925 MBq of Bi-213-anti-EGFR-MAb at different time points after tumour cell instillation. Controls received PBS. Mice were imaged weekly by BLI to monitor tumour development and regression after therapy.

**Results:** Tumour growth could easily be monitored by BLI from day 7 after cell instillation. Animals that received Bi-213-anti-EGFR-MAb showed tumour regression independent of tumour size at all time points after therapy. Biodistribution studies following intravesical application of Bi-213-anti-EGFR-MAb showed a negligible systemic spread suggesting no toxic side effects.

**Conclusion:** The orthotopic xenograft mouse model is close to clinical situation after TUR. BLI permits sensitive in vivo monitoring of tumour development and therapeutic efficacy of Bi-213-anti-EGFR-MAb in the murine bladder. Therapy using Bi-213-anti-EGFR-MAb is a very promising approach to reduce the high recurrence rate of urothelial carcinoma after TUR.

#### BR8-05 MITOMYCIN DELIVERED IN HYDROGEL DELAYS BLADDER CANCER DEVELOPMENT

Y. Hou, C. Wang, J. Hu, J. Lu—China

**Background:** Direct instillation of drug solutions into the bladder through a urethral catheter evades systemic adverse effects of drugs used for bladder cancer. In situ bladder cancer murine model is always used to test some special anti-tumor drugs. However, it is difficult to keep the drugs inside the bladder and prolong the drug exposure post instillation. This study was designed to investigate if hydrogel would serve as a matrix for sustained intravesical drug delivery and maintain the anti-tumor effect of the drug.

**Methods:** C57BL/6 female mice were bred and used for experiments at 6 and 12 weeks of age (approximate weight 20 g). For intravesical instillation, mice were anesthetized by intra-peritoneal injection of Pentobarbitone (40–60 mg/kg) and supported with Isoflurane inhalation. MB49 tumor cells were installed into the preconditioned bladders by intravesical inoculation of poly-L-lysine solution to establish the in situ bladder tumors. On the first day post tumor cell instillation, the mice were intravesical treated with mitomycin solution (1 mg/ml) or the same amount of mitomycin in a 30% w/v dispersion of [Poly (ethylene glycol)-Poly[lactic acid-co-glycolic acid]-Poly(ethylene glycol)] (PEG-PLGA-PEG) polymer solution or phosphate buffer solution. After instillations, mice were kept in metabolic cages and were sacrificed 7 days later. Bladders were harvested and underwent histological examination.

**Results:** In the control group, tumors were found in the bladders of all the mice. Tumors were found in 4 mice of all the 15 mice treated with mitomycin (26.7%) and 2 mice of all the 15 mice treated with mitomycin in hydrogel (13.3%). In addition, the tumour size was reduced in the mitomycin hydrogel treated mice compared with the mitomycin group. The results suggested that mitomycin instilla-

tions significantly delayed the development of bladder cancer by restricting tumor growth.

**Conclusion:** This study showed that PEG-PLGA-PEG polymer could be used as a viable sustained drug delivery system for intravesical therapy. Prolonged mitomycin exposure to the bladder afforded by hydrogel may help to avoid or delay the bladder tumor development induced by MB49 cells installation.

#### BR8-06 COMBINED REPETITIVE LOCAL CHEMO-HYPERTHERMIA (SYNERGO®) FOR NON MUSCLE INVASIVE TRANSITIONAL CELL BLADDER CANCER (NMIBC)

F. Hasner, S. Thueroff, C. Chaussy

**Background:** Non-muscle-invasive bladder cancer (NMIBC) recurs in 30–50% within 24 months. 30% progress to infiltrating stage. We analyzed, if repetitive intravesical hyperthermia (42 C°) combined with instillation of Mitomycin-C (MMC) could reduce rate of recurrence/progression of NMIBC after 8 years.

**Methods:** Analysis 9/08: Inclusion: rNMIBC after MMC/BCG, with high Rec-rate or multilocal tumor growth (pTaG1/pTaG2), high risk patients (pT1G2/pT1G3/Cis): 23 Pat between 8/00 and 8/04. 13 adjuvant (2×20 mg MMC), 10 neo-adjuvant (2×40 mg MMC). T×6 times once per week (induction), followed by 6 sessions (maintenance) every month. All TUR before: if resection was complete (= tumor free): adjuvant Tx. If tumor growth was multilocal or resection was incomplete before: neo-adjuvant Tx. Follow up: bladder biopsies every three months. Device used: Synergo® SB-TS 101.1 by Medical Enterprises Europe (MEE) with specific urethral catheters including RF antenna, thermocouples and MMC circulation channels. Costs/Txcycle (Germany 2009): device & service € 1.000 (9%), catheters € 7.200 (66%), MMC € 2.700 (25%).

**Results:** Outpatient Tx: local anesthesia&analgo-spasmolytic iv medication. Tx time/session: 1 h. Tx related adverse effects: urethral strictures (22% “men only”) and bladder fibrosis (9%). Of 13 pat with prophylactic treatment, 5 (38%) were tumor free within 57.6 months, 3 (23%) within 36 months, 2 (15%) within 32 months and only 2 showed recurrences each within 67 months, 1 (6%) within 11 months. Nobody had tumor progression. Of 10 patients in the neo-adjuvant arm 3 (30%) were tumor free within a mean time of 66.3 months.

**Conclusion:** Synergo® Tx is an additional local therapy option in treatment of rNMIBC after failed TUR, MMC or BCG therapy to postpone/avoid cystectomy.

#### BR8-07 HIGH RESOLUTION OPTICAL COHERENCE TOMOGRAPHY (OCT) ON HUMAN BLADDER CANCER AND PRE-CANCER STAGES

G. Joachim, J. Bornemann, B. Hermes, F. Spöler, R. Knüchel-clarke, G. Jakse—Germany

**Background:** OCT—an optical analog to ultrasound imaging—is a non-invasive contactless cross-sectional imaging technique with image resolutions down to 1 μm. Imaging depths are in the range of 1–3 mm. Based on an optical method known as low-coherence interferometry this contactless technique provides high-resolution (HR) images in almost real time. The objective of our study is to distinguish healthy and morphological altered bladder tissue.

**Methods:** An OCT system comprising a Ti:Sapphire femtosecond laser to support a resolution of 3 μm axial×7 μm lateral was employed to image 160 fresh human bladder tissue samples from

cystectomy specimen. The OCT images were finally referenced to histological sections using standard HE staining.

**Results:** Examining healthy areas of bladder tissue using HR-OCT allows a clear differentiation of urothelium and submucosa. Additionally, the basement membrane zone is visualized as a low scattering layer within the highly scattering surrounding tissue. This is also true for non-invasive urothelial lesions. In contrast, images of cancerous lesions does not show the typical layered structure but a more inhomogeneous texture, loss of basement membrane as well as higher local variability in the appearance of the tissue. In this study the specificity was 77.3%, the sensitivity was 86.2%. histology OCT normal urothelium OCT tumor OCT CIS OCT fatOCT no urothelium total normal urothelium 68 4 0 0 16 88 tumor 0 25 0 0 4 29 CIS 0 0 2 0 0 2 fat tissue 0 3 0 8 0 11 nonexsistent urothelium 0 2 0 0 28 30 total 6834 2 8 48 160

**Conclusion:** HR-OCT is a promising modality for the evaluation of bladder microstructures. With the possibility of visualizing the basement membrane zone this new method might have diagnostic importance for in vivo endoscopic procedures to differentiate pTa/C is against higher stages ( $\geq$ pT1). DFG supported, grant no. Kn 263/10-1, Ja 482/5-1, Ku 540/47-2.

#### BR8-08 DIFFUSION-WEIGHTED (DW) MRI IN PATIENTS SELECTED FOR RADICAL CYSTECTOMY: DETECTION RATE OF PELVIC LYMPH NODE METASTASES

R. Papalia, G. Simone, S. Guaglianone, M. Ferriero, E. Forastiere, M. Gallucci

**Background:** We evaluated sensitivity and specificity of preoperative diffusion-weighted (DW) MRI in the detection of Pelvic Lymph Node Metastases in patients with muscle invasive bladder cancer selected for radical cystectomy.

**Methods:** Between November 2008 and march 2009 ten consecutive patients affected by muscle invasive bladder cancer with a mean age of 68 years (range 61–77) underwent CT scan and diffusion-weighted MRI before radical cystectomy. Each examination was performed with T1 and T2 TSE sequences, FLASH 2D/3D with fat suppression, before and after administration of contrast media. All patients underwent radical cystectomy and extended pelvic lymphadenectomy. Nodal packets were sent for pathologic examination separately (right common iliac, left common iliac, right external iliac, left external iliac, right obturator, right hypogastric, left obturator, left hypogastric, and presacral lymph nodes). Sensitivity, specificity, accuracy, positive and negative predictive value of MRI were analyzed matching imaging with pathologic reports. MRI images were evaluated by the same radiologist and histological examinations were performed by a single uro-pathologist.

**Results:** The CT-detection rate of nodal metastasis was 0%. Out of 90 nodal stations pathologically examined, 10 were suspected for metastasis at preoperative DW-MRI. All but one nodal station suspected for metastasis at DW-MRI were positive at pathological examination. The sensitivity, the specificity, the accuracy, the positive and negative predictive value of DW-MRI were 100%, 98.8%, 98.9%, 90.9% and 100% respectively. The sensitivity and the positive predictive value of CT scan were not significant in our series, while the specificity was 100% and the accuracy and negative predictive value were both 88.9%. The main limit of this study is the small size of the examined population.

**Conclusion:** Despite comparable specificity, the sensibility of DW-MRI and CT scan were significantly different. Although preliminary results of DW-MRI in preoperative nodal staging of

muscle invasive bladder cancer are encouraging they need to be further validated by larger series.

#### BR8-09 MEASURING IMMUNE RESPONSES IN PROSTATE CANCER

R. Viney, G. Priti, P. Searle, E. Porfiri

**Background:** We will be embarking on a phase I/II clinical trial using a combination virus delivered enzyme prodrug therapy and immunotherapy in patients with locally advanced hormone refractory prostate cancer. We will use an E1/E3 deleted replication deficient adenovirus vector expressing nitroreductase and granulocyte macrophage colony stimulating (GM-CSF) factor off a cytomegalovirus promoter. We will use CB1954 as the prodrug. Tumour response will be measured with serial prostate specific antigen assessment but a robust validated assay to measure the impact of any GM-CSF expressed on immune responses is needed. **Methods:** With appropriate consent, PBMCs were extracted from Buffy coats, healthy donors and prostate cancer patients. B cells were extracted and activated with CD40 ligand in different ways to generate antigen presenting cells (APCs). Using a variety of antigens, nucleofection and transfection protocols were explored to maximize expression. These APCs were then co-incubated with autologous T cells to optimize ELISpot and ELSA assays for the interferon gamma released. These techniques were then applied to samples from a variety of prostate cancer patients.

**Results:** Antigen presented by CD40 ligand activated B cells after electroporation nucleofection can stimulate the release of interferon gamma from autologous T cells in people sensitized to that antigen. A variety of immune responses are seen in patients with prostate cancer.

**Conclusion:** We present a validated assay for cellular immune responses evident in peripheral blood from patients with prostate cancer and some early data on these responses from various patients with prostate cancer.

#### BR8-10 MULTIDETECTOR CT RENAL ANGIOGRAPHY FOR PREOPERATIVE EVALUATION OF LAPAROSCOPIC RADICAL NEPHRECTOMY

R. Zeng, Y. Sun, X. Gao—China

**Background:** We studied the accuracy and value of multidetector CT (MDCT) renal angiograph in the evaluation of renal cell carcinoma for radical nephrectomy, and found that MDCT angiography is highly accurate for detecting vascular anomalies and providing anatomic information for laparoscopic radical nephrectomy.

**Methods:** Sixty patients of renal cell carcinoma (mean age, 55.7 years) who underwent laparoscopic radical nephrectomy (LRN) were evaluated by means of MDCT. Scans were reconstructed at 1-mm intervals for three-dimensional (3D) imaging using technique of volume-rendering, maximum intensity projection (MIP) and multi-planar reformation (MPR). Axial CT images and 3D CT angiography were evaluated prospectively by one reviewer and retrospectively by two reviewers who had no knowledge of surgical results.

**Results:** All patients undergo transperitoneal laparoscopic radical nephrectomy in the guidance of MDCT. Thirty-two patients underwent left LRN, and twenty-eight patients underwent right LRN. Nine supernumerary renal arteries (two arteries to 7 kidneys and three arteries to one kidney) to 60 kidneys underwent LRN. CT and surgical findings agreed in 93% of subjects (the average of three

reviewers; range, 89–97%). Two small accessory renal arteries were missed by all three reviewers. Those arteries were diminutive and were thought to be insignificant by the surgeons. Renal vein anomalies were present in eight subjects, and CT and surgical findings agreed in 99% of the cases (range, 96–100%). The Sur-

geon shorten the time looking for supernumerary renal artery in the direction of MDCT.

**Conclusion:** MDCT angiography is highly accurate for detecting vascular anomalies and providing anatomic information for laparoscopic radical nephrectomy.

## MP1: PROSTATE DIAGNOSIS AND TREATMENT

### MP1-01 EARLY DETECTION OF PROSTATE CANCER IN PATIENT WITH PROSTATIC SPECIFIC ANTIGEN LEVELS OF 2.5 TO 4.0 NG/ML

S. Shah—India

**Background:** Investigate the cancer detection rate and clinical relevance of prostate cancer in this PSA range 2.5 to 4.0 ng/ml. Lowering the cutoff value of PSA may improve detection at least for younger man who would potentially benefit more from early detection.

**Methods:** All urological patients above 45 years were subjected to routine PSA assay and DRE examination. Between April 2007 to January 2009 there were 51 patients with PSA between 2.5 to 4.0 ng/ml. All these patients were subjected to 6 core Transrectal Biopsy.

**Results:** Out of the 51 patients with PSA between 2.5–4.0 ng/ml 5 patients were having Prostatic carcinoma. Thus the Cancer detection rates in patients who underwent biopsy were 10.02 % at PSA levels 2.5 to 4.0 ng/ml.

**Conclusion:** Detection of prostate cancer at PSA threshold below 4.0 ng/ml may improve the chance of cure and disease free outcome.

### MP1-02 DOES MAXIMAL PERCENT OF CORE BIOPSY POSITIVE FOR PROSTATE CANCER CORRELATE TO PREDICTORS OF DISEASE RECURRENCE?

M. Lux, T. Greene, E. Erturk, J. Joseph—USA

**Background:** Although there is a significant amount of literature about the percentage of cores positive on prostate biopsy, very little information exists regarding maximal percent of an individual core biopsy positive (MPCBP). In this study, we evaluate the relationship of MPCBP to predictors of prostate cancer recurrence.

**Methods:** The MPCBP value for an individual patient was determined by prospectively collecting the largest percentage of any individual core from a sample of 311 patients. Patient demographics, predictors of biochemical recurrence (BCR), and BCR (defined as postoperative PSA  $\geq 0.1$  ng/ml) were all collected prospectively. Univariate analysis and logistic regression were performed to determine correlation.

**Results:** 311 patients at time of surgery had an average MPCBP of 31.8%. Using MPCBP as the variable, univariate analysis found percentage of tumor in surgical specimen, pre-operative Gleason, and post-operative Gleason significant at  $<0.0001$ . Logistic regression for extracapsular extension found T3a and T3b disease to be significant at the 0.0023 and 0.0005 levels respectively. When using MPCBP as the response variable in univariate analysis, for each increase in pre-operative Gleason sum, the MPCBP increased by 16.9%. Positive PLND's had a 49.7% increase in MPCBP. pT3a and pT3b patients had 19.7% and 28.1% increase in MPCBP over

that of pT2 disease. MPCBP was not found to correlate with BMI, pre-op PSA, or recurrence.

**Conclusion:** Although MPCBP was not found to predict BCR in the current cohort, MPCBP was shown to have a significant impact on pathologic stage, Gleason sum, and tumor volume.

### MP1-03 PROSTATE BRACHYTHERAPY: COMPLICATIONS, PROGNOSTIC FACTORS, SEXUAL FUNCTION AND RESULTS FROM 300 CASES

A. Rempelakos, A. Marketakis, A. Papas, T. Arvanitakis, E. Koutsiaris, A. Thanos

**Background:** To evaluate the prognostic factors for acute urinary retention, sexual function and results after prostate brachytherapy.

**Methods:** From December 2000 to March 2009 300 consecutive patients with localized prostate cancer treated with brachytherapy. The preimplant, prostate volume was more than 31cc in 87 patients and international prostate symptoms score (IPSS) were more than 17 in 45 patients. The follow-up ranged between 3 and 96 months (median 38.7). The clinical and treatment-related factors were evaluated for the catheterization owing to urinary retention.

**Results:** Twenty-seven (8.7%) patients required catheterization because of urinary retention. In 24 of those patients the prostate size was more than 36cc and the IPSS was more than 15. In all those patients the number of needles was more than 23. Nineteen catheterized patients were successfully relieved from their catheter by nonsurgical means ( $\alpha$ 1-blockers plus anti-inflammatory) and eight underwent transurethral resection of the prostate (TUR-P) not earlier than 7 months postimplant. From the potent patients pre-implantation, 66% remained unchangeable at the end of the first year and 60% after the second year. Thirty-four patients (10%) appeared biochemical relapse during the follow-up.

**Conclusion:** From our results it seems that preimplant prostate volume, IPSS and the number of the needles are the strongest predictors factors for catheterization. Catheterized patients who are refractory to medical therapy can safely undergo a minimal TUR-P. The incidence of impotence also increase after the second year of implantation. Although it is early to comment on the outcome of this method it is encouraging as only 30 patients (10%) appeared biochemical relapse.

### MP1-04 IS THE PSA NADIR AFTER HIFU TREATMENT OF LOCALIZED PROSTATE CANCER DEPENDENT ON THE GENERATION OF HIFU TREATMENT DEVICE?

R. Ganzer, H. Fritsche, W. Wieland, A. Blana

**Background:** PSA nadir after HIFU treatment of localized prostate cancer (PC) correlates highly with oncologic outcome.



Disease-free survival rates at 5 years (Phoenix criteria) has been shown to be as high as 95% if the PSA nadir was  $\leq 0.2$  ng/ml. Since the development of the Ablatherm Prototype (Edap, France) HIFU technology has advanced with the Maxis and the Integrated Imaging device. In this study we investigate if the PSA nadir is dependent on the generation of HIFU devices used.

**Methods:** Between November 1997 and April 2006 184 patients underwent HIFU treatment for clinically localized PC and were followed-up every three months. Patients with a minimum follow-up of one year were analysed retrospectively. Twenty-five (13.6%), 127 (69.0%) and 32 (17.4%) of patients were treated with the Ablatherm Prototype, Maxis and the Integrated Imaging, respectively.

**Results:** Mean age was  $66.5 \pm 6.4$  years, mean PSA  $7.5 \pm 3.9$  ng/ml. The groups were similar concerning risk group, PSA and number of positive biopsies. The median biopsy Gleason score was 5 (3–7), 5 (3–7) and 6 (4–7), respectively ( $p = 0.002$ ). The PSA nadir was achieved after a mean time of  $21.2 \pm 11.9$  weeks. A PSA nadir of  $\leq 0.2$  ng/ml was achieved in 48%, 70.9% and 78.1% by the Prototype, Maxis and Integrated Imaging device, respectively, which was highly statistically significant ( $p = 0.009$ ).

**Conclusion:** Significantly more patients achieved a PSA nadir  $\leq 0.2$  ng/ml with the latest generation of Ablatherm device (Integrated Imaging). This could be shown to be associated with favourable oncologic outcome. The results mirror the benefit of advanced HIFU technology.

#### MP1-05 FOCAL THERAPY WITH HIFU FOR PROSTATE CANCER IN THE ELDERLY: A FEASIBILITY STUDY WITH 10 YEARS FOLLOW-UP

A. Benchikh, E. Barret, R. Sanchez-salas, D. Prapotnich, X. Cathelineau, G. Vallancien—France

**Background:** To evaluate focal therapy for prostate cancer with high-intensity focused ultrasound (HIFU) in patients older than 65 years. Initial experience with long term results is presented.

**Methods:** From June 1997 to March 2000, 12 patients were included in a focal therapy protocol with HIFU. Patients were fully informed and consented the procedure. Data was prospectively collected and retrospectively analyzed. The endpoint of the study was defined as cancer specific survival. Patients outcomes at latest evaluation were also matched with The Phoenix criteria. Functional outcomes in terms of urinary status and continence were assessed. Sexual function was not included in the analysis. Inclusion criteria: PSA  $\leq 10$  ng/ml,  $\leq 2$  positive biopsies with only 1 only lobe involved, Clinical stage, Gleason score  $< 7$  (3 + 4), Negative CT scan and bone scan. Technique: Patients underwent HIFU with the first-generation of Ablatherm device (Technomed SA, Vaux en Velin France) using a 2.5 and 3 MHz probe. Treatment was performed in one lobe only in each prostate. Procedure was performed under general anesthesia. Transurethral resection of the prostate (TURP) was indicated in the last six patients in order to reduce the risk of post-operative acute urinary retention (AUR). Follow-up: Clinical evaluation including a DRE and PSA test every 6 months during 5 yr then annually, Control biopsies were performed at 1 yr, Urinary status (IPSS score) and continence were evaluated, Treatment failure was defined as any positive biopsy in treated lobe or any salvage therapy requirement.

**Results:** Twelve patients with a mean age 70 yr (65–75) were treated. Mean follow-up was 10 yr (8.5–11.5). Control prostate biopsies were negative in 11/12 (91%) patients at one year after the

procedure. Cancer specific survival was 100% at 10 years and overall survival was 83% (10/12), 2 patients died at 2 and 3 yr from other causes. Disease free survival was 59% (7/12) at 10 yr. Postoperative PSA levels lowered in all patients treated. Five patients had a salvage therapy with HIFU or hormonal therapy and are still alive after at 10 yr follow-up. None of the patients developed bone metastasis. No urinary incontinence was referred and mean IPSS of X (X-X) was verified at 1 year. Complications included AUR (1 patient) and urinary infections (2 patients). There were no complications associated with re-treatment with HIFU. Interestingly, recurrences observed in present series concord with more recent Phoenix criteria.

**Conclusion:** Focal therapy with HIFU is a reasonable treatment strategy with an effective long-term cancer control and a low complication rate for a selected population of men older than 65 years. Re-treatment with HIFU is safe and feasible without any cumulative side-effects of ultrasonic energy. Results from larger prospective studies using improved imaging techniques and extensive biopsy protocols are awaited.

#### MP1-06 EXPERIENCE OF TRANSRECTAL HIGH-INTENSITY FOCUSED ULTRASOUND IN THE TREATMENT OF LOCALIZED PROSTATE CANCER

K. Goto, T. Hayashi, Y. Inoue, M. Hayashi

**Background:** We evaluated the treatments of transrectal high-intensity focused ultrasound (HIFU) for patients with localized prostate cancer (T1–2).

**Methods:** One hundred fifteen patients with localized prostate cancer were treated with 130 sessions of HIFU, and the results were analyzed. The HIFU device we used was the Sonablate 500<sup>®</sup> (Focus Surgery, IN, USA). As the follow-up examinations, the sextant biopsy was conducted at 6 months and the serum prostate-specific antigen (PSA) was measured every 3 months after HIFU treatment.

**Results:** The followed-up periods after HIFU in these cases were 12–69 months (median 30 months). No major postoperative complications associated with these treatments were found, although urge incontinence in 13 cases and dysurias in 32 cases were observed after removal of the urethral catheter. Of 115 cases, 97 patients had normal PSA, including 61 patients with PSA  $< 1.0$  (59%). Of 113 patients who received prostate biopsy at 6 months after HIFU, 109 cases were found to be negative (96%). The overall complete response rate in 115 cases was 81.0% based on the Gelet's criteria. As for the risk groups, the rates of low, intermediate and high risk group were 92, 88 and 61%, respectively.

**Conclusion:** The clinical results of HIFU in this series was proven to be an effective, repeatable and minimally invasive treatment, furthermore, it can be another option for patients with localized prostate cancer.

#### MP1-07 HIGH INTENSITY FOCUSED ULTRASOUND (HIFU) FOR THE TREATMENT OF LOCAL RECURRENCE OF PROSTATIC CANCER AFTER RADICAL PROSTATECTOMY: EVALUATION WITH TISSUE RESONANCE INTERACTION METHOD PROBE (TRIMPROB<sup>®</sup>) AND COMBINATION OF ENDORECTAL MRI AND SPECTROSCOPY

B. Carlo

**Background:** To evaluate the efficacy of TRIMprob<sup>®</sup> device combined with endorectal magnetic resonance imaging (MRI) and magnetic resonance spectroscopic imaging (MRSI) in patients

underwent to radical prostatectomy with curative intent, for detecting local recurrence of prostatic cancer before and after treatment with High Intensity Focused Ultrasound (HIFU).

**Methods:** Between January 2004 and September 2008 we investigated 191 patients who had undergone radical prostatectomy with curative intent, with PSA nadir (obtained 6 weeks after radical prostatectomy)  $<0.20$  ng/ml and subsequent disease progression  $>10$  months after treatment. Disease progression was defined as a PSA level of 0.2 ng/ml or greater or initiation of androgen deprivation therapy. Suspicious zones in prostatic bed can be identified with the TRIMprob<sup>®</sup> test through using an analysis of 465 MHz resonance. This frequency is characteristic of the electromagnetic interaction with abnormal biological conditions caused by tumor metabolism and is characterised by an increase of incoherence and disorder, resulting in the reduction of the first line below 10% in at least two anterior and posterior projections in a time persistent manner. The indication for MRI imaging was a focal nodular region of low intensity signals on T2 weighted images. MRSI criteria for tumor were voxels with choline (Cho) plus creatine (Cr) to citrate (Cit) ratio  $([Cho + Cr]/Cit)$  of at least 0.5 or voxels with detectable Cho in prostatic bed after RP. Patients with a confirmed recurrent were treated with HIFU and all patients underwent a Trans Rectal Ultra Sound examination before and after HIFU and Trimprob/MRI/MRSI analysis. The TRUS findings, digital rectal examination (DRE) findings, serum total prostate-specific antigen (PSA) level, Trimprob and MRSI findings were noted before and after HIFU treatment. All patients underwent to anastomotic zone biopsy. To exclude possible metastasis to lymphnodes and bones all patients underwent prior PET colina and abdominal CT. All the patients underwent a 10—core biopsy protocol targeted to the prostatic bed according to the findings obtoneid from Trimprob and MRSI. PSA nadir (at 3 months) following HIFU was used as a surrogate for longer term efficacy.

**Results:** Diagnosed 59 new cases of Local Recurrence of Prostatic Cancer (59/191—30.8%). 15 patients of these underwent HIFU Ablatherm<sup>®</sup> treatment; other patients received a different therapy. The mean age was 68.2 years (63—72.6), and mean PSA serum before the treatment was 2.5 ng/ml (0.2—21). After the treatment with HIFU, the mean PSA nadir was 0.35 ng/ml. All patients were analyzed before and after HIFU treatment with Trimprob/MRI/MRSI analysis and the results were compared with PSA biochemical value.

**Conclusion:** TRIMprob according to the prostate specific antigen elevation and MRI/MRSI imaging has been useful to distinguish men with local recurrence of prostatic cancer. HIFU appears to be effective as a treatment for local recurrences following radical prostatectomy. Further study is needed.

#### **MP1-08 HIGH-INTENSITY FOCUSED ULTRASOUND (HIFU) VS RADICAL PROSTATECTOMY IN LOCALIZED PROSTATE CANCER: IS POSSIBLE TO SAVE ERECTILE FUNCTION?**

B. Carlo

**Background:** The growing interest in high-intensity focused ultrasound (HIFU) is mainly due to its promise as a minimally invasive therapy. HIFU has been assessed for its role in the treatment of localized prostate cancer in patients who otherwise would not have benefited from surgery and in local recurrences after radiation failure. To assess the short-term outcome and evaluate the post treatment erectile function in patients with prostate cancer treated by

transrectal high-intensity focused ultrasound (HIFU) in comparison to patients who underwent to radical retropubic prostatectomy (rP). **Methods:** we analyzed the erectile function in 140 patients with T1-T2 prostatic cancer before and after to underwent HIFU treatment (case), versus a control group, 171 patients with prostatic cancer treated with radical retropubic prostatectomy. None of the patients, case or control received neoadjuvant and/or adjuvant therapy. All patients were analyzed with NPT test and color Doppler test before and after to underwent HIFU or traditional surgery for prostatic cancer. All patients received 10 mg taladafil, every 3 day for three months.

**Results:** High biochemical efficacy, excellent tumor local control and favorable mid-term oncological data with a low morbidity rate have already been proven in those series of patients. In patients who underwent HIFU, 85% (120/140) had preservation of erectile function. Of the 90 patients who underwent nerve sparing radical prostatectomy 36 maintained potency (36/90—40%) and of the 81 who underwent non-nerve sparing prostatectomy 7 has preservation of erectile function (7/81—8.6%).

**Conclusion:** HIFU is an emerging technology that is attractive to patients and physicians due to its minimally invasive nature. Although not a randomized trail the outcomes of potency preservation are encouraging in comparison to radical prostatectomy. More study is needed.

#### **MP1-09 LONG TERM CANCER-SPECIFIC SURVIVAL FOR MEN FOLLOWED MORE THAN 10 YEARS AFTER PROSTATE CRYOABLATION**

P. Cheetham, A. Katz—USA

**Background:** Albertsen reported 10 year disease-specific survival for clinically localized prostate cancer after radical radiotherapy; 93%, 88%, 80% for low, medium, high risk groups respectively. We report long-term cancer survival rates for men who had prostate cryotherapy over 10 years ago.

**Methods:** 49 men stratified according to low, moderate and high risk groups underwent prostate cryotherapy (primary or salvage) before 11.1.98. Data retrieved pre-, intra- and post treatment included; patient age, presenting PSA, Gleason grade, primary or salvage treatment, biochemical failure (ASTRO definition) and need for adjuvant hormones. Primary endpoints were overall mortality and prostate cancer-specific death.

**Results:** Mean age 69 yrs, preoperative PSA 14.91, median follow up 11.3 years; mean Gleason score was 7 (range 4—9). 8 primary cases; 39 post radiation; 2 unspecified; 33 received hormones post ablation. At 10 years 29 men were still alive (59.2%). Only 3 (6.1%) had died of prostate cancer and 9 (18.4%) had died of non cancer causes.

**Conclusion:** Longterm results of prostate cryotherapy in our series are extremely good, with 94% 10 year prostate cancer-specific survival despite early cryotherapy technology. Our findings suggest that patients undergoing cryotherapy may have a cancer specific survival advantage compared to those electing for radiation or hormones alone.

#### **MP1-10 OUTCOMES OF HORMONE NAIVE HIGH-RISK PROSTATE CANCER PATIENTS TREATED WITH THIRD GENERATION PROSTATE CRYOTHERAPY**

P. Cheetham, A. Katz—USA

**Background:** Traditional therapy for elderly men with high risk prostate cancer is long-term hormones and radiotherapy. With the

emergence of newer technology high energy ablative therapies the possibility of similar or improved outcomes has been postulated. We report on outcomes and QoL after modern-day primary prostate cryoablation in D'Amico high risk patients.

**Methods:** We studied 55 "high risk" patients who underwent total primary prostate cryotherapy. Patient demographics, intra- and post treatment data was evaluated. Primary endpoints were mortality and disease recurrence/progression. Biochemical failure was assessed according to the Phoenix definition.

**Results:** There were no reported deaths during follow up. There were no intra-operative complications, postoperative rectal fistulae or new incontinence. Of the 19 men who did not receive hormones biochemical disease free survival was 63%. 7 failed by the Phoenix criteria however, none of these patients were found to have new bone or lymph node metastases.

**Conclusion:** Prostate cryoablation is a controversial treatment for high risk patients. Our early experience revealed no cancer-specific mortality, low morbidity, and encouraging biochemical and local control rates for these high risk patients without the use of radiation or hormones. These results support the further study of prostate cryoablation for high risk patients.

#### **MP1-11 FOCAL PRIMARY CRYOTHERAPY FOR PROSTATE CANCER: EARLY OUTCOME DATA FOR LOW RISK PATIENTS**

P. Cheetham, A. Katz—USA

**Background:** Cryotherapy as a treatment modality for prostate cancer has traditionally targeted treatment of the entire gland. Partial gland (focal) prostate cryoablation addresses only known cancerous foci, sparing healthy tissue. The objective was to report our outcomes of focal cryoablation.

**Methods:** A retrospective review of our IRB approved on-line cryotherapy database was performed. Inclusion criteria: PSA <10 ng/mL, Gleason score 6, tumor stage T1/T2 who underwent focal primary cryoablation. None received radiation or hormone therapy. Data retrieved included; patient age, presenting PSA, prostate volume, Gleason grade, biochemical failure (defined according to the ASTRO definition of 3 consecutive PSA rises) and need for adjuvant hormones.

**Results:** 38 men fulfilling criteria received focal cryoablation by a single surgeon. Mean values: patient age 69 years; presenting PSA 4.88 (range 1.2–8.8); 22 patients clinical stage T1c; 1 patient T2; 15 unknown; mean prostate volume 49.8 (range 16.9–101) median IPSS 6; (out of five patients); median pre-treatment IIEFF 30 (out of five patients); mean follow up 19.4 months (range 1–86.5 months). 4/38 (11%) developed transient haematuria but none went into urinary retention or required admission. There were no new cases of urinary incontinence. There were no reported fistulae. 26/38 (68.4%) patients had documentation of >3 postoperative PSA's. Of these 26 men, 21 (55.3%) had confirmed biochemical disease free survival, with no PSA rise after reaching their PSA nadir. Biochemical status was unknown for 12 men. 5 of the 26 men had biochemical failure according to the ASTRO criteria and 4 of them had a prostate biopsy. Histology revealed: 2 benign; 1 high grade PIN, 1 Gleason 6 on contralateral side who subsequently had a repeat focal procedure on the affected side. None received adjuvant hormones.

**Conclusion:** Primary focal cryoablation has low morbidity with early efficacy supported by encouraging 19 month biochemical disease free survival rates. It is a viable option for carefully se-

lected patients. Long term disease control will determine the role of focal cryotherapy.

#### **MP1-12 AFRICAN AMERICAN MEN HAVE LOWER RATE OF CASTRATE RESISTANT PROSTATE CANCER ON PRIMARY LHRH AGONIST THERAPY**

P. Sassani, J. Blumberg, J. Gleason, C. Cheetham, S. Williams, G. Chien

**Background:** It is well documented that African American males in the US are disproportionately affected by prostate cancer, having higher incidence of advanced stage at diagnosis and mortality from prostate cancer. Given that Leutinizing Hormone Releasing Hormone (LHRH) agonist therapy is one of the mainstays of treatment for advanced stages of prostate cancer, we investigated the biochemical failure rate among different races in men treated with LHRH agonist therapy for prostate cancer.

**Methods:** Patients with prostate cancer who received LHRH agonist therapy in the Kaiser Permanente Southern California Cancer Registry from January 2003 to December 2006 were evaluated. Only patients who received LHRH agonist as primary monotherapy were included in this analysis. (Patients who had prior treatment for their cancer with surgery or radiation were excluded). Treatment failure was defined as a rise in PSA more than 2 ng/ml from nadir PSA, with no subsequent decrease in PSA. We compared the biochemical failure rate in Caucasian patients compared to African American, Hispanic, and Asian/other/Unknown. Cox proportional hazards regression model was used to estimate the Hazards Ratio (HR) for failure among the groups.

**Results:** Our study population consisted of 681 patients who received an LHRH agonist as primary mono-therapy, with the following breakdown regarding race: Caucasian = 416 (61%), African American = 107 (16%), Hispanic = 107 (16%), and Asian/Other = 51 (7%). After controlling for all demographic and prostate cancer related variables, the relative risk for treatment failure was as follows: African American vs. Caucasian (HR = 0.66, p = 0.03), Hispanic vs. Caucasian (HR = 1.00, p = 0.8), Asian/other vs. Caucasian (HR = 1.5, p = 0.1). In this multivariate analysis, pre-treatment PSA and stage were the only other variables that were associated with higher risk of treatment failure. Pre-treatment baseline testosterone was also evaluated in this cohort, and no significant differences were noted between ethnic groups.

**Conclusion:** For patients receiving LHRH agonist as primary mono-therapy for their prostate cancer. African-American patients had a significantly lower rate of treatment failure (early androgen resistance) compared to Caucasian men. While the etiology of this finding is unclear, it suggests the possibility that prostate CA in African American men may be more androgen sensitive, despite no significant differences in pre-treatment baseline testosterone.

#### **MP1-13 INCIDENTAL PROSTATIC ADENOCARCINOMAS IN TURP OVER A 12 MONTH PERIOD**

S. Pereira, D. Martinho, R. Rodrigues, T. Mendonça, C. Soares, H. Correia—Portugal

**Background:** Before the generalization of PSA use, localized prostate cancer [PCa] was only found through histological examination of transurethral resection of the prostate [TURP] or open adenectomy specimens, with rates varying between 10 and 31%. Nowadays incidental PCa rates are between 5 and 8%. Unlike previously accepted, recent studies showed that incidental PCa isn't always indolent, presenting disease specific mortality rates of

26.6% at 10 years. This retrospective study aimed to evaluate incidental PCa rate at our institution.

**Methods:** The files of all patients submitted to TURP over a 12 month period at our institution were analyzed.

**Results:** Over a 12 month period, 186 patients were submitted to TURP at our institution. Eleven were excluded due to a history of PCa and two due to previous negative prostatic biopsies. We found 10 patients with incidental PCa (5.71%). The average age of patients was 72.3; average PSA was 1.73 (0.6–4.4); average PSA density was 0.05 (0.02–0.13); and average Gleason score was 6 (4–8). Seventy percent of these patients were in stage T1a, with the remaining 30% in stage T1b.

**Conclusion:** Despite the systematic use of the PSA, incidental PCa is unavoidable, indicating that this screening method isn't always accurate. These patients are being watched for future clinical output reports.

#### **MP1-14 ROBOTIC-ASSISTED LAPAROSCOPIC RADICAL PROSTATECTOMY IN PATIENTS WITH PROSTATE CANCER WITH HIGH RISK FEATURES: PREDICTORS OF FAVORABLE PATHOLOGIC OUTCOME**

R. Munver, J. Yates, M. Gross, D. Golombos, J. Uberoi, I. Sawczuk—United States

**Background:** Preoperative determination of pathologic outcomes in patients with high risk prostate cancer is challenging due to limitations of existing nomograms. We assessed whether preoperative clinical and pathologic characteristics correlate with pathologic outcome in high risk prostate cancer patients following robotic-assisted laparoscopic radical prostatectomy (RALP).

**Methods:** A retrospective evaluation of patients with high risk disease (PSA  $\geq 10$  ng/dL or Gleason score  $\geq 8$ ) that underwent RALP between December 2004 and September 2008 was conducted. Patients were grouped based on favorable pathology, including organ-confined disease and negative surgical margins (Group 1), and unfavorable pathology, including positive surgical margins or extracapsular extension (Group 2). Preoperative PSA levels, TRUS findings, and biopsy reports were compared to final pathology data.

**Results:** Of 69 patients, 40 had high PSA levels [mean 16.4 ng/dL; range 10–39.9 ng/dL], and 39 had high Gleason scores [GS 8 (n = 24); GS 9 (n = 14) GS 10 (n = 1)]. Ten patients had high PSA and Gleason scores. 37 patients (54%) had favorable postoperative pathology (Group 1), compared 32 (46%) with unfavorable pathology (Group 2). Mean PSA was 10.0 ng/dL (range 4.1–20.3) (Group 1) and 13.8 ng/dL (range 3.1–39.9) (Group 2). Mean PSA density was 0.28 (Group 1) and 0.41 (Group 2). Mean positive biopsy cores was 33% (Group 1) and 44% (Group 2). Differences in PSA levels, PSA density, and percentage of positive cores were statistically significant ( $p < 0.05$ ) between the groups. Bilateral disease and HGPN were not statistically significant ( $p > 0.05$ ).

**Conclusion:** Lower PSA level and PSA density, as well as fewer positive biopsy cores, were associated with favorable postoperative pathology. Continued surveillance will serve to determine whether these findings will assist in predicting which high risk prostate cancer patients are most likely to benefit from RALP.

#### **MP1-15 NERVE-SPARING ROBOTIC-ASSISTED LAPAROSCOPIC RADICAL PROSTATECTOMY: COMPLIANCE WITH A POSTOPERATIVE PENILE REHABILITATION PROGRAM**

J. Yates, D. Shin, D. Golombos, M. Gross, I. Sawczuk, R. Munver—United States

**Background:** The use of phosphodiesterase 5 (PDE-5) inhibitors is hypothesized to increase penile blood flow and aid in return of sexual function in patients undergoing nerve-sparing radical prostatectomy. We analyzed patient compliance with a penile rehabilitation program in patients that underwent robotic-assisted laparoscopic radical prostatectomy (RALP).

**Methods:** This prospective analysis included patients that underwent RALP between July 2007 and October 2008. All patients completed the sexual health inventory for men (SHIM) questionnaire preoperatively. Patients that had a bilateral nerve-sparing procedure and adequate preoperative sexual function (SHIM  $\geq 20$ ) were included. Penile rehabilitation consisted of postoperative sildenafil 50 mg nightly. Patient compliance and reasons for discontinuation of therapy were recorded and correlated to return of erectile function.

**Results:** A total of 40 patients met inclusion criteria. Mean age was 58.7 years (range 45–72), and mean preoperative SHIM was 21.1 (range 20–25). Initially, 27 patients (67.5%) reported nightly use of sildenafil postoperatively. In patients that did not comply, the reasons included medication cost (56%), side effects (22%), and lack of interest in sexual activity (22%). After 1 month,  $>50\%$  of patients reported non-compliance, citing cost as the primary reason. The median follow up was 11 months, at which point 32% of patients had full return of sexual function, 30% had partial return of function, and 38% had no erections.

**Conclusion:** Approximately half of patients in this study were not compliant with the prescribed penile rehabilitation program due to the high cost of the medication. While the optimal regimen remains to be determined, clinicians must consider cost as a factor in prescribing PDE-5 medications for patients undergoing RALP.

#### **MP1-16 HAS PRIMARY PROSTATE CANCER THERAPY AN EFFECT ON TUMOR AGGRESSIVENESS IN CASE OF TUMOR RECURRENCE?**

S. Thueroff, F. Hasner, K. Herzog, R. Nanieva, C. Chaussy

**Background:** Prostate cancer (PCa) therapy can be performed by surgery (S), radiation (R), hormonal ablation (HA) or high intensity focused ultrasound (HIFU). After any therapy rPCa can occur and leads to a restaging. Prostatic biopsies are the most important staging tool. Histological analysis allows topographic, volume and aggressiveness analysis of the current PCa stage. These biopsies can be compared to primary staging biopsies. Histo-pathological differences between primary and recurrent PCa help to understand impact of primary therapeutic modalities on disease development.

**Methods:** Analysis by prospective Harlaching database: Patients with Gleason scoring before and after therapy (S/R/HA/HIFU), coming for secondary therapy of recPCa have been included into the analysis. PSAi, Tumorvolume, Gleason for primary as recurrence therapy was analyzed.

**Results:** 126 patients were isolated with complete data set for analysis after n = 35(S); n = 22(R); n = 33 (HA); n = 36(HIFU). Gleason "i": 7 (4–9) (S); 6.5 (4–8)(R); 7 (4–9)(HA); 7 (5–10)(HIFU). PSAi: 11.7(S); 11.5(R); 16.5(HA); 10.3(HIFU). rPSA: 1.8 (0.19–9.6)(S); 7 (1.2–30)(R); 9.5 (0.5–507)(HA); 2.1 (0.25–36)(HIFU). rGleason: 7(3–9)(S); 7(5–10)(R); 9 (6–10)(HA); 7 (4–9)(HIFU).

**Conclusion:** Histo-pathological analysis after therapies as (S/R/HA/HIFU) is possible: Gleason can be determined. "mechanical"

local therapies (S/HIFU) did not show problems in histological analysis or Gleason score interpretation nor a Gleason increase in recPCa (disease did not get more aggressive in time!!). Hormonal ablation (HA) as radiation therapy (R) showed Gleason shift to higher grades! Whether this is due to cell selection by therapy (iatrogenic) or due to negative case selection (statistics) should be subject to further studies.

### MP1-17 IS PREOPERATIVE CYSTOSCOPY WARRANTED FOR PATIENTS UNDERGOING ROBOTIC-ASSISTED LAPAROSCOPIC RADICAL PROSTATECTOMY?

J. Yates, M. Gross, D. Golombos, I. Sawczuk, R. Munver—United States

**Background:** Variations in prostatic and bladder neck anatomy can pose challenges during robotic-assisted laparoscopic radical prostatectomy (RALP). We examined the utility of preoperative cystoscopy in patients undergoing RALP and evaluated whether the information acquired facilitated preoperative or intraoperative decision making.

**Methods:** The records of 200 consecutive patients who underwent office flexible cystoscopy prior to RALP were retrospectively reviewed. Documentation included digital color images accompanied with written and dictated reports. Abnormal cystoscopic findings were correlated with intraoperative findings.

**Results:** Of 200 patients, 34 (17%) had cystoscopic findings that assisted with, or altered treatment planning. Twenty-three patients (11.5%) had either intravesical lateral lobes or median lobes that distorted the trigone or ureteral orifices. Additionally, there were 2 (1.0%) urethral strictures/meatal stenosis, 1 (0.5%) ureterocele, 1 (0.5%) urachal cyst, 2 (1.0%) patients with bladder calculi, and 5 (2.5%) patients with bladder tumors. Patients with bladder calculi (mean diameter 1.8 cm) underwent cystolitholapaxy prior to RALP. Patients with bladder tumors underwent transurethral resection prior to RALP and pathology revealed: pTa (n = 4), pT1 (n = 1), with 3 low grade and 2 high grade tumors.

**Conclusion:** The majority of patients that are candidates for surgical removal of the prostate will likely have a normal preoperative cystoscopic examination. Information regarding prostate or bladder anatomy, such as a large intravesical median lobe or ureterocele can facilitate bladder neck dissection and preclude ureteral orifice injury at time of RALP. The 6% incidence of other bladder/urethral pathology, most significantly bladder tumors, suggests that preoperative cystoscopy may be useful in patients undergoing RALP.

### MP1-18 A LONG-TERM RETROSPECTIVE REVIEW OF PROSTATE CANCER TREATMENT EFFECTS ON LOWER URINARY TRACT SYMPTOMS

J. Durbin, S. Stroup, B. Auge, J. L'esperance—USA

**Background:** Quality of life issues are become increasingly important to men diagnosed and treated for prostate cancer. We sought to evaluate the effect of prostate cancer treatment on baseline lower urinary tract symptoms (LUTS) in men.

**Methods:** A retrospective analysis of the Center for Prostate Disease Research database identified 413 patients from from January 1997 to December 2006 who underwent RP or XRT for localized prostate cancer and had completed pre- and post-treatment IPSS questionnaires. Groups were then divided based on IPSS scores into mild (0–8), moderate (9–20), and severe (>20). Chi-square, Wilcoxon rank sum, and signed-rank tests were used as appropriate.

**Results:** Of 413 eligible patients, 410 men underwent treatment for localized prostate cancer, 268 (65%) RP and 142 (35%) XRT. Median age at diagnosis and treatment was 63.6 and 63.9 years, respectively. Men that underwent neo-adjuvant hormonal treatment reported less moderate/severe LUTS ( $p < 0.04$ ) and men that reported treatment for BPH had significant higher moderate/severe LUTS ( $p > 0.0004$ ). On univariate analysis, XRT cohort reported significantly higher post-treatment IPSS at 12, 18, 24, 36, and 60 months than men undergoing RP ( $p < 0.01$ ). Men with mild symptoms get worse in the short term with XRT and RP, but recover. At all time periods, surgery patients with moderate to severe LUTS do better than XRT patients from a urinary standpoint ( $p < 0.05$ ).

**Conclusion:** In this study, men with RP reported better post-treatment urinary symptoms than XRT patients when they presented with moderate to severe LUTS prior to treatment. There was a significant improvement in LUTS for men with moderate to severe symptoms undergoing RP vs. EBRT as measured by IPSS at 60 months. Urinary symptoms should play an important role in pre-treatment patient counseling. Managing these expectations may better select patients for particular treatments and help to improve quality of life.

### MP1-19 A PROSPECTIVE COMPARATIVE STUDY FOR SURGICAL OUTCOMES OF HYBRID RADICAL PROSTATECTOMY AND MINI-LAP RETRO PUBIC PROSTATECTOMY

T. Saika, T. Tsushima, Y. Kobayashi, R. Arata, Y. Nasu, H. Kumon

**Background:** We compared surgical outcomes of radical prostatectomy using our new concept Hybrid Radical Prostatectomy (HRP, hybridized laparoscopic and open retro pubic radical prostatectomy) technique vs. an open minimally invasive retro pubic (mini-lap RRP) technique in prospective non-randomized study.

**Methods:** From May 2006 to April 2009, a cohort of 89 consecutive patients undergoing HRP and a cohort of 90 patients undergoing mini-lap RRP were analyzed and compared, in non randomized prospective fashion. The two groups were comparable in terms of mean pre-operative PSA. The peri-operative data included operative time, quantity of intra-operative blood loss, complications, hospitalization length, and duration of catheterization. The following pathological parameters were considered: pathological stage, and positive surgical margin rate.

**Results:** Operating times of HRP was shorter than that of mini-lap RRP ( $p = 0.002$ ). The median operative time was 215 for HRP and 239 for RRP. The blood loss was comparative with both procedures. The median estimated blood loss was 586 g for HRP and 578 g for mini-lap RRP. There was no intraoperative trouble except one ileal injury by a trocar introduction in the HRP group. The median durations of catheterization were 6 days in both groups. All patients had regained continence at 6 months post surgery. The overall positive margin rate was 17.9% vs. 16.7% for HRP and mini-lap RRP, respectively. In patients with pT2 or less, the margin-positive rate in the HRP group (9.7%) was better than that in the mini-lap RRP group (15.4%). Margin positive rate in apex lesion in HRP patients was fewer than that in mini-lap RRP patients ( $p = 0.031$ ).

**Conclusion:** These results indicate that hybrid radical prostatectomy is safe and has the potential to decrease the positive margin ratio.

**MP1-20 DELAYED INFECTION OF A PELVIC LYMPHOCELE FOLLOWING ROBOTIC RADICAL PROSTATECTOMY AND PELVIC LYMPHADENECTOMY: TWO CASES**

M. Tremp, T. Sulser, H. Seifert—Switzerland

**Background:** Pelvic lymphocele is an infrequent complication of pelvic surgery, usually presenting shortly after surgery.

**Methods:** We report two cases with a delayed infected pelvic lymphocele presenting after transperitoneal pelvic lymphadenectomy and robotic radical prostatectomy for adenocarcinoma of the prostate.

**Results:** The first patient developed an infected lymphocele 20 months after the operation with fever and progressive right lower abdominal pain. After percutaneous drainage of the fluid collection and administration of amoxicillin/clavulan acid, the patient immediately defervesced, the drain was removed uneventfully after 12 days. The second patient developed an infected lymphocele 8 months after the pelvic lymphadenectomy and robotic radical

prostatectomy. He developed progressive left lower abdominal pain and edema of his left leg. After robotic assisted laparoscopic resection of the lymphocele, the symptoms resolved and the patient was discharged home in good health.

**Conclusion:** These cases illustrate that late infection of pelvic lymphoceles may occur following radical prostatectomy and pelvic lymphadenectomy. The practicing urologist should be aware of this possibility and look for an infected lymphocele in postoperative pelvic lymphadenectomy patients presenting with fever and leukocytosis of uncertain etiology, regardless of the time elapsed since surgery. To date, there is a paucity of data in the literature on robotic-assisted laparoscopic resection of a lymphocele after radical prostatectomy. The minimally invasive technique is recommended as a reasonable alternative to lymphocele percutaneous drainage. It is effective, results in minimal patient morbidity and allows for a rapid recovery.

## MP2: ESWL

**MP2-01 ESWL IN THE HORSESHOE-SHAPED KIDNEY**

A. Palmieri, A. Maletta, F. Mangiapia, C. Imbimbo, N. Longo, V. Mirone

**Background:** Shockwave lithotripsy (SWL) is accepted as first-line therapy for urinary tracts stones at all levels. The aim of this study was to evaluate SWL therapy in patients with renal stone of up to 1 cm in size and horse-shoe kidney.

**Methods:** Twentyfive patients with horse-shoe kidneys and nephrolithiasis (8 females, 17 men, age from 17 to 63 years) participated in the trial. ESWL were carried by the Storz Modulith SLX-MX lithotripter. All the patients were evaluated by a series of pre-operative assessments which included a urine culture, intravenous urography or TC, x-ray of the abdomen and urinary ultrasound scan.

**Results:** Rate of stones free was 45.4% and the rate of clinically insignificant residual fragments was 17.2%. The mean number of re-treatments 2.86. The re-treatment rate was 74%. The time-lapse for re-treatment was 20–30 days. No sign of stone disintegration was observed in 2 patients. They underwent open surgery. Polyurethane Double Pigtail stents (Cook) were placed in 11 patients.

**Conclusion:** ESWL can be considered as a first line treatment for patients with calculi and this sort of anomalous kidney.

**MP2-02 THE DORNIER COMPACT DELTA II UIMS: VERSATILITY AND PERFORMANCE COMBINED**

G. Tailly

**Background:** From July 01, 2007 till March 31, 2009 we operated a Dornier Compact Delta II lithotripter in the management of stones at all levels of the urinary tract. The treatment results were retrospectively evaluated.

**Methods:** The Dornier Compact Delta II is equipped with an electromagnetic SW-source (EMSE 140), a dual imaging system allowing on-line use of both fluoroscopy and ultrasound and a data

management system. The patient table is suitable for endourological procedures. A total of 138 patients were treated with ESWL for both renal and ureteral stones. Average stone size was 50.3 mm<sup>2</sup> (range 15–240 mm<sup>2</sup>), mean number of SW 2257 at a mean energy level of 3.7 (range 3–6).

**Results:** Retreatment rate was 8.7%, auxiliary procedure rate pre-ESWL 5.1%, post-ESWL 9.4% and total 14.5%. Stone free rate at 1 month was 81.9%. Extended Effectiveness Quotient (EQB) was 66 for all stones and 77 for ureteral stones in situ. No major complications were observed.

**Conclusion:** With a very good EQB of 66 for stones at all levels and 77 for ureteral stones in situ the results are well within the range of modern electromagnetic lithotripters. The dual imaging system combined with the possibility to position the therapy head both overtable and undertable offer an operator friendly versatility in targeting and positioning making the Compact Delta II an excellent multifunctional workstation.

**MP2-03 ESWL FOR AN ANNULAR CALCULUS AT THE SITE OF A PYELOPLASTY: A CASE REPORT**

A. Ashish Patil—India

**Background:** To present a case of an annular calculus formed at a pyeloplasty site and the use of ESWL for the treatment.

**Methods:** A 33-year-old female patient, presented with right renal colic. History revealed a past history of pyeloplasty. Routine investigations included a KUB, intravenous urography which revealed a circular right renal calculus at the pelviureteric junction with no significant obstruction and suggestive of a well draining PUJ. Ultrasonography also confirmed the site of the calculus as the pelviureteric junction. The patient was treated with extracorporeal shock wave lithotripsy. This resulted in total clearance of the calculi. The patient is now under regular follow up. On detailed history taking the pyeloplasty was performed in a rural setup which has few facilities. Other details were not available. The annular

calcification appeared to be on the sutures of the pelviureteric junction anastomosis!

**Results:** Calculus formed over the pyeloplasty site was amenable to ESWL.

**Conclusion:** Calculi forming over sutures like a pyeloplasty in this case are soft and easily amenable to extracorporeal lithotripsy.

#### **MP2-04 COMPLICATIONS FOLLOWING USE OF THE DORNIER COMPACT DELTA ELECTROMAGNETIC LITHOTRIPTOR**

J. Mobley III, A. Stewart, M. Brewer, F. Klein, W. White—USA

**Background:** To present surgical complications following the treatment of urinary calculi using a third generation electromagnetic lithotripter.

**Methods:** A prospective, longitudinal study was conducted to determine the incidence and nature of intraoperative and postoperative adverse events following treatment on a Dornier Compact Delta Lithotripter. Demographic and salient perioperative data were obtained using an IRB-approved database. Complications were stratified and reported according to the Clavien Classification System.

**Results:** Between January 1999 and June 2008, 12,552 patients underwent 17,946 ESWL treatments for renal and ureteral calculi. A total of 15,443 (86.1%) cases completed satisfactory after-care and were included for analysis. Clavien Grade 1 surgical complications included 46 hematomas (0.30%) and 77 fevers (0.50%). Clavien Grade 2 complications included 76 urinary tract infections (0.49%), 4 blood transfusions (0.03%), and 1 rib fracture (0.006%). Clavien Grade 3 complications included 431 patients (2.8%) who required intervention for management of obstructing stone fragments. Clavien Grade 4 complications occurred in 3 patients (0.019%). Two patients had significant renal hemorrhage requiring angioembolization and 1 patient (0.006%) required a splenectomy for splenic rupture. One patient died (Clavien Grade 5) secondary to splenic and renal rupture, coagulopathy, and sepsis. Of interest, all patients with Grade 4 and 5 complications had 1–1.5 cm ureteropelvic junction calculi and had previously unidentified connective tissue disorders.

**Conclusion:** Based on our large, single-center experience, complications following ESWL using a third generation lithotripter are relatively uncommon. Severe adverse events are extremely rare. Further analysis is required to determine potential risk factors for adverse events.

#### **MP2-05 THE IMPACT OF SHOCK WAVE RATE ON SHOCK WAVE LITHOTRIPSY (SWL) EFFICIENCY**

A. Jamshaid, S. Biyabani, M. Ather—Pakistan

**Background:** In order to improve the efficiency of lithotripsy various modifications have been recommended. One of these is to investigate the impact of rate on stone free rate. We determined the impact of shock wave lithotripsy (SWL) rate on SWL efficiency in patients with renal and proximal ureteral stone

**Methods:** A total of 92 patients were included in this study. Patients were divided into 2 groups on the basis of shock wave delivery rate (60 versus 90/min). In the study group data was collected prospectively, whereas patients in group 2 were historical controls from a prospectively maintained data base. Inclusion criteria were patients with single renal or proximal ureteric stone <20 mm. Patient's characteristics, stone and SWL features were

reviewed. The primary outcome was the stone free status, Efficiency quotient (EQ) and ESWL suite occupancy time.

**Results:** Of the 92 patients with complete followup 46 patients were treated at 60 shock waves per min and 46 at 90 shock waves per min. There was no statistically significant difference between 2 groups with regards to age, sex, body mass index, stent status and stone diameter. The success rate was evaluated at 1 and 3 months, it was (69.5% versus 80% at 1 month, 78.2% versus 80% at 3 months p value 0.229). EQ was 48% and 50% in group 1 and 2. The Mean ESWL suite occupancy time was 77.41 + 17.25 vs 62.23 + 14.41 min (p = 0.000).

**Conclusion:** Slowing shock wave rate does not impact stone free status and EQ but significantly effects the mean ESWL suite occupancy time.

#### **MP2-06 15 YEARS OF EXPERIENCE WITH SHOCK WAVE LITHOTRIPSY (SWL) IN PATIENTS WITH HORSESHOE KIDNEY (HSK)**

A. Ray, D. Ghiculete, R. Honey, K. Pace

**Background:** Horseshoe kidney (HSK) is the most common renal fusion anomaly, with a prevalence of approximately 1 in 400 and an incidence of urolithiasis between 20–60%. The role of shock wave lithotripsy (SWL) in patients with HSK remains poorly studied.

**Methods:** Data from all patients treated since January 1994 with a known HSK was reviewed (64 patients, 103 calculi). Analysis was restricted to all patients with a minimum follow-up of 2-weeks after SWL. Success was defined as patients who were stone-free or had asymptomatic, clinically insignificant residual fragments  $\leq 4$  mm after a single SWL treatment.

**Results:** Data from 46 patients with horseshoe kidney was analyzed (70 calculi). Mean stone size was  $88.8 \pm 75.0$  mm<sup>2</sup>, mean body mass index (BMI) was  $26.7 \pm 5.6$ , and 47.1% of stones were in the lower calyx. The overall single-treatment success rate at 2-weeks was 47.1% and the stone-free rate was 29.6%. Success rate at 3-months was 29.6%. On multivariate analysis, stone burden (p < 0.001), lower calyceal location (p = 0.04) and BMI (p = 0.007) were found to be prognostic for SWL success. In total, 35 calculi (50%) underwent an additional treatment at our centre (SWL 34 and PCNL 1, respectively).

**Conclusion:** Patients with HSK have lower single-treatment success and stone-free rates following SWL than patients with normal kidneys. This likely has to do with factors such as greater skin to stone distance (particularly for lower and medial calyces) and restricted urinary drainage. SWL may be offered to patients with a horseshoe kidney once limitations in stone clearance have been considered.

#### **MP2-07 LONG-TERM EFFECTS OF EXTRACORPOREAL SHOCK WAVE LITHOTRIPSY IN PEDIATRIC POPULATION**

K. Villányi, L. Farkas, C. Pusztai, J. Székely

**Background:** In spite of numerous studies the effect of SWL of the immature kidney has not yet been evaluated. Our goal was to detect and determine the long-term effects of ESWL in children.

**Methods:** We retrospectively reviewed the treatment and follow-up records of 115 children treated with ESWL between 1993 and 2008. The median follow-up time was 9.27 years (1–15). Changes in blood parameters (electrolyte and creatinine assay, complete blood count, liver function, C-reactive protein, estimated creatinine clearance), urine parameters (protein, microalbumin, sediment,

culture) and blood pressure were analyzed. Maximum length and width, parenchyma structure of the treated and untreated kidneys were checked by ultrasonography. Predisposing disorders, stone composition and recurrence rate were analyzed.

**Results:** After 3 months the stone free rate was 89.5%, the EQ was 80.4%. The overall renal function and serum parameters remained unaltered. 45/106 children (42.4%) had one or more risk factors for stone formation, 22/115 children (19%) had recurrent stones. No evidence of new onset hypertension was observed, except one patient, who was treated for distal ureteric stone. Proteinuria was detected in 1 case, chronic pyelonephritis developed in 1 patient. No significant differences were found in the sizes of the treated and untreated kidneys.

**Conclusion:** No data about the long-term deleterious effect of ESWL but the judicious use of the method is recommended.

### **MP2-08 A PROSPECTIVE RANDOMIZED STUDY COMPARING 60 VERSE 120 SHOCK WAVES PER MINUTES FOR INDUCED TRAUMA INJURY IN EXTRACORPORAL SHOCK WAVE LITHOTRIPSY**

A. Lo, D. Gohel, N. Lee, C. Ng

**Background:** Slower shock wave delivery rate may be advantageous to stone fragmentation in shock wave lithotripsy (SWL). The in vivo effect of different shock wave (SW) delivery rates on renal damage was not known. Therefore, we would like to investigate the degree of renal trauma of SWL at different SW delivery rates.

**Methods:** Adult patients with solitary renal stones of size 5–20 mm were randomized with SWL treatment of Snolith Vision (Technomed, France) at either 60 SWs/min or 120 SWs/min. Spot urine samples were collected a day before SWL (baseline), immediately (post-treatment), 2 days, 7 days and 4 weeks after SWL. Renal trauma was determined by measurement of urinary Interleukin-18 (IL-18), neutrophil gelatinase-associated lipocalin (NGAL) and N-acetyl- $\beta$ -D-glucosaminidase (NAG). The values were normalized to urine creatinine.

**Results:** 70 patients were recruited, with 35 patients randomized to receive SWL at 60 SWs/min and 120 SWs/min respectively. All three markers were increased significantly at immediate post-treatment when compared to baseline levels ( $p < 0.05$ ). There were significantly higher IL-18 level at immediate after SWL for treatment at 60 SWs/min ( $p < 0.01$ ), when compared to 120 SWs/min. Though, the mean levels of NGAL and NAG at immediate after SWL were both higher in 60 SWs/min than that in 120 SWs/min, the difference did not reach the significant level. All the markers were back to pretreatment level at 4 weeks after treatment.

**Conclusion:** 60 SWs/min delivery rate may induce more renal damage than that caused by 120 SWs/min.

### **MP2-09 IMPACT OF BMI ON EXTRACORPOREAL SHOCK WAVE TREATMENT FOR KIDNEY STONES—RESULTS FOR 3RD GENERATION LITHOTRIPTERS**

G. Hatiboglu, V. Popeneciu, M. Kurosch, S. Pahernik, A. Hafferkamp, M. Hohenfellner—Germany

**Background:** Body mass index [BMI] has been reported to be an independent predictor for stone free status after extracorporeal shockwave lithotripsy [SWL] performed with 1st or 2nd generation lithotripters. The effect of different parameters including BMI on therapy outcome in patients suffering from upper urinary tract stones treated with a 3rd generation lithotripter was investigated.

**Methods:** 172 patients suffering from kidney stones with a mean size of 9.2 mm (range: 3.0–32.0) were included into the study. 91 patients (52.9%) were treated with urethral stent in situ. SWL therapy was performed with a 3rd generation, electromagnetic lithotripter (Siemens Lithoskop). Stone free status was reached, when no more treatable stones were seen (no stone or stone  $< 3$  mm). BMI, stone size and localization, age, gender, treatment parameters and urethral stent in situ were evaluated for their prognostic relevance on therapy success.

**Results:** Mean BMI of all patients was 27.8 (range: 19.0–58.6). Patients were categorized into 2 groups: A) patients that were stone free after 1 treatment; B) patients with residual stones. BMI was  $27.4 \pm 4.6$  and  $28.4 \pm 6.1$  for A and B, respectively. Univariate and multivariate analysis for freedom of stones showed that only stone size and treatment with urethral stent were independent prognostic parameters ( $p < 0.01$ ,  $p = 0.01$  respectively). BMI had no significant influence on therapy outcome ( $p = 0.508$ ).

**Conclusion:** Using 3rd generation lithotripters, BMI is not an independent predictor of stone free rate in the SWL therapy of kidney stones. This effect might be attributed to a greater penetration depth of shockwave energy. Stone size and treatment with urethral stent are the only parameters with prognostic significance.

### **MP2-10 CLINICAL EVALUATION OF A NOVEL ELECTROHYDRAULIC LITHOTRIPTOR**

A. Krambeck, S. Handa, J. Mcateer, T. Soergel, A. Evan, J. Lingeman—United States

**Background:** Shock wave lithotripters have evolved from the electrohydraulic HM3 waterbath to small focus high pressure dry-head electromagnetic models. The goal of the current study is to evaluate the clinical efficacy of a novel wide-focus, low pressure, dry-head, electrohydraulic lithotripter, the Lithogold (Tissue Regeneration Technology, Woodstock, GA).

**Methods:** From November 2008 to April 2009, we prospectively evaluated 146 patients treated with the Lithogold for urinary calculi. Of this group, 98 patients had solitary renal or ureteral stones and were selected for analysis. All patients were treated under general anesthesia and all images were reviewed by an independent radiologist. Patients were imaged pre-operatively, 2 and 4 weeks post-operatively.

**Results:** Of the 48 patients with completed post-operative follow-up, mean stone size was 8.2 mm (3–18) and location included: ureteral 16 (33.4%), ureteropelvic junction/renal pelvis 10 (20.8%), mid/upper calyx 10 (20.8%), lower pole 12 (25%). Mean shocks delivered was 3000 (2000–4000) and energy setting 10.77 (9–11). On first post-operative imaging, 16 (33.4%) were stone-free, 5 (10.4%) fragments  $< 2$  mm, 26 (54.2%) stones  $> 2$  mm, 1 (2.1%) indeterminate. 12 patients had a second post-operative image, of which 2 additional patients were stone-free, resulting in a total of 18 (37.5%). Ancillary procedures were required in 10 (20.8%) patients: 1 SWL, 1 stent, and 8 ureteroscopy. Calcium oxalate was the most common composition (52.1%). Success rates (stone-free or  $< 5$  mm non-ureteral fragments) by location were found: ureter 9 (56.3%), ureteropelvic junction/renal pelvis 6 (60%), mid/upper calyx 6 (60%), lower pole 8 (67%).

**Conclusion:** The Lithogold novel approach to lithotripsy is effective in fragmenting urinary calculi, regardless of stone location. Further follow-up is needed to assess success based on stone location.



### MP2-11 SERIAL EXTRACORPOREAL SHOCKWAVE LITHOTRIPSY (ESWL): THE EFFICACY, SAFETY AND PATIENT SATISFACTION WITH TREATMENT IN A BUSY TERTIARY REFERRAL STONE CENTRE

K. Moraitis, T. El-husseiny, Z. Maan, A. Papatsoris, J. Masood, N. Buchholz

**Background:** We evaluate the efficacy, safety and patient satisfaction with serial inpatient ESWL (at least three sessions over a 5-day period) in patients with a complex stone burden and in others who find the outpatient procedure painful or require to stopping anticoagulation.

**Methods:** Thirty six patients (mean age 51 years) have had serial inpatient ESWL (Lithostar Multiline, Siemens) sessions. 10 patients with low pain tolerance received an intravenous pain protocol, 9 stopped anticoagulant therapy prior to ESWL, 14 had emergency ESWL and 3 patients were treated for residual stones after percutaneous renal surgery. The number of impulses, maximum energy delivered to the stone and shockwave's frequency was according to Siemens ESWL guidelines. Stone free status was defined as the absence of stones or residual fragments <2 mm.

**Results:** 36 patients had a total of 93 calculi treated with serial inpatient ESWL. The mean stone burden per patient was 121 mm<sup>2</sup>. The overall mean number of ESWL sessions per patient was 3.34. The stone-free rate for patients with a kidney stone burden less and greater than 70 mm<sup>2</sup> was 87% and 67% respectively. For a ureteric stone burden less and greater than 50 mm<sup>2</sup>, the stone free rate was 93% and 85% respectively. Four patients needed an auxiliary procedure. 2 patients had transient minor complications.

**Conclusion:** Our experience with serial ESWL shows it to represent a safe and effective treatment for patients with large stone burdens, those with low pain thresholds and in those who have to stop anticoagulation. Patients found treatment safe, convenient and acceptable.

### MP2-12 LONG TERM OUTCOME OF PERINEPHRIC HEMATOMAS COMPLICATING SHOCKWAVE LITHOTRIPSY (SWL)

A. Cooper, A. Chachashvilli, I. Sabler, E. Lang, Y. Siegel

**Background:** Post SWL perinephric/subcapsular (PSPH) hematomas are considered to be one of the serious but infrequent complications of SWL for kidney stones. New generation lithotripters are thought to increase the risk, due to smaller focal region with higher pressure levels. We report long term outcome of PSPH.

**Methods:** During 01.2004–06.2008 we treated 1818 patients with SWL for kidney and ureteral stones. All treatments were provided with the Siemens modularis lithostar, under sedation. We recorded prospectively all patients with PSPH. All patients received up to 2000 shockwaves, at a frequency of 90 Hz and at an energy level from 2.7 to 4 (Siemens scale). We recorded prospectively all patients with severe perinephric hematomas: patients symptoms, hemodynamics, blood transfusions, ureteral stenting. Patients were followed at the ambulatory stone clinic with periodic CT scan or US of the kidneys.

**Results:** 17 severe PSPH were recorded during the study period. Patient characteristics are depicted in table 1: Table 1: Patients Characteristics

No. of patients	Age (mean)	Years	Gender	Male	Female	Side	Rt	Lt	Mean Stone Size (mm)	Stone Location	Renal Pelvis	Lower pole	Ureter
17	60	13	4	8	9	12.1	10.1	5	9	2	During hospitalization	6	Patients required insertion of ureteral stent due to

symptomatic obstruction resulting in azothemia. 3 patients received blood transfusion due to hemodynamic instability. Mean Follow up period was 10.2 month (3–27 Month). All but 3 PSPH were totally absorbed on radiological evaluation by US or CT scan at that time period. The 3 PSPH remaining (Follow up of 3–8 month) demonstrated considerable diminution of more than 50% in hematoma size.

**Conclusion:** Perinephric hematoma rate in our series was 0.9%. Although serious in manifestation the long-term sequel, requiring only conservative measures, is with excellent resolution. This data confirms previous published data.

### MP2-13 PRIMARY TREATMENT ESWL IS BEST VALUE

E. Havranek, M. Hanna, A. Shamusddin, J. Ramsay

**Background:** First-line ESWL, including emergency treatment of acute renal colic, can provide a clinically effective service preferred by patients. We analyse its financial viability.

**Methods:** We performed a cost analysis of ESWL and ureteroscopy in our unit. We compared this to the income for each procedure derived from the hospital tariff and confirmed by analysis of 165 consecutive patients by our finance department.

**Results:** ESWL: Costs: Annual lithotripter running costs (inc. lease and staff) £196,000. Cost per case £362. Income: Hospital Tariff adjusted for our case mix £612 per treatment episode Ureteroscopy: Costs: (incl. inpatient stay, theatre time, disposable costs, laser, ureteroscope, removal costs of JJ stent) incl. JJ stent £2159, without JJ stent £1859. Income: Hospital tariff for ureteroscopic laser fragmentation of calculus of ureter £1538, but if include insertion of JJ and followed by flexible cystoscopy and removal of stent £2696. This analysis shows that ESWL is significantly cheaper than ureteroscopy (£362 vs £1859). ESWL is profitable whereas ureteroscopy is loss making when no JJ stent is inserted (£250 vs -£321).

**Conclusion:** ESWL is significantly cheaper than ureteroscopy and pays for itself. Fast access to ESWL should be made more readily available. This can reduce the need for anaesthesia, reduce inpatient admissions, reduce complications, and ease pressures on theatres and save cost.

### MP2-14 RE-ADMISSION AND INTERVENTION RATES POST ESWL

O. Gilleard, D. Allen, M. Hanna, A. Shamsuddin, J. Ramsay

**Background:** Extracorporeal shock wave lithotripsy (ESWL) offers a non-invasive treatment for calculi in the kidney and ureter. Stone clearance is similar to that of ureteroscopy with lower quoted complication rates. Our study aimed to quantify patient hospital re-attendance, need for admission as well as emergency intervention.

**Methods:** Using the hospital database we identified 90 consecutive patients who underwent ESWL between January 2006 and January 2007. It was performed by a single clinician on a fixed third generation lithotripter (Storz Modulith SLX-F2). All patients were contacted by telephone and their medical notes and imaging reviewed.

**Results:** Twenty two of the 90 patients (24%) re-presented as an emergency within 28 days of treatment, most commonly with flank pain. Ten had treatment to renal pelvic stones, 7 lower pole and 5 ureteric. Twelve (13%) required admission, with 3 (3%) needing operative intervention (2 JJ stents and 1 ureteroscopy).

**Conclusion:** Even when discharged with regular analgesia and post treatment information sheets, nearly one quarter of patients

sought emergency medical advice. Those undergoing ESWL need to be adequately counselled to expect renal colic as fragments are passed. When asked directly though, 98% of patients would recommend ESWL as a treatment for renal calculi.

### MP2-15 LOW FREQUENCY SHOCK WAVE ESWL IMPROVES RENAL PELVIS STONE DISINTEGRATION IN THE PIG MODEL

A. Neisius, J. Wöllner, R. Gillitzer, C. Hampel, J. Thüroff

**Background:** Previous clinical studies have shown improved disintegration rates for low frequency shock wave ESWL. However, fragmentation results and stone free rates did rely mainly on radiographic analysis. We studied disintegration rates for renal stones at 60 vs 120 shock waves/minute (shocks/min) using validated standardized stone phantoms in the pig.

**Methods:** Gypsum model stones measuring 13×6 mm were inserted in the renal pelvices of ten anesthetized pigs by open surgery. ESWL was performed with the Lithoskop electromagnetic lithotripter at a rate of 60 shocks/min vs. 120 shocks/min. 3000 shocks were applied to each kidney with comparable energy settings. The stone fragments were collected after nephrectomy, passed through calibrated test sieves and weighed. Fragment size categories were stratified according to the sieve hole size. Fragments <4.75 mm were defined as capable of spontaneous passage. Statistical analysis was performed by Mann-Whitney-test.

**Results:** Median fragment count for fragments >4.75 mm was 0.0 (0–1) for 60 shocks/min and 1.0 (0–3) for 120 shocks/min ( $p = 0.015$ ); for fragments between 2.8–4.75 mm counts were 7.5 (4–12) for 60 shocks/min and 5.0 (3–13) for 120 shocks/min ( $p > 0.05$ ); for fragments between 1.0–2.8 mm counts were 55.5 (43–105) for 60 shocks/min and 33.0 (8–81) for 120 shocks/min ( $p = 0.002$ ). 1.25% of stone mass treated with 60 shocks/min and 30.43% of stone mass treated with 120 shocks/min were >4.75 mm. Complete disintegration yielding fragments capable of spontaneous passage occurred in 8/10 renal units at 60 shocks/min and in 3/10 renal units at 120 shocks/min. One parenchymal hematoma measuring 15×10 mm developed in the 60 shocks/min group and another of 20×10 mm developed in the 120 shocks/min group.

**Conclusion:** ESWL fragmentation yields significantly smaller fragments at 60 shocks/min than at 120 shocks/min. Theoretical stone passage rate could therefore be in the range of 80% for 60 shocks/min vs 30% for 120 shocks/min ESWL. Side effects were comparable in both groups.

### MP2-16 MANAGEMENT OF OBESE PATIENTS WITH RENAL STONES: PRELIMINARY RESULTS OF SWL IN A MODIFIED LATERAL POSITION

S. Gravas, A. Karatzas, V. Tzortzis, M. Melekos

**Background:** The aim of the study was to evaluate the efficacy and safety of SWL using a modified lateral position in obese patients with renal stones

**Methods:** Nineteen obese patients with renal stones were enrolled in our study (group A). The mean stone diameter was 1.3 cm (0.7–1.9 cm). The mean BMI was 34.6 kg/m<sup>2</sup> (range from 31 to 41 kg/m<sup>2</sup>). Patients were placed in lateral position, with the energy source facing their body posteriorly and the site where the stone was located in direct contact with the water cushion. Success rate (defined as the percentage of patients who were stone-free or with insignificant fragments after 3 months), mean number of SWL

sessions, mean duration of SWL session, and complications were recorded. The results were compared with those of 17 obese patients (Group B) with similar baseline characteristics treated in the standard supine position. All SWLs were performed using the Dornier lithotripter SII.

**Results:** Both success rate (68.4% vs 64.7% for groups A and B, respectively) and mean number of sessions (2.2 vs 2.6) did not differ significantly between the two groups ( $p > 0.05$ ). Interestingly, the time required to complete SWL was significantly shorter for group A patients (56 mins) compared to group B (73 mins). No severe complications (including hematoma, pyelonephritis) were recorded.

**Conclusion:** SWL in the modified lateral position for renal calculi in obese patients seems to be feasible and safe. In addition, it is faster than in the supine position since it overcomes technical difficulties. Further studies with larger number of patients are required to support our findings

### MP2-17 THE EVALUATION OF EFFECTIVENESS OF COMPUTED TOMOGRAPHY FOR SUCCESSFUL RATE OF SWL IN URINARY STONE DISEASE

L. Kyoungtaek, D. Kim, S. Park, Y. Kim, H. Park, T. Lee

**Background:** Shock Wave Lithotripsy is one of the most effective treatment modalities in urinary stone disease. but, it is difficult to predict whether the stone passes or not. Herein, we analyze the information from computed tomography to evaluate whether stone passes or not, so that it may be helpful on treatment plan.

**Methods:** We examined the medical charts of 108 urinary stone patients who had undergone SWL and CT scan, retrospectively. Successful group is those whose stone size decreased over 50% on CT scan or KUB in 3 months follow up. Failure group was those whose stone size decreased below 50%. Hounsfield units, size of stone, skin to stone distance (SSD), number of interface were measured and compared numerical value of each group by stone location.

**Results:** 40 patients had renal stone, 48 patients had upper ureter stone, remaining 20 patients had lower ureter stone. 75 patients (69.4%) were in successful group and 33 patients (30.6%) were in failure group. The mean number of times of SWL was  $1.7 \pm 1.1$  times in successful group and  $3.2 \pm 1.8$  times in failure group. Mean Hounsfield unit was  $860.2 \pm 336.3$ ,  $1061.7 \pm 345.5$ , respectively ( $p = 0.01$ ). Mean stone size was  $0.8 \pm 0.3$  cm,  $1.1 \pm 0.5$  cm, respectively ( $p < 0.01$ ). Table 1. shows mean Hounsfield unit of each group by stone location, stone size, SSD and number of interface. Table 1. Radiologic parameters for success and failure groups for each stone location Renal stone (23/17) †Upper ureter stone (35/13) Lower ureter stone (17/3) Total stone (75/33) Average HU: Success (Mean ± SD)  $1000.6 \pm 332.5860.6 \pm 317.7678.5 \pm 292.7860.2 \pm 336.3$  Failure (Mean ± SD)  $1100.8 \pm 329.41034.9 \pm 386.0955.7 \pm 336.41061.7 \pm 345.5$   $p$  value\* 0.350. 120.290.01 SSD(cm): Success (Mean ± SD)  $8.8 \pm 2.111.4 \pm 1.49.9 \pm 1.510.0 \pm 2.8$  Failure (Mean ± SD)  $8.7 \pm 3.011.5 \pm 1.710.0 \pm 2.410.3 \pm 2.0$   $p$  value 0.900.850.890.50 Stone size(cm): Success (Mean ± SD)  $1.0 \pm 0.40.7 \pm 0.20.7 \pm 0.30.8 \pm 0.3$  Failure (Mean ± SD)  $1.3 \pm 0.61.0 \pm 0.41.0 \pm 0.31.1 \pm 0.5$   $p$  value 0.05 < 0.010.33 < 0.01 The number of interface: Success (Mean ± SD)  $6.4 \pm 1.16.7 \pm 1.37.3 \pm 1.46.7 \pm 1.3$  Failure (Mean ± SD)  $6.6 \pm 0.66.4 \pm 1.08.0 \pm 1.06.6 \pm 0.9$   $p$  value 0.500.460.420.70\*: t-test, HU: Hounsfield unit, SD: Standard Deviation, SSD: skin to stone distance †: (the number of success/ the number of failure)

**Conclusion:** We have concluded that mean Hounsfield unit and stone size is relevant to the success rate of SWL. Therefore, with mean housefield unit and size of stone from CT, it is possible to determine prior to SWL whether SWL will be successful or not.

### MP2-18 SUBCAPSULAR HEMATOMA AS A COMPLICATION OF SWL: EXPERIENCE WITH THE STORZ SLX-F2 LITHOTRIPTER

R. Leistner, C. Mendez Probst, L. Nott, H. Razvi—Canada

**Background:** Subcapsular and perinephric hematomas are a potentially serious complication of extracorporeal shock wave lithotripsy (SWL). We determined the incidence of and evaluated the risk factors for the development of clinically apparent post SWL renal hematomas with the latest generation shock wave lithotripter.

**Methods:** From April 2006 to September 2008, 3351 SWL treatments were performed using the Storz Modulith SLX-F2. Data was collected prospectively for patient age, body mass index (BMI), gender, stone size, stone location, number of shock waves, energy level, shock frequency, medications and the existence of hypertension.

**Results:** Following SWL treatment, 12 patients developed a clinically apparent renal hematoma (0.3%). All affected patients were male, 8 (66%) had hypertension prior to SWL, in 6 (50%) the treated stone was in the lower calyx, 2 (17%) in upper calyx, 2 (17%) in the renal pelvis, 1 (8%) in mid calyx and 1 (8%) in the upper ureter. The mean energy level of 6.0 (5.0–8.0) in the hematoma patients was significantly higher ( $p = 0.0379$ ) compared to 5.4 (0.5–9.0) in the control cohort. Age, BMI, number of shock waves, shock frequency or stone size had no significant impact on the formation of renal hematomas ( $p > 0.05$ ). All patients with a hematoma were treated conservatively, with 1 patient receiving blood transfusion.

**Conclusion:** The incidence of a clinical apparent hematomas following SWL with the SLX-F2 was 0.3%. A mean energy level of 6, male gender (100%), use of ASA, NSAIDs and clopidogrel all had a statistically significant impact on the formation of renal hematomas.

### MP2-19 PREDICTIVE VALUE OF STONE DENSITY BY HOUNSFIELD UNIT (HU) ON UN ENHANCED COMPUTED TOMOGRAPHY IN SUCCESSFUL STONE FRAGMENTATION BY EXTRACORPOREAL SHOCK WAVE LITHOTRIPSY (ESWL)

M. Ather, A. Jamshaid

**Background:** To determine the predictive value of stone density by Hounsfield unit (HU) on un enhanced computed tomography (CT scan) in successful stone fragmentation by extracorporeal shock wave lithotripsy (ESWL).

**Methods:** We evaluated 30 patients who underwent extracorporeal shock wave lithotripsy for 10 to 20 mm renal stones. HU calculations were performed for each stone and post treatment radiographic assessment categorized patients into a stone-free or a residual stone group. Statistical analysis was performed using the Mann-Whitney U test to compare mean HU values in the stone free

and residual group. The chi-square test was used to see the difference between the stone free and residual group for stone location and complication of ESWL.

**Results:** The overall stone free rate in the study was 73.3%, while 26.7% patients had residual stone. There were no statistically significant differences between the two groups (stone free and residual group), with respect to age, gender, body mass index (BMI), serum creatinine, stone size and location and pre ESWL double J stenting. Mean HU for the stone-free and residual stone groups were significantly different ( $588.82 + 316.61$  versus  $1067 + 297.4$  HU,  $p = 0.002$ ). In stone free group 18 patients (81.8%) had no complication while in residual group only 1 (12.5%) had no complication while 5 patients (62.5%) had steinstrasse and needed ureterorenoscopy (for stone removal) and double J stenting as ancillary procedure. In residual group 2 patients (25%) had renal colic that needed inject able pain killer.

**Conclusion:** HU measurement of urinary calculi on pretreatment un enhanced computerized tomography is predictive of the stone-free rate. This information is beneficial for selecting the preferred treatment option for patients' with urinary calculi.

### MP2-20 MEASUREMENT OF STONE HOUNSFIELD UNIT (HU)—DOES IT MATTER DURING EXTRACORPOREAL SHOCKWAVE LITHOTRIPSY (ESWL)

R. Sabnis, K. Shah, A. Kurien, M. Desai

**Background:** This study evaluates effect of HU in predicting outcome of ESWL in a stone belt area of a tropical country.

**Methods:** This is a prospective study where 99 patients undergoing ESWL for solitary renal and upper ureteral stones from January 2007 to December 2008 were analyzed. All patients underwent non contrast CT scan prior to ESWL. The mean HU value of stones in our study was  $1213.3 + 314.5$ . Group A consisted of 42 patients with stones of HU less than 1200 and group B had 57 patients with stones of HU greater than 1200. Stone size, location, requirement of number of shockwaves, shock intensities, re-treatment rate, complication rate, auxiliary procedure rate and effectiveness quotient ratio were studied.

**Results:** The mean total number of shocks required to fragment the stones in groups A and B were  $1317.14 + 345.32$  and  $1646.49 + 610.76$  respectively ( $p = 0.001$ ) with a mean shock intensity of  $12.19 + 0.72$  kV and  $12.42 + 0.48$  kV respectively ( $p = 0.03$ ). Re-treatment was not required in patients of group A, while 14.03% patients in group B required re-treatment ( $p < 0.0001$ ). Clearance rates in group A was 88.1% while in group B was 82.5% ( $p = 0.35$ ). Auxiliary procedure rates were 9.5% and 10.5% in groups A and B ( $p = 0.22$ ). Effectiveness quotient (EQ) in group A was 80.44% and 66.21% in group B ( $p = 0.03$ ). Complication rates were similar with 2.4% and 3.5% in group A and B respectively ( $p = 0.37$ ).

**Conclusion:** Patients with stones less than 1200 HU have significantly better EQ. These stones are fragmented with significantly fewer and lower intensity shocks.

## MP3: UROLITHIASIS 1

### MP3-01 UROLITHIASIS IN THE ELDERLY

J. Mccarthy, R. Norman—Canada

**Background:** Urolithiasis is an increasing problem in patients  $\geq 80$  yrs. Our objective was to compare patients  $\geq 80$  yrs with urolithiasis to a younger cohort in terms of presentation, management and outcomes.

**Methods:** Patients presenting with urolithiasis between January 1, 2004 and December 31, 2008 were reviewed. Data were collected on clinical parameters including: age, medical co-morbidities, stone size and location, treatment, complications and follow up. Patients  $\geq 80$  yrs were compared with those  $< 80$  yrs.

**Results:** 26 patients  $\geq 80$  yrs were compared with 72 patients  $< 80$  yrs. Mean age was 83.5 and 45.5 respectively. The older group had more co-morbidities. Older patients were more likely to be referred from the ER than the primary care physician compared with the younger group ( $p = 0.03$ ). The presenting complaint was flank pain in 87.5% of young patients and 65% of older patients ( $p = 0.038$ ). The largest stone in the older group was 13.2 mm and 7.5 mm in the young group ( $p = 0.01$ ). The most common treatment modalities in the older group were ureteral stents (27%) and PCNL (24%). ESWL was the most common treatment in the young group (33%). There was no difference in intra-operative complications. 38% of the older group were managed as outpatients. More of the older group had post operative complications (26% vs 8%) but most were minor. Younger patients were stone free more often (60% vs 38%,  $p = 0.012$ ).

**Conclusion:** Urolithiasis in the elderly is often difficult to treat. These patients have more co-morbidities, and are less likely to present with classic symptoms of renal colic. This may result in a later presentation with larger and more complex stone disease. Our data shows that it is safe to operate on patients  $\geq 80$  years of age with stones, often as an outpatient. Pursuing stone free status in the elderly may not be as important as in younger patients.

### MP3-02 THE METABOLIC SYNDROME AND URIC ACID NEPHROLITHIASIS

Y. Seo, K. Shim, J. Huh, J. Park—Korea

**Background:** Insulin resistance is associated with excessively low urinary pH and it increases the concentration of the insoluble undissociated uric acid, causing formation of both uric acid and mixed stones. We investigated the relationship of uric acid stone and metabolic syndrome, defined by International Diabetes Federation (IDF).

**Methods:** We investigated 521 outpatients type II diabetes mellitus (DM), visited the endocrinology department. We evaluated waist circumference, body mass index (BMI) and the other factors related to MS. Urinary PH, serum and urinary uric acid and renal ultrasonography were performed. By IDF 2005 criteria, we divided the patients as two groups, metabolic syndrome group (MS group) and control. We compared two groups. Then compared urine PH and incidence of renal stone disease. Student t-test was used for statistical analysis.

**Results:** The mean age of the patients was 56.4 years. MS was diagnosed in 60.8% ( $n = 371$ ) of the 521 patients. Mean value of BMI in MS group and control were 24.1 and 21.6 ( $p > 0.05$ ).

16.1% ( $n = 83$ ) of patients in MS group and 7.5% ( $n = 39$ ) of patients in control had history of nephrolithiasis ( $p < 0.01$ ). 11.7% ( $n = 61$ ) of patients in MS group and 8.4% ( $n = 44$ ) of patients in control were newly diagnosed nephrolithiasis by ultrasonography ( $p > 0.05$ ). Mean urinary PH were 5.1 and 6.2 in MS group and control ( $p < 0.01$ ). Mean serum uric acid level were 8.8 mg/dL in MS group and 7.6 mg/dL in control ( $p > 0.05$ ). Mean 24 hr urinary uric acid level were 730 mg/day in MS group and 880 mg/day in control ( $p < 0.01$ ). Urinary ammonia excretion were  $48.0 \pm 2.4$  mEq/day and  $26 \pm 1.5$  mEq/day ( $p < 0.01$ ) in each group. Urinary citrate excretion were  $1.34 \pm 58$  g/day and  $0.56 \pm 32$  g/day ( $p < 0.01$ ) in each.

**Conclusion:** We conclude that one renal manifestation of metabolic syndrome may be low urinary pH, low urinary ammonium and citrate excretion. This defect can result in increased risk of uric acid stone formation.

### MP3-03 ANALYSIS OF 24-HOUR URINE PARAMETERS AS PREDICTOR FOR AGE OF ONSET OF CYSTINE STONE FORMATION

N. Miller, E. Lambert, H. Altamar, S. Herrell

**Background:** Cystinuria is an inherited disorder characterized by the impaired reabsorption of the dibasic amino acid, cystine, in the proximal tubule of the nephron. Patients with cystinuria are often plagued by recurrent nephrolithiasis secondary to the poor solubility of cystine in urine. Cystine stones most frequently occur in the first through third decades of life with a decreased incidence in old age. We sought to determine whether there were differences in 24-hour urine parameters between those patients that present with their first cystine stone early as opposed to patients that form cystine stones later in life (greater than 45 years of age).

**Methods:** This is a retrospective review of 18 patients with cystinuria and cystine stones who performed a 24-hour urine test (Litholink Corporation, Chicago, IL). The patients were divided into 2 groups based on age at first clinical stone event: Group 1, greater than 45 years of age ( $n = 10$ ), Group 2, age 18–30 years ( $n = 8$ ). All 24 hour urines were collected prior to any medical therapy for cystinuria. Statistical analysis was performed using non-parametric Kruskal Wallis test.

**Results:** There were no significant differences in 24-hour urine parameters between the 2 groups of patients. Urine was analyzed for pH ( $p = 0.21$ ), 24-hour urine cystine excretion (mg/d) ( $p = 0.37$ ), cystine supersaturation ( $p = 0.25$ ), and capacity ( $p = 0.13$ ), which is how much cystine can be dissolved in a volume of urine (mg/l).

**Conclusion:** We hypothesized that the cystinuric patients presenting at an older age would have more favorable 24-hour urine parameters such as greater urine volume and lower cystine excretion compared to those patients that present early. However, in this small retrospective study, no correlation was found between the age of onset of cystine stones and 24-hour urine parameters. Although, the study could be underpowered to detect a significant difference, it is also possible that cystinuric patients presenting at an older age may have an as yet unrecognized mechanism that confers a protective effect. This study highlights the importance of a complete metabolic workup and aggressive medical treatment of

all patients with cystinuria regardless of the age at which they present with their first stone event.

#### **MP3-04 OUT PATIENT URETEROSCOPY: EVALUATION OF COMPLICATION AND CAUSES OF HOSPITALIZATION 2 YEARS EXPERIENCE IN IMAM REZA HOSPITAL**

M. Darabi Mahboub, K. Tavakkoli Tabassi, A. Naderi—Iran

**Background:** Uteroscopy is a routine procedure for all urologists. Advances in technology have increased the success rate of ureteroscopy and widened its indication. The complication rate has also been reduced significantly. This study audited our outpatient ureteroscopy service to identify risk factors that can predict postoperative events.

**Methods:** The data of 301 patients who underwent outpatient ureteroscopy from July 2005 to June 2007 were analyzed. All these patients were in physical class 1 or 2 and had no previous history of any major anesthetic problem. Patients with any anesthetic problem were excluded from the study. After operation, the urologist and anesthesiologist assessed the patient again and if he had a problem admit him. All of the procedures were therapeutic ureteroscopy.

**Results:** 82% of the patients were male and 17% were female. The overall mean age was 36.88 years, mean stone diameter 10.59 mm and mean operating time 20.13 min. The calculi were more frequently localized in the distal ureter than in the proximal and middle one. (44.1% versus 28.7% and 22%). 91.7% of patients were fit for discharge within 5 hours and 8.3% of them were admitted. Cause of unplanned admissions were severe pain, long operating time, background disease, collection of pus after stone, anesthetic problem, sensitivity to anesthetic drug, no responsible adult for accompany home, had trauma and vertigo. Nobody was admitted after successful discharge. Severe pain in female was more than male (5.7% versus 1.27%). The mean age in patient who admitted was higher. No severe pain reported in patient who had stones in lower ureter.

**Conclusion:** TUL can be successfully performed in an outpatient setting with our equipment. In this study some of the predictive factors for unplanned admissions were identified.

#### **MP3-05 CHARACTERISTICS OF METABOLIC RISK FACTORS IN UROLITHIASIS PATIENTS WITH FAMILY HISTORY**

Y. Ha, Y. Kim, W. Jung, E. Kim, D. Kim, Y. Jeon

**Background:** Urolithiasis are more frequently developed in patients with family history (FHx). However, little is known about the frequency and risk factor for stone recurrence by FHx. The aim of this study is to examine the clinico-metabolic characteristics in urinary stone formers (SF) according to FHx.

**Methods:** A total of 1,068 SF who underwent the urine metabolites examination were reviewed. SF were divided into two groups based on FHx. Characteristics of clinical factors and urine metabolites were compared between two groups.

**Results:** There were no significant differences in clinical characteristics, such as gender, age, body mass index, history of stones and multiple stones, between two groups ( $p > 0.05$ , respectively). Compared to SF without FHx, serum calcium concentration was more elevated in SF with FHx. Also, urinary calcium excretion of calcium is higher in SF with FHx than SF without FHx. Other urinary metabolites showed no significant difference between two groups ( $p > 0.05$ , respectively).

**Conclusion:** Our study revealed that SF with FHx had increased urinary calcium excretion as well as elevated serum concentration of calcium. This finding suggests that the increased risk of stone formation with FHx is associated with calcium metabolites.

#### **MP3-06 THE RELATIONSHIP OF METABOLIC SYNDROME WITH UROLITHIASIS IN A SCREENED POPULATION**

T. Kang, J. Park, J. Park, J. Hong, H. Park—Korea

**Background:** To investigate the relationship of metabolic syndrome (MS) with urolithiasis in a screened population.

**Methods:** We reviewed the data of 34,948 Korean people who received general health examinations at single institute. The database for health examinations included demographic, anthropometric, serum-related and radiographic data. The presence of the MS was determined according to the NCEP-ATPIII and NCEP update criteria and the presence of urinary stone was evaluated by computerized tomography or ultrasonography. We analyzed the prevalence of urolithiasis and calculated the odds ratios of urolithiasis by traits of MS.

**Results:** Of the enrolled people, 4,029 (11.5%) patients were corresponded to MS criteria. The prevalence of urolithiasis in MS group and non-MS group were 3.5% and 2.3%, respectively, which was significantly different ( $p < 0.001$ ). In univariate and multivariate analyses for comparing the variables between urolithiasis and non-urolithiasis people, age ( $p < 0.001$ ), male sex ( $p = 0.003$ ), height ( $p = 0.015$ ), waist circumference ( $p = 0.007$ ), BMI ( $p = 0.041$ ), and diastolic BP ( $p < 0.001$ ) were shown significant differences. Among the categories of MS, the presence of hypertension (OR: 1.389, 95% CI: 1.191–1.621,  $p < 0.001$ ) is the only factor shown significant differences between urolithiasis and non-urolithiasis people.

**Conclusion:** The risk for urolithiasis is associated with metabolic syndrome. Among the anthropometric variables, age and hypertension is the most significant factor for predicting urolithiasis in a screened people.

#### **MP3-07 HETEROGENEITY IN THE REPORTING OF DISEASE CHARACTERISTICS AND TREATMENT OUTCOMES IN STUDIES EVALUATING TREATMENTS FOR NEPHROLITHIASIS**

E. Hyams, A. Bruhn, M. Lipkin, O. Shah—USA

**Background:** There is no standardization in the nephrolithiasis literature regarding the evaluation of preoperative stone burden or the reporting of treatment outcomes. We evaluated variability in the literature regarding pre- and postoperative evaluation of patients undergoing treatment for nephrolithiasis.

**Methods:** A systematic PUBMED search was performed for 2006–2008 using search terms “kidney stones,” “nephrolithiasis,” “ureterolithiasis,” “ureteroscopy (URS),” “shock wave lithotripsy (SWL),” “percutaneous nephrolithotomy (PNL).” Articles evaluating outcomes of treatment for nephrolithiasis were included.

**Results:** 154 articles were included in the analysis. Preoperative stone burden was evaluated using CT (42), ultrasound (42), plain radiography (92), multiple modalities (52), and no mention (45). Stone burden was reported as maximal diameter (105), surface area (32), volume (6), other (1), and no mention (10). Treatment modalities included URS (46), PNL (71), SWL (50), and multiple modalities (9). Postoperative imaging included CT (37), ultrasound (67), plain radiography (115), multiple modalities (70), other (11), and no mention (19). Radiographic outcomes included strict stone

free (114) and presence of residual fragments (64). There was wide variation in size of residual fragments reported (<2 through <7 mm). "Stone free" included the presence of residual fragments in 18 studies. Treatment "success" was defined variably to include residual fragments of various sizes. Reported clinical outcomes included stone-related events (46) and stone-related surgery (90). **Conclusion:** There is extensive variation in the reporting of pre-operative disease characteristics and postoperative outcomes in studies evaluating treatments for nephrolithiasis. Standardization of these criteria is necessary for more meaningful comparisons of treatment modalities for different disease subgroups.

### MP3-08 THE IN-VITRO CRYSTALLIZATION OF MELAMINE AND ITS EFFECT ON CALCIUM OXALATE CRYSTALLIZATION

C. Ng, N. Poon, A. Lo, M. Gohel

**Background:** An epidemic of melamine contamination of milk formula for infants in China in 2008 and has led to great concern about the effect of melamine and its analog, cyanuric acid, in stone formation. This study aims to understand the melamine crystallization and its role in calcium oxalate (CaOx) crystallization.

**Methods:** Continuous flow crystallizer system, Mixed Suspension and Mixed Product Removal (MSMPR) and particle sizing machine, COULTER Multisizer III were used in this study to assess the crystallization process of melamine and CaOx. First of all, different ratios of melamine and cyanuric were used to determine the optimal ratio (OR) for melamine cyanurate crystallization. Then the crystallization of CaOx was assessed at different levels of melamine, cyanuric acid and melamine cyanurate at different concentrations in a CaOx solution.

**Results:** Melamine and cyanuric acid could only form crystal when they were mixed together and the highest crystallization rate was observed at 1:1 ratio of them. Melamine, cyanuric acid and melamine cyanurate could all increase the nucleation rate and suspension density, with decrease in crystal growth rate of CaOx crystal. These observations suggested they can all promote CaOx crystallization process. The effects were highest for melamine cyanurate.

**Conclusion:** Melamine and cyanuric acid can only form crystal when they are presented together. Melamine cyanurate is a stronger promoter for CaOx crystallization than melamine and cyanurate alone.

### MP3-09 SERUM TESTOSTERONE MAY BE AN INDEPENDENT RISK FACTOR FOR CALCIUM OXALATE UROLITHOGENESIS

J. Watson, A. Shrewsbury, S. Taghchian, J. Pattaras, C. Rite-nour, K. Ogan—USA

**Background:** The incidence of urolithiasis is 2 to 3-fold higher in men than in women. Several animal studies have suggested an association between testosterone levels and the formation of kidney stones. Specifically, castration has been shown to decrease stone formation in rat models. To our knowledge, however, the association between testosterone and stone formation has not been investigated in humans. We therefore hypothesized that testosterone levels would be higher in stone formers compared to control male subjects.

**Methods:** In a prospective study, early morning total and free testosterone levels were collected from 49 male patients (stone formers and normal subjects). Clinical records of all enrolled

subjects were reviewed, and stone composition was determined in the stone formers. Student t-test analysis was utilized to examine the data sets.

**Results:** Of the 49 patients, 22 had no history of urolithiasis and 27 either had a stone at the time of enrollment or had a history of urolithiasis. Between the stone formers and controls, there were no significant differences in age (47.0 vs. 40.1,  $p=0.15$ ) or BMI (27.5 vs. 26.3,  $p=0.28$ ). Results of the mean total and free testosterone levels are shown in Table 1. Table 1 Stone Formers Controls  $p$  value Average Total Testosterone (ng/dL) 423.48 363.82 0.19 Average Free Testosterone (pg/mL) 60.51 58.61 0.75

**Conclusion:** In this small pilot study, subjects with urolithiasis were found to have a trend towards higher total serum testosterone levels. This finding is consistent with several animal models that have demonstrated that testosterone is a risk factor for stone formation. Further prospective studies, with increased sample size, is needed to further elucidate the association between serum testosterone levels and urolithiasis in humans. A clinically significant association may have relevant therapeutic implications.

### MP3-10 DOES POTASSIUM CITRATE THERAPY INCREASE THE PHOSPHATE CONTENT OF STONES?

M. Ferrandino, C. Donnelly, J. Raman, K. Sakhaee, M. Pearle, G. Preminger

**Background:** Potassium citrate (Kcit) therapy has been implicated as a potential cause of the observed increase in prevalence of calcium phosphate (CaPhos) stones. We sought to determine whether the phosphate content of stones increases after initiation of Kcit.

**Methods:** We identified 35 patients for whom stone analyses were available before and after initiation of Kcit, 14 of whom had corresponding 24-hour urine analyses. We compared the CaPhos content of stones and urine pH before and during treatment.

**Results:** Our study group comprised 19 women and 16 men with a mean age of 41.9 years. Mean daily Kcit dosage was 35 mEq with 63% of patients taking 40 mEq. Mean duration of treatment until second stone analysis was 2.1 years. Median pre- and post-treatment CaPhos content was 10% and 50% (range 0 to 100%), respectively. Mean change in CaPhos content was +22.7%. Although the median change was 0 (−30 to 100%), the change in distribution was statistically significant ( $p=0.003$ ). Overall, 31% of patients demonstrated no change, 20% showed a decrease and 49% showed an increase in CaPhos content. No difference in mean Kcit dosage (34 mEq vs 36 mEq,  $p=0.61$ ) or change in urine pH (0.35 vs 0.32,  $p=0.95$ ) was found between patients with no change or a decrease and those with an increase in CaPhos content.

**Conclusion:** Kcit therapy results in a small but significant increase in CaPhos content of stones. Further study may identify urine parameters that could be used to titrate dosage to effect while avoiding conversion to CaPhos stones.

### MP3-11 THE COMBINED EFFECT OF OMEGA-3 FATTY ACIDS EICOSAPENTAENOIC ACID AND DOCOSAHEXAENOIC ACID IN THE MANAGEMENT OF IDIOPATHIC HYPERCALCAEMIA. DEPARTMENT OF UROLOGIC SURGERY, UNIVERSITY OF MINNESOTA, MINNEAPOLIS, MINNESOTA, USA \*DIETARY SERVICES UMMC

O. Ortiz-alvarado, C. Kriedberg, R. Miyaoka, A. Moeding\*, M. Stessman\*, M. Monga

**Background:** Previous studies have shown a relationship between prostaglandin metabolism and urinary calcium excretion suggest-

ing a role for omega-3 fatty acids in the treatment of hypercalciuric urolithiasis. We investigate the use of fish oil omega-3 fatty acids in the dietary management of idiopathic hypercalciuric stone formers.

**Methods:** Retrospective cohort study of the patients treated at our stone clinics from July 2007 to February 2009. Patient's urinary risk factors for stone disease were evaluated with pre and post intervention 24 hours urine collections. All patients received empiric dietary recommendations to intake of fluids, sodium, protein, and citric juices. All subjects with hypercalciuria ( $>250$  mg/day for males or  $>200$  mg/day for females) on at least two 24 hours urine collections were counseled to supplement their diet with fish oil (1200 mg/dy).

**Results:** Twenty-nine patients were treated for hypercalciuria with dietary modifications and fish oil omega-3 fatty acids. 15 men and 14 women with a mean age of 43.6 years and average follow up of 7.41 months composed our study group. Fifteen patients (52%) showed a significant decrease in urine calcium ( $326.13 \pm 100.87$  to  $247.47 \pm 84.53$ ,  $p < 0.0001$ ) including 7 patients with a decrease in urine calcium from high to normal levels ( $286.71 \pm 49.95$  to  $204.57 \pm 35.31$ ,  $p = 0.003$ ).

**Conclusion:** Omega-3 fatty acids combined with empiric dietary counseling results in a measurable decrease in urinary calcium excretion in hypercalciuric stone formers.

### MP3-12 PYRIDOXINE SUPPLEMENTATION FOR THE MEDICAL MANAGEMENT OF IDIOPATHIC HYPEROXALURIA DEPARTMENT OF UROLOGIC SURGERY, UNIVERSITY OF MINNESOTA, MINNEAPOLIS, MINNESOTA, USA \*DIETARY SERVICES, UMMC FAIRVIEW

O. Ortiz-alvarado, C. Kriedberg, R. Miyaoka, A. Moeding\*, M. Stessman\*, M. Monga

**Background:** To examine the effect of dietary manipulation and pyridoxine medical management for idiopathic hyperoxaluria.

**Methods:** Retrospective cohort study of the patients treated in our stone clinics from July 2007 to February 2009. Patient's urinary risk factors for stone disease were evaluated with pre and post intervention 24 hours urine collections. All patients received dietary recommendations of hydration to keep urine volume above 2L/day and low sodium, low animal protein, calcium with meals and low oxalate diet combined with oral pyridoxine. Initial dosage ranged from 50–100 mg depending on the baseline oxalate level, and was titrated to a maximum of 200 mg based on follow-up urinary evaluations. All subjects with at least two 24 hours urine collections and idiopathic hyperoxaluria managed with diet and oral pyridoxine were included in the study.

**Results:** There were 314 patients with complete metabolic and urinary profile evaluation in the time period under study. Fifty-four subjects (30 males and 24 females) met the study inclusion criteria. Average follow up was 14.62 months and mean age was 50.3 years. There was a significant change in urinary parameters in 39 patients (72%) with a decrease in urinary oxalate excretion ( $60.64 \pm 30.25$  to  $40.38 \pm 14.09$ ,  $p < 0.0001$ ) and 20 patients had a decrease from a high urine oxalate levels to a normal range urine oxalate ( $55.30 \pm 22.04$  to  $33.45 \pm 3.93$ ,  $p = 0.0004$ ). No peripheral neuropathy was reported.

**Conclusion:** Dietary management combined with medical treatment using pyridoxine is an effective therapy to decrease hyperoxaluria in stone formers.

### MP3-13 DESIGNING 'PATIENT CENTRED CARE' FOR CYSTINURICS: THE EXPERIENCE OF A NEW SPECIALIST MULTI-DISCIPLINARY CLINIC

K. Thomas, A. Doherty, M. Kabia, J. Glass, T. Doulton, G. Rottenberg—UK

**Background:** Cystinuria presents huge challenges for both patients and clinicians. Historically regarded as a 'difficult', 'non-compliant' patient group, their management has often been fragmented and sub-optimal.

**Methods:** A monthly multi-disciplinary clinic has been established by a consultant endo-urologist with specialist nurse, experienced dietician, consultant nephrologist, consultant uro-radiologist and urology research fellow.

**Results:** 30 patients have accepted invitations to the clinic. Ultrasound was performed on all patients during the clinic, with XR and CT KUB as required. Uptake of dietician consultations is 100% with very positive feedback from patients. All patients attending have produced urine pH 'diaries' however only 60% have consistently acidic urine. Urinary 'pH stix' monitoring at home enables targeted alkalinisation therapy and alongside dietary manipulation allows patients to take ownership of the disease and an active role in management. Serial ultrasound has identified five patients requiring intervention. All patients were offered procedure dates within two weeks at convenient times. Patient engagement is good: the 'did not attend' rate is low (1 patient in 7 months) with no emergency admissions.

**Conclusion:** Patient feedback has been positive: Empowering patients to manage their disease through better education and self directed therapy has improved patient care, access to a regular clinic run by a familiar multi-disciplinary team, 'walk-in' access if required and the provision of peer support have been especially welcomed. Specialist patient-centred care has minimised the disruption and distress of this chronic disease and timely surgical intervention avoided emergency admissions.

### MP3-14 GLOBAL CHANGES IN KIDNEY STONE PREVALENCE AND INCIDENCE

D. Assimos, V. Romero

**Background:** The prevalence and incidence of nephrolithiasis is thought to be increasing across the world. We performed a study to better assess this hypothesis.

**Methods:** A literature search using PubMed and Ovid was performed to identify peer reviewed journal articles containing information on the incidence and prevalence of kidney stones. Key words used included kidney stone prevalence, incidence and epidemiology. Data were collected from the identified literature, sorted by demographic factors, and time period.

**Results:** A total of 75 articles were identified containing kidney stone related incidence or prevalence data from 20 countries. Thirty-four provided suitable information for review. Data regarding overall prevalence or incidence for more than one time period was found for 7 countries (incidence data for 4 and prevalence data for 5 countries). These included 5 European countries (Italy, Germany, Scotland, Spain, Sweden), Japan and the United States. In the US, overall stone prevalence has doubled since the 1964–1972 period, and appears to have stabilized since the early 1980's. Other countries with documented increases in prevalence include Germany, Spain, and Italy. Only Scotland had a slight prevalence decrease from 3.83% in 1977 to 3.5% in 1987. In the US, overall incidence

increased from 1971 to 1978. In the year 2000, an incidence of 1116 per 100,000 was reported for 18–64 year old employees covered by 2 large insurance carriers. This incidence is significantly higher than those from the aforementioned periods. In Japan the incidence of nephrolithiasis has doubled over a 40 year time period, both in males and females. These increases were most prominent in the last 10–20 years, with rates among males increasing sharply since the 1990's, and rates among females increasing more gradually since the 1980's. The incidence in Germany and Sweden increased while that in Spain decreased. The changes in prevalence and incidence seen across gender, race and age.

**Conclusion:** The body of evidence suggests that the incidence and prevalence of kidney stones is increasing globally. These increases are seen across gender, race and age.

**MP3-15 CURRENT DIETARY IMPACT ON THE MANAGEMENT FOR UROLITHIASIS DEPARTMENT OF UROLOGIC SURGERY, UNIVERSITY OF MINNESOTA, MINNEAPOLIS, MINNESOTA, USA \*DIETARY SERVICES, UMMC FAIRVIEW**  
O. Ortiz-alvarado, M. Stessman\*, R. Miyaoka, C. Kriedberg, A. Moeding\*, M. Monga

**Background:** To investigate the current impact of dietary management for the treatment of urolithiasis.

**Methods:** Retrospective cohort study of the patients treated in our stone clinics from July 2007 to February 2009. Patient's urinary risk factors for stone disease were evaluated with pre and post intervention 24 hours urine collections. All patients received dietary recommendations from a registered dietician.

**Results:** One hundred-thirty seven subjects were identified with high urinary sodium (85.4%), uric acid (33.6%), calcium (35%), oxalate (32.8%), and/or low urinary volume (98.5%) or citrate (51.8%). Average follow-up for all groups was 9.82 months. Subjects showed significant changes in: urine volume (71.1%,  $1.68 \pm 0.68$  to  $2.59 \pm 0.80$  liters/day,  $p < 0.0001$ ), urine sodium (58.1%,  $229.68 \pm 72.51$  to  $146.65 \pm 56.57$  mg/day,  $p < 0.0001$ ), urine calcium (43.8%,  $312.10 \pm 98.69$  to  $216.81 \pm 80.90$  mg/day,  $p < 0.0001$ ), urinary uric acid (47.8%,  $0.817 \pm 0.214$  to  $0.615 \pm 0.126$  grams/day,  $p < 0.0001$ ), urinary citrate (47.9%,  $561.21 \pm 325.25$  to  $772.56 \pm 410.19$ ,  $p < 0.0001$ ) and urine oxalate (51.1%,  $46.39 \pm 10.42$  to  $32.57 \pm 9.22$  mg/day,  $p < 0.0001$ ).

**Conclusion:** Urolithiasis is a multi-factorial disease requiring a multidisciplinary approach. Our results support the use of dietary counseling by a registered dietician in the management of urolithiasis.

**MP3-16 ACCURACY OF IDENTIFICATION OF PATIENTS WITH URINARY CALCULI THROUGH ADMINISTRATIVE RECORDS: A DATA VALIDATION STUDY**

M. Semins, J. Berkowitz, B. Matlaga—USA

**Background:** Administrative databases are increasingly utilized for epidemiologic investigations. The validity of any work using such data depends on the accuracy of the codes that are used as indicators of the disease being studied. Presently, it is not known how accurately upper tract stone disease is captured in billing records. Therefore, we performed a study to assess the validity of ICD-9 codes for upper tract stone disease in an administrative database.

**Methods:** We retrieved the billing records of all inpatients and outpatients submitted between November 2007 and October 2008 with an ICD-9 code of 592, 592.0, 592.1, and 592.9 as one of the

first three diagnosis codes. A random number generator was used to select 100 encounters for further review. We considered a patient to have a true diagnosis of an upper tract stone if the medical records specifically referenced a kidney stone event or included current or past treatment for a kidney stone. Descriptive and comparative analyses were performed.

**Results:** A total of 8,245 encounters were identified; 101 were randomly selected for review. Three patients could not be identified within the electronic medical record and were excluded. The sensitivity of the selected ICD-9 codes for indicating a diagnosis of an upper tract stone was 100%. The positive predictive value of these codes was 95.9%. However, when examining the accuracy of those coded with 592.1 (ureteral stone), the sensitivity was 20%, although the positive predictive value was 100%.

**Conclusion:** ICD-9 coding for urinary calculi is likely to be sufficiently sensitive to be useful in studies using administrative data to evaluate the burden of stone disease. However, ICD-9 coding is not a reliable means to differentiate between renal and ureteral calculi.

**MP3-17 METABOLIC CHARACTERISTICS OF PATIENTS WHO USE TUBE FEEDING AS THEIR PRIMARY DIETARY SOURCE**

E. Gnessin, S. Handa, J. Lingeman—United States

**Background:** Many common tube feeding formulas are based primarily on high oxalate-containing soy products. Recommended nutrient intakes for neurologically impaired immobile patients have not been established. Our goal was to determine if excessive concentrations of various ingredients in tube feeding formulas may contribute to stone formation.

**Methods:** We retrospectively reviewed the records of all patients in our outpatient clinic that had renal stones. We identified 6 patients who use tube feeding as their primary dietary source. All patients had their stones analyzed and had 24-hour urine metabolic studies.

**Results:** Two patients were excluded due to history of infection stones. Disabilities in the remaining four arose from a variety of conditions: two patients secondary to spinal cord traumatic injury, one due to cerebral palsy, and one due to spina bifida. Average age was 25.7 (range 21–34). Primary hyperoxaluria was ruled out in all patients. 3 of 4 patients were markedly hyperoxaluric. Median urine oxalate level was 111.5 mg/d (range 15–229). All patients were hypercalciuric. The median Ca<sup>24</sup>/Cr<sup>24</sup> ratio was 285.5 (range 220–467). Median 24-hour urine pH was 7.60 (range 7.21–7.81). All patients had predominantly calcium phosphate stones. Calculated intake in these patients include: median calcium intake 1100 mg/d (range 1080–1165) and median vitamin D intake 436.5 IU/d (109% RDA). Oxalate nutrition values are not indicated in formula labels and could not be obtained.

**Conclusion:** These patients represent a complex paradox in that they form predominantly calcium phosphate stones, yet have dangerously high levels of oxalate excretion. We hypothesize that this unusual metabolic constellation of abnormalities is in some way related to the tube feeding formulas. Further study is warranted to better understand this clinical syndrome. Oxalate values should be listed in common feeding formulas to allow for better assessment of these patients.

**MP3-18 ASSESSMENT OF IMPROVEMENT IN S CREATININE FOLLOWING DEFINITIVE TREATMENT OF UROLITHIASIS IN PATIENTS WITH RENAL INSUFFICIENCY**

T. Haresh, J. Vivek, K. Sushi, A. Jitendra, S. Moteria, S. Sudhir



**Background:** In our stone belt region with poor socioeconomic status, late presentation of urolithiasis with impaired renal function is very common. We present our data of patients with urolithiasis and renal insufficiency and evaluate the efficacy of surgical intervention in reducing the S creatinine.

**Methods:** We studied 210 patients with S creatinine more than 2 mg/dl (1.5 to 34 mg/dl). All were evaluated as per our protocol for stone and renal failure and treated according to patient's condition and dialysed as per need. Emergency Urinary diversion was done as per need (DJ stenting or PCN). Once nadir S Creatinine is achieved definitive surgical procedure was carried out. Age, gender, reoperation, stone burden, imaging study with renal status, infection, therapeutic procedures, complication clearance rate, progress of renal functional status assessed.

**Results:** 88 patients were put on dialysis. PCN was done in 62 patients. URS in 72 cases. PCNL in 58 cases. RIRS in 6 cases. Complete clearance was achieved/partial clearance in 24 cases. Reduction in dialysis postoperative was seen in 70% of cases. At 6 months, 118 cases showed improvement. 66 cases showed stabilisation and 26 cases showed worsening. All these patients had S Creatinine more than 9, cortical atrophy, recurrence infection and late presentation with large stone bulk.

**Conclusion:** Patients with renal insufficiency with stone diseases requires aggressive multimodal team approach to deobstruct urinary tract, control infection, achieve stone clearance and treatment of co-morbidity.

### MP3-19 URINARY CANDIDIASIS WITH SEPSIS AFTER ENDOUROLOGIC SURGERY: PATHOGENESIS AND TREATMENT OF A RARE AND SEVERE COMPLICATION

I. Kartalas Goumas, G. Cordima, B. Mangiarotti, F. Longo, E. Inneo, E. Montanari

**Background:** Although uncommon, invasive urinary candidiasis after endourologic surgery has been described. We report 2 cases of Candida urosepsis following endourologic procedures.

**Methods:** A 35 years old female with a left ureteral stone, a left renal staghorn stone and bacterial pyelonephritis underwent initial ureterolitholapaxy and secondary percutaneous nephrolithotomy (PNL) with complete stone clearance. A 32 years old female with multiple right renal stones and a severely encrusted forgotten ureteral stent underwent an initial cystolitholapaxy and secondary PNL with complete removal of the stent and the stones. Both patients developed a postoperative sepsis with lack of response to antibiotics. CT scan revealed a severe pyelonephritis. Nephrostomy tube and blood cultures were positive to *C. glabrata* and *C. albicans* respectively in each case. Colonized nephrostomy tubes and stents were removed and intravenous fluconazole was initiated with regression of the fungal infection.

**Results:** Yeasts may colonize a mucosa and inanimate surfaces (stents, stones). PCNL determines a disruption of the colonized mucosa allowing invasion of the renal parenchyma and candidemia. Patients usually present an acute septic syndrome indistinguishable from bacteremia. Cultures and upper tract imaging with CT scan are essential for the diagnosis. Successful therapy requires removal of a colonized stent or nephrostomy and high dose anti-fungal treatment.

**Conclusion:** Postoperative fungal sepsis complicating endourologic surgery is possible even in young patients, with PCNL being at most risk. It can be a life-threatening condition which requires a high index of suspicion and appropriate cultures and treatment, as the clinical features are indistinguishable from those of bacterial urosepsis.

### MP3-20 FACTORS RESPONSIBLE FOR UROSEPSIS FOLLOWING PERCUTANEOUS NEPHROLITHOTOMY: ROLE OF NITROFURANTOIN PROPHYLAXIS

S. Bag, S. Kumar, A. Mandal, N. Taneja, U. Mete, S. Singh—India

**Background:** To analyze various risk factors for post PNL sepsis, and the role of Nitrofurantoin prophylaxis.

**Methods:** In this prospective analytical and case control study 205 adult patients undergoing PNL were grouped into 4 cohorts; group A (n = 50): stone size  $\leq 2.5$  cm, no hydronephrosis, sterile urine; group B (n = 54): diabetics, creatinine  $> 2$  mg%, UTI, stone size  $\geq 2.5$  cm, patients on nephrostomy and bilateral simultaneous PNL; group C (n = 53): hydronephrosis and/or stones  $\geq 2.5$  cm; group D (n = 48): similar to group C, received nitrofurantoin prophylaxis 100 mg bid for 7 days. Preoperative urine, intra-operative renal pelvic urine & stone cultures were obtained. Fever  $> 38.0$ C and leucocyte counts  $> 12000$  was considered SIRS. Endotoxaemia was assessed using limulus amoebocyte lysate gelation technique. Multivariate analysis and chi-square test were applied for statistical analysis.

**Results:** Overall 23% had positive renal pelvic urine & stone culture, 25% endotoxaemia (8.6%, 65.2%, 41.9%, 17.5%, in group A, B, C & D) and 34% SIRS (8%, 70%, 49% & 19% respectively). Significant risk factors for urosepsis were females patients, CRF, anemia, hydronephrosis, large stones, and prolonged surgery. Endotoxaemia and SIRS were significantly lower in group D as compared to group C (17.5% vs 41.9%  $p = 0.001$ ; 19% vs 49%,  $p = 0.01$ ; respectively).

**Conclusion:** Patients with CRF, anemia, hydronephrosis, large stone burden, prolonged surgery and female gender are at higher risk for post PNL urosepsis and warrants a suitable preventive measures. Prophylaxis with nitrofurantoin has a significant preventive role in those with larger stone and hydronephrosis.

## MP4: PCNL 1

### MP4-01 SPINAL ANESTHESIA FOR PERCUTANEOUS NEPHROLITHOTOMY VIA INTERCOSTAL PUNCTURE

S. Mousavi-bahar, B. Borzouei, S. Amirhassani—Iran

**Background:** Recently, there has been a considerable increase in the number of procedures carried out under regional anesthesia. However, percutaneous nephrolithotomy (PCNL) procedures are performed under general anesthesia especially in patients require intercostal puncture for stone removal. The purpose of this study is to assess the safety and efficacy of spinal anesthesia in patients undergoing PCNL via intercostal puncture.

**Methods:** 64 patients (55 male and 9 female) with renal stone were included in study from February 2002 to April 2009. All patients received spinal anesthetics and underwent PCNL via intercostal puncture.

**Results:** The mean patients' age was  $43.5 \pm 14.1$  years (mode 33, min 21, and max 78). 17 patients had staghorn stone, 8 patients upper ureteral stone and the others had pelvic or calyceal stones. Stone burden was staghorn in 17 patients (26.6%), larger than 2 cm in 41 patients (64.1%) and smaller than 2 cm in 6 patients (9.4%). Two tracts were needed in 13 cases and three tracts in 1 case. The mean operation time was  $54.9 \pm 20.4$  minutes (mode 60, min 20, and max 120). Overall stone-free rate was 92.2%. Patients with residual stones were 7.8% and managed by reoperation. There was no need to change from spinal to general anesthesia in any patient. The incidence of complications was 10.9%. Bleeding during operation occurred in 4 cases and perforation of pelvicalyceal system in 1 case with no serious sequelae. 1 patient had nausea and vomiting and 1 patient had pain, No transfusion requirement was reported.

**Conclusion:** PCNL under spinal anesthesia is a feasible, safe, and well-tolerated for management of patients undergoing PCNL via intercostal puncture. The method is particularly valuable for patients who are not able to receive general anesthesia.

### MP4-02 CHANGES IN RENAL PRESSURE WITH URETERAL CATHETERS AND ANTIRETROPULSION DEVICES DURING PERCUTANEOUS NEPHROLITHOTOMY

B. Chew, B. Poh, L. Jonat, D. Lange—Canada

**Background:** Infusion of irrigant fluid during percutaneous nephrolithotomy (PCNL) is associated with the potential of stone fragments migrating down the ureter, spread of infection, and fluid overload. The objective was to measure renal pressure changes with placement of ureteral catheters and antiretropulsion devices at the ureteropelvic junction (UPJ).

**Methods:** Freshly excised porcine kidneys ( $N = 3$ ) were accessed with a 30 Fr Amplatz sheath and guidewire antiretropulsion devices (Stone Cone (Boston Scientific) or NTrap (Cook Urological)) or catheter-based (5 Fr Pollock catheter (Cook Urological) or Coaxial Accordion (PercSys)) devices were retrogradely placed at the UPJ. Renal pressure was measured 30 and 60 seconds following irrigant infusion under gravity (60 cm above table height) through a simulated nephroscope. Measurements without any device were also recorded as controls.

**Results:** The renal pressures with the Coaxial Accordion ( $7.33 \pm 0.56$  cm H<sub>2</sub>O) and 5F ureteral catheter ( $6.67 \pm 0.21$  cm H<sub>2</sub>O) were

significantly higher than controls ( $4.33 \pm 0.42$  cm H<sub>2</sub>O,  $P < 0.05$ ). The StoneCone renal pressure ( $5.83 \pm 0.17$  cm H<sub>2</sub>O) was not significantly higher than any device. The NTrap resulted in a pressure of  $5.50 \pm 0.50$  cm H<sub>2</sub>O which was significantly less than the Coaxial Accordion ( $P < 0.05$ ).

**Conclusion:** The guidewire-based StoneCone and NTrap devices provided low pressures similar to controls. The catheter-based devices (5F catheter and Coaxial Accordion) produced significantly higher pressures than control; they do offer the advantage of being able to retrogradely inject contrast during the procedure. Despite the Coaxial Accordion having a larger cross-sectional area, its presence at the UPJ resulted in similar pressures to that produced by the 5F ureteral catheter.

### MP4-03 TWO CONTEMPORARY SERIES OF PERCUTANEOUS TRACT DILATION FOR PNL

C. Mamoulakis, J. Rioja, F. Wezel, M. Michel, P. Alken, J. de la Rosette—Netherlands

**Background:** Tract dilation is an essential step of percutaneous nephrolithotomy (PNL). The aim of this retrospective study is to compare two different dilation techniques, namely metallic telescoping dilation (MTD); (Karl Storz GmbH Tuttlingen, Germany) vs. balloon dilation (BD); Nephromax<sup>TM</sup> (Boston Scientific, Natick, MA, US) in terms of safety, based on the experience of two European centers.

**Methods:** The population consisted of patients submitted to PNL using MTD (University Hospital Mannheim; group A:  $n = 100$  renal units) or BD (Academic Medical Centre, Amsterdam; group B:  $n = 100$  renal units). All operations were performed between August 2003–February 2009 (group A) and November 2006–February 2009 (group B). Variables of main interest included: 1) blood transfusion, 2) perforation, 3) urinary tract infection, 4) organ injury. The modified Clavien grading system was used, to compare overall perioperative morbidity. Statistical analysis was based on logistic and linear regression models using SPSS 15.0.

**Results:** Groups differed significantly in some patient- (gender, ASA score, stone burden, presence of nephrostomy preoperatively) and procedure-related characteristics (type of guidance, supracostal access, number of tracts, size of tract, type of lithotripter). Differences were detected regarding urinary tract infections (group A: 12/100 vs. group B: 28/100;  $p = 0.008$ ) and Clavien grading ( $p = 0.024$ ), which was mainly attributed to a greater number of cases graded as 2 in group B (18/100 vs. 6/100;  $p = 0.017$ ). Median operation/hospitalization duration was shorter in group B (20 minutes/2 days, respectively;  $p < 0.001$ ). The dilation technique was not a significant predictor of any of these differences.

**Conclusion:** MTD and BD present a similar safety profile.

### MP4-04 A RANDOMIZED TRIAL OF INTERCOSTAL NERVE BLOCK FOLLOWING PCNL (PERCUTANEOUS NEPHROLITHOTOMY)

R. Honey, D. Ghiculete, A. Ray, K. Pace—Canada

**Background:** The aim of this study was to find an efficient and inexpensive method to reduce postoperative pain and length of

hospital stay after PCNL. We sought to examine the effects of intercostal blockade after PCNL versus no intercostals blockade.

**Methods:** 63 patients scheduled to undergo PCNL were enrolled and randomized to either have intercostal blockade with 20 mL of 0.5% bupivacaine with epinephrine (group 1) or 20 mL placebo saline solution (group 2). All patients received intravenous narcotic patient-controlled analgesia (PCA) post-operatively. Data was collected on analgesic usage, length of stay, and health-related quality of life (HRQL) as assessed by the Post-operative Recovery Scale (PRS, a modification of the SF-36 that includes visual analog assessments of pain). Data were analyzed with Chi-square, ANOVA, and repeated measures ANCOVA where appropriate according to our pre-planned blinded interim analysis.

**Results:** 63 patients, 38 were male (60.3%), with a mean age of 47.95 (SD = 1.46) and mean BMI of 28.14 (SD = 0.62) were enrolled between January, 2004 and April, 2009. There were no differences between the groups at baseline. There was a significant difference in narcotic usage between the two groups (9.3 mg in group 1 vs. 12.1 mg in group 2,  $p = 0.03$ ). The HRQL score were significantly higher in group 1 ( $p = 0.034$ ). There was a trend to less post-operative pain in group 1 ( $p = 0.058$ ).

**Conclusion:** Intercostal nerve blocks are an easy, safe and inexpensive method to optimize immediate analgesia following PCNL, and may facilitate its use as an outpatient procedure.

#### MP4-05 ALMOST TOTALLY TUBELESS PERCUTANEOUS NEPHROLITHOTOMY: REPLACING THE DOUBLE-J STENT BY AN EXTERNALIZED URETERAL CATHETER

P. Recabal, F. Marchant, E. Ossandon, O. Storme, J. Roman, R. Ledezma—Chile

**Background:** Percutaneous Nephrolithotomy (PNL) has become widely accepted as standard treatment for most of large renal stones in urological practice. Several studies question the need for nephrostomy placement at the end of the procedure in patients with no evidence of active bleeding, arguing it accounts for more postoperative pain and prolonged hospital stay. The objective of this study is to evaluate feasibility and safety of the "Almost totally tubeless" technique that comprises placement of an externalized ureteral catheter at the end of the procedure, which is removed at 24 hours postoperative.

**Methods:** A Case-control study was designed. 21 patients who underwent almost totally tubeless PNL were compared to 21 matched patients in whom conventional technique was used. Outcomes evaluated were hospital stay length; postoperative hematocrit drop, postoperative haematoma assessed by renal ultrasound and postoperative pain assessed by the visual analogue scale. Means were compared using t-test. A  $p$ -value  $< 0.05$  was considered significant.

**Results:** Both groups were comparable in terms of age ( $p = 0.94$ ), BMI ( $p = 0.42$ ) and stone size ( $4.37 \text{ cm}^2$  v/s  $4.31 \text{ cm}^2$   $p = 0.93$ ). No difference in postoperative hematocrit drop was noticed ( $p = 0.93$ ). Almost totally tubeless patients had a significantly shorter hospital stay (46 v/s 74 hours;  $p = 0.01$ ), and less postoperative pain on day 1 (6.2 v/s 4.0;  $p < 0.01$ ) and day 2 (4.8 v/s 1.4;  $p < 0.001$ ). There were no haematomas on the ultrasound performed prior to catheter removal. Ureteral catheter was removed at 24 hours in all patients. No urinary leaks were noticed.

**Conclusion:** Almost totally tubeless technique is feasible and safe in selected patients, and it's likely to reduce postoperative pain and hospital stay. Prospective studies are warranted to prove its real

benefits. Nephrostomy placement should be restricted to patients who are likely to benefit from it.

#### MP4-06 REMOVING THE STENT VIA A FLANK TETHER—OUR EXPERIENCE DURING TUBELESS PCNL

D. Bodiwala, A. Colquhoun, P. Butterworth—UK

**Background:** The placement of a nephrostomy tube at the end of a percutaneous nephrolithotomy (PCNL) is standard practice. This has been challenged, with the aim of reducing patient morbidity and hospital stay. To this effect, tubeless PCNL has been advocated. We present our local experience of this procedure over a three year period and a novel method for removing the stent post operatively.

**Methods:** We retrospectively analysed all patients who had a PCNL (with and without a nephrostomy) between 2006 and 2009 with respect to post operative analgesia requirements, hospital stay, stone size/location and complications. The outcomes of patients in these two groups were compared. The indwelling JJ stent was removed via a flank tether, obviating the need for removal via flexible cystoscope.

**Results:** Tubeless PCNL was performed in 31 patients and in 29 a nephrostomy placed. Post operative analgesia requirements with respect to morphine, tramadol and codeine were less in the tubeless group (13.5 mg vs 15.6 mg, 185 mg vs 340 mg and 133 mg vs 256 mg respectively). Hospital stay was also reduced in the tubeless group by a mean of 2 days. There were 2 major complications in the tubeless group compared to 4 in the nephrostomy group.

**Conclusion:** We have shown that tubeless PCNL is beneficial for the patient in terms of reduced post operative analgesia needs and hospital stay without increasing complication rates.

#### MP4-07 COMPARISON OF THE INCIDENCE AND COMPOSITION OF UPPER TRACT AND LOWER TRACT CALCULI IN PATIENTS WHO HAVE UNDERGONE URINARY DIVERSION

N. Miller, E. Lambert, H. Altamar, S. Herrell

**Background:** Patients who have undergone urinary diversion, including ileal conduit, continent diversions and augmentation cystoplasty can develop calculi. However, the prevalence and stone composition is underreported in the urologic literature. We evaluated the incidence of procedures performed for stones in patients who have undergone urinary diversions, as well as the differences in stone composition.

**Methods:** Between January 1998 and March 2009, we performed a retrospective analysis of all patients who have undergone urinary diversion, including continent cutaneous diversions, neobladders, augmentation cystoplasty and ileal conduits, and had subsequent procedures for stone disease. Stone composition for each patient was recorded and then compared between the groups.

**Results:** 1285 patients underwent neobladder, continent cutaneous diversion and ileal conduit at our institution. A total of 35 patients following urinary diversion underwent 43 stone procedures. 9 additional patients who underwent augmentation cystoplasty underwent 12 stone procedures. There was a significant increase in patients requiring procedures for stone formation in those who underwent a continent diversion (7.3%) as opposed to an ileal conduit (1.5%)  $p < 0.001$ . 41 (75%) of the stone procedures were performed on patients with continent diversions, in which the majority were found in the reservoir. In the entire cohort, 52% of the stones were metabolic, 38% were infectious and 10% were mixed. Of the 25 procedures performed for upper tract stones, 14

(56%) were metabolic. In patients with continent urinary diversions with lower tract stones, 45% were metabolic stones.

**Conclusion:** Patients with continent urinary diversions are more likely to require a treatment for stones when compared to other types of urinary diversion. Stones formed in the setting of urinary diversion have traditionally been thought to be infectious in nature. However, our data demonstrates that as a group patients with urinary diversion are more likely to form metabolic stones. Upper tract stones in all types of urinary diversion are more often metabolic, and it is only in the patients with continent diversions and reservoir stones that we observe slight predominance of infectious stones over metabolic stones (55% vs 45% respectively). These findings suggest the importance of performing an appropriate metabolic evaluation and regular imaging in patients who form stones following urinary diversion.

#### MP4-08 THE EFFECTS OF HALF-SALINE AS AN IRRIGATION FLUID ON SERUM SODIUM IN PERCUTANEOUS NEPHROLITHOTOMY

A. Tabibi, M. Mohammadi Sichani, A. Kashi

**Background:** Percutaneous nephrolithotomy (PCNL) is the treatment of choice for large renal stones. It is showed that irrigation fluid will be absorb during the procedure, therefore severe electrolyte changes may occur and in many articles it is recommended to use normal saline as an irrigation fluid in PCNL. We evaluated the effect of half saline on serum sodium in acceptable number of cases. In this way we can save money and will decrease probable side effects of distilled water.

**Methods:** The study was performed in Labafinejad University Hospital in Tehran, Iran, between May-august 2008. Following ethics committee approval 96 adult patients were included. We included only adult patients with normal preoperative serum sodium and creatinine. Half-saline was used for continuous irrigation and the height of fluid as constant at 80 cm above the operation table. 0.9% NaCl was infused for intravenous fluid administration in all cases. We measured serum sodium, hemoglobin, urea and creatinine before and 6, 24 and 72 hours after PCNL.

**Results:** The mean serum sodium was 140.3 preoperatively that decreased to 140.1 about 6 hours after surgery. Declining continued to 139.1 during first day after PCNL but it increased to 139.3 after 48 hours. No significant differences were seen between groups.

**Conclusion:** Half saline is an acceptable irrigation fluid for straightforward cases.

#### MP4-09 LIMITS OF MINIATURIZATION IN PNL—A THEORETICAL MODEL

H. Hentschel, M. Hentschel, V. Janitzky, T. Weirich—Germany

**Background:** Percutaneous Nephrolithotomy (PNL) is a minimally-invasive and effective procedure in treatment of upper urinary tract calculi  $\geq 2$  cm. There are changes in indicating PNL due to the miniaturization of equipment. To evaluate the role and limits of miniaturized PNL a theoretical model is being introduced.

**Methods:** A theoretical model, developed in cooperation with a physicist, describes the process of stone disintegration and removal during PNL. PNL is disintegration of a spherical body with diameter  $R_0$ . Its fragments ( $R_1 \dots i$ ) are disintegrated in several steps (i) and a variable time (tD), until they can be removed by suction through the instrument with  $R_i < R_{instr}$ . Suction is described by a

suspension (viscosity  $\eta$ ) of small particles flowing through a tube (Diameter  $R_{instr}$ ) in laminar flow.

**Results:** When a spherical body (Volume  $V_0$ ) is disintegrated into two spherical bodies ( $V_1$ ), both spheres show a diameter of 79% of the original stone. After one further step of disintegration there are 4 spheres with  $R_2 = 0.63 R_0$ . For each step i of disintegration the stone size and time required for disintegration and suction can be calculated. After 6 steps there are 64 fragments requiring time of disintegration. For removal of fragments must be considered the 4th-potency- influence of instrumental diameter on the flow (Hagen–Poiseuille equation) resulting in a prolonged time.

**Conclusion:** There seem to be limits to miniaturization in PNL. In current literature, time of stone destruction and removal should be stated in order to evaluate efficacy of miniaturized instruments. Thus, invasiveness should consider the amount of time as well as instrument diameter.

#### MP4-10 THE PRESENCE OF SPINE PATHOLOGIES DOES NOT AFFECT THE OUTCOME OF PERCUTANEOUS NEPHROLITHOTOMY

C. Kara, B. Resorlu, E. Ozyuvali, A. Unsal

**Background:** The primary aim of this study was to evaluate the safety and efficacy of percutaneous nephrolithotomy (PCNL) in patients with spine pathologies.

**Methods:** We retrospectively reviewed the medical records of patients who underwent PCNL from November 2006 to January 2009 with a total number of 517. We performed PCNL for renal stones on 5 patients with spine pathologies, including 4 with congenital scoliosis and 1 with ankylosing spondylitis. Two patients had a history of renal surgery. Mean age of patients was 37.8 years (32–44) and mean stone burden was 485 mm<sup>2</sup> (400–1350). All procedures performed in the prone position after retrograde ureteral catheterization. Tract dilatation was accomplished using Amplatz or balloon dilators of up to 24 or 28 F. PCNL was accomplished using rigid nephroscope with ultrasonic and/or pneumatic lithotripter under general anesthesia. Flexible nephroscopy was performed in all patients to improve stone-free rates.

**Results:** The stones localizations were in lower calyx in one patient, in renal pelvis in 3 patients, multiple calyces and pelvis in one patient. Mean operative and fluoroscopic screening time were 67.3 (55–90), and 3.1 (2–5) minutes respectively. The stone was cleared by a single tract in two cases, and three required 2 tracts. Three patients were stone-free after the operation. Auxiliary procedures were required in 2 patients and included ureteroscopy in 1, and SWL to fragment residual stone in 1 patients. No severe complication, either due to anesthesia or surgical procedure, was observed in the patients. Damage of neighboring organs and bowel perforation were not seen in any patients. One patient required blood transfusion. Transient fever was seen in 1 patient which resolved with conservative treatment. Two of the cases had to stay for 24 hours to screen pulmonary and cardiac signs in the intensive care unit following PCNL.

**Conclusion:** PCNL is safe and effective procedure even in patients with severe spine pathologies. The patient should be informed about the possibility of intensive care postoperatively.

#### MP4-11 SINGLE CENTER EVALUATION OF POST-OPERATIVE COMPLICATIONS DETECTED BY COMPUTERIZED TOMOGRAPHY FOLLOWING PERCUTANEOUS NEPHROLITHOTOMY

E. Gnassin, S. Handa, J. Lingeman—United States

**Background:** CT post-percutaneous nephrolithotomy (PNL) is frequently used to assess stone-free status. However, many centers do not use CT routinely. Timely CT is useful in recognition and management of post-operative complications. We review the post-operative complications diagnosed with CT scan and the missed early complications in patients who did not have CT post-operatively.

**Methods:** We retrospectively reviewed the records of all patients in our institutional review board-approved database who underwent PCNL from April 1999 to May 2009. Patients were divided into two cohorts based on whether they had a CT scan within 24 hours post-surgery. Demographic data, CT findings, and complications were reviewed.

**Results:** 961 patients that had PNL were available for analysis. 364 (37.8%) had BMI >30. 60 patients (6.2%) had significant skeletal anomalies such as scoliosis or limb contractures and 74 (7.7%) had an ectopic kidney or renal fusion anomalies. 66 patients (6.8%) did not have a CT done post-operatively, among them 2 (3%) were readmitted—one due to perinephric hematoma and one due to large renal pelvic hematoma. 895 patients had a post-operative CT scan. Among them, 3 (0.3%) had negative POD1 CT and were readmitted due to hematoma (2 patients) or hydrothorax (1 patient). Patients who had post-operative CT were less likely to be readmitted due to missed complications ( $p = 0.04$ ). Complications diagnosed by CT were: perinephric hematoma in 31 (3.4%), of them two required embolization and 6 necessitated blood transfusion; and pleural effusion in 27 (3%), of them 9 required treatment. There were 2 colon perforations and 2 splenic injuries.

**Conclusion:** Post-PNL complications are not common but their prompt diagnosis and treatment is imperative. CT scan is able to diagnose post-operative complications in a timely manner and should be considered in every patient undergoing PNL.

#### MP4-12 THE ROLE OF PERCUTANEOUS NEPHROLITHOTOMY IN THE TREATMENT OF PREGNANCY RELATED RENAL CALCULI

E. Gnessin, A. Krambeck, S. Handa, J. Lingeman—United States

**Background:** We evaluate the treatment outcomes of patients treated with percutaneous nephrolithotomy (PNL) for complex stones presenting during pregnancy.

**Methods:** All patients treated with PNL for calculi presenting during pregnancy were reviewed. 8 patients were identified from 2001–2009. PNL was performed at second trimester in 2 patients and the remaining 6 underwent PNL post-partum.

**Results:** Mean stone size was 1.78 cm (range 0.6–4.5). Patients presented with recurrent UTI (1), flank pain (2), or both (5). Calyceal diverticulum was present in 2 patients and 1 had a solitary kidney. Initial treatment included a nephrostomy tube in one, ureteral stenting in 3, and PNL in 2. Two patients underwent unsuccessful shock wave lithotripsy post-partum. Mean time from delivery to PNL was 5.6 months [0–24]. Four stones were calcium oxalate monohydrate, 3 calcium phosphate, and 1 cystine. No intra- or post-operative complications were identified. Mean length of hospitalization was 1.6 days (1–3).

**Conclusion:** Complex renal calculi during pregnancy can be treated with conservative measures in most patients until post-partum PNL can be performed. However, multiple exchanges of stents and nephrostomy tubes is usually necessary. With adequate precautions, PNL can be safely performed in pregnant patients, avoiding multiple surgical interventions.

#### MP4-13 THE UTILITY OF PELVI-CALYCEAL MUCOSA BIOPSIES DURING PERCUTANEOUS NEPHROLITHOTOMY (PCNL)

A. Mathew, A. Kurien, R. Sabnis, M. Desai

**Background:** A wide spectrum of histological changes of the pelvic urothelium can occur in patients with stone disease. It ranges from hyperplasia or metaplasia to a frankly malignant lesion. In addition, associated infections and mucosal inflammation can complicate the picture.

**Methods:** From 1995 to 2009, 5184 PCNLs were done in our institution for renal stones. A pelvic mucosal biopsy during PCNL was obtained in 81 (1.6%) patients with a mean age of  $45.4 \pm 12.8$  years with a male:female ratio of 3.3:1. These biopsies were taken from suspicious looking pelvi-calyceal mucosa.

**Results:** We diagnosed ten (12.3%) malignant neoplasms, which included high grade dysplasia, transitional cell carcinoma and squamous cell carcinoma. There were 22 (27.2%) cases of metaplasia of urothelium which included squamous, glandular and osseous metaplasia. Associated infections were seen in seven (8.6%) patients. Fungal hyphae of aspergillus and candida species were seen in the biopsies taken from six patients and caseous material which stained positive for acid fast bacilli was obtained in another patient. Florid inflammatory response was seen in 26 (32.1%) patients. The remaining 16 (19.8%) biopsies revealed calcification.

**Conclusion:** We require a high index of suspicion for an associated urothelial malignancy in all patients with renal calculi. The dismal prognosis of the renal pelvic malignancies warrants a biopsy from any abnormal looking mucosa while performing PCNL. In addition, the prevalence of osseous metaplasia in these patients with stone disease may point to a possible role of this phenomenon in the pathogenesis of renal calculi.

#### MP4-14 PERCUTANEOUS NEPHROLITHOTOMY IN CHILDREN

I. Aridogan, N. Satar, Y. Bayazit, V. Izol, O. Karsli, S. Zeren—Turkey

**Background:** Treatment of pediatric urinary stones with a minimally invasive method is extremely important in our country where urolithiasis is a common entity. In this study, results of the percutaneous nephrolithotomy (PNL) on pediatric patients are presented.

**Methods:** PNL was performed on 301 renal units of 277 pediatric patients. Mean age was 7.4 (7 months–14 years) and 169 (56%) patients were male. Twenty four (8.7%) patients had previous open renal surgery and 16 (5.3%) patients had unsuccessful SWL history. Six (1.9%) patients had solitary kidney, eight (2.6%) had impaired kidney function and three (0.9%) had anuria. Initially open tip ureter catheter was inserted into the ureter in lithotomy position, followed by percutaneous needle access to an appropriate renal calyx under general anesthesia. Then the tract was dilated to insert a renax tube with a minimum required diameter with the help of a fluoroscopy. Stones were visualized with a rigid nephroscope or a ureteroscope and extracted after pneumatic or ultrasonic lithotripsy when necessary.

**Results:** Two hundred and fortyfive (81%) patients were rendered stone-free. Success rate was 92% with the inclusion of 32 patients with clinically insignificant residual fragments. Blood transfusions were required in 23 (7.6%) of the procedures. Open surgery performed on three (0.9%) patients and SWL was scheduled for 6

(1.8%) patients. There were two (0.6%) colonic perforation that was managed conservatively.

**Conclusion:** PNL can be performed effectively, reliably and successful results can be obtained in the pediatric age group and infants with stone disease when it is performed carefully with paying attention.

#### **MP4-15 COMBINATION OF PNEUMATIC AND ULTRASONIC LITHOTRIPTER IN PERCUTANEOUS NEPHROLITHOTOMY**

L. Tahmaz, S. Bedir, M. Zor, H. Topac, M. Dayanc

**Background:** We evaluated clinical efficacy of combination of pneumatic and ultrasonic lithotripter in percutaneous nephrolithotomy.

**Methods:** From February 2005 to June 2009, a total of 90 patients undergoing percutaneous nephrolithotomy for symptomatic calculi were evaluated retrospectively. Stone fragmentation and removal was done with a standard ultrasonic (U) device in 66 and combination of pneumatic/ultrasonic (P/U) unit in 24 patients. Complications, stone-free rates and operation time were compared in the 2 groups.

**Results:** Stone location and burden were similar in both of the two groups (P/U: mean 726 mm<sup>2</sup>, U: mean 685 mm<sup>2</sup>) ( $p > 0.05$ ). Average time required for complete stone clearance was considerably less for the combination device compared with ultrasonic device (P/U: mean 71 minutes U: mean 96 minutes) ( $p < 0.05$ ). Stone-free and complications rates were slightly superior for the combination group.

**Conclusion:** The combination pneumatic/ultrasonic lithotripter is capable of disintegrating and extracting stone material at a more rapid rate than standard ultrasonic devices. Especially it can be efficacious and safe for removing large renal calculi.

#### **MP4-16 EFFICACY OF NOVEL COAXIAL OCCLUSION DEVICE TO PREVENT STONE MIGRATION DURING PERCUTANEOUS NEPHROLITHOTOMY (PCNL)**

M. Gupta, M. Rothberg, M. Wosnitzer—United States

**Background:** PCNL is often preceded by placement of a ureteral catheter into the collecting system to perform retrograde pyelography (RPG), define pelvicalyceal anatomy, and distend the collecting system to facilitate percutaneous needle access. We tested the safety and efficacy of a new coaxial film-based 15 mm occlusion device, Coaxial Accordion™ (Percsys, Mountain View, CA), designed to facilitate RPG while simultaneously preventing stone migration during PCNL.

**Methods:** A retrospective review of our institutional PCNL database from January to July 2009 analyzed patient demographics, pre-operative imaging, and outcomes following PCNL with the coaxial device. Following cystoscopic placement of a guidewire, the device was passed into the collecting system and deployed at the UPJ. RPG was performed and the patients were placed in prone position. Contrast and/or saline were instilled as necessary during percutaneous access. PCNL was performed in standard fashion. Following conclusion of PCNL the device was withdrawn in retrograde fashion.

**Results:** The device was deployed at the UPJ successfully in 14/14 patients (mean age 63.5) and was felt to enhance the ability of guidewires to bypass severely impacted stones. Initial RPG in supine position was performed successfully in 14/14 patients. RPG in prone position was performed successfully in 13/14 patients

with one failure due to kinking of the device shaft in a morbidly obese patient. During PCNL, fragments in the renal pelvis were extracted by ultrasonic lithotripsy and suction with no instances of stone migration into the ureter, even in patients with complete staghorn calculi (mean diameter 2.2 cm; largest 3.6 cm). The device was successfully undeployed and removed in 14/14 patients. Post-operative ureteral stents were placed in 13/14 patients, and nephrostomy tube placed in 11/14 patients. The mean length of stay was 26 hours (18–120) and the mean operative time was 135 minutes (110–170).

**Conclusion:** This new Coaxial Accordion™ 15 mm device is safe and efficacious for use in PCNL procedures and can improve outcomes by preventing antegrade stone fragment migration, improving stone-free rate, facilitating RPG, and decreasing operative time and length of stay.

#### **MP4-17 THE SAFETY OF TUBELESS PERCUTANEOUS NEPHROLITHOTOMY BASED ON IMMEDIATE POST-OPERATIVE NONCONTRAST COMPUTED TOMOGRAPHY**

J. Choi, H. Kim, D. Han, B. Jeong, S. Seo, S. Jeon—South Korea

**Background:** Although tubeless percutaneous nephrolithotomy (PCNL) has been shown to be a safe method in the treatment of renal calculi, there is few data to evaluate the postoperative imaging findings after tubeless PCNL. In this study, we evaluated the safety of tubeless PCNL including CT findings.

**Methods:** Between August 2008 and May 2009, 42 cases (41 patients) of PCNL were performed at our institute and 25 cases of them by tubeless PCNL. We reviewed the medical records of the initial 22 cases (including 1 simultaneous bilateral patient) in which non-contrast helical abdominal CT was obtained on the first postoperative day. The decision was made at the end of the procedure whether or not to place a nephrostomy tube depending on the surgeon's findings. Tubeless PCNL was not performed in patients who had significant intraoperative bleeding, perforation of the pelvicalyceal system, excessive manipulation at the ureteropelvic junction, residual stone burden necessitating a staged second-look nephroscopy, and azotemia. At the end of the procedure, a double-pig tail ureteric stent was placed antegradely and a nephrostomy tube avoided. All cases were performed by staged operation and done by one percutaneous tract. We investigated whether there was perinephric fluid collection like hematoma or urinoma, remnant stone, and other complications by CT scan. Perioperative parameters including operation time, hospital stay, hemoglobin change, and complications were also measured.

**Results:** The mean was 54.9 ± 13.3 years (range 31–78). All patients had an uneventful postoperative recovery. The mean maximal stone diameter was 20.1 ± 6.0 mm (range 13 to 32 mm) and the mean stone weight was 5.6 ± 5.8 gm (range 1 to 24 gm). 11 units had multiple stones. The mean operative time was 81.0 ± 35.6 mins (range 30 to 170 mins). The mean hospital stay was 2.1 ± 0.4 ds (range 2 to 3 ds). The mean hemoglobin decrease was 0.76 ± 0.73 g/dL. No blood transfusion was necessary. The mean visual analogue scale pain intensity score on postoperative day 1 was 30 ± 17.3 mm (range 0 to 70 mm). On the CT scan, there was no case of urinoma formation and there was 1 case which showed small amount of subcapsular hematoma (25 × 9 mm) that was resolved spontaneously without any intervention. There was no case of urinary tract infection, delayed hemorrhage and/or urine leakage, and organ trauma. Stone free rate according to non-contrast CT scan was 27.3% (6/22). However, if clinically insignificant

residual fragments were included, the success rate was 86.4% (19/22). One case became stone-free after 1 session of extracorporeal lithotripsy and 2 cases were followed-up without clinical problems. **Conclusion:** Tubeless PCNL appears to be a feasible and safe procedure with low postoperative pain, short hospital stay, and low complications. Non-contrast CT scan also revealed that even at the immediately postoperative period there was negligible insult in the affected kidney.

#### **MP4-18 PROSPECTIVE RANDOMIZED TRIAL OF NEPHROSTOMY TRACT CLOSURE USING FLOSEAL VS. FASCIAL STITCH VS. COPE LOOP FOLLOWING PERCUTANEOUS NEPHROLITHOTRIpsy**

R. Li, H. Lee, D. Pick, M. Louie, E. Mcdougall, R. Clayman—CA

**Background:** Choice of nephrostomy tract closure after percutaneous nephrolithotomy (PCNL) is often dependent on surgeon preference. While there are data evaluating the safety and efficacy of “tubeless” nephrostomy tract closure, these studies are often of a retrospective nature. We present a prospective randomized controlled trial to evaluate the effect of Floseal versus fascial stitch versus 10F nephrostomy tube on post-operative morbidity.

**Methods:** Thirty-one patients undergoing PCNL were randomized into one of the three tract management groups. All patients had a 7F ureteral stent placed at the end of the procedure. Data collected included demographics, stone burden, hospital course and stone free rates. We also examined analgesic use, analog pain scales and SF-36 questionnaires pre-operatively, 1 day post-operatively, and at 1 week, 1 month and 3 month follow ups. All variables were analyzed using the ANOVA test.

**Results:** Mean age, BMI, stone burden, pre-op labs, and complication rates were similar among the three groups. Post-operative hospital stay ( $P=0.45$ ), analgesia in morphine equivalents ( $p=0.79$ ), changes in creatinine ( $p=0.28$ ) and hemoglobin ( $p=0.09$ ) were also similar. SF-36 total scores and pain analog scores on post-op day #1 and at 1 week, 1 month, and 3 month follow-up visits were also comparable for all three groups.

**Conclusion:** Nephrostomy tract closure with Floseal, deep fascial stitch or 10F cope loop nephrostomy tube following PCNL showed no significant difference in post-operative blood loss effect, pain, hospital stay or recovery outcomes.

#### **MP4-19 COLON POSITION IN VENTRAL AND INTERMEDIATE DORSAL DECUBITUS (VALDIVIA)**

G. Mariano Sebastian, N. Billordo Peres, P. Garcia Marchiñena, M. Sinclair, J. Ocantos, P. Daels

**Background:** To compare the colon position in ventral and intermediate dorsal decubitus with abdominal and pelvic CT scan, to determine the percutaneous renal puncture safety.

**Methods:** Twenty patients were prospectively studied with an abdominal and pelvic CT scan (64 tracts Siemens Somatom Volume Zoom model, tomography), in ventral and Valdivia decubitus. Considering the end of the twelve rib and the kidney lower pole as fix reference points, the distances between the 12th rib and the colon, the kidney and the colon, and between the 12th rib and the kidney were analyzed. Age, sex body mass index (BMI) and surgical history were taken into account.

**Results:** Average age was 48 years and BMI 25.5. Colon slips away from the kidney, an average of 12.9 mm more in the Valdivia

decubitus than in the ventral one ( $p=0.0019$ ). When comparing the distances between the colon and the twelve rib, colon moves away an average of 23.8 mm more with the patient in the Valdivia position ( $p=0.0007$ ). The distance between the kidney and the ribs does not vary in both decubitus ( $p=0.08$ ).

**Conclusion:** Colon moves away from the puncture site in the Valdivia position allowing a safer percutaneous puncture.

#### **MP4-20 PREOPERATIVE ADMINISTRATION OF ETHAMSYLATE: REDUCES BLOOD LOSS ASSOCIATED WITH PERCUTANEOUS NEPHROLITHOTOMY? A PROSPECTIVE RANDOMIZED STUDY**

O. Negrete-pulido, M. Marnes, J. Gutierrez-Aceves

**Background:** Bleeding continues to be most frequent complication of percutaneous nephrolithotomy (PNL). Although most bleeding associated with PNL can be managed conservatively some patients require blood transfusion (22%) or even a selective angioembolization (0.8%). Ethamsylate is a systemic non-thrombogenic hemostatic that acts on the first step of hemostasis by improving platelet adhesiveness and restoring capillary resistance. It could be used for surgical or postsurgical capillary bleeding. The objective is to assess the effects of ethamsylate before and after surgery on blood loss associated with PNL in a prospective randomized controlled study.

**Methods:** Candidates for PNL among patients with nephrolithiasis were randomized to receive (Group 1) or not (Group 2) ethamsylate 500 mg 1 hour before and 500 mg tid after surgery during their hospitalization. For all patients enrolled pre and postoperative hemoglobin (Hb) and hematocrite (Hct) were measured. Hb and Hct decrease, blood transfusion rate, incidence of renal hematoma, number of days of nephrostomy tube requirement and hospitalization days were evaluated. Factors thought to be related with increased risk of blood loss as number of tracts and transoperative complications were also analyzed. Statistical analysis was done using independent samples T and Chi-square test ( $p < 0.05$ ) for each of these factors (SPSS.10.0 version).

**Results:** 69 PNL procedures in 59 patients were included in our study. Group 1: 31 patients, 34 procedures. Group 2: 28 patients, 35 procedures. In all patients a nephrostomy tube was placed after surgery. Mean decrease in Hb was 1.77 g/dl (0–3.77) vs. 1.82 g/dl (0–5.4) respectively ( $p=0.88$ ). Mean decrease in Hct was 5.06% (0–8.8) vs. 5.9% (0–15.9) respectively ( $p=0.44$ ). No patients were transfused in group 1 and 2 patients (7.7%) in group 2 ( $p=0.149$ ). Renal hematoma was diagnosed in 4 Vs 1 case in group 1 Vs 2 respectively ( $p=NS$ ). Of the others factors related with increased blood loss only the nephrostomy tube permanence and the hospitalization days showed statistical significance (mean days of nephrostomy  $3.7 \pm 0.89$  vs.  $4.75 \pm 2.98$ ,  $p=0.019$ , hospital stay  $3.31 \pm 1.01$  vs.  $5.42 \pm 4.18$   $p=0.025$ ).

**Conclusion:** Even though the transfusion rate and the incidence of renal hematoma showed a tendency to be lower in the group receiving ethamsylate according with our results the use of ethamsylate showed no difference in Hb and Hct decrease between groups. Duration of the nephrostomy tube and hospital stay may be associated with a faster clearance of the urine and a more favorable postoperative recovery.

## MP5: BLADDER CANCER

### MP5-01 COMPARING EFFICACY OF BCG THERAPY AND CAUTERIZATION OF TUMOR VERSUS BCG THERAPY WITHOUT CAUTERIZATION IN SUPERFICIAL BLADDER CANCER

S. Falahatkar, A. Roshani, Ghanbari, S. Asadi, M. Akbarpour, N. Khaki

**Background:** Bladder cancer recurrence occurs at 30–80% of cases depending the grade, stage and number of tumors. Regarding the high rate of local recurrence of tumor and because of the mechanisms of action of cauterization that destroys the malignant cells, we studied the efficacy of BCG therapy and cauterization of 10 mm of tumor margin versus BCG therapy without cauterization, in superficial bladder cancers to prevent the recurrence of bladder tumor.

**Methods:** Files of 60 patients, including 30 patients with cauterization (group 1) and 30 patients without cauterization (group 2), referred from March 2006 to June 2008 with primary stage Ta, T1, and T2a, grade G1 to G3 TCC of the bladder and treated by TUR-BT were reviewed in this study. The two groups did not differ significantly in age, sex, and tumor grade, location, and size. Grade, stage, location and size of tumors with recurrence were compared.

**Results:** There was no significant difference between two groups in stage, location and size of tumors. The rate of recurrence in low grade tumors in group 2 was significantly higher than in group 1 ( $p = 0.02$ ).

**Conclusion:** In conclusion, this technique appears to be useful for reducing recurrence in patients with grade 1 and 2 of bladder tumors.

### MP5-02 COMPARISON OF SURGICAL OUTCOME BETWEEN LAPAROSCOPIC AND OPEN RADICAL CYSTECTOMY FOR BLADDER CANCER: SAPPORO CITY GENERAL HOSPITAL EXPERIENCE

T. Seki, M. Miura, T. Suzuki, H. Sasaki, T. Mochizuki, H. Harada—Japan

**Background:** We compared the surgical outcome of laparoscopic and open radical cystectomy for bladder cancer.

**Methods:** From January 2001, ninety-five radical cystectomies were performed in our institute. Seventy-two cases were done by open procedure (open group), but 23 were laparoscopically (laparoscopic group). Urinary diversions were employed continent reservoir (10 cases), ileal conduit (59), ureterocutaneostomy (22), and three no diversion cases. There was no significant difference between open and laparoscopic group in diversion methods. Median follow-up were 9 months (laparoscopic group) and 27 months (open group). The procedures of laparoscopic radical cystectomy were done by 4 or 5 ports methods and bladder was extracted through perineal wound in male or vagina. Ileal conduit and ureterocutaneostomy was created through 12 mm port hall.

**Results:** Median operative time was significantly longer in the laparoscopic group [504 min (laparoscopic group), 398 min (open group)]. However, mean blood loss (450 ml, 1205 ml) and analgesic requirement were significantly less in the laparoscopic group. Postoperative oral intake (1 day, 5 day) was started significantly earlier and hospital stay (29 day, 39 day) were significant shorter in

the laparoscopic group. Rate of surgical site infection (0%, 26%) and the major postoperative complication (4%, 27%) were significantly lower in the laparoscopic group. The cancer-specific and the recurrence-free survival ratio in the two groups were comparable.

**Conclusion:** The laparoscopic approach provides the benefit of lesser blood loss and postoperative pain in patients undergoing radical cystectomy. The oncological outcome is comparable to that of open radical cystectomy. The laparoscopic radical cystectomy is a useful and safe procedure.

### MP5-03 LAPAROSCOPIC RADICAL CYSTECTOMY (LRC): SHORT TERM OPERATIONAL AND ONCOLOGICAL OUTCOMES

O. Sanli, T. Tefik, E. Salabas, E. Aliyev, O. Aytac, T. Esen—Turkey

**Background:** The aim of this prospective study is to compare LRC with its open counterpart and delineate its role in bladder cancer treatment.

**Methods:** Between January 2008 and June 2009, 34 patients were diagnosed with muscle invasive bladder cancer and underwent radical cystectomy (LRC 13 cases, open radical cystectomy (ORC) 21 cases). In LRC group urinary diversion was performed extracorporeally through infra umbilical median incision. Baseline patient characteristics, perioperative parameters and postoperative oncologic outcomes of LRC were evaluated and then compared with ORC statistically.

**Results:** There was no statistically significant difference in age, sex, body mass index, previous abdominal surgeries, ASA score or pathological tumor stage between the two groups. The LRC group yielded a significantly smaller incision for urinary diversion ( $9.5 \pm 2.8$  vs.  $18.4 \pm 3.9$  cm,  $p < 0.005$ ), longer mean operative time ( $266.9 \pm 90.1$  vs.  $191.4 \pm 68.8$ ,  $p < 0.005$ ), shorter hospital stay ( $8.4 \pm 2.8$  vs.  $12.5 \pm 6.7$ ,  $p < 0.05$ ) than the open group. Meanwhile, the mean estimated blood loss, blood transfusion rate, oral intake time and complications were similar in two groups. The mean follow-up was  $6.08 \pm 5.00$  (1–14) months in LRC with overall survival (OS) and cancer specific survival (CSS) rate of 100%. After a mean follow-up of  $7.48 \pm 4.05$  (1–14) months in ORC group, the OS and CSS was 80.9% and 85.7%, respectively. There was no statistically significant difference for these parameters between groups.

**Conclusion:** Despite limited number of patients, our study revealed that LRC presents similar oncological results with ORC in short term with some advantages such as shorter hospital stay and cosmetic outcome.

### MP5-04 ROBOTIC EXTENDED PELVIC LYMPHADENECTOMY FOR BLADDER CANCER: INITIAL EXPERIENCE WITH GREATER NODAL YIELD

H. Lavery, R. Abaza—USA

**Background:** The extent of pelvic lymphadenectomy (PLND) for bladder cancer has been shown to impact patient survival. Increased nodal yield improves staging accuracy and has demonstrated survival benefit. The oncologic efficacy of laparoscopic or



robotic extended PLND has been questioned due to typically lower nodal yields. We report our initial experience with robotic extended PLND for bladder cancer, maximizing nodal yield by reproducing open techniques.

**Methods:** The initial 15 consecutive patients who underwent robotic radical cystectomy with extended PLND by a single surgeon (RA) were reviewed. The boundaries of dissection were the genitofemoral nerves laterally, 2 cm above the aortic bifurcation proximally, the node of Cloquet distally, and included the presacral nodes medially. The common, external and internal iliac vasculature were circumferentially skeletonized.

**Results:** Four of fifteen patients received neoadjuvant chemotherapy. Pathologic stage was pT0 in five, pT1 in three, pT1 in one, pT2 in two, pT3 in three, and pT4 in one. Mean nodal yield was  $41.8 \pm 19$  nodes (range 18 to 67). Three patients (20%) were found to have nodal metastases in 1/50, 2/64 and 3/24 nodes. Mean operative time was 431 min, with a mean of 107 min (range 66 to 160) for the PLND. Mean postoperative length of stay was 3.4 days. There were no complications attributable to the PLND.

**Conclusion:** Our initial experience with robotic extended PLND for bladder cancer achieved nodal yields previously only reported in open surgical series. A larger series with long-term follow-up will be necessary to confirm oncologic efficacy.

#### MP5-05 LAPAROSCOPIC RADICAL CYSTECTOMY AND DETENIAL SIGMOID COLON ORTHOTOPIC NEOBLADDER FOR CHILDREN BLADDER RHABDOMYOSARCOMA (REPORT OF TWO CASES)

X. Kai—People's Republic of China

**Background:** Rhabdomyosarcoma is the most common soft tissue sarcoma in childhood, with an annual incidence of 4 to 7 per million children 15 years or younger. Until now, there is no report of laparoscopic radical cystectomy for children bladder rhabdomyosarcoma in the world. We will present our initial experience and results of laparoscopic radical cystectomy and detenial sigmoid colon orthotopic neobladder for children bladder rhabdomyosarcoma.

**Methods:** After preoperative routine chemotherapy, two cases of 3 years old boys with bladder rhabdomyosarcoma underwent this technique. The procedure of bilateral pelvic lymphadenectomy and cystectomy was performed purely laparoscopically. Removal of the mobilized specimens and urinary diversion operation were managed via enlarged abdomen incision. The urinary diversion procedure includes: construction of the detenial sigmoid pouch, bilateral stented antireflux implantation of the ureters in the pouch and orthotopic anastomose of neobladder with urethra.

**Results:** The procedure was completed successfully. The total operative time were 6 h and 6.5 h respectively, and laparoscopic procedure time was about 3.5 h and 4 h respectively. The intraoperative blood loss was 70 ml and 80 ml respectively, and transfusion was resorted to one case with 2U pycnotic erythrocyte during operation because of preoperative hypohemoglobinemia. Two cases were all received bilateral pelvic lymphadenectomy, and the number of lymph nodes of dissection were all six in each pelvic side, and all of them were negative. The surgical margins of ureter and urethra were negative. The bowel recovery time were 5 d and 7 d after operation respectively. The pelvic drainage was removed in 14 d and 17 d respectively, the neobladder's drainage was removed in 20 d and 26 d respectively, urethral catheter and ureteral stents were removed in 27 d and 34 d respectively after the

leak tightness was confirmed by transurethral cystography. There were no perioperative complications such as water-electrolyte and acid-base balance derangement, urinary leakage, reflux and ileus occurred. Average follow up was 3 months, all patients were able to void continuously and completely at regular intervals in daytime. Renal function was normal in all patients, and average reservoir capacity were 130 ml and 150 ml respectively. Long time follow up is carry on.

**Conclusion:** This is the first time in the world that the laparoscopic radical cystectomy for children bladder rhabdomyosarcoma is reported. With more experience and improvement of the surgical technique, laparoscopic radical cystectomy with small incision and rapid recovery, may become a feasible and safe alternative method for children bladder rhabdomyosarcoma.

#### MP5-06 CLINICAL PATHWAY FOR EARLY DISCHARGE AFTER ROBOTIC CYSTECTOMY

A. White, R. Abaza—USA

**Background:** Typical lengths of stay after open cystectomy are 7 days, without dramatic differences reported for robotic radical cystectomy (RRC). We developed a clinical pathway for early discharge after RC and analyzed our initial outcomes.

**Methods:** The initial twelve consecutive patients who underwent RRC by a single surgeon (RA) and were treated on a clinical pathway developed at our institution were reviewed. This included an extraction incision of  $\leq 3$  inches, no ICU stay, and no NG tube. For pain, a continuous catheter-infused local anesthetic at the extraction site, oral analgesia and intravenous ketorolac were used. Patients are required to ambulate on post-operative day (POD) zero or one with clear liquids uniformly on POD#1 then regular food POD#2 or #3 depending on exam with discharge when tolerating diet.

**Results:** Mean age was 64.1 yrs (46–86 yrs), and mean operative time was 420.5 min. All ambulated by POD#1. Seven had regular diet on POD#2, three on POD#3, and two on POD#4. Four required any intravenous narcotics while eight had none. Ten were discharged POD#3 and two POD#4 for a mean of 3.1 days. One was seen in the emergency department on POD#6 for emesis that resolved without admission. No others returned to the clinic or hospital within a week of discharge.

**Conclusion:** Our clinical pathway after RC allows shorter hospital stays than typical and is, to our knowledge, the shortest reported after cystectomy by any technique. Only one unplanned visit occurred during the first ten days. Further experience will be necessary to confirm the initial success.

#### MP5-07 AN AUDIT OF LASER ABLATION OF UPPER TRACT TRANSITIONAL CELL CARCINOMA; A SAFE AND EFFECTIVE TREATMENT IN LOW GRADE DISEASE?

S. Graham, P. Gurung, S. Longhorn, R. Smith, T. Philp, S. Choong

**Background:** We present our departmental experience in minimal access endourological management of upper tract Transitional Cell Carcinoma. We find an increasing number of referrals for this condition, both for palliation & now as a treatment option.

**Methods:** A Clinical audit was performed of our departmental database back to 2006. Results were supplemented with data from the electronic patient record, clinical case notes and pathology database. Information recorded included patient demographics, grade & stage of tumour, position of tumour, stenting, frequency of procedure, progression & ultimate outcome. Data were also

recorded for concomittant conditions, adjuvant treatment & discussion at a multi disciplinary team meeting (MDT).

**Results:** A total of 17 patients had 48 procedures. Mean patient age was 68 years. Average number of procedures was 2.7 with a median of 3.75%. Of patients were presented to MDT, the others presenting prior to 2006. 9 patients were G1, 4 were G2 and 4 G3 (pT1 max). of the 4 G3 patients. One was for symptomatic relief from haematuria, one had a contralateral nephroureterectomy and remained clear, and the third had also a nephroureterectomy but progressed and was referred on for specialist oncological management. The final patient was referred for nephroureterectomy after initial biopsy, and has subsequently died. 65% are maintained with stents, and 2 of 17 have had adjuvant BCG. To date, one patient has DNA follow up, 1 has progressed to nephroureterectomy and the other 11 patients remain on surveillance of either 4 or 6 months.

**Conclusion:** Endourological management of upper tract TCC is a useful and effective management option in low grade, low stage disease of the upper tract. In more aggressive disease, symptomatic relief may be useful, but more aggressive treatment options should also be considered.

#### **MP5-08 HAND-ASSISTED LAPAROSCOPIC RADICAL CYSTECTOMY WITH EXTRACORPOREAL URINARY DIVERSION**

S. Jung, M. Gil, S. Kim, J. Ha, S. Yoon, J. Chung

**Background:** The laparoscopic radical cystectomy with extracorporeal urinary diversion needs well trained laparoscopic surgical technique. The goals of managing bladder tumor are to control cancer, as well as to improve the quality of life including reducing pain and skin incision with appropriate urinary diversion procedures. The objectives of this study are to present the clinical outcomes of 10 patients who underwent the hand-assisted laparoscopic radical cystectomy (HALRC) with urinary diversion and to evaluate usefulness of this operative method.

**Methods:** HALRC with urinary diversion was performed for 10 cases of cT1-2N0M0 bladder tumors. We evaluated the operation times, blood loss, transfusion episodes, severity of pains, differences of pain control method, hospital stay, diet resumption, complications and recurrences of tumors. HALRC was done by transperitoneal hand assisted laparoscopic approach. The resected specimen was extracted through the same paraumbilical skin incision transperitoneally. The types of all cases of urinary diversion are ileal conduits. We could use the same port site for creation of opening of ileal conduits without additional skin incision.

**Results:** Parameters HALRC Uages 63.7 (47–73) Op. times (mins) 6.5 (5.5–8.1) Hosp. stay (days) 7.5 (6–10) Blood loss (cc) 330 (250–550) NSAID (person) 10 Diet resumption (days) 3.3 (2–5) Drain remove (days) 4.7 (3–7) Conversion to open surgery 0 Transfusions 0 complications 3 Recurrence 0

**Conclusion:** HALRC has a good operative outcomes. We could achieve the goals of cancer control, as well as improving the quality of life and creating ileal conduits without additional skin incision. But the long-term follow up is needed.

#### **MP5-09 OVERCOMING THE UROTHELIAL BARRIER: THE EFFECT OF CHITOSAN ON URETERAL INTRALUMINAL DRUG ADMINISTRATION AND PERISTALSIS**

D. Pick, S. Shelkovich, N. Canvasser, M. Louie, E. Mcdougall, R. Clayman—CA

**Background:** Chitosan, the product of the deacetylation of chitin, has been demonstrated to disrupt the bladder urothelial barrier. Relaxing the ureter prior to endourological procedures could ease instrument access. In an ex vivo model, intraluminal nifedipine has been shown to relax the ureter. We continue our work with medications to increase ureteral permeability, studying the effect of 1 mM nifedipine on peristalsis before and after pretreatment of the ureter with chitosan.

**Methods:** Freshly harvested 4 cm porcine tubular ureteral segments were placed in a novel organ bath with gassed Krebs solution. Each ureter had both ends cannulated. A pressure transducer was placed in-series at the inflow end of each ureter. Outflow drained by gravity. Intraluminal flow (1 ml/min) was maintained by a constant pressure, gravity fed reservoir. Phenylephrine, 10 mM, was added to the external bath to induce peristalsis. Then 1 mM nifedipine was added to the intraluminal reservoir. The time required to stop peristalsis was measured. Chitosan (0.5% w/v, 30 minutes) was then used to denude the urothelium and the study repeated.

**Results:** In six trials intraluminal nifedipine (1 mM) had no effect on ureteral peristalsis after 60 minutes of exposure. After pretreatment with chitosan, nifedipine (1 mM) stopped ureteral peristalsis within an average of  $12.30 \pm 1.93$  minutes. Ureteral contractile amplitudes were similar ( $p=0.53$ ) before and after chitosan administration.

**Conclusion:** Pretreatment of the intraluminal surface of the ureter with chitosan allows nifedipine to reversibly block peristalsis at low concentrations. Chitosan changes ureteral urothelial permeability, but has no long-term effect on ureteral contraction.

#### **MP5-10 OBESITY DOES NOT AFFECT THE SURGICAL AND ONCOLOGIC OUTCOMES OF ROBOTIC ASSISTED RADICAL CYSTECTOMY**

U. Boylu, M. Oommen, M. Raynor, B. Lee, R. Thomas—USA

**Background:** Obesity has been thought to be associated with poor surgical outcomes. We evaluated the effect of body mass index (BMI) on surgical and oncologic outcomes of robotic assisted radical cystectomy (RARC).

**Methods:** Between 2005 and 2008, a total of 36 patients underwent RARC with extracorporeal urinary diversion. Demographic data and outcome measures including age, sex, ASA score, operative time, blood loss, lymph node yield, number of positive nodes, need for transfusion, hospital stay, surgical margin status, complications, overall and disease-specific survival were compared between obese ( $BMI \geq 30 \text{ kg/m}^2$ ,  $n=17$ ) and non-obese ( $BMI < 30 \text{ kg/m}^2$ ,  $n=19$ ) patients. Complications were stratified according to Clavien system. Grade 1 and 2 complications were considered as minor, whereas grade 3, 4, and 5 were taken as major complications.

**Results:** Obese and non-obese groups were comparable regarding age, sex, and ASA score. There was no difference in operative time ( $p=0.9$ ), lymph node yield ( $p=0.1$ ), lymph node status ( $p=0.9$ ), surgical margin status ( $p=0.5$ ), need for transfusion ( $p=0.9$ ), hospital stay ( $p=0.8$ ), complication rates ( $p=0.8$ ) (Table 1). Estimated blood loss was significantly higher in obese group (459 vs. 258 ml,  $p=0.04$ ). Mean follow-up was 28.8 months (range 6–48 months). Overall and disease-specific survival revealed no significant difference between obese and non-obese groups ( $p=0.3$  and  $p=0.5$ , respectively). Obese ( $n=17$ ) Non-obese ( $n=19$ ) P Age (years)  $67.2 \pm 10.3$   $64.2 \pm 11.1$  0.4 BMI ( $\text{kg/m}^2$ ) [Range]

33.1 ± 1.9 [30–36.7] 25.4 ± 3.7 [17.5–29.7] - Sex (M/F) 14/3 15/4 0.9 ASA score 0.9 ASA 2 7 8 ASA 3 10 11 OR time (min) 437 ± 85 441 ± 98 0.9 Blood loss (ml) 459 ± 112 258 ± 172 0.04 Transfusion (n) 4 2 0.9 LN yield (n) 20.3 ± 14.7 18.2 ± 8.9 0.1 LN + (n) 5 6 0.9 Surgical margin positive (n) 1 0 0.5 Hospital stay (days) 6.5 ± 4.9 5.3 ± 2.3 0.8 Complications 0.5 None 8 13 Minor 6 4 Major 3 2 Overall Survival (months) 29.2 (95% CI 19.1 to 39.2) 36.3 (95% CI 28.9 to 43.7) 0.3 Disease-specific survival (months) 37.6 (95% CI 27.9 to 47.1) 41.9 (95% CI 35.6 to 48.2) 0.5 Table 1 Comparison of surgical and oncologic outcomes of robotic assisted radical cystectomy.

**Conclusion:** Blood loss in obese patients appears to be higher during robotic assisted radical cystectomy. Obese patients undergoing robotic assisted radical cystectomy have similar oncologic outcomes and survival compared to non-obese patients.

### MP5-11 ONCOLOGIC OUTCOMES OF ROBOTIC ASSISTED RADICAL CYSTECTOMY

U. Boylu, M. Oommen, B. Lee, R. Thomas—USA

**Background:** To report the intermediate-term oncologic outcomes of robotic assisted radical cystectomy (RARC).

**Methods:** A total of 36 patients who underwent RARC with extracorporeal urinary diversion for bladder cancer between 2005 and 2008 and have a follow-up of at least 6 months were reviewed. Pathologic outcomes, surgical margin status, overall survival and disease-specific survival were evaluated.

**Results:** RARC was performed in 29 men and 7 women. Mean age was 66.1 years. Studer pouch (6), ileal pouch (24), Hautmann orthotopic bladder (5), and Indiana pouch (1) was performed. There were 4 pTis, 4 pT1, 10 pT2, 14 pT3, and 4 pT4 patients. The mean number of lymph nodes removed was 16.8 (range 7–62) and 11 (31%) patients have Stage N+ disease. One patient (2.8%) had surgical margin positive. Mean follow-up was 28.8 months (range: 6–48 months). Mean estimated overall survival was 33.1 months (95% CI 26.9 to 39.3) and disease-specific survival was 40.5 months (95% CI 35.2 to 45.8). The difference in mean survival between LN+ (n = 11) and LN– (n = 25) patients was statistically significant (22.1 vs. 27.9 months, p = 0.006).

**Conclusion:** The oncologic outcomes and survival of patients undergoing RARC due to bladder cancer appears to be favorable in intermediate term.

### MP5-12 LEG ENDOSCOPIC GROIN LYMPHADENECTOMY FOR GENITOURINARY CANCER (LEG PROCEDURE)

V. Master, K. Ogan, D. Kooby, W. Hsiao, K. Delman—USA

**Background:** Inguino-femoral lymphadenectomy can serve as a diagnostic and potentially therapeutic procedure in a variety of malignancies, including those of the genitalia and the skin. Historically, this procedure is associated with significant morbidity. We hypothesized that both superficial and deep groin dissection (complete inguino-femoral lymphadenectomy) could be performed endoscopically with low morbidity.

**Methods:** In an IRB approved study, 18 groin dissections (LEG) were undertaken in 9 patients, male and female, over a 10 month time period. Groin dissections were performed for a variety of genitourinary cancers including: penile (7), scrotal (1) and urethral (1). Perioperative data including complications were recorded.

**Results:** The average length of the procedure was 147 minutes per groin. There were no intraoperative complications. The mean

number of lymph nodes harvested was 10 (range 2–24). Post-operative complications occurred in 4 patients including groin seroma (2) requiring further drainage and cellulitis (2).

**Conclusion:** Leg endoscopic groin (LEG) lymphadenectomy is feasible, with lymph node yields comparable to open series. There were no major complications for this classically morbid open operation. Longer term follow up will be necessary to determine oncological efficacy.

### MP5-13 ROBOTIC-ASSISTED LAPAROSCOPIC RADICAL CYSTECTOMY (RARC) WITH EXTRACORPOREAL URINARY DIVERSION : INITIAL EXPERIENCE

S. Jung, M. Gil, S. Kim, J. Ha, S. Yoon, J. Chung

**Background:** The goals of managing bladder cancers are to control cancer, as well as to improve the quality of life including reducing pain and skin incision and also urinary diversions are essential parts of bladder cancer patients. The aims of this study are to present the clinical outcomes of bladder cancer patients who underwent robot-assisted laparoscopic radical cystectomy (RARC) with extracorporeal ileal conduit.

**Methods:** For RARC surgical procedure, we undertook RACP and extracorporeal ileal conduit urinary diversion. First, using a six-port approach and the da Vinci Surgical System (Intuitive Surgical, Sunnyvale, CA, USA), one surgeon carried out a complete pelvic lymphadenectomy and cystoprostatectomy using a technique developed specifically for robotic surgery. And then the specimen entrapped in a bag and removed through a 5–6 cm suprapubic incision. Second, a different surgical team exteriorized the bowel through this incision and created a ileal conduit urinary diversion extracorporeally.

**Results:** For RARC surgical procedure, the patient age was 55.5 years. In our case ileal conduit urinary diversion was performed extracorporeally. Mean operative time was 7.3 hours. Mean surgical blood loss was 330 ml, which was significantly less than in our open cystectomy (570 ml). On surgical pathology, TCC was confirmed and staging is pT1-2, G2-3. In no case was there inadvertent entry into the bladder or positive surgical margins. The time to flatus was 2.5 days and time to bowel movement was 3.0 days. The patients was discharged home on postoperative days 7.0. There were a no postoperative complications.

**Conclusion:** Our initial experience with robot-assisted laparoscopic radical cystectomy (RARC) with extracorporeal ileal conduit urinary diversion appears to be favorable with acceptable operative, pathological and short-term clinical outcomes. As our experience increases, we expect to continue to develop our surgical technique and decrease operative time.

### MP5-14 OUTCOMES OF ENDOSCOPIC RADICAL CYSTECTOMY WITH EXTRACORPOREAL ILEAL CONDUIT

G. Sung, T. Kim, K. Moon, W. Cho—Korea

**Background:** We analyzed perioperative and oncological outcomes following radical cystectomy by the laparoscopic and robot assisted laparoscopic methods.

**Methods:** Between January 2003 and May 2009, we performed radical cystectomy with extracorporeal ileal conduit using laparoscopy (LRC) and robot-assisted laparoscopy (RLRC) for bladder cancer in 45 patients and the results of the LRC and RLRC were analyzed. Surgical results such as the operation time, estimated blood loss (EBL), transfusion rate, hospital stay and complication rates and the oncological results were reviewed retrospectively.

**Results:** LRC was performed in 39 patients and RLRC in 6 patients. The pathologic reports showed transitional cell type in all cases. The preoperative stage was T1, high grade in 22 cases, T2 in 17, and T3 in 6. For the LRC groups, the mean operation time was 176.8 min (120–340), the EBL was 294.2 ml (150–800), the transfusion rate was 16.9%, the hospital stay was 10.5 days, the intraoperative complications was 5/32 cases (15.6%). For RLRC group, the mean operative time was 163.5 min (130–190), the EBL was 186.4 ml (140–210), and the transfusion was 0%. The pathologic surgical margins were all negative except one.

**Conclusion:** Because case of RLRC is few, it is difficult to directly compare two groups. But, RLRC showed better operative results than LRC in early experience. LRC and RLRC with extracorporeal ileal conduit is acceptable treatment option in patients with muscle invasive bladder tumor.

### MP5-15 THE USE OF FLUORESCENCE IN SITU HYBRIDIZATION (FISH) TESTING IN PATIENTS WITH KNOWN UPPER TRACT TRANSITIONAL CELL CARCINOMA

J. Johannes, E. Nelson, B. Lepchuk, M. Bibbo, D. Bagley—USA

**Background:** Fluorescence in situ hybridization (FISH) testing is gaining popularity in transitional cell carcinoma (TCC) screening. The purpose of this study is to determine the accuracy of FISH in identifying upper tract TCC (UTTCC).

**Methods:** Retrospective review of our UTTCC database from 2005–2008 identified 35 patients with an UTTCC who submitted voided urine specimens for FISH analysis (commercial laboratory) during a routine office visit. Each patient was evaluated endoscopically in the operating room within 3 months of these samples. Suspicious lesions were biopsied and treated. Presence of TCC in either lower or upper tracts was proven by either direct visualization, positive biopsy, or an upper tract cytology read as positive or highly suspicious for malignancy.

**Results:** 35 patients satisfied inclusion criteria. 67 total FISH specimens were submitted. UTTCC was identified in 51 operative evaluations and 23 of these had concurrent bladder tumor. The sensitivity of FISH for all encounters was 56% while the specificity was 80%. Sensitivity for low and high grade lesions was 68% and 67% respectively. 28 patients had only upper tract tumors. In this group there were 2 false positive and 13 false negative voided FISH examinations. The FISH sensitivity in these patients was 54% and specificity 78% compared to the sensitivity and specificity of bladder cytology, 18% and 100%. Sensitivity for low grade and high grade UTTCC was 60% and 50% respectively.

**Conclusion:** Voided FISH testing has become an adjunct for surveillance of bladder TCC, however, it may have limited value in upper tract tumor surveillance.

### MP5-16 INTERMEDIATE-TERM EFFICACY OF INTRA-URETERAL BCG AND INTERFERON-ALPHA 2B FOR UPPER TRACT UROTHELIAL CARCINOMA

L. Wang, J. Decastro, G. Hruba, J. Mckiernan, M. Benson, G. Mantu

**Background:** Treatment for urothelial cancer of the upper urinary tract can be challenging in patients unable to undergo definitive surgery because of bilateral disease, a solitary kidney, or significant comorbidities.

**Methods:** We retrospectively evaluated the results of 15 patients diagnosed with upper tract urothelial carcinoma who underwent intra-ureteral instillation of BCG and Interferon-alpha 2b (IFN-

a2b). Lesions were previously ablated endoscopically. Weekly intra-ureteral instillations were performed for an induction period of 6 weeks. Maintenance therapy was initiated in the case of non-recurrence. In the case of disease recurrence, lesions were either re-resected and patients underwent repeat induction therapy, or nephroureterectomy was performed.

**Results:** Of the 15 patients reviewed, five (33%) were considered non-operative candidates because of a solitary kidney and one (7%) due to bilateral disease. The remaining 9 patients either had low-risk disease and/or were considered to be poor surgical candidates due to comorbidities. Four patients (27%) had low-grade disease and 11 (73%) demonstrated high-grade features. Regarding clinical stage, seven patients (47%) had Ta disease, 3 (20%) T1, and 5 (33%) had CIS. A total of 16 renal units were treated with BCG/IFN. Mean follow-up was 29 months (range 3 to 107 months). Eight patients (53%) demonstrated a complete response to therapy following initial treatment with 3 to 107 months of follow-up, while another 3 patients (20%) had no evidence of disease after multiple treatments. Four patients (27%) had recurrent disease after a mean of 16 months from initial treatment—3 patients (20%) underwent nephroureterectomy at a mean of 28 months after initial treatment due to disease recurrence not amenable to endoscopic resection and one patient (7%) died of metastases 14 months after initial treatment. One patient underwent cystectomy with distal ureterectomy due to progression of bladder cancer. There was one treatment-related mortality due to BCG sepsis.

**Conclusion:** BCG-IFN treatment for upper tract urothelial carcinoma offers a reasonable therapy for patients who may be poor candidates for radical surgical, providing complete response in a subset. Delayed nephroureterectomy is feasible in cases where intra-ureteral therapy fails.

### MP5-17 OPEN VERSUS ROBOT-ASSISTED RADICAL CYSTECTOMY: COMPARISON OF EARLY OUTCOMES AND COST

J. Mandeville, S. Tsai, A. Sorcini, J. Libertino, D. Canes, A. Moinzadeh—USA

**Background:** Robot-assisted radical cystectomy (RARC) is an alternative for patients undergoing radical cystectomy. The relative financial burden has yet to be elucidated. We report a retrospective comparison of our early experience with robotic versus open radical cystectomy in terms of early perioperative outcomes and cost.

**Methods:** Following IRB approval, a retrospective review of medical and billing records was performed on 64 patients undergoing radical cystectomy (14 robotic, 43 open, 7 incomplete data) between November 2007 and March 2009. The majority of patients underwent concomitant ileal loop urinary diversion. Patients with prior pelvic irradiation who had undergone open surgery were excluded (n = 15). After matching for BMI, 13 robotic and 13 open cases were selected for analysis. Perioperative outcomes and early postoperative morbidity were compared. Early postoperative morbidity was defined as a complication occurring within 90 days of surgery, as classified by the Clavien morbidity grading system. Overall cost was calculated by factoring in OR time, instrument and robot costs, ICU care, and length of stay. Student's t-test, Mann-Whitney U-test, and Fisher's exact test were used for statistical analysis.

**Results:** Patients undergoing RARC were significantly younger than their open counterparts. The groups also differed significantly in disease extent, with extravesical extension confirmed on final

pathology in 5 open cystectomy patients versus none of the robotic patients. The robotic approach resulted in a reduction in median blood loss (200 mL vs 600 mL,  $p = 0.0004$ ) and higher mean lymph node yield (13.75 vs 7.1,  $p = 0.0057$ ). Mean operative time for RARC was longer (571 min vs. 423 min,  $p = 0.002$ ). Notably, there were 4 concomitant neobladders in the robotic group compared to zero in the open group. The direct cost associated with the robotic approach was significantly higher than the cost for open surgery (\$17,710 vs \$11,357,  $p = 0.017$ ). Characteristic Robotic (N = 13) Open (N = 13) P value Mean Age 64.4672.690.016 Mean BMI 27.6627.300.739% Male 69920.3217 ASA class 2-3 (%)100100 n/a Urinary Diversion Ileal conduit (n) 9130.0957 Neobladder (n) 40 TNM Stage: organ-confined (%) 10061.60.0391 Prior abdominal surgery (%) 15.3846.150.1159 Mean operative time (min) 5714230.002 Median EBL (mL) 2006000.0004 Transfusion rate (%)23.130.81 Mean node yield 13.757.10.0057 Positive margin (n)11 n/a Early morbidity (%) < Grade 384.761.50.2016  $\geq$  Grade 315.338.5 Mean hospital stay (days) 7.698.920.3346 Mean direct cost (\$)17,71011,3570.017.

**Conclusion:** Our small sample population reveals that the robotic approach affords increased nodal yield and decreased blood loss with comparable perioperative morbidity. The potential benefits of the robotic approach should be balanced against the elevated cost of robotic cystectomy.

#### MP5-18 COCULTURE OF BLADDER UROTHELIUM AND BLADDER ACELLULAR MATRIX SHEET

Y. Haichao, X. Hanbiao, T. Shengping—China

**Background:** Objective: To seed cultured porcine urothelium to selfmade bladder acellular matrix (BAM) sheet and to investigate the feasibility of construction of tissue engineered transplantable complex in vitro for urothelium rebuilding on neobladder with urothelium and BAM sheet.

**Methods:** Porcine bladder urothelium was isolated and cultured then implanted on the BAM sheet. Cocultured bladder urothelium and the BAM sheet into a tissue engineered transplantable complex with stratified cells. The configuration of the BAM sheet and cell adhesion and cell growth were evaluated by histological observation.

**Results:** BAM sheet could be prepared with integrate collagen structure. Good state of cell adhesion and cell growth could be observed during the coculture. Tissue engineered composite with stratified cells could be constructed.

**Conclusion:** Porcine bladder urothelium can be cultured successfully in this way. The BAM sheets had good biocompatibility with urothelium. Cell-scaffold complex for urinary bladder mucosa substitute can be constructed by coculture and has the potential to be used to rebuild the urothelium on neobladder.

#### MP5-19 NOTES APPROACH TO MANAGEMENT OF INADVERTENT SPLENIC, ENTERAL AND BLADDER INJURIES

S. Parekattil, Sijo j., C. Fyock, H. Atalah, L. Su, C. Forsmark, M. Wagh

**Background:** Visceral organ injury during Natural Orifice Transluminal Endoscopic Surgery (NOTES) can be life threaten-

ing. Conversion to standard laparoscopy or laparotomy is needed in these circumstances. This study presents the video technique of managing inadvertent intra-operative splenic, enteral and bladder injuries utilizing a NOTES approach in a porcine model.

**Methods:** 14 female pigs underwent either transgastric or transcolonic NOTES under general anesthesia. Lacerations of varying length were made in the spleen, small bowel and bladder. The injuries were managed as such: 1) endoscopic cautery for splenic lacerations, 2) endoscopic clips for enteral and bladder closure. Acute cases underwent immediate post-operative euthanasia and necropsy. Survival studies were performed in 4 animals. These pigs underwent euthanasia and necropsy one week after surgery per protocol. At necropsy, the peritoneal cavity and access sites were inspected for abscesses, bleeding or damage to surrounding structures. Leak test was performed to assess successful closure of the enterotomies.

**Results:** Successful management of the injuries was achieved in all cases. Survival animals had an uneventful post-operative course without any complications. Food intake and bowel movements were not compromised. At necropsy, all injury and access sites were well healed without evidence of necrosis, adhesions, abscess, bleeding or spillage of intestinal contents in the peritoneal cavity. There was no evidence of small bowel luminal obstruction.

**Conclusion:** Inadvertent splenic, enteral and bladder injuries can be managed in a NOTES approach using currently available endoscopes and accessories without the need for laparoscopy or laparotomy.

#### MP5-20 SOME EXPERIENCES OF LAPAROSCOPIC RADICAL CYSTECTOMY WITH ORTHOTOPIC STUDER NEOBLADDER

L. Ma, Y. Huang, X. Hou, G. Wang, L. Zhao, K. Hong

**Background:** To introduce our experiences of Laparoscopic radical cystectomy with orthotopic neobladder.

**Methods:** 42 patients were operated of Laparoscopic radical cystectomy with orthotopic Studer neobladder during July 2005 to June 2009 in our department. Our experiences: 1. Lymphadenectomy first. 2. During lymphadenectomy, find ureter which is in front of iliac vessels and Separate ureter to bladder. Using two HEMO-LOKs to shut ureter where adjacence bladder, and snip off the part of ureter which between the tow HEMO-LOKs. We can save time by cleaning Lymph node and Separating ureter at one time. 3. Infusing 100–150 ml saline into the neobladder after Studer neobladder sutured, then observe whether the saline leak out. 4. Using mucosa to mucosa interrupted suture of Ureteroneocystostomy can decrease complications. 5. In order to suture urethra and neobladder easier, we Use 2–0 absorbable Suture to pull the neobladder to the Catheter on the direction of 6 o'clock.

**Results:** 42 Laparoscopic operations were successful, blood loss was between 100–800 ml, operating time was between 5 h–7 h 45 min.

**Conclusion:** After being master of laparoscopic skills, there was little blood loss of Laparoscopic radical cystectomy with orthotopic neobladder, and operating time was no more than laparotomy.

## MP6: MIS—KIDNEY AND ADRENAL

### MP6-01 INITIAL EXPERIENCE WITH CRYOABLATION FOR RENAL ANGIOMYOLIPOMA

J. Sausville, K. Suson, H. Richard, M. Phelan

**Background:** Angiomyolipoma (AML) is a renal neoplasm that may cause pain or retroperitoneal hemorrhage. We report a pilot study of cryotherapy for AML.

**Methods:** 4 patients with radiographically diagnosed AML underwent percutaneous cryotherapy under computed tomography (CT) guidance. 1 patient underwent laparoscopic cryotherapy using a transperitoneal pure laparoscopic approach.

**Results:** There were no perioperative complications. The mean preoperative lesion size was 5.3 cm. All lesions for which follow up was available at a mean of 8.6 months had become smaller, with a postoperative average size of 4.4 cm. No patient has reported pain or suffered recurrent bleeding or a decrement in renal function.

**Conclusion:** For this small group of patients, cryotherapy appears to have been a safe and well tolerated modality for management of AML.

### MP6-02 USE OF RENAL TISSUE FOR THE INVESTIGATION OF TISSUE SPECIFIC PHARMOCDELIVERY SYSTEMS

J. Durbin, P. Oh, S. Stroup, J. L'esperance, B. Auge, J. Schnitzer

**Background:** Newer cancer treatment strategies are designed around the concept of tissue-specific delivery systems in order to overcome the vascular endothelial and epithelial barriers that limit the transport of drug and gene therapies in vivo. We sought to identify tumor-specific proteins that could provide a pathway to overcome the inherent cell barrier for gene and drug delivery.

**Methods:** In an IRB-approved human use protocol, 18 human kidneys were obtained from nephrectomy specimens. These kidneys were immediately prepared on a back table and then perfused with a suspension of cationic colloidal silica particles to coat the luminal endothelial cell plasma membranes exposed to the circulating blood. This coating created a stable pellicle that specifically marked the membrane, enhanced its density, and allowed for purification from total tissue homogenates (P) by centrifugation. Eighteen kidneys were adequately perfused and 1–2 grams of “normal” and tumor-containing tissue were obtained from each kidney.

**Results:** Final pathology of the kidney specimens revealed clear cell renal cell carcinoma with Furhman grades of 2–3 in all cases. Stained SDS-PAGE gels indicate upregulated distinct proteins in tumor P as well as in normal P consistent with what has been observed with our rat tumor model. Mass spectroscopy analysis also revealed an upregulation as well as downregulation of distinct specific proteins in both normal and tumor P consistent with observed gel analysis.

**Conclusion:** Therefore we believe that this systems biological approach will enable us to detect targetable proteins for gene and drug therapeutics.

### MP6-03 DURABLE ONCOLOGIC OUTCOMES FOLLOWING RADIOFREQUENCY ABLATION (RFA): EXPERIENCE FROM TREATING 243 SMALL RENAL MASSES OVER 7.5 YEARS

C. Tracy, J. Raman, C. Donnally, C. Trimmer, J. Cadeddu—USA

**Background:** Long-term oncologic outcomes for renal thermal ablation are limited. We present our experience with radiofrequency ablation (RFA) therapy for 243 small renal masses (SRMs) over the past 7.5 years.

**Methods:** Our prospectively maintained RFA database was reviewed to determine intermediate and long-term oncologic outcomes for patients with SRMs managed by RFA. Particular attention was placed on patients with a minimum of three years of follow-up.

**Results:** Two hundred-eight patients (with 243 SRMs) without evidence of prior ipsilateral renal cancer treatment underwent RFA and had follow-up imaging available for review. Overall, tumor size averaged 2.4 cm and follow-up ranged from 1.5 to 90 months (mean 27 months). Of the 227 tumors (93%) undergoing pre-ablation biopsy, RCC was confirmed in 79%, with no significant difference between the overall cohort and the subgroup of patients with >3 years of follow-up. Initial treatment success rate was 97%, with an overall 5-year recurrence-free survival rate of 93% (90% for the 160 patients with biopsy-proven RCC). Three patients developed metastatic disease and one patient died of RCC during follow-up, yielding 5-year metastasis-free and cancer-specific survival rates of 95% and 99%, respectively.

**Conclusion:** RFA provides successful treatment of small renal masses, with a low rate of recurrence following treatment and metastasis-free and cancer-specific survival rates similar to partial nephrectomy at five years. Though longer-term follow-up of RFA ablation is required to determine late recurrences, current results indicate a minimal risk of disease recurrence in patients who are more than three years removed from RFA.

### MP6-04 COMPARISON OF PERCUTANEOUS RADIOFREQUENCY AND CRYOABLATION FOR THE TREATMENT OF SMALL RENAL MASSES

K. Ebrahimi, P. Mahdavi, C. Tenggardjaja, L. Nicolay, J. Smith, D. Baldwin—USA

**Background:** Percutaneous ablative techniques are gaining acceptance for the treatment of small renal masses. Despite increased application of these techniques, no previous study has performed a comparison of percutaneous cryotherapy (cryo) with percutaneous radiofrequency ablation (RFA). The purpose of this study is to compare outcomes of percutaneous RFA and cryo for small renal masses when performed by a single surgical team.

**Methods:** A retrospective review was performed of 41 patients (21 male, 20 female; mean age 67 yr) with solitary renal masses < 4.0 cm. Patients were treated with either RFA or cryotherapy. 63% of patients underwent biopsy prior to ablation. Follow-up imaging was performed at 3 months post ablation and then at 3–6 month intervals.

**Results:** 41 patients underwent 41 ablations (22 RFA, 19 cryo). ASA score was similar between groups (cryo 2.2, RFA 2.1,  $p = 0.27$ ). Renal mass size ranged from 1.1–3.8 cm (mean: 2.3 cm RFA, 2.8 cm cryo,  $p = 0.01$ ). Pathology revealed renal cell carcinoma in 17 cases. Eight complications in 7 patients were identified including 2 with abdominal pain and laxity (cryo), 2 peripheral nerve paresthesias (cryo), 2 skin burns (RFA), 1 pulmonary embolus (2 wks post cryo), and 1 intra-procedural cardiac arrhythmia

(RFA). There has been no radiographic evidence of recurrence in either group.

**Conclusion:** RFA was associated with more skin burns and cryoablation was associated with more parasthesias. There was, however, no difference in treatment outcomes between techniques when the same surgical team administered both percutaneously.

### MP6-05 A PROSPECTIVE RANDOMIZED COMPARISON OF TRADITIONAL LESS TO NEEDLESCOPIC-ASSISTED LAPAROSCOPIC NEPHRECTOMY IN THE PORCINE MODEL

D. Baldwin, L. Nicolay, R. Bowman, N. Mehr, K. Ebrahimi, F. Jellison

**Background:** Laparoendoscopic Single-site Surgery (LESS) produces virtually no scar but is technically challenging due to the loss of triangulation. There have been no prospective comparison studies comparing LESS to other forms of minimally invasive surgery. The purpose of this study was to compare LESS with a modified scarless approach called Needleoscopic-assisted Laparoscopy (NAL) that restores triangulation for the performance of laparoscopic nephrectomy in the porcine model.

**Methods:** Ten female farm pigs were randomized to laparoscopic nephrectomy with LESS or NAL. In NAL, 5 and 10 mm ports were placed in the umbilicus and a 2 mm port was placed in the mid-clavicular line. With LESS a Triport was placed through a single 2.5 cm umbilical incision. Preoperative, perioperative, and post-operative parameters were compared. The Likert scale (1–10) was used to rate surgeon comfort and technical difficulty. Objective cosmesis (modified Vancouver Scar Scale) and subjective cosmesis (best overall appearance) were compared and a cost analysis performed.

**Results:** There was no difference in complications, blood loss, objective ( $p = 0.75$ ) or subjective cosmesis ( $p = 0.48$ ). In the NAL group, operative time was shorter (103 vs. 150 minutes,  $p = 0.008$ ) and both surgeon comfort (7.78 vs. 2,  $p = 0.003$ ) and ease (7.8 vs. 2  $p = 0.002$ ) was significantly better. NAL had significantly lower disposable cost (\$1195 vs. \$228,  $p \leq 0.01$ ).

**Conclusion:** NAL is safe and effective, enabling shorter operative times, increased surgeon comfort, technical ease and lower cost, while maintaining the scarless outcome of LESS.

### MP6-06 PERCUTANEOUS CRYOABLATION FOR LARGE RENAL MASSES

Z. Okhunov, J. Landman, B. Shingleton

**Background:** Herein we assessed the feasibility and efficacy of percutaneous cryoablation of renal masses greater than 3 cm.

**Methods:** Retrospective review of prospectively collected data of 19 patients with 21 renal masses 3 cm or greater was performed. Data including demographic, clinical and surgical characteristics, tumor parameters and renal function outcomes were collected and analyzed.

**Results:** Nineteen patients, 13 males (61.9%) and 8 females (38.1%) with 21 renal masses, were identified, with the mean age of 67 ( $\pm 9.5$ ). Mean tumor size was 3.4 cm (range 3–5 cm). Mean preoperative creatinine level was 1.35 ( $\pm 0.44$ ) mL. There were 10 (47.6%) left and 11 (52.4%) right side tumors. There was 1 patient (5.9%) with solitary kidney. There were 7 exophytic (33.3%), 1 endophytic (4.8%), and 2 mesophytic (9.5%) tumors. Additionally, there was 37% malignancy rate, 1 oncocytoma (5.3%), 26.3% nondiagnostic and biopsy wasn't performed in 6 patients (31.6%). There were no intra or post-operative complications. Only 1 flank

pain (4.8%) was documented. Mean hospital stay was 0.5 days (range 0–1). With a mean documented follow-up of 12.8 mos (range 1–26), the primary success rate was 90.5% and with 2 (9.5%) re-ablation procedures the success rate was 100% at 1 and 5 mos of follow-up.

**Conclusion:** Percutaneous cryoablation is technically feasible and safe method of treatment for selected renal masses greater or equal to 3 cm. Short term follow up is promising, however, longer follow-up required to evaluate functional and oncological efficacy of this new method.

### MP6-07 EVOLUTION OF SURGICAL THERAPY FOR RENAL MASSES: A

P. Sountoulides, M. Louie, D. Pick, A. Dash, E. Mcdougall, R. Clayman—CA

**Background:** The increasing application and the improved sensitivity of modern imaging modalities have led to a steep rise in the detection of small renal masses. Laparoscopy, combined with sophisticated imaging in the operating room and in the interventional radiology suite has dramatically changed the way renal masses are treated. This study reviews the evolving management of renal tumors at the University Of California, Irvine (UCI).

**Methods:** All cases of renal masses treated at our institution from 2002–2008 was retrospectively reviewed. The total numbers, the percentages of open and laparoscopic radical and partial nephrectomy, and cryoablative procedures for localized renal masses were compared for each year.

**Results:** Open surgery, both radical and partial nephrectomy, for renal masses declined over the past 7 years, from 22% to less than 2% of procedures by 2008. By 2008, over 95% of all nephron-sparing procedures were being done using less invasive techniques; approximately half of these cases were laparoscopic partial nephrectomies while the other half were renal cryoablations. With regard to cryoablation, CT guided percutaneous cryoablation; the latter accounted for over 50% of the cryoablation procedures performed in 2008. Table 1: Renal Surgery Performed for Localized Renal Masses by Year

YEAR	Open radical	partial	Lap radical	Lap partial	Cryo total	MIS total
2002	22.2%	2.2%	11.7%	3.1%	11.7%	23.9%
2003	16.6%	4.2%	11.7%	3.1%	11.7%	23.9%
2004	15.6%	5.4%	11.7%	3.1%	11.7%	23.9%
2005	18.5%	10.6%	11.7%	3.1%	11.7%	23.9%
2006	8.4%	10.6%	11.7%	3.1%	11.7%	23.9%
2007	4.1%	11.1%	11.7%	3.1%	11.7%	23.9%
2008	0.0%	9.2%	11.7%	3.1%	11.7%	23.9%

**Conclusion:** Two trends in the treatment of renal masses are evident: a) the era of open surgery for renal masses has largely ended at our institution, being largely reserved for those rare cases with a caval thrombus and b) a constantly increasing number of cases are performed using minimally invasive, image-guided ablative cryotherapy. The need for urologists to familiarize themselves with current imaging modalities for both diagnostic and therapeutic purposes can not be over-emphasized.

### MP6-08 LAPAROSCOPIC ADRENALECTOMY FOR PATIENTS WITH ALDOSTERONE-PRODUCING MICROADENOMA: PROPOSAL OF NEW CLASSIFICATION OF PRIMARY ALDOSTERONISM

S. Ishidoya, Y. Kawasaki, A. Ito, F. Satoh, T. Ishibashi, Y. Arai—Japan

**Background:** The Endocrine Society published Clinical Practice Guideline of primary aldosteronism (PA) in 2008. It recommended that the distinction between unilateral and bilateral adrenal disease be made by adrenal venous sampling (AVS) when surgical treatment is practicable. We performed 180 laparoscopic adrenalectomies for patients with PA according to the results of AVS and here propose a new classification for surgery.

**Methods:** A total of 180 patients with PA were retrospectively analyzed. All patients received MDCT and AVS with ACTH stimulation. Subsequently unilateral or bilateral laparoscopic adrenalectomy was carried out according not to the presence of adenoma but to the results of AVS.

**Results:** Among 180 PA patients, 114 showed a CT-detectable unilateral aldosterone-producing adenoma (APA: Type 1A; 63.3%) while 11 had marked bilateral APAs (Type 2B; 6.1%). Meanwhile, 52 showed CT-undetectable aldosterone-producing microadenoma (micro APA) associated with aldosterone-hypersecretion from unilateral (41 patients-22.8%: Type 2A) or bilateral (11 patients-6.1%: Type 2B) adrenal gland. Three patients (1.7%) proved idiopathic hyperaldosteronism (Type 3) after pathological examination. Laparoscopic unilateral adrenalectomy is applied for for Type 1A and 2A while bilateral adrenalectomy (total removal with contralateral partial resection) was performed for Type 1B and 2B. Majority of patients achieved normalization of plasma aldosterone concentration and improvement of hypertension after surgery.

**Conclusion:** It is reported that 3~10 % of patients with essential hypertension are virtually PA. We propose a new classification of PA according to the new concept, micro APA.

#### MP6-09 ADRENO-CORTICAL CANCER: OPEN OR LAPAROSCOPIC SURGERY?

C. Fiori, F. Porpiglia, F. Daffara, M. Terzolo, A. Angeli, R. Scarpa—Italy

**Background:** Adreno-cortical cancer (ACC) is a rare but extremely aggressive tumour and its treatment is still matter of debate. The aim of this study is to evaluate the role of laparoscopy in the treatment of ACC.

**Methods:** We retrospectively reviewed the database of our Center and we extracted the informations about patients with ACC undergone open (group A) and laparoscopic (group B) adrenalectomy. Exclusion criteria were: stage disease > III and patients undergone neo-adjuvant medical therapy. We considered: sex, age, size and weight of the lesion, Weiss score, ki 67 score, survival time.

**Results:** Group A consisted of 25 pts and group B consisted of 18 pts. The two groups were comparable in terms of age, sex, size and weight of lesion and Weiss score ( $p > 0.05$ ). Ki 67 score was significantly higher in the group B (11% vs 26%,  $p < 0.05$ ). During a mean follow up of 43 months 7 patients of group A and 1 pt of group B deceased. Log rank test did not reveal statistical significant difference between the two groups.

**Conclusion:** Our data suggest that laparoscopy does not impair oncological results of adrenalectomy in patients with ACC.

#### MP6-10 THE LONG-TERM SAFETY AND EFFICACY OF RADIOFREQUENCY ABLATION OF RENAL TUMOR INCLUDING 6 MONTHS FOLLOW UP BIOPSY

W. Cho, T. Kim, D. Kim, G. Sung, J. Chung—Korea

**Background:** To report long-term safety and efficacy of radio-frequency ablation for small renal tumor including 6 months follow up biopsy to ablated renal lesion.

**Methods:** A total of 50 patients underwent radiofrequency ablation of renal tumor between June 2004 to June 2009. 32 of combined Computed tomography (CT) and ultrasonogram-guided percutaneous RFA and 18 intraoperative ultrasonography-guided laparoscopic RFA were performed. Treatment indications were localized, small (<4 cm), solid renal mass in elderly patients and those with comorbid conditions and patients preference. For evaluation of recurrence or remnant tumor, renal biopsy was done at 6 months in 39 patients. The mean follow-up duration was 41.6 months (range, 6–60 months).

**Results:** All patients underwent successful RFA without any serious events. 6 patients had mild perinephric hematoma on follow-up CT scan and 4 patients had mild gross hematuria post-operatively. With a mean follow-up of 41.6 months, only 3 patients showed recurrence of renal mass and there were no patients with distant metastasis. 2 of 3 patients showed recurrence with 3 month follow up CT, 1 patient with 22 month. Repeat RFA was performed to these patients. We performed routine 6-month biopsy of RFA lesions to 39 of all patients. Only 2 patient showed remnant tumor, histologic diagnosis was chromophobe type and clear cell type. Re-RFA was done and rebiopsy was done after 6 months and showed no tumor. Distant metastasis was not found in any cases and all patients are alive on serial follow-up.

**Conclusion:** Percutaneous or laparoscopic RFA is considered useful treatment for selected patients with small renal mass, and for nephron-sparing. Contrast-enhanced CT/MRI performed serially after ablation was reliable to exclude residual viable tumor. The 6-month postoperative biopsy data of RFA lesion has proved the safety of RFA. The ultimate role of this modality will continue to evolve and warrant further studies.

#### MP6-11 ACTIVE SURVEILLANCE OF RENAL CORTICAL NEOPLASM

J. Rosales Araujo, J. Moreno, A. Perez-lanzac, J. Mckiernan, K. Badani, J. Landman

**Background:** We retrospectively evaluated our single center experience of patients with renal cortical neoplasms (RCN) who elected active surveillance (AS).

**Methods:** We evaluated our prospectively established urologic oncology database between January 1993 and January 2009 and identified a total of 223 RCN in 212 patients that were initially managed with AS. We described patient and tumor characteristics and assessed the differences between the patients who remained on AS and those who required intervention or had metastasis.

**Results:** The mean age was 71 at the time of the study (range 50–92) and 117 (56%) patients were male. The median Charlson comorbidity index was 3 (range 1–6) at diagnosis. The mean global tumor size (TS) at the time of entry into AS was 2.8 cm (range 0.5–13.7), and at the time of final assessment was 3.7 (range 0.9–14.1). Mean growth rate (GR) for the entire cohort was 0.34 cm/year (range –0.29–2.30). The mean follow-up was 35 months (range 6–137). Fifteen patients (7%) failure to AS, of those, 4 (2%) progressed to metastasis and 11 (5%) required intervention. When comparing patients who continued AS and those who underwent surgical intervention or made metastasis, there were statistical differences in initial, final and global TS and GR ( $p = 0.039$ ), ( $p = 0.001$ ), ( $p = 0.024$ ) and ( $p = 0.021$ ), respectively. There was



no correlation between initial TS and GR (Pearson's coefficient  $r = 0.006$ )

**Conclusion:** Active surveillance of renal cortical neoplasm in older patients with co-morbidities is a reasonable treatment option. With approximately 3-year follow-up, the anticipated failure rate is 7%.

### MP6-12 RATIONALE FOR A LESS AGGRESSIVE THERAPY FOR SMALL RENAL TUMORS

M. Tsivian, V. Mouraviev, M. Kimura, D. Albala, C. Robertson, T. Polascik—USA

**Background:** Currently, most renal masses are detected incidentally on imaging for unrelated problems. Small renal masses, amenable to nephron-sparing procedures are frequently encountered. We evaluated the influence of tumor size on pathological characteristics of the lesion to determine whether less aggressive treatment may be appropriate for smaller renal lesions.

**Methods:** We retrospectively reviewed medical records of patients who underwent a partial nephrectomy for a solitary enhancing lesion suspected to be renal cell carcinoma (RCC) between 2000–2008. Cases of known von Hippel Lindau syndrome were excluded from the analysis. Pathological features were analyzed and correlated to radiologically measured tumor size.

**Results:** We identified 243 records matching the criteria. Mean tumor size was 2.93 ( $\pm 1.60$ ) cm. Pathology reports showed RCC in 179 (73.7%) specimens, benign tumors in 45 (18.5%) and no tumor in 19 (7.8%). Benign tumors were found in 25.5% of lesions  $< 2$  cm and 16.5% of larger lesions. No tumor was found in 14.5% of  $< 2$  cm lesions and 5.9% of larger lesions ( $p = 0.021$ ). RCC was pathologically confirmed in only 60% of smaller kidney lesions. Moreover, pathologically confirmed RCC lesions  $< 2$  cm by imaging had a significantly lower mean Fuhrman grade (1.09 vs 1.4,  $p = 0.037$ ). There were no grade 3 and 1 grade 4 RCC among tumors  $< 2$  cm.

**Conclusion:** Among patients treated with partial nephrectomy, our experience reveals that solitary kidney lesions  $< 2$  cm suspected to be RCC are malignant by final pathology in only 60% of cases. Additionally, small sized RCC lesions are mostly low (1–2) grade. These findings suggest possible overtreatment of small suspicious lesions that may be adequately treated with less invasive modalities or even carefully followed.

### MP6-13 COMPLICATIONS AFTER LAPAROSCOPIC AND PERCUTANEOUS RENAL CRYOABLATION

V. Chen, M. Tsivian, D. Zilberman, R. Nelson, D. Albala, T. Polascik

**Background:** Laparoscopic (LCA) and percutaneous cryoablation (PCA) of small renal masses have gained popularity but only limited data exists on the complication rates. In this study we report on perioperative complications associated with LCA and PCA in a single tertiary center experience.

**Methods:** Retrospective review of electronic medical records was carried out for patients undergoing LCA or PCA between 2005–2009 at our institution with at least one month follow-up available. Demographics, radiographic variables and complication rates were compared between the two groups. Complications were classified according to the modified Clavien system.

**Results:** Of a total of 152 patients, 61 underwent LCA and 91 PCA. Caucasians accounted for 69% and 71% of LCA and PCA groups, respectively; males composed 62.3% of LCA and 64.8% of

PCA groups. Mean age was 65.2 and 62.0 years, respectively ( $p = 0.154$ ) and mean body mass index was 29.0 and 31.3 ( $p = 0.046$ ). We observed 6 (9.8%) LCA complications and 17 (18.7%) PCA complications ( $p = 0.169$ ). In the LCA group there were 3 grade I, 0 grade II, 2 grade III and 1 grade IV complications whereas in the PCA group there were 13 grade I, 1 grade II, 3 grade III and no grade IV complications. On multivariate regression analysis no factor was independently associated with perioperative complications.

**Conclusion:** LCA and PCA are not void of complications. Most of the complications encountered are mild, however severe (grade III–IV) events may occur in up to 4% of patients.

### MP6-14 EFFECTS OF THE RENAL COLLECTING SYSTEM ON MICROWAVE ABLATION OF RENAL TISSUE

N. Salas, C. Moore, J. Zaias, J. Shields, V. Bird, R. Leveillee—USA

**Background:** Thermal ablative therapy with cryotherapy and radiofrequency ablation is utilized for treatment of small renal masses. Microwave ablation (MWA) has recently been investigated for soft tissue destruction, yet clinical experience for renal masses is limited. This study was designed to evaluate the effectiveness of the microwave treatment modality in the porcine kidney in-vivo.

**Methods:** Six pigs were treated with the Evident Microwave Ablation System (EMAS) (Valleylab, Boulder, Co) with a 3.7 cm active tip percutaneous, water-cooled antenna. Three pigs were non-survival; three pigs were survived for 7 days. Microwave ablations were performed in the upper and lower poles of both kidneys at 45 W (Watts) for 3, 5 and 10 minutes. After necropsy the kidneys were harvested, ablation zones were measured, and histological analysis was performed.

**Results:** The ablated zones at each time interval were inconsistent. The gross appearance of the lesions in both groups was similar. The antenna tract was charred, the collecting system damaged, and there was asymmetry of the zones of ablation. Histological analysis revealed coagulative necrosis in the area of the ablation with sloughed and denuded urothelium.

**Conclusion:** MWA of the kidney yields inconsistent geometrical lesions when applied near the renal collecting system. Microwave energy may be preferentially absorbed by the increased water content in the collecting system and results in damage to the urothelium. Further study is needed to assess the attenuation of the microwave field in the kidney at different locations due to its heterogeneity and its long term effects on the collecting system.

### MP6-15 COMPARISON OF PERCUTANEOUS AND LAPAROSCOPIC RENAL CRYOABLATION FOR SMALL

Z. Okhunov, A. Pérez-lanzac de lorca, J. Rosales, K. Badani, B. Shingleton, J. Landman

**Background:** We reviewed our cryoablation experience and compared the risk of procedure-related complications and outcomes between laparoscopic (LCA) and percutaneous cryoablation (PCA) in the management of small renal cortical neoplasms (RCN).

**Methods:** A retrospective comparison of two institution databases was performed to assess perioperative and treatment outcomes in patients with small ( $< 3.5$  cm) RCN treated by LCA or PCA. Demographic, radiographic, peri- and post-operative complications and outcomes were stratified and analyzed by the type of surgery.

**Results:** Between July 2006 and December 2008, 73 patients underwent PCA for 85 lesions and 80 patients had LCA for 97 lesions. The mean length of hospitalization for PCA and LCA groups, was 0.1 days (range 0–2) and 1.5 (range 1–4), respectively ( $p=0.001$ ). PCA group had 8 complications (9.5%); LCA group had 4 complications; ( $p=0.02$ ); (Table 1). At a mean follow-up of 11 and 12 months respectively, there were 6 (7.1%) residual enhancements in PCA group and 2 (4.3%) in LCA group, respectively. The PCA required multiple ablations in 2 cases (2.4%), whereas, there were no incomplete ablations in the LCA group ( $p=0.2$ ). Pathology revealed renal cell carcinoma variants in 43.6% and 64.9% in PCA and LCA group tumors, respectively ( $p=0.03$ ). There were indeterminate biopsies in 32 (41.5%) and 11 (11.3%) in the PCA and LCA groups, respectively; ( $p=0.03$ ). In LCA group the higher blood loss was associated with tumor location; exophytic, endophytic, mesophytic and hilar tumors had 74 mL ( $\pm 88$ ), 70 mL ( $\pm 44$ ), 71 mL ( $\pm 50$ ) and 191 mL ( $\pm 112$ ), respectively ( $p=0.05$ ). Table 1. Demographic, clinical and tumor parameters, intraoperative and postoperative data PCA LCA

p = values	No. patients	73	80	total = 153
No. lesions	85	97	182	Mean age (years)
66.5 ( $\pm 9.5$ )	69 ( $\pm 11.5$ )	0.174	Gender (m/f)	50/35 (59.5%/40.5%)
65/32 (67%/33%)	0.353	PreOp Cre mg/dL	1.3 ( $\pm 0.5$ )	1.2 ( $\pm 0.5$ )
0.348	Mean tumor size	2.1 (range 1-3.5)	2.0 (0.7-3.5)	0.126
No. cryoprobes/tumor	2.8 ( $\pm 1$ )	2.7 ( $\pm 0.9$ )	0.740	Mean freeze time
20.3 ( $\pm 7.5$ )	6.2 ( $\pm 2.9$ )	< 0.001	Length of hospitalization	0.1 (0-2)
1.5 (1-4)	< 0.001	Complications	8 (9.5%)	Flank pain
5 (5.9%)	Fever	2 (2.4%)	Pneumothorax	1 (1.2%)
4 (4.1%)	Transfusions	3 (3.1%)	conversion	1 (1.0%)
0.02	Recurrences	6 (7.1%)	2 (2.1%)	0.149
Mean follow-up mos (range)	11.0 (1-34)	12 (1-44)	0.572	

**Conclusion:** At short-term follow-up, both LCA and PCA are similarly effective and safe treatments for small RCN, albeit sometimes PCA required multiple procedures. PCA seems more advantageous regarding hospital stay and complications. Long-term data for both procedures is required to confirm the long-term oncological efficacy.

### MP6-16 ACTIVE SURVEILLANCE OF RENAL CORTICAL NEOPLASM

J. Rosales Araujo, J. Moreno, A. Perez-lanzac, K. Badani, J. Mckiernan, J. Landman—USA

**Background:** We retrospectively evaluated our single center experience of patients with renal cortical neoplasms (RCN) who elected active surveillance (AS).

**Methods:** We evaluated our prospectively established urologic oncology database between January 1993 and January 2009 and identified a total of 223 RCN in 212 patients that were initially managed with AS. We described patient and tumor characteristics and assessed the differences between the patients who remained on AS and those who required intervention or had metastasis.

**Results:** The mean age was 71 at the time of the study (range 50–92) and 117 (56%) patients were male. The median Charlson comorbidity index was 3 (range 1–6) at diagnosis. The mean tumor size (TS) at the time of entry into AS was 2.8 cm (range 0.5–13.7) and at the time of final assessment was 3.7 (range 0.9–14.1). Mean growth rate (GR) for the entire cohort was 0.34 cm/year (range –0.29–2.30). The mean follow-up was 35 months (range 6–137). Fifteen patients (7%) failure to AS, of those, 4 (2%) progressed to metastasis and 11 (5%) required intervention. When comparing patients who continued AS and those who underwent

surgical intervention or made metastasis, there were statistical differences in initial, final and global TS and GR ( $p=0.039$ ), ( $p=0.001$ ), ( $p=0.024$ ) and ( $p=0.021$ ), respectively. There was no correlation between initial TS and GR (Pearson's coefficient  $r=0.006$ ).

**Conclusion:** Active surveillance of renal cortical neoplasm in older patients with co-morbidities is a reasonable treatment option. With approximately 3-year follow-up, the anticipated failure rate is 7%.

### MP6-17 THE USE OF SINGLE LUNG HIGH-FREQUENCY OSCILLATING VENTILATION DURING PERCUTANEOUS RENAL CRYOTHERAPY

R. Li, M. Louie, J. Rinehart, A. Wong, E. McDougall, R. Clayman

**Background:** High-frequency oscillating ventilation (HFOV) can be used when normal respiratory movement hinders the precision and success of the intervention. We present two cases where HFOV was used for single contralateral lung ventilation during upper pole percutaneous renal cryoablation.

**Methods:** Two patients, a 67 year old man with a 2 cm right upper pole renal mass, and a 74 year old woman with a left 2.9 cm upper pole renal mass were treated. Pre operative CT showed in both cases that the lower pleural edge was in close proximity to the proposed path of the cryoablation needle. Contralateral lung HFOV was done to isolate the ipsilateral lung and prevent pleural injury. In one case, a 5 F Yueh centesis needle was used to float the kidney away from adjacent structures. Three and four Galil Icerods<sup>®</sup> were used in the first and second patient, respectively, to cryoablate the renal lesions after biopsy and multi-temperature probes were used to verify a –20°C temperature and predict cell death.

**Results:** Both patients tolerated one-lung HFOV without complication. The renal lesions were frozen without pleural injury, and both patients were discharged home the following day.

**Conclusion:** At our institution, percutaneous renal cryoablation of renal masses is a cooperative effort by the anesthesiologist, urologist, and interventional radiologist. The use of techniques such as HFOV and single lung ventilation make it possible to treat lesions that would otherwise require laparoscopic or open surgical techniques.

### MP6-18 PER-OPERATIVE HISTOLOGICAL NEEDLE BIOPSIES OF SMALL RENAL TUMORS PERFORMING LAPAROSCOPIC ABLATIVE SURGERY

H. Van der zee, B. Lagerveld

**Background:** Currently, an increasing number of small renal masses (SMR) with a suspicion of malignancy is found, for which a laparoscopic thermo-ablative therapy as treatment option can be considered. Conform the literature a rate of up to 20% benign disease can be expected. A successful ablation is still defined by a persistent non-enhancing lesion which is declining in size in subsequent iv. contrast CT or MR imaging. A histological diagnosis is of importance for the mode of follow-up. However, We compared our data of laparoscopic cryoablation for SMR with the reported histological results of laparoscopic radiofrequency- and cryoablation.

**Methods:** From December 2006 up to April 2009 36 laparoscopic cryoablations for SRM were performed. Biopsies were taken with a Biopsy-gun loaded with a 16G needle. Depending on the macroscopical quality of the material, 3–4 biopsies were obtained for

every tumor. The biopsies were treated according to standard pathological procedures. Our results were compared to a Pubmed search of reported series of laparoscopic renal RFA or cryoablation between 2000 and today. Only series with more than 30 laparoscopically treated tumors were included.

**Results:** All 36 tumors were treated with cryoablation. In 35 cases peroperative biopsies were taken. One patient had a pre-operative biopsy elsewhere and was excluded. In all cases a histological diagnosis was obtained. In 30 patients a malignancy was proven. The five other cases were diagnosed as benign lesions, being 3 oncocytoma's, and 2 angiomyolipoma's. The malignant tumors revealed 20 clear cell carcinoma's, 5 papillary carcinoma's, and 1 chromofoob carcinoma. In 3 cases (10%) of the malignant tumors a subtype differentiation was not obtained. Histology results of laparoscopic cryoablation or RFA for SRM Cryo/RFA Malignant Benign non-conclusive Gill '04 (n=39) Cryo 79% 15% 6% Schwartz '06 (n=50) Cryo 59% 27% 14% Rukstali '06 (n=48) Cryo 79% 6% 15% Weld '07 (n=36) Cryo 61% 39% 0% van der Zee (n=35) Cryo 88% 12% 0% Kyle '08 (n=138) RFA 69% 25% 6%

**Conclusion:** Adequate histological diagnosis of SRM can be obtained by per-operative biopsies at the time of laparoscopic cryoablation. In the follow up the mode, frequency, and quantity of imaging is depending on the histological diagnosis. Therefore, a maximal rate of 20% of non-conclusive plus benign histology should be pursued.

#### MP6-19 INTERMEDIATE-TERM OUTCOMES OF RENAL CRYOABLATION: THE WASHINGTON UNIVERSITY EXPERIENCE

B. Benway, J. Landman, M. Gardner, C. Chen, S. Bhayani, R. Figenschau—USA

**Background:** Over the past decade, cryoablation has become established as a viable alternative to extirpative surgery for suspected renal malignancy. However, there remains a relative paucity of information regarding intermediate- and long-term functional and oncologic outcomes. We evaluated intermediate-term outcomes associated with renal cryoablation performed at Washington University.

**Methods:** A retrospective chart review was performed, evaluating 61 consecutive patients who underwent renal cryoablation at Washington University between 2002 and 2005.

**Results:** Mean age at treatment was 67 years. Mean tumor size was 2.5 cm, with most masses requiring 1–2 probes to cover the ablation zone. Cracking of the renal capsule was noted in 4 patients (6.6%); of these, 2 required postoperative transfusion. An additional 2 patients required transfusion, for a total transfusion rate of 6.6%. There was 1 incomplete treatment requiring repeat cryoablation at 4 months. At a mean follow-up of 51 months, the mean increase in serum creatinine was 0.17 mg/dL, which was not statistically significant ( $p=0.3$ ). There were 6 recurrences (9.8%)

requiring repeat ablation or extirpative surgery. Mean time to recurrence was 29 months.

**Conclusion:** Renal cryoablation appears to be a safe and effective technique for the treatment of renal masses amenable to nephron-sparing surgery, offering acceptable morbidity and excellent preservation of renal function. However, when counseling patients regarding management options, those considering cryoablation should be made aware of the approximately 10% incidence of repeat treatments that may be required. Further long-term evaluation of this technique is warranted.

#### MP6-20 ANALYSIS OF LOCAL RELAPSE AFTER LAPAROSCOPIC AND PERCUTANEOUS CRYOABLATION FOR RENAL TUMORS

M. Tsivian, B. Shingleton, V. Mouraviev, B. Wynia, J. Mayes, T. Polascik

**Background:** Diagnosis of local relapse after cryoablation remains a challenge for urologic oncologists. Current imaging techniques do not provide sufficient accuracy to early detect local recurrence early after cryoablation. We analyzed the timeframe to detect local relapse with imaging modalities (CT, MRI) based upon our two institutional experience with laparoscopic cryoablation (LCA) and percutaneous cryoablation (PCA).

**Methods:** Between January 2001 and August 2008, 123 patients underwent cryosurgical procedures for an organ-confined renal tumor(s). All patients had been carefully selected based on the following criteria: tumor size <3.5 cm for LCA, <5 cm for PCA, respectively; along with the absence of local and systemic spread on MRI or CT. Cryoablation was employed using third generation cryotechnology (Galil Medical, Plymouth Meeting, PA). Patients were followed by serial CT or MRI scan, creatinine level and physical examination at least every 3 months after PCA and 6 months after LCA.

**Results:** The mean patient age was  $66.1 \pm 9.6$  years in PCA versus  $64.4 \pm 9.6$  in the LCA group ( $p=0.35$ ). The median tumor size was 2.20 cm (range: 1–4.5 cm) in the PCA vs. 1.55 cm (range 1–3.5 cm) in the LCA group, ( $p=0.027$ ). The recurrence rate in the PCA group was 7 from 77 (9.1%) PCA procedures versus 3 of 54 (5.6%) LCA procedures ( $p=0.52$ ). The median time to failure was 3 months (range: 1–12) in the PCA group vs. 20 months (range: 6–48) for LCA ( $p=0.092$ ). With PCA 5 of 7 recurrences were identified within the first 3 months while all others were within the first 12 months. With LCA 2 of 3 recurrences in LCA group occurred in first 8 months and a third case was diagnosed at 48 months.

**Conclusion:** In our experience, 9 out of 10 recurrences occurred in the first 12 months. In light of these results, it could be prudent to recommend intensive early follow up imaging and if there is no evidence of recurrence by 12 months, then one could embark on a longer interval for imaging these patients.

## MP7: TRANSURETHRAL SURGERY

### MP7-01 TRANSURETHRAL RESECTION IN INTRAMURAL URETERAL STENOSIS TREATMENT

P. Geavlete, R. Multescu, D. Georgescu, B. Geavlete—Romania

**Background:** Endoscopic surgery increased the number of patients with stenosis of the ureteral orifice and intramural ureter. Our study aimed to review the cases with this pathology and evaluate the efficacy of transurethral resection in their surgical management.

**Methods:** Between January 1999 and January 2009, transurethral resection was performed in 48 cases with intramural ureteral stenosis. The intrinsic stenosis was secondary to TURB of urothelial tumors (33 cases), removal of intramural calculi (5 cases) or idiopathic (4 cases). In 6 female patients with advanced gynecological malignant tumors, we encountered extrinsic intramural ureteral stenosis. The mean follow-up period was 28 months (3 to 94 months).

**Results:** Achievement of a permeable upper urinary tract after transurethral resection of the narrowed or obliterated segment was achieved in 93.8% of the cases: in 97.5% of the patients with intrinsic stenosis and in 66.7% of the patients with extrinsic stenosis. A JJ stent was indwelled for 8 weeks in 88.9% of the cases. 84.4% of the patients had no hydronephrosis during the follow-up period. In 8.9% of the cases, the degree of hydronephrosis decreased, the renal scintigraphy showing no obstruction (residual hydronephrosis). Recurrence of the stenosis occurred in 6.7% of the cases after a period of 3 to 12 months.

**Conclusion:** Transurethral resection may be a safe and efficient treatment alternative in ureteral orifices' and intramural ureter's stenosis. The method has good stable result in the majority of cases, especially for intrinsic stenosis.

### MP7-02 SECOND TURB IN NON MUSCLE INVASIVE BLADDER CANCER—EXPERIENCE ON 400 CASES

P. Geavlete, D. Georgescu, B. Geavlete—Romania

**Background:** Even experienced urologists have a high percentage of persisting carcinoma after transurethral bladder tumor resection (TURB) for non-muscle invasive bladder tumors (NMIBT). The aim of our study was to quantify the percentage of residual tumors detected by re-TURB.

**Methods:** Between January 2005 and January 2009, 400 patients with NMIBT underwent re-TURB at 4–6 weeks after the initial resection. The indications were represented by absence of muscle tissue in the specimen from the initial resection, large, multiple, high grade or T1 tumors. After the first TURB, the pathologic stage was pTa in 102 patients (25.5%), pT1 in 288 (72%) and CIS in 10 (2.5%). The pathologic records of the second TUR were reviewed and compared with the findings of the first operation.

**Results:** Re-TURB was negative in 262 patients (65.5%). Of 102 patients with pTa and 288 patients with pT1 at the first TURB, 71 (69.6%) and 184 (63.9%) had a negative re-TUR, respectively. Three patients with initial CIS had residual tumors. Eighty-eight patients (22%) had residual tumors of the same stage, 28 (7%) had a lower stage and 22 (5.5%), a higher stage. In 85% of the cases, residual tumors were located at the initial site. The protocol treatment was changed in 26 cases (6.5%).

**Conclusion:** A routine re-TURB should be advised in selected patients with NMIBT in order to achieve a more complete tumor resection and to identify patients in which the treatment protocol should be changed. In addition, removal of residual cancer is achieved early.

### MP7-03 HAL FLUORESCENCE CYSTOSCOPY AND TURB: A BETTER CHANCE FOR PATIENTS WITH NON-MUSCLE INVASIVE BLADDER TUMORS?

B. Geavlete, R. Multescu, D. Georgescu, M. Jecu, P. Geavlete—Romania

**Background:** We aimed to evaluate the importance of hexaminolevulinate blue light cystoscopy (HAL-BLC) in cases of non-muscle invasive bladder tumors (NMIBT), to compare it with standard white light cystoscopy (WLC) and to establish the efficiency of blue light transurethral bladder resection (BL-TURB).

**Methods:** Between December 2007 and December 2008, WLC and HAL-BLC were performed in 70 cases. WL-TURB was performed for all lesions visible in WL, and BL-TURB for those only detected in BL. Patients diagnosed with NMIBT were followed-up after an average period of 5 months by WLC and HAL-BLC. The control group included the same number of consecutive cases of NMIBT, which underwent only WLC and WL-TURB, and the same follow-up protocol as the study group.

**Results:** The general detection rate was 68.8% for WLC, with a 9.4% rate of false-positive results, and 94% for HAL-BLC, with a 14.6% rate of false-positive results. The diagnostic accuracy was 57.3% for WLC and 95% for HAL-BLC in CIS lesions, and 68.8% for WLC and 94% for HAL-BLC in pTa tumors. After WL-TURB, fluorescent margins confirmed by pathology were discovered in 10.4% of the bladder cancer patients. 62 cases of the study group diagnosed with NMIBT emphasized a recurrence rate of 6.4% after 5 months. The control group described a recurrence rate of 24.2%. **Conclusion:** HAL-BLC is a valuable diagnostic method for patients with NMIBT, with considerably improved accuracy by comparison to WLC and a significant impact upon the short-term recurrence rate. BL-TURB provides a superior endoscopic treatment.

### MP7-04 PROSTATIC URETHRAL DIAMETER AS A POTENTIAL NON-INVASIVE MEASURE OF OBSTRUCTION: A COMPUTATIONAL FLUID DYNAMICS SIMULATION STUDY

Y. Siang Lin, H. Chin Tiong, L. Heow Pueh—Singapore

**Background:** Non-invasive techniques to detect bladder outlet obstruction (BOO) associated with benign prostatic hyperplasia have yet to be understood. This study aims to investigate the efficacy of prostatic urethral diameter (PUD) as a potential non-invasive measure of BOO using computational fluid dynamics (CFD) simulation.

**Methods:** CFD model comprising a bladder, prostatic urethral and urethra was developed. We define PUD as a relative reduction of cross sectional area compared to unobstructed urethra. The model simulates urinary flow velocities based on detrusor pressures (Pdet) ranging from 10 cmH<sub>2</sub>O to 100 cmH<sub>2</sub>O, mimicking low to high pressure voiding. The maximum flow rate (Q<sub>max</sub>) was calculated

by multiplying the maximum flow velocity through the mid-prostatic urethral and its cross-sectional area. A total of 50 simulations were conducted based on 5 sets of PUD size with 10 varying Pdet for each set.

**Results:** The distribution of Qmax and Pdet were plotted within the framework of International Continence Society nomogram. The maximum urinary flow rates are found to increase exponentially with Pdet. When the cross-sectional area is reduced by half, the reduction of flow is about 18%. Similarly, when the cross-sectional area is reduced by 72.5% and 82.5%, the flow rate is reduced by about 55% and 69% respectively. Worst, for a very constricted prostatic urethral where the cross-sectional area is reduced by 90%, the flow slowed down by 87%.

**Conclusion:** The reduction of PUD appears to aggravate the maximum flow rate at voiding stage. More importantly, our study has elucidated that PUD measurements may be a potential non-invasive assessment of BOO. Further clinical correlation is warranted.

#### MP7-05 BLADDER NECK STRICTURE AFTER TRANSURETHRAL PROSTATECTOMY (TURP) ASSESSMENT OF RISK FACTORS

R. Mahdavi Zafarghandi, D. Arab, M. Mahdavi Zafarghandi—Iran

**Background:** Bladder neck stricture (BNS) is an uncommon complication after TURP. The purpose of this study was to assess risk factors for the development of BNS after TURP.

**Methods:** Between 1996–2006, 985 patients undergone TURP by one surgeon 42 cases (4%) of BNS after TURP were identified and retrospectively were evaluated with attention on some parameter like. Resected weight of prostate, blood transfusion, resection time, catheter time, age, and diabetes. Factor analysed were IPSS and in this analysis we compared these factors in other cases without BNS after TURP.

**Results:** More than 75% cases with BNS underwent surgical treatment 5–14 months after TURP and 25% more than this time. Analysis show that resected weight of prostatic tissue is a significant factor for the developing BNS ( $P < 0.005$ ). The tissue resected per time was lower in BNS cases compare to cases without BNS ( $P < 0.002$ ). Others parameters like blood transfusion, Catheter time, age, blood transfusion were not significant in the developing of BNS.

**Conclusion:** Low weight of resected prostate for the developing BNS is significant risk factor. Prolonged operation time may also be important factor.

#### MP7-06 EXPERIENCE WITH A LONG-STANDING METALLIC STENT IN MANAGEMENT OF MALIGNANT URETERAL OBSTRUCTION A. D'ADESSI, M. RACIOPPI, F. PINTO, PF. BASSI DEPARTMENT OF UROLOGY. CATHOLIC UNIVERSITY SCHOOL OF MEDICINE, ROME, ITALY

A. D'addressi, M. Racioppi, F. Pinto, P. Bassi

**Background:** Patients suffering extrinsic ureteral obstruction by advanced malignancy have to be offered both quality of life and urinary tract patency. Currently both the nephrostomy and the internal stenting have negative impact in terms of body-image and infections, or encrustations and frequent changes, and costs.

**Methods:** Resonance® (Cook Medical) is a stent made by tightly coiled spiral metal wires, which can prevent tumor in-growth, with

an inner safety wire welded to both closed ends, and it is unfenestrated, thus necessitating a co-axial method of insertion. Made by a nonmagnetic nickel–cobalt–chromium–molybdenum alloy, it has high tensile strength, excellent resistance to corrosion, compatibility with a 1.5 T MRI scan, and it is approximately 25 times more resistant to occlusion as compared to the plastic stents. The stent is approved to remain in situ for 12 months, so offering significant benefit for patients and lowering of the costs.

**Results:** Five stents, 6 F, have been placed in a two months period in 5 women suffering from gynecological cancer with predicted life-expectancy of greater than twelve months. All procedures were performed with an anesthetic support. The max follow up is 3 months, long enough to observe that the introduction of the stent was easy under fluoro control; the incidence of irritative symptoms is comparable as when using a plastic stent; the renal function was always maintained; and pre-existing dilation of collecting system didn't change at monthly ultrasound scans.

**Conclusion:** The Resonance stent may allow patients with neoplastic ureteral obstruction to avoid the disfigurement and discomfort associated with a chronic nephrostomy or a conventional plastic sten and so it seems to be a useful and valid alternative for patients. Costs may also be considerably reduced.

#### MP7-07 FLUORESCENCE ENHANCED CYSTOSCOPY AND TRANSURETHRAL RESECTION OF BLADDER CANCER IMPROVE THE QUALITY OF RESECTION, ACCURACY OF STAGING AND PATIENTS CARE

G. Joachim, A. Makris, K. Durt, G. Jakse

**Background:** Fluorescence enhanced cystoscopy (FC) with 5 aminolevulinic acid (ALA) or HEXVIX® (HAL) has been increasingly used in the last few years in the diagnosis and transurethral resection of bladder tumors (TURBT). In this study we evaluated if ALA/HAL-FC improved the quality of resection, the accuracy of staging of bladder cancer and subsequently the choices of adjuvant therapy after transurethral resection thus improving patients care.

**Methods:** A total of 136 patients underwent ALA/HAL-FC and TURBT. 41 out of 136 patients were 2nd look TUR, 55 were for recurrent tumors and 40 were first time TURBT. The total number of tissue samples was 702; from these 120 were Ta tumors, 29 were T1 tumors, 53 CIS, 17 Dysplasia and 9 invasive tumors.

**Results:** Four of the 32 Patients (12%) who underwent 2nd look FC-TURBT had residual tumor or stage migration (3×pT1G3, 1×pT2G3), all 32 had FC enhanced TURBT as initial procedure. In 54 out of 136 Patients (39.7%) ALA/HAL-FC revealed tumors or CIS which were overlooked with conventional white light cystoscopy (WLC). 18 of the 120 Ta tumors (15%), 4 of the 29 pT1 tumors (13.7%) and 36 of the 53 CIS (67.9%) lesions were overlooked with WLC. FC-TURBT increases the overall sensitivity by 26%, especially in CIS and Dysplasia lesions by 50%. The treatment plan of 12 Patients (9%) was subsequently changed with the help of HAL-FC due to improved cancer staging.

**Conclusion:** ALA/HAL fluorescence enhanced cystoscopy and assisted TURBT not only improves the diagnostic accuracy of bladder cancer staging, especially in CIS, but also ensures complete resection at TUR thus improving quality of resection. As a result the therapeutic management plan may change in a considerable number of patients allowing to offer the most beneficial treatment for these patients without delay.

### MP7-08 OPTIMIZATION OF CONTINUOUS URETHRAL BLADDER IRRIGATION BY ADDITION OF EXTRA INFLOW THROUGH A SUPRAPUBIC CATHETER

R. Norman, L. Connor

**Background:** Continuous bladder irrigation (CBI) is often used to help manage hematuria and might be optimized by adding suprapubic inflow to increase urethral outflow. Our objective was to develop an experimental model that would reliably measure urethral outflow through a 3-way urethral catheter (UC) with and without the addition of suprapubic inflow using a variety of suprapubic catheters (SC) of different size combinations (Bard).

**Methods:** A 1 L IV bag (Hospira) was modified by inserting a 3-way UC into its outflow spigot and a 2-way SC into the front of the bag; different bags were used for each test. The urethral outflows for each size of UC were measured in various combinations of 18, 20, 22 and 24 F 3-way UC with and without added inflows from 12, 14 and 16 F 2-way SC. Water was used as the irrigant for both the urethral and suprapubic catheters and was drained by gravity from 3 L bags from a height of 140 cm. Urethral outflow was measured with a Dantec Urodyne 1000 uroflowmeter. Each run was done 5 times using outflows of at least 150 cc over at least 75 seconds and means were compared by paired t-test.

**Results:** Table shows mean outflow in cc/sec from the 3 way UC with its inflow alone and with the addition of SC inflow for a variety of catheter size combinations (\* means  $P < 0.01$  or better). Three way 18 F, 20 F and 22 F UC were unable to handle the extra inflow from a 16 F suprapubic catheter and the "bladder" became overly distended (OD). Catheter size Without and with 2-way 12 F inflow Without and with 2-way 14 F inflow Without and with 2-way 16 F inflow 3-way 18 F outflow 1.7 1.7 1.9 1.9 2.9 4.9\* (OD) 3-way 20 F outflow 3.2 3.6 2.9 4.1\* 4.1 5.0 (OD) 3-way 22 F outflow 3.3 4.2\* 3.6 5.0\* 5.0 5.8 (OD) 3-way 24 F outflow 5.6 5.8 2.7 6.3\* 3.1 9.0\*

**Conclusion:** Additional inflow from a 14 F or 16 F SC will maximally increase urethral outflow by at least 3.6 cc/sec only when combined with a 24 F 3 way UC.

### MP7-09 A COMPARATIVE STUDY OF URINE CYTOLOGY AND FLUORESCENCE IN SITU HYBRIDIZATION (FISH) FOR DETECTING UROTHELIAL CARCINOMA OF UPPER URINARY TRACT

W. Kim, H. Kim, J. Choi, S. Seo, S. Jeon, B. Jeong

**Background:** We prospectively compared the sensitivities and specificities between urine cytology and fluorescence in situ hybridization (FISH) for the detection of upper urinary tract urothelial carcinoma.

**Methods:** A total of 84 patients, including 39 with diagnosed upper tract urothelial carcinoma and 45 without evidence of malignancy. Both of urine cytology and FISH were checked by ureteroscopic irrigation. A mixture of fluorescent labeled probes to the centromeres of chromosomes 3, 7 and 17, and band 9p21 (p16) was used to assess urinary cells for chromosomal abnormalities indicative of malignancy. A positive result was defined as 4 or more urinary cells with gains of 2 or more chromosomes.

**Results:** The sensitivity of FISH and urine cytology for patient group was 79.5%, 59.0% ( $p = 0.021$ ), the specificity was 77.8%, 91.1% respectively ( $p = 0.058$ ). The sensitivity of FISH and urine cytology for pTa, pT1 group (20 cases) was 75.0%, 65.0%, for

pT2–pT4 (19 cases) was 84.2%, 52.6% respectively ( $p = 0.315$ ,  $p = 0.116$ ). The sensitivity of FISH and urine cytology for low grade (grade I, II) group (20 cases) was 70.0%, 60.0%, for high grade (grade III) group (19 cases) was 89.5%, 57.9% respectively. ( $p = 0.635$ ,  $p = 0.068$ ). The sensitivity of FISH and urine cytology for pelvis tumor (23 cases) was 87.0%, 43.5%, for ureter tumor (16 cases) was 68.8%, 81.3% respectively. ( $p = 0.003$ ,  $p = 0.315$ ).

**Conclusion:** The sensitivity of FISH for the detection of upper urinary tract urothelial carcinoma is superior to that of cytology, and the specificity of FISH and cytology for upper tract urothelial carcinoma are not significantly different. FISH was more sensitive than cytology for renal pelvis tumor. Further studies are required, but FISH has the potential to improve the diagnostic accuracy in upper urinary tract urothelial carcinoma especially in renal pelvis tumor.

### MP7-10 NARROW BAND IMAGING CYSTOSCOPY IMPROVES THE DIAGNOSTIC WORKUP FOR NON-MUSCLE INVASIVE BLADDER CANCER

E. Cauberg, S. Kloen, M. Visser, J. de la Rosette, M. Babjuk, T. De rejke—The Netherlands

**Background:** Objective was to determine whether narrow band imaging (NBI) cystoscopy improves the detection of non-muscle invasive bladder cancer (NMIBC) over white light imaging (WLI) cystoscopy.

**Methods:** We included 91 patients scheduled for transurethral resection of a bladder tumour (75) or bladder biopsies (16). All patients were first evaluated by WLI cystoscopy followed by NBI cystoscopy, using the same cystoscope. Both procedures were performed by different blinded surgeons who separately recorded all tumours and suspect areas on a bladder diagram. The lesions were then resected or biopsied under NBI guidance. Subsequently, tumours possibly left behind were resected under WLI. All specimens obtained were examined by histopathology.

**Results:** In 86 (94.5%) of the 91 patients we found one or more tumour(s)/suspect areas, with a total of 310 (201 urothelial carcinoma (UC), 77 benign, 13 dysplasia, 19 diagnosis lacking). Of the UC, 36 tumours (17.9%) (24pTa, 6pT1, 1pT2, 5pTis) within 25 patients were only seen by NBI and 4 (2.6%) tumours (1pTa, 1pT1, 2pTis) within 3 patients were only seen by WLI. The false positive detection rate of NBI and WLI was 33.4% and 27.9%, respectively. The mean (SD, range) number of UCs per patient identified by WLI was 1.8 (2.4, 0–15), versus 2.2 (2.7, 0–15) by NBI ( $z = -3.98$ ,  $p < 0.00$ ). In 5 patients NBI revealed a more extensive tumour field then estimated by WLI, whereas in 5 other patients the NBI image was suboptimal due to hematuria.

**Conclusion:** NBI cystoscopy, in addition to WLI cystoscopy, improves the detection of NMIBC and might lead to a more complete resection, thereby possibly resulting in less early tumour recurrences.

### MP7-11 TRANSURETHRAL HOLMIUM LASER LITHOTRIPSY IN THE TREATMENT OF VESICAL CALCULUS

J. Lu, C. Wang, Y. Hou, Q. Chen, J. Hu

**Background:** Vesical calculus is a common disease in urology. The small stones can be discharged without any treatments. If stones are big or complicated with bladder outlet obstruction, the

traditional treatment is mainly cystolithectomy. Transurethral Holmium laser lithotripsy has been used in the treatment of vesical calculus. We explore the clinical effect and safety of this therapy.

**Methods:** From December 2005 to March 2009, we treat 170 cases of vesical calculi with transurethral Holmium laser lithotripsy. Of the patients, 159 cases are male and 11 female. The ages ranged from 20 to 89 and the mean age is 67.1. There were 117 cases of calculi combined with BPH, and 7 cases combined with urethral stricture. There are 51 cases with single stone, 119 cases with multiple. The diameter of stones ranged from 0.5 cm to 5.5 cm. Ultrasound, KUB or IVP or cystourethroscopy have been taken in all patients. Versa Pulse Select Holmium lithotrite (Lumenis) and cystoscope or transurethral resectoscope (Olympus) was used. The cases combined with urethral stricture were performed with Holmium laser urethrostomy first. Then Holmium laser lithotripsy proceeded. Stones are crushed into ones whose diameters are less than 2 mm with direct view, and removed with Elick. Cases combined with BPH were performed TURP after lithotripsy. F18-20 Foley catheter was indwelt after the operation.

**Results:** Hemorrhage occurred in one case during lithotripsy and the operation was changed into cystolithectomy because of the poor view. No vesical perforation or hemorrhage occurred in all cases. The time for lithotripsy ranged from 10 to 120 min, and the mean time was 30.5 min. All cases are stone-free in one time, and the rate is 100%. Foley catheters were indwelt for one day in cases without BPH or urethral stricture. In cases which were performed TURP simultaneously Foley catheters were indwelt for 3–5 days and in cases performed Holmium laser urethrostomy were 1–3 weeks.

**Conclusion:** Transurethral Holmium laser lithotripsy has many advantages such as high success rate, little trauma, fewer bleeding, shorter recovery time and fewer complications. The cases complicated with BPH or urethral stricture can be solved simultaneously with this therapy. Treating vesical calculi with transurethral Holmium laser lithotripsy is safe and effective.

### MP7-12 RETROGRADE ENDOURETHROTOMY WITH HOLMIUM :YAG LASER FOR TREATMENT OF URETHRAL STRICTURES

Z. Wu, Q. Ding, H. Jiang, P. Gao, Y. Zhang—China

**Background:** To evaluate the efficacy and safety of retrograde endourethrotomy with holmium:YAG laser for treatment of urethral strictures.

**Methods:** 42 patients with urethral strictures (21 bulbar, 8 membranous, 7 combined, 6 prostatic) were treated with retrograde endourethrotomy using holmium:YAG laser in our hospital from June 2003 to May 2009. The stricture length range 0.8–3.2 cm (with a mean of 2.3 cm). The stricture was incised with holmium:YAG laser under direct vision at the 10-o'clock and 2-o'clock positions. After complete incision of the stricture area while confirming free passage of the 22F~24F dilator into the bladder, an indwelling 20F~22F urethral catheter was left in place for an average of 3.5 weeks (range 2~6 weeks).

**Results:** Retrograde endourethrotomy with holmium:YAG laser could be performed in all 42 patients. No gross hematuria and other serious complications were encountered during the procedures. 13 patients (31.0%) developed recurrent strictures that were treated by

second laser urethrotomy in 9 patients (23.1%), while 4 patients (9.5%) needed regular urethral dilatation. 4 patients (9.5%) with urethral stricture length >2.5 cm were performed 3rd laser urethrotomy, 2 of whom needed regular urethral dilatation after the procedure, and the other 2 were changed to open surgery. 7 patients (16.7%) had urinary tract infections postoperatively, and were managed successfully. No incontinence was observed.

**Conclusion:** Retrograde endourethrotomy with holmium:YAG laser is a safe, effective and minimally invasive therapeutic modality for patients with urethral stricture ( $\leq 2.5$  cm).

### MP7-13 INSTILLATION THERAPY AFTER ENDOSCOPIC TREATMENT OF UPPER URINARY TRACT TRANSITIONAL CELL CANCER VIA VESICO-URETERAL REFLUX?

G. Wendt-Nordahl, P. Honeck, T. Knoll

**Background:** Endoscopic treatment of superficial transitional cell carcinoma of the upper urinary tract offers an alternative to nephroureterectomy in selected cases. The postoperative instillation therapy (e.g. with mitomycin C) is postulated to reduce the recurrence rate. A proposed application mode is placing an ureteral stent after the procedure and instilling the substance in the bladder. Via a vesico-ureteral reflux (VUR) an effect in the upper urinary tract is postulated. Aim of our study was to determine the occurrence of a VUR after placement of an ureteral stent.

**Methods:** 12 consecutive patients receiving an ureteral stent after ureterorenoscopic stone treatment were instilled with 50 ml of contrast agent in the empty bladder. After radiologic check for a VUR, additional 200 ml were instilled and another radiologic check for VUR was performed. The same experiment was repeated on postoperative day one.

**Results:** None of the patients displayed a VUR after the instillation of 50 ml contrast agent. After instilling 250 ml a VUR could be observed in 6/12 patients. The results were confirmed in the experiments performed one day later.

**Conclusion:** Despite the placement of an ureteral stent, instillation of volumes under 50 ml did not lead to a VUR. Therefore, the instillation therapy of volumes <50 ml does not seem effective. Dilution to 250 ml leads to a reflux in 50% of the patients. However, the effect of such a diluted instillation therapy is not known.

### MP7-14 VIRTUAL TRANSURETHRAL RESECTION (TUR) OF THE BLADDER TRAINING FOR NOVICE UROLOGISTS

S. Kruck, J. Bedke, S. David, C. Schwentner, A. Stenzl, K. Sievert

**Background:** Virtual-reality based simulation opens up new fields in training and education. "flight simulators for surgeons" potentially shorten the learning curve for surgical skills, particularly for junior trainees. The STORZ® "URO-Trainer" allows realistic transurethral resections of the bladder (TURBT) associated with satisfying visual simulations and haptic sensations. The aim of this study was to validate the use of a virtual reality trainer for TURBT.

**Methods:** Novice endoscopists: 5 residents and 5 medical students were assessed on their ability to perform virtual cystoscopy and TURBT. They completed five standardized 5-minute resection

scenarios. Additionally 5 TUR-experienced residents performed 5 (5 minute) resections with fluorescence (PDD) and white light (WLC) guidance.

**Results:** Experienced residents (n=5) showed superior inspection (51% vs. 49.8%; P=0.08) and resection rates (55.6% vs. 37.8%; P=0.08) with PDD. Computer-recorded scores showed positive training effects for residents and experienced urologists. Among beginners virtual inspected area increased during training sessions (TS) from 46.5% to 62.9% (P=0.13). Significant improvements were noted for resection rates from 30.2% to 58.4% (P=0.0028). Bleeding was reduced from 92.0 ml to 58.2 ml (P=0.097).

**Conclusion:** This study supports the need for simulator-based education programs. Virtual-reality and PDD based training can help to improve tumor recognition and resection. Further investigations will determine when residents should start to perform initial patient surgery in order to ensure complete resection and reduce morbidity.

#### **MP7-15 FLUORESCENCE CYSTOSCOPY WITH HEXAMINOLEVULINATE IN BLADDER CANCER: OUR EXPERIENCE**

P. Massimiliano, C. Cracco, C. Scoffone, M. Cossu, S. Grande, R. Scarpa

**Background:** Fluorescence cystoscopy (FC) with hexaminolevulinatate (HAL) is a new technique of photodynamic diagnosis (PDD), with the potential to significantly improve bladder cancer detection, compared to standard white light cystoscopy (WLC). We present our experience using combined WC and HAL-FC for diagnosis and follow up of bladder tumors.

**Methods:** From September 2007 to March 2009 we submitted 63 patients (47 males and 16 females, range of age 35-83 years) with suspect first diagnosis of bladder cancer, or in follow up for previous superficial bladder cancer, to combined WLC and HAL-FC. One hour before the procedure we administered intravesically HAL 85 mg diluted in PBS 50 ml. We performed a traditional rigid WLC, followed by FC with blue light. We performed bioptic resection of all suspect lesions (82 biopsies) detected in white or blue light. In 9 cases simple FC without biopsies was carried out (negative WLC/HAL-FC); finally we performed 91 procedures.

**Results:** WLC detected 51 (56%) suspect lesions and 40 negative (44%), while FC detected 72 (79%) suspect lesions and 19 negative (21%). WLC found 32 cancer/dysplasia, while FC 46 cancer/dysplasia (+6 Cis). The diagnostic gain of bladder cancer with HAL-FC was about 19.4% more than with WLC alone. Among the 46 WLC+/FC+ lesions, 45.7% were neoplastic, 23.9% dysplasia and 30.4% flogosis. The patients WLC-/FC+ were 26: 27% neoplastic, 27% dysplasia and 46% flogosis. The patients WLC+/FC- were 5, all negative for tumours. 14 patients were WLC-/FC- (mapping negative for tumor).

**Conclusion:** Fluorescence cystoscopy with hexaminolevulinatate is well tolerated, and is a useful adjunct to white light cystoscopy, improving its sensitivity. In fact, false positive slightly increased in the FC group (FC: 20% vs WLC: 28%), but the FC diagnostic gain is relevant (about 20%). Better therapeutic outcomes are expected at long term follow up, due to more complete transurethral bladder resections and correct histological responses.

#### **MP7-16 A RANDOMISED SINGLE-BLIND COMPARISON OF THE EFFECTIVENESS OF THE HIGH-LEVEL DISINFECTANTS TRISTEL FUSION (CHLORINE DIOXIDE) AND CIDEX OPA (ORTHO-PHTHALDEHYDE) FOR USE WITH FLEXIBLE CYSTOSCOPES: RATIONALE AND STUDY DESIGN**

P. Gilling, R. Reuther, M. Fraundorfer, C. Frampton, M. Lockhart, M. Addidle

**Background:** The objectives of this study are to compare the effectiveness of Tristel as compared with Cidex on clinical and microbiological efficacy, safety, cost-effectiveness and ease-of-use. Chlorine Dioxide is a non-toxic high-level disinfectant which does not require an automated reprocessor and is therefore suitable for the urologists office.

**Methods:** A sample size of 80 patients completing each study arm (160 in total) was estimated on the basis of showing a non-inferiority (not more than 10% worse) of Tristel Fusion compared with Cidex OPA with regards to the incidence of MSU detected UTIs. Clinical Endpoints include, urethra/bladder irritation and quality of life 3-7 days post-cystoscopy compared with baseline using the following questionnaires: UDI-6, AUA-7, Single Question Quality of Life Score (QoL). Microbiology Endpoints: Mid-stream urine (MSU) will be obtained from study participants prior to flexible cystoscopy and 3-5 days after the procedure. The following equipment samples will be collected after every 5th disinfection: Culture of washings and brushings from the flexible cystoscopes working channel. Culture of samples from the AER (lid, rinsing solution and entry and exit ports), Tristel inner tray and exit port. Ethics committee approval was obtained.

**Results:** The primary endpoint is the rate of acquired urinary tract infections as determined by a mid-stream urine test (MSU) 3-7 days post intervention in the patients undergoing flexible cystoscopy when the cystoscope is disinfected with Tristel Fusion compared with Cidex OPA.

**Conclusion:** If equivalent in efficacy, the ease-of-use of Tristel Fusion will provide an important alternative to other available liquid sterilants for use with flexible endoscopes.

#### **MP7-17 FOLLOW-UP EVALUATION OF A GENITOURINARY SKILLS TRAINING CURRICULUM FOR MEDICAL STUDENTS**

A. Kaplan, S. Kolla, P. Sountoulidis, O. Kaufmann, R. Clayman, E. Mcdougall

**Background:** The proper training of the basic genitourinary (GU) examination and bladder catheterization is of paramount importance to the burgeoning physician. We developed an intensive GU skills training curriculum for medical students (MS) and performed a 6-month follow-up study of MS comfort with and utilization of these skills.

**Methods:** Ninety-three final second year medical students (MS3) participated in the curriculum 1 month prior to beginning their clinical clerkship year. The curriculum consisted of a 1 hour didactic and questions and answers (Q&A) session regarding testicular exam (TE), rectal exam (RE), male Foley catheter (MFC) and female Foley catheter (FFC) placement. The following day, the MS3 underwent standardized patient (SP) TE and RE training with urology faculty, model based MFC and FFC placement training, VR cystourethroscopy and faculty directed small group Q&A tutorial. Six months following the course, MS3 were asked by



questionnaire to rate their comfort with each skill on a 6 point Likert scale (0–5), describe the reasons for any discomfort, and describe how often these skills were used. These results were compared to precourse questionnaire as well as results of the same questionnaire given to current 4th year students (MS4) who had not undergone the curriculum.

**Results:** Sixty-eight MS3 at 6 month follow-up, and 44 MS4, responded to the questionnaire. They reported comfort-level (Likert scale 3–5) in the following distribution: GU SkillMS3, Pre-GUSTMS3, Immediately Post-GUSTMS3, 6 months Post-GUSTMS4, No-GUSTTesticular Exam13% (12/91)93% (81/87)69% (47/68)55% (24/44)Digital Rectal Exam11% (10/91)92% (83/90)74% (50/68)80% (35/44)Female Foley Catheter10% (9/91)86% (77/90)72% (49/68)89% (39/44)Male Foley Catheter7% (6/91)86% (78/91)72% (49/68)86% (38/44)MS4 were most likely to learn their exam skills from Faculty and Foley catheter placement from nursing staff. Eleven percent of MS4 never formally learned to do a TE or DRE. MS3 and MS4 performed TE on 5.5% and 4.3% of patients during the months prior to questioning, respectively, and performed DRE on 6.2% and 7.2% of patients, respectively.

**Conclusion:** A dedicated GU skills training curriculum significantly improved MS comfort with performing these procedures. However, due to an unacceptable frequency of using these skills clinically this comfort declined significantly during clerkship. Attention must be directed to better application of the GU skills clinically during clerkship. Testing of GU skill proficiency in curriculum trained MS4 is being done now.

### MP7-18 COMPARISON OF RE-RESECTION RATES FOR NEW G3PT1 BLADDER CANCER, IN PATIENTS RANDOMISED TO INITIAL BLUE LIGHT OR WHITE LIGHT RESECTION: 1 YEAR FOLLOW UP DATA

D. Wilby, B. Chappell, E. Ray, K. Chatterton, T. O'brien

**Background:** Guidelines recommend early re-resection of high grade non-muscle invasive bladder tumours both to improve staging and maximize tumour clearance. However PDD-assisted initial resection may be more complete making re-resection less necessary.

**Methods:** A prospective analysis of the results of white light re-resections of newly presenting T1G3 tumours identified in 200 patients managed in a randomised trial of PDD versus white light since April 2005. Re-resection was offered on a case-by-case basis and was considered mandatory when muscle was not present.

**Results:** Thirty-nine out of two hundred (19.5%) tumours were initially staged T1G3. In the PDD arm 4/21 (19%) patients underwent early re-resection: no patient had residual disease. In the white-light arm 12/18 (66%) underwent re-resection: 3/12 (25%) had residual disease (2×T1G3; 1×upstaged to G3T2). At one year, one patient in the PDD arm progressed to muscle invasive disease, in the white-light group 6 patients developed muscle invasive disease.

**Conclusion:** This pilot study suggests that a PDD-assisted first resection of new G3pT1 tumour may be so complete as to have the potential to reduce the need for early re-resection. Re-resection clearly remains mandatory if there is doubt about tumour stage, or suspicion of incomplete resection.

### MP7-19 THE USE OF KTP LASER FOR ABLATION OF SMALL, SUPERFICIAL TRANSITIONAL CELL CARCINOMA OF BLADDER IN OUTPATIENT, OFFICE SETTING

M. Siddiqui, J. Grocela, W. Mcdougal, K. Alvi, S. Psutka, S. Tabatabaei

**Background:** Non-invasive, low grade transitional cell carcinoma (TCC) of bladder comprises the majority of bladder cancers. Although this type of bladder cancer has a low potential for invasion, it does recur and progress. We review the use of KTP laser ablation for small, superficial TCC of bladder, as an outpatient, office-based procedure.

**Methods:** From September 2006 to June 2009, 118 patients with a known history of superficial bladder TCC were treated. Patients were between 32 and 98 years old and 48 were females. End fire, 600 micron, laser fiber with 15 watts KTP laser generator was used. Using flexible cystoscopy, and under local anesthesia via urethral lidocaine gel instillation, KTP laser tumor ablation was performed. Average settings were Energy: 1–10 Watts and Total Power: 17 to 4816 Joules. Patients were discharged the same day following void trial.

**Results:** Average follow-up is 9.6 months. Tolerance of the procedure was 97.7%. Overall, 79% of our cohort has had successful treatment defined by at least one follow-up normal cystoscopy. Of these patients, 91% of patients were tumor free using outpatient KTP laser treatments alone (average 1.6 treatments). The additional 9% of patients required TURBT in the OR. Tumor recurred in 21% of patients after an average of 180 days. Multiple tumors were treated in 53% of cystoscopies. The treatment showed greater success for grade 1 TCC (83%) however still demonstrated 56.5% efficacy in treating grade 3 superficial disease using KTP laser alone.

**Conclusion:** Office-based KTP laser ablation may be used on small, superficial, recurrent bladder tumors with greatest efficacy in low grade disease. Because of ablative nature of the procedure and lack of pathology specimen, we suggest reserving this procedure for recurrent, superficial appearing bladder TCCs.

### MP7-20 A NOVEL TECHNIQUE FOR UPPER TRACT HEXYLAMINOLAEVULINATE BLUE LIGHT FLUORESCENCE FACILITATES UPPER TRACT CIS DIAGNOSIS

E. Havranek, D. Hrouda, J. Ramsay, A. Shamsuddin—United Kingdom

**Background:** Persistently positive ureteric urine cytology despite negative conventional investigations remains a diagnostic dilemma. The reliability of ureterorenoscopy and biopsy in the diagnosis of upper tract CIS is uncertain. Hexylaminolaevulinate 'blue light' fluorescence improves the detection of bladder tumors, including carcinoma in situ, compared with standard white-light cystoscopy. We carried out a preliminary evaluation of this technology in upper tract diagnosis.

**Methods:** Patients with positive urine cytology from ureteric washings but normal further investigations including multiple random bladder biopsies and negative white light flexible ureterorenoscopies were recruited. Hexvix<sup>®</sup> was instilled into a closed system created by the use of a ureteric access sheath for 30 minutes prior to renoscopy using a flexible renoscope with blue filter (Storz Flex-X2 with blue filter). All fluorescent areas and random non-fluorescent areas were biopsied including areas adjacent to fluorescent areas.

**Results:** 5/7 fluorescent area biopsies showed CIS, severe dysplasia or nuclear atypia. Two biopsies were insufficient for diagnosis. All random biopsies from non-fluorescent areas showed normal urothelium.

**Conclusion:** Upper tract CIS remains difficult to diagnose. Our pilot study shows the feasibility of using 'blue light' fluorescence

to maximise diagnostic yield. This approach aids targeting biopsies and could help with in-situ laser or diathermy. Although this technology is expensive, we believe it warrants further investigation. Its availability within Cancer Networks should facilitate diagnosis and treatment and may help decrease the need for nephroureterectomies.

## MP8: URETERORENOSCOPY

### MP8-01 FLEXIBLE RETROGRADE URETEROSCOPY/HOLMIUM LASER LITHOTRIpsy FOR THE TREATMENT OF RENAL STONES MEASURING 2-3 CM: A MULTI-INSTITUTIONAL EXPERIENCE

E. Hyams, J. Uberoi, R. Munver, O. Shah—USA

**Background:** Percutaneous nephrostolithotomy (PNL) is the standard of care for treatment of large renal stones (>2 cm). Flexible retrograde ureteroscopy/Holmium laser lithotripsy (URS) has been evaluated as an alternative for patients with contraindication to or preference against PNL. We report a multi-institutional series of URS for renal stones in an intermediate size range (2–3 cm).

**Methods:** Patients undergoing URS for 2–3 cm renal stones were identified retrospectively at two tertiary care centers. Demographic, perioperative, and postoperative information was gathered from hospital and office charts.

**Results:** Seventy patients underwent URS for 2–3 cm renal stones (2004–2009). Mean age was 57.5 years (range 22–83) and mean BMI was 29.2 kg/m<sup>2</sup> (20–49). Mean stone burden (maximal diameter) was 2.3 cm. Documented reasons for URS vs. PNL included patient comorbidities (17), anatomic factors (4), patient habitus (3), solitary kidney (3), and patient preference (44). Thirteen patients (18.5%) were pre-stented. Sixty one patients (87%) were treated as outpatients. Ureteral access sheath was utilized in 50 cases (71%). Mean operative time was 81 minutes (44–124). Nine patients underwent multi-stage procedures (12.8%). There were no intraoperative and 7 postoperative complications (10%) during mean 10.5 months (1–54) follow-up, including ipsilateral obstruction requiring repeat URS (3), urinary tract infection requiring admission (2), subcapsular hematoma (1), and ureteral perforation/extravasation (1). Forty patients had residual fragments on follow-up imaging 0–2 mm (57%), and 59 patients had residual fragments <4 mm (84%).

**Conclusion:** URS is safe and effective for treatment of renal stones measuring 2–3 cm. Although PNL achieves superior stone clearance, URS is an acceptable treatment option for certain patients based on medical and individual factors.

### MP8-02 THE DIFFICULT URETER: WHAT IS THE INCIDENCE OF PRE-STENTING?

R. Cetti, S. Keoghane—UK

**Background:** Retrograde access for rigid and flexible ureteroscopy (URS) may be difficult due to anatomic abnormalities, a narrow ureteric lumen, or previous instrumentation. Dilatation using a balloon or tapered dilator can occasionally fail and will

usually lead to the placement of a ureteric stent. We present our experience and incidence of pre-stenting after failed standard access and dilatation techniques, the aim being to quote a figure for the patient at the time of consent.

**Methods:** Data were collected prospectively from a single surgeon at a regional tertiary referral stone unit. Between Dec 2007 and Dec 2008, a total of 120 patients, mean age 49, underwent flexible or rigid URS.

**Results:** Of the 120 patients, 108 cases were undertaken for urolithiasis and 12 cases for diagnosis of upper tract malignancy. 12% (13/108) of cases were for on going pain and borderline imaging. 8.3% (09/108) of patients were pre-stented because of failed access, without complication, and subsequently had successful interval treatment. Of the remaining cases, 33% (28/84) and 77% (56/84) were undertaken for ureteric and renal calculi respectively. Stone clearance rate was 100% (13/13) for solitary lower pole calculi 5.0-10 mm in size. Total clearance rate for lower pole calculi was 81% (22/27). (Table: Percentage stone clearance rates for patients treated with URS in regards to stone size, site and number.)

	Distal Ureter (%)	Mid Ureter (%)	Proximal Ureter (%)	Renal Pelvis (%)	Lower Pole (%)	Mid Pole (%)	Upper Pole (%)
5.0-10 mm(solitary)	92(11/12)	100(3/3)	89(8/9)	60(6/10)	100(13/13)	100(1/1)	100(1/1)
> 10 mm(solitary)	0(0/1)	50(1/2)	75(3/4)	5.0-10 mm(multiple)	100(1/1)	100(1/1)	60(6/10)
> 10 mm(multiple)	0(0/1)	17(1/6)	0(0/1)	0(0/1)			

**Conclusion:** The incidence of ureteric pre-stenting in a tertiary referral unit was 8% and should be considered and indeed discussed with patients when obtaining consent, especially for purely elective, non-urgent, upper tract cases. The alternative for these difficult, tight ureters is extensive balloon dilatation, with the risk of trauma and the potential for long term stricture formation.

### MP8-03 URETEROSCOPY AND LITHOTRIpsy OF URETERAL CALCULI: STENTED VS. NON-STENTED, A RANDOMIZED CLINICAL TRIAL(PRELIMINARY REPORT)

M. Hosseini, K. Tamaddon, A. Aminsharifi, A. Aryafar, A. Yousefi, A. Hassanpour—Iran

**Background:** To evaluate and compare the safety, efficacy and complication of stented and non-stented, uncomplicated ureteroscopy and lithotripsy of ureteral calculi ≤ 10 mm.

**Methods:** Thirty-nine patients, 25 male, 14 female, 20–54 years old (32.6), with mid/distal ureteral calculi measuring 10 mm or less, assigned randomly in 2 groups: A, Stented and B, Non-stented. We recorded and compared post-op pain, LUTS, fever, analgesic requirement, and stone-free rate.

**Results:** twenty patient were stented with ureteral stent Fr. 5 which extriorized from urethra and sent into lumen of the urethral Foley catheter. 19 patients only had Foley catheter. Catheters removed the day after operation and the patients followed for 3 days. Stone-free rate (KUB) and fever were almost equal, but pain, LUTS and analgesic requirement was higher in stented group.

**Conclusion:** It seems that outcome of stented and non-stented ureteroscopy and lithotripsy in uncomplicated situations are same, therefore, no need for postoperative stenting, unless in complicated cases.

#### **MP8-04 COMPARISON OF A REDUCED AND STANDARD FLUOROSCOPIC PROTOCOL DURING URETEROSCOPIC LITHOTRIPSY**

G. Agarwal, D. Greene, C. Tenggardjaja, R. Bowman, K. Ebrahimi, D. Baldwin—USA

**Background:** Although the long term effects of radiation exposure are not completely understood, the lowest possible radiation dose “As Low as Reasonably Achievable” (ALARA) should be used. The purpose of this study was to compare fluoroscopy times before and after the implementation of a protocol designed to reduce radiation exposure during ureteroscopic lithotripsy.

**Methods:** A retrospective review was conducted of 299 consecutive stone patients in a single institution from January 2007 to June 2009. Patients undergoing simple ureteroscopy without ancillary procedures or balloon dilation were specifically studied to determine the effect of a reduced fluoroscopy protocol implemented in January of 2009. The protocol included many measures including a laser-guided C-arm, designated fluoroscopy technician and substitution of visual for fluoroscopic cues. Fluoroscopy times were compared between groups using a paired t-test with  $p < 0.05$  considered significant.

**Results:** 28 ureteroscopic cases prior to protocol implementation were compared to 21 procedures after implementation. Stone size and location was similar between groups. Protocol implementation significantly reduced the mean fluoroscopy exposure 88.5 seconds (range 22–360) to 23.6 seconds (range 2–108) following protocol implementation ( $p < 0.001$ ). There was no difference in mean operative time 71.1 vs 69.9 min;  $p = 0.87$ , or complications (3 patients vs. 4 patients;  $p = 0.52$ ) between protocols. No complication in either group could be ascribed to fluoroscopy technique.

**Conclusion:** This reduced fluoroscopy protocol resulted in a 73% reduction in fluoroscopy time without altering outcome. These simple radiation reducing techniques add no technical difficulty to the case and may improve procedure safety for the patient, surgeon and operating room staff.

#### **MP8-05 OPTIMIZING RETROGRADE FLEXIBLE URETEROSCOPY FOR UPPER URINARY TRACT PATHOLOGY**

R. Multescu, B. Geavlete, D. Georgescu, P. Geavlete—Romania

**Background:** The development of retrograde flexible ureteroscopy significantly modified the diagnosis and treatment of upper urinary tract pathology. This study aimed to identify solutions to optimize this endoscopic procedure.

**Methods:** Between 2002–2008, 173 patients underwent retrograde flexible ureteroscopy in our department. We evaluated the variables influencing method’s performances, as well as solutions to solve these problems.

**Results:** The visibility, reduced due to the technical particularities of flexible ureteroscopes, may be supplementary diminished by the presence of hematuria/pyuria or the insertion of accessory instruments through the working channel. By avoiding iatrogenic lesions of the urothelium, using pressure irrigation or inserting small caliber accessory instruments through the working channel (eventually unsheathed baskets), visibility may be improved. The access to the entire pyelocaliceal system (especially the lower pole) may be limited by the renal anatomy, presence of hydronephrosis or ureteroscope’s maximal deflection. In cases with the infundibulopyelic angle lower than  $30^\circ$ , or between  $30^\circ$ – $90^\circ$  associated with an inferior calyx infundibular length shorter than 3 cm, the success rates of the lower pole access were 0% and 61.1%, by comparison to 88% in other patients. Massive hydronephrosis imposes ureteral stenting followed by flexible ureteroscopy in a secondary setting. Maintaining an acute deflection for a long time must be avoided by calculus displacement into the renal pelvis.

**Conclusion:** Specific limitations of the method must be taken into consideration when indicating this procedure. Each problem has a specific solution, however applicable only in selected cases.

#### **MP8-06 THE EXPERIENCE OF USE URETERAL ACCESS SHEATHS IN TRANSURETHRAL PYELOCALICOLITHOTRIPSY. SCIENTIFIC RESEARCH INSTITUTE OF UROLOGY, MOSCOW, RUSSIAN FEDERATION**

R. Fatikhov, D. Merinov, E. Borisenko

**Background:** More less invasive nephrolithiasis treatment options spread widely due to innovative technologies development and introduction of new rigid miniureteroscopes, flexible ureteroscopes and Ureteral Access Sheaths for permanent access, upgrading of laser lithotripsy methods. In our work we analyze the experience of stabile transurethral access Flexor (Cook Urological, USA) system use in transurethral pyelocalicolithotripsy.

**Methods:** Contact transurethral stone fragmentation requires an adequate access. Modern ureteropyeloscopes usually do not need ureteral orifice and ureter intramural part dilatation, but for huge stones (more than 1.5 cm) fragmentation, especially with flexible ureteroscopes there is necessity for stabile access system installation. This system consists of ureteral bougie and cover placed transurethrally to kidney with a help of cord under X-ray control. Ureteral semirigid atraumatic cover provides a permanent access to calices-pelvis system, free liquid drainage, good visualization and a possibility of multiple instrument extraction for stones fragments removal. Ureteral covers were used in 30 cases: 22 with a help of rigid ureteroscope (cover diameter 14 F, length 35 cm), 8 with a flexible ureteroscope (cover diameter 9.5–14 F, length 55 cm).

**Results:** In all patients stones were fragmented and extracted. Ureteral cover allows to extract fragments sized up to 1.1 cm. After cover removal rigid ureteropyeloscopy showed small mucous tears, no active bleeding. Ureteral stent was inserted to all patients. 7 patients underwent additional flexible ureteroscopy and residual fragments removal. No pathologic ureter changes were noticed in long-term period.

**Conclusion:** Ureteral covers use for contact pyelocalicolithotripsy significantly improves renal stones removal due to better endoscopic visualization, permanent irrigation that provides low liquid pressure, multiple instrument extraction possibility and less ureter trauma. Rigid ureteropyeloscopy is possible only with short covers

(35 cm and less, diameter 12F and bigger). Thus Ureteral Access Sheaths can be recommended for clinical use to improve renal stones management.

### MP8-07 RETROGRADE URETEROPYELOSOPIC TREATMENT OF LARGE UPPER URINARY TRACT AND STAGHORN CALCULI WITH AQUAGUIDE

M. Araki, S. Uehara, T. Watanabe, T. Saika, Y. Nasu, H. Kumon

**Background:** Japanese guideline recommends combined therapy with percutaneous nephrolithotomy (PCNL) and ESWL for 2 cm or greater upper urinary tract and staghorn calculi. However PCNL is not always an ideal modality. AquaGuide (Bard, NJ, USA) is a new access sheath, which enables irrigation through a second lumen for a clearer vision during ureteropyeloscopies and laser lithotripsy. We examine the safety and efficacy of AquaGuide during retrograde endoscopic lithotripsy in treating large renal stone burdens.

**Methods:** Lithotripsy was based on the application of fiberoptic ureteroscopes and the holmium laser lithotripter. Successful therapy was defined as total fragmentation of a stone burden with creation of fine sand and 2 mm or smaller debris.

**Results:** A total of 9 patients with 19 (average 15 (6–35) mm) renal stones including one partial staghorn calculi were included. All were successfully treated solely in a retrograde ureteroscopic manner. Six (67%) patients were successfully treated in a single session including one patient with seven renal calculi (6–15 mm). Second look endoscopy defined significant residual fragments requiring additional endoscopic lithotripsy in three patients including one patient with a large (26 mm) renal stone burden composed of pure cystine for steinstrasse after the first session. No intraoperative and postoperative adverse events were encountered except one pyelonephritis requiring antibiotic therapy. New stone growth was observed during follow-up in two which was related either to uncorrectable metabolic disorders and/or urinary stasis.

**Conclusion:** AquaGuide is safe and useful tool for the retrograde endoscopic treatment of large renal stone burden.

### MP8-08 SUITABILITY AND INDICATION OF URETEROPYELOSOPY BASED ON RADIOGRAPHIC FINDINGS AND URINE CYTOLOGY FOR DETECTION OF UPPER URINARY TRACT CARCINOMA

A. Takao, T. Saika, S. Uehara, K. Monden, T. Watanabe, H. Kumon

**Background:** The objective of the present study was to clarify the indications, usefulness and limitations of ureteropyeloscopies.

**Methods:** From January 1997 to December 2008, 124 consecutive patients (70 men and 54 women) with a mean age of 57.5 years (range, 14–87 years) underwent ureteropyeloscopies to diagnose upper urinary tract tumors (UUT). Patients were divided into four subgroups by voided urine cytology and preoperative radiographic findings. Group A (n = 8, 6.2%), positive voided urine cytology and positive preoperative radiographic findings; group B (n = 4, 3.1%), positive cytology and negative radiographic findings; group C (n = 55, 42.6%), negative cytology and positive radiographic findings and group D (n = 62, 48.1%), frank hematuria originating from the UUT but negative cytology and negative radiographic findings. We analyzed the findings of ureteropyeloscopic examination with the results of radiographic examination and cytology, and adverse effect of ureteropyeloscopies.

**Results:** In group A, all 8 patients were confirmed UUT by ureteropyeloscopies. In group B, one revealed small UUT and remaining 3 confirmed CIS by biopsy with ureteropyeloscopies. In group C, 33 patients (60%) were revealed their UUT. And in group D, four patients (6.5%) were found UUT. Seventy-eight patients (97.5%) of 80 patients without malignant disease in group C and D were confirmed their benign disease in upper urinary tract by ureteropyeloscopies. No patient was found UUT during follow up after negative finding of ureteropyeloscopies.

**Conclusion:** Results indicated that ureteropyeloscopies is suitable and useful modality for patients with negative voiding cytology. On the other hands, ureteropyeloscopies could not bring any benefit for patients with positive radiographic findings and positive voiding cytology.

### MP8-09 PREDICTORS FOR NEGATIVE URETEROSCOPY IN THE MANAGEMENT OF UPPER URINARY TRACT STONE DISEASE

R. Dickstein, J. Manger, R. Babayan, D. Wang—USA

**Background:** Computed tomography (CT) is extremely accurate in assessing urolithiasis, but urologists have recently been trying to minimize this modality, and thus, excessive radiation exposure. On the other hand, patients occasionally undergo unnecessary ureteroscopy without evidence of stones, if they have not had repeated confirmatory imaging. We sought to identify predictive factors of negative ureteroscopies in a large cohort of patients from an academic medical center.

**Methods:** A retrospective chart review was performed on all ureteroscopies performed at our institution by a single surgeon from August 2003 to May 2008. Pre-operative patient characteristics, radiographic stone sizes, and operative findings were all recorded. Univariate analysis facilitated identification of predictors for negative findings at the time of ureteroscopy. Student's t-test was utilized for continuous variables and chi-square or Fischer's exact test for nominal variables ( $\alpha = 0.05$ ).

**Results:** Four hundred sixteen patients underwent ureteroscopy with intent to perform laser lithotripsy. Of this cohort, twenty (4.8%) did not have stones upon direct visualization. Patients who underwent negative ureteroscopies, compared to those with identifiable stone at the time of surgery, were more likely to have smaller stones (6.1 mm  $\pm$  3.2 versus 8.2 mm  $\pm$  4.3,  $p = 0.028$ ), distal (as opposed to proximal) ureteral stones (OR 2.67, 95% CI 1.07–6.63), and ureteral (as opposed to renal) stones (OR 0.38, 95% CI 0.15–0.98). Age, gender, past medical history, pre-operative imaging modality, pre-operative pain, and pre-operative obstruction, were not predictors of negative ureteroscopy.

**Conclusion:** Negative ureteroscopy occurred in about five percent of our patients, but is difficult to predict based on patient presentation or imaging modality. When counseling patients, they should be aware of this possibility. Smaller, more distal stones are more likely to spontaneously pass, leading to a negative ureteroscopy. Thus, in patients with small, distal, ureteral stones predictive of spontaneous passage, repeat imaging with CT should be considered.

### MP8-10 LARGE URETERAL FIBROEPITHELIAL POLYPS CAN BE TREATED ENDOSCOPICALLY USING HOLMIUM:YAG LASER

C. Kara, B. Resorlu, E. Sahin, A. Unsal—Turkey

**Background:** Fibroepithelial polyps (FEPs) are the most common benign lesions of the ureter. Although open resection and endoscopically treatment modalities are available, the management of large lesions is still controversial. We review our experience with four patients having large FEP which treated with holmium:YAG laser.

**Methods:** We identified four patients with FEP that partially obstructed the ureteral lumen from 2005 to 2009. All of the patients were women. The patients were evaluated with urinary ultrasonography, intravenous urography and CT or magnetic resonance (MR) urography preoperatively. The base of polyp was ablated with a 365 nm holmium laser fibre operating at 10 W to 15 W. Ureteral stents were placed at the completion of the procedure.

**Results:** Mean age of patients was 42.5 years (32–48) and the mean length of the polyps was 5.25 cm (3.5–7). Mean operative time was 57.5 minutes (55–65). The result of urine cytology was negative in all patients. Histologic analysis demonstrated FEP with no evidence of malignancy. No complication was observed during the procedure. The ureteral stents was removed at 4 weeks. Subsequent intravenous urography at 6 months was normal in all patients. No recurrence or ureteral stricture was detected during the follow-up period.

**Conclusion:** Although ureteroscopic resection can be difficult in patients with large polypoid lesion, large FEPs in ureter can be treated safely and effectively using holmium:YAG laser.

### MP8-11 EFFICACY OF URETEROLITHOTRIPSY WITH THE STONEBREAKERTM SYSTEM

A. Leventis, S. Leontis, L. Leonardopoulos, G. Sakelariou, D. Georgoulas, A. Rempelakos

**Background:** To evaluate the safety and efficacy of the StonebreakerTM portable, cordless, pneumatic lithotripter for intracorporeal lithotripsy of ureteral stones.

**Methods:** Ninety-six ureteral stone disease patients, six of which were ESWL failures, were prospectively included in this study during an 18-month period. Stone number and position, number of shocks required for stone fragmentation to size sufficient for removal, as well as operative time were recorded for each patient. Lithotripsy was performed through a semi-rigid ureteroscope under epidural anesthesia.

**Results:** One hundred and four stones were treated in our patient population. Upper, mid and lower ureteral stones were located in 9 (8.6%), 27 (26.0%) and 68 (65.4%) patients respectively. Mean stone size was 1.8 cm (0.7–3.4). Mean number of shocks delivered was 29 (12–76). Stone fragmentation was achieved in all patients, including ESWL failures. Repeat ureterolithotripsy and renal ESWL due to stone migration were performed in four and three patients respectively. No evidence of ureteral trauma due to the lithotripsy was noted. All patients remained stone-free at a three month follow-up.

**Conclusion:** Stone breakerTM lithotripsy represents a safe, effective procedure with a short learning-curve for the treatment of ureteral stone disease.

### MP8-12 COMPARATIVE EVALUATION OF PNEUMATIC VERSUS HOLMIUM: YAG LASER LITHOTRIPSY FOR IMPACTED URETERAL STONES

M. Binbay, A. Singh, A. Tepeler, T. Akman, A. Muslumanoglu, A. Tefekli

**Background:** We prospectively analyzed and compared effectiveness and complications of pneumatic with the Holmium\_

yttrium-aluminum-garnet (Ho:YAG) laser in the ureterorenoscopic management of impacted ureteral stones.

**Methods:** From January 2006 to January 2008, we performed retrograde endoscopic treatment in 288 patients with ureteral stones in our clinic. The patients with impacted stones were prospectively randomized into two groups according to the lithotripter used to fragment the stone: pneumatic (n: 40) and laser (n: 40). The preoperative, operative and postoperative follow up findings are analyzed and compared.

**Results:** The average stone size was similar in both groups (11.3 + 4 mm versus 11.4 + 5 mm). The calculi were located in the distal ureter in most of the patients in both groups (65% in pneumatic group and 52.5% in laser group). The operation time was significantly diminished in laser (p < 0.001). The stone free rates after a single ureteroscopic procedure were 80% and 97.5% in pneumatic and laser, respectively (p < 0.05). Auxiliary treatments were needed in 8 patients in pneumatic group while it was needed only 1 patient in the laser group (p: 0.02). After the additional procedures 100% success rate was achieved in both groups. The rate of double J stent insertion was significantly higher in pneumatic (p: 0.01). In the pneumatic group, 3 cases of stone up migration and 1 case of post-operative stricture was seen while no such complication was noted in the laser group. The rate of complications was significantly higher in the pneumatic group (p: 0.02).

**Conclusion:** Ureteroscopic treatment with Ho: YAG laser may be considered an effective first line therapy for chronically impacted ureteral stones with diminished operation time, high stone free and low complication and additional treatment rates.

### MP8-13 THE PEDITROL IRRIGATION SYSTEM FOR URETERORENOSCOPY—OUR EXPERIENCE

S. Umranikar, R. Kulkarni, P. Kumar, K. Patil

**Background:** Assessment of the clinical application of the Peditrol irrigation system designed to improve visibility during rigid and flexible diagnostic and therapeutic uretero-rensoscopy. The Peditrol device is a foot-operated hands-free device that provides a short and controlled burst of irrigant fluid during endoscopic procedures.

**Methods:** The device was used in 50 patients undergoing ureteroscopy of which 25 patients underwent flexible ureteroscopic stone fragmentation using the Holmium-YAG laser, 21 patients underwent rigid ureteroscopic stone fragmentation with the Lithoclast system and 4 patients underwent flexible ureteroscopic Holmium-YAG laser ablation of upper tract tumours. The device along with the specified disposable pumping unit was used as instructed with no modifications. A note was made of operating time and subjective improvement of visibility. Further ex-vivo studies were carried out to demonstrate pressure and flow dynamics.

**Results:** We observed a significant improvement in vision with improved efficiency of the procedure and reduced operating time. Flow was easily controlled and well modulated to improve visibility without causing retropulsion of stone fragments. It also improved the visibility due to bleeding during tumour ablation. No malfunction or obvious shortcomings were noted.

**Conclusion:** The Peditrol device is a relatively inexpensive and a practical user-friendly device during ureteroscopic procedures. Its obvious advantages include better visibility, hands free approach with excellent pressure and flow control. It appears to be particularly suited for use with the flexible ureteroscope and is able to overcome the flow reduction when the instrument channel is in use.

### MP8-14 PROSPECTIVE STUDY OF 630 CONSECUTIVE FLEXIBLE URETERORENOSCOPES (FURS) OF THE UPPER URINARY TRACT

P. Ober, P. Liske, Y. Aguilar, S. Lahme—Germany

**Background:** Since new flexible ureterorenoscopes have been invented, flexible endoscopy of the upper urinary tract became easier and its significance has to be determined. Pathologies of the upper urinary tract, such as calyceal and renal pelvic stones, calyceal diverticulum stones, morphological obstructions and tumors, can be treated under direct endoscopic vision. Especially in cases with lower pole stones flexible ureterorenoscopy shows more favourable results than extracorporeal shockwave lithotripsy (SWL).

**Methods:** A prospective study of 630 consecutive flexible URS-procedures for stone treatment, diagnosis or laser surgery of calyceal stenosis was conducted. Endoscopic procedures were done by means of 270°-deflectable or double-bending ureterorenoscopes using an ureteral access sheath of 14 or 16 F. Lithotripsy or incision was done by means of a holmium-laser. Data for stonefree rate, operating time, hospital stay length, complication rate, stone analysis, localisation of the stone and auxiliary procedures was collected in 630 procedures.

**Results:** Mean operating time was 55.6 min. In 514 cases urinary tract stones were detected and treated. Mean stone size was 72.1 mm<sup>2</sup>. In 50.1% Holmium-laserlithotripsy was performed. 32.8% of the patients had been pretreated by SWL and flexible uretero-rensoscopy was used to remove residual fragments. Complication rate was 7.3% for pyelonephritis and 1.9% for ureteral perforation. Overall stonefree rate was 87.3%.

**Conclusion:** Flexible ureterorenoscopy is a reliable and effective diagnostic and treatment modality for different pathologies of the upper urinary tract. Main advantage in comparison to SWL is an increased stone-free rate and a reduced treatment time. Anatomical abnormalities, e.g. calyceal stenosis, can be treated simultaneously with stone therapy. Since now flexible ureterorenoscopy of the upper urinary tract is not recommended as a first line therapy by international guidelines. Based on the presented results randomized studies are needed to determine the significance of flexible ureterorenoscopy in the upper urinary tract.

### MP8-15 CAN FLEXIBLE URETERORENOSCOPY (FURS) BE RECOMMENDED IN THE TREATMENT OF STONE MASSES GREATER THAN 100 MM<sup>2</sup> IN THE UPPER URINARY TRACT?

P. Ober, V. Zimmermanns, P. Liske, S. Lahme

**Background:** Since new flexible ureterorenoscopes have been invented, flexible ureterorenoscopy is more frequently used for the treatment of calyceal stones in combination or alternatively to extracorporeal shockwave lithotripsy (SWL). For a reasonable procedure the diameter of the ureteral access seems to limit the maximal stonesize to 100 mm<sup>2</sup>. With enhanced surgical ability the treatment of higher stone masses is possible.

**Methods:** A prospective study of 630 consecutive flexible URS-procedures for stone treatment, diagnostic purpose or laser surgery of calyceal stenosis was conducted. We compared a subgroup A (148 procedures on 107 patients with stonemasses >100 mm<sup>2</sup>) with a subgroup B (482 procedures on 434 patients). Endoscopic procedures were done by means of 270°-deflectable or double-bending ureterorenoscopes using an ureteral access sheath of 14 or 16 F. Lithotripsy was done by means of a holmium-laser. Data for

stonefree rate, operating time, hospital stay length, complication rate, stone analysis, stone localisation and auxiliary procedures was collected.

**Results:** In group A in all cases urinary tract stones were detected and treated, in Group B in 354 cases (73.4%) stones were found in the calyceal system. Stonefree rates were 86.9% (A) and 94.8% (B). Mean operating time was 67.2 min (A) and 50.8 min (B). Reoperating rate was 32.7% in group A and 9.1% in group B. Complication rate was 14.9% (A) versus 6.6% (B) for pyelonephritis and 2.8% (A) versus 2.2% (B) for ureteral perforation. Mean hospitalisation time after the last procedure was 5.0 days (A) versus 3.2 days (B).

**Conclusion:** Flexible ureterorenoscopy is a reliable and effective diagnostic and treatment modality for stones of the upper urinary tract. With acceptance of a slightly higher complication rate and length of hospitalisation stones of more than 100 mm<sup>2</sup> can be treated successfully. Until today SWL is the guideline recommended therapy for stones between 1 and 2 cm diameter. Randomized studies are needed to determine the significance of flexible ureterorenoscopy in the treatment of stones >100 mm<sup>2</sup> in the upper urinary tract.

### MP8-16 THE IMPACT OF ACCESS SHEATHS ON STONE FREE RATES AFTER URETEROSCOPY: THE PRELIMINARY RESULTS OF A CANADIAN MULTICENTRE RANDOMIZED CONTROLLED TRIAL

C. Mendez Probst, L. Nott, D. Beiko, B. Chew, T. Wollin, H. Razvi—Canada

**Background:** Ureteral access sheaths (UAS) were developed to facilitate the initial entry or re-entry to the upper urinary tract, however their impact on stone free rates (SFR), has only been sporadically investigated by retrospective studies. We present the preliminary results of a multicentre prospective controlled randomized trial to determine the impact of the use of UAS on SFR at 3 months.

**Methods:** Patients with either a proximal and renal calculi were randomized 1:1 to either the use of a ureteral access sheath (UAS) or no sheath at 4 Canadian centres. Ureteroscopy with Ho: YAG laser lithotripsy was performed according to each of the institutions standard protocols using a Navigator 11/13 Fr UAS (Boston Scientific). Primary outcome was SFR at 3 months post URS. Secondary outcomes such as operative time, complications and stent insertion were recorded.

**Results:** Twenty patients were randomized to UAS and 22 to no UAS. No significant difference was found in patient age (55 UAS vs 52 non UAS p=0.40), gender (16 vs 17 males) BMI (32 vs 29 p=0.11), stone size (21 vs 18 mm p=0.9), operative time (59 vs 51 p=0.7), or SFR (16 vs 21 p=0.10) or need for post operative stent insertion (23 vs 17 p=0.12). No mayor complications occurred in either group.

**Conclusion:** Our preliminary data show that use of a UAS does not increase the SFR at 3 months, nor reduce surgical time or need for stent placement.

### MP8-17 ENDOSCOPIC MANAGEMENT OF RETAINED FOREIGN BODIES FOLLOWING FLEXIBLE URETERORENOSCOPY FOR RENAL CALCULI THE STONE CENTRE, DEPARTMENT OF UROLOGY, DARENT VALLEY HOSPITAL, KENT, UK

A. Sahai, H. Marsh, J. Palmer, S. Sriprasad

**Background:** In the current minimally invasive era, the numbers of endourological procedures are on the increase. Retained foreign bodies related to flexible ureteroscopy is rare. However, little is published in the literature about its management. We report on our small experience in this field.

**Methods:** Cases were identified between the 3 senior operating surgeons from our department. All were related to flexible ureteroscopic procedures for renal calculi. Retained foreign bodies related to the procedure included 2 guidewire fragments (situated in a lower and midpole calyx) and laser fibre in 1 case (situated in a lower pole calyx).

**Results:** Three female patients were identified with ages of 39, 44 and 53, respectively, in an extensive series of approximately 650 flexible ureteroscopies. All patients were stone free after their first procedure. The retained guidewire was related to direct laser damage and the laser fibre fragments were related to mechanical injury. All patients underwent a secondary flexible ureteroscopy procedure and the foreign body was identified and removed successfully with the use of triradiate forceps. The procedures were unremarkable.

**Conclusion:** Retained guidewires will be obvious on image intensifier as they are radio opaque. Holmium laser damage to guidewires can be identified during surgery by an associated bluish hue. However laser fibres are radiolucent and therefore a thorough inspection of all equipment utilised during ureteroscopy to assess for retained fragments is recommended. Retrograde endoscopic management of foreign bodies related to previous ureteroscopy is feasible and safe.

### MP8-18 “PUSH-PULL”—A GOOD OPTION FOR LARGE BULK UPPER URETERAL STONES

A. Kurien, L. Sinha, A. Patel, S. Mishra, R. Sabnis, M. Desai

**Background:** Multiple options are available for treatment of upper ureteral stones including shockwave lithotripsy, retrograde and percutaneous ureteroscopy. We present our experience with ‘Push-pull’, a technique which we favour for larger upper ureteral stones.

**Methods:** In our institution since the last twenty years, 735 push-pull procedures have been done for upper ureteral stones. In this poster we analyse our recent 90 push-pull procedures. Push-pull is defined as ‘pushing’ the stone back into the renal pelvicalyceal system from the ureter using various manoeuvres. The stone is then ‘pulled’ out using a nephroscope through a percutaneous track.

**Results:** Ninety patients with a mean age of  $47.7 \pm 12.3$  years underwent push-pull. The mean stone length of the stone was  $15.8 \pm 5.8$  mm located at a median position of third lumbar vertebrae. Percutaneous nephrostomies were preplaced in 64.4%. After a successful ‘push’, the ‘pull’ was achieved with a single track in almost all patients except in three patients who required two tracks each. The upper, middle and lower calyceal tracks were utilised in 4.8%, 45.8% and 49.4% of cases respectively. The mean hospital stay was  $5 \pm 2.9$  days. The mean haemoglobin drop was  $1.09 \pm 0.85$  gm/dL. Blood transfusion was required in 4.4%. Complete clearance was achieved in 95.6%. Re-treatment was required in 3.3% of the patients. None of the patients required auxiliary procedures for stone clearance. Complication rate was 8.9%.

**Conclusion:** Good clearance rates with low re-treatment and auxiliary procedure rate with acceptable complication rates are achieved with Push-pull for large bulk upper ureteral stones.

### MP8-19 THE NEED FOR INTRODUCER SHEATHS FOR URETERIC ACCESS: A COMPARATIVE STUDY BETWEEN OLD GENERATION FIBRE-OPTIC FLEXIBLE URETEROSCOPES AND THE NEW INVISIO DUR-D DIGITAL FLEXIBLE URETEROSCOPE

T. El-husseiny, S. Nesar, Z. Maan, A. Papatsoris, J. Masood, N. Buchholz—UK

**Background:** Compared to fibre-optic scopes, digital flexible ureteroscopes have a larger tip diameter. This may necessitate more frequent use of an introducer sheath to gain ureteric entry increasing the risk of ureteric injury, the need for ureteric stents and may increase cost. We compare the need to use introducer sheaths to gain ureteric access, the need for stenting and complications for fibre-optic (FO) and liquid crystal display (LCD) digital flexible ureteroscopies (f-URS).

**Methods:** Over a 30 month period we studied the need for a sheath to gain ureteric access in patients having f-URS under GA. Patients were scoped with either a FO flexible ureteroscope (DUR-8, Elite, ACMI; Distal Tip Diameter = 8.5 F) or a digital flexible ureteroscope (Invisio D-URD; Distal Tip Diameter = 8.7 F). The age and sex of the patients and indications for f-URS were noted.

**Results:** Eighty FO and 77 LCD flexible ureteroscopies were performed. Sheaths were used significantly more often for the digital f-URS group (p value 0.00174). Both groups were well matched in terms of age and sex as well as indications for f-URS. Stents were placed in 45% patients in the digital f-URS group and in 39% in the fibre-optic f-URS group. Two patients in the digital f-URS group had ureteric perforation from the introducer sheath compared with none in the FO group.

**Conclusion:** The obvious improvement in the images obtained and the likely better durability of the digital scopes needs to be offset against the increased use of ureteric access sheaths and possible increase in morbidity and expense.

### MP8-20 PERCUTANEOUS ANTEGRADE URETEROSCOPY AN EFFECTIVE PROCEDURE FOR REMOVING IMPACTED UPPER AND MID URETERIC STONES

M. Baptistussi, M. Morihisa, E. Gewher, A. Martins—Brasil

**Background:** Our experiences of treating impacted upper and mid-ureteric stones with percutaneous Antegrade ureteroscopy are presented.

**Methods:** Between October 1999 and September 2008, sixty-six consecutive patients presenting with symptomatic impacted upper or mid-ureteric stones underwent percutaneous antegrade ureteroscopy. Success rates were evaluated immediately with a nephrostogram and after six weeks with a KUB.

**Results:** two patients had had previous treatment for their ureteric stone; one had extracorporeal shockwave lithotripsy, another had a failed retrograde, ureteroscopic extraction. Altogether 66 stones were treated of which 59 were upper ureteric and 7 mid-ureteric. Eighteen people had antegrade ureteroscopic stone extraction during their emergency admission. Stones were lifted out whole in 41 procedures. Complete ureteric stone clearance was achieved immediately in 56/66 (84.8%) patients, and in 63/66 (95.5%) patients at six-weeks follow up without the need for ancillary procedures. There were two complete failures, one of which was mechanical failure of the litrotripper. Postoperative pyrexia (38°C) developed in six patients. A further six patients developed minor

complications. All complications settled with conservative treatment. No major complication were encountered.

**Conclusion:** Percutaneous antegrade ureteroscopy is affective at removing problematic impacted upper and mid-ureteric stones,

with minimal morbidity. It should be offered as an alternative first-line treatment.

## MP9: PCNL 2

### MP9-01 BILATERAL SINGLE PROCEDURE PERCUTANEOUS NEPHROLITHOTOMY

R. Multescu, V. Cauni, V. Mirciulescu, E. Alexandrescu, B. Geavlete, P. Geavlete—Romania

**Background:** Unlike SWL or ureteroscopy, the percutaneous renal approach is not limited by stone size. However, the inherent complications of this technique, some of which really significant, necessitate a rigorous selection of the cases.

**Methods:** Since introducing the percutaneous approach in our department in 2001, more than 2000 patients benefited from this surgical technique. With the continuously expanding experience, we approached more and more complex cases, with good results and a decreasing rate of complications. Among the 2103 patients with lithiasis, 174 presented bilateral disease. 6 patients were operated by single session percutaneous approach. The selection criteria for these patients consisted of lack of urinary infections, severe associated diseases (such as renal failure, diabetes, heart failure, coagulation problems, extreme obesity etc.). Patients' choice was also decisive. The surgical procedure was continued on the contra-lateral renal unit only when the first intervention took place in good conditions, without complications.

**Results:** The hospital stay was  $5 \pm 1$  days, without major complications. After suppressing the nephrostomy tubes, 1 patient developed unilateral lumbar fistula, which necessitated ureteral stenting for 14 days. One patient presented upper urinary tract infection, which required antibiotherapy.

**Conclusion:** The renal percutaneous approach continues to remain an important alternative in the treatment of renal lithiasis, with no limitations related to stone size. Single session bilateral percutaneous nephrolithotomy may be used only in rigorously selected cases, in order to limit any eventual complications.

### MP9-02 COMPARISON OF PCNL WITH OPEN SURGERY IN PATIENTS WITH RENAL STAGHORN STONES

S. Falahatkar, Z. Panahandeh, sourati, M. Akbarpour, N. Khaki

**Background:** Open surgery is considered the gold standard of treating staghorn calculus with which all other forms of treatment were compared. New endourological techniques lead to treating staghorn calculus with more effective and less invasive methods. The aim of this study was to compare the complication of PCNL (percutaneous nephrolithotomy) with open surgery in staghorn stones.

**Methods:** In this study 120 patients suffering from staghorn stones were considered. We extracted requested information such as age, sex, treatment method, intraoperative and postoperative complication and hospital stay. We compared the results and complications in patients who underwent PCNL with open surgery.

**Results:** We studied 72 patients (60%) who underwent PCNL and 48 patients (40%) who underwent open surgery. We recorded intraoperative complication in 18.8% and 13.9% of patients in PCNL and open surgery respectively. The most common intraoperative complication was bleeding requiring blood transfusion. We recorded postoperative complication in 12.5% and 4.2% of patients in PCNL and open surgery respectively. Mean hospital stay was  $3.93 \pm 1.76$  and  $5.08 \pm 2.42$  day in PCNL and open surgery respectively. Stone free rate was 81.9% and 91.6% in patients who underwent PCNL and open surgery respectively.

**Conclusion:** PCNL is a valuable treatment option for staghorn stones with complication and stone free rate close to open surgery. Moreover, it has advantages such as shorter hospital stay. Therefore, it can be considered as the first stage in treatment of most patients with staghorn stones.

### MP9-03 PNL: IS IT THE FIRST CHOICE FOR MANAGEMENT OF STAGHORN STONES. PREDICTIVE VALUES OF SUCCESS

M. Badreldin, T. Abdelbaky, K. Salah, A. Gamal—Egypt

**Background:** We are reporting our experience in PNL to treat staghorn stones and parameter that predict the choice of that technique to be the first line of treatment.

**Methods:** 52 patients with 56 staghorn stones were included in the study during the period from 1995 to February 2005. Patients were collected from Menoufeya University hospital. PNL was the treatment for all patients as the primary choice. Full history, examination and investigation needed were done to the patients. Patients weight, recurrence of stone, pelvicalyceal configuration, renal abnormality, stone shape and burden were collected and analyzed to study their contribution in success. A group of 30 patients managed by open surgery were set as a control group.

**Results:** The mean operative time was  $155 + 43$  minutes. Operative complications were, failure of puncture in 3 cases, hence conversion to open surgery was decided, massive bleeding requiring blood transfusion in 12 patients, colonic injury in 2 cases, perforation of the pleura in 2 cases and perforation of the pelvis in 6 cases. Postoperative complication includes; fever, hematuria, septicemia, and leakage were met in 21 cases. 33 renal units were totally stone free, and 23 renal units had residual stone that required further management. Six patients lost follow up and the rest were treated by ESWL. Pelvicalyceal complex configuration, stone burden  $>2500 \text{ mm}^2$ , and congenital anomalies contribute negatively in the success of the operation.

**Conclusion:** Staghorn stone management needs preoperative study of pelvicalyceal system carefully before deciding the line of management. PNL is considered the 1st choice for treatment in



recurrent cases, simple pelvicalyceal system configuration and with stone burden less than 2500 mm<sup>2</sup>. However, every case is unique and need meticulous evaluation.

#### **MP9-04 EVALUATION OF THE LEARNING CURVE FOR PERCUTANEOUS NEPHROLITHOTOMY**

S. Ziaee, M. Mohammadi sichani, A. Kashi

**Background:** Nowadays, percutaneous nephrolithotomy (PCNL) is the treatment of choice for large renal stones and is associated with difficult and complicated learning. Defining the number of PCNL operations to achieve competence or excellence has been a challenge. We studied learning curve of one surgeon in a university hospital.

**Methods:** 105 consecutive PCNL operations done by a fellowship in endourology with no previous experience at performing solo PCNL were studied. Operation duration, stone extraction percent, stone free rate, number of accesses, tubeless cases, and complications were studied in sequential groups of 15 patients as the surgeon gained experience.

**Results:** Operation duration decreased from a mean  $\pm$  SD of 95.4  $\pm$  24.1 in patients 1–15 to 78.3  $\pm$  17.0 in patients 31–45 and then remained in plateau. Complications which were minor in category were only observed in patients 1–45. Stone extraction percent increased from a mean  $\pm$  SD of 88.3  $\pm$  14.8 minutes in patients 1–15 to 99.3  $\pm$  2.6 minutes in patients 91–105. Percent of patients with no residual fragments decreased from 53% in patients 1–15 to 6.7% in patients 91–105. No statistically significant differences were observed in estimated blood loss or transfusion rate between sequential groups of cases.

**Conclusion:** Improvement in operation duration was observed and absence of complications was achieved after 45 cases. Improvement in stone clearance was observed up to 105 cases. Competence was achieved after 45 cases but excellence was achieved after 105 operations.

#### **MP9-05 PCNL IN PATIENTS WITH PREVIOUS HISTORY OF RENAL SURGERY**

M. Rahmani, M. Darabi Mahboub

**Background:** Evaluation and comparison of results and complications of PCNL in patients with previous history of renal surgery.

**Methods:** In one year, 28 patients with previous history of renal surgery (16 patients history of renal stones open surgery, 11 patients with history of previous PCNL, and 1 patient with history of pyeloplasty) underwent PCNL for renal stones. Main duration of hospitalization, duration of operation time, duration of fluoroscopy, complications of operative and post operative compared with patients that had non history of renal surgery.

**Results:** Main hospitalization after operation in two groups was approximately equal (2.3 days). Main operation time in patients with history of previous open renal surgery was 68 min and in patients with history of previous PCNL was 56 min and in patients without previous renal surgery was 52 min. Main fluoroscopy time in patients with previous open renal surgery was 85 sec and in patients with previous PCNL was 47 sec and in patients without previous renal surgery 52 sec. Nephrostomy tracts dilation (specially with fascial dilation) was major problem in patients with previous renal open surgery, and usually early metal coaxial dilation was needed. Major complication at operative time was hemorrhage that occurred in 3 patients with previous renal surgery

and in one patients without previous renal surgery that needed only transfusion and managed conservatively.

**Conclusion:** PCNL in patients with history of previous renal surgery have more complication and need more attention compared with intact kidneys.

#### **MP9-06 PERCUTANEOUS NEPHROLITHOTOMY IS A SAFE AND EFFECTIVE PROCEDURE EVEN IN PATIENTS WITH NON-OPAQUE RENAL STONES**

C. Kara, B. Resorlu, U. Oguz, A. Unsal—Turkey

**Background:** We performed a study to define the outcome of patients with non-opaque renal stones who were treated with percutaneous nephrolithotomy (PCNL).

**Methods:** From November 2006 to June 2009, 517 patients were evaluated retrospectively in our clinic. 41 patients were have non-opaque renal stones. The mean age was 37.2 years (range 2–69) and the average stone burden was 475 mm<sup>2</sup> (range 213–1720). PCNL was accomplished using rigid nephroscope with ultrasonic and/or pneumatic lithotripter under general anesthesia. Flexible nephroscopy was used in all patients to improve stone-free rates.

**Results:** Mean operative and fluoroscopic screening time were 45.3 (18–145), 3.5 (1–7) minutes respectively. The stones localizations were 16 (39%) in lower calyx, 8 (19.5%) in renal pelvis, 5 (12.1%) mid calyx, 5 (12.1%) multiple calyx and /or pelvis. 7 (17%) patients had staghorn stones. The stone was cleared by single tract in 29 cases (70.8%), and 12 (29.2%) required more than one tract. Postoperative evaluation was performed by non-contrast computer tomography and/or ultrasonography. Stone-free rate was achieved in 32 patients (78%). Auxiliary procedures were required in 9 renal units (22%) and included ureteroscopy in 2, second-look PCNL in 4, and SWL to fragment residual caliceal stones in 3 patients. 37 patients were stone-free after primary and secondary procedures and an overall stone-free rate was reached 90%. A urinary tract infection developed in 3 (7.3%) patient who did not have general symptoms and 5 (12.1%) patients required a blood transfusion. Of the stones 10 (24.3%) were cystine, 12 (29.2%) were uric acide, and 19 (46.3%) were infection and/or matrix stones.

**Conclusion:** PCNL as a minimally invasive modality preserves its efficiency and safety even in non-opaque renal stones.

#### **MP9-07 PERCUTANEOUS NEPHROLITHOTOMY FOR TREATMENT OF ENCRUSTED URETERAL STENTS: A MULTICENTER STUDY**

B. Eisner, M. Kurtz, B. Matlaga, O. Shah, E. Hyams, V. Pais jr, J. Page, R. Venkatesh, O. Arsovska, R. Patterson, B. Chew

**Background:** Encrusted ureteral stents are a challenging endourologic problem that may require multiple procedures. We performed a multi-institutional review of percutaneous nephrolithotomy (PNL) as primary treatment for encrusted stents.

**Methods:** Patients were identified who underwent PNL for treatment of an encrusted ureteral stent. Retrospective review was performed to compile details of procedures and outcomes.

**Results:** Thirty-one patients underwent PNL for encrusted ureteral stents. Mean age was 47.9 years ( $\pm$  16.0) and female:male ratio was 15:16. Mean stent indwelling time prior to removal was 28.3 months ( $\pm$  25.4). Reason for long indwelling time was reported in 19 cases and included “patient unaware stent needed to be removed” (12 cases), pregnancy (2 cases), other comorbidities (3 cases), and patient was a prisoner (2 cases). Mean operative time

was 161 minutes ( $\pm 68.3$ ). There were no major intraoperative complications and no patients required blood transfusion. Litholopaxy was required for bladder coil encrustations in 16 cases (51.6%) and ureteroscopy with lithotripsy was required for encrustation of the ureteral portion of the stent in 10 cases (32.2%). Second look percutaneous procedures were required in 12 cases (38.7%). All stents were removed successfully. Patients were rendered stone-free or had small non-obstructing residual fragments ( $<5$  mm) in 29 cases (93.5%).

**Conclusion:** Encrusted ureteral stents present a challenging surgical problem. All portions of the stent may become encrusted, requiring PNL with or without ureteroscopy and/or litholopaxy. Patient education is paramount for prevention as a majority of patients were unaware that their initial stent needed to be removed.

#### **MP9-08 POST-PCNL FEVER: PROSPECTIVE ANALYSIS OF PRE-OPERATIVE URINE, RENAL PELVIC URINE, AND STONE CULTURES**

R. Korets, R. Walsh, M. Gupta—USA

**Background:** The exact mechanism of fever and urosepsis after percutaneous procedures has not been established. Prior studies suggest that pelvic urine culture is a better predictor of urosepsis. We conducted a prospective study to determine the correlation between pre-operative and intra-operative cultures in patients with post-PCNL fevers.

**Methods:** From February 2009 to June 2009 all patients with nephrolithiasis treated with PCNL at our center were recruited. Renal pelvic urine was collected at the time of retrograde ureteral catheter placement or at percutaneous puncture of the pelvicaliceal system. Extracted stones were also sent for culture. Patients were monitored for any systemic inflammatory responses.

**Results:** Of 37 patients treated with PCNL, 13 (35%) had positive preoperative urine cultures, all treated prior to PCNL. Pelvic urine culture was positive in 7 (19%) patients with 5/7 (71%) concordant with preoperative cultures. Stone culture was positive in 4(8%) of patients with 3/4 (75%) positive stone cultures concordant with preoperative urine cultures. Two post-procedural febrile responses were noted, with one resulting in candiduria and candidemia. In both patients, pelvic urine cultures were positive, but were discordant from preoperative culture.

**Conclusion:** Our findings suggest that even appropriately treated preoperative urinary infections may not prevent infected urine at the time of PCNL and that pelvic urine culture may be better at predicting post-PCNL fever. Routine collection of pelvic urine is recommended. We continue to accrue patients to further elucidate the role of pelvic culture in a larger cohort.

#### **MP9-09 THE IMPACT OF PERCUTANEOUS NEPHROLITHOTOMY IN SOLITARY FUNCTIONING KIDNEY WITH CHRONIC KIDNEY DISEASE (CKD)**

A. Kurien, R. Baishya, S. Mishra, A. Ganpule, R. Sabnis, M. Desai

**Background:** To study the renal functional outcome of solitary functioning kidneys with chronically impaired renal function following percutaneous nephrolithotomy (PCNL).

**Methods:** Twenty two chronic kidney patients with solitary functioning kidney with a mean age of  $52.7 \pm 14.8$  years underwent PCNL in our institution in a period of five years. A mean of  $1.7 \pm 1.4$  tracks and  $1.4 \pm 0.7$  sittings was required for PCNL. The eGFR (estimated Glomerular Filtration Rate) was calculated using

the 4-variable MDRD (Modification of Diet in Renal Disease) equation. The eGFR pre-PCNL (post de-obstruction), peak eGFR on follow up and eGFR at last follow up were recorded. The CKD stage pre PCNL was compared with the CKD stage at last follow up.

**Results:** Complete clearance, auxiliary procedure and complication rates were 81.8%, 4.5% and 9.1% respectively. Blood transfusion was required in 18.1%. The mean eGFR pre-PCNL, peak eGFR at follow up and eGFR at last follow up were  $31.8 \pm 12.1$ ,  $44.9 \pm 17.5$  and  $40.8 \pm 19.0$  ml/min/1.73 m<sup>2</sup> respectively. At a mean follow up of  $187 \pm 200$  days deterioration with up-migration of CKD stage was not seen in any patient. Down-migration of CKD stage was seen in seven patients (31.8%) following PCNL. One patient (4.5%) required renal replacement therapy in the form of maintenance haemodialysis. Recurrent urinary tract infection and residual stones are two factors which adversely affect the renal functional improvement.

**Conclusion:** PCNL has a favourable impact in CKD patients with good clearance rates, good renal functional outcome, low auxiliary procedure rate and acceptable complication rates.

#### **MP9-10 PERCUTANEOUS NEPHROLITHOTOMY IN PATIENTS WITH PREVIOUS OPEN NEPHROLITHOTOMY: BALLOON DILATATION VERSUS AMPLATZ DILATATION FOR NEPHROSTOMY TRACT DILATATION**

S. Bedir, L. Tahmaz, M. Zor, H. Topac, M. Dayanc

**Background:** Percutaneous nephrolithotomy (PCNL) can be done in patients who have previously undergone open nephrolithotomy. Currently, Amplatz renal dilators, balloon dilators or metallic dilators can achieve dilatation of the nephrostomy tract. The aim of this study was to compare balloon dilatation procedure in patients with previous open nephrolithotomy with Amplatz renal dilatation technique.

**Methods:** Fourteen patients with past history of open surgery for renal stone disease underwent PCNL at our institution in the past year included to the study. Patients were randomly divided into two groups according to dilation technique used: group 1 (Amplatz renal dilatation) and group 2 (balloon dilatation). 7 patients were included in each group. X-ray exposure and operation times were evaluated.

**Results:** Stone location and burden were similar in both of the two groups. Fluoroscopy time during the balloon dilatation procedure was significantly shorter than that of the Amplatz renal dilatation procedure (Grup 1: 9.8 minutes Grup 2: 7.2 minutes,  $p < 0.05$ ). Average time required for tract dilatation was also considerably less for the balloon dilatation group (Grup 1: 6.2 minutes grup2: 4.3 minutes,  $p < 0.05$ ). The stone free and complication rates were the same in the two groups.

**Conclusion:** Our experience indicated that the balloon dilatation procedure is feasible in patients with previous open nephrolithotomy. It is associated with significant reduction in x-ray exposure and tract dilatation time.

#### **MP9-11 METANALYSIS OF COMPLICATIONS OF PERCUTANEOUS NEPHROLITHOTOMY**

G. Pareek, S. Patel, G. Haleblan

**Background:** We performed a meta-analysis of the literature to define the complications associated with percutaneous nephrolithotomy (PNL).

**Methods:** MEDLINE database was searched from 1997 to 2007 using the terms “complications” and “percutaneous nephrolithotomy.” Inclusion criteria included any study with greater than 20 patients, age >18 years and any complications listed for PNL. Procedures included were unilateral tubed, synchronous bilateral and tubeless PNL. A data extraction form was created to categorize major and minor complications. A panel reviewed all of the studies that were extracted. Data was entered into a spreadsheet and a meta-analysis performed. Q-statistic (Cochran method) revealed  $p < 0.05$  for the tubed PNL, tubeless PNL and synchronous bilateral PNL groups, thus a random effects model was used for analysis.

**Results:** 64 of 383 references met our study inclusion criteria. 3783 patients and 4279 renal units were included in the meta-analysis. 3059 patients (3227 renal units), 426 patients (456 renal units) and 298 patients (596 renal units) underwent unilateral tubed PNL, tubeless PNL and synchronous bilateral PNL respectively. The probability of major complication (95% confidence interval) for tubed PNL, tubeless PNL and synchronous bilateral PNL were 13.8% (2.9–44.4), 13.0% (6.5–23.6), 20.6% (16.0–26.4) respectively. The probability of minor complication (95% confidence interval) for tubed PNL, tubeless PNL and synchronous bilateral PNL were 8.3% (5.7–11.5), 8.3% (5.7–13.0), 18.0% (13.0–24.2) respectively. There was no statistically significant difference between the major or minor complication rates per renal unit for each of the three groups. ( $p > 0.05$ ).

**Conclusion:** Traditional unilateral tubed PNL is associated with major and minor complication rates of 13.8% and 8.3%, respectively. Complication rates appear to be similar amongst the various contemporary PNL techniques.

### MP9-12 PERCUTANEOUS NEPHROLITHOTOMY FOR URINARY MATRIX CALCULI

L. Tahmaz, M. Zor, S. Basal, I. Karabuga, H. Topac, M. Dayanc

**Background:** Matrix stones are a rare form of renal calculi. Percutaneous nephrolithotomy (PCNL) has become the treatment of choice for matrix stones. We reported our institution's experience with the use of PCNL in matrix calculi treatment in two cases.

**Methods:** Data of two patients with urinary matrix calculi treated with PCNL at our institution were reviewed.

**Results:** Both patients had right renal matrix stone and were female. The patients were 22 and 47 years old, respectively. The first case was presented with lower urinary symptoms and the second with right flank pain. Plain graphics were revealed mild calcification of the calculi. The diagnosis was done with computed tomography. Matrix calculi of cases were treated successfully with PCNL without any significant intraoperative and postoperative complications. Complete stone removal can only be achieved in the second case. The patients were given prophylactic antibiotics. Despite the second patient had no recurrence in 14 months follow-up, the first patient had recurrence in the 3. month of follow-up period. We thought the recurrence was due to incomplete removal of the matrix stone and we performed a second PCNL and complete removal of the whole matrix component was achieved. No recurrence was seen after the second PCNL procedure (12 months follow-up).

**Conclusion:** Percutaneous techniques afford the best chance of complete removal of matrix stones. Although previous articles have discussed the potential role of antibiotic prophylaxis for prevention of matrix stone recurrence, we experienced that complete removal of matrix stone is more crucial.

### MP9-13 PERCUTANEOUS NEPHROLITHOTOMY WITH THE PATIENT IN SUPINE-SLOPE POSITION TO TREAT THE UPPER URINARY TRACT UROLITHIASIS(52 CASES)

H. Zongyao, L. Chaozhao, Z. Xiansheng, Z. Jun, F. Song

**Background:** This study was intended to discuss the effectiveness and advantage of percutaneous nephrolithotomy (PCNL) with the patient in the supine-slope position to treat the upper urinary tract urolithiasis.

**Methods:** A total of 52 subjects underwent the supine-slope position percutaneous nephrolithotomy (PCNL). Among of them aged from 22 to 61 years male and female, were 27 and 25, respectively. Their mean age was 45 years. There were 12 staghorn stones, 19 single renal-pelvis lithiasis, 18 multiple renal stones, 3 upper ureter lithiasis and 9 patients undergone the previous opened renal surgery. The biggest is 6 cm×8 cm, meanwhile the smallest is 0.5 cm×0.4 cm. Firstly, all patients were in dorsal lithotomy position under the general anesthesia. After placement of the retrograde the ureteral catheter which is tied to the Foley catheter and then with the patient in a supine-slope position, a thick pillow was under renal region, the flank bridge was elevated and patients' hip and chest were slope curve. Secondly, under continuous ultrasound monitoring, the urologists used the spinal needle below the 12th rib or between the 11th and 12th rib margin for the middle caliceal puncture after surface marking the anterior and posterior axillary line, while the assistant retrograde to infuse the water or graphic solution through the ureteral catheter so that the renal pelvic is hydrocele. Thirdly, once the puncture was successful, a 0.035-in. guidewire was placed inside the pelvicaliceal system, the tract was dilated over this guidewire from F8 to F16–18 with the fascial dilator as adding 2F each time, followed by placement of a 16–18F Peel-away plastic sheath through which the 8.0/9.8F rigid ureteroscopy or nephroscopy, tract could be dilated to 22–26F sometimes. What's more, in the case of perfusion with the high-pressure pump which provide the surgeon with a clear view, we performed the lithotripsy, furthermore, the fragment be dashed out by means of irrigation pressure or out with the lithotomy forceps. Finally, the double J stent was inserted and a appropriate tube of drainage was indwelling all the patients.

**Results:** All subjects underwent the primary single tract to gallet and remove stones. The mean operative time was 120 min, the average clearance was 85.6%, the drained tube mean duration was 5 days and mean hospital stay was 15 days which post operation was 5–7 days. Only did one need blood transfusion because of significant hemorrhage during the operation. There was no hemorrhagic subjects which need to embolism of vascular intervention no serious complications for instance the puncture of pleural or bowel etc.

**Conclusion:** The safety, more effectiveness, litter trauma, rapid recovery and high clearance are integral components of the percutaneous nephrolithotomy (PCNL) with the patient in the supine-slope position. Moreover, it adds ease and comfort to the patient and surgeon, which will be a good way of treating upper urinary tract stone.

### MP9-14 PERCUTANEOUS NEPHROLITHOTOMY IN SOLITARY KIDNEY STONE DISEASE

I. Aridogan, Y. Bayazit, V. Izol, D. Abat, Z. Tansug, S. Zeren—Turkey

**Background:** Effectiveness and reliability of percutaneous nephrolithotomy (PNL) was assessed in solitary kidneys with stone disease.

**Methods:** Between July 1998 and June 2009, 104 patients (70 male, 34 female) with solitary kidney underwent PNL procedures in our clinics and the mean age of the patients was 44.1 (4–74). Mean stone burden was 364 mm<sup>2</sup> (75–2250). Sixteen patients had staghorn kidney stone and 6 patients' age were less than fourteen. All operations were performed on prone position after inserting a ureteral catheter. Postoperative residual stone fragments were evaluated with plain abdominal radiography.

**Results:** Mean operation and hospitalization times were 74.6 minutes and 4.5 days respectively. Eighty six patients' (83%) results were stone free and 6 patients (6%) had clinically insignificant residual fragments, postoperatively. Second session was required for 7 patients and third session was done in only one patient. Shock wave lithotripsy was planned for 4 patients with residual fragments. The operation was done through a single access in 83 patients and a second access was necessary in 19 patients. Six of the 10 upper pole accesses were with intercostal approach. Eight patients (7%) needed blood transfusion, 38°C and higher body temperature were seen in 16 patients (15%). One patient was died on postoperative ninth day due to disseminated intravascular coagulopathy. Haematuria was seen in 3 patients and a double-J stent was inserted due to prolonged urine leakage in 3 patients. Diuresis was occurred in 3 patients and serum creatinine levels elevated temporarily in 3 patients. Drain was inserted for one patient for perirenal urinoma.

**Conclusion:** PNL is postulated as a gold standart for the treatment of kidney stones and it is also effective and reliable in the treatment of solitary kidneys with stone disease.

#### MP9-15 PERCUTANEOUS MANAGEMENT OF STAGHORN CALCULI IN HORSESHOE KIDNEYS. A MULTI-INSTITUTIONAL EXPERIENCE

P. Kallidonis, E. Liatsikos, A. Al Aown, J. Stolzenburg, O. Traxer, A. Smith

**Background:** Percutaneous nephrolithotomy (PNL) is a first line treatment technique for staghorn stones and stones located in horseshoe kidney (HK). We present our multi-institutional experience on the management of staghorn calculi within HKs.

**Methods:** The study included 15 patients with 17 staghorn calculi in HKs which were treated by PNL in our institutions. All PNL procedures were performed in a standard one-session technique with fluoroscopic guidance. The following information was assessed: number of access tracks, renal access location, fascial dilations, blood loss, blood transfusion, stone free rate, length of hospitalization. Intraoperative and postoperative complications as well as secondary procedures (second-look PNL, ureteroscopy, and SWL) were reviewed.

**Results:** Mean patient age was 50.26 (range 24–72) years old. Subcostal (n = 16) or intercostal (n = 1) puncture was performed. The average anaesthesia time was 126 min (93–200 min). The average blood loss was 450 ml and transfusions were deemed necessary in 20% of the cases. Single skin incisions performed for the management of 11 renal units and multiple incisions in 6. The average number of tract dilations per renal unit was 2.11 (range 1–4). The overall stone free rate was 82%. The average length of hospital stay was 4.4 days (range 3 to 7 days). The average duration of nephrostomy tube drainage was 80 hours with a range of 72 to

96 hours. Major and minor complication rate was 20% and 46.6%, respectively.

**Conclusion:** The performance of PNL is a safe and effective method to manage staghorn calculi in HKs.

#### MP9-16 THE PREDICTIVE FACTORS FOR THE SUCCESS AND COMPLICATION RATES IN PERCUTANEOUS NEPHROLITHOTOMY: EVALUATION OF 409 PROCEDURES AT A SINGLE CENTER

O. Tanriverdi, M. Kendirci, M. Kadihasanoglu, M. Sýlay, M. Taskiran, C. Miroglu

**Background:** To evaluate the predictive factors for the success and complication rates in 409 percutaneous nephrolithotomy (PCNL) procedures at a single center using multivariate analysis.

**Methods:** A total of 409 patients who had undergone PCNL from 2005 to 2009 were retrospectively analyzed regarding to the factors on success and complication rates, such as operation and fluoroscopy times, patients' age and gender, lateralization, the presence of hydronephrosis, stone burden, number of access, and location of stones. All the variables were analyzed using chi-square, Student t and Mann-Whitney U tests.  $p < 0.05$  was considered as statistically significant.

**Results:** Records for 409 PCNL procedures were available for the analyses. Mean age, gender and body mass index did not show any impact on occurrence of complication and stone-free status ( $p > 0.05$ ). Similarly, neither the presence nor the severity of hydronephrosis exhibited significant impact on the success and complication rates ( $p > 0.05$ ). Stone burden was negatively correlated with stone-free rates ( $p < 0.0001$ ), but positively correlated with operation time ( $p < 0.0001$ ). However, the complication rates were not affected by stone burden ( $p = 0.148$ ). Increased complication rates were reported in PCNL cases with reduced stone-free status ( $p = 0.01$ ). Although lateralization and the number of access did not show significant impact on complication and stone-free status ( $p > 0.05$ ), the lower pole access was associated with reduced complication ( $p < 0.05$ ) but increased stone-free rates ( $p < 0.05$ ).

**Conclusion:** These data demonstrated that stone burden and location of access might determine the success and occurrence of complication in PCNL procedures. Furthermore, occurrence of complication may reduce the stone-free rates.

#### MP9-17 TWELVE YEARS OF EXPERIENCE IN PERCUTANEOUS NEPHROLITHOTOMY FROM A SINGLE CENTER

I. Aridogan, Y. Bayazit, N. Satar, S. Doran, Z. Tansug, S. Zeren—Turkey

**Background:** Percutaneous nephrolithotomy (PNL) is a widely accepted modality in the treatment of kidney stones and increasingly being used in our country. Experience and outcomes in 2595 renal units from a single center are presented in this study.

**Methods:** Between June 1997 and July 2009, data of PNL procedures performed in 2595 renal units were recorded. Stone burden, operative and fluoroscopy times, number of intercostal access and skin incisions, stone-free status, types and sizes of nephrostomy catheters, blood transfusions, days of nephrostography and nephrostomy removal, hospital stay and complications were the parameters that were discussed in this presentation.

**Results:** Of the cases, 1532 (59%) were male and the mean age was 39.2 years. Three hundred and one renal units (11%) were in pediatric group. The mean stone size was 499 mm<sup>2</sup>, mean operative

time and fluoroscopy times were 76.8 and 11.6 minutes, respectively. Intercostal access was performed in 166 (6%) procedures. In 279 (11%) cases, there was a second skin incision. Stone free rate was 79%. Blood transfusions were needed in 342 patients (13%). A 14F nephrostomy catheter was placed in 33% and 20F in 46% of the cases. Renal vascular embolization was performed in 6 patients due to hemorrhage. There were 3 pleural and 5 colonic injury. Residents operated 1209 (46%) of cases under supervision. Time to nephrostography and nephrostomy removal as well as hospital stay were decreased in recent years.

**Conclusion:** PNL is a successful and safe procedure in the treatment of renal calculi greater than 2 cm. Serious complications are rare in an experienced clinic and they can be managed conservatively. PNL can also be performed in complicated cases.

### **MP9-18 PERCUTANEOUS NEPHROLITHOTRIPSY (PCNL) FOR PATIENTS WITH PREVIOUS OPEN RENAL SURGERY: IS THERE ANY PROGNOSTIC FACTOR?**

S. Ben Rhouma, S. Sallami, M. Basli, N. Yassine, A. Horchani

**Background:** To investigate the efficacy and complication rates of Percutaneous Nephrolithotomy (PCNL) performed in patients who previously underwent open renal surgery.

**Methods:** Between October 1998 and September 2008, 258 patients with renal calculi in which PCNL was performed were divided into two groups. Group A comprised 211 patients who had no previous open renal surgery and group B included 47 who had previous open renal surgery. In each group of patients the stone size, position, operation time, number of tracts, hospitalization time, residual stones and complication rates were recorded and were compared with each other.

**Results:** No significant differences were between the two groups concerning: hospitalization time, stone free rate, residual stones, per and post-operative complications (table). Group A Group B P value Hospitalization time  $2.7 \pm 2.1$   $3.5 \pm 2.7$  0.21 Stone free rate 74.9% (n = 158) 66% (n = 31) 0.28 Pelvis perforation 24 3 0.45 Per-operative heavy bleeding 9 (one nephrectomy) 1 0.78 Significant residual stones 43 12 0.56 Access to renal stone was considered more difficult in group B than in group A. Operation time is longer and transfusion rate is lower in PCNL after open surgery (0.04 and 0.03 respectively).

**Conclusion:** Due to the formation of fibrosis in patients who had previous open renal surgery access difficulties can be seen. PCNL can be performed with low complication and high success rates in patients who previous open renal surgery was performed.

### **MP9-19 THE ADVANTAGES OF THE PERCUTANEOUS NEPHROLITHOTOMY IN SUPINE POSITION (THE VALDIVIA TECHNIQUE). PERSONAL EXPERIENCE**

V. Bucuras, R. Bardan, A. Muresan, C. Balarie, C. Comsa, M. Georgiadis

**Background:** Aim of our study was to compare the efficacy and safety of the percutaneous nephrolithotomy (PCNL) in supine position (as described by Valdivia), with the "classical" technique, in prone position.

**Methods:** We have evaluated a number of 48 patients which underwent PCNL between 01 October 2008 and 30 June 2009. 24 patients (group A) were operated in the prone position, while the

other 24 patients (group B) were operated in the supine position. We have evaluated the following parameters: duration of intervention (from insertion of the ureteric catheter to nephrostomy tube insertion), blood loss (the difference between postoperative and preoperative hemoglobin levels), serum creatinine variation, duration of postoperative hospitalization, complications and stone free status.

**Results:** In patients from the group A, we have recorded the following results: the average duration of the intervention was 22.19 minutes, average blood loss 2.99 g/dL, serum creatinine level decreased in average with 0.06 mg/dL, medium postoperative hospitalization was 3.94 days; the complication rate was 37.5% (all complications were due to moderate intraoperative/postoperative bleeding, treated with conservative measures, not requiring any significant re-intervention). Patients from group B, had the following results: average duration of the intervention was 17.91 minutes, average blood loss was 2.48 g/dL, serum creatinine level decreased with 0.04 mg/dL, postoperative hospitalization time was 4.02 days. The complication rate was 41.66%: eight patients had moderate intraoperative/postoperative bleeding (solved by conservative therapy), one patient had colon perforation (closed spontaneously, with no re-intervention) and one pyelic perforation (also closed spontaneously). Stone free rate was 79.16% in group A and 83.3% in group B.

**Conclusion:** Percutaneous nephrolithotomy in supine position is effective and safe, having advantages over the prone position technique in patients with morbid obesity or associated cardiovascular pathology. The duration of the intervention is reduced (no re-positioning of the patient is needed), while the stone-free rate is slightly higher.

### **MP9-20 OUTPATIENT PERCUTANEOUS NEPHROLITHOTOMY: IS IT SAFE AND FEASIBLE**

M. Baptistussi, M. Morihisa, E. Gewher, A. Martins—Brasil

**Background:** To examine the role, indications and safety of outpatient percutaneous nephrolithotomy (PCN).

**Methods:** A retrospective review of consecutive (PCNs) done by a single surgeon over 2 years (10/2006–10/2008) was performed. Variables included age, stone side, stone size, use of a nephrostomy tube, hospital stay, and complications.

**Results:** A total of 66 (PCNs) were performed. Median age was 51.5 years (range:23–69). Forty-five procedures were on the left (68%), 21 were on the right (32%). Average and median stone size were 3.55 and 3 cm respectively (range 2–65). All patients had antegrade double-J (Cook Urological) internal stents placed. 42 procedures (64%) required overnight hospitalization and 24 procedures (36%) were hospitalized for more than a 24 hours. The younger patients was 80% (age < 40 anos). There was one complication for ileus. Four procedures were stone size were 3.05 and 3 cm respectively (range 2.3–4). Nephrostomy tubes were used. There were no complications or readmissions, and all patients were stone free at follow-up.

**Conclusion:** Our early experience indicates outpatients (PCN) is safe and effective in well selected patients. Review of our data revealed 3 criteria for consideration of outpatients (PCN): 1, stone size 4 cm or less, 2, younger patients in good health, and 3, the same surgeon doing the procedure.

## MP10: URETERAL STONES

### MP10-01 COMPARISON OF URETEROSCOPY AND EXTRACORPOREAL SHOCK WAVE LITHOTRIPSY IN THE TREATMENT OF DISTAL URETERAL CALCULI IN CHILDREN: A MULTICENTERIC RANDOMIZED CLINICAL TRIAL

A. Basiri, S. Zare, F. Sharifiaghdas, A. Tabibi, A. Aminsharifi, H. Ahmadnia

**Background:** To evaluate transureteral lithotripsy (TUL) and extracorporeal shock wave lithotripsy (ESWL) in children.

**Methods:** Sixty-eight children with distal ureteral calculi were randomized for treatment using ESWL on a Dornier Delta-2 and TUL with Pneumatic Lithotripter (34 patients in each group). The rate of stone-free, retreatment, auxiliary procedure, complications and efficacy quotient was assessed in each group, and compared. Follow up was performed using KUB plus Ultrasonography 2 weeks, and IVP 3 months, postoperation.

**Results:** Stone burden ranged from 15 to 50 mm<sup>2</sup> (mean 35 mm<sup>2</sup>) in TUL group and 20 to 56 mm<sup>2</sup> (mean 37 mm<sup>2</sup>) in ESWL group. The duration of procedures was 46 and 42 min in TUL and ESWL groups, respectively. Stone free rate 2 weeks and 3 months after TUL and single session ESWL were 82.1% vs 48.5% and 92.3% vs 77.5% respectively ( $P < 0.05$ ). With two session of ESWL, stone free rate increased to 82% after 3 months follow up. Retreatment was required in TUL and ESWL group, 17.4% vs 38% respectively. Auxiliary procedures such as ureteral stent replacement were needed in 10% of TUL and 12% of ESWL groups. Efficacy quotient rate was significantly higher for TUL than ESWL groups (83.7% vs 73.2%) ( $P < 0.05$ ). Minor complications were comparable and negligible in two groups ( $p < 0.05$ ).

**Conclusion:** It seems that both ESWL and TUL are effective for treatment of distal ureteral calculi in children. TUL have higher efficacy rate when performed meticulously with appropriate instruments in experienced hands.

### MP10-02 MEDICAL EXPULSION THERAPY: A SURVEY OF PRACTICE PATTERNS OF PRIMARY CARE PROVIDERS AND UROLOGISTS

S. Stroup, J. L'esperance, K. Stroup, B. Auge—USA

**Background:** Alpha-blockers and calcium channel blockers have shown promise for medical expulsion therapy (MET) of distal ureteral calculi <1 cm in size. Although MET has been discussed in urology for some time, little has been written about MET in the emergency medicine and primary care literature. We sought to evaluate current practice patterns of MET among urologists, emergency medicine physicians, other primary care providers, and frontline military care providers.

**Methods:** Web-based survey to assess the current practice patterns of providers for the initial management of uncomplicated ureteral calculi, and specifically, their frequency of using MET. Cross-tabulation strategies utilizing compiled survey results were used to assess survey outcomes.

**Results:** Of 293 medical professionals 114 (39%) were urologists, and 55 (48%) were fellowship trained in endourology. Fifty-six (19%) were emergency medicine physicians, 21 (7%) were family practitioners, 19 were internists and other primary care physicians, and medical paraprofessionals comprised the remaining 34%.

Overall 22.2% of respondents were unfamiliar with MET for expulsion of uncomplicated ureteral stones, including 13% of staff physicians, 19% of emergency medicine doctors, 56% of family practitioners, 40% of internists, and 43% of other primary care providers. All urologists were familiar with MET, but 30% rarely, never, or only sometimes used this therapy. Specifically, urologists, emergency physicians, family practitioners, internists, and other providers, usually or always used MET 69%, 55%, 16%, 16%, and 27%, of the time, respectively. In academic institutions, 71.6% use MET usually or almost always compared to 36% in military healthcare settings and 47% in other practice settings. Tamsulosin is the most widely used medication for MET, accounting for 57% of MET use. Factors identified that inhibit more wide-spread use of MET include, physician unfamiliarity with MET (72%), the belief that MET is not effective (10%), patient unwillingness to undergo MET (5%), and medications not covered by insurance plans (4%).

**Conclusion:** While MET has been established as a reasonable adjunct for management of uncomplicated ureteral stones, it may be underutilized due to physician unfamiliarity and with this type of treatment and perceived ineffectiveness. Education programs and practice-specific guidelines may help to improve the dispersion of MET into the general community.

### MP10-03 RIGID URETEROSCOPY CAN BE USED AS A FIRST LINE TREATMENT FOR THE MANAGEMENT OF DISTAL URETERAL CALCULI IN CHILDREN

C. Kara, B. Resorlu, M. Bayindir, A. Unsal

**Background:** Pediatric ureteroscopic stone treatment has been used widely as a minimally invasive method. We evaluated the safety and efficacy of rigid ureteroscopy for the treatment of distal ureteral stones in children.

**Methods:** The records of 19 male and 12 female (totally 31) children with a mean age 5.7 years (range 9 months to 14 years) treated with rigid ureteroscopy from November 2005 to June 2009 were retrospectively evaluated. All stones were located in the distal ureter. All patients underwent initial cystoscopy to place a guide wire. A 7.9/11.5 F semirigid pediatric ureteroscope and pneumatic lithotripter were used in all patients under general anesthesia. Complete disappearance of the stone considered as success.

**Results:** The mean stone size was 7.9 mm (range 5 to 14). Eighteen patients (58%) required balloon dilatation of the ureteral orifice. Each patient was cleared from the stone burden with a single session. The average operating time was 25.8 minutes (20–42). Stone free rate after ureteroscopy with pneumatic lithotripsy was 100%. There were no major intraoperative complications, although 5 (16.1%) patients required stent placement for mucosal laseration of ureter. Transient fever was seen in 3 (9.6%) patients which resolved with conservative treatment.

**Conclusion:** Ureteroscopy with pneumatic lithotripsy can be considered a primary treatment option for children with distal ureteral stones.

### MP10-04 SURGICAL MANAGEMENT OF URETERAL STONES DURING PREGNANCY A 10 YEARS EXPERIMENT

M. Mohamad Zadeh Rezaie—Iran

**Background:** Renal colic is a common problem during pregnancy, stones can be passed often easily but sometimes a stone may be impacted in the ureter or even a large renal stone may be found with refractory pyelonephritis. Here we report our experiment about surgical management of such stones.

**Methods:** In a case review study in Ghaem Hospital of Mashhad University of medical science in Iran, from 1998 to 2008, we found a total of 35 cases of symptomatic urinary tract stones during pregnancy which were considered refractive after 15 days of conservative treatment.

**Results:** Age range of our patients was 18 to 35 years and pregnancy age was between 2 and 8 months. The stone size in ureteral stones was between 6 and 18 mm and in renal stones was between 20 and 42 mm in diameter. Most of the ureteral stones were found in the lower ureter. Surgical interventions consisted of cystoscopy and Double-J stent insertion has been done in 5 patients. Ureterscopy and TULP (transurethral lithotripsy of pneumatic) and stone removal in 28 cases and open procedures for a large ureteral stone in 2 cases. No abortion or premature labor was recorded during our study period.

**Conclusion:** Invasive surgical procedures during pregnancy may impose considerable risk on pregnant mother or the fetus but in difficult stone cases which are non response to conservative therapies surgery must be considered as a salvage option. In experienced hand and with good anesthetic support these operations can be done safely.

#### MP10-05 OPTIMIZED MANAGEMENT OF URINARY STONE DISEASE IN THE PREGNANT POPULATION

W. White, N. Zite, J. Gash, W. Thompson, F. Klein—USA

**Background:** We present our institution's experience employing Low Dose Computed Tomography (LDCT) to direct therapeutic treatment of pregnant patients with suspected urolithiasis.

**Methods:** A retrospective review was performed to determine the peripartum outcomes of pregnant women presenting with intractable flank pain consistent with urolithiasis. Salient data including age, gestational age, urinalysis/urine culture results, and renal sonography findings were recorded. LDCT results were obtained and fetal radiation dosimetry calculated. Management decisions were reviewed and the postpartum course documented.

**Results:** Between November 2004 and June 2008, 46 women (mean age = 26.2 years) with a mean gestational age of 24 weeks were evaluated for intractable flank pain consistent with urolithiasis. All 46 patients demonstrated negative or equivocal (physiologic hydronephrosis) findings on renal sonography and underwent LDCT. Mean calculated fetal radiation dose was 945mrads ( $\pm$  548 mrads). LDCT demonstrated renal or ureteral stones in 29 patients (63%). Of this group, 11 were successfully managed conservatively, 14 underwent successful and definitive treatment with ureteroscopy, and 4 were temporized with ureteral stents and treated postpartum. Among those treated with ureteroscopy, no intraoperative complications were noted and no preterm labor was encountered. The remaining 17 patients with negative LDCT findings were successfully managed by the antepartum service without further intervention.

**Conclusion:** Optimal management of pregnant women with intractable flank pain must weigh the risks and benefits of diagnostic and therapeutic intervention to both the mother and fetus. Based on our experience, LDCT is of low fetal risk and yields critical diagnostic information that can better guide decision-making.

#### MP10-06 CALCIUM OXALATE NEPHROLITHIASIS: URINARY "MEDIUM SIZE PEPTIDES" ANALYSIS USING MICROBCA PROTEIN ASSAY D'ADESSI A., BONGIOVANNI L., VITTORI M., SACCO E., BASSI PF. DEPARTMENT OF UROLOGY, CATHOLIC UNIVERSITY SCHOOL OF MEDICINE, ROME, ITALY

A. D'addressi, L. Bongiovanni, M. Vittori, E. Sacco, P. Bassi

**Background:** In order to explore possible differences in urinary proteins between individual with and without urinary stones, we compared the medium size peptides urinary excretion of patients with calcium oxalate nephrolithiasis respect of healthy subjects, using the quantitative bicinchoninic acid method (BCA).

**Methods:** The urinary protein composition of 17 patients (11 male, 6 female; mean age 45 yrs  $\pm$  14SD) with calcium oxalate nephrolithiasis undergoing extracorporeal shock wave lithotripsy treatment (SWL), was assessed in comparison with 17 healthy subjects of the same age and sex. Exclusion criteria were recent episodes of renal colic, radiotransparent lithiasis, renal impairment; upper urinary tract obstruction. A urine sample was centrifuged for two times before stored. Lipid supernatants was further centrifuged using filters Microcon YM-10 and filters Biomax-5 Ultrafree in order to obtain in samples only peptides of molecular weight <10kDa and <5kDa. For the quantification of proteins, the MicroBCA Protein Assay Kit (Pierce Biotechnology, Rockford, USA) was used.

**Results:** Are expressed as a "ratio" of the total protein concentration in samples stored after double centrifugation [P], and the concentration achieved following further centrifugation using the two different types of filters [p]. Using filters limiting molecular weights to 5kDa the [P]/[p] ratio is in patients greater than in the control subjects (mean ratio = 117.73  $\pm$  13.60 SD vs 107.48  $\pm$  3.62 SD).

**Conclusion:** Patients with renal stone inside show lower concentrations of urinary peptides in the range mentioned above compared to the control subjects ( $p=0.001$ ). These results led to further research in order to clarify the significance and outcome that quantitative shortages of medium size peptides in patients actually have.

#### MP10-07 ENDOUROLOGICAL MANAGEMENT OF A SERIES OF SEVERELY ENCRUSTED AND RETAINED URETERAL STENTS D'ADESSI A., FOSCHI N., VITTORI M., RACIOPPI M., BASSI PF. DEPARTMENT OF UROLOGY, CATHOLIC UNIVERSITY SCHOOL OF MEDICINE, ROME, ITALY

A. D'addressi, N. Foschi, M. Vittori, M. Racioppi, P. Bassi

**Background:** Ureteral stent retention and encrustation can lead to renal failure, hydronephrosis and urinary sepsis. We report about the management of a series of patients.

**Methods:** Data of 8 patients, mean age 40.2 yrs, admitted for severely encrusted and retained ureteral stents over a 2 years period were reviewed. Only patients with large (>20 mm) or multiple calcifications were considered. Seven had the stent placed during treatments for urinary stones and one had a hydronephrosis secondary to a non-urological malignancy. Indwelling time was 7 months (range 4–11). Stent material was polyurethane or silicon, both hydrophilic coated or not. Two patients had large encrustations (diameter >25 mm) of the renal coil only, 5 had encrustations of the renal coil and of the stent body while one had macroscopic

calcifications from the renal to the bladder coil. All underwent ultrasounds and CT-scan. Treatment modalities were retrograde ureteroscopy (URS) and percutaneous nephrolithotomy (PCNL), alone or with ancillary procedures as anterograde ureteroscopy (AURS) and extracorporeal lithotripsy (SWL).

**Results:** Mean operating time was 180 min. Three patients needed 2 different endourological procedures (2 PCNL + URS and 1 PCNL + AURS) and one underwent two separate operative sessions. All were rendered stent and stones free without early complications. Seven had a new 6F ureteral stent placed to preserve ureteral mucosa. No patient underwent an open procedure.

**Conclusion:** Patients can require a combination of endourological procedures and also multiple operative sessions, but open procedures are today seldom necessary. High risk patients (stone formers, recurrent UTI) should be closely followed-up by a bi-monthly ultrasounds and for any patient subjected to a stent placement the date of the procedure should be recorded in a data base.

### MP10-08 OBESITY AND THE TREATMENT OF NEPHROLITHIASIS: A SYSTEMATIC REVIEW OF THE LITERATURE AND META-ANALYSIS

E. Hyams, L. Dulabon, O. Shah—USA

**Background:** The objective of our study was to delineate the relationship of obesity and treatment outcomes for nephrolithiasis based on a systematic review of the literature.

**Methods:** A systematic review of English language literature using MEDLINE was performed using keywords “obesity” plus each of the following: “nephrolithiasis,” “ureterolithiasis,” “kidney stone,” “shock wave lithotripsy or SWL,” “ureteroscopy,” and “percutaneous nephrolithotomy or PCNL.” All articles evaluating outcomes of nephrolithiasis based on body mass index (BMI) or other measure of patient weight were included.

**Results:** A systematic literature search revealed 26 studies (2 case reports, 15 case series, 8 retrospective comparisons, 1 prospective comparison) between 1988–2009 that evaluated treatments for nephrolithiasis based on BMI or other measures of patient weight. Seven studies compared PCNL outcomes in patients with overweight, obesity, or morbid obesity (1130) with normal body weight patients (980). No differences in stone free rates or complications were seen. Two series compared ureteroscopy outcomes in patients with overweight, obesity or morbid obesity (89) with normal body weight patients (72). No differences in stone free rates or complications were seen. No comparisons based on BMI were made regarding SWL outcomes; however, SWL success correlated with BMI and/or skin-to-stone distance in several series.

**Conclusion:** The literature supports use of PCNL and URS for treatment of nephrolithiasis in patients with overweight, obesity, and morbid obesity. Outcomes for SWL appear compromised by patient habitus. Both institutional and individual factors may determine which treatments are offered to patients; counseling patients regarding the risks and benefits of the different treatment options is essential.

### MP10-09 TREATMENT OF THE PROXIMAL URETERAL STONES WITH RIGID URETEROSCOPE

M. Baptistussi, M. Morihisa, E. Gewher, A. Martins—Brasil

**Background:** Ureteroscopy is used for treatment of ureteral stones. For treatment of proximal ureteral stones often have been recommended as a flexible ureteroscope. We report the results of rigid ureteroscopy in management of proximal ureteral stones.

**Methods:** In the patients with proximal ureteral stones a 8F rigid ureteroscope was used. If it was impossible to access the stone a ureteral catheter have been placed in the ureter and 2 days later ureteroscopy was repeated. Ureteral catheter after lithotripsy were used in specific cases in patient with large stones >1 cm and in patients in whom we had difficult ureteroscopy because of the caliber of ureter.

**Results:** We had 98 proximal ureteral stones which treated with rigid ureteroscope 62 men and 36 women. The average of age was 39 years. In 57 men and 33 women in the first time we could reach the stone and lithotripsy was done successfully with pneumatic probe. 5 men and 3 women needed ureteral catheter and a second procedure. In second ureteroscopy in 3 men and 1 women ureteroscopy and lithotripsy were done successfully and only in 2 men and 2 women treatment had failure.

**Conclusion:** Rigid ureteroscopy is a good procedure for treatment of proximal ureteral stones. In 95% of men and 93% of women with one stage the rigid ureteroscope with pneumatic probe treated the patients. 5% of men and 7% of women need second procedure and finally only in 3% of men and 5% of women we couldn't treat the proximal stones.

### MP10-10 URETERAL STONE LOCATION AT TIME OF EMERGENCY ROOM PRESENTATION IN PATIENTS WITH COLIC

B. Eisner, A. Reese, S. Sheth, M. Stoller—MA

**Background:** To define the position where stones lodge in the ureter when patients first present to the emergency department with colic.

**Methods:** A retrospective review was performed of 94 consecutive patients who presented to the emergency department with a chief complaint of colic and a computed tomography (CT) scan which demonstrated a single ureteral calculus. Stone position and size (axial diameter and coronal length) were recorded, as well as the position of the ureteropelvic junction (UPJ), where the ureter crosses over the iliac vessels, and ureterovesical junction (UVJ). Patients with a history of nephrolithiasis or history of ureteroscopic instrumentation were excluded.

**Results:** Ureteral stone position at the time of emergency department presentation for colic was as follows: UPJ –10.6%, between UPJ and iliac vessels –23.4%, at level of iliac vessels –1.1%, between iliac vessels and UVJ –4.3%, and at UVJ –60.6%. Proximal calculi had greater axial diameter than distal calculi (6.1 versus 4.0 mm,  $p < 0.001$ ) and greater coronal length than distal calculi (6.8 versus 4.1 mm,  $p < 0.001$ ). Both axial diameter ( $r = -0.47$ ,  $p < 0.001$ ) and coronal length ( $r = -0.55$ ,  $p < 0.001$ ) were moderately negatively correlated with stone position.

**Conclusion:** Upper ureteral stones were larger in axial diameter and coronal length than lower ureteral stones. At the time of emergency department presentation for colic, a majority of stones were located at the ureterovesical junction and in the upper ureter (between UPJ and iliac vessels). A minority were located at the UPJ and only 1 stone lodged at the level of the iliac vessels despite historical teaching that the UPJ and the level of the iliac vessels are two of the narrowest points of the ureter.

### MP10-11 STONE COMPOSITION DIFFERENCES IN SYNCHRONOUS BILATERAL RENAL CALCULI

Kyoko Sakamoto, Thomas Will, Alex Acosta-Miranda, Thomas Turk



**Introduction:** Although the kidneys in an individual are exposed to the same metabolic environment, the synchronous kidney stones are not always composed of the chemical compositions.

**Methods:** We retrospectively evaluated patients who underwent bilateral stone procedures including percutaneous nephrolithotomy, ureteroscopy and open stone surgery. Patients with cystine stones were excluded. Differences between stones were considered to be significant if the percentage ratio of similar mineralogical components varied by more than 20%.

**Results:** Of the 37 patients who underwent bilateral stone procedures for synchronous nephrolithiasis between 1999 and 2008, 32 patients were included in our study. Five patients were excluded due to lack of the information regarding the chemical analysis of the stones and due to cystine stones. Ten of the 32 (28%) patients reviewed had significant differences in stone composition between renal units. Variations in stone components were identified with no particular pattern evident.

**Conclusions:** Significant differences in stone composition can exist in synchronous bilateral nephrolithiasis between different renal units in select patients. These findings suggest differences in the local micro-environment, metabolism and urine chemistries between the kidneys.

### MP10-12 THE NATURAL HISTORY OF STONE FRAGMENTS FOLLOWING URETEROSCOPY

A. Macejko, V. Bhalani, P. Ramos, D. Rebeck, R. Nadler

**Background:** The goal of ureteroscopy is to fragment stones into particles small enough to pass spontaneously. Recent CT studies suggest that stone-free rates following ureteroscopy are only on the order of 50–54%. The goal of this study is to describe the natural history of small ( $\leq 4$  mm) stone fragments following ureteroscopy based upon CT follow-up.

**Methods:** Patients treated with ureteroscopy for urolithiasis from February 2000 to April 2006 by a single surgeon (RBN) were retrospectively identified. Patients with residual stone fragments measuring  $\leq 4$  mm on initial postoperative CT and at least one additional follow-up CT scan were included in our study. Outcomes measured were fragment passage (stone-free) and stone event (ER visit or stone procedure). The location and growth of stone fragments were also recorded.

**Results:** Twenty-two patients following 23 ureteroscopies met inclusion criteria. The overall mean follow-up was 32.4 months (2.7 years). The mean size of the residual stone fragment on initial postoperative CT, occurring at a mean of 2.92 months, was 2.6 mm. At one year, the size of stone fragments remained stable at 2.9 mm. For patients who underwent 3 year CT follow up, stone fragments were 2.98 mm. The majority of stone fragments were located in the lower pole. Five (21.7%) patients became stone free during follow-up, 3 of 5 (60%) in the first year following ureteroscopy. Five (21.7%) patients with residual stone fragments experienced stone events.

**Conclusion:** The majority of residual stone fragments following ureteroscopy remained small and stable in size. Twenty-one percent of patients eventually passed their fragments to become stone-free while another 21.7% experienced subsequent stone events.

### MP10-13 THE ACCORDION DEVICE FOR LIMITING URETERAL RETROGRADE STONE MIGRATION: INITIAL BRAZILIAN EXPERIENCE

A. Mitre, C. Gromatzky, G. Ebaid, F. Dénes, C. Pagotto, V. Pagotto—Brazil

**Background:** Retrograde migration of calculi remains a challenge during rigid ureteroscopic lithotripsy. This study was to assess the initial clinical experience in Brazil using the Accordion device to limit stone migration during ureteroscopic stone fragmentation.

**Methods:** Ten consecutive cases of ureteral calculi were treated with rigid ureteroscopy using either a ballistic lithotripter or holmium laser, with an Accordion device (PercSys) engaged proximal to the stone. Data was collected on stone size, hardness based on UH on CT, and migration of the stone during fragmentation.

**Results:** In all ten patients, the Accordion device passed the stones successfully. The device was visible clearly under fluoroscopic imaging. A total of 12 stones were treated, ranging in size from 0.7 to 12 mm. In one case, the device was removed prior to starting lithotripsy due to space limitations in a narrow ureter once the ureteroscope was inserted. Of the remaining 9 cases, no fragments migrated beyond the film occlusion in 7 patients, but in two laser cases small fragments ( $< 2$  mm) migrated past the occlusion due to highly dilated ureters. These fragments were eliminated spontaneously and required no further action. In one patient with multiple stones, two ureteral stones were treated without subsequent migration but a third stone at the ureteropelvic junction migrated to an inferior calyx; this stone was not considered for use with the Accordion device.

**Conclusion:** The Accordion device effectively occluded the ureter preventing retrograde migration of clinically relevant calculi or fragments during ureteroscopic pneumatic ballistic or laser lithotripsy.

### MP10-14 THE STONE BREAKER<sup>®</sup> LITHOTRIPTER FOR STONE FRAGMENTATION: OUR PRELIMINARY RESULTS

F. Cauda—Italy

**Background:** Aim of the study was to evaluate safety and effectiveness of a new device for stone fragmentation in clinical practice.

**Methods:** The study lasted from March to June 2009 and involved 40 patients treated for urinary stones by the same surgeon, both with ureteroscopic both with percutaneous procedures. Stone fragmentation was exclusively performed with Stonebreaker<sup>®</sup> (Cook Ireland Ltd), a pneumatic handheld, non-electric lithotripter which can be used via rigid or semi-rigid endoscope. We considered the following data: age, sex, side (right or left), location (ureter or pelvis/calix) and size of stones. Type of procedure, number of shock waves (SW), stone free rate, complications and post-operative hospital stay were recorded too.

**Results:** Mean age was 51 years, 25 patients were male and 15 female. Left: Right side of the stone was 22:18. Mean stone size was 13 mm (5–40 mm). Stone location was ureter in 15 cases and pyelocaliceal system in 25 cases. In 25 cases a supine PNL and in 15 cases an ureteroscopy was performed. Mean number of SW was 12 (2–25). No complications were recorded, in particular no perforation of ureter or bleeding were recorded, moreover no malfunctioning of the device was recorded. Stone free rate after the procedure (evaluated with RX KUB and/or abdominal US after 15 days from the procedure) was 97%. Mean post operative hospital stay was 2 days (1–4).

**Conclusion:** The results of our initial experience suggest that StoneBreaker<sup>®</sup> is a safe and effective device for stone fragmentation. It allows a quick, ergonomic and easy fragmentation, reduces the “stone dust” that impair endoscopic vision during

lithotripsy, and last but not least, it is atraumatic for the urinary mucosa.

### MP10-15 CLINICAL CHARACTERISTICS OF THE IMPACTED DISTAL URETERAL STONE SMALLER THAN 5 MM

J. Lim, E. Hwang, Y. Kim, D. Han, Y. Kim, C. Sul—Korea

**Background:** To analyze clinical characteristics of small impacted stones presenting in distal ureter, we reviewed retrospectively radiologic and ureteroscopic findings of impacted stones smaller than 5 mm.

**Methods:** From May 2004 to June 2008, we evaluated 27 cases with impacted distal ureteral stones. All of the patients were evaluated with unenhancing helical computed tomography (UHCT) and the secondary changes on UHCT associated with impacted ureteral stones (hydronephrosis, perinephric edema, and the tissue rim sign) were graded on a scale of 0–3. All of the patients were treated by ureteroscopic pneumatic lithotripsy (URSL) without significant complication. Ureteral lesions associated impacted stones were characterized on the basis of the ureteroscopic findings.

**Results:** There was a tendency toward significantly increasing grades of hydronephrosis and perinephric edema with increasing duration of stone impaction ( $P = 0.001$ ). Ureteroscopic observation showed severe mucosal edema associated stone in 9 (25.9%), ureteral stricture in 5 (18.5%), ureteral polyps in 4 (14.8%), and intramural impacted stone in 2 (7.4%). Concurrent ureteral lesion was associated with high grades hydronephrosis, and perinephric edema. The grade of hydronephrosis and perinephric edema were significantly higher in the group with ureteral lesion than the group without ureteral lesion ( $P = 0.002$ ).

**Conclusion:** Ureteroscopic observation revealed that long-term impacted stones are frequently associated with severe mucosal edema, strictures, and ureteral polyps. The secondary sign of urinary tract obstruction such as high degree of hydronephrosis and perinephric edema on the UHCT are seems to be useful sign in predicting the presence of concurrent ureteral lesions.

### MP10-16 CURRENT MEDICAL TREATMENT OF UROLITHIASIS: COMTEMPORARY THERAPY AND ITS EFFICACY DEPARTMENT OF UROLOGIC SURGERY, UNIVERSITY OF MINNESOTA, MINNEAPOLIS, MINNESOTA, USA \*DIETARY SERVICES, UMMC FAIRVIEW

O. Ortiz-alvarado, M. Stessman\*, C. Kriedberg, R. Miyaoka, M. Monga, A. Moeding\*

**Background:** To elucidate the effect of modern medical treatment of urolithiasis and its efficacy.

**Methods:** Retrospective cohort study of the patients treated in our stone clinics from July 2007 to February 2009. Patient's urinary risk factors for stone disease were evaluated with pre and post intervention 24 hours urine collections. Patients were initially recommended dietary changes, and those with persistent abnormalities were directed to medical therapy. Selective drug therapy was given based on metabolic abnormalities with: hydrochlorothiazide or indapamide prescribed for hypercalciuria, potassium citrate for hypocitraturia and allopurinol for hyperuricosuria. All subjects with persistent metabolic disruptions after diet management and at least two 24 hours urine collections were included. Medication dosages were titrated based on the follow-up urine parameters.

**Results:** One hundred and thirty-seven patients met the inclusion criteria with metabolic urine abnormalities of high calcium (37%),

high uric acid (13%) and low citrate (51%). Mean follow-up was 14.39 months. Mean age was 47.2 years and male to female ratio was 1.04. Significant changes were found in: 82% of subjects treated for hypercalciuria ( $337.40 \pm 112.13$  to  $183.62 \pm 92.99$  mg/day,  $p < 0.0001$ ), 72% of hyperuricosuric subjects ( $0.93 \pm 0.22$  to  $0.60 \pm 0.18$  grams per day,  $p < 0.0001$ ) and 67% of the hypocitraturic subjects ( $380.28 \pm 318.29$  to  $663.96 \pm 463.78$  mg/day,  $p < 0.0001$ ).

**Conclusion:** Medical management of stone disease should be instituted based on individual risk factors. These findings support the efficacy of patient-directed medical therapy for stone disease in patients refractory to lifestyle and dietary changes.

### MP10-17 STONE VOLUME—A PREDICTOR OF SPONTANEOUS URETERAL STONE PASSAGE

I. Sternberg, I. Kafka, I. Vardi, I. Leibovitch

**Background:** Uncomplicated ureteral stones may be managed either expectantly by medical expulsive therapy or by surgical extraction. The treatment of choice is largely guided by the probability of spontaneous stone passage which is affected by the stone's location and size. Stone size is usually measured as its diameter on axial CT. To the best of our knowledge, stone volume, as a predictor of its spontaneous passage, has not been assessed.

**Methods:** The records of all patients coded as renal colic during a six month period were retrieved, their CT scans were reviewed and follow-up data were recorded. Stone volume was calculated using an ellipsoid volume formula. Univariate and multivariate logistic regression were used to assess the correlation between spontaneous passage and stone volume.

**Results:** Complete data were available for 69 patients of which 51 (73.9%) passed the stone spontaneously and 18 (26.1%) needed surgical intervention due to lack of spontaneous passage. The minimal time to intervention was one week with patients with an intervention earlier excluded from the analysis. Stone volume was statistically significant both on univariate analysis ( $p = 0.008$ ) and multivariate analysis using stone volume and location ( $p = 0.014$ ). ROC curve analysis revealed a stone volume of  $80 \text{ mm}^3$  as the optimal cutoff for predicting spontaneous passage with a positive predictive value (PPV) of 70% and negative predictive value (NPV) of 67%. This cutoff had a PPV of 77% and a NPV of 70% for the spontaneous passage of distal ureteral stones. The median volume of passed and retained stones was  $40.9 \text{ mm}^3$  (mean  $79.5 \text{ mm}^3$ , 40.2–118.8 95%CI) and  $119.6 \text{ mm}^3$  (mean  $258.2 \text{ mm}^3$ , 63.5–452.8 95%CI), respectively.

**Conclusion:** Stone volume predicts the spontaneous passage of ureteral stones and can be used for this purpose with the advantage of incorporating both stone diameter and stone length into a single variable with a high PPV and NPV.

### MP10-18 USE OF MEDICAL EXPULSIVE THERAPY (MET) IN ACUTE UROLITHIASIS IN A SINGLE EMERGENCY ROOM SETTING

D. Kaplon, K. Babaian, S. Nakada—wi USA

**Background:** This study seeks to determine the prevalence of medical expulsive therapy (MET) use in the emergency room setting for ureterolithiasis. Referral patterns in surgical and metabolic follow up of urolithiasis were also assessed.

**Methods:** A retrospective review identified 556 patients with ureterolithiasis in the emergency department at our center between

2005 and 2007. Of these, 131 patients met inclusion criteria including first time stone formers and no prior urological visit within the past five years. Emergency room records were reviewed and telephone interviews were performed to determine if MET was utilized, if the patient was referred to a urologist, if surgery was ultimately required, and if a metabolic workup was ultimately performed.

**Results:** Average stone size was 4.19 (2–10) mm. Ten patients were admitted directly from the emergency room and 121 were discharged home. Of the 121 discharged patients, 48 (40%) were prescribed MET. Patients received tamsulosin 0.4 mg or doxazosin 2 mg in 46 and 2 patients, respectively. No patient was prescribed steroids. Mean size of passed was statistically significantly lower than mean size of stones that did not pass ( $p < 0.05$ ). Patients prescribed MET had a 23% chance of needing surgery versus 32% in those not prescribed MET ( $p < 0.05$ ). Metabolic workup was ultimately performed in 31 (23%) patients and was abnormal in 29 (95%).

**Conclusion:** In this single institution ER experience, 40% of patients with symptomatic ureteral calculi were treated with MET upon discharge from the emergency room. Our data also demonstrate that only patients referred to a urologist received a metabolic evaluation. This is noteworthy given that the vast majority of those undergoing evaluation were found to have a correctable abnormality.

### MP10-19 STATINS AND THE RISK OF UROSEPSIS AFTER ENDOUROLOGICAL PROCEDURES

J. Eswara, B. Chapin, D. Sacco

**Background:** Statins have been shown to reduce rates of infection and associated mortality in a variety of patient settings. We determined the risk of urosepsis related to statin use in patients undergoing endourological procedures.

**Methods:** We identified 100 consecutive patients who underwent endourological procedures for urolithiasis at our institution from 2008–2009. The procedures included ureteroscopy and laser lithotripsy (75), percutaneous nephrolithotomy (14), extracorporeal shock wave lithotripsy (7), and stent placement (4). All patients had negative urine cultures preoperatively and were treated with antibiotics for 1–7 days prior to surgery. The primary endpoint was urosepsis defined as postoperative fever requiring admission. Comorbidities

including diabetes and neurological disorders were identified. The rates of urosepsis were compared using the Fisher's exact test.

**Results:** Of the 23 patients who had been on a statin prior to the procedure, 2 developed urosepsis (8.7%). Of the 77 patients not on a statin, 4 developed urosepsis (5.2%), which was not significantly different than the statin group ( $p = 0.619$ ). All 6 patients who developed urosepsis underwent laser lithotripsy. Of the 9 diabetic patients in the study, 6 were on a statin and none was readmitted. Of the 4 patients with neurological disorders, none was on a statin and 1 developed urosepsis.

**Conclusion:** We found that the rate of urosepsis after stone procedures was similar between the statin and non-statin groups. These results suggest that the use of statins does not reduce the rate of urosepsis in patients undergoing endourological procedures.

### MP10-20 TREATMENT OF PROXIMAL URETERAL STONES SUCCESS RATES AND FINANCIAL COST OF TREATMENT WITH ESWL INSITU OR AFTER PUSH BACK THE STONE

R. Mahdavi Zafarghandi, M. Mahdavi Zafarghandi—Iran

**Background:** To compare the stone free rate and financial cost of in situ ESWL and push back proximal ureteral stone before ESWL.

**Methods:** This is prospective study that 90 cases with proximal ureteral stone were successively divided in 2 groups: for 45 cases (Group I) in situ ESWL were performed and for others 45 cases (Group II) at first we push back proximal ureteral stone into kidney with insertion ureteral stent and then ESWL were performed. Stone free rate and mean/person cost of both modalities was evaluated after a follow up during 3 months.

**Results:** In group I, one month after treatment stone free rate was 81% (37/45) and in group II, 94% (42/45). This stone free rate for group II statistically significant ( $P = 0.035$ ) but the financial cost in one session of ESWL was higher in group II compare to group I (4,000,000 Rials = 265 Euros VS 2,200,000 Rials = 150 Euros) but in group I, 35% of cases need more one ESWL session and more follow up visit, thus the final cost of two therapeutic modalities almost equal between two groups.

**Conclusion:** Pushback proximal ureteral stone before ESWL offers higher and faster stone free than in situ ESWL but the final cost of two therapeutic pathways are almost equal.

## MP11: ROBOTIC PROSTATE 1

### MP11-01 RAPID IMPLEMENTATION OF A ROBOTIC PROSTATECTOMY PROGRAM IN A LARGE HMO SETTING

H. Jung—USA

**Background:** We present the rapid implementation of a robotic surgery program by one of the largest health-maintenance organizations (HMOs) in the United States.

**Methods:** A core group of 10 Urologists were offered access to a new da Vinci S surgical system. Data including patient demographics, preoperative parameters, detailed operative times, pathologic outcomes, complications, and Expanded Prostate Cancer

Index-26 quality of life questionnaires were collected prospectively and centrally reviewed. Detailed operative times included, for example, time to control vascular pedicles and bilateral nerve-sparing and anastomosis times separately.

**Results:** 100 robotic prostatectomies were performed during the first 3 months of the program. The results are outlined in table format in meticulous detail.

**Conclusion:** At the current rate, after one year, one-third of the 1200 annual radical prostatectomies performed within this system will be completed robotically. This constitutes the most rapidly growing robotic prostatectomy program in the U.S.

### MP11-02 THE INCIDENCE OF LYMPHOCELES AFTER ROBOTIC-ASSISTED PELVIC LYMPH NODE DISSECTION

M. Patel, K. J Palmer, S. Chauhan, R. Ferreira Coelho, B. Rocco, V. Patel—US

**Background:** The incidence of lymphocele formation after pelvic lymph node dissection (PLND) during robotic-assisted laparoscopic prostatectomy (RALP) is unknown, especially in transperitoneal approaches. We sought to determine the incidence of lymphoceles in pts undergoing robotic-assisted PLND, and to determine predictive factors to its formation.

**Methods:** Over a 10 month period, 416 patients underwent RALP at our institution. We prospectively followed 76 patients who underwent PLND for ( $\geq$ cT2c, PSA  $\geq$  10, GI  $\geq$  7) PCa by obtaining pelvic CT within 6–12 weeks after the procedure. The PLND was limited to zones 1 & 2 as defined by Studer and performed via the PK bipolar system during RALP.

**Results:** At mean period of 10.8 weeks, 51% (39/76) of pts presented w/lymphocele of mean size of 4.3 $\times$ 3.2 cm. The range was from 1.5–12.3 cm, with 58.9% lymphoceles being  $>$ 4 cm in diameter. There was no significant difference in location of lymphocele, w/equal distribution of 32 lymphoceles on each side of pelvis. Of the patients with radiologically-apparent lymphoceles, 15.4% (6/39) presented w/clinical manifestations (pelvic pressure in 5, distended abdomen/ileus in 3, leg pain/weakness in 1, and costovertebral tenderness in 1). Of these pts, only one (1/39) required intervention for placement of CT-guided drain for an infected lymphocele causing an iliopsoas abscess. There was no correlation between EBL, BMI or the number LN dissected to the presence of lymphocele.

**Conclusion:** In our robotic series, rate of lymphocele formation after PLND of any size—irrespective of whether these were clinically apparent and/or required treatment—was 51%, despite the presence of peritoneal communication. Lymphocele formation is more common than is apparent clinically and is associated with a potential risk of serious complications.

### MP11-03 POSITIVE SURGICAL MARGINS AND THEIR LOCATIONS FOLLOWING ROBOT ASSISTED LAPAROSCOPIC PROSTATECTOMY: A MULTI-INSTITUTIONAL STUDY

S. Chauhan, G. Coughlin, M. Patel, R. Coelho, K. Palmer, V. Patel

**Background:** Robot Assisted Laparoscopic Prostatectomy (RALP) is gaining popularity as a treatment option for patients with clinically localized prostate cancer. At present, positive surgical margins (PSMs) are being used as a surrogate marker for the oncological efficacy of this procedure. We present a multi-institutional collaboration looking at the PSMs following RALP and their locations.

**Methods:** We collected the data retrospectively for 7416 patients who had undergone RALP between January 2002 and January 2009 over 7 institutions. The average number of patients per institution was 1059 and the median Gleason's grade was 6. The average age, BMI, pre-operative PSA and prostate weight were 61.7 years, 28.3 kg/m<sup>2</sup>, 7.3 ng/ml, and 49.6 gm respectively. A PSM was defined as the presence of cancer cells at the inked margin of the pathological specimen. Statistical analysis was done using SAS software for Windows.

**Results:** In our study, 1244/7416 patients (16.78%) had PSMs. The rate for pT2, pT3, pT4 was 10.36%, 37.63% and 57.19% respectively. The apex was the most common location (36.17%) followed

by posterior lateral (28.54%), multi-focal (13.83%) and bladder neck (11.82%). The frequency of apical margins was higher in pT2 stage. This discrepancy disappears with higher stage disease as posterior lateral, bladder neck and multifocal margins are more prevalent comparatively pT3 disease. This difference was statistically significant ( $p < 0.0001$ ).

**Conclusion:** The positive margin rate and distribution for robotic surgery is comparable to that of contemporary open and laparoscopic series. Apical margins are the most common in T2 disease but the discrepancy disappears in higher stage tumors as the posterior lateral and bladder neck become more prominent.

### MP11-04 CORRELATION OF BLADDER NECK LOCATION ON CYSTOGRAM PREDICTS EARLY RETURN OF CONTINENCE FOLLOWING ROBOTIC RADICAL PROSTATECTOMY

U. Boylu, M. Pinsky, B. Richardson, R. Thomas, B. Lee—USA

**Background:** Elucidation of return of urinary control following radical prostatectomy is multifactorial. Various contributing factors such as surgical technique, reconstruction of anatomic supporting structures such as the rectourethralis muscle have been reported. Such reconstruction leads to prevention of bladder neck descent on post operative cystogram. We evaluated the association between location of the bladder neck on cystogram after robotic prostatectomy to determine if there was a correlation with time to continence.

**Methods:** Following Institutional Review Board approval, we retrospectively evaluated cystograms of 56 patients who underwent robotic assisted radical prostatectomy. Measurements were taken from the top of the symphysis, and then the length of the bladder neck covered by symphysis was measured and divided by total symphysis length to generate a ratio to control for patient positioning. Patients were contacted and questioned for continence and time to continence. Patients with 0–1 pad were considered as continent. Pearson correlation test was used to analyze the association.

**Results:** There was a positive correlation between the time to continence and the bladder neck location ( $R = 0.28$ ,  $p = 0.04$ ). The lower the bladder neck location was, the longer the return of continence. At three months, there were 35 (63%) continent and 21 (37%) incontinent patients. The ratio was significantly lower in continent group (0.37) compared to incontinent group (0.53) ( $p = 0.002$ ).

**Conclusion:** The bladder neck location predicts early return of continence following robotic assisted radical prostatectomy. In patients with a higher bladder neck location, urinary control is regained earlier.

### MP11-05 CONTINENCE AND POTENCY IN ELDERLY FOLLOWING ROBOTIC RADICAL PROSTATECTOMY

S. Shikanov, V. Desai, A. Razmaria, D. Lifshitz, G. Zagaja, A. Shalhav—USA

**Background:** There is accumulating evidence that elderly patients with localized prostate cancer may benefit from radical prostatectomy (RP). Recently, robotic RP has gained acceptance. This study evaluated the probability for continence and potency following robotic RP in elderly.

**Methods:** The cohort included 1436 robotic RP cases performed at our institution between 2003 and 2008. Continence (being pad-free) and potency (erections sufficient for intercourse) at 1 year following surgery were assessed by UCLA-PCI self-administered

validated questionnaire. The outcomes were modeled using binary regression adjusting for age, bilateral nerve-sparing (NS), baseline IPSS and SHIM scores. From these models we calculated the predicted probabilities for continence and potency at 65, 70 and 75 age strata. Preoperatively impotent patients or receiving hormones or radiation within 1 year following surgery were censored.

**Results:** Mean (range) age was 59 (38–85) years; 77 (5%) of patients were  $\geq 70$  years. Age (OR 0.97,  $p=0.002$ ), baseline IPSS (OR 0.98,  $p=0.002$ ) and SHIM scores (OR 1.02,  $p=0.003$ ) were independent predictors of continence. Age (OR 0.92,  $p<0.0001$ ), baseline SHIM score (OR 1.1,  $p<0.0001$ ) and bilateral NS (OR 2.9,  $p<0.0001$ ) were independent predictors of potency. Predicted probabilities (95% CI) of continence at ages 65, 70 and 75 were 0.63 (0.57, 0.67), 0.59 (0.51, 0.66) and 0.55 (0.45, 0.65). The corresponding probabilities for potency following bilateral NS were 0.66 (0.61, 0.70), 0.56 (0.48, 0.63) and 0.46 (0.36, 0.56).

**Conclusion:** In our experience robotic RP yields acceptable functional outcomes in selected elderly patients providing a viable therapeutic option for localized prostate cancer in this population.

#### MP11-06 PERI-OPERATIVE PREDICTORS OF BEING PAD-FREE AT 12 MONTHS FOLLOWING ROBOTIC-ASSISTED LAPAROSCOPIC PROSTATECTOMY

T. Deklaj, A. Razmaria, S. Shikanov, D. Lifshitz, A. Shalhav, G. Zagaja—USA

**Background:** To identify peri-operative predictors associated with being pad-free 12 months following robotic-assisted laparoscopic prostatectomy (RALP).

**Methods:** We reviewed our institution's prospectively-maintained RALP database. Between May 2003 and February 2008, 1 surgeon (GPZ) performed a total of 787 RALP procedures for clinically-localized prostate cancer. Continence was defined as zero pad usage at 12 months and was derived from the validated, self-administered UCLA PCI questionnaire. Clinico-pathological and surgical data were analyzed in patients with adequate follow-up. The outcome was modeled with multi-variate logistic regression.

**Results:** A total of 534 (67.8%) patients had at least 12 months follow-up. Mean age was 59.4 (SD = 6.7) years with a mean BMI of 28.3 (SD = 4.2). 108 (20.2%) of the subjects were African American. 392 (73.4%) patients presented with stage T1c disease, with a mean pre-operative PSA of 6.1 (SD = 3.5), SHIM score of 19.6 (SD = 6.9) and IPSS of 7.5 (SD = 6.0). At 12 months, 344 (64.4%) patients reported being pad-free. In multi-variate analysis, race (African American) (OR 0.56,  $p=0.012$ ) predicted the usage of pads whereas the absence of pre-operative urinary leakage (OR 2.19,  $p=0.006$ ) and a bilateral nerve-sparing procedure (OR 1.63,  $p=0.03$ ) were predictive of being pad-free. There was a trend towards younger age being associated with zero pad usage (OR 0.97,  $p=0.06$ ). Multi-variate logistic regression analysis OR OR 95% CI p value Age (years) 0.968 0.936–1.00 0.06 Race (African American) 0.559 0.355–0.879 0.01 Pre-operative IPSS 0.986 0.953–1.020 0.41 Pre-operative SHIM 1.021 0.990–1.053 0.18 Bilateral Nerve Preservation 1.626 1.041–2.539 0.03 Pre-operative Urinary Leakage 2.191 1.248–3.845 0.006

**Conclusion:** Our results indicated that race (non-African American), the absence of pre-operative urinary leakage and a bilateral nerve-sparing procedure are independent predictors of achieving a pad-free status 12 months following RALP.

#### MP11-07 ARE PATIENTS' EXPECTATIONS MET AFTER ROBOTIC ASSISTED RADICAL PROSTATECTOMY?

A. Razmaria, S. Shikanov, D. Lifshitz, K. Zorn, G. Zagaja, A. Shalhav—USA

**Background:** Recently it has been speculated that robotic-assisted laparoscopic radical prostatectomy (RALP) leads to unreasonably high expectations translating into lower satisfaction compared to the open procedure. Herein we evaluated how patients assess the results of RALP relative to their expectations.

**Methods:** 900 patients 7 months or longer after surgery were contacted. A third party epidemiological service at the Department of Social Sciences conducted a phone survey. Continence (pad-free), potency and recurrence-free status (PSA  $< 0.1$  ng/ml) were assessed. A five-level Likert item question evaluated to which extent the surgery and its outcomes met patients' expectations.

**Results:** 682 patients (76%) completed the survey. Among them 52 patients (7.6%) reported that their expectations regarding the surgery and its outcome were not met (Group 1). 630 patients (92.4%) referred to their expectations as being met (Group 2). Out of Group 2, 438 (64% overall) stated that their expectations were exceeded. No difference in age, PSA, stage, Gleason Score, positive-margin rate and recurrence rate was observed between the two groups. Likewise the mean time of follow-up was similar in both groups (26 months  $\pm 16$ , versus 27 months  $\pm 14$ ). Lower preoperative IPSS (mean 10.6  $\pm 8$  versus 7.6  $\pm 6$ ;  $p=0.008$ ), higher postoperative pad-free rate (22% versus 68%; OR 2.5,  $p=0.004$ ) and higher postoperative potency rate (21% versus 58%; OR 4.8,  $p<0.0001$ ) proved to be independent predictors of meeting patients' expectations.

**Conclusion:** This study suggests that RALP overwhelmingly meets or exceeds patients' expectations at our institution. We assume that surgeon's presentation of realistic outcomes plays an important role in forming patient's expectations and hence influencing the overall satisfaction.

#### MP11-08 MEDIAN LOBE IN ROBOTIC PROSTATECTOMY: BLADDER NECK RECONSTRUCTION AND PELVIC DRAIN NOT ROUTINELY REQUIRED

H. Martinez-suarez, A. White, R. Abaza—USA

**Background:** A median lobe (ML) may affect the outcomes of robotic prostatectomy. We do not routinely perform cystoscopy prior, use pelvic drainage or bladder neck reconstruction. We assessed the incidence of a ML among our patients and compare their outcomes, specifically addressing whether bladder neck reconstruction (BNR) or use of a drain was needed.

**Methods:** We reviewed 250 consecutive robotic prostatectomies to identify patients with a median lobe and their perioperative outcomes as compared to those without.

**Results:** Forty patients had a ML (16%). Mean operative time was 171.7 min and 165.5 min, respectively ( $p=0.36$ ). Mean blood loss was 145 mL (50–500 mL) in those with a ML, which was higher than the 116 mL (20–500 mL) in those without ( $p=0.02$ ). No patients with ML required transfusion while 1.4% of others did. Mean gland size of 73.5 g (35.9–148.1g) was larger in those with a ML compared with 51.7 g (25.5–151.7g) in those without ( $p<0.005$ ). There was no difference between those with and without a ML in length of hospitalization (1.0 vs 1.0days,  $p=0.56$ ), catheterization time (5.08 vs 5.77days,  $p=0.13$ ), anastomotic leak on cystogram (2.6% vs 1.5%,  $p=0.15$ ), drain use

(2.5% vs 1.4%,  $p=0.42$ ), or need for BNR (7.5% vs 3.3%,  $p=0.22$ ).

**Conclusion:** Patients with a ML had a greater gland size and blood loss but no additional need for transfusion, bladder neck reconstruction, or drain use and no additional catheterization time or risk of leak. With proper handling, a ML can be addressed without adverse affect outcomes and without routine use of pelvic drainage or BNR.

### MP11-09 IMPROVED OUTCOMES FOLLOWING ROBOT-ASSISTED RADICAL PROSTATECTOMY: TECHNIQUE AND/OR EXPERIENCE?

J. Davis—USA

**Background:** A wide range of oncologic, functional, and safety outcomes have been reported following radical prostatectomy (RP), and attempts have been made to link them to surgeon experience, technique, and/or access (open, laparoscopic (lap), robotic-assisted (RA), etc.). An unmet need in surgery for prostate cancer is to identify the ideal surgical techniques and to design efficient training programs that ensure reproducible outcomes. In this hypothesis generating study, a single surgeon's range of results over time were studied as a framework for future studies of RARP training outcomes.

**Methods:** A single surgeon trained in open RP during residency (1996–99), and fellowship (2001–2002), lap-RP during a 6 month fellowship (2002), and self-taught RARP starting in 2004. Yearly RP volumes from 2003–2008 were 32, 50, 75, 119, 195, and 233. Years 2003–2004 were a mix of lap and open, and 99% of all cases 2005 and forward were RA. Years 2003–2006 were in Eastern Virginia and 2006 to date at M.D. Anderson Cancer Center. RP cases were assessed for available oncologic outcomes, functional outcomes, and complications. Changes in technique that may be linked to outcomes and/or complications were prospectively annotated.

**Results:** During the period of study, the operation was sub-divided into 11 steps with the number of changes in parentheses: drop bladder (1), endopelvic fascia (2), dorsal vein (3), anterior bladder neck (2), posterior bladder neck (2), vas/seminal vesicles (4), nerve bundles (3), apex (2), nodes (1), posterior anastomosis (2), and anterior anastomosis (2). Nerve sparing descriptors went from 3 (bilateral, unilateral, non) to 9 (high vs low fascia release, incremental nerve sparing, etc.). Positive surgical margins in the 1st 150 cases in Virginia were 26% (16% pT2), in the first 2 years at MDACC were 12.2% (7.2% pT2), and in the last 100 cases were 2% (1.2% pT2). Lymph node yields with standard templates in 2006–2008 were 8.5 (range 1–47) and in the last 100 with extended templates were 18 (range 6–47). Functional surveys using EPIC (Expanded Prostate Cancer Index Composite) for 2006–2007 (2008–9 pending) showed baseline EPIC urine function/bother baseline 92/83, 6-months 82/83, and 12 months 86/87. EPIC sexual function/bother were baseline 52/68, 6 months 24/41, and 12 months 32/46. Complications in 2006 were 5% major/14% minor, and from 2007–2008 1.3% major/4.5% minor ( $p=0.005$ ). Of complications in 2006, 45% resulted in technique or management changes.

**Conclusion:** Improved short-term oncologic and complication rates were demonstrated in a single surgeon series of 760 cases of RARP, and further follow-up is needed to evaluate changes in functional outcomes. A potential benefit of RARP worthy of further study is whether or not detailed training curricula, possibly with simulators, can be developed such that new surgeons can duplicate results without extended learning curves.

### MP11-10 POSTERIOR RECONSTRUCTION OF RECTOURETHRALIS MUSCLE PRIOR TO URETHROVESICAL ANASTOMOSIS IMPROVES EARLY RETURN OF CONTINENCE IN PATIENTS UNDERGOING ROBOTIC ASSISTED RADICAL PROSTATECTOMY

U. Boylu, M. Pinsky, B. Richardson, R. Thomas, B. Lee—USA

**Background:** Several techniques of anterior, posterior, or combined reconstruction of the rectourethralis muscle prior to urethrovesical anastomosis were reported to improve early urinary control. We investigated the effect of three different reconstructive techniques on the return of continence.

**Methods:** A total of 94 patients underwent robotic assisted radical prostatectomy between 2008–09 and were prospectively included in the study. Institutional Review Board approval was obtained. In posterior reconstruction (PR,  $n=29$ ), a suture was placed posterior to the urethral stump and bladder neck to add support. Anterior suspension (AS+PR,  $n=29$ ) was performed as suturing bladder neck to the pubic symphysis in addition to posterior reconstruction. No reconstruction (NR) was performed in 36 patients. Patients with 0–1 pad were considered as continent. Time to continence was recorded and Kaplan-Meier analysis was performed. Comparison between groups was conducted with Log Rank test.

**Results:** Mean estimated time to continence was 8.8 weeks (95% CI 4.3–13.2) in PR group, 16.2 weeks (95% CI 11.7–20.6) in AS+PR group, and 18.1 (95% CI 13.1–23.2) in NR group. Time to continence was significantly shorter in PR group ( $p=0.003$ ). There was no significant difference between AS+PR and NR groups.

**Conclusion:** Posterior reconstruction of the urethrovesical anastomosis improves early return of continence in patients undergoing robotic assisted radical prostatectomy. Continence returns in a mean of 8.8 weeks after surgery in patients with posterior reconstruction.

### MP11-11 PREDICTORS OF POSITIVE SURGICAL MARGIN IN ROBOTIC ASSISTED RADICAL PROSTATECTOMY

U. Boylu, M. Pinsky, B. Lee, R. Thomas—USA

**Background:** Previous studies suggested different factors affecting surgical margin status during radical prostatectomy. Our purpose was to determine the predictors of positive surgical margins (SM) in robotic assisted radical prostatectomy (RARP).

**Methods:** Between 2002 and 2009, a total of 625 RARP was performed. After the Institutional Review Board approval, a retrospective chart review was performed. Potential factors including biopsy Gleason score, PSA, prostate volume, SM status, type of nerve sparing, operative time, perineural invasion, and lymphovascular invasion were evaluated. Logistic regression was performed to define the independent predictor for positive SM.

**Results:** Surgical margins were positive in 114 (18%) patients. Average Gleason score was 6.34 in SM+ group and 6.57 in SM– group. Mean PSA was 7.1 ng/ml in SM+ group and 7.9 ng/ml in SM– group. Mean operative time was 216 min and 259 min in SM+ and SM– groups respectively. Bilateral nerve sparing was performed in 458, unilateral nerve sparing was performed in 110, and no nerve sparing was performed in 57. Mean prostate volume was 47.8 g in SM– group and 42.9 g in SM+ group. There were 68 pT2 or less and 46 pT3 or higher in SM+ group. The location of the surgical margin was posterolateral in 47 (41%), apex in 37 (32%), anterior in 21 (19%), and bladder neck in 9 (8%) patients. Peri-

neural invasion was found as an independent predictor of positive SM (OR = 3.1, 95% CI 1.1 to 8.6). None of the other factors had a statistically significant effect on surgical margin status.

**Conclusion:** Our study demonstrated that presence of perineural invasion in prostate specimen is associated with a 3-times more risk of positive surgical margin during RARP.

### MP11-12 TECHNIQUES FOR EARLY RECOVERY OF CONTINENCE IN PATIENTS WITH ROBOTIC-ASSISTED PROSTATECTOMY

G. Sung, T. Kim—Korea

**Background:** With the introduction of the da-Vinci system, many techniques have been reported to improve the quality of life for patients undergoing robot-assisted radical prostatectomy (RARP). We would like to report our results from using the posterior reconstruction and ultra-dissection technique.

**Methods:** From December 2007 to April 2009, we analyzed the postoperative data of 80 patients that had undergone RARP. There were 32 patients in the A group where the posterior reconstruction and the ultra-dissection technique were not performed. In group B of 28 patients, only the posterior reconstruction technique was performed. In Group C of 20 people where both techniques were utilized. We analyzed the recovery of continence in these 3 groups. We defined 'recovery of continence' as the usage of 1 pad or less within 24 hours.

**Results:** Mean age was similar among 3 groups (65.9 years in group A, 65.3 years in group B and 64.7 years in group C ( $p=0.69$ ). Preoperative mean PSA was 9.5 ng/ml, 10.4 ng/ml and 9.1 ng/ml ( $p=0.45$ ) in each group. Mean BMI was 24.3 kg/m<sup>2</sup>, 23.9 kg/m<sup>2</sup> and 24.9 kg/m<sup>2</sup> ( $p=0.43$ ) and the mean prostate volume was 33.8 g, 39.2 g and 36.8 g ( $p=0.15$ ) in each group. Mean operative time was 237.6 min, 203 min and 168.5 min ( $p=0.23$ ). Mean blood loss was 229.7 cc, 202.8 cc and 146.2 cc ( $p=0.61$ ). Mean catheter duration was 8.7 days, 6.4 days and 5.9 day in each group. In group A, there were 2 patients with urine leakage, while group B and C were none. Recovery rate of continence was 34.8% at 1 month, 34.8% at 3 month, 31.8% at six month in group A. Group B was 57.2%, 32.1% and 7.1% at each interval. Group C was 80% at 1 month and 20% at 3 month. Overall at 6 month, the recovery rate of continence was 90.6% in group A, 96.4% in group B, 100% in group C. The positive surgical margin rate was 31.2% in group A, 21.4% in group B, 30% in group C.

**Conclusion:** In RARP, the posterior reconstruction and ultra-dissection techniques showed the decreased rate of urine leak and increased early recovery of continence. But within the ultra-dissection cases, the rate of positive surgical margin has increased. Therefore, efforts need to be directed to decrease the rate of positive surgical margin, while increasing the quality of life for the patients.

### MP11-13 A COMPARISON OF ROBOTIC ASSISTED VERSUS PURE LAPAROSCOPIC RADICAL PROSTATECTOMY: A SINGLE SURGEON EXPERIENCE

K. Tae Hyo, G. Sung, W. Cho, W. Lee—Korea

**Background:** We compared a single institution experience with radical prostatectomy using a pure laparoscopic technique vs robotically assisted technique with regard to preoperative, intraoperative or postoperative parameters.

**Methods:** From May 2006 to May 2008 we reviewed 70 consecutive patients who underwent robot assisted radical prostatectomy

and compared them to 70 match-paired patients treated with a pure extraperitoneal laparoscopic approach. The patients were matched for age, body mass index, prostate specific antigen, pathological stage and Gleason score. Preoperative, perioperative and postoperative data, including complications and oncological results, were analyzed between the 2 groups.

**Results:** The 2 groups were statistically similar with respect to age ( $p=0.45$ ), body mass index ( $p=0.05$ ), prostate specific antigen ( $p=0.28$ ), Gleason score and clinical stage ( $p=0.51$ ). The group of robotic surgery showed statistical differences in regarding operative time ( $p=0.01$ ), estimated blood loss ( $p=0.02$ ), bladder catheterization ( $p=0.013$ ) than laparoscopic surgery group. The percentage of major complications was 17.0% vs 2.1%, respectively ( $p=0.03$ ). The overall positive margin rate was 34.2% vs 21.4% for laparoscopic radical prostatectomy and robotic assisted laparoscopic prostatectomy, respectively ( $p=0.12$ ).

**Conclusion:** We demonstrated that the robot assisted laparoscopic radical prostatectomy is superior to laparoscopic radical prostatectomy with respect to operative time, operative blood loss, length of bladder catheterization.

### MP11-14 ASSESSMENT OF LYMPH NODE YIELD IN ROBOTIC ASSISTED PROSTATECTOMY AND OPEN RADICAL PROSTATECTOMY IN THE CONTEMPORARY ERA

M. Truesdale, P. Cheetham, D. Lee, K. Badani—USA

**Background:** Some have questioned whether surgeons performing robot-assisted prostatectomy (RALP) retrieve an adequate lymph node yield. We sought to evaluate and compare lymph node yield from RALP and open prostatectomy (RP) at a major tertiary care center.

**Methods:** A retrospective study was performed using data from the Columbia Urologic Oncology Database in the contemporary PSA era. Between January 2005 and October 2008, 161 consecutive patients underwent RP. Between November 2007 and October 2008, 77 consecutive patients underwent RALP by a single surgeon. In men with D'Amico intermediate or high-risk disease, an extended PLND was performed.

**Results:** Those who underwent RALP were significantly younger ( $p=0.04$ ), and had lower Gleason sums ( $p=0.02$ ). RP had longer operative time (204 minutes vs. 153 minutes,  $p=0.03$ ) and higher estimated blood loss than RALP (940cc vs. 158cc,  $p<0.01$ ). Men who underwent RALP with D'Amico low risk disease had a statistically lower lymph node yield compared to those who underwent RP. Median lymph node yield for Gleason 6 was 2.5 and 6 for RALP and RP, respectively, ( $p=0.003$ ). For pT2 disease, median yield was 4.5 and 5 for RALP and RP, respectively ( $p=0.026$ ). In D'Amico intermediate and high-risk men, LNY was not significantly different in the two groups.

**Conclusion:** Men who had higher stage and grade disease and underwent either RP or RALP did not exhibit any significant differences in lymph node yield. Blood loss and operating time were less in RALP than RP. These findings will require validation in a multi-center setting.

### MP11-15 LYMPH NODE YIELDS WITH PELVIC LYMPHADENECTOMY DURING ROBOTIC-ASSISTED LAPAROSCOPIC RADICAL PROSTATECTOMY ARE HIGHER THAN WITH OPEN RADICAL RETROPUBIC PROSTATECTOMY

E. Trabulsi, T. Chandrasekar, F. Lee, P. Mccue, C. Lallas, A. Colon—USA

**Background:** Robotic-assisted laparoscopic radical prostatectomy (RALP) attempts to replicate the surgical and oncologic outcomes of open radical retropubic prostatectomy (RRP). Pelvic lymphadenectomy has both diagnostic and therapeutic implications for the surgical treatment of prostate cancer, but has not been extensively studied for RALP. We compared the lymph node yields after pelvic lymphadenectomy for RALP and standard open RRP.

**Methods:** We examined our departmental, IRB approved, retrospective database of radical prostatectomy procedures performed by several surgeons from 2001 until 2008. A total of 881 patients underwent radical prostatectomy, including 307 open RRP and 574 RALP. Patients undergoing bilateral pelvic lymphadenectomy were included for analysis, including 297 open RRP and 472 RALP; patients who had a unilateral or no PLND performed were excluded (112 total). The boundaries of pelvic lymphadenectomy were standard for each surgical approach, including the template commonly referred to as the obturator lymph node packets. The pathologic processing technique was standard over this time period. Lymph node yields and lymph node involvement for each surgical approach were examined and compared. Statistical analysis was performed using the SPSS statistical package, using the Student's t-test.

**Results:** The mean lymph node yields for RALP and RRP were 6.9 (median 6.0, range 0–38) and 6.0 (median 5.0, range 0–23), respectively ( $p=0.01$ ). The interquartile range for RALP and RRP was (3–9) and (3–8), respectively. The percentage of patients with lymph node involvement was 1.1% for RALP and 2.7% for RRP, respectively ( $p=NS$ ).

**Conclusion:** Despite controversy regarding the adequacy of RALP for pelvic LND, when compared to RRP, the lymph node yields were slightly higher when performed robotically in a large, single institution surgical series.

#### MP11-16 ROBOTIC-ASSISTED LAPAROSCOPIC PROSTATECTOMY: FUNCTIONAL AND ONCOLOGIC OUTCOMES WITH A MINIMUM 12 MONTH FOLLOW-UP

H. Lavery, F. Nabizada-pace, J. Carlucci, D. Samadi—USA

**Background:** Despite the increasing use of robotic-assistance for radical prostatectomy, long- and intermediate-term outcomes data remains sparse. Results from large series with follow-up longer than a year have only recently been reported.

**Methods:** An institutional database of 1418 robotic-assisted laparoscopic prostatectomies (RALP) by a single surgeon (DSS) was queried for patients with follow-up 12 months or longer after RALP. Continence was defined as the use of zero or one security pad daily. Potency was defined as erections sufficient for vaginal penetration with or without phosphodiesterase-5-inhibitors in men who were potent preoperatively. Focal and extensive positive surgical margins were defined as tumor present at the inked margin less than or greater than 2 mm, respectively. Biochemical recurrence was defined as  $PSA > 0.2$  ng/ml.

**Results:** Outcomes data was available on 497 patients with follow-up longer than a year from surgery. Mean follow-up was 21 months, with a range from 12 to 76 months. Pathologic stage was pT2a-c in 79%, pT3–4 in 21%. Gleason scores were 6 or less in 29%, 7 in 63% and 8–10 in 8%. Bilateral nerve-sparing was performed on 87%. Continence was achieved in 91% and potency in 77%. Positive surgical margins were present in 18%: 7% focal and 11% extensive. Margin rates were 12% and 44% in organ-confined

and non-organ-confined disease, respectively. Biochemical recurrence occurred in 5.9%.

**Conclusion:** Excellent outcomes at one year can be achieved with RALP. Our data confirms similar recently reported RALP series and compares favorably with open radical prostatectomy outcomes from centers of excellence.

#### MP11-17 ROBOT ASSISTED PROSTATECTOMY: A SINGLE CENTRE EXPERIENCE OF 1000 CASES

D. Porres, A. Schuette, C. Wagner, V. Zugar, J. Witt

**Background:** The robot assisted radical prostatectomy (RARP) with the daVinci system becomes more and more a well established minimal invasive therapy of localized prostate cancer all over the world. The aim was to describe the experience and oncological and functional outcomes of this method in our institution.

**Methods:** 1000 consecutive patients underwent RARP with the daVinci system in our institution since March 2006. The perioperative results, complications and postoperative oncological and functional data were analyzed prospectively.

**Results:** Mean age of the patients was 63.0 years and all of them had a clinical stage  $\leq$  cT3a with a mean preoperative PSA level of 10.2 ng/ml. The overall mean surgery time was 157 minutes and it could be improved from 234 minutes in the first 100 cases to 151 minutes in the last 100 cases. The mean blood loss was 165 ml and the transfusion rate was 0.6%. The overall complications were bowel lesion in 0.7%, port infection/hematoma in 0.7%, camera-port-hernia in 0.7%, symptomatic lymphocele in 0.3% and stricture of the anastomosis in 0.5% with a conversion rate of 0.5% and a reintervention rate of 0.8%. The oncological results showed stage pT2 in 77.6%, stage pT3 in 19.5% and stage pT4 in 2.1%. The positive margin rate in pT2-tumors could be improved from 8.2% in the first 100 cases to 3.0% in the last 500 patients and the overall positive margin rate in pT3-tumors was 16.5%. The functional results were assessed after 3, 6 and 12 months and showed that 93.4% of the patients were pad-free continent after 12 month.

**Conclusion:** The RARP is a well established minimal invasive therapy in the management of localized prostate cancer. As a high volume prostate cancer center we could demonstrate our continued improvement of this technique. The growing experience of 1000 cases in the last three years showed excellent oncological and functional results that are at least as good as in open surgery.

#### MP11-18 REDUCTION OF PT3 POSITIVE SURGICAL MARGINS IN ROBOT-ASSISTED LAPAROSCOPIC RADICAL PROSTATECTOMY: DOES THE APPLICATION OF PARTIN NOMOGRAM OFFER A MEANINGFUL RESULT?

J. Jeong, E. Choi, D. Kang, I. Kim—USA

**Background:** Intrafascial nerve sparing is associated with improved potency and continence and is routinely used at our institution. However, initial analysis demonstrated that the positive surgical margin (PSM) rate in pT3 disease was unacceptably high. To reduce the risk of PSM in the patients with non-organ confined prostate cancers after robot-assisted laparoscopic radical prostatectomy (RALRP), we applied the Partin nomogram in determining the nerve sparing technique during RALRP.

**Methods:** From July 2008 to June 2009, 148 patients were candidates for bilateral nerve sparing procedures (Gleason 7 or less, PSA less than 10, and cT2a or less). All of the first 70 patients (Cohort I) had intrafascial nerve sparing. Because initial analysis demonstrated the PSM rate to be high in patients with pT3 disease,



the Partin nomogram was used to determine the nerve sparing approach in the next 78 patients (Cohort II). In patients with the chance of non-organ confined disease greater than 60%, the conventional interfascial nerve sparing was performed; otherwise, intrafascial nerve sparing was carried out. Preoperative patient characteristics, perioperative surgical variables and pathologic results including PSM were evaluated. PSM was defined as the presence of cancer at the inked margin.

**Results:** Preoperative patient demographics were similar between the two cohorts including mean PSA levels and mean biopsy Gleason scores. Also, perioperative parameters showed no significant differences between the two cohorts consisting of operating time and estimated blood loss. Among the 70 patients of Cohort I, 75.7% showed pT2 disease and 24.3% presented pT3 disease. In the 78 patients of Cohort II, 87.2% showed pT2 disease and 12.8% presented pT3 disease. Overall PSM rates were 15.7% and 5.1% for the Cohort I and II, respectively. In the organ confined (pT2) disease, PSM rates were not significantly different between the two cohorts (7.6% and 4.4%). On the other hand, in the pT3 patients, PSM rates were significantly different between the two cohorts (41.2% and 10.0%).

**Conclusion:** By using the Partin nomogram in deciding interfascial vs intrafascial nerve sparing, we demonstrated a significant reduction of PSM rate in the patients with non-organ confined prostate cancers.

### MP11-19 ROBOTIC-ASSISTED LAPAROSCOPIC RADICAL PROSTATECTOMY OPERATIVE DETAILS UND FUNCTIONAL OUTCOME

J. Wöllner, A. Neisius, G. Wöllner, R. Gillitzer, J. Thüroff, C. Hampel—Germany

**Background:** The patients with localized prostate cancer are faced with a variety of treatment options. Robotic-assisted laparoscopic prostatectomy is increasingly used for the management of this disease.

**Methods:** Between April 2008 and December 2008, we performed a prospective, controlled study to evaluate and compare the operative und functional outcomes of retropubic prostatectomy (RPX), robotic-assisted laparoscopic prostatectomy (RALP) und perineal prostatectomy (PPX).

**Results:** In this period, 228 patients underwent radical prostatectomy, 128 were performed as RPX, 85 as RALP and 15 as PPX. Mean age was 65.5. The majority had a BMI > 25. There was no difference between the median of BMI, prostate weight and the

patients age. Most tumors were clinically localized with gleason score 6 or 7. Rate of positive margins despite of negative intraoperative frozen sections was 9.9% in the group of RALP, 11.8% (RPX), and 22% respectively for PPX. Operative time was 320 min for RALP, 201 min (RPX) and 163 min (PPX). No conversion to open procedere was necessary. Mean blood loss was 2.8 g/dl haemoglobin, the difference between RALP and RPX was significant ( $p < 0.001$ ). The transfusionrate was significant lower in the group of RALP ( $p < 0.001$ ).

**Conclusion:** The RALP is minimally invasive procedure with low morbidity. Despite longer operation time, low blood loss and hospitalization time favorises robotic assisted prostatectomy.

### MP11-20 OUTCOMES OF ROBOTIC ASSISTED LAPAROSCOPIC PROSTATECTOMY IN PATHOLOGICAL ADVANCED LOCALIZED (PT3) PROSTATE CANCER IN 1700 PATIENTS

Y. El douaihy

**Background:** The purpose is to analyze the surgery outcomes of Robotic Assisted Laparoscopic Prostatectomy (RALP) in advanced localized prostate cancer (pT3) in 1700 cases.

**Methods:** 259 (16% of cohort) cases were pathologically T3 cases. Chi square t-test was used to compare pre operative pathology and radiology findings. Binary regression tested the MRI predictability of detecting T3 prostates. Kaplan-Meier curves compared biochemical recurrence (defined as  $\leq 0.2$  ng) in pT3 and the rest of the cohort. Sexual outcomes are reported.

**Results:** Pre op PSA was significantly higher (sig. = 0.00) in pT3 patients ( $8.2 \pm 9.1$ ) than in the rest of the cohort ( $5.5 \pm 3.8$ ). Positive margin rates were 22.8 for pT3 group vs. 7.4 for the cohort (sig. = 0.00). Distribution of positive surgical margins by location was comparable in both groups except for the "posterolateral" site where pT3 accounted for half of the PSM in the entire cohort. 74% of pT3 patients were pT3a and 75% of PSMs in pT3 patients were pT3a prostates. In binary logistic regression, MRI showed statistical significance in predicting EPE (sig. = 0.00) but was not significant in predicting PSM (sig. = 0.419). Over a median follow up period of 3 years, recurrence rate for T3 group was 11 % whereas the overall recurrence rate was found to be 4.1%.

**Conclusion:** pT3 patients are older and present with higher PSA values. MRI gives a good idea about the site of extension. With respect to PSM, pT3a and pT3b behaved similarly. Localized advanced cancer carries higher risks for PSM especially at the posterolateral sites. Stage 3 disease treated with RALP has acceptable pathologic outcomes, making RALP a definite treatment option.

## MP12: LAPAROSCOPIC SURGERY

### MP12-01 LAPAROSCOPIC RADICAL PROSTATECTOMY (9 CASES)

L. Chaozhao, H. Zongyao, Z. Jun, Z. Xiansheng, F. Song—Chian

**Background:** To evaluate the laparoscopic radical prostatectomy and reduce its complications in the future.

**Methods:** A total of 9 men with prostatic carcinoma (mean age, 68) undergoing the laparoscopic radical prostatectomy was re-

cruited in our study. Each patient underwent the trans-rectal prostatic biopsy which demonstrated the prostatic carcinoma and Gleason score ranging from 4 to 7.

**Results:** There was none patient transforms to opening surgery in our study. The operation time and bleeding was 150 to 240 minutes (mean 180minutes) and 200 to 1000 ml (mean 300 ml), respectively. 2 patients underwent the transfusion (mean 400 ml). There were 4 patients with leakage of urine, 2 patients with incontinence

and 2 patients with sexual dysfunction among whom drainage (from 3 to 7 days), sphincter exercise (from 1 to 3 months) and medication were carried out.

**Conclusion:** Based on an initial experience of 9 patients, we can confirm that radical prostatectomy can be perfectly performed by trans-peritoneal laparoscopy by a team experienced in laparoscopy, with an operating time compatible with that of usual activity. This will need to be improved after this initial learning curve by a larger series of operated patients with a longer follow-up. Laparoscopic radical prostatectomy is now performed routinely and is proposed as the first-line surgical treatment for localized prostatic cancer in our department.

### MP12-02 INCREASED POSITIVE SURGICAL MARGIN RATE OF LAPAROSCOPIC RADICAL PROSTATECTOMIES PERFORMED IN JULY AND AUGUST

J. Page, R. Unnikrishnan, S. Strup

**Background:** Purely laparoscopic radical prostatectomy is a technically challenging procedure requiring trained surgical assistants. Our objective is to evaluate differences in positive surgical margin rate by month of academic year for laparoscopic radical prostatectomy (LRP) performed by a single surgeon (SS).

**Methods:** 375 LRPs performed between 2003–2008 were retrospectively evaluated. 357 had sufficient data for interpretation. Total number of procedures performed per month and number of positive surgical margins per month were collected. Positive margin rate by month was calculated. Student t-test was utilized to evaluate for significance in differences of margin rate.

**Results:** Overall positive margin rate was 19.9%. Positive margin rate was 33.3% for July and 30.4% in August. The remaining ten months had an average rate of 17.6 percent (range 12.8–28%, stdev 5.65). The average positive margin rate for July and August was significantly higher than the rate for September through June (31.9% vs 17.6%,  $p = 0.006$ ).

**Conclusion:** LRPs performed in the first two months of the academic training year have a significantly higher positive margin rate. Proficiency of surgical assistance may affect pathological outcomes.

### MP12-03 EFFECTS OF ELEVATED BMI ON PERIOPERATIVE CLINICAL AND PATHOLOGICAL OUTCOMES FOLLOWING LAPAROSCOPIC RADICAL PROSTATECTOMY

J. Page, D. Davenport, M. Paszek, C. Lagrange, B. Dusseault, S. Strup—USA

**Background:** To evaluate the effects of elevated body mass index (BMI) on operative and perioperative outcomes in patients undergoing laparoscopic radical prostatectomy (LRP).

**Methods:** A single institution prospective database of 303 patients who underwent LRP between 2003 and 2008 was evaluated, 283 patients (93%) had sufficient data for analysis. Subjects were stratified into normal weight ( $BMI \leq 25 \text{ kg/m}^2$ ,  $n = 72$ ), overweight ( $BMI 25.1\text{--}30 \text{ kg/m}^2$ ,  $n = 132$ ), obesity I ( $BMI 30.1\text{--}35 \text{ kg/m}^2$ ,  $n = 68$ ), and obesity II ( $BMI > 35.1 \text{ kg/m}^2$ ,  $n = 11$ ) cohorts. Perioperative parameters were compared for association of elevated BMI with operative and pathological outcomes.

**Results:** Preoperative PSA, clinical stage, and percent core biopsy involvement were similar across all cohorts. Obese I patients were slightly younger ( $p = 0.049$ ), and obese II subjects of elevated ASA score ( $p = 0.021$ ). Operative times increased with each group compared to normal BMI subjects (212 minutes, 230 minutes

( $p = 0.033$ ), 237 minutes ( $p = 0.013$ ), and 259 minutes ( $p = 0.015$ ) respectively). EBL was greater for those with  $BMI > 30 \text{ kg/m}^2$  than those  $< 30 \text{ kg/m}^2$ . All procedures were completed laparoscopically. No associations were found with final Gleason's score, number of postoperative complications, intraoperative complications, number of nerve sparing procedures, lymph node dissections or bladder neck reconstructions performed. However, 5/11 (45%) obese II patients had an anastomotic leak ( $p = 0.000$ ) on post-operative day one. Among all groups, 14% had a positive surgical margin, with no statically significant difference between cohorts. Prostate mass was 16% larger in obesity I, and 34% larger in obesity II categories versus normal weight subjects ( $p = 0.023$  and  $p = 0.012$ ).

**Conclusion:** Elevated BMI is associated with increased operative time and estimated blood loss during LRP. Those with  $BMI > 35$  suffered more anastomotic leaks, but this association warrants further investigation. Otherwise, LRP provided similar short-term clinical and pathological outcomes across BMI categories.

### MP12-04 EXTENDED PELVIC LYMPHADENECTOMY DURING RADICAL PROSTATECTOMY—IS IT WORTHWHILE?

A. Arora, C. Eden

**Background:** The literature on the merit of extended pelvic lymphadenectomy (ePLND) in men with medium/high-risk and apparently localized prostate cancer is contradictory.

**Methods:** Of a total of 1159 patients who underwent laparoscopic radical prostatectomy (LRP) 311 had a PLND: 242 men had a standard (sPLND) lymphadenectomy for high-risk disease (before April 2008) and 68 men had an ePLND for intermediate- or high-risk disease (after April 2008).

**Results:** Peri-operative parameters in sPLND and ePLND patients were: operating time = 188 & 222 minutes ( $p \leq 0.0001$ ); blood loss = 243 & 209 ml ( $p = 0.21$ ); complication rate = 6.2% & 7.4% ( $p = 0.91$ ); node count (with range) = 4.6 (1–8) & 10.4 (4–23) ( $p \leq 0.0001$ ). Lymph node positivity for sPLND and ePLND patients by Gleason grade was: G6 = 0.8% & 0% ( $p = 1.00$ ); G7 = 1.1% & 11.9% ( $p = 0.02$ ); G8 = 3.8% & 0% ( $p = 1.00$ ); G9 & 10 = 0% & 0% ( $p = 1.00$ ).

**Conclusion:** ePLND doubled the lymph node count ( $p \leq 0.0001$ ) and significantly increased the rate of detection of lymph node metastases in patients with Gleason 7 prostate cancer ( $P \leq 0.02$ ). The authors recommend that PLND is performed in all patients with Gleason <sup>3</sup>7 prostate cancer undergoing RP and that ePLND should replace sPLND.

### MP12-05 FINAL OUTCOME OF PATIENTS WITH PROSTATE CANCER SUITABLE FOR ACTIVE SURVEILLANCE BUT TREATED SURGICALLY

A. Arora, C. Eden

**Background:** Recent National Institute for Clinical Health and Excellence (NICE) guidelines have recommended that active surveillance should be offered first to UK patients with low-risk localized prostate cancer prior to considering radical treatment whilst providing scant evidence that this is safe.

**Methods:** Of 1080 patients who underwent RP between March 2000 and April 2008, 549 patients (51%) had low pre-operative risk disease. The pathological outcomes of these patients as well as a further subgroup of 74 patients with pre-operative prediction of insignificant disease were assessed.

**Results:** Mean age = 61 years, mean PSA = 6.1 (1–9); 38% patients were staged as cT2a. 126 patients (23%) were upgraded on final pathology to Gleason score >7. 29 patients (5%) had extra-prostatic extension with 5 patients (0.9%) demonstrating seminal vesicle involvement. Of the 74 patients with pre-operative prediction of insignificant disease, 61% had significant disease with 16% upgraded to the intermediate risk group. Overall positive margins were noted in 44 patients (8.0%) and biochemical failure occurred in 6 patients (1.1%) with a median follow up of 28 months.

**Conclusion:** In this contemporary UK cohort of patients with apparently low-risk prostate cancer, 25% had higher risk disease than pre-operatively predicted.

### MP12-06 IS LAPAROSCOPIC RENAL DENERVATION THE TREATMENT OF CHOICE FOR 'LOIN PAIN-HAEMATURIA SYNDROME (LPHS)': EXPERIENCE FROM SCOTLAND

D. Clark, B. Somani, N. Kadi, N. Townell

**Background:** Traditional treatment for LPHS is nephrectomy with most alternative methods failing to offer long-term treatment success. Open renal denervation has been reported with limited success. We wanted to evaluate the outcome of laparoscopic renal denervation for these patients.

**Methods:** A review of eleven laparoscopic renal denervations was carried out for LPHS in 10 patients between Feb 2002 and Nov 2008 by an experienced laparoscopic surgeon. Data was independently assessed by two reviewers and was evaluated for patient demographics, mode of presentation, investigations, analgesia requirement, and follow-up.

**Results:** Ten females with a median age of 34.5 years (range 18–47 years). All patients had normal urological investigations including USS, IVU and renogram. Median follow-up was 48 months (range 6–77) Laparoscopic renal denervation was curative in four patients who remained pain free (median follow up 38 months; range 12–64). Six patients were initially pain free for 36 months (range 24–42 m) and subsequently developed pain, one of whom required nephrectomy. The analgesic requirement decreased for 4 of the other five patients. Overall, eight of the ten patients benefitted from the procedure with nine avoiding nephrectomy.

**Conclusion:** Laparoscopic renal denervation offers the best short term pain relief to most patients, with long-term benefit in some patients. The overall requirement for analgesics is reduced with most patients avoiding nephrectomy.

### MP12-07 VALVE-LESS TROCAR REDUCES CARBON DIOXIDE ABSORPTION DURING LAPAROSCOPY COMPARED TO CONVENTIONAL TROCARS

A. Herati, S. Andonian, S. Rais-bahrami, A. K. Srinivasan, L. Richstone, L. R. Kavoussi—United States

**Background:** Laparoscopic trocars employ trap door valves and silicone seals to maintain pneumoperitoneum. A new generation of valve-less trocar have been developed that maintain pneumoperitoneum by using a curtain of forced carbon dioxide gas. The aim of the present study was to evaluate the newly designed valve-less trocar in a prospective fashion compared to conventional trocars, qualifying the amount of CO<sub>2</sub> use and CO<sub>2</sub> elimination during laparoscopic renal cases.

**Methods:** The new AirSeal™ trocars were prospectively used in 26 patients and compared with another 25 patients undergoing laparoscopic renal surgery at our institution. Patient demographics,

operative time, amount of CO<sub>2</sub> gas used, CO<sub>2</sub> elimination, perioperative parameters, and postoperative complications were analyzed.

**Results:** There were no significant differences in the estimated blood loss, operative time, change in hemoglobin, or length of stay between the two arms. Significant less carbon dioxide elimination was seen in the valve-less trocar cohort after 16 minutes of insufflation when compared to the conventional trocar. Two patients in the valve-less trocar developed subcutaneous emphysema and one developed pneumomediastinum. No complications occurred in the conventional trocar cohort.

**Conclusion:** The valve-less trocar was associated with significantly lower CO<sub>2</sub> elimination and thus decreased CO<sub>2</sub> absorption. The new valve-less may prove to be an added benefit for obese patients and those with COPD. Randomized trials are needed to confirm these results.

### MP12-08 OPTIMUM TEMPERATURE FOR COLD ISCHEMIA: PRELIMINARY RESULTS ON A PORCINE MODEL

G. Schoeppler, E. Klippstein, A. Häcker, L. Trojan, P. Alken, M. Michel

**Background:** The ideal temperature for cold ischemia during partial nephrectomy (PN) is supposed to be around 15°C (J.P. Ward, 1975) whereas the cold-storage temperature in kidney transplantation ranges between 0–4°C (G.M. Collins, Lancet, 1969). The mean cooling temperature for inducing hypothermia during PN, performed with crushed ice, ranges between 0–7°C. The aim of our study was to identify the optimum cooling temperature to protect renal parenchyma from ischemic injury, as a variety of cooling methods with different temperature levels are described for laparoscopic use.

**Methods:** Warm-ischemia (WI) and cold-ischemia (CI) were each performed in 3 pigs by clamping the renal artery for 60 min. For CI a novel material Freka Gelice, based on modified iced gelatine, was used. Before clamping (t = 0) and after 120 min (t = 120) of reperfusion, laboratory blood (Hb, HCT, pH, Na<sup>+</sup>, K<sup>+</sup>, Crea, LDH) and urine values were analysed for the evaluation of acute renal failure. Kidney temperature was digitally recorded with sensors in the upper (UP), middle (MP) and lower (LP) pole.

**Results:** The mean temperature decrease in CI for UP, MP and LP was 14.7°C, 15°C and 19.6°C, respectively. Due to arterial clamping alone the kidney temperature decreased by 1.4°C (range 0–3.5°C). A significant difference between t = 0 and t = 120 in WI and CI could only be found for Crea (p = 0.03), with the difference for K<sup>+</sup> being marginally significant (p = 0.07).

**Conclusion:** Our preliminary results show a significant difference in Crea rise during WI compared to CI in the porcine model. Further investigations with a higher number of cases are needed to define the best cooling temperature to prevent renal parenchyma from ischemic injury.

### MP12-09 THE MOST EFFECTIVE COOLING METHOD FOR INDUCING HYPOTHERMIA: COMPARISON OF 4 DIFFERENT TECHNIQUES INCLUDING A NOVEL GEL-LIKE MATERIAL

G. Schoeppler, J. Hell, A. Häcker, L. Trojan, P. Alken, M. Michel

**Background:** We describe initial results of inducing hypothermia during laparoscopic partial nephrectomy (LPN) by using a new gel-like ice (Freka Gelice, FG). So far no standardised cooling method for inducing hypothermia in LPN has been established. We

therefore evaluated 3 different cooling methods for inducing hypothermia during LPN compared with conventional crushed NaCl-ice (NaCl-ice) which is used as standard cooling method in open partial nephrectomy.

**Methods:** We compared the cooling effectiveness of FG, NaCl-ice, transureteral (TU) and transarterial (TA) cooling with 4°C cold saline-perfusion. FG is based on iced modified gelatine. Ex-vivo porcine-kidneys were heated up to 37°C and cooled down with each cooling method. Temperature measurement was performed by sensors placed in the renal parenchyma. Temperature decrease over 120 min and practical application was evaluated.

**Results:** Mean temperatures for NaCl-ice, FG, TU and TA were 7°C; 4,8°C ; 24°C and 32°C at 30 min, 0,7°C; 2,5°C; 20°C and 20°C at 60 min, and -0,2°C; 2,4°C; 17°C and 18°C at 120 min, respectively. No significant differences were found for the mean value distribution at different time points for NaCl-ice and FG ( $p=0.18$ ). The largest decrease in temperature was found for NaCl-ice and FG with a lowest mean value of 5,8°C and 4,1°C, whereas for TU and TA cooling this effect was less substantial (22°C and 21°C, respectively). FG was easy to handle due to its gel-like state.

**Conclusion:** Instead of difficult-to-control crushing of ice, FG is easy to handle and can be pressed through a trocar. Its cooling effectiveness was comparable to NaCl-ice and better than TU and TA perfusion. Therefore it is a favourable material which can be used for inducing hypothermia in LPN.

#### **MP12-10 A COMPARATIVE ASSESSMENT OF LAPAROSCOPIC AND MICROSURGERY OPERATIONS IN PATIENTS WITH BILATERAL VARICOCELE**

Z. Kadirov, N. Savitsky, V. Musienko

**Background:** Surgical treatment of patients with bilateral varicocele is hitherto considered to be subject of discussions. Laparoscopic treatment of varicocele has shown safety and efficiency. The usage of general anaesthesia limits the usage of this method. Microsurgical method is also considered in terms of bilateral varicocele. In addition, the present method can be applied under local anaesthesia and in the hospital one day. The main purpose of this work was lifestyle comparative analysis of patients with bilateral varicocele after laparoscopic and microsurgery methods of treatments.

**Methods:** A total of 40 patients suffering from infertility underwent videoendoscopic and microsurgery operations. Among them, 28 patients were treated with videoendoscopic procedures, and 12—with 1 microsurgery ones. The patients were aged from 22 to 34 years (mean 26 years). Quality of life of the patients was assessed according to the scale of physical activity (1—normal physical activity, 2—slightly decreased activity with the patient being able to visit a doctor without assistance, 3—moderately decreased activity with the patient staying in bed less than 50% of the daily hours, 4—significantly decreased activity with the patient staying in bed more than 50% of the daily hours, 5—minimum physical activity with complete confinement to bed) and according to the duration of the night sleep.

**Results:** The average time of operation with laparoscopic methods was  $45 \pm 5,5$  min, with microsurgery  $-54 \pm 4,6$  min. The average amount of anaesthetic after laparoscopic treatment was 1000 mg (baralgin), after microsurgery  $-2000$  mg. One day postoperatively, the quality of life of the patients treated with laparoscopic operations was  $1.8 \pm 0.12$  points; in the patients treated with microsurgery

$-2.8 \pm 0.14$  points. The difference between the patients treated with LO and those treated with microsurgery was statistically reliable ( $p < 0.05$ ).

**Conclusion:** The results of this study suggest better quality of life in the patients treated with laparoscopic operations as compared with those treated with microsurgery operations.

#### **MP12-11 SUBCUTANEOUS EMPHYSEMA AFTER LAPAROSCOPIC EXTRAPERITONEAL INGUINAL HERNIA REPAIR**

S. Soleymani

**Background:** The case of a healthy 46-yr-old man who underwent elective laparoscopic extraperitoneal inguinal hernia repair and general anaesthesia is presented.

**Methods:** After one hour of surgery, a sudden increase in the FETCO<sub>2</sub> from 5.0% to 9.4% in relation to a massive subcutaneous emphysema, but without any haemodynamic instability, was noticed. The acute rise of FETCO<sub>2</sub> was the first sign of an abnormal event. Nevertheless, subcutaneous emphysema was diagnosed with chest wall examination and palpation. Subcutaneous emphysema and hypercarbia are potential complications of laparoscopic surgery, but are more likely to occur in extraperitoneal surgery, since insufflated CO<sub>2</sub> can diffuse easily into the surrounding tissues. High insufflation pressures will increase chances of this occurring and was the most likely cause of this complication.

**Results:** This case encouraged us to make recommendations for the management of laparoscopic extraperitoneal surgery which included: monitoring of CO<sub>2</sub> insufflation pressure, routine examination and palpation of chest wall.

**Conclusion:** Use of N<sub>2</sub>O with caution, adjusting ventilation to physiological FETCO<sub>2</sub> and excluding other causes of subcutaneous emphysema and hypercarbia.

#### **MP12-12 COMPARATIVE ASSESSMENT OF LAPAROSCOPIC SINGLE SITE SURGERY INSTRUMENTS TO CONVENTIONAL LAPAROSCOPIC IN LABORATORY SETTING**

J. Stolzenburg, P. Kallidonis, M. Do, A. Dietel, T. Haefner, E. Liatsikos

**Background:** Laparoendoscopic single site surgery (LESS) represents the latest innovation in laparoscopic surgery. We compare in dry and animal laboratory the efficacy of recently introduced pre-bent instruments with conventional laparoscopic and flexible instruments in terms of time requirement, manoeuvrability and ease of handling.

**Methods:** Participants of varying laparoscopic experience were included in the study and divided in groups according to their experience. The participants performed predetermined tasks in dry laboratory using all sets of instruments. An experienced laparoscopic surgeon performed 24 nephrectomies in 12 pigs using all sets of instruments. Single port was used for all instrument sets except for the conventional instruments, which were inserted through three ports. The time required for the performance of dry laboratory tasks and the porcine nephrectomies were recorded. Errors in the performance of dry laboratory tasks of each instrument type were also recorded.

**Results:** Pre-bent instruments had a significant advantage over flexible instruments in terms of time requirement to accomplish tasks and procedures as well as manoeuvrability. Flexible instruments were more time consuming in comparison to conventional laparoscopic instruments during the performance of the tasks.

There were no significant differences in the time required for the accomplishment of dry laboratory tasks or steps of nephrectomy using conventional instruments through appropriate number of ports in comparison to pre-bent instruments through single port.

**Conclusion:** Pre-bent instruments were less time consuming and with better manoeuvrability in comparison to flexible instruments in experimental single port access surgery. Further clinical investigations would elucidate the efficacy of pre-bent instruments.

### MP12-13 TRAINING IN URO-LAPAROSCOPY: LIGHTS AND SHADOWS

R. Autorino, R. Stein, M. De sio, R. Damiano, E. Lima, J. Kaouk—USA

**Background:** Aim of this review paper is to provide an evidence-based analysis on the current status and future perspectives of laparoscopic training in urologic surgery.

**Methods:** A thorough review of the current literature was performed in January 2009 using the PubMed search engine. The search protocol included a free text query using the following terms: “training”, “urologic laparoscopy”, “urology” and “laparoscopy”. Suitable papers were selected on the basis of the study content. The following issues were addressed: prediction of laparoscopic skills; impact of lap training on clinical practice; formal laparoscopic training programmes; home-made lap-trainers; training on lap-trainer; model of training in specific uro-laparoscopic procedures; robotics and virtual reality for laparoscopic surgical education.

**Results:** Most currently available tools predicting laparoscopic skills lack adequate validation to justify their application. Intensive laparoscopic training may decrease the time required to transfer specific competence to one’s own surgical practice. Postgraduate urologists may possibly be more rapidly and efficiently trained using a structured mentoring program. Various non-formal training programs exist, yet most urologists will not be able to complete a formal fellowship. There still is not enough evidence to show definite transfer of skills from currently available simulators to the operating theatre. Specific models have been developed for complex urological procedures including partial nephrectomy, pyeloplasty and vesico-urethral anastomosis, yet further study is required to analyze the degree of benefit of these prototypes. As experience grows, robotics is likely to have an increasing role in teaching and learning uro-laparoscopy.

**Conclusion:** Despite the progress of recent years and an extensive amount of data from urological literature, training in uro-laparoscopy remains a field of controversial issues requiring further investigation.

### MP12-14 USE OF FOOT GEL PADS IMPROVES OPERATING ROOM STAFF COMFORT DURING LAPAROSCOPIC RENAL SURGERY

J. Rosales Araujo, J. Moreno, D. Lee, Z. Okhunov, K. Badani, J. Landman—USA

**Background:** We evaluated the comfort of our laparoscopy team during renal surgery with and without gel footpads.

**Methods:** From September 2008 to April 2009 we prospectively randomized 100 consecutive laparoscopic renal procedures to establish if a foot gel-pad altered surgeon comfort. A questionnaire was used to measure the discomfort 18 different subjects, before, during and one day after the procedures. Procedures performed with and without the foot gel-pads were compared.

**Results:** One hundred minimally invasive laparoscopic renal procedures were evaluated. In 50 (50%) procedures the foot gel-pad was used. The mean age of the subjects was 36 (y/o) ranges (25–52). The mean surgical experience was 7 years. The comparison between those procedures with and without pad, for preoperative characteristics was similar. In the immediate post-operative period there were statistical differences in number of brakes taken ( $p=0.001$ ), number of stretches ( $p=0.001$ ), number of rest taken ( $p=0.001$ ), foot ( $p=0.003$ ), knee ( $p=0.001$ ), back discomfort ( $p=0.001$ ), amount of overall discomfort ( $p=0.001$ ) and level of energy ( $p=0.049$ ) about the IP evaluation. At the 24 hours post-procedure time point evaluation significantly favored the gel-pads regarding foot pain ( $p=0.004$ ) and overall amount discomfort ( $p=0.001$ ) and level of energy ( $p=0.044$ ).

**Conclusion:** The use of a foot gel-pad improves surgeon comfort and ergonomics during laparoscopic renal procedures. The pads have been incorporated into our routine operating room set-up.

### MP12-15 ASSESSMENT OF RENAL DAMAGE FOLLOWING WARM ISCHEMIA TIME DURING LPN: RESULTS OF A PROSPECTIVE STUDY

F. Porpiglia, C. Fiori, R. Bertolo, B. Cavallone, D. Vaccino, R. Scarpa

**Background:** To evaluate the renal damage and impairment of renal function after laparoscopic partial nephrectomy (LPN) following warm ischemia time (WIT).

**Methods:** Fifty-five patients who underwent LPN at our Institution were divided into three Groups according to WIT: Group A ( $n=22$ )  $< 20'$ ; Group B ( $n=23$ )  $> 20' < 30'$ , Group C ( $n=12$ )  $> 30'$ . Daily proteinuria (DP), serum creatinine (CrS), and creatinine clearance (CrCl), were assessed on 5th postoperative day (pod) and at 3rd month, renal scintigraphy was performed before the procedure, on 5th pod and at 3rd month and at one year post-operatively. Data of three groups were compared using Student t-test and Chi-square test.

**Results:** Groups were comparable about baseline CrS, CrCl, DP and %RF. At 5th pod, DL was significantly lower in Group A respect to that in Groups B and C; there was a statistical difference between the %RF in Groups A and B with respect to Group C. At the 3rd month CrS is similar in all the Groups ( $p > 0.05$ ); DP is significantly higher in Groups B and C respect to that in Group A ( $p=0.04$ ); CrCl in Groups A and B ( $p > 0.05$ ) is significantly better than that in Group C. In Group C the %RF remained significantly lower with respect to baseline conditions.

**Conclusion:** Our results demonstrate that kidney damage surely occurs during LPN only when WIT is over 30 minutes and efforts should be made to keep WIT within 30 minutes.

### MP12-16 TRANSPERITONEAL LAPAROSCOPIC DECORTICATION OF SIMPLE RENAL CYST USING CONVENTIONAL MONOPOLAR DEVICE:TWO YEARS OF OUR EXPERIENCE WITH 15 PATIENTS

A. Tuncel, O. Aydin, Y. Aslan, V. Nalcacioglu, M. Balci, A. Atan—Turkey

**Background:** To assess the efficacy, safety and feasibility of transperitoneal laparoscopic decortication of simple renal cysts using conventional monopolar device.

**Methods:** Records of 15 patients who underwent transperitoneal laparoscopic renal simple cyst decortication which was performed by conventional monopolar device between August 2007 and

January 2009 were retrospectively reviewed. Patients underwent radiological follow-up with computerized tomography. Long-term symptomatic and radiological results were assessed.

**Results:** The mean age of the patients were 49.7 (range, 23–76) years. There were 9 male and 6 female patients. Their presenting symptoms were lomber pain in 11 (73.4%), recurrent urinary tract infection in 3 (20%) and hypertension in 1 (6.6%). One patient underwent bilateral, the others underwent unilateral laparoscopic renal cyst decortication. One single cyst was treated in 12 (80%) patients, two cysts in 3 (20%) patients. They were peripherally located in all the patients. The mean operating time was  $64.6 \pm 34.9$  (range, 30–150) min. Neither open conversion nor blood transfusion was necessary. Jackson-Pratt drain was placed and it was removed postoperative first day in all the patients. No complications were encountered. Mean hospital stay  $2.2 \pm 1.2$  (range, 1–5) days. After a mean follow up of  $12.08 \pm 6.3$  (range, 8–21) months, radiological success, defined by no recurrence was 100%. Symptomatic success was achieved in 13 (86.6%) patients, while 2 patients were reported with residual lomber pain. All patients had had negative cytological and pathological findings for malignancy or any other abnormalities.

**Conclusion:** Laparoscopic transperitoneal decortication using conventional monopolar device (that can be provided easily and cheaply) represents an effective and safe treatment option in the management of renal cyst without any need for more expensive energy sources. Furthermore we also think that laparoscopic transperitoneal decortication using conventional monopolar device by providing reasonable operation time, short hospital stay and high long-term success rates.

### MP12-17 URO-ONCOLOGIC SURGERY IN JEHOVAH'S WITNESS PATIENTS

L. Jones, L. Deane

**Background:** Jehovah's Witness patients represent a unique challenge to the urologic surgeon due to their refusal of transfused blood products. Robotic and laparoscopic surgery offers the possibility of decreased blood loss compared to open oncologic surgery. We review our experience with laparoscopic and robotic urologic surgery in these patients.

**Methods:** Five Jehovah's Witness patients underwent laparoscopic or robotic urologic surgery by a single surgeon at our institution. One patient each underwent robot-assisted laparoscopic radical cystoprostatectomy with lymph node dissection, laparoscopic radical nephrectomy, robot-assisted radical prostatectomy, laparoscopic nephroureterectomy, and robot-assisted laparoscopic partial nephrectomy. Patient demographics, operative data and outcomes were collected retrospectively.

**Results:** The mean age was 60.4 (range 46–76) and the mean body mass index was 26.4 (range 21–28). All patients were male. All operations were completed as planned with minimal blood loss (mean: 130 cc, range: 50–200 cc) without need for conversion to open operation or transfusion of blood products. The mean post operative hemoglobin was 12.3 (range: 10.5–14.2). No operative complications were noted and the patients were discharged home in a median of 5 days (range: 3–12).

**Conclusion:** Laparoscopic and robotic procedures are safe in Jehovah's Witness patients for a wide-variety of uro-oncologic operations.

### MP12-18 LAPAROSCOPIC RADICAL NEPHRECTOMY—A DECADE SPECIFIC COMPARATIVE OUTCOMES ANALYSIS

S. Kommu, Z. Hashim, D. Cartledge, T. Finnigan, C. Luscombe, A. Golash—United Kingdom

**Background:** Laparoscopic Radical Nephrectomy (LRN) is the current gold standard for the treatment of renal cancers. Renal cell carcinoma predominantly develops in the sixth or seventh decade of life. In England has a life expectancy at birth of 77.5 years for males and 81.7 years for females [www.statistics.gov.uk]. This is projected to increase with time. In tandem with this increase in life expectancy, urologists will face increasingly older patients who present with renal cancer. The elderly patient has a higher level of co-morbidities, peri-operative morbidity and declined renal reserve. The patient who is eighty or older represents a distinct cohort of patient in terms of life expectancy quotients. Herein, we aim to assess the outcomes of LRN in patients by conducting a Decade Specific Comparative Outcomes Analysis (DSCOA).

**Methods:** We conducted a retrospective collection of data using the hospital Electronic CRIS System together with supplementary patient notes for 250 LRN that were successfully completed in our unit since 2006.

**Results:** One patient (0.5%) was in his 2nd decade, no patients were in the 3rd; 14 (6.9%) in 4th; 23 (11.3%) in 5th; 37 (18.1%) in 6th; 63 (30.8%) in 7th; 55 (27%) in 8th and 11 (5.4%) in the 9th decades respectively. Findings in terms of specific decades are as follows: Second Decade [Age = 18 years; operating time = 122 minutes; there were no complications. The procedure was done as a daycase and Operating time ASA was I]. Fourth Decade [mean age was 36 (32–39) years; mean operating time was 148 (115–169) minutes; no patients developed complications (major and minor); mean hospital stay was 4 (day case—9) days; 2 (14%) patients had a neoplasm; no patients died and 9 patients were ASA I, 2 ASA II, 3 ASA III]. Fifth Decade [mean age was 44 (41–49) years; mean operating time was 171 (80–230) minutes; 6 patients (26%) developed complications (major and minor); mean hospital stay was 7 (1–22) days; 12 (52%) patients had a neoplasm; no patients died; 15 patients were ASA I, 3 ASA II, 5 ASA III]. Sixth Decade [mean age was 56 (50–59) years mean operating time was 151 (60–229) minutes. 8 patients (22%) developed complications (major and minor). 1 patient (3%) died. The mean hospital stay was 6 (1–28) days and 24 (65%) patients had a neoplasm. Seventeen patients were ASA I, 12 ASA II, 8 ASA III]. Seventh Decade [mean age was 64 (60–69) years; mean operating time was 176 (100–379) minutes; 8 patients (13%) developed complications (major and minor). There were no deaths in this group. The average hospital stay was 6 (1–29) days; 49 (79%) patients had a neoplasm. 24 patients were ASA I, 28 ASA II, 10 ASA III]. Eighth Decade [mean age was 74 (70–79) years; mean operating time was 155 (60–286) minutes; seventeen patients (31%) developed complications (major and minor); 5 (9%) patients died; mean hospital stay was 8 (2–28) days. 46 (84%) patients had a neoplasm; 19 patients were ASA I, 30 ASA II, 6 ASA III]. Ninth Decade [mean age was 82 (80–87) years. The mean operating time was 132 (135–212) minutes; none developed complications (major and minor). There were no deaths; mean hospital stay was 6 (3–17) days; 8 (73%) patients had a neoplasm. 1 patients were ASA I, 6 ASA II, 4 ASA III. All patients were pre-assessed leading to 12 anaesthetic consults. Mean operating time was 153 minutes. 26 patients (13%) developed complications (major and minor) and 6 patients (3%) were transferred to HDU. Complications included: 20 infections, 3 cardiac events, 1

Pulmonary Embolus, 1 Ischemic Colitis, 1 port-site hernia. The average hospital stay was 4 days. 140 (75%) patients had a neoplasm. 1 patient died on day.

**Conclusion:** Despite the purported significant risk of developing complications during oncological extirpation of renal tumours by LRN, we found that the procedure is feasible and reasonably well tolerated in elderly patients.

### MP12-19 PAIN ASSESSMENT AFTER RADICAL RETRO-PUBIC VS EXTRAPERITONEAL LAPAROSCOPIC RADICAL PROSTATECTOMY—A PROSPECTIVE TRIAL

T. Vögeli, I. Akbarov, M. Lehnhardt

**Background:** Reduction of pain in the postoperative period is thought to be one major advantage of laparoscopic surgery compared to an open surgical access. However only a few randomized trials have been conducted to evaluate pain after open and laparoscopic procedures. Especially for radical prostatectomy no valid data are available.

**Methods:** We performed a prospective trial with postoperative pain assessment using a analog scale of pain evaluation. Patients were subjected to EERP with PSA <15 ng/ml and a Gleason score less or equal than 7. Patients with a PSA >15 ng/ml and a Gleason of 8–10 were done by open RRP. Pain was measured during 3 days after surgery on fixed times in the morning and than after 6 and 12 hours.

**Results:** A total of 72 patients were included in the study, 36 were enrolled in each arm. Surgery was done by two surgeons and patients received a standard pain medication including i.v. novaminsulfat. Pain during the first 24 hours was low (0–2) in 24 of the EERP group compared to 10 in the open surgical group. medium: 22% EERP and 30% RRP. 48 hours after surgery the mean pain was 1.5 for the EERP and 3 for the RRP.

**Conclusion:** Pain is less after EERP compared to standar RRP durin the fist 24 hours after surgery. On the second day the difference is neglelible with only a lesser degree of pain and after 3 days no significant difference could be evaluated in this study. this

should be mentioned when chosing the surgical technique and in the preoperative information for the patient.

### MP12-20 THE INFLUENCE OF POSITIVE APICAL MARGINS ON BIOCHEMICAL RECURRENCE FOLLOWING LAPAROSCOPIC RADICAL PROSTATECTOMY: COMPARISON WITH NON-APICAL POSITIVE MARGINS

S. Hong, U. Ha, S. Kang, T. Hwang—Korea

**Background:** At the apex of prostate, capsule cannot be identified and histologic boundary is vague. So the prognostic significance of apical positive margin might be different from any other sites. The aim of this study was to determine if there were any differences in oncologic outcomes.

**Methods:** We reviewed 155 patients who underwent laparoscopic radical prostatectomy between July 2001 and July 2007. Biochemical recurrence (BCR) was defined as two consecutive PSA values more than 0.2 ng/ml. We analyzed the differences in BCR among margin negative group (SM–), apical positive group (AM+), non-apical positive group (NAM+) and factors predicting BCR.

**Results:** Of the 155 men who met our inclusion criteria 108 were SM–, 19 were AM+, and 28 were NAM+. BCR rates for SM–, AM+, and NAM+ were 14.8%, 36.8% and 46.4%, respectively. Kaplan-Meier curves showed that positive surgical margins had significant higher BCR compared with those with negative (SM– vs. AM+ and SM– vs. NAM+,  $p < 0.05$ ), however patients with AM+ experienced similar BCR free survival compared those with NAM+ ( $p = 0.613$ ). On multivariate analysis, factors significantly predictive of BCR were PSA, pathologic stage, and surgical margin status. In independent analysis of positive margins, there was no difference of effect on time to BCR between AM+ and NAM+.

**Conclusion:** In comparison with non-apical positive margins, positive apical margins didn't show significant difference of influence on BCR in men following laparoscopic radical prostatectomy. Longer follow-up and larger sample size are necessary to confirm these findings.

## MP13: IMAGING

### MP13-01 IMAGING CHARACTERISTICS OF RENAL CRYOLESIONS: 2 YEAR FOLLOW-UP

D. Kaplon, S. Hedican, F. Lee, L. Hinshaw, S. Nakada

**Background:** The purpose of this study is to describe the characteristics of renal cryolesions on magnetic resonance (MR) and computed tomography (CT) after two years of follow-up.

**Methods:** Seventy-two patients (men, 40; women, 32; age range 43–86 years; mean age, 68 years) underwent renal cryoablation (percutaneous 22; laparoscopic 50) for suspicious renal masses (size range 1.3–3.7 cm; mean size 2.4 cm) between February 2001 and September 2006. Of these, 34 patients had imaging performed at greater than 2 years post ablation and were included for review. Either MR ( $n = 25$ ) or CT ( $n = 11$ ) was used for follow-up and generally completed at 3, 6, 12, and 24 months post-operatively.

One radiologist retrospectively reviewed the images for lesion size (CT/MR), signal intensity (MR), and enhancement characteristics (CT/MR) on all postoperative imaging. Biopsy was performed in 16 patients and demonstrated RCC in 10, oncocytoma in 4 and inconclusive diagnosis in 3.

**Results:** Mean decrease in lesion size was 49%. First follow-up imaging study was performed at a mean of 3.6 (1–6) months post procedure. Seven patients (20%) had lesion enhancement at first follow up. Of these, 6 had spontaneous resolution of enhancement by two years. One patient had persistent enhancement and required retreatment. One patient developed secondary enhancement after two years and is scheduled to undergo retreatment. Characteristic MRI features of ablated lesions include a high intensity T1 signal, low intensity T2 signal, an early high intensity T1 rim signal which disappears over time, and a low intensity T2 rim signal which also disappears over time.

**Conclusion:** Our data demonstrate the evolution of ablated renal lesions on CT and MR over a two years. Characteristic rim enhancement and rim signals are often seen early postoperatively and disappear on follow-up imaging. Treatment failure is suggested by persistent nodular or diffuse enhancement after treatment.

### MP13-02 EVALUATION OF AFFECTED RENAL FUNCTION USING RENAL SCINTIGRAPHY AFTER LAPAROSCOPIC PARTIAL NEPHRECTOMY

K. Tatsugami, K. Kuroiwa, A. Yokomizo, M. Eto, S. Naito

**Background:** Laparoscopic partial nephrectomy (LPN) is an increasingly performed, minimally invasive alternative to open partial nephrectomy (OPN). We compared early postoperative renal function in patients undergoing OPN and LPN.

**Methods:** A total of 50 patients with renal tumors underwent OPN (n = 31) and LPN (n = 19). LPN were achieved via retroperitoneal (n = 10) or transperitoneal (n = 9) routs. In cases of retroperitoneal LPN (RLPN), the affected kidney was cooled by iced water for 5 min after clamping of the renal artery. The renal function was analyzed using pre- and postoperative renal scintigraphy using 99m Technetium-mercaptoacetyltriglycine (99mTc-MAG3).

**Results:** Median operating time was 190.5 min in OPN and 248 min in LPN (P < 0.01), median tumor diameter was 2.6 cm and 2.5 cm, mean blood loss was 273 ml and 100 ml (P < 0.01), and mean ischemic time was 34 (19–90) min and 41 (21–64) min, respectively. Median ratio of the affected kidney-mag/contralateral kidney-mag 1 week and 3 months after surgery to those of pre-surgery was 59.5% and 63.2% in OPN and 59.7% and 64.1 in LPN, respectively. In cases of LPN, there were no differences of operative data between transperitoneal LPN (TLPN) and RLPN except for mean ischemic time (37 vs. 50 min) (P < 0.05). Median ratio of the affected kidney-mag/contralateral kidney-mag 1 week and 3 months after surgery to those of pre-surgery was 59.6% and 56.5% in TLPN and 60.1% and 67.8% in RLPN, respectively.

**Conclusion:** We evaluated postoperative function of affected kidney using renal scintigraphy and showed no significant differences of the postoperative affected renal function between OPN and LPN. Furthermore, the data of TLPN and RLPN showed that renal cooling prevents renal dysfunction of the affected kidney with longer ischemic times.

### MP13-03 CRITICAL ANALYSIS OF THE USE OF PRE-OPERATIVE IMAGING STUDIES FOR PATIENTS UNDERGOING ROBOTIC-ASSISTED LAPAROSCOPIC RADICAL PROSTATECTOMY: IS PRACTICE CONSISTENT WITH PUBLISHED GUIDELINES?

J. Yates, G. Dakwar, I. Sawczuk, R. Munver—United States

**Background:** Preoperative imaging studies are often used in the staging of prostate cancer for patients that are candidates for robotic-assisted laparoscopic radical prostatectomy (RALP). The purpose of this study is to compare local practice patterns regarding preoperative imaging to the published recommendations of the National Comprehensive Cancer Network's (NCCN) on staging workup based on risk stratification for localized disease.

**Methods:** A retrospective review was conducted of 249 consecutive patients that underwent RALP over a one year period at our institution. Most patients were diagnosed and staged by their primary urologists. Patients were divided into 2 groups: "low risk" group, for which the NCCN recommends no imaging (Gleason < 7

and PSA < 10 ng/dL); and "intermediate/high risk" group (Gleason ≥ 7 or PSA ≥ 10 ng/dL), some of which would receive preoperative imaging per NCCN guidelines. The use of computed tomography (CT), endorectal coil magnetic resonance imaging (erMRI), and bone scans were recorded for each group.

**Results:** Results: The "low risk" group consisted of 146 (58.6%) patients with a mean PSA of 4.74 ng/dL (range 0.9–9.1) and mean Gleason score of 5.99 (range 5–6). The "intermediate/high" risk group contained 103 (41.4%) patients with a mean PSA of 9.42 ng/dL (range 0.8–58.0) and mean Gleason score of 7.16 (range 7–10). None of the imaging studied suggested advanced disease in any of the 249 patients. Low risk (n = 146) Intermediate/High risk (n = 103) P value CT Scan 102 (69.9%) 87 (84.5%) p > 0.05 erMRI 39 (25.7%) 47 (45.6%) p > 0.05 Bone Scan 109 (74.7%) 89 (86.4%) p > 0.05

**Conclusion:** There is a striking discrepancy between the NCCN recommendations for preoperative imaging studies and the observed practice patterns. A significant percentage of low risk patients appeared to receive unnecessary studies.

### MP13-04 TOTAL RADIATION EXPOSURE DURING AN ACUTE STONE EVENT IN INSURED AND UNINSURED PATIENTS

D. Greene, J. Chamberlin, C. Tenggardjaja, F. Jellison, K. Huynh, D. Baldwin—USA

**Background:** Radiation exposure from computed tomography (CT) is significant resulting in 1 of 1000 patients developing a fatal malignancy. In addition to CT scans, stone patients are also exposed to ionizing radiation from plain films and fluoroscopy. Physician knowledge of radiation risks is poor and may contribute to excess exposure. Lack of health insurance may result in delays in treatment and subsequent increased radiation exposure. The purpose of this study was to determine radiation exposures in insured and uninsured patients presenting with a single stone episode.

**Methods:** A retrospective review of 100 consecutive patients who were treated for a single stone episode was performed. Diagnostic imaging, stone characteristics and demographics were recorded. Total radiation exposure was compared by insurance status (private, public and uninsured) using a linear regression with p < 0.05 considered significant.

**Results:** Age, gender, and stone burden were statistically similar between insured and uninsured patients. Privately insured patients received less radiation per stone episode than those not privately insured (34 vs. 45 mSv; p = 0.027). 6 of 50 patients with private insurance received more than 50 mSv compared to 18 of 50 without private insurance (12% vs. 36%, p = 0.004).

**Conclusion:** Patients without private insurance are at greater risk for higher radiation exposure when presenting with urinary calculi. Efforts to reduce radiation exposure in all patients are required.

### MP13-05 DOES LOW DOSE CT PREDICT URETERAL STONE SIZE?

C. Tenggardjaja, F. Jellison, F. Almaguel, J. Smith, T. Kelly, D. Baldwin—USA

**Background:** Non-contrast CT is the gold standard for evaluating urinary calculi, but results in high radiation exposure. Thus to limit radiation, low dose CT protocols have been proposed. Although we have previously demonstrated the ability of low dose CT scan to



detect ureteral stones, the ability to accurately determine stone size has not been evaluated. The purpose of this study was to compare the accuracy of low and conventional dose CT protocols to determine ureteral stone size.

**Methods:** Calcium oxalate stones were measured in the two largest dimensions and were randomly placed into a cadaver ureter. Non-contrast CT scans were performed on a cadaver model utilizing low (30 mAs) and conventional (100 mAs) doses. Two radiologists, blinded to stone sizes, then read the studies. Statistical analysis for stone accuracy measurement was compared using the intraclass correlation coefficient (ICC).

**Results:** The ability to accurately measure largest stone dimension in the axial plane, regardless of position, was similar in both the low dose and conventional CT models with an ICC of 0.897 (95% CI 0.862–0.923) and 0.911 (95% CI 0.842–0.940) respectively. In both models, measurement accuracy appeared similar when stone sizing was divided into location (proximal vs distal) and laterality (left vs right). All ICC values had a p-value less than 0.05 suggesting the positive correlation between the radiologist's reading and actual stone measurement was not due to chance.

**Conclusion:** Despite reducing radiation exposure by 70%, there was no effect upon accuracy of ureteral stone size determination. This suggests that a 30 mAs protocol is equally effective to a standard protocol in predicting ureteral stone size and therefore will successfully predict those patients that are candidates for a trial of passage.

### MP13-06 IMPACT OF THE DIFFERENCE IN TUMOR SIZE MEASURED ON IMAGING AND FINAL PATHOLOGY ON PARTIAL NEPHRECTOMY OUTCOMES

U. Boylu, M. Hopkins, M. Pinsky, A. Tracey, B. Lee—USA

**Background:** The purpose of the study was to compare the preoperative size of the tumor on imaging to the size on final pathology review in patients undergoing partial nephrectomy.

**Methods:** Between 1999 and 2009, a total of 144 open, laparoscopic, and robotic partial nephrectomies were performed. Of these 144, there were 114 solid malignant tumors. Preoperative size of the tumor on CT or MRI was compared to the size reported in final pathology. Mean follow-up time was 34 months (range: 6–96 months).

**Results:** Mean preoperative size on imaging was  $3.7 \pm 2.2$  cm (range: 1.5–10.3) and mean postoperative size in final pathology was  $3.2 \pm 2.3$  cm (range: 1.5–10) ( $p = 0.001$ ). Preoperative size was larger in 70 patients and smaller in 32 when compared to postoperative tumor size. Only 12 patients had the same pre- and postoperative tumor size. In 22 patients, who had tumors larger than 4 cm (cT1b), the size in final pathology was smaller than 4 cm (pT1a) and was subsequently downgraded in stage. Of these 22 patients, only 4 patients had positive surgical margins. No patient had clinical recurrence.

**Conclusion:** Clinical staging of renal tumors based on preoperative imaging may be higher than pathological stage. Tumor size should not be considered as strict criteria to perform partial nephrectomy, rather surgeon's judgement in the ability to resect the mass entirely.

### MP13-07 THE ROLE OF ABDOMINAL IMAGING IN THE EVALUATION OF PATIENTS FOLLOWING ROBOT-ASSISTED LAPAROSCOPIC RADICAL PROSTATECTOMY

T. Feng, J. Yohannan, J. Berkowitz, M. Allaf

**Background:** Patients undergoing robot-assisted laparoscopic radical prostatectomy (RALRP) occasionally require abdominal imaging to assess symptoms not completely explained by clinical evaluation. This retrospective study evaluates the indications and outcomes of abdominal imaging studies ordered following RALRP.

**Methods:** The records of patients who underwent transperitoneal RALRP at our institution between December 2004 and March 2009 were reviewed. All abdominal imaging studies obtained on these patients in the immediate postoperative period ( $\leq 30$  days postoperatively) were recorded. The indications, imaging findings, and postoperative course of the patients were tabulated and analyzed. The effect of surgeon experience, patient demographics, and disease related factors on the likelihood of obtaining an imaging study was analyzed.

**Results:** Of 881 patients undergoing RALRP, 65 (7.3%) underwent an abdominal imaging study. Of those imaged, 54 underwent computed tomography (CT) and 21 underwent abdominal x-ray (AXR). The main indications for obtaining these studies were abdominal pain and distention. Approximately half of the CT studies revealed clinically significant findings—namely anastomotic leak, pelvic hematoma, and bowel obstruction. Of those undergoing AXR, 76% (16) were found to have either a small bowel obstruction pattern or ileus. The mean time at imaging for CT scan and AXR was 7.3 and 2.6 days postoperatively. Mean length of stay was considerably longer for those with imaging (4.2 vs 1.8 days). Surgeon experience did not correlate with propensity to order an imaging study.

**Conclusion:** Abdominal imaging following RALRP while rarely performed is helpful in yielding a clinically significant diagnosis in the patient with complaints not explained by clinical examination and laboratory data.

### MP13-08 MINIMALLY INVASIVE MANAGEMENT WITH PERCUTANEOUS EMBOLIZATION EXPERIENCE IN TWELVE PATIENTS WITH RENAL INJURY

H. Ahn, S. Kim, J. Choi, S. Kim, H. Im, Y. Kim—Korea

**Background:** To evaluate superselective embolization therapy for the management of arterial damage in patients with severe renal trauma. We reviewed our experience with renal artery injury management at a single center.

**Methods:** Among 147 patients in the ajou university Hospital renal trauma database from 2000 to 2008, 13 patients underwent superselective embolization of the specific bleeding vessel with the use of microcoils and/or Gelfoam particles. The record of 12 patients with traumatic renal injury managed by embolization were reviewed. Procedural and medical success and complications (eg, postembolization syndrome, abscess, permanent serum creatinine elevation, hypertension) were retrospectively assessed from the patients' records. Mean clinical follow-up was  $10.1 \pm 12.0$  months (range, 1–50 months). Main renal artery injury occurred in 1 of 12 patients and segmental renal artery injury occurred in 8 of 12 patients. 2 patient occurred pseudoaneurysm a renal injury during hospitalization. Angiographic investigation of the kidneys preceded further intervention in all cases. Early complications are minor and rare and late complications e.g. hypertension, are also rare.

**Results:** All patients treated by superselective renal artery embolization had a successful outcome, including a steady renal function and a stable clinical course. No remarkable complications occurred.

**Conclusion:** Superselective embolization may be used for effective, minimally invasive control of active renovascular bleeding.

### MP13-09 MULTI-CENTER ANALYSIS OF POST-OPERATIVE CT FINDINGS FOLLOWING PERCUTANEOUS NEPHROLITHOTOMY

M. Semins, B. Chew, M. Humphreys, N. Miller, O. Shah, B. Matlaga—USA

**Background:** A benefit of CT imaging following percutaneous nephrolithotomy (PNL) is its ability to detect procedure-related complications. Presently, the incidence of such complications is not well-defined. Therefore, we performed a multi-institutional study to characterize CT-detected complications following PNL.

**Methods:** PNL procedures performed at 5 stone-referral centers between July 2007 and June 2008 were reviewed, and all patients undergoing CT within 24 hours following surgery were selected for further analysis. All CT studies were reviewed by a staff radiologist.

**Results:** 197 patients satisfied the study inclusion criteria. A BMI > 30 was present in 27.5%. Treated stone burden was: staghorn in 70 (35.5%), > 2 cm in 72 (36.5%), and < 2 cm in 55 (28%). 6 treated renal units (3%) were ectopic. 45.4% of calculi were predominantly lower pole. Thoracic complications encountered were: atelectasis in 88 (44.7%), pleural effusion in 17 (8.6%), pneumothorax in 3 (1.5%), hemothorax in 2 (1%), and hydrothorax in 1 (0.5%). Renal complications were: perinephric hematoma in 15 (7.6%), collecting system perforation in 4 (2%), subcapsular hematoma in 3 (1.5%), urinoma in 2 (1%), and pseudoaneurysm in 1 (0.5%). There was one trans-splenic nephrostomy without splenic hematoma. No injuries to hollow viscera were detected. Two patients (1%) were found with ascites.

**Conclusion:** Post-PNL complications detected by CT are uncommon, and when encountered are generally amenable to conservative management. However, in several cases presented herein, CT imaging revealed injuries that altered patient care in the peri-operative period, a benefit that supports the use of CT in the post-PNL setting not just to define a stone-free state, but also to inspect for surgical complications.

### MP13-10 UNENHANCED SPIRAL CT-ASSISTANT LOCALIZATION COMBINED WITH C-ARM IN COMPLEX RENAL STONE TREATMENT BY MINIMALLY PERCUTANEOUS NEPHROLITHOTOMY (MPCNL)

L. Jiang—China

**Background:** To investigate the use value of unenhanced spiral CT-assistant localization combined with C-arm in complex renal stone treatment by minimally percutaneous nephrolithotomy (MPCNL).

**Methods:** 86 sides of 79 cases of complex renal calculi, which would be treated by MPCNL, were given a prone position spiral CT scan and localized the puncture spot, measured the puncture distance and angle which were used in establishing a tunnel of MPCNL, then make a 2D and 3D reconstruction to determining the main stone's position and shape, the location and direction of branch of the stone, and the hydronephrotic changes and so on. The

operations were all in a complete prone position, and all the punctures were almost under the guide of outcomes of CT measure as a blind puncture, after success of puncture and guide wire insertion, the C-arm should be used to determine if the guide wire was in right position, and then established the tunnel after dilation with a peel-a-way sheath, if not, a second puncture would be undertaken. The searching for stone crush was also under the guide of the location and direction of stone branch which CT determined. A last use of C-arm was to determine if there were residue stones.

**Results:** The channels of 63 sides were built up with only one puncture, 14 with two and 6 with three, and 3 channels of complete staghorn cases with stricture calyces and calyces neck were built up under C-arm with one puncture either, the average puncture was 1.27 times per side (109/86). For all the 86 sides of 79 cases of the complicated renal calculi patients, among which including 55 sides of kidney poly-stone with part renal pelvic casting mold stone in 39 and 31 cases of whole pelvic casting mold stone. The length of stone size ranged from 4 cm ~ 10 cm, and the average operation time was 108 min (50 min ~ 210 min). All the patients except 10 achieved stone-free at 1 session in 70 and 2 session in 6 because of hemorrhage or intolerance, the total stone-clearance rate was 88% (76/86) and 81% (70/86) at 1 session.

**Conclusion:** The unenhanced spiral CT-assistant localization combined with C-arm in complex renal stone treatment by minimally percutaneous nephrolithotomy can elevate the success rate of accurate puncture effectively and decrease the use of C-arm accompany with lower radio exposure both for patients and surgeons, and it is helpful for searching and clearance of stones simultaneously.

### MP13-11 MORPHOMETRIC ANALYSIS OF THE URETEROPELVIC JUNCTION USING AN IMAGE ANALYSIS SOFTWARE

A. Mathew, A. Kurien, S. Mishra, V. Muthu, R. Sabnis, M. Desai

**Background:** To evaluate the histological characteristics of the ureteropelvic junction (UPJ) in patients with ureteropelvic junction obstruction (UPJO) and to quantify the same with image analysis based morphometry.

**Methods:** Biopsies from 131 patients who underwent dismembered pyeloplasty for UPJO in the past 5 years at our institute were analyzed. Twenty-four controls were also analyzed. Following standard processing and staining techniques, the slides were analyzed for the amount of collagen deposited in the lamina propria and between the muscle bundles. Morphometry was performed using the Micro Image TM Lite version 4.0 image analysis software. The thickness of the lamina propria and thickness of muscle layer were measured in all cases. The ratio between the two layers was also calculated.

**Results:** The mean thickness of lamina propria, mean thickness of muscle layer and the mean ratio of thickness between the two layers in adult and children control group were  $0.21 \pm 0.05$  millimeters,  $0.29 \pm 0.04$  millimeters,  $0.75 \pm 0.13$  and  $0.21 \pm 0.02$  millimeters,  $0.28 \pm 0.03$  millimeters,  $0.75 \pm 0.07$  respectively. In contrast the mean thickness of lamina propria, mean thickness of muscle layer and the mean ratio of thickness between the two layers in adult and children with UPJO were  $0.29 \pm 0.15$  millimeters,  $0.6 \pm 0.27$  millimeters,  $0.61 \pm 0.48$  and  $0.25 \pm 0.1$  millimeters,  $0.52 \pm 0.25$  millimeters,  $0.58 \pm 0.39$  respectively ( $p < 0.0001$ ). Qualitative analysis revealed an excessive amount of collagen deposited in the lamina propria as well as between the muscle bundles as compared to the controls.

**Conclusion:** The obstructed ureteropelvic junction in children and adults show significant qualitative and quantitative differences from the control population.

### MP13-12 PERCUTANEOUS ULTRASOUND-GUIDED RADIOFREQUENCY ABLATION OF RENAL TUMORS

I. Camargo, J. Del cura, R. Zabala, I. Iriarte, A. Loizaga, M. Unda

**Background:** The widespread of modern imaging modalities has led to increase the diagnosis of small renal masses and encouragement for developing therapeutic options based on nephron-sparing surgery. One of these options is the ablation of renal tumors using radiofrequency (RFA). The aim is to present our clinical experience with renal tumors ablation applying radiofrequency through percutaneous ultrasound-guided access.

**Methods:** From May 2005 to December 2008 we have performed 65 RFA using an impedance based system (Boston Scientific). The technique was carried out under conscious sedation and the needle was inserted percutaneously under ultrasound guidance. Previously, a biopsy of the lesion was always done. Post-surgical follow-up was performed by CT after one month and during the first two years, we alternate the MRI and the CT every three months. Criteria for successful treatment required lack of contrast uptake (less than 10 HU) during the follow up.

**Results:** Diameter of the tumor Complete ablation in one session Incomplete ablation/relapse Final success rate Final failure rate < 3 cm 28 (93%) 2 (7%) 29 (97%) 1 (3%) 3–3,9 cm 18 (82%) 4 (18%) 19 (86%) 3 (14%) 4–4,9 cm 6 (75%) 2 (25%) 8 (100%) 0 (0%) 5 cm or more 1 (20%) 4 (80%) 3 (60%) 2 (40%) TOTAL 53 (22%) 12 (18%) 59 (91%) 6 (9%) The stay in hospital lasted 24 hours. There was 1 cutaneous burn on the thigh and 6 perirenal hematomas.

**Conclusion:** Radiofrequency ablation of renal tumors is a viable conservative surgical approach when dealing with renal masses smaller than 4 cm in diameter. Percutaneous ultrasound-guided RFA allows an excellent anatomic visualization and an exact control of the technique. A tight clinical follow up is required to ensure the long term efficacy of this procedure.

### MP13-13 APPLICATION AND LONG TERM EFFICACY OF MAG3-F0 RENAL SCAN TO DEFINE FUNCTIONALITY AND SUCCESS IN LAPAROSCOPIC PYELOPLASTY

R. Leveillee, V. Bird, J. Bracho II, M. Aziz, G. Sfakianakis, M. Georgiou

**Background:** Laparoscopic pyeloplasty (LP) is gaining popularity as a minimally invasive technique in treatment of ureteropelvic junction obstruction (UPJO). Diuretic renography (MAG3: Mercapto-Acetyl-Tri-Glycine) is superior to determine successful surgical outcome. MAG3-F0 (simultaneous injection of Tc-99m-MAG3 and 40 mg of Furosemide) is useful as a diagnostic tool to detect improvement in renal function (RF) and as a predictor of success after LP.

**Methods:** MAG-3-F0 renal scans were performed preoperatively and at varying intervals post-operatively to assess stability versus improvement and durability of function in a single center after LP (conventional and robotic-assisted) by two different surgeons. Patient criteria for operation were based on accepted clinical and radiological findings.

**Results:** 144 LP's were performed over a 9 year period. 32 patients had pre-operative and post-operative MAG3 scans done at our

institution. Analysis of the MAG3-F0 data indicated that Early (2–4 months) post-operative studies provide only partial information regarding the effects of surgery. Delayed (8–12 months) studies indicated continued improvement. Four categories regarding the postoperative behavior could be distinguished. Chronic obstruction either with RF <40% or >40% showed improvement in drainage but not in function. Acute obstruction with SRF >40% showed slight improvement of the function. Acute obstructions with hydronephrosis, enlargement and SRF <40% showed the most improvement in function, size and drainage of the CS with return to nearly normal.

**Conclusion:** MAG3-F0 renal scan is a highly accurate and appropriate diagnostic tool to identify renal obstruction. Delayed imaging suggests continued improvements in SRF as the time from surgery expands. The greatest improvements occur in kidneys with acute obstruction with hydronephrosis and measurable functional loss. Interpretation of early post-operative scans should be made cautiously.

### MP13-14 IMAGING OF THE URETEROPELVIC JUNCTION OBSTRUCTION WITH MDCT AND DESIGNATION OF THE SURGICAL PLAN

C. Kalogeropoulou, P. Kallidonis, I. Kyriazis, A. Al Aown, J. Stolzenburg, E. Liatsikos—Greece

**Background:** Ureteropelvic junction obstruction (UPJO) is a benign disease with unpredictable course and is surgically managed when renal function is compromised. The newer minimally invasive methods for the treatment of UPJO require detailed investigation of the obstruction site.

**Methods:** Nineteen patients underwent MDCT over a period of 2 years due to suspicion of UPJO associated with compromised renal function. The protocol of the MDCT assessment included the multi-phase acquisition of enhanced and unenhanced sequences (corticomedullary, parenchymal and excretory phases). Subsequent image processing took place including techniques such as arbitrary anatomical planes reconstruction (MRP), curved planar reconstruction (CPR), maximum intensity projection (MIP) and volume rendering (VR). For reduction of radiation exposure the protocol was individualized for each patient (low dose without contrast CT scanning and reduction of examination phases). The information obtained by the above protocol was compared with the intraoperative findings.

**Results:** The presence of non-specific imaging signs indicative of UPJO (hydronephrosis, difference in the presentation of parenchymal-excretory phase etc) and crossing vessels at the site of UPJ was investigated. Five patients were treated by laparoscopic dismembered pyeloplasty and the preoperative findings provided by the current imaging protocol were confirmed intraoperatively (i.e. crossing vessels).

**Conclusion:** Multi-phase MDCT with subsequent image processing and reconstruction of multiple anatomical planes is a comprehensive one-stop examination for diagnosis, further study and surgical planning.

### MP13-15 PRELIMINARY INVESTIGATIONS OF COMPUTED TOMOGRAPHIC (CT) THERMOMETRY DURING PERCUTANEOUS CT-GUIDED RENAL TUMOR TREATMENT

R. Leveillee, N. Salas, C. Moore, L. Zhang, S. Peairs, D. Gustafson—USA

**Background:** Previous studies have determined that, for thermal minimally-invasive treatment procedures such as radiofrequency (RF) ablation in which cell death is achieved at 60°C within seconds, the treatment endpoint can be determined by temperature measurements within the target volume using computed tomography (CT), demonstrating a 0.3–0.5 change in Hounsfield units per degree C. We extend this study to demonstrate the feasibility of CT temperature monitoring during percutaneous RF renal tumor ablation.

**Methods:** Two patients with solid renal masses underwent CT-guided RF ablation with a Siemens Sensation 64-slice scanner and a single needle ValleyLab Cool-Tip RF ablation system (Covidien, Boulder, CO). Temperatures were measured before, during, and after ablation with four fiber-optic thermal sensors placed at the tumor periphery and recorded with the FocalPoint temperature monitor and TruTemp 3.0 software (Lumasense Inc., Santa Clara, CA). Under an IRB approved protocol, a software algorithm (INTIO Inc., Broomfield, CO) was used to detect the density changes between the baseline image (pre-ablation) and those taken during ablation and correlate them to the temperature change. This software uses a color scheme to map changes in the Hounsfield units, showing changes in tissue density, between a baseline image (pre-ablation) and images taken during ablation.

**Results:** Color variations in the CT images during ablation were observed within the target region.

**Conclusion:** Changes in the Hounsfield units between CT images taken before, during, and after thermal renal tumor treatment ablation suggests non-invasive temperature monitoring to ensure treatment endpoint may be possible utilizing CT density measurements.

#### MP13-16 USE OF INTRAOPERATIVE DOPPLER ULTRASOUND TO FACILITATE IDENTIFICATION OF CROSSING VESSEL DURING ROBOTIC AND LAPAROSCOPIC PYELOPLASTY

S. Parekattil, Sijo J., B. Canales, H. Atalah, L. Su

**Background:** Robotic and laparoscopic pyeloplasty (RLP) is a treatment option for ureteropelvic junction (UPJ) obstruction. A crossing vessel is often the cause for the obstruction. Our goal was to assess if Doppler ultrasound during the dissection of the UPJ would aid in identification of a crossing vessel and provide any benefit to the surgeon in terms of decreasing operative time or blood loss.

**Methods:** 40 consecutive RLP cases from Jul 2005 to Jun 2009 were reviewed. Twenty-eight (70%) of these patients were found to have a crossing vessel. 12 patients underwent the procedure with the assistance of real time intraoperative laparoscopic Doppler ultrasound (VTI probe, Vascular Technology™, NH) to identify any crossing vessel at the UPJ. Operative time and blood loss was compared between the Doppler (DO) and no-Doppler (NDO) groups.

**Results:** Mean operative time for DO was 159 minutes (60–210 min) vs. 197 minutes (90–300 min) for NDO,  $p = 0.04$ . There was no significant difference in mean estimated blood loss (52cc for DO vs. 85cc for NDO,  $p = 0.5$ ). Subjectively, intraoperative Doppler assisted the surgeon in assessing the presence/absence and

location of a crossing vessel prior to UPJ dissection and was a useful teaching tool for resident training.

**Conclusion:** The use of Doppler ultrasound identification of a crossing vessel during RLP may provide guidance to surgeons during dissection of the UPJ. These preliminary findings appear to indicate that the use of the intra-operative Doppler may decrease overall operative time, however further prospective studies and evaluation are warranted to confirm these observations.

#### MP13-17 MR GUIDED LASER INDUCED THERMOTHERAPY (LITT) OF THE KIDNEY

S. Vallo, S. Zangos, D. Jonas, W. Bentas—Germany

**Background:** Today MR guided laser induced thermotherapy (LITT) is already used for treatment in different organs. Till now there exist no standardized studies for the treatment of kidney neoplasms. The aim of this study was to show the feasibility and efficacy of LITT in ex vivo kidney tissue.

**Methods:** In this study 15 pig kidneys were ablated. Direct after slaughter kidneys were perfused with 0.9% saline. Laser treatment was performed using a Nd-Yag laser for 7, 10 or 13 min. Kidneys were at a constant temperature of 37°C. During the treatment, heat distribution in the tissue was documented using thermosensitiv T1 MR sequences. Lesion size and shape was measured and correlated with pathological findings.

**Results:** After the treatment with LITT, there are round whitish lesions with a mean diameter of  $2.0 \pm 0.5$  cm. Size of lesions correlated macroscopically with the measured lesions in MRI. Control of lesion volume only by alteration of treatment time was not sufficient, because size of the lesion was influenced by surrounding structures like renal pelvis, parenchyma or kidney cyst. With MR guidance we could obtain a real-time monitoring of the ablation size.

**Conclusion:** Thermometry with real-time MR guided LITT allows continuous controlled ablation and is an alternative treatment option for patients with an increased risk for general anesthesia or with only one kidney left.

#### MP13-18 NON DESTRUCTIVE EX VIVO URINARY STONE COMPOSITION ANALYSIS USING COHERENT-SCATTER COMPUTED TOMOGRAPHY

C. Mendez Probst, L. Nott, J. Denstedt, I. Cunningham—Canada

**Background:** At present, calculi are subjected to either infrared spectroscopy (IRS) or conventional x-ray diffractometry to determine composition. Both methods are limited to surface analysis requiring that stones be powdered, then examined and a bulk measure of composition is obtained. Many stones have a heterogeneous composition in layers around a central core. Coherent-scatter computed tomography (CSCT) could provide superior detailed structural information, including composition at the core of the stone, which could be a consideration in stone recurrence prevention management.

**Methods:** In an ongoing prospective trial examining urinary calculi from consenting patients undergoing percutaneous nephrolithotripsy, calculi were removed and initially analyzed with CSCT and then IRS. Stone analyses from the two modalities were compared for overall bulk composition and the CSCT data analyzed to determine composition of the core.

**Results:** To date, 45 stones have been examined. There is 100% agreement between CSCT and IRS when identifying the composition for uniform stones, 90% on the primary fraction by mass. Furthermore, CSCT identified core material that is not equal to IRS primary material in 40% of the stones and in 20%, reported core material not seen by IRS. In this subset, 50% of the cores were composed of uric acid (UA).

**Conclusion:** Our data indicates both methods are technically accurate. However, in a significant number of stones, IRS was miss-reported or did not report the mineral component at the core of the stone. With the high incidence of UA cores, CSCT may help guide medical stone prophylaxis in the future.

### MP13-19 PREVALENCE OF NEPHROLITHIASIS IN AN ASYMPTOMATIC SCREENING POPULATION: ADDITIONAL FINDINGS ON VIRTUAL COLONOSCOPY

S. Stroup, J. Durbin, G. Patino, D. Lacey, J. L'esperance, B. Auge—USA

**Background:** Virtual colonoscopy, or computed tomography (CT) colonography, has been developed as a non-invasive means to screen for colon cancer. CT colonography has proven effectiveness in identifying approximately 90% of adenomas and colon cancers greater than 10 mm in size. We sought to determine the incidence of nephrolithiasis in a group of asymptomatic adult patients undergoing virtual colonoscopy.

**Methods:** Five-hundred twenty-seven patients who were referred for screening colonoscopy were enrolled in an IRB-approved protocol and underwent CT colonography followed by standard endoscopic colonoscopy. Four-hundred ninety patients completed the study. The CT images were utilized to determine the incidence, size, and laterality of nephrolithiasis. Other genitourinary abnormalities were evaluated by a single radiologist and grouped into categories of minor, moderate, and major clinical significance.

**Results:** Of the 490 patients who underwent CT, 68 (13.9%) were found to have at least 1 stone in either kidney. The largest stone seen was 1.2 cm, and the smallest was 1 mm, 59% had stones <3 mm, 20% between 3 mm and 5 mm, 18% between 5 mm and 10 mm, and 3% >10 mm in size. Seventy percent of patients had a single stone, while 30% had multiple and 18% had bilateral stones. The average number of stones was 2, (range 1–16).

**Conclusion:** Virtual colonoscopy has become an alternative to endoscopic inspection for screening of colon cancer. The prevalence of nephrolithiasis in our older screening population was 13.9% and is higher than previously reported.

### MP13-20 ACUTE CHANGES IN THE RENAL RESISTIVE INDEX IN A SOLITARY KIDNEY WITH A URETERAL STONE: A COMPARATIVE IN VIVO PORCINE STUDY

R. Venkatesh, S. Labarbera, N. Das, G. Baca, R. Figenshau, A. Tawfik—USA

**Background:** We studied the changes in renal resistive index (both arterial and venous) in a porcine model with and without a ureteral stone in a solitary kidney and also with normal contralateral kidney.

**Methods:** Twenty four female domestic pigs were divided into 4 groups; each of 6 animals. Group 1: control group, Group 2: solitary kidney without a ureteral stone, Group 3: ureteral stone with a normal contralateral kidney, Group 4: solitary kidney with a ureteral stone. In the solitary kidney model, a laparoscopic nephrectomy was performed before evaluating the contralateral ureter. Renal resistive index (RI), (arterial, venous and hilar) was measured in all animals on hourly basis for 5 hours using a duplex ultrasound after exposing the kidney through a lumbotomy incision. Ureteral activity and intrapelvic pressure was also measured, a 6 mm stone was placed in the proximal ureter in groups 3 and 4. Duplex ultrasound probe was placed at 3 positions on the kidney surface (upper, mid and lower pole) and the average was calculated.

**Results:** Immediately after nephrectomy in group II animals, the median RI values was lower in comparison to control pigs (0.59 in group II and in comparison to 0.63 in group I). This decline was maximum during the second hour reading. After 2 hours, the RI started to rise to be very close to the control group reading by the hour 5 reading. These changes were very similar but more apparent in animals of group III, where placing stone in the ureter drove the RI downwards for the first hour then with a slow rise. (0.62 before stone placement, 0.56 at H1 and 0.63 at H5). In group IV animals, although RI was lower after nephrectomy (0.57), it didn't show further decline with ureteral stone placement. Though the above changes could represent trends, none were statistically significant.

**Conclusion:** In the above porcine study, contra-lateral nephrectomy or ureteral stone obstruction produced an insignificant acute biphasic changes in renal blood flow with slight initial increase then gradual decline of RI. Also after contralateral nephrectomy, ipsilateral ureteral obstruction from stone did not further increase the renal blood flow. The venous RI was not a reliable parameter to measure renal RI.

## MP14: LAPAROSCOPY—KIDNEY 1

### MP14-01 MALE VERSUS FEMALE LAPAROSCOPIC PARTIAL NEPHRECTOMY: IS THERE A DIFFERENCE?

H. Jung—USA

**Background:** There is anecdotal evidence that laparoscopic renal surgery may be technically more difficult in the male patient, when compared to female. This may be due to a more difficult hilar and

perinephric fat dissection. We compared surgical parameters of male and female laparoscopic partial nephrectomies (LPN). We chose to study LPN because it requires both hilar and perinephric fat dissection.

**Methods:** We reviewed our database of LPN. We compared patient parameters, tumor characteristics and operative results of 69 patients who underwent LPN; 28 females and 41 males, from April

2005 to October 2008. Statistical analysis was performed using a student's t-test to compare mean values.

**Results:** Estimated blood loss was the only significantly different factor between male and female LPN. The results are outlined in Table 1. Male Female p-value Age (yrs) 58.857.4 0.652 BMI (kg/m<sup>2</sup>) 30.330.4 0.967 ASA 2.52.2 0.444 CT tumor size (cm) 2.72.8 0.753 Operative time (min) 264243 0.576 Warm ischemia time (min) 2831 0.193 Pathologic tumor size (cm) 2.52.6 0.753 Estimated Blood Loss (cm) 364175 0.014 Hospital Stay (days) 2.33 0.271.

**Conclusion:** Other than a higher estimated blood loss, there was no difference between male and female LPN's. A possible explanation for this finding is the thicker and denser androgenized retroperitoneal perinephric fat in the male population.

### MP14-02 LAPAROSCOPY-ASSISTED PARTIAL NEPHRECTOMY THROUGH A SMALL INCISION

O. Kamihira, Y. Yoshikawa, A. Fukatu, K. Kimura, Y. Moriya, O. Matsuura—Japan

**Background:** We developed a minimally invasive technique for partial nephrectomy which is performed easily and safely through a small incision.

**Methods:** The patient was a 57 year-old woman with a 2.5 cm mass in her left kidney. Under the clinical diagnosis of renal cell carcinoma, partial nephrectomy was selected for treatment. Since a small artery fed the upper pole directly, making it difficult to clamp the renal hilus, we decided to compress the renal parenchyma with an aortic clamp to control renal blood flow. Under general anesthesia, a small oblique incision was made in her left flank. After the lateroconal fascia was incised and perirenal fat was removed, we grasped the renal parenchyma with the aortic clamp directly. To control bleeding, we used a tweezer-type bipolar handpiece which had water outlet in its tips to flush saline into a coagulating field. After removal of the tumor, the resected stump was covered with autologous fat.

**Results:** With the aid of the aortic clamp, we could attenuate the blood flow and lift the kidney near the incision to operate easily. Bleeding was controlled by clamping vessels with bipolar handpiece which successfully coagulated tissues in combination with the VIO system™ (ERBE).

**Conclusion:** Although not all RCC tumors can be managed with our technique, in patients where possible, it is valuable for safe and easy operation, alleviating ischemic damage to residual renal function.

### MP14-03 A RANDOMIZED, DOUBLE-BLINDED TRIAL OF KETOROLAC IN ADDITION TO NARCOTIC PATIENT-CONTROLLED ANALGESIA (PCA) FOLLOWING LAPAROSCOPIC DONOR NEPHRECTOMY

K. Pace, D. Ghiculete, R. Honey—Canada

**Background:** The ideal postoperative pain management regimen for laparoscopic donor nephrectomy (LapDN) has not been elucidated. The current standard is PCA. We sought to examine the impact of adding intravenous (IV) ketorolac to PCA following LapDN on post-operative recovery and quality of life (QOL).

**Methods:** 78 patients scheduled to undergo LapDN were enrolled and randomized. All patients received intravenous narcotic PCA post-operatively, in addition to either 10 mg saline (group 1) or IV ketorolac (group 2) q6 h for 48 h. Data was collected on analgesic

usage, bowel function, serum creatinine, and QOL as assessed by the Post-operative Recovery Scale (PRS, a modification of the SF-36 that includes visual analog assessments of pain). Data were analyzed with Chi-square, ANOVA and repeated measures ANCOVA.

**Results:** There were no differences between the groups at baseline. Length of stay was similar (101.2 vs. 99.4,  $p = 0.77$ ), but there was less PCA narcotic usage in group 2 (114.9 vs. 148.0 mg morphine equivalent,  $p = 0.02$ ). QOL scores were significantly higher in group 2 throughout the immediate post-operative period ( $p = 0.025$ ). By two weeks and three months post-operatively the difference in QOL scores between the two groups disappeared ( $p = 0.60$ ). There were no differences in serum creatinine between the two groups ( $p = 0.06$ ). There was a trend towards a lower rate of ileus in group 2 ( $p = 0.39$ ).

**Conclusion:** Ketorolac improves pain control and QOL in the immediate post-operative period, reduces morphine usage, and has no adverse impact on renal function in patients undergoing LapDN.

### MP14-04 COMPARISON OF INVASIVENESS BETWEEN TRANSPERITONEAL AND RETROPERITONEAL APPROACHES IN LAPAROSCOPIC NEPHRECTOMY BY MEASURING CIRCULATING CYTOKINES

S. Narita, T. Kumazawa, M. Saito, Y. Horikawa, N. Tsuchiya, T. Habuchi

**Background:** In recent years, minimally invasive surgeries such as laparoscopic surgeries for various urological diseases have been widely accepted in many urologists. Although it is believed that the retroperitoneal approach (RA) is less invasive than the transperitoneal approach (TA), the scientific basis for this hypothesis is not well understood. It is suggested that perioperative cytokine levels reflect surgical invasiveness and postoperative risk of infection. In this study, we attempted to compare objectively the invasiveness of TA and RA in laparoscopic nephrectomies by measuring perioperative cytokine levels.

**Methods:** The present study included 105 patients who underwent nephrectomy, 75 by TA (33 radical and 42 donor) and 30 by RA (18 radical and 12 donor). Serum samples were obtained from each patient at three time points, i.e., before operation, immediately after operation, and on postoperative day 1 (POD1). The levels of six cytokines (IL-10, IL-6, TNF- $\alpha$ , IL-1 $\beta$ , IL-8, and IL-12), and C-reactive protein (CRP) as well as the white blood cell (WBC) counts were measured to compare the surgical invasiveness of TA and RA.

**Results:** The mean WBC count on POD1 was higher in the TA group ( $12060 \pm 5408$ ) than in the RA group ( $9813 \pm 3597$ ) ( $p = 0.051$ ). There was no significant difference between the two groups in the mean levels of CRP, IL-10, TNF- $\alpha$ , IL-1 $\beta$ , IL-8 and IL-12 at all time points. The mean IL-6 level immediately after operation was significantly higher in the RA group ( $164.7 \pm 279.0$  pg/ml) than in the LA group ( $132.3 \pm 401.0$  pg/ml) ( $p = 0.005$ ). The mean IL-6 level on POD1 was significantly higher in the RA group ( $87.7 \pm 83.9$  pg/ml) than in the LA group ( $67.7 \pm 135.8$  pg/ml) ( $p = 0.006$ ).

**Conclusion:** Since IL-6 induces local inflammation by amplifying leukocyte recruitment, the results of our immunological study suggest that TA is less invasive than RA in laparoscopic nephrectomy from the perspective of cytokine production.

### MP14-05 HIGH OPEN CONVERSION RATE IN LAPAROSCOPIC RENAL ABLATIVE SURGERY IS LIMITED WITH 20 CASES

O. Sanli, T. Tefik, M. Ortac, S. Karakus, F. Ozcan, H. Issever—Turkey

**Background:** To report the initial experience with the laparoscopic renal ablative surgical procedures in comparison with open counterparts.

**Methods:** We prospectively reviewed the outcomes of the initial 131 laparoscopic renal ablative surgeries (radical nephrectomy (RN, n = 50), simple nephrectomy (SN, n = 51), nephroureterectomy (NU, n = 16), partial nephrectomy (PN, n = 11), heminephroureterectomy (n = 2) and nephrectomy for ectopic kidney (n = 1)) in comparison with 142 open surgeries (62 RNs, 19 SNs, 35 donor nephrectomies, 7 NU and 19 PN). We evaluated demographics, estimated blood loss (EBL), operative time, change in hemoglobin level, length of hospital stay (LHS) and complications.

**Results:** Open conversion rate (OCR) was found to be 7.63% (n = 10; 7 RN, 3 SN). The OCR was 30% (n = 6) in the first 20 cases, whereas this rate was found to be 3.60% (n = 4) in the remaining 111 cases. Despite, the mean operative time was statistically higher in the complete laparoscopy group (n = 131); the LHS was significantly lower. Meanwhile, both the mean EBL and hematocrit drop for laparoscopic procedures were lower than open surgeries. The rate of complications for laparoscopic and open procedures were 25.2% (n = 33, Clavien I: n = 12; Clavien II: n = 15; Clavien IIIa: n = 1; Clavien IIIb: n = 4; Clavien IVa: n = 1) and 26.7% (n = 38, Clavien I: n = 8; Clavien II: n = 26; Clavien IIIa: n = 2; Clavien IVa: n = 2) after a mean follow-up of  $14.68 \pm 9.71$  (1–45) and  $16 \pm 9.1$  (1–39) months, respectively (p = 0.683).

**Conclusion:** Laparoscopic procedures are associated with decreased hospital stay and better cosmesis. However, initiating a laparoscopic renal ablative surgery programme is associated with a high OCR in the first 20 cases. These unfavorable outcomes decrease with the increasing experience in laparoscopic surgery.

### MP14-06 PERIOPERATIVE OUTCOMES OF THE MANAGEMENT OF RENAL TUMORS IN THE ELDERLY

A. Herati, A. K. George, S. S. Saluja, A. K. Srinivasan, M. A. Vira—United States

**Background:** Improved life expectancy combined with an aging population has led to an increase in operative interventions in patients traditionally managed conservatively. However, very little is known about the complications of surgical extirpation versus minimally invasive cryoablative and radiofrequency therapies.

**Methods:** Retrospective analysis was conducted to identify patients over the age of 75 that presented to a single institution for the surgical management of renal mass. Demographic, clinicopathologic, and perioperative factors of patients undergoing open resection (N = 30), laparoscopic resection (N = 46) and percutaneous ablation (N = 24) were analyzed.

**Results:** The mean age of patients in the open, laparoscopic, and ablative groups were 78.27, 80.57, and 85 years respectively. No significant differences existed in the demographics, ASA, or BMI. Those patients undergoing percutaneous treatment had the lowest intra-operative and post-operative transfusion rate 0% (0/24), followed by laparoscopic 17.3% (8/46) and open resection 50% (15/

30). Patients in the laparoscopic arm had the lowest post-operative transfusion rate at 15.2% (7/46) when compared to the percutaneous and open group, although the difference was not significant. The postoperative complication rates of the open, laparoscopic, and percutaneous groups were 60% (18/30), 19.5% (9/46), and 37.5% (9/24) respectively. Complications in the three groups included altered mental status, decompensated CHF, bleeding, hematoma, urinoma, and acute renal failure. No mortalities were noted.

**Conclusion:** Patients undergoing open resection, laparoscopic resection, and percutaneous ablation of renal tumors are comparable in morbidity and mortality in the octogenarian population. Long-term studies are needed to determine what impact these surgeries have on the expected survival.

### MP14-07 COMPARISON OF CONVALESCENCE AND POSTOPERATIVE PAIN USING VARIOUS HAND PORT INCISION LOCATIONS

D. Kaplon, S. Hedican, S. Nakada—wi USA

**Background:** The purpose of this study is to compare convalescence and postoperative pain between varying hand port incision sites in patients undergoing hand assisted laparoscopic nephrectomy (HALN).

**Methods:** We performed a retrospective chart review to assess perioperative opioid analgesic requirements and postoperative convalescence parameters in patients undergoing varying incision locations with hand assisted laparoscopic nephrectomy at our institution between August 2002 and November 2007. A telephone survey was performed to determine duration of recovery after discharge from the hospital. Patients were grouped according to hand port incision site. ANOVA analysis was performed to compare opioid analgesic requirement, time to return to activities of daily living (ADLs), time to return to work, and time to feeling fully recovered between hand port sites.

**Results:** A total of 193 patients underwent hand assisted laparoscopic nephrectomy at our institution between August 2002 and November 2007. One hundred patients could be contacted for complete follow-up information. Forty-two patients had a lower quadrant hand port incision (LQ), 32 had a midline incision (ML), 18 had a subcostal incision (SC), and 8 had a paramedian incision (PM). Mean age for all patients was 59 (range 21–83) years and mean length of stay (LOS) was 4 (range 2–11) days. Three patients developed postoperative wound infection (1 ML, 2 LQ) and no patients developed a symptomatic port site hernia. There was no significant difference in mean age or mean LOS between the four groups. Mean morphine equivalent analgesic dose was not significantly different between the four groups (p = 0.63). A statistically longer time to return to ADLs was noted in the SC group (mean 12 days, p = .04) as compared to the other three groups, but the groups did not differ with regard to time to return to work (p = 0.82) or time to feeling fully recovered (p = 0.81).

**Conclusion:** Our data does not reveal a significant difference with regard to post-operative pain or convalescence between varying hand port sites in HALN with exception of the subcostal location. We conclude that it should be left to surgeon preference when deciding where to place this incision, understanding the increased time to return to ADL in the SC group.

### MP14-08 PROLONGING THE POST-OP LENGTH OF STAY FOLLOWING LAPAROSCOPIC NEPHRECTOMY. A CAUTIONARY TALE ON THE INTRODUCTION OF AN INTEGRATED CARE PATHWAY

A. Stewart, R. Khafagy, G. Lewis, J. Barrie, J. Cartledge—UK

**Background:** To allow best practice in the post-operative management of patients undergoing laparoscopic nephrectomy to be shared between several wards, and allow continuity of management out-of-hours and at weekends, we developed a standardised care pathway. Lessons learnt from its introduction are presented. **Methods:** An integrated care pathway was written with input from Endo-urologists, Consultant Anaesthetists & Urology Nursing Staff. Prospective interim analysis of the pathway was compared with retrospective data for all patients undergoing laparoscopic nephrectomy under the care of a single consultant prior to its introduction. A replacement didactic pathway was introduced and further prospective outcome data collected.

**Results:** Pre Co-Operative Didactic Number of Patients 196 1166 Age (Mean) 21–89 (56) 36–78 (56) 28–90 (57) Length of Stay (Median) Days 3–105 (4) 3–21 (5) 2–16 (3) Transfusion (%) 4 (2%) 01 (1.5%) Conversion (%) 7 (3.5%) 1 (9%) 0

**Conclusion:** The introduction of an over complicated integrated care pathway successfully extended the median length of stay following laparoscopic radical nephrectomy and nephroureterectomy without a demonstrable improvement in outcomes. An alternative, simplified pathway has reduced median length of stay and maintained quality. It is now the standard of care in our institution.

### MP14-09 RETROPERITONEAL APPROACH IS ADVANTAGEOUS TO TRANSPERITONEAL APPROACH IN TERMS OF OPERATIVE TIME; BLOOD LOSS AND LENGTH OF HOSPITAL STAY FOR LAPAROSCOPIC NEPHRECTOMIES

T. Tefik, O. Sanli, T. Mut, A. Atar, E. Aliyev, Nane

**Background:** We compared the laparoscopic transperitoneal (TA) and retroperitoneal (RA) approaches for laparoscopic nephrectomies (LNs) in a prospective manner to assess the differences with respect to perioperative outcomes and morbidity.

**Methods:** Between September 2005 and June 2009, 131 patients (TA = 65 patients, RA = 66 patients) underwent LNs in our institution. All data were prospectively recorded on a database system and then retrospectively reviewed.

**Results:** There was no statistically significant difference in BMI, gender or ASA score and nephrectomy types between two groups. The patients in RA tended to be younger ( $50.91 \pm 16.38$  vs.  $44.13 \pm 19.22$ ,  $p < 0.05$ ). 121 procedures were technically successful without the need for open conversion, while 5 approaches from each group required conversion to open surgery. Compared to the TA, the RA was associated with shorter total operative time ( $147 \pm 64.9$  vs.  $107 \pm 39.2$  minutes,  $p < 0.005$ ), lower estimated blood loss ( $303.2 \pm 404.0$  vs.  $152.2 \pm 276.1$  mL,  $p < 0.005$ ), lesser number ( $4.46 \pm 0.53$  vs.  $3.42 \pm 0.84$ ,  $p < 0.005$ ) and size of trocars used and shorter hospital stay ( $3.97 \pm 2.63$  vs.  $3.36 \pm 2.53$ ,  $p < 0.005$ ). However, the TA and RA were similar in terms of transfusion (13.8% vs. 6.1%,  $p = 0.156$ ) and overall complication rates according to Clavien grading system (26.2% vs. 24.2%,  $p = 0.842$ ). All patients in both groups resumed oral intake on postoperative day 1.

**Conclusion:** The present study revealed no significant difference between the two approaches related with patient morbidity. However, there are some advantages of RA when compared to TA such as operative time, estimated blood loss and length of hospital stay.

### MP14-10 IS LAPAROSCOPIC NEPHRECTOMY INDICATED IN NONFUNCTIONING GIANT HIRONEPHROTIC KIDNEYS?

M. Arslan, T. Degirmenci, B. Gunlusoy, S. Minareci, A. Ayder—Turkey

**Background:** To report our experiences on nonfunctioning giant hidronephrotic kidneys—with or without stone—with laparoscopic transperitoneal nephrectomy (LTPN).

**Methods:** Between June 2006 and April 2009 we performed 24 (15 female, 9 male) LTPN for nonfunctioning hidronephrotic kidneys. The mean age was 37 (17–65) years. Preoperative abdominal computerised tomography and renal sintigraphy were ordered. In LTPN procedure 4-ports (2 ports 5 mm, 1 port 10 mm, 1 port 12 mm) were used. Harmonic scalpel and ligasure were used for dissection and the control of small vessels. Endogia stapler or polymer ligation clips were used for renal pedicle control. All of the specimens were taken out in endobags through camera port after morcellation.

**Results:** All included cases demonstrated a mass with a longitudinal length of 20 cm or more on CT and had renal function less than 10% on renal sintigraphy. Mean operation duration was 128 minutes, mean blood loss was 180 ml, mean hospitalization duration was 2.75 days in LTPN patients. Complications occurred in 4 patients, but there was no need to return to open surgery. Mean wound healing time was 12.6 days, and mean time to return to normal activities was 18.6 days. Mean follow-up time was 12.4 (3–32) months.

**Conclusion:** Open surgery remains to be a safe and effective procedure in giant hidronephrotic nonfunctioning kidneys. By the help of increasing experience, LTPN—which has better cosmetic results and faster recovery period—can be performed for giant hidronephrotic nonfunctioning kidneys.

### MP14-11 CRYOABLATION OF SMALL RENAL MASSES IN SOLITARY KIDNEYS

Z. Okhunov, M. Ordonez, J. Rosales, B. Shingleton, J. Landman

**Background:** We evaluated the feasibility of cryoablation for small renal masses in patients with solitary kidneys.

**Methods:** We retrospectively evaluated prospectively collected databases of two institutions. A total of 32 patients were identified with solitary kidneys that underwent percutaneous or laparoscopic cryoablation between 2006 and 2008.

**Results:** In our cryoablation database thirty two patients were identified with solitary kidneys. In the solitary kidney group, there were nine females (28.1%) and 23 males (71.9%) with the mean age of 62 (range 40–83). The mean tumor size was 2.2 cm (0.7–4.4 cm). Eighteen (56.3%) cases were performed laparoscopically and 14 (43.8%) percutaneously. There were 15 (46.9%) left side and 17 (53.1%) right side tumors. There were 12.5%, 40.6%, 25% and 6.3% of exophytic, mesophytic, endophytic and hilar tumors, respectively. The biopsy at cryoablation revealed 66.7% renal cell carcinoma variants; additionally there were 30% benign tumors and 3.3% nondiagnostic biopsies. Preoperative and immediate



postoperative creatinine levels averaged at 1.3 ( $\pm 0.37$ ) and 1.23 ( $\pm 0.23$ ), respectively; ( $p = 0.27$ ). Immediate postoperative and late creatinine levels averaged at 1.2 ( $\pm 0.23$ ) and 1.26 ( $\pm 0.37$ ), respectively; ( $p = 0.47$ ). There were 3 (9.4%) minor complications, and no major complications. The first and second freeze minutes averaged at 14 ( $\pm 8.1$ ) and 9 ( $\pm 4.4$ ) minutes, respectively. The length of hospitalization averaged at 0.5 days (range 0 to 2 days). There were no incomplete ablations. With the mean follow-up of 18.3 months (range 1–60) there were 2 (6.2%) persistent enhancements on follow-up CT images.

**Conclusion:** With short-term follow-up, laparoscopic and percutaneous cryoablation of small renal cortical neoplasms seems effective and safe in patients with solitary kidneys. Renal function appears to be preserved in this challenging population. Longer follow-up with a larger number of patients is required to evaluate long-term oncological and functional outcomes.

### MP14-12 IMPACT OF WARM ISCHEMIA ON RENAL FUNCTION FOLLOWING LAPAROSCOPIC PARTIAL NEPHRECTOMY: A MULTICENTER STUDY

S. Shikanov, D. Lifshitz, S. Matin, J. Landman, J. Wolf, Jr., A. Shalhav—USA

**Background:** The impact of warm ischemia (WI) on global renal function following laparoscopic partial nephrectomy (LPN) is uncertain. This study assessed the influence of ischemia on renal function in LPN patients with 2 functioning kidneys in a large, multicenter cohort.

**Methods:** The demographic, clinical and surgical characteristics, tumor parameters and renal function outcomes were collected from 4 institutions for 401 LPN patients with 2 functioning kidneys. Postoperative and last (>1month) estimated glomerular filtration rate (eGFR) were calculated from 4-variable MDRD equation. Ischemia time and co-variables were modeled on %change eGFR using linear regression.

**Results:** Median (IQR) ischemia time was 29 (22–34) min. Median baseline, postoperative and last eGFR were 78, 65 and 71 ml/min/1.73 m<sup>2</sup>, respectively and postoperative %change eGFR–16% and last %change eGFR–11% at median follow-up of 13 months. Median (IQR) tumor size was 2.5 cm (2.0–3.5), 247 (62%) patients were male and 74 (18%) had diabetes. In 49 (12%) of cases external or ureteral irrigation with cold saline was applied. In multivariate analysis shorter ischemia ( $\beta - 0.3$ ,  $p = 0.03$ ) and surgery time ( $\beta - 0.06$ ,  $p = 0.03$ ), use of cold saline irrigation ( $\beta 11.1$ ,  $p = 0.003$ ) and female gender ( $\beta - 6.4$ ,  $p = 0.02$ ) were associated with a smaller postoperative % change eGFR decrease. Smaller tumor size ( $\beta - 1.9$ ,  $p = 0.05$ ) and absence of diabetes ( $\beta - 6.2$ ,  $p = 0.05$ ) were associated with a smaller last % change eGFR decrease. Ischemia time was not associated with last %change eGFR on univariate analysis.

**Conclusion:** Warm ischemia in the clinical range has no significant impact on global renal function in LPN patients with 2 functioning kidneys, probably due to compensatory effect of the contralateral kidney.

### MP14-13 PROSPECTIVE COMPARISON OF LAPAROSCOPIC RADICAL NEPHRECTOMY (LRN) VERSUS OPEN RADICAL NEPHRECTOMY (ORN)

O. Sanli, T. Tefik, M. Ortac, S. Karakus, F. Kucukdurmaz, T. Esen—Turkey

**Background:** We aimed to compare the outcomes of LRN versus ORN at our institution.

**Methods:** From September 2005 to June 2009, 100 patients diagnosed with renal mass underwent laparoscopic (50 patients) and open (50 patients) radical nephrectomy. A review was performed of a prospective database of patients for comparing demographic, operative and postoperative data.

**Results:** The mean age ( $55.90 \pm 12.60$  vs.  $59.46 \pm 14.61$ ,  $p = 0.20$ ) and BMI ( $27.37 \pm 5.14$  vs.  $27.67 \pm 4.65$ ,  $p = 0.76$ ) were similar in both groups. Patients in the open and laparoscopic groups were comparable in regard to mean tumor size ( $5.00 \pm 2.02$  vs.  $5.64 \pm 2.14$ ,  $p = 0.16$ ). There was no statistical difference between groups in terms of transfusion ( $p = 0.27$ ) and complication rate ( $p = 0.45$ ). The mean operation time was longer in LRN group ( $132 \pm 68$  vs.  $98 \pm 38$  minutes,  $p < 0.005$ ); whereas the mean hospital stay ( $3.82 \pm 2.99$  vs.  $5.32 \pm 2.07$  days,  $p < 0.005$ ) was shorter. The Hct drop ( $3.39 \pm 2.59$  vs.  $5.13 \pm 4.61$ ,  $p = 0.01$ ) and the mean blood loss ( $315 \pm 457$  vs.  $390 \pm 256$  mL,  $p < 0.005$ ) was lower in the LRN group. The recurrence rate was similar in both groups (2% in LRN and 4% in ORN,  $p = 0.95$ ). After a mean follow-up  $13.4 \pm 7.6$  (1–38) and  $13.0 \pm 8.3$  (1–33) months, overall and cancer specific survival rates were 98% and 98%; 86% and 90% for both groups ( $p = 0.714$ ,  $p = 0.32$ ), respectively.

**Conclusion:** The present study confirmed the major advantages of LRN such as hospital stay and blood loss. Moreover short to intermediate term oncologic outcomes are comparable to those of the open experience.

### MP14-14 VIDEO ASSISTED MINILAPAROTOMY NEPHRON SPARING SURGERY FOR CHALLENGING CASES OF RENAL TUMORS IN A SOLITARY KIDNEY

S. Lee, K. Koo, H. Jeon, S. Yang, W. Han

**Background:** Continued advances and refinements in conventional and laparoscopic technology have made the hybridization of video assisted minilaparotomy nephron sparing surgery (VAM-NSS) feasible for anatomically complex renal tumors. We describe our experience with the VAM-NSS for challenging cases of renal tumors in a solitary kidney.

**Methods:** A retrospective study was performed in 184 patients underwent VAM-NSS between October 2000 and December 2008. Three patients who had undergone VAM-NSS for complex renal tumors in a setting of solitary kidney were identified. Data were analyzed for parameters including preoperative, perioperative, and postoperative course.

**Results:** VAM-NSS was successfully completed in all three patients without perioperative complications. The operative time for each patient was 152, 330, and 252 min, whereas cold ischemic time was 40, 73, and 52 min, respectively. Tumor size was 2.5, 6.5, and 5.5 cm, respectively, all within 5 mm of the hilar vessels and involving the renal pelvis. All patients had negative margins on the final pathologic examination. Remaining renal units retained adequate function to maintain postoperative serum creatinine level at 1.2 mg/dl (1.1–1.3). After a mean follow up period of 26 months CT scan revealed no tumor recurrence.

**Conclusion:** VAM-NSS for complex renal tumors is a safe and reasonable surgical option. Given the technically challenging nature of complex renal tumors, intraoperative hypothermia is an essential factor in preserving postoperative renal function. The ability of VAM-NSS to safely achieve and maintain renal surface

hypothermia, and to clamp renal vessels in both direct and simultaneous magnified vision allows excellent oncological, functional, and cosmetic results.

### MP14-15 PREDICTING ONCOLOGICAL OUTCOMES IN PATIENTS UNDERGOING LAPAROSCOPIC NEPHROURETERECTOMY

M. Lee, G. Haber, K. Kamoi, D. Snow, J. Kaouk, I. Gill—USA

**Background:** In the last decade, laparoscopic nephroureterectomy (LNU) has emerged as an alternative treatment for urothelial carcinoma of the upper urinary tract (UC-UUT). We analyzed the factors to predict overall, disease-specific and recurrence-free survival of patients treated by LNU.

**Methods:** 217 consecutive patients who were treated with LNU for UC-UUT between 9/1997 and 2/2008 at the Cleveland Clinic (Cleveland, OH, USA) were identified. Data was collected prospectively and retrospectively when missing. Survival was determined from clinical follow up and the Social Security Death Index. The factors affecting overall, disease-specific and disease-free survival were analyzed using Cox proportional hazard model.

**Results:** The median age at the time of surgery was 75 years (IQR 65–80). Median follow up was 35 months (IQR 18–64). Kaplan-Meier estimate revealed that 5-years overall, disease-specific and recurrence-free survival was 54%, 76% and 60%, respectively. In multivariate analysis T stage (muscle invasive) and positive surgical margin were independent predictors for disease-specific survival ( $P < 0.01$  for all). Five-year disease-specific survival rate was 92% in the non-invasive diseases (127 patients) and 52% in the muscle invasive diseases (90 patients). Positive surgical margin was documented in 20 patients whose median survival was 17 months. In multivariate analysis grade 3 tumor in the pathological specimen was an independent predictor for recurrence-free survival ( $p < 0.05$ ). Five-year disease-free survival rates were 79% in the patients without grade 3 tumor (71 patients) and 49% in the patients with grade 3 tumor (146 patients).

**Conclusion:** For patients undergoing LNU, T stage 2 or higher was an independent predictor for disease-specific survival and tumor grade 3 was an independent predictor for recurrence-free survival. Patients with positive surgical margin had overall poor prognosis.

### MP14-16 OUTCOMES OF LAPAROSCOPIC RADICAL SURGERY FOR RENAL AND UPPER URINARY TRACT MALIGNANCIES IN PATIENT WITH END-STAGE RENAL DISEASE

K. Hirai, F. Sato, M. Imagawa, Y. Tasaki, N. Nasu, H. Mimata—Japan

**Background:** To assess the outcomes of laparoscopic radical surgery for renal and upper urinary tract malignancies in patients with end-stage renal disease (ESRD).

**Methods:** From February 1999 to December 2007, 347 laparoscopic radical renal surgeries including both laparoscopic radical nephrectomy (LRN) ( $n = 215$ ) and laparoscopic nephroureterectomy (LNU) ( $n = 132$ ) were performed at Oita university hospital and three cooperative centers. Of the 347 patients, 30 patients (8.6%) with ESRD, including 27 patients on maintenance hemodialysis before surgery, were identified. A retrospective chart analysis was performed, and the perioperative outcomes were compared between the patients with ESRD (ESRD group,  $n = 30$ ) and without ESRD (control group,  $n = 317$ ).

**Results:** In ESRD group, 23 patients (77%) underwent LRN for renal cell carcinoma, and 7 patients (23%) underwent LNU for

upper urinary tract urothelial carcinoma. Transperitoneal approach was used for 3 cases (10%), and retroperitoneal approach was used for 27 cases (90%) in ESRD group. In contrast, 192 patients (61%) underwent LRN, and 125 patients (39%) underwent LNU with transperitoneal ( $n = 128$ , 40%) or retroperitoneal ( $n = 189$ , 60%) approach in control group. Median operative time was 214 min in ESRD group and 255 min in control group. Median estimated blood loss was 68 ml and 110 ml in ESRD and control group, respectively. Perioperative major complication rate was 3.3% (1 patient) in ESRD group and 10.4% (33 cases) in control group.

**Conclusion:** Although retroperitoneal approach was extensively adopted in our series, LRN and LNU are safe and feasible surgical options for renal and upper urinary tract malignancies in patients with ESRD.

### MP14-17 LAPAROSCOPIC RESECTION OF LOCAL RECURRENCE FOLLOWING PRIOR RADICAL NEPHRECTOMY FOR CLINICALLY LOCALIZED RENAL CELL CARCINOMA: PERIOPERATIVE OUTCOMES AND INITIAL OBSERVATIONS

M. Allaf, J. Berkowitz

**Background:** Local recurrence is rare following radical nephrectomy for clinically localized renal cell carcinoma (RCC). Aggressive open surgical resection of isolated local recurrence has been shown to offer durable local control and potential improvement in cancer specific survival. The object of this study is to assess the outcomes of patients who underwent laparoscopic resection of isolated local recurrence following radical nephrectomy for RCC.

**Methods:** We retrospectively reviewed the perioperative and clinical outcomes of four patients who underwent laparoscopic resection of local recurrence following radical nephrectomy between 2007 and 2009 by a single surgeon. All procedures were performed via a four port transperitoneal laparoscopic approach.

**Results:** Two patients underwent resection of ipsilateral adrenal recurrence while the remaining two underwent resection of recurrence in retroperitoneal lymph nodes. Mean age of patients was 57 (44–66), all had primary tumors with clear cell histology, and ECOG performance status 0. The mean recurrence size was 4 cm (2–7 cm) and all surgical margins were negative. Two patients had received systemic therapy prior to surgical resection (IL-2 in 1 and Tamsirolimus in 1). Two patients had undergone open radical nephrectomy, and the other two had undergone a hand-assisted and a pure laparoscopic approach respectively. Mean OR time was 195 min (170–210) and mean EBL was 187 cc (100–250). No patient required a blood transfusion and mean length of stay was 2.5 days (2–3). With a mean follow-up of 12 months (2–26), 2 patients experienced recurrence. With further therapy (contralateral partial nephrectomy and cryoablation) all patients are alive and three of them have no evidence of disease.

**Conclusion:** Aggressive surgical resection of isolated local recurrence of renal cell carcinoma following radical nephrectomy with curative intent may be of benefit and has traditionally been performed using open surgery. In our limited experience, a laparoscopic approach may be utilized in select patients with low morbidity and excellent short term outcomes.

### MP14-18 CHANGES IN RENAL FUNCTION AFTER LAPAROSCOPIC PARTIAL NEPHRECTOMY WITH TEMPORARY RENAL ISCHEMIA

Y. Komai, G. Kawa, N. Takizawa, N. Oguchi, H. Kinoshita, T. Matsuda—Japan

**Background:** To examine the factors affecting postoperative renal function after a laparoscopic partial nephrectomy (LPN), we analyzed the changes in renal function using the estimated glomerular filtration rate (eGFR) during the perioperative period.

**Methods:** 65 patients with T1 renal tumors underwent LPN between 2002 and 2008, and the pre- and postoperative eGFRs were obtained from 58 patients. To analyse the changes in renal function, we used the eGFR, which was calculated by a formula specific for Japanese subjects. The preoperative eGFR was compared to the eGFR at one week, six months and one year after the operation. Variables including age, tumor diameter and renal ischemic time were tested for their independent effects on postoperative renal function.

**Results:** In most patients, the eGFR decreased significantly at one week after the operation, but gradually recovered. The loss of renal function was significantly less in those patients with a renal ischemic time less than 30 minutes as compared to other patients (95.5% v.s. 87.8%,  $p=0.02$ , Mann-Whitney U test), although there was no significant difference between the two groups at six months and one year after the operation. No other statistically significant factors affecting postoperative the eGFR were detected.

**Conclusion:** The renal function of patients underwent a LPN with temporary renal ischemia will recover subsequently, although it decreases transiently during the early postoperative period. The renal ischemic time may have an effect on the degree of transient renal dysfunction. In term of the preservation of renal function, a LPN should be recommended for patients with T1 renal tumors.

#### MP14-19 LAPAROSCOPIC RADICAL NEPHROURETERECTOMY: RESULTS OF A MULTICENTRIC ITALIAN STUDY

F. Porpiglia, A. Celia, L. Luciani, C. Terrone, G. Guazzoni, P. Parma

**Background:** The aim of this study is to evaluate the results of laparoscopic nephroureterectomy (LNU) with open ureterectomy (OU) for upper urinary tract transitional cell carcinoma (UUT-TCC) and the role of lymphadenectomy (LND) in this kind of surgery.

**Methods:** From 1/2000 to 5/2009, 92 patients underwent LNU with OU in 5 institutions in Italy. When performed, the lymphadenectomy has been laparoscopic for tumours of calyx/pelvis/lumbar ureter, while it has been open for pelvic ureter. Follow up visits were scheduled every 6 months.

**Results:** We used transperitoneal approach in 71 patients and retroperitoneal in 21. Mean lesion number was 1,13 with a mean size of 5,9 cm. We recorded 29 complications (31,5%), of which 14 intraoperative bleedings and 15 postoperative. The conversion and transfusion rate were respectively 3,3% and 7,6%. We performed

LND in 58,7% of patients, with a mean number of 7,8 lymph-nodes removed. No positive margin was recorded. Mean follow-up was 20,95 (2–77) months. 10 patients died: 8 for systemic disease progression, one for acute myocardial infarction and one for pulmonary cancer. We recorded 15 cases of subsequent bladder tumour, 9 cases of metastasis and 2 cases of contralateral UUT-TCC. Stratifying patients by LND, no differences in survival time were recorded.

**Conclusion:** The results of our study suggests that LNU with OU is a feasible and safe surgical approach. Oncologic results seem to be comparable with traditional open approach even if a longer follow up is needed.

#### MP14-20 COMPARISON OF EFFECTS OF OPEN AND LAPAROSCOPIC PARTIAL NEPHRECTOMY ON RENAL FUNCTION

Y. Funahashi, R. Hatorri, T. Yamamoto, O. Kamihira, M. Gotoh

**Background:** In recent years, partial nephrectomy has been performed by not only open surgery but laparoscopic surgery. However, there is limited evidence for the relationship between renal ischemia time and residual renal function.

**Methods:** Forty-seven patients with elective indications underwent partial nephrectomy for renal masses. Open and laparoscopic surgeries were performed in 25 and 22 patients, respectively. The mean tumor diameter was 26 mm and 29 mm. The warm ischemic time was 26 min for both surgeries. We assessed effective renal plasma flow (ERPF) by  $^{99m}\text{Tc}$ -mercaptoacetyl triglycine (MAG3) renal scintigraphy. In addition, we analyzed MAG3 uptake regionally in the surgically non-affected parts. MAG3 renal scintigraphy was performed preoperatively and 1 week postoperatively.

**Results:** The mean serum creatinine level was 0.87 mg/dl preoperatively and 0.99 mg/dl one week postoperatively in the open group, and it was 0.92 mg/dl preoperatively and 0.99 mg/dl postoperatively in the laparoscopic group. ERPF of the operated kidney decreased by 34% (from 176 to 115 ml/min/1.73 m<sup>2</sup>) in the open group and by 17% (from 144 to 119 ml/min/1.73 m<sup>2</sup>) in the laparoscopic group ( $p=0.004$ ). Regional MAG3 uptake of the operated side decreased to 81% in the open group and to 92% in the laparoscopic group. Although these decreases are correlated with the renal ischemia time in both groups, the decrease was greater in the open group.

**Conclusion:** The loss of renal function during partial nephrectomy was comparatively less after laparoscopic surgery. This may indicate the protective effect of pneumoperitoneum pressure against renal ischemic damage.

## MP15: ROBOTIC PROSTATE 2

**MP15-01 USE OF A FLEXIBLE CO<sub>2</sub> LASER FIBER FOR PRECISE DISSECTION OF NEUROVASCULAR BUNDLE DURING ROBOTIC ASSISTED LAPAROSCOPIC PROSTATECTOMY**  
M. Rothberg, C. Ritch, P. Cheetham, J. Landman, K. Badani—USA

**Background:** Excess thermal spread during dissection of the neurovascular bundle (NVB) can affect potency in patients following radical prostatectomy. Carbon dioxide (CO<sub>2</sub>) lasers have been cited to deliver energy with minimal thermal spread to tissues during dissection; however, previous surgical uses of CO<sub>2</sub> lasers have been limited by the necessity for their delivery through a rigid fiber and 2D projection upon tissue. We report on a novel delivery of CO<sub>2</sub> laser energy through a flexible fiber to enhance the accuracy of dissection of the NVB during robotic assisted laparoscopic prostatectomy (RALP).

**Methods:** A feasibility study of the CO<sub>2</sub> laser was performed on a patient with clinical stage T1c, Gleason 6(3+3) prostate cancer during RALP. Upon identification of the NVB, a robotic needle driver was used to manipulate the flexible laser fiber introduced through an assistant port. Bilateral lateral fascial nerve sparing was performed in an antegrade fashion.

**Results:** Total operative time was 3 hours. During the nerve sparing portion of the procedure, the flexible CO<sub>2</sub> laser fiber displayed minimal thermal spread, allowing for meticulous dissection of the NVB and fascial layer identification; the fiber was easily manipulated by the robotic instruments. While the laser did provide extremely accurate dissection, it was unable to serve as an adequate means of coagulation in larger vessels. Patient recovered on pathway and was discharged on POD#1.

**Conclusion:** The flexible CO<sub>2</sub> laser fiber was easily manipulated and identification of fascial layers during nerve sparing was facilitated with the fiber. Long-term follow-up is necessary to determine the efficacy of this technology versus conventional techniques on the NVB. Larger studies are currently in progress.

**MP15-02 EFFECT OF BONY PELVIC DIMENSIONS MEASURED VIA PREOPERATIVE MAGNETIC RESONANCE IMAGING ON PERFORMING ROBOT-ASSISTED LAPAROSCOPIC PROSTATECTOMY**

S. Hong, S. Jeong, S. Byun, H. Park, S. Doo, S. Lee—Korea

**Background:** We evaluated the effect of bony pelvic dimensions measured via preoperative magnetic resonance imaging (MRI) on performing robot-assisted laparoscopic prostatectomy (RALP).

**Methods:** In this exploratory study, we analyzed the data of 141 patients who received RALP for clinically localized prostate cancer after undergoing MRI at our institution. Associations of various clinicopathologic factors, including pelvic dimension parameters measured via preoperative MRI, with operative time, estimated blood loss (EBL), surgical margin status, and postoperative status regarding continence and erectile function were analyzed.

**Results:** With regards to operative time, no pelvic dimension parameter was observed to have significant association on univariate analyses, with only newly-developed variable of pelvic cavity index (PCI) approaching significance ( $p=0.071$ ). Only prostate volume was observed to have a significant association with oper-

ative time on multivariate analysis ( $p=0.015$ ). As for EBL, no bony pelvic dimension-related parameter demonstrated significant association on univariate analyses, with only intertuberous distance (ITD) and interspinous distance (ISD) approaching significance ( $p=0.087$  and  $p=0.072$ , respectively). Only prostate volume was shown to be significantly associated with EBL on univariate analyses ( $p=0.045$ ). No pelvic dimension-related parameter was observed to have any significant effect on surgical margin status and recovery of continence or erectile function at 6 months after RALP.

**Conclusion:** Bony pelvic dimensions may not be a significant factor with regards to the technical difficulty of RALP among Korean patients compared with other patient-related factors such as prostate volume.

**MP15-03 ANTERIOR VERSUS POSTERIOR APPROACH TO SEMINAL VESICLE DISSECTION DURING ROBOTIC ASSISTED LAPAROSCOPIC PROSTATECTOMY**

E. Coronato, J. Singh, P. Ginsberg, J. Jaffe, J. Harmon

**Background:** The original Montsouris technique for laparoscopic radical prostatectomy (LRP) described a posterior dissection allowing an early approach to the seminal vesicles. Later, a modification of this technique was developed (Montsouris II) permitting access to these structures in an antegrade fashion following division of the posterior bladder neck. We compare our experience with both anterior and posterior approaches to RALP, and evaluate both perioperative and postoperative factors for each technique.

**Methods:** A retrospective analysis was obtained on a consecutive series of 105 patients undergoing RALP, performed by 2 surgeons (JJ and JH), at a single institution. Patients were divided into 2 groups: anterior approach (AA) and posterior approach (PA). Patient demographics, operative parameters, pathological characteristics and complications were compared between groups. Statistical analyses were performed using the student-t test and Levene's test. Functional outcomes such as impotence and incontinence were not evaluated in this study.

**Results:** Preoperative factors among the AA and AP groups were similar with mean age of 60 years [range 40–74], mean PSA of 6.3 ng/mL [range 0.5–22.3], and similar clinical stage. The pathologic staging, Gleason scores, and margin status were not significantly different ( $p>0.05$ ) in both groups, either. The factors that proved to be of statistical significance included a lower console time for PA of 162.1 minutes versus 193.8 minutes in AA group ( $p=0.01$ ) and a lower transfusion rate ( $p<0.0001$ ) in the PA group. There was one rectal injury in both groups repaired robotically. Hospital stay and length of foley catheter duration were similar in both groups, a reflection of the surgeons' practice. **Conclusion:** With preoperative factors being similar, the posterior approach to a RALP is associated with lower console time and a lower transfusion rate. Perhaps this approach may facilitate in shortening the learning curve for RALP.

**MP15-04 PERCEPTIONS OF ROBOTIC SURGERY AMONGST PATIENTS TREATED WITH ROBOT ASSISTED RADICAL PROSTATECTOMY**

M. Lerner, R. Bowens, S. Lucas, M. Koch, C. Sundaram

**Background:** Robot assisted radical prostatectomy (RARP) is a common treatment modality for the management of prostate cancer. We are interested in understanding how patient perceptions of RARP influence their decision to undergo the procedure.

**Methods:** An IRB approved questionnaire was sent to 420 patients who underwent RARP since 2006. Patients answered 16 questions about their experience and perceptions of RARP.

**Results:** 215 patients responded to the questionnaire. 57% of patients first heard about RARP from their urologist, 18% from friends or family, and 10% from the internet. The urologist was the most important source of information for patients. 71% of patient expected to have a RARP when they first visited the urologist. If their current urologist only performed an open or traditional laparoscopic prostatectomy, 88% of patients stated they would go to another urologist who performed RARP. When asked how their approval of RARP changed after surgery, 70% had increased approval. If given the choice to do over, 88% of patients would choose the surgery again. 94% of patients would recommend RARP if other patients sought their advice.

**Conclusion:** The urologist is the most important source of information for patients. Patients' perceptions of RARP influence their decision to undergo the surgery and influence where they seek treatment. A high percentage of patients would have made the same choice for the management of their prostate cancer if given the chance to do over.

### MP15-05 DOES PREOPERATIVE 3.0 TESLA MRI CONTRIBUTE IN TREATMENT OF HIGH-RISK PROSTATE CANCER?

U. Boylu, O. Sartor, B. Lee, R. Thomas—USA

**Background:** Patients with high tumor volume, high PSA levels, high Gleason scores, and significant palpable disease are considered to be in a high-risk category. Healthy patients with no other co-morbidities can be candidates for appropriate surgical excision in the setting of clinically organ-confined disease. Our purpose was to determine whether 3.0 Tesla MRI (3T-MRI) might allow better assessment of local extraprostatic extension (EPE) or seminal vesicle involvement (SVI).

**Methods:** Twenty-nine patients with high-risk prostate cancer underwent 3T-MRI of the prostate and pelvis. Seven patients were excluded due to EPE and/or SVI on MRI. Twenty-two patients with no sign of EPE and/or SVI on 3T-MRI underwent robotic assisted radical prostatectomy (RARP). Surgical and oncologic outcomes were compared to the high-risk prostate cancer patients (n = 35) who underwent RARP without prior 3T-MRI.

**Results:** One RARP case in 3T-MRI group was aborted due to locally advanced disease. SVI was present in 38% of 3T-MRI group and 31.4% of control group (p = 0.61). (Table 1) EPE was present in 67% in 3T-MRI group and 68% in control group (p = 0.88). Lymph node involvement was found in 4 patients in 3T-MRI group and 2 patients in control group (p = 0.18). Surgical margins were positive in 33% of the 3T-MRI group and 37% of the control group (p = 0.77). 3T-MRI Control P SVI 8 (38%) 11 (31.4%) 0.61 EPE 14 (67%) 24 (68%) 0.88 LN involvement 4 (19%) 2 (6%) 0.18 Positive Margins 7 (33%) 13 (37%) 0.77 Table 1 Comparison of 3T-MRI and control groups

**Conclusion:** In treatment of high-risk prostate cancer patients, 3T-MRI does not improve assessment of EPE, SVI, and lymph node involvement.

### MP15-06 PRE-OPERATIVE URINARY FUNCTION INFLUENCES PATIENT REPORTED SATISFACTION AND REGRET FOLLOWING ROBOTIC RADICAL PROSTATECTOMY

D. Lee, M. Truesdale, K. Badani, P. Cheetham—USA

**Background:** Health-related quality of life can influence satisfaction and regret men experience following prostate cancer treatment. Previous studies suggest robotic prostatectomy (RALP) is associated with regret and dissatisfaction after treatment due to unrealistic expectations. We sought to evaluate factors that affect postoperative satisfaction and regret.

**Methods:** 78 consecutive men with localized prostate cancer underwent RALP by a single surgeon at an academic institution. Men completed preop Sexual Health Inventory for Men (SHIM) & International Prostate Symptom Score (IPSS) questionnaires. 52 men were interviewed with 4 weeks minimum follow-up by an independent non-clinical researcher. Continence was defined as soaking 0 pads/24 hours. Satisfaction and regret were measured using five-level Likert item scales.

**Results:** Of 52 men evaluated, 50 (96.2%) were satisfied with their treatment choice and 46 (88.5%) did not regret their decision to undergo RALP. When comparing satisfied and unsatisfied men, there was no significant difference in postop potency and urinary control. Median pre-operative IPSS score was 16 for men who regretted their decision and 7 for those with no regret (p = 0.04). Only IPSS overall score (OR = 1.13, p = 0.044) and IPSS Quality of Life (QoL) score (OR = 2.06, p = 0.023) were significant predictors of regret on a univariate logistic regression model.

**Conclusion:** The overwhelming majority of men expressed satisfaction and did not regret their decision to undergo RALP after adequate pre-operative counseling. Men with higher pre-op IPSS scores were more likely to regret their decision to undergo RALP than those with lower scores. Further assessment of satisfaction and regret will require continued analysis and long-term follow up.

### MP15-07 SIGNIFICANCE OF PROSTATE SIZE ON PATHOLOGICAL OUTCOMES IN PATIENTS UNDERGOING ROBOTIC ASSISTED LAPAROSCOPIC PROSTATECTOMY

A. Akhavan, J. Carlucci, F. Nabizada-pace, P. Muntner, D. Samadi—USA

**Background:** We examined the effect of prostate weight on the incidence of pathological outcomes in robotic-assisted laparoscopic prostatectomy (RALP).

**Methods:** Pre-, peri- and post-operative data were available from 716 consecutive patients undergoing RALP at a single institution. Prostate size, stratified into < 50 g, 50–80 g, and > 80 g, was compared with clinical and pathological variables in both univariate and multivariable-adjusted analyses.

**Results:** Prostate size was directly associated with increased BMI, operative time, blood loss, age, preoperative PSA, more benign Gleason histology, and lower pathological staging (p < 0.05). Length of hospital stay was not influenced by prostate size. The incidence of positive extensive surgical margins was 14.8%, 9.7%, and 5.3% in small, medium, and large prostates, respectively (p < 0.001); however, this association was no longer statistically significant after controlling for either all other variables, or just pathological stage alone. After multivariable adjustment, only Gleason score and pathological stage were significantly associated with the incidence of positive margins (p < 0.05); prostate weight was not significantly associated.

**Conclusion:** Patients with larger prostates have favorable pathological outcomes following RALP; however, when controlling for pathological stage, prostate size is not associated with margin positivity.

#### **MP15-08 COMPARISON OF FUNCTIONAL OUTCOMES BETWEEN ROBOT-ASSISTED RADICAL PROSTATECTOMY AND RADICAL RETROPUBIC PROSTATECTOMY: A SINGLE SURGEON EXPERIENCE**

T. Kang, J. Park, C. Song, J. Hong, H. Park, H. Ahn

**Background:** To evaluate the surgical and functional outcomes of robotic-assisted radical prostatectomy (RARP) compared with radical retropubic prostatectomy (RRP).

**Methods:** A prospective nonrandomized study was performed in patients undergoing RARP and RRP from August 2007 and October 2008. We compared preoperative variables, pathologic stage and functional outcomes in patients underwent RARP (n = 144) and RRP (n = 89) performed by single surgeon who had experienced prior 700 RRP surgeries. Continence was defined as no pad wearing and the patients with Erection Hardness Score 3 (EHS 3, hard enough for penetration but not completely hard) or EHS 4 (completely hard and fully rigid) were defined as potent.

**Results:** There was no significant difference in mean age (RARP vs. RRP: 64.9 vs. 66.5 years;  $p=0.06$ ). While prostate specific antigen was different between the groups (RARP vs. RRP: 10.5 vs. 15.8 ng/ml;  $p=0.042$ ), there was no significant difference in pathologic stage. There was no significant difference in postoperative complication rate between two groups. Continence rates at the time of postoperative 3, 6, and 12 months were 20.7%, 41.6%, and 81.5% for RARP and 19.3%, 37.5%, and 72.1% for RRP, respectively ( $p=0.247$ ). Potency rates in RARP group were 4.2%, 13.8%, and 62.2% at postoperative 3, 6, and 12 months while 0.0%, 2.2%, and 20.6% for RRP group ( $P<0.001$ ) among the patients who were potent preoperatively and received a nerve sparing procedure.

**Conclusion:** Functional outcomes of RARP seem to be comparable to RRP and superior especially in recovery of potency.

#### **MP15-09 PATTERN OF COMPLICATIONS AFTER ROBOT-ASSISTED LAPAROSCOPIC RADICAL PROSTATECTOMY: AN ANALYSIS BASED ON THE CLAVIEN CLASSIFICATION SYSTEM**

J. Jeong, E. Choi, T. Mueller, M. Ercolani, I. Kim—USA

**Background:** To demonstrate the safety and feasibility of robot-assisted laparoscopic radical prostatectomy (RALRP), we analyzed perioperative parameters and the pattern of complications in our patients.

**Methods:** To date, more than 500 RALRPs have been performed at our institution. In this report, we reviewed the medical records of first 200 patients retrospectively. Patients were divided into 4 groups of 50 patients each and compared inter-group differences in terms of preoperative characteristics and perioperative parameters. All patients were included in the analysis of perioperative complication pattern, and complications were classified according to the Clavien classification system.

**Results:** The mean operative time was 222.5 minutes and the mean blood loss was 208.8 ml. The mean length of hospital stay was 1.13 days. Overall, 12% (24 men) experienced perioperative complications. Of the 24 patients, 5 men (20.8%) experienced intraoperative complications and 19 men (79.2%) had postoperative

complications. Rectal injury occurred in 2 men (1%) and was repaired primarily using 2-layer suture technique without any sequelae. Among the 200 patients, no transfusion was needed intraoperatively and postoperatively. There were 9 patients (4.5%) in the Clavien grade I complications and another 9 men (4.5%) were classified as grade II complications. Six men (3.0%) had grade IIIb complications and there was no grade IV or V complications.

**Conclusion:** In our initial series of 200 RALRP procedures, we experienced low morbidity with overall 12% of complication rate. After applying minor modifications, most of the early minor complications were prevented. Rectal injuries, if recognized intraoperatively, can be repaired primarily.

#### **MP15-10 THE EFFECT OF OBESITY ON INTRA-OPERATIVE OUTCOMES DURING ROBOT-ASSISTED RADICAL PROSTATECTOMY (RARP)**

S. Sharma, J. Stern, B. Meredith, M. Nguyen, D. Eun, D. Lee

**Background:** Obesity has an overall impact on perioperative and intraoperative outcomes. Herein we have reported our experience in impact of obesity on intra-operative factors and pathological outcomes in patient undergoing RARP.

**Methods:** A retrospective review of RARP database was performed. Patient were stratified into obese ( $BMI \geq 30 \text{ kg/m}^2$ ) and non obese ( $BMI < 30 \text{ kg/m}^2$ ) groups. Demographic data, operative time, intra-operative blood loss, pathological grade, margins were compared.

**Results:** A total of 580 consecutive patients were included in this study (n = 162 obese group, n = 418 non-obese group). There were zero conversions from RARP to open. Average age was 59.1 vs. 60.1 years and average BMI was 33.75 vs. 25.63  $\text{kg/m}^2$  in obese vs. non-obese group. There was a small but significant difference between the operative time in minutes, being higher in obese vs. non-obese groups [137.54 vs. 131.16 ( $p \leq 0.005$ )]. EBL in ml was more in the obese group vs. non obese group [137.74 vs. 114.95 ( $p \leq 0.004$ )]. Average preoperative PSA was 5.7 vs. 5.6 ng/ml ( $p \leq 0.85$ ). Pathological staging distribution was T2c in 65.8% vs. 63.2% and T3a 16.7% vs. 21.5% respectively. Average Gleason score was 6.8 vs. 6.7 ( $p=0.4$ ). Positive margin rates were 23.75% vs. 19.68% respectively. On Chi-square test, there was a significant association between obesity and positive margins ( $p \leq 0.01$ )

**Conclusion:** In our series, operative time and overall blood loss were significantly affected by the presence of obesity but the magnitude of the change was relatively small. Obesity has a significant association with positive margins in our series. Overall, RARP is an effective and efficient means of prostate cancer treatment in the obese population although care must be taken to avoid positive margins in these patients.

#### **MP15-11 SURGEON PERCEPTION IS NOT A GOOD PREDICTOR OF PERIOPERATIVE OUTCOMES IN ROBOT-ASSISTED RADICAL PROSTATECTOMY (RARP)**

S. Sharma, J. Stern, B. Meredith, M. Nguyen, C. Schwab, D. Lee

**Background:** Surgeons have always used their cognitive intuitive skills for execution of skilled tasks and real time perception of the intra-operative outcomes. Here, we attempted to measure the overall impact of surgeon's intraoperative perception in terms of the functional outcome of early continence in RARP.

**Methods:** A single experienced surgeon (DL) used a scoring sheet to prospectively capture in real time his subjective opinion of how well a particular portion of the RARP procedure was completed. Surgeon perception was graded as bad, average or good. We measured the early continence outcomes in 39 consecutive patients. Factors thought to affect post operative continence such as quality of bladder neck preservation, nerve sparing, urethral length, anastomosis, striated sphincter thickness, Rocco repair, and Walsh intussusception (total 7 variables) were graded.

**Results:** Total of 273 (39 patients \*7 variables) responses recorded: 58.6% were “good”, 32.2% were “average” and 8.4% were “bad”. Log-rank test for all variable perceptions showed no significant differences in reaching 0 PPD or 1 PPD ( $p > 0.05$ ) both at 1 month and 3 month time points. There were contrasting results with some perception variables. In some variable outcomes, patients with “bad” perceived results were doing well as compared to patients with “good” perceived results, with median time to reach social continence 7 weeks vs. 10 weeks respectively.

**Conclusion:** In our study, surgeon perception is not a good predictive indicator of intra-operative performance and subsequent functional outcome in terms of continence. Inter-surgeon variability of perception may vary and needs investigation

### **MP15-12 STAGING IMPLICATIONS OF ANTERIOR PROSTATIC FAT PAD EXCISION DURING ROBOT-ASSISTED LAPAROSCOPIC RADICAL PROSTATECTOMY**

J. Jeong, S. Lamba, M. Ercolani, I. Kim—USA

**Background:** Lymph node status has significant implications for management following radical prostatectomy. Presently, pelvic lymph node dissection is the recommended procedure for staging, but additional lymph node sites may be of clinical significance. We performed anterior prostatic fat (APF) pad excision during robot-assisted laparoscopic radical prostatectomy (RALRP) in an effort to seek the staging implications of the excision.

**Methods:** After performing each APF pad dissection during RALRP, we collected the specimen and submitted en bloc to the pathology department where it was evaluated for the presence of lymphoid tissue and metastatic prostate cancer.

**Results:** In a total of 129 consecutive patients, we performed APF pad excisions between July 2007 and June 2008. Of these patients, 16 (12.4%) were found to have 1 or more APF pad lymph nodes with 3 patients found to have nodes positive for metastatic disease. Of note, all 3 had high-risk preoperative features with biopsy Gleason scores greater than 7 and/or PSA scores greater than 20 ng/ml. In 1 of these 3 patients, the cancer was upstaged secondary to detection of positive APF pad lymph nodes with negative pelvic lymph nodes. At 1.5 year follow-up, PSA level of this patient remains undetectable.

**Conclusion:** In this study, we demonstrated that the APF pad contained lymph nodes in over 12% of the time and the dissection of the APF pad enhanced more accurate pathologic staging.

### **MP15-13 INITIATING A ROBOTIC UROLOGY PROGRAM WITH OPTIMAL ONCOLOGIC EFFICACY; IMPACT OF MENTORSHIP ON POSITIVE SURGICAL MARGINS IN ROBOTIC RADICAL PROSTATECTOMY**

A. Kural, F. Atug, I. Tufek, H. Akpınar, V. Patel, A. Mottrie

**Background:** Oncologic efficacy is the primary concern in any patient with urologic cancer. Oncologic status of patients may be compromised during the initiation of a robotics program. There-

fore, the implementation of a robotic urology program requires a careful, ethical and staged approach. We initiated our program with significant mentorship in order to minimize complications and optimize oncologic efficacy during the learning curve. We present our initial histopathological data and surgical margin positivity (SMP) rates during the initiation of our robotic program.

**Methods:** Between March 2005 and June 2009, 200 patients underwent robot assisted radical prostatectomy at our institution. Our program started under the guidance of two mentors; V.P. and A.M. Prior to starting the robotic program, our team spent significant time reviewing surgical video from our mentors. The mentors then supervised on-site the initial 20 cases and then returned periodically throughout our learning experience to further refine our skills. After the initial 20 cases, records of 180 were retrospectively reviewed. Patients were divided into 3 groups based on the time of surgery; each group including 60 patients. We compared the incidence of SMP among the groups. Moreover, we examined the factors that might affect the SMP rate. Patients were also stratified for high and low risk profiles for having SMP.

**Results:** Overall SMP rate was 7.7%. Factors that could affect the surgical margin status, such as PSA level, Gleason pattern and final pathological stage were evenly distributed among the groups ( $p > 0.05$ ). The SMP rates were 13.3%, 3.3% 6.6% for groups I, II and III, respectively. The difference was statistically significant ( $P < 0.05$ ). The SMP rate for pT2 disease was 3.9%, 2.2%, 2% for groups I, II and III, respectively.

**Conclusion:** We present our SMP rates during the initiation of a robotics program. A very low SMP rate for pT2 disease even early in our experience clearly demonstrates the effect of mentorship training.

### **MP15-14 TANDEM-ROBOT ASSISTED LAPAROSCOPIC RADICAL PROSTATECTOMY (T-RALP) TO IMPROVE THE NEUROVASCULAR BUNDLE VISUALIZATION: A FEASIBILITY STUDY**

M. Han, B. Trock, D. Petrisor, C. Kim, D. Stoianovici

**Background:** Robot-assisted laparoscopic radical prostatectomy (RALP) using daVinci<sup>®</sup> surgical robot system is a commonly performed surgery for the treatment of clinically localized prostate cancer. The preservation of the neurovascular bundle (NVB) including cavernous nerves during the surgery improves the post-operative recovery of sexual potency. However, NVB visualization can be challenging due to the periprostatic connective tissue and intraoperative hemorrhage. The accompanying blood vessels in the NVB, which are visible with Doppler ultrasound, can serve as a macroscopic landmark to localize the microscopic cavernous nerves in the NVB. In this feasibility study, a novel, robotic-transrectal ultrasound probe manipulator (TRUS Robot) and three-dimensional (3-D) reconstruction/navigation software were used concurrently with the daVinci<sup>®</sup> robot in a tandem robot approach (T-RALP) to enable the intraoperative use of TRUS for image-guidance navigation.

**Methods:** After the Institutional Review Board (IRB) and the Food and Drug Administration (FDA) approval, we performed T-RALP on three subjects with prostate cancer. TRUS Robot was developed to provide a steady holding of the TRUS probe and to allow remote manipulation using a joystick located next to the daVinci<sup>®</sup> console where the surgeon sits during RALP. We also developed 3-D reconstruction program of the ultrasound images.

**Results:** After informed consent was obtained, all three subjects underwent T-RALP without associated complications. During T-RALP, the surgical instruments were clearly visible in the TRUS images, and that the prostate could be scanned with the TRUS Robot to reconstruct the 3D shape of the gland. With the TRUS Robot, the surgeon was able to directly and remotely control the TRUS probe and utilize the ultrasound images at critical points of the operation. The most important advantage of the TRUS Robot was that it can track the accurate position of the TRUS probe, allowing 3-D reconstruction of the images. Image navigation was then performed by observing the tips of the daVinci® instruments in the live TRUS image (hyperechoic marks). NVBs were clearly visualized using Doppler ultrasound in the 3-D reconstruction.

**Conclusion:** In this feasibility study, TRUS-guided intraoperative 3-D image-guided navigation system using a robotic ultrasound probe manipulator has been developed. The use of TRUS imaging during radical prostatectomy can potentially improve the visualization of the NVB and subsequently improve postoperative recovery of potency in men. In addition, the 3-D reconstruction images of the prostate gland can provide clear and accurate guidance of surgical landmarks to the surgeon.

### MP15-15 EXTREMELY LARGE PROSTATE SIZE MATTERS FOR FUNCTIONAL OUTCOMES FOLLOWING ROBOTIC ASSISTED RADICAL PROSTATECTOMY

B. Hollenbeck, R. Hedgepeth, S. Zhang, T. Skolarus—USA

**Background:** For radical prostatectomy, the advantages of robotic surgery may facilitate more precise dissection and improve functional outcomes. While this is evident in most cases, patients with extremely large prostates, i.e., over 100 grams, may pose increased challenges due to limited working space. For this reason, we undertook a study to understand the relationship between extremely large prostate size and functional outcomes after robot-assisted prostatectomy.

**Methods:** Patients undergoing robotic-assisted radical prostatectomy from 2003 to 2009 at our institution were included in the study. Prostate volume was categorized into three groups: <50 grams, 50–100 grams and >100 grams. The primary outcome was return of function 3 months after surgery measured using EPIC. Intraoperative and pathologic variables were also measured and compared among the groups.

**Results:** A total of 885 patients underwent robotic assisted prostatectomy (<50 gm n = 582, 50–100 gm n = 279, > 100 gm n = 24). Increasing prostate weight was associated with increased age, operative time and blood loss, while positive surgical margins and pathologic Gleason score decreased. No surgical margins were positive in prostates > 100 gm and there were no differences in nerve-sparing among the groups. After adjustment, postoperative irritative symptoms and sexual function were similar, however recovery of urinary continence worsened with increasing prostate size. Prostate size category (gm) <50 50–100 > 100 p-value Prostate size (gm, mean) 38.9 62.0 119.6 p < 0.001 Age at surgery (years, mean) 59.4 62.0 67.4 p < 0.001 Estimated blood loss (mL, mean) 155 169 250 p = 0.01 OR time (minutes, mean) 232 248 250 p = < 0.01 Neurovascular bundle sparing (%) p = 0.17 Bilateral 64.2 61.7 54.2 Unilateral/partial 22.9 22.9 25.0 None 12.9 15.4 20.8 Pathologic Gleason score (%) p < 0.01 ≤ 6 22.0 36.2 47.6 7 74.0 58.6 38.1 8–10 4.0 5.2 14.3 Surgical margin (%) p < 0.01 Negative 81.0 88.9 100 Positive - focal 15.0 9.3 0 Positive - extensive 4.0 1.8 0 Baseline EPIC urinary-irritative subscale (mean)

89.6 83.8 74.6 p < 0.001 Baseline EPIC urinary-incontinence subscale (mean) 95.4 90.7 87.5 p < 0.001 Baseline EPIC sexual subscale (mean) 76.6 69.3 45.8 p < 0.001 3 month EPIC urinary-irritative subscale (mean)\* 88.8 87.9 88.8 p = 0.88 3 month EPIC urinary-incontinence subscale (mean)\* 62.0 49.3 44.0 p = 0.03 3 month EPIC sexual subscale (mean)\*\* 35.3 29.1 10.5 p = 0.90 Adjusted for baseline, age at surgery \*\*and nerve-sparing. **Conclusion:** Extremely large prostate size increases the complexity of robotic assisted radical prostatectomy leading to longer operative times and increased blood loss. Oncologic parameters are improved in patients with larger glands, however it appears to hamper early return of continence.

### MP15-16 HYPOTHERMIC NERVE SPARING ROBOTIC RADICAL PROSTATECTOMY: IMPACT ON EARLY CONTINENCE FOR MEN AGED 70 OR GREATER

T. Ahlering, D. Finley, K. Osann, A. Chang, R. Santos, D. Skarecky—USA

**Background:** Radical prostatectomy (RP) associated urinary leakage is thought to be primarily related to intrinsic sphincteric deficiency and to a lesser extent bladder dysfunction. A contributing factor to transient incontinence may be acute inflammation of the sphincteric complex and bladder secondary to the trauma of surgical excision of the prostate. We hypothesized that pre-emptive loco-regional hypothermia to the pelvis would attenuate this inflammation and previously implemented novel methods in RP resulting in earlier return to continence. Herein we examine our early continence results for men aged ≥70 years, who are considered at greater risk for incontinence.

**Methods:** 104 men undergoing robotic laparoscopic RP (RLP) were grouped into either hypothermic RP (HRLP) n = 16, or undergoing standard non-cooled RLP, n = 88. Pelvic cooling was achieved utilizing cold irrigation and an endo-rectal cooling balloon (ECB) cycled with 4°C saline. Continence was defined as zero urinary pad usage. Time to pad-free urinary continence was determined by postcards returned with the date of achieving pad-free status or validated self assessment questionnaires. Statistical analysis was performed using Mann-Whitney and Kaplan-Meier analysis of time to zero pads (SAS software).

**Results:** Preoperative means for the HRLP versus RLP groups respectively, were as follows: Age (72.4 vs 73.1, p = .31), PSA (6.7 vs 8.2, p = .44), AUA (11.0 vs 9.6, p = .41), Bother (1.8 vs 1.9, p = .100), BMI (26.8 vs 26.6, p = .51), EBL (87.5 vs 89, p = .52). Pad free rates at 1 and 3 months were for HRLP 37%, 73% compared to RLP, 14%, 53%, (p values = .03, .13) respectively. Kaplan Meier curves for all times gave significant results for generalized Wilcoxon p = .021, and trend for Long Rank p = .063.

**Conclusion:** This study represents the initial application of local hypothermia to reduce traumatic inflammatory sequela of RLP for men aged ≥70 years. Hypothermia is an easily induced, safe method for significantly improving early post-operative return of pad-free urinary function in men with higher risk of incontinence.

### MP15-17 IMMEDIATE SURGICAL OUTCOMES OF ROBOT-ASSISTED LAPAROSCOPIC RADICAL CYSTECTOMY: COMPARATIVE ANALYSIS WITH THE OPEN PROCEDURE

T. Kim, T. Kwon, E. Yoo, Y. Park, H. Kim, J. Kim—Korea

**Background:** We analyzed initial clinical experience of the robot assisted laparoscopic radical cystectomy with an extracorporeal



ileal conduit and compared these findings with those of the conventional open procedure.

**Methods:** Between January 2007 and June 2009, we performed robot assisted laparoscopic radical cystectomy (RLRC) with an extracorporeal ileal conduit for 7 patients with invasive bladder cancer and these immediate surgical outcomes of RLRC were compared with those of open radical cystectomy (ORC) in 10 cases. The surgical results including the operative time, estimated blood loss (EBL), transfusion rate, recovery time, hospital stay, complications and pathological results were reviewed retrospectively.

**Results:** There were no significant differences of demographic data between the two groups. The pathologic reports showed a urothelial cell carcinoma in all cases. The table shows the immediate surgical outcomes of RLRC and ORC group. Table 1. Immediate surgical outcomes after RLRC and ORC RLRC (n = 7) ORC (n = 10) p value Cystectomy time (min) 223279 0.093 Urinary diversion time(min) 126127 0.220 EBL (ml) 241.7440 0.019 Transfusion rate (%) 3 (42.8) 3 (30) 0.139 Time to oral intake (days) 5.162 0.166 Time to ambulation (days) 3.247 0.198 Hospital stay (days) 15.520.8 0.112 Complication (%) 0 (0) 2 (20) 0.257 Urinary tract infection 01 Delayed bleeding 01

**Conclusion:** Our initial clinical experience indicates that RLRC is a safe and feasible procedure with minimal blood loss, and may be an alternative to the open technique. Long term follow-up with larger patient population is needed to determine long term oncological outcomes.

### MP15-18 ROBOTIC-ASSISTED LAPAROSCOPIC RADICAL PROSTATECTOMY IN THE MORBIDLY OBESE PATIENT: IS THERE A SIZE LIMIT?

J. Yates, M. Gross, D. Golombos, I. Sawczuk, R. Munver—United States

**Background:** Obesity and prostate cancer are among the more common health issues affecting men in the United States. Current studies are examining the relationship between obesity and prostate cancer. We report on our experience of robotic-assisted laparoscopic radical prostatectomy (RALP) in the morbidly obese individual in terms of intraoperative and postoperative outcomes.

**Methods:** A retrospective review of morbidly obese (BMI  $\geq$  40 kg/m<sup>2</sup>) patients that underwent RALP between 2004–2009 was performed. Parameters including operative time, estimated blood loss (EBL), hospital stay, pathology, and complications were examined.

**Results:** A total of 15 patients with a mean BMI of 43 kg/m<sup>2</sup> (range 40–53) and mean weight 128.2 kg (range 93–173) underwent RALP. Mean preoperative PSA was 5.78 ng/dL and Gleason score was 6.6 (range 6–8). Mean operative time was 163 min (range 115–250) and EBL was 210 ml (range 50–400). The mean hospital stay was 1.3 days (range 1–2). Final pathology revealed pT2a (n = 3) and pT2c (n = 8), pT3a (n = 3), pT3b (n = 1). The Gleason score was 5 (n = 1), 6 (n = 6), 7 (n = 7) and 9 (n = 1). Mean prostate volume was 48.5 g (range 37–62). Positive margins were noted in 2 (13%) patients, each with pT3 disease. There were no blood transfusions, open conversion, or complications.

**Conclusion:** In our experience, RALP is feasible and safe in morbidly obese patients. We noted several technical issues in this patient population with regard to optimal trocar placement, insufflation, ventilation in the steep Trendelenburg position, and intraperitoneal space limitation. Obese patients undergoing RALP

require particular attention, and a thorough knowledge of these challenges is essential.

### MP15-19 A COMPARISON OF OUTCOMES AMONG MEN WITH AND WITHOUT URINE LEAKS AFTER ROBOTIC-ASSISTED LAPAROSCOPIC RADICAL PROSTATECTOMY

D. Rebeck, D. Kim, R. Rico, J. Meeks, K. Perry, R. Nadler

**Background:** Historically, leakage of urine leading to a urinoma around an anastomosis is thought to predispose to long-term complications including erectile dysfunction and incontinence. We sought to compare rates of erectile dysfunction (ED) and urinary incontinence between men who did and did not have post-operative urine leaks after robotic-assisted laparoscopic radical prostatectomy (RALRP).

**Methods:** A retrospective chart review of all RALRPs performed since October, 2006 was conducted. We excluded cases with < 6 months of follow-up. Urine leaks were defined as an elevated drain creatinine on the first and second post-operative days resulting in prolonged (>2 days) drainage. Erectile function was measured using the International Index of Erectile Function (IIEF) and Sexual Health Inventory for Men (SHIM) pre-operatively and post-operatively at 1, 3, 6, and 12 months, respectively. Incontinence was measured using pad usage at 1, 3, 6, and 12 months postoperatively.

**Results:** We reviewed 294 cases and 232 were eligible for inclusion. Among these, 21 patients had a urine leak (9.1%). Pre-operative IIEF scores were not significantly different between the groups (57.3 vs. 49.5, for no-leak and leak, respectively; p = .11). Post-operative SHIM scores at 1, 3, 6, and 12 months were also not significantly different between the groups (5.0 vs. 5.5, 6.8 vs. 7.0, 7.6 vs. 9.5, and 10.8 vs. 8.0, for no-leak and leak, respectively, p > .18). Rates of pad usage during the same intervals were also not significantly different between the groups (p > .20 for all comparisons).

**Conclusion:** In this study, anastomotic urine leak was not associated with an increase risk of ED or pad usage up to 1 year postoperatively.

### MP15-20 EVALUATION OF THE SAFETY OF PERI-OPERATIVE ENOXAPARIN ADMINISTRATION IN PATIENTS UNDERGOING ROBOTIC-ASSISTED LAPAROSCOPIC RADICAL PROSTATECTOMY

J. Yates, J. Uberoi, I. Sawczuk, D. Golombos, M. Gross, R. Munver—United States

**Background:** Patients undergoing robotic-assisted laparoscopic radical prostatectomy (RALP) are at increased risk for deep venous thrombosis (DVT) due to advanced age, surgery for pelvic malignancy, and procedure duration. We evaluated the safety of perioperative enoxaparin for patients undergoing RALP.

**Methods:** This prospective randomized study included 112 consecutive patients with localized prostate cancer that underwent RALP. Patients either received preoperative enoxaparin (40 mg subcutaneously) 3 hours prior to surgical incision time and another dose in the morning of the first postoperative day (enoxaparin group), or did not receive enoxaparin (control group). All patients had lower extremity sequential compression devices during surgery. Perioperative data included blood loss, operative time, subjective assessment of intraoperative bleeding, and blood transfusion rates.

**Results:** Of 112 patients, 58 received perioperative enoxaparin and 54 did not. Mean patient age was 59 (range 42–73) [enoxaparin group] and 60 (range 49–71) [control group]. Blood loss was 169 mL (range 25–450) [enoxaparin group] and 154 mL (50–350) [control group]. No patients required blood transfusions. Mean operative time was 127 min (range 72–182) [enoxaparin group] and 132 min (range 95–175) [control group]. Blood loss and operative times were not statistically significant between the two groups. Subjectively, surgeons rated the enoxaparin group as

having increased intraoperative bleeding based on blinded video review of each procedure. One patient in the control group developed postoperative DVT that required anticoagulation.

**Conclusion:** Perioperative enoxaparin administration was associated with a subjective perception of increased intraoperative bleeding, although the mean blood loss was not statistically significant between the groups. Enoxaparin administration appears safe for patients undergoing RALP and may be considered for patients that are at increased risk.

## MP16: UROLITHIASIS 2

### MP16-01 REMOVAL OF ASYMPTOMATIC IPSILATERAL RENAL STONES FOLLOWING RIGID URETEROSCOPY FOR URETERAL STONES

H. Ahmadnia, A. Yarmohamadi, M. Imani, M. Shokohian

**Background:** To evaluate the feasibility and outcome of rigid ureteroscopic removal of asymptomatic reachable renal stone(s) following rigid ureteroscopy for ureteral stones.

**Methods:** 30 patients underwent rigid ureteroscopy for removal of ureteral stones. All had asymptomatic renal stone(s) on the same side, which were then removed using rigid ureteroscopy. The renal stones were either removed intact with a grasp or fragmented with the pneumatic lithotripsy to small pieces, with grasp removal of larger fragments. The size of stones, added time for renal ureteroscopy and intraoperative and postoperative complications were recorded. Follow-up at 1 month included a plain abdominal film and renal ultrasonography.

**Results:** 30 renal stones with a mean size of 7.3 mm were treated. 13 patients had stone on the right side, and 17 had stones on the left. The mean added operative time was 9.25 + 0.05 minutes. Stones were removed intact in 21 patients and fragmented in 9 patients. One-month follow-up confirmed none of patients had new onset stones or hydronephrosis.

**Conclusion:** Removal of asymptomatic reachable renal stones at the time of rigid ureteroscopy for ureteral stones appears safe and effective and requires little additional operative time.

### MP16-02 HAND ASSISTED URETEROSCOPY IN URETERAL AND PYELIC STONE TREATMENT

P. Geavlete, R. Multescu, D. Georgescu, B. Geavlete—Romania

**Background:** Successful ureteroscopic procedures sometimes require various tricks such as hand-assistance. The aim of this study was to determine the value of manual maneuvers applied in order to facilitate the ureteroscopic approach of upper urinary tract lithiasis.

**Methods:** Between June 1994 and February 2009, 5102 patients underwent retrograde ureteroscopy (5534 ureteroscopic procedures). The retrograde approach was applied in 1238 cases with proximal ureteral lithiasis and 47 cases with pyelic stones. Hand assisted ureteroscopy was necessary in 362 cases.

**Results:** The success rate in patients with proximal ureteral stone was 86.5%, the approach of the calculus being impossible in 5.2% of cases. The hand assisted ureteroscopy was necessary in 338 cases with proximal ureteral lithiasis. In 285 of these cases, the

procedure was applied in order to facilitate the passage of the ureteroscope through the tortuous segments of the ureter, with a 78.5% success rate. In the other 53 cases with proximal ureteral lithiasis as well as the 24 cases with pyelic lithiasis, the manual assistance facilitated efficient lithotripsy by optimizing stone position and energy appliance.

**Conclusion:** According to our experience, hand assistance may facilitate retrograde ureteroscopic approach, thus improving the stone-free rates. This maneuver proved to be extremely efficient and provided the advantage of not raising the costs of the procedure.

### MP16-03 HYPERKALEMIA DOES NOT NEED CORRECTION PRIOR TO PERCUTANEOUS NEPHROSTOMY (PCN) IN OBSTRUCTED HYDRONEPHROSIS (OHN)

B. Somani, H. Gupta, S. Bramwell, A. Todd

**Background:** Hyperkalaemia is a known complication of obstructive uropathy. When present there is thought to be an increased risk of cardiac dysrhythmia. This study assesses the value of correcting the serum potassium prior to percutaneous nephrostomy with early intervention.

**Methods:** A total of 350 PCN was done for obstructed hydronephrosis between 2003 and 2008. Of these, fifty (14%) had hydronephrosis with hyperkalemia, defined as serum potassium >5 mmol/L.

**Results:** Fifty (14%) had hyperkalemia. In patients who underwent PCN (median: 1 day), 41 had malignant disease of which 20 were bladder or prostate and 9 had benign causes. 7 patients had urinary sepsis. PCN was bilateral in 23 (46%) cases. The mean pre-nephrostomy potassium and creatinine were 6 (range: 5.1–7.9), and 551 (median: 480; range: 62–1602) respectively. PCN alone was done for 29 patients, combined with dialysis in 6 patients and with additional medical treatment (iv insulin-dextrose or iv calcium gluconate or oral resonium) in 15 patients. The mean pre-nephrostomy potassium for PCN alone and with additional treatment were 5.5 (range: 5.1–6.8) and 6.6 (range: 5.4–7.9) respectively. Post-nephrostomy potassium the following day for all patients was 4.8 (range: 3.5–6.4). Median post-nephrostomy creatinine improved to 140 (range: 68–1002) after 10 days (range: 1–45 days). Two patients developed atrial fibrillation (AF), one resolved spontaneously and the other needed temporary treatment with verapamil.

**Conclusion:** PCN need not be delayed for attempts to correct potassium  $<6.5$  mmol/L and in the absence of ECG changes it remains a safe and effective procedure. Early drainage of obstructive uropathy by PCN is an effective and safe strategy to correct hyperkalaemia and restore renal function.

#### **MP16-04 KIDNEY FUNCTION IS DECREASED AFTER TREATMENT OF SILENT URETERAL STONE**

F. Vicentini, L. Borges, E. Mazzucchi, E. Chedid Neto, A. Brito, M. Srougi

**Background:** To describe the characteristics of the patients with asymptomatic ureteral stone and to evaluate the kidney function after its treatment.

**Methods:** Between 2005 and 2008, 325 patients underwent ureteroscopy for ureteral stones removal. We identified 20 patients with asymptomatic ureteral calculi (6.2%), 12 of them with postoperative kidney function evaluation with Dimercaptosuccinic Acid (DMSA). We describe the characteristics of these 12 patients.

**Results:** Median age of the 7 male and 5 female patients was 54.5 years (range 23 to 71). Localization of stones was 1 proximal, 4 mid and 7 in the distal ureter. Median stone size was 14 mm (range 8 to 45 mm). Stones were diagnosed by radiological abdominal evaluation for non urological diseases in 7 patients (58%) and during follow-up after previous urolithiasis treatment in 5 patients (32%). All patients had some degree of hydronephrosis. Primary therapy was ureteroscopic lithotripsy with laser and a double J insertion in all patients. The stones were impacted in 7 cases (58%). The stone-free rate after one procedure was 92% and 100% after a second look in one case. One ureteral stenosis (8%) was diagnosed after a medium follow-up of 23.5 months (range 6 to 84). Median postoperative kidney relative function on DMSA of the 12 patients was 34.5% (range 17 to 53%). In 9 patients (75%), DMSA showed an impaired renal function (less than 45%).

**Conclusion:** Silent ureteral stones are associated with a decreased kidney function after their treatment, suggesting that these stones must be treated when diagnosis is made.

#### **MP16-05 A "CUBIC STONE": L-SHAPED KIDNEY COMPLICATED BY CALCULOSIS AND HYDRONEPHROSIS**

M. Malta Almeida, J. Teixeira Bessa, A. Vommaro Mendes, J. Milfont, M. Fortes, J. Callijão Araújo—Brazil

**Background:** Congenital anomalies of the upper urinary tract comprise absent and supernumerary kidney, anomalies of location, form and fusion, rotation, renal vasculature and anomalies of the collecting system. Abnormalities are usually asymptomatic and only cause problems when complications occur, such as stone formation. L-shaped fused ectopic kidney is a rare variant of crossed fused renal ectopia. Congenital ureteropelvic junction (UPJ) obstruction may occur in crossed ectopia.

**Methods:** A 38-year-old female patient consulted for lower back pain mainly on the right side and recurrent urinary infections. The urinary sediment showed leucocyturia and haematuria. The radiography indicates presence of a radiopaque squared image on the topography of the right kidney. Intravenous urography and CT showed an L-shaped kidney with dilation of right renal pelvis and calyces complicated by presence of two calculi.

**Results:** With a diagnosis of a crossed fused ectopia with stones and UPJ obstruction of the orthotopic kidney the patient was managed laparoscopically with right pyelolithotomy and pyeloplasty after endoscopic placement of urethral double-J catheter bilater-

ally. Urethral catheterization of the ectopic kidney was done prior to the surgery, and it helped us avoid urethral injury. Anomalous vasculature was not found and a high implantation of the ureter was the cause of UPJ obstruction.

**Conclusion:** Although treatment for calculi in abnormal kidneys such as L-shaped kidney can be challenging, the decision must be made on individual basis regarding multiple variables. Endoscopic and laparoscopic procedures or a combination of both seems to be the trend for treatment of stones in anomalous kidneys. Providing all techniques are available to the surgeon, stones can be cleared in almost all patients.

#### **MP16-06 IMPACT OF PERCUTANEOUS NEPHROLITHOTOMY ON RENAL FUNCTION DURING FIRST FEW DAYS AFTER SURGERY**

A. Nouraliadeh, M. Mohammadi Sichani, A. Kashi, M. Kamranmanesh

**Background:** Long term effects of PCNL on renal function were evaluated in many studies but we have very limited data about renal effects of PCNL immediately after surgery. The aim of this study was to evaluate estimated GFR during first few days after PCNL.

**Methods:** Between July and September of 2008, we gathered preoperative and postoperative serum creatinine of 105 consecutive patients who underwent PCNL in our center. We calculated clearance of creatinine by Cockcroft-Gault and MDRD2 equation and compared them.

**Results:** The mean clearance of creatinine by Cockcroft-Gault equation was 94.33 cc/min preoperatively that decreased to 90.74 cc/min about 6 hours after surgery. Declining continued to 84.18 cc/min and 82.25 cc/min during first and second days after PCNL but, fortunately it increased to 87.55 cc/min after 72 hours.

**Conclusion:** Renal GFR will decrease immediately after PCNL and take several days to return to normal level then it is necessary to prevent factors that have a negative effect on renal function during this period.

#### **MP16-07 IS OPEN URINARY STONE SURGERY DEAD?**

R. De lima favaretto, M. Augusto Elias de Mattos, M. Jose Bruschini Rodrigues Netto, N. Rodrigues Netto Junior—Brazil

**Background:** Development in extracorporeal shock wave lithotripsy (ESWL), percutaneous nephrolithotripsy (PCNL) and ureteroscopy (URC) have almost eradicated the need for open stone surgery. However, there are still a small number of patients submitted to this procedure. The aim of this study is to evaluate the incidence and indications of open surgery during a 10-year period.

**Methods:** Between 1995 and 2005 a total of 425 patients with urinary stones were treated. Endourological procedures were performed in 391 patients (71 PCNL and 320 URC). Open surgery was performed in 34 patients (12 ureterolithotomy, 16 pyelolithotomy and 6 anatomic nephrolithotomy). The mean age was 42 years. We retrospectively analyzed the incidence, indications and types of open surgery.

**Results:** Of a total of 425 patients, 34 (8%) underwent open surgery. A total of 332 had ureteral calculi, 320 (96.4%) of them underwent URC and 12 (3.6%) had open surgery. A total of 8 of the 12 patients referred for open surgery had failed ureteroscopy and 4 had failed ESWL. A total of 93 patients who underwent surgery for renal stones 71 (76.3%) performed PCNL, 16 (17.2%) pyelolithotomy and 6 (6.5%) anatomic nephrolithotomy. Indication for

open surgery was complete staghorn calculus in 8 patients, anatomical abnormality in 1 and - ESWL or PCNL failure in 13.

**Conclusion:** Even with the development of endourological techniques, there is still a small percentage of patients whose stones require open surgery.

### MP16-08 UNKNOTTING A KNOTTED ZEBRA WIRE IN THE URETER: A USEFUL TECHNIQUE INVENTED

A. Ashish Patil—India

**Background:** Zebra wire is commonly used during reterorenoscopy. Knotting of a such a wire in the ureter is unfortunate, rare and an unpleasant surprise and experience for the urologist. We herewith describe a unknotting technique used by us.

**Methods:** The technique described was used after a Zebra wire accidentally knotted when put up the ureter during a Ureterorenoscopy. In order to stent the ureter at the end of a ureterorenoscopy for a calculus in the mid ureter; a Zebra wire was introduced up the ureter through the ureterorenoscope. The wire could not be advanced more than 10 cms beyond the ureteroscope. On fluoroscopy the wire revealed a knot. The knot was then pulled into view. Its anatomy studied. The following two steps were then repeated in order to undo the knot. STEP 1: The tip of the wire was lightly abutted against the ureteric mucosa and the wire with the ureterorenoscope minimally advanced. This resulted in the end of the wire getting pushed into the knot increasing the diameter of the loop of the knot. STEP 2: Minimal withdrawal of the wire into the scope. Decreasing the diameter of the knot loop. Repeating STEP 1 and 2 the knot came free in approximately 3 minutes.

**Results:** We found the technique effective for unknotting the knotted zebra wire.

**Conclusion:** We find this technique safe and effective. It is easy to learn and does not need any special equipment. We recommend this technique for a knotted wire.

### MP16-09 CONTRALATERAL URETEROSCOPY PERFORMED AT TIME OF PERCUTANEOUS NEPHROLITHOTOMY: A UNIQUE EVALUATION OF STONE FREE RATES

A. Krambeck, S. Handa, J. Lingeman—United States

**Background:** The immediate stone free rates of ureteroscopy are rarely analyzed. The goal of our study is to assess the immediate success rate and safety of ureteroscopy by evaluating all patients undergoing contralateral ureteroscopy (URS) at time of percutaneous nephrolithotomy (PCNL).

**Methods:** From our prospectively collected PCNL database, we identified 65 patients who underwent contralateral URS for urolithiasis at time of PCNL from December 2001 to December 2008. Stone-free status was assessed by computed tomography scan (CT) performed on post-operative day 1.

**Results:** Mean age at surgery was 51 years (19–84) and there were 32 males, 33 females. Mean patient BMI was 38.6 (17.9–56.3). All stones were <2 cm in size. Flexible URS was performed in 56, semi-rigid 3, semi-rigid + flexible 5, and unspecified 1. Mean surgery time including PCNL was 143.2 minutes (60–260.0). Postoperative imaging was available for 63 patients of which, 61.9% were stone-free, 12.7% had 1–3 mm fragments, 3.2% had >3 mm fragments, and 24.7% size of fragment was not documented. Three patients went on to have a secondary URS for residual fragments. Mean length of hospitalization was 2.5 days (1–

11). No major complications were attributable to the URS portion of the procedure.

**Conclusion:** Over 60% of patients can be rendered immediately stone-free with URS. When passable fragments are included, the relative success rate based on gold standard imaging is 75%. Furthermore, URS at time of PCNL is safe with minimal prolongation of the procedure or overall hospitalization.

### MP16-10 PROFILE OF THE BRUSHITE STONE FORMER

A. Krambeck, S. Handa, F. Coe, A. Evan, J. Lingeman—United States

**Background:** The incidence of brushite stones has increased over the last 3 decades. We report our experience with brushite stone forming patients.

**Methods:** From 1996 to 2008 we identified 84 patients with brushite urinary calculi. After institutional review board approval a review of our prospectively collected database was performed.

**Results:** There were 55 (65.5%) males and 29 (34.5%) females. Mean age was 44 years (range 4–84). Prior stone events were reported by 70 (83.3%) patients with 54 (64.3%) having SWL. Bilateral calculi were present in 25 (31.6%). Mean stone area was 28.9 mm (2–130). Surgery was performed in 80 patients including: 61(76.3%) PCNL, 9 (11.2%) ureteroscopy, 5 (6.2%) SWL, 5 (6.2%) combination. 64 (80%) were stone-free status and the remaining 16 underwent a secondary procedure. 24-hour urine studies were available in 47 patients. All demonstrated one or more abnormalities: hypercalciuria 38 (80.9%), urine pH > 6.2 in 29 (61.7%), urine volume < 2L in 27 (57.4%), hypocitraturia 22 (46.8%), hyperuricosuria 8 (17%), and hyperoxaluria 5 (10.6%). Recurrent stone events occurred in 18 (21.4 %) patients at a mean of 318 (34–1080) days from treatment.

**Conclusion:** Brushite stone formers are a treatment challenge. Almost a third will present with bilateral stones and stone burden is sizeable. Nearly 65% of patients report a prior SWL and recurrent stone events occurred approximately 1 year after treatment. All brushite patients in this cohort had an underlying metabolic abnormality, specifically brushite stones should be heralded as a marker for hypercalciuria. Based on these data we recommend all brushite stone formers undergo 24-hour urine studies and have long-term follow-up.

### MP16-11 STONEMAG: IMPROVED BINDING TIMES PERMIT MAGNETIZATION OF STONE FRAGMENTS FOR “REAL-TIME” REMOVAL WITH ENDOSCOPIC PLATFORMS

C. Tracy, S. Mcleroy, B. Gnade, M. Pearle, J. Cadegdu—USA

**Background:** We have developed iron-based microparticles (StoneMag) that adhere to calcium-based kidney stones, such that they may be removed with magnetic instrumentation. Herein, we report our experience with improved particle surface coating, which significantly decreases lengthy incubation times that previously hindered this technology.

**Methods:** A modified peptide coating was covalently bound to commercially available iron oxide microparticles and the solution was incubated with human calcium oxalate kidney stone fragments, using 3 separate concentrations of iron microparticles and two stone fragment sizes (1–2 mm and 2–3 mm) for three different incubation times (2, 5, and 10 minutes). For each trial, 10 fragments were extracted from a glass vial using a 7.6Fr magnetic extraction device. Stone removal was successful if individual

stones could be removed from the solution without uncoupling from the device.

**Results:** 18 trials were completed with an overall success rate of 91% and 43% for all concentrations and incubation times for 1–2 mm fragments (small) and 2–3 mm fragments (large), respectively. After 2 minutes, 70% of small fragments were successfully extracted at the lowest particle concentration, while 100% of small fragments were successfully extracted at both the middle and high particle concentrations (Figure 1). No large stone fragments were successfully extracted at the lowest particle concentration, but 70% and 100% were successfully extracted after 10 minutes of incubation at the middle and highest concentrations, respectively.

**Conclusion:** Improved peptide coating allows for successful in vitro extraction of small (1–2 mm) stone fragments at low particle concentrations, providing the necessary framework for “real time” in vivo magnetization of stone fragments for endoscopic removal with magnetic instrumentation.

### MP16-12 METABOLIC STONES: HOW RELIABLE ARE STONE ANALYSIS RESULTS?

A. Krambeck, N. Khan, M. Jackson, J. Lingeman, J. Williams Jr—United States

**Background:** The goal of this study was to determine the accuracy of stone composition analysis by major commercial laboratories.

**Methods:** Forty-six human renal stones with infrared spectroscopy (IR) determined composition were fragmented into six aliquots and studied with micro computed tomography (CT). Only 26 stones had fragments similar enough to be considered identical. The fragments were submitted to 1 research and 5 commercial laboratories for blinded analysis.

**Results:** All labs agreed on composition for the 2 uric acid (UA) and 2 cystine stones. All reported brushite as the primary component for 2 stones; 4 also reported secondary components [carbonate apatite (CA), hydroxyapatite (HA), calcium oxalate (CaOx) monohydrate (COM), or calcium oxalate dehydrate (COD)], that did not agree. For 9 CaOx stones, 3 (33%) were not reported as CaOx by a lab. All labs agreed on the secondary component in only 2 stones, and in only 1 stone was the proportion of COM/COD agreed upon by all labs. The labs did not agree on the primary or secondary components for 2 mixed UA/COM stones. For 4 apatite stones, all labs agreed on the primary component in only 1 stone. One lab reported all apatite as CA and never HA, another lab never reported CA and always HA, and a third lab reporting CA as a percentage of apatite mixed with calcium carbonate.

**Conclusion:** Commercial laboratories can reliably diagnose pure calculi; however, there is significant variability in both qualitative and quantitative results of mixed calculi. Furthermore, there is a lack of standardization of nomenclature used by laboratories.

### MP16-13 A NOVEL DEVICE TO REDUCE TIME REQUIRED IN IRRIGATION MANAGEMENT DURING SEMI-RIGID URETEROSCOPIC LITHOTRIPSY

J. Ditrolio, M.D., M. Lasalle, M.D., R. Bhalla, M.D.—USA

**Background:** Control of irrigation fluid during ureteroscopy and lithotripsy consumes approximately twenty percent of the operative time. The objective of this study was to evaluate a more efficient control of irrigation fluids; therefore, reducing the operative time required to treat ureteral calculi endoscopically.

**Methods:** Semi-rigid ureteroscopy performed with the pressure-bag irrigation was evaluated for intraoperative time required to control

irrigating fluids during an ureteroscopic lithotripsy. The percentage of total operative time was calculated comparing the standard procedure of stopcock adjustment to using the Classic Universal Piggyback Irrigation System produced by Kosin Technologies.

**Results:** Time required to manage irrigating fluids in the standard stopcock fashion was compared to utilization of the Kosin device. Operative irrigation showed a reduction from approximately 20 percent to 10 percent of the total operative time. Reduction in operative time was directly attributed to better fluid management, better visibility and increased dexterity. Added benefits were the ability to leave one hand available continuously for lithotripsy treatment.

**Conclusion:** Better fluid management using a device that is structurally attached to the semi-rigid ureteroscope allows for one hand manipulation of both the scope and irrigation fluid, allowing the second hand to be directed to the lithotripsy management. Reduction in operating time is directly related to decreased fluid management time, better visibility and less stone migration because of better control of fluid management.

### MP16-14 THE COMPARISON BETWEEN TWO GROUPS OF PATIENTS UNDER OPERATION AND LITHOTRIPSY DUE TO URINARY TRACT STONES FROM THE ASPECT OF EPIDEMIOLOGIC PARAMETERS DURING YEARS 2003–2006 ADMITTED AT UROLOGY DEPARTMENT OF LR HOSPITAL

R. Taghavi, K. Tavakkoli Tabassi, R. Mahdavi Zafarghandi, M. Darabi Mahboub—Iran

**Background:** Urolithiasis is one of the most frequent diseases of urinary system which forms high percentage of patients who come to Urology wards. Therefore, study of epidemiological characteristics of patients of each ward can be helpful for making the best general decision.

**Methods:** First, we divided 5133 cases who had come to Urology department of our hospital during 2003 – 2006, in 2 groups and then in 6 groups. We investigated and compared 2 groups of lithotripsy and surgery from the aspect of epidemiological characteristics. so we did for 6 groups: pyelolithotomy and nephrolithotomy (in 1 group), ureterolithotomy, ureteroscopy and TUL (in 1 group), PNL, ESWL, cystolitholapaxy.

**Results:** From 5133 cases, mean age of 43.41, men to female ratio 2.1, 90.1% had done lithotripsy and 9.2% surgery. Percentage of patients of pyelolithotomy and nephrolithotomy was 3.5%, ureterolithotomy 0.8%, ureteroscopy and TUL 39.5%, PNL 4.9%, ESWL 49.5%, cystolitholapaxy 1.9%. mean stay in hospital for lithotripsy  $1.31 \pm 0.38$  and for surgery  $4.84 \pm 0.32$ , in ESWL  $0.81 \pm 0.5$  and in pyelolithotomy and nephrolithotomy  $5.09 \pm 0.34$  days. During years 2003–5 percentage of ESWL was: 59.9, 51.4 & 38.4% of all admissions in these years. PNL's percentage was: 3.8, 5.51, 5.53%. Choosing of PNL in urban people was highest (84.5%) and for rural people pyelolithotomy and nephrolithotomy was the most frequent technique in use.

**Conclusion:** Despite of other advanced countries high percentage of our patients undergo open surgery especially in rural people, yet. So we should provide facilities of education and financials for modern and lower costs of urinary tract stone treatments.

### MP16-15 PERCUTANEOUS NEPHROSTOMIC TREATMENT OF UPPER URINARY TRACT FUNGAL BALL COMPLICATING HYDRONEPHROSIS

H. Chen, W. Xue, J. Pan, M. Cao, Y. Chen, Y. Huang

**Background:** To evaluate the efficacy and clinical outcome of percutaneous nephrostomic (PCN) treatment for upper urinary tract fungal ball complicating hydronephrosis or fungemia.

**Methods:** 3 cases (2 female and 1 male) of upper urinary tract fungal ball complicating hydronephrosis were studied retrospectively. All the cases were admitted in the department of urology of Shanghai Renji Hospital. Case 1, a 37-year-old female, treated by corticosteroid for the dermatomyositis. Meanwhile, the patient was treated by PNL procedure for staghorn calculi in the right kidney 6 months before the onset of the pyonephrosis and fungemia. The emergency right kidney drainage by PCN was carried out and the fungal ball was completely removed by the rat tooth forceps in the secondary surgery when the infection was controlled. Case 2, a 42-year-old female, had the medical history of diabetes mellitus type-1. The patient came to the out-patient department for filling defect with scattered calcification in the right uretero-pelvic junction, which was clinically diagnosed as right uretero-pelvic fungal ball. The PCN was realized and then the fungal ball was removed in the secondary operation. Case 3, a 57-year-old male, was firstly diagnosed as left ureteral stone with hydronephrosis and a left ureteroscopic lithotripsy was programmed. During the procedure, since a grey, putty-like cast was found, the left PCN drainage was realized immediately and the fungal cast was removed in the same time. In all the 3 cases, the specimen pulled out was sent to the laboratory to look for the hyphae and to make the fungal culture. After the PCN drainage, the fluconazole was administered intravenously during the first 3–4 days and was given orally after 48 hours afebrile status. Meanwhile, during the first 5 days after the completely removal of the fungal ball, the upper tract was irrigated by 200 mg fluconazole diluted to 1000 ml with physiological saline. A follow-up by IVU was carried out 3 months after the procedure.

**Results:** The fungal ball was completely removed in all the cases. In case 1, the body temperature was put back 48 hours after the PCN drainage. There was no fever in case 2 and case 3 after the surgery. The fungal hyphae was positive in all the cases and the candida albicans was found by the fungal culture. There was no kidney or liver function alteration during the anti-fungi treatment. The IUV was clean in all the cases 3 months after the removal of the fungal ball.

**Conclusion:** The PCN drainage should be carried out when the diagnosis of upper urinary fungal ball was established. By the PCN procedure, the complete removal of the fungal ball is possible and the risk of fungemia after the procedure was relatively low. The intravenous administration and renal pelvic irrigation of fluconazole is very important for such cases.

#### MP16-16 LATERAL DECUBITUS POSITION PERCUTANEOUS ENDOUROLOGICAL PROCEDURES IN HIGH RISK PATIENTS

T. El-husseiny, K. Moraitis, Z. Maan, P. Saunders, J. Masood, N. Buchholz

**Background:** Percutaneous endourological procedures are most commonly performed with the patient in the prone position under a general anaesthetic. In high risk patients, this approach can lead to circulatory and respiratory compromises. Operating on such patients in a full lateral position will minimize the haemodynamic and respiratory risks and—if combined with regional anaesthesia—will allow for increased patient comfort and safety.

**Methods:** A total of 27 medically high risk patients (12 males, 15 females) with a mean age of 62 years and an ASA score of >3 were included in this study. The majority (78%) had regional (spinal/epidural) anaesthesia. In the majority of these cases we performed an initial retrograde renal study/ filling with contrast medium in lithotomy position to aid the kidney puncture. The percutaneous procedure was then performed with the patient in the lateral decubitus position and access was performed under fluoroscopic guidance. In the remaining patients where there was no first stage, the puncture was performed under ultrasound guidance. Twenty-two percutaneous nephrolithotomies (PCNL), 3 antegrade endopyelotomies (AEP), 1 percutaneous resection of renal pelvic transitional cell carcinoma, and 1 percutaneous renal cyst sclerotisation were performed.

**Results:** 11 patients were stone free after PCNL and a further 8 after adjuvant SWL for small residual fragments. One renal access failed. Two procedures were aborted because of haemorrhage after tract dilatation. Nuclear medical renal scanning after 3 months showed relief of obstruction in all three AEP patients. Ultrasound confirmed complete resolution of the sclerotized renal cyst. None of our patients with regional anaesthesia required conversion to general anaesthesia.

**Conclusion:** The full lateral position—which whilst requiring expertise and experience to gain proficiency in performing good renal access—is safe and effective in medically high risk patients. Complex percutaneous renal procedure can be safely and effectively performed under regional (spinal/epidural) anaesthesia avoiding the risks of general anaesthesia. Cardiac and respiratory parameters are improved and easily controlled. In morbidly obese patients the lateral position under spinal anaesthetic not only reduces circulatory and respiratory complication but allows for easier access to the kidney when compared to the prone position.

#### MP16-17 THE NEW INVISIO® DUR-D “CHIP-ON-THE-TIP” URETEROSCOPES—EVALUATION OF CHANGES IN PHYSICAL PROPERTIES OVER TIME

T. E. -lusseiny, K. Moraitis, Z. Maan, M. Birch, J. Masood, N. Buchholz

**Background:** Flexible ureteroscopes have become an essential tool in endourological practice. Recently, a new generation of digital flexible ureteroscopes has been marketed (Invisio® DUR-D, ACMI, USA) with which a new optical technology was introduced. The tip houses dual Light Emitting Diodes (LED) driven light carriers. A 1 mm digital camera at the tip eliminates the need for fragile low-resolution fibre-optics and provides superior resolution. In addition, the image quality is digitally enhanced. It was claimed that not only should this markedly increase the image quality, but also make the instrument more durable in the whole. We have therefore compared both, light intensity and deflection angles with and without indwelling instruments between identical scopes after different number of uses.

**Methods:** On three identical Invisio® DUR-D digital flexible ureteroscopes of different usages we measured and compared the light intensity at a given setting of the light source using an Ocean Optics optical spectrometer at 20 mm distance from the tip. Measurements were taken three times each with the ureteroscopes in straight position and upwards/ downwards deflection, respectively. The first scope was brand new; the second had been used 30 times while the third had been used 44 times. We also measured and compared the deflection angles without and with instruments—a

0.035" Cook guidewire, a 200  $\mu$ m laser fibre and a 3F zero-tip nitinol basket - inside the working channel in four identical scopes after 0, 10, 30, and 44 uses, respectively.

**Results:** Light intensity for each scope showed slight differences in relation to deflection angles, which is within the experimental error and did not significantly differ. Light output remained stable after many uses. Table 1. Light intensity in different deflection (unit: Lux $\times 10^3$ ). Straight Upwards Downwards 0 Uses 5.54.36 4.84 30 Uses 6.196.30 6.26 44 Uses 5.055.25 5.15 In contrast, the deflection angle is shown to deteriorate with instruments inside the working channel. This is relatively independent of the type of micro-instrument used, but the decrease is directly proportional with advanced age of the scope. Table 2. Deflection angles with different instruments No instruments .035" guidewire 200  $\mu$ m laser fibre 3F nitinol basket 0 uses upwards 218° 196° 205° 204° 10 uses upwards 216° 194° 203° 203° 30 uses upwards 197° 173° 174° 174° 44 uses upwards 163° 148° 155° 152° 0 uses downwards 216° 194° 209° 191° 10 uses downwards 199° 191° 192° 190° 30 uses downwards 230° 139° 151° 147° 44 uses downwards 170° 123° 141° 158°

**Conclusion:** As an advantage over earlier generation scopes, light output remains constant due to the avoidance of the fragile low-resolution fibre-optics, further helped by digital enhancement. Similarly to the earlier generation scopes, there remains a decrease in deflection capability over time with the new Invisio® DUR-D digital flexible ureteroscopes.

### MP16-18 COST-EFFECTIVENESS OF ANTI-RETROPULSION DEVICES FOR URETEROSCOPIC PNEUMATIC LITHOTRIPSY

E. Olweny, B. Eisner, M. Stoller

**Background:** The use of anti-retropulsion devices during ureteroscopic lithotripsy decreases stone migration and secondary procedures. These devices include the the Stone Cone (Boston Scientific, Natick, MA), the Accordion Stone Management Device (PercSys, Palo Alto, CA), and the NTrap (Cook Urological, Bloomington, IN). We examined the cost-effectiveness of the use of these devices during ureteroscopic pneumatic lithotripsy.

**Methods:** A decision analytic model was created to simulate treatment. Outcome probabilities were derived from peer-reviewed literature (Journal of Urology, Journal of Endourology, Urologia Internationalis). Direct procedural costs were derived from institutional billing records. Decision analysis models were based on ureteroscopic pneumatic lithotripsy as primary treatment of a ureteral stone and shock wave lithotripsy (SWL) as salvage secondary procedure for retropulsed clinically significant residual stone fragments.

**Results:** Procedural and office costs for ureteroscopy with lithotripsy and SWL were \$5580 and \$5191 respectively. Device costs averaged \$262 (range \$235–\$295). Stone retropulsion requiring a secondary procedure was 15.6% for pneumatic lithotripsy without anti-retropulsion devices and 0.9% for pneumatic lithotripsy with anti-retropulsion devices. Decision analysis revealed that anti-retropulsion devices are cost-effective for use during pneumatic lithotripsy at a retropulsion rate of 14% or greater.

**Conclusion:** Anti-retropulsion devices are cost-effective at retropulsion rates of 14% or greater. Many reports of pneumatic lithotripsy report retropulsion rates far greater than this. Therefore, due to the high risk of retropulsion (and subsequent procedures) during pneumatic lithotripsy, use of anti-retropulsion devices can

potentially reduce costs and secondary procedures, leading to improvements in patient care.

### MP16-19 HYDROXYPROLINE-INDUCED HYPEROXALURIA USING ACIDIFIED AND TRADITIONAL DIETS IN THE PORCINE MODEL

D. Kaplon, T. Crenshaw, K. Penniston, S. Nakada

**Background:** This study seeks to create a model of hyperoxaluria in the adult sow by feeding hydroxyproline (HP). We tested this model in sows fed a traditional gestating diet and in those fed an acid-rich diet similar to the Western-type diet in humans.

**Methods:** Twelve multiparous, gestating sows were randomly allotted to either a control diet (CD) or acidogenic (AD). Each sow was catheterized, and urine was collected for 6 consecutive days. On day 1 and 2, each sow was fed 2 kg of the assigned basal diet (CD or AD). On days 3, 4, and 5, 200 g of L-hydroxyproline was added to each basal diet for all 12 sows. On day 6, each sow was fed the basal diet originally assigned without HP.

**Results:** The addition of HP to the diet increased urinary oxalate and glycolate excretion. There was a 145% (CD) and 74% (AD) increase in urinary oxalate. The increase in oxalate peaked on day 5 in the CD group and day 3 in the AD group and gradually declined in each group by day 6. There was a 9000% (CD) and 8500% (AD) increase in urinary glycolate between day 1 and day 3. The increase in glycolate peaked on day 3 and then declined only gradually by day 6.

**Conclusion:** A model for human hyperoxaluria can be reliably created in the adult sow. Such a model will be useful to further our understanding of oxalate metabolism and ultimately aid in the prevention of calcium oxalate calculi.

### MP16-20 THE IMPACT OF METABOLIC RISK MANAGEMENT ON RECURRENCE OF URINARY STONES: 9-YEAR AKDENIZ UNIVERSITY EXPERIENCE

M. Baykara, Y. Akin, T. Erdogan, A. Danisman, S. Yucel—Turkey

**Background:** Although recurrence in stone formation is linked to metabolic abnormalities accessible by metabolic risk analysis, few data is present proving the management of metabolic risks may decrease the recurrence. In this study, we analyzed our 9-year urinary stone database to search the effect of metabolic management of risk factors detected by risk analysis studies on recurrent stone formers.

**Methods:** We retrospectively analyzed Akdeniz University Urinary Stone Database between dates of January 2000 and March 2009. We found over 3200 patients who were managed by any intervention. All patients were recorded according to their age, sex, previous urinary stone disease, previous and current stone analysis, previous and current metabolic analysis, previous and current metabolic management, current stone burden and location, modality and result of intervention, and current stone status on the last visit date.

**Results:** 525 patients metabolic risk analysis was ordered due to recurrent urinary stone disease. Only 134 (25.5%) current metabolic analysis were returned. Mean patient age was 32.2 years (range: 19–82 years) and 103 male and 31 female. Stone analysis results were Ca oxmono-dihydrate in 70 (52.2%), Ca oxmonohydrate in 48 (35.8%), Ca oxdihydrate in 8 (5.9%), uric acid in 3, Ca oxmonohydrate and uric acid in 2, cystine in 2, struvite in 1. The metabolic risk analysis showed abnormality in 54 (40.2%). The

most common abnormality was hypocitraturia in 31(57.4%) patients. The second and third most common abnormalities were hyperoxaluria in 21 (38.8%) and hypercalciuria in 19 (35.1%) patients. No primary hyperoxaluria was noted. In 2 hypercalciurics primary hyperparathyroidism was found and referred for adenoma removal. In other 2 hypercalciurics renal type hypercalciuria was found and started on thiazids. Patients were started on metabolic management by urinary alkalinization, citrate replacement, Vit B6, allopurinol and dietary restrictions accordingly. All were followed up for a mean of 39 months (range: 3 months–8 years) with renal US and KUB. In 8 (5.9%), stone recurrence was detected. Recurrent stone formers demonstrated stone types as Ca oxalate monohy-

drate in 5, cystine in 1, uric acid in 1, Ca oxalate dihydrate and uric acid in 1 patient. Their metabolic abnormalities were hypercalciuria in 3 (1 rejected parathyroid adenoma removal and 1 stopped thiazids), hyperoxaluria in 1, hypocitraturia and hyperoxaluria in 1, hyperuricosuria in 1 (stopped allopurinol treatment). Remaining one recurrence was in a cystinuric case while the other recurrence showed no metabolic abnormality.

**Conclusion:** Recurrence of urinary stones in patients who are started on appropriate metabolic management can be prevented. Patients should be warned about the close relationship between metabolic risk screening and compliance to management and urinary stone recurrence.

## MP17: ROBOTICS—KIDNEY

### MP17-01 ROBOTIC KIDNEY SURGERY IN PATIENTS WITH PREVIOUS ABDOMINAL SURGERY: FEASIBILITY AND PERIOPERATIVE OUTCOMES

M. Patel, A. Bhandari, E. Khetarpal, A. Pichurko, M. Menon, C. Rogers—USA

**Background:** Transperitoneal minimally invasive partial nephrectomy may be challenging in patients with a history of previous abdominal surgery. We evaluate feasibility and perioperative outcomes during robotic kidney surgery in patients with previous abdominal surgery.

**Methods:** 143 patients underwent robotic kidney and adrenal surgery between 2004 to 2008, of which 75 had a history of prior abdominal surgery. Demographic and perioperative variables including operative time, blood loss, rate of adhesiolysis, length of stay, transfusion rate, complication rate were reviewed. Patients without prior surgery were compared to patients with major and minor prior abdominal surgery. Minimally invasive and gynecologic procedures not involving the upper abdomen were classified as minor while open and other procedures were classified as major. Initially in our experience access was gained using a Veress needle, while more recently direct vision access and Hassan techniques were also used. Adhesiolysis was performed laparoscopically as needed to allow for robotic port placement.

**Results:** 75 patients with prior abdominal surgery underwent robotic kidney surgery (minor–28, major–47). No statistically significant differences were found between groups operative time, blood loss, transfusion rates, and complication rates. There was one bowel injury during Veress needle placement and one enterotomy during laparoscopic adhesiolysis, both in major surgery group patients.

**Conclusion:** Robotic assistance is a feasible option for minimally invasive kidney surgery with similar perioperative outcomes in the setting of prior abdominal surgery.

### MP17-02 ROBOTIC PARTIAL NEPHRECTOMY FOR RENAL TUMORS GREATER THAN 4 CM

M. Patel, R. Laungani, A. Shrivastava, E. Khetarpal, M. Menon, C. Rogers

**Background:** Minimally invasive partial nephrectomy is generally reserved for renal tumors less than 4 cm. The efficacy of robotic partial nephrectomy (RPN) for larger tumors has not been assessed. We evaluate RPN outcomes for tumors greater than 4 cm in comparison to RPN for smaller tumors.

**Methods:** Patients undergoing RPN at our institution between August 2007 and May 2009 by a single high-volume robotic renal surgeon (CR) were reviewed. Patients with tumors greater than 4 cm on preoperative imaging were compared to a similar cohort undergoing RPN for smaller tumors during the same period. Perioperative variables including operative time, estimated blood loss (EBL), warm ischemia time (WIT), length of stay (LOS), estimated glomerular filtration rate (eGFR), and complication rate as well as pathological variables including histology, Furman grade, pathologic stage and positive margin rate were analyzed.

**Results:** 57 patients underwent RPN during the study period of which 12 were greater than 4 cm on preoperative imaging. Both groups had similar demographic characteristics. Radiographic tumor size was larger for larger tumors ( $p < 0.001$ ). Both groups had similar EBL, LOS and complication rates. WIT were longer for larger tumors (28.4 vs 22.2 min,  $p = 0.011$ ) as was total operative time (303.4 vs 253.5 min,  $p = 0.044$ ). Both groups had similar postoperative and follow-up eGFRs ( $p = 0.968$  and  $p = 0.438$  respectively). Pathologic factors including tumor type and Furman grade were similar between the groups. Pathologic stage was higher and pathologic tumor size was larger for larger tumors ( $p < 0.001$  for both).

**Conclusion:** With appropriate patient selection, RPN for tumors, 4 cm is a technically feasible approach to nephron sparing surgery showing results comparable to RPN for smaller tumors.

### MP17-03 ROBOTIC LAPAROENDOSCOPIC SINGLE SITE SURGERY USING GELPORT AS THE ACCESS PLATFORM

R. Stein, W. White, R. Goel, B. Irwin, G. Haber, J. Kaouk

**Background:** To present our experience using the GelPort® laparoscopic system as an access platform for robotic LESS (R-LESS) procedures.

**Methods:** A prospective, observational study was performed to evaluate the GelPort® laparoscopic system as an access platform



during R-LESS. Using a 2.5–5 cm skin incision, the GelPort<sup>®</sup> was deployed and the da Vinci<sup>®</sup> Surgical System docked through the GelPort<sup>®</sup>. Perioperative data were obtained for all patients including demographic data, operative indications, operative records, length of stay, visual analog pain scale at discharge, complications, and pathological analysis.

**Results:** Between April 2008 and June 2009, 14 R-LESS procedures were completed. Four R-LESS procedures were successfully performed using the GelPort<sup>®</sup> as the access platform. Two patients underwent R-LESS pyeloplasty with a mean operative time of 235 minutes and a mean EBL of 38 cc. One patient underwent R-LESS radical nephrectomy for a 5.1 cm enhancing renal mass. Operative time was 200 minutes and EBL was 250 cc. One patient underwent R-LESS partial nephrectomy for an 11 cm angiomyolipoma refractory to embolization. Operative time was 180 minutes and EBL was 600 cc. No intraoperative complications occurred. Mean length of hospitalization for the 4 patients was 1.75 days. The patient who underwent R-LESS partial nephrectomy required a blood transfusion post-operatively.

**Conclusion:** Use of the GelPort<sup>®</sup> as an access platform for R-LESS procedures provides adequate spacing and flexibility of port placement and acceptable access to the surgical field for the assistant, especially during procedures that require a specimen extraction incision. Additional platform and instrumentation development will further simplify R-LESS procedures.

#### MP17-04 DOES TRAINING ON A VIRTUAL REALITY ROBOTIC SIMULATOR IMPROVE PERFORMANCE ON THE DAVINCI SURGICAL SYSTEM?

M. Lerner, M. Ayalew, S. Lucas, W. Peine, C. Sundaram—USA

**Background:** The primary objective of this study is to determine if training on the Mimic dV-Trainer (MdVT) simulator results in improved ability on the da Vinci<sup>®</sup> surgical system (dVSS) using exercises with inanimate objects.

**Methods:** 12 trainees (MdVT group) and 11 residents (dVSS group) were recruited for the study. Each participant in the MdVT group completed one session of 5 exercises on the dVSS that were scored for timing and accuracy, followed by 4 training sessions on the MdVT, and concluded with a final session on the dVSS in which the initial exercises were repeated. Improvement on the dVSS exercises were compared with dVSS group who completed 4–6 training sessions using the same exercises on the dVSS without any simulator training.

**Results:** Both groups had similar significant improvements in the Letter Board and String Running exercises for both timing and accuracy. The MdVT group demonstrated significant improvement in the Pattern Cutting and Peg Board times. Only the dVSS group significantly improved in the Knot Tying time and the Peg Board accuracy.

**Conclusion:** Training with the MdVT provided similar improvement on 5 exercises performed on the dVSS when compared to training on the dVSS alone. The use of this simulator in resident and student training may help bridge the gap between the safe acquisition of surgical skills and effective performance during live robotic surgery.

#### MP17-05 INITIAL EXPERIENCE WITH ROBOT-ASSISTED NEPHRECTOMIES: COMPARISON WITH LAPAROSCOPIC AND HAND-ASSISTED LAPAROSCOPIC APPROACHES

M. Lerner, S. Popp, T. Gardner, C. Sundaram—USA

**Background:** The purpose of this study is to compare the initial peri-operative outcomes of our robot-assisted laparoscopic nephrectomies with laparoscopic and hand-assisted nephrectomies performed by 2 experienced laparoscopic surgeons.

**Methods:** We retrospectively evaluated all patients who underwent laparoscopic (LN), hand-assisted (HALN) and robot-assisted laparoscopic nephrectomy (RALN) for benign and malignant diseases between August 2006 and December 2008. Data collected included patient age, body mass index, operative times, estimated blood loss, complications, and hospital stay. Radical nephrectomy was performed for renal neoplasms and simple nephrectomy was performed for suspected benign diseases. In addition, average direct costs and total costs were calculated for each laparoscopic approach.

**Results:** 46 patients underwent LN, 20 patients underwent HALN, and 13 patients underwent RALN. The mean operative time was 175, 214, and 179 minutes, respectively. LN, HALN, and RALN groups had similar mean EBL (137, 127, and 219 mL), length of hospital stay (2.8, 3.2, and 4.3 days), and post-operative morphine equivalent analgesic requirements (44 mg, 69 mg, and 43 mg). 3 patients (6%) had complications in the LN group, 2 patients (10%) in the HALN group and 4 patients (30%) in the RALN group.

**Conclusion:** Initial experience with robot assisted laparoscopic nephrectomy provides comparable peri-operative outcomes to laparoscopic and hand-assisted nephrectomy.

#### MP17-06 ROBOT-ASSISTED LAPAROSCOPIC PARTIAL NEPHRECTOMY PRACTICE PATTERNS: THE DA VINCI<sup>™</sup> SURGICAL SYSTEM FACILITATES ADOPTION OF MINIMALLY INVASIVE PARTIAL NEPHRECTOMY

R. Munver, J. Uberoi, J. Yates—United States

**Background:** The utilization of nephron-sparing surgery has been slow in gaining popularity as laparoscopic partial nephrectomy (LPN) is a technically challenging procedure with a steep learning curve. Since the introduction of the da Vinci<sup>™</sup> Surgical System, surgeons are evaluating this technology to assist with LPN. A retrospective review of robot-assisted laparoscopic partial nephrectomy (RALPN) practice patterns at our institution was performed over the past 4 years.

**Methods:** A retrospective review was conducted of minimally invasive partial nephrectomies from 2006–2009 (year-to-date) at our institution. Our medical center has 3 da Vinci<sup>™</sup> Surgical Systems for clinical use (2 standard da Vinci<sup>™</sup> systems, 1 da Vinci<sup>™</sup> S system). The trends for LPN and RALPN were analyzed.

**Results:** Prior to 2007, all partial nephrectomies were performed laparoscopically via a pure or hand-assisted approach by 2 (10%) of 20 urologists at our institution. In 2007 the first RALPNs were performed (n = 4). In 2008, nearly all minimally invasive partial nephrectomies at our institution were performed via a robotic-assisted approach (n = 25). The number of urologists that currently perform RALPN has risen to 7 (35%), including 1 academic urologist and 6 community urologists. In 2009 (year-to-date), 100% of minimally invasive partial nephrectomies (n = 20) have been performed utilizing the da Vinci<sup>™</sup> Surgical System.

**Conclusion:** The introduction of the da Vinci<sup>™</sup> Surgical System has allowed an increasing number of urologists at our institution to perform minimally invasive partial nephrectomy. The acquisition of the da Vinci<sup>™</sup> S system directly correlated with a full transition

to RALPN. This technology may facilitate a quicker adoption of a minimally invasive approach.

### MP17-07 ROBOTIC OR MANUAL GUIDED HIGH INTENSITY FOCUSED ULTRASOUND?

S. Thueroff, A. Neumayr, H. Kiel, C. Chaussy

**Background:** Technological comparison of two serial HIFU devices - Sonablate® (Focus surgery) and Ablatherm® (EDAP-TMS) for the transrectal treatment of prostate cancer by high intensity focused ultrasound (HIFU).

**Methods:** technological and applicative analysis by distributed and published marketing materials of two different providers, as review of published study data.

**Results:** definitions as “HIFU”, “piezoelectric transducer”, “transrectal approach”, “pulsed HIFU application”, “TRUS localisation”, “software guided planning and application software” are similar, which suggests a certain similarity. This similarity could not be proven in this analysis. We isolated more than 50 differences in our technology analysis. Basic technological, applicative and published data show, that the two devices, inclusion and application is significantly different. One device is a robotic (rHIFU: Ablatherm®) the other a manually driven (mHIFU: Sonablate®) device. Despite of all differences, there are still no comparison or prospective studies for the two devices available.

**Conclusion:** In 2009 there are two serial devices using transrectal pulsed HIFU technology for the treatment of prostate cancer. They have multiple differences in construction, security features, software, power settings, application mode, hygiene, indications and published data (basically rHIFU vs mHIFU). Experimental and clinical research as clinical results with one of these devices does not automatically allow conclusions on the efficacy / side effect profile of the other device, because of unpredictable influence of each complex technology and application mode.

### MP17-08 COMPARISON OF ROBOTIC-ASSISTED VERSUS CONVENTIONAL LAPAROSCOPIC PYELOPLASTY FOR PATIENTS WITH URETEROPELVIC JUNCTION OBSTRUCTION: A SINGLE CENTER STUDY BY TWO SURGEONS

R. Leveillee, J. Bracho II, M. Aziz, V. Bird

**Background:** Robotic assisted laparoscopic Pyeloplasty (RALP) is performed to treat ureteropelvic junction obstruction (UPJO). RALP may enhance dissection and reconstruction; however it is unclear whether this impacts results. We compare these two surgical techniques based on perioperative variables and success rates

**Methods:** 144 patients underwent RALP and CLP by two experienced surgeons (A&B). Patient demographic and perioperative variables are collected and analyzed. For statistical analysis p-value <.05 was considered statistically significant.

**Results:** Of 144 patients, 82 underwent RALP (77-A; 5-B) and 62 were CLP (34-A; 15-B). The mean age and BMI was  $38.77 \pm 14.6$ ,  $25.7 \pm 6$  for RALP and  $39.47 \pm 13.9$ ,  $25.33 \pm 4.9$  for CLP (p-value = 0.632 and 0.983). The groups were similar in gender distribution and type of repair [dismembered repair 90.2% of RALP and in 85.5% of CLP patients]. 13 patients (9%) had 2ry UPJO. The total operative time was  $190.5 \pm 64$ , and  $193 \pm 77$  (p-value = .937) respectively. The intraoperative and postoperative complication in RALP and CLP was 1.2%, 6.2% and 1.2%, 3.3% (p-value = 0.877 and 0.361) respectively. The only significant difference between the two groups was the mean suturing time:  $50.47 \pm 33$  and  $69 \pm 51$  (p-value = .063) for RALP and CLP

respectively. Long-term follow up was available for 113 patients showing 94.1% and 94.2% radiographic success rate based upon diuretic scintigraphy for the RALP and CLP respectively.

**Conclusion:** CLP is the benchmark for laparoscopic pyeloplasty having been established several years ago as the gold standard. RALP may save up to 20% of anastomosis time compared to CLP, however, the total operative time shows no significant difference. CLP appears to be equivalent to RALP in terms of perioperative complications and success rates.

### MP17-09 CONTRASTING THE DAVINCI SI AND THE DAVINCI S ROBOT SURGICAL SYSTEMS: WHAT IS NEW?

C. Wong, K. Strom, M. Spaliviero—USA

**Background:** Da Vinci robot surgical systems (Sunnyvale, CA) have revolutionized prostate surgery over the last ten years. Recently, the da Vinci Si model was introduced, having enhanced features compared to its predecessors. We review these enhancements in contrast to features of the da Vinci S system.

**Methods:** Specific features of the da Vinci Si and S surgical systems were reviewed. The novel features of the da Vinci Si model are highlighted.

**Results:** Both the da Vinci Si and S systems offer 3D vision with up to 10x magnification with either 0° or 30° endoscopes; motion scaling with tremor filtration; 7° of freedom, 180° articulation and 540° rotation per robot arm; 5 and 8 mm platforms; multiple instruments and an ergonomic console. Unique features of the da Vinci Si system include the option of two consoles, offering the capability for surgeon and trainee to exchange control of one or more instruments and the endoscope, to facilitate training. As well, the potential for dual surgeon robot-assisted procedures is introduced. The more ergonomic and adjustable console gives ergonomic tailoring for each individual surgeon. The fingertip controls of the console allow seamless master controller repositioning and control of camera focus and zoom, while touchpad controls complete the system integration. The 3D high-definition (1080i per eye) visual system improves vertical digital image resolution.

**Conclusion:** These technological enhancements make the da Vinci Si the first fully integrated 3D high-definition robot surgical system. It has the potential for greater ease of use, improved surgeon training and expansion of robot-assisted surgery.

### MP17-10 COMPLICATIONS OF ROBOT-ASSISTED PARTIAL NEPHRECTOMY: THE LEARNING CURVE FOR ADOPTION OF A NEW TECHNOLOGY

R. Munver, J. Yates, J. Uberoi—United States

**Background:** Laparoscopic partial nephrectomy (LPN) is an underutilized procedure for small enhancing renal masses. The introduction of the da Vinci™ Surgical System, and the rapid growth of robotic urological surgery, has led to an interest in evaluating this technology to assist with LPN. We reviewed our experience with robot-assisted laparoscopic partial nephrectomy (RALPN) and report on our complications and challenges with adoption of this procedure.

**Methods:** A retrospective review was conducted of 40 consecutive robot-assisted nephron-sparing procedures for tumors  $\leq 4$  cm. Procedures were performed by surgeons with extensive experience in performing laparoscopic and robotic renal surgery. The intraoperative complications for RALPN were recorded and evaluated based on video review of the procedures.

**Results:** Of the 40 procedures, 9 (22.5%) were associated with intraoperative complications. Complications consisted of hemorrhage during tumor resection in 4 (44%), inadvertent tumor violation in 2 (22%), renal vein injury in 1 (11%), and conversion to a hybrid laparoscopic-robotic approach due to robotic arm/instrument collisions in 2 (22%). All procedures were successfully completed via a minimally invasive approach without open conversion. The mean tumor size was 2.1 cm and all final pathological margins were negative.

**Conclusion:** The introduction of the da Vinci™ Surgical System is allowing an increasing number of urologists to perform minimally invasive partial nephrectomy. Advances in robotic technology such as the second and third generation da Vinci™ systems, as well as newer robotic instrumentation, may facilitate this transition. However the learning curve and potential complications warrants judicious adoption of robot-assisted laparoscopic partial nephrectomy.

### MP17-11 ROBOTIC PARTIAL NEPHRECTOMY: CUMULATIVE SINGLE CENTER EXPERIENCE

W. White, G. Haber, R. Goel, S. Cruzet, J. Kaouk

**Background:** We present perioperative outcomes in an observational cohort of patients who underwent Robotic Partial Nephrectomy (RPNx) at a single academic institution.

**Methods:** A prospective study was performed to evaluate operative outcomes following RPNx. Salient demographic and radiographic data were obtained. Operative data including estimated blood loss (EBL), operative time, and warm ischemia time (WIT), where applicable, were recorded. Pathology was reviewed and classified according to the AJCC staging system. Patients were followed post-operatively for evidence of immediate and delayed complications. Renal functional outcomes were obtained and estimated creatinine clearance calculated using the MDRD formula. Statistical analysis was performed

**Results:** Between June 2006 and June 2009, a total of 72 patients underwent right (n = 35) or left (n = 37) RPNx for radiographic evidence of an enhancing renal mass. Mean age of the cohort was 64 years. Mean BMI was 27.9 kg/m<sup>2</sup>. Mean operative time was 203 minutes. Mean EBL was 325 mL. Ten patients underwent RPNx without hilar clamping. The remaining 62 patients underwent hilar clamping with a mean WIT of 23 minutes. Mean pathologic tumor size was 2.7 cm (range 1–7.5 cm). Pathology confirmed renal cell carcinoma in 63 patients, angiomyolipoma in 4 patients, and oncocytoma in 5 patients. All margins were negative. Complications occurred in 6 patients. Three patients required blood transfusions, 1 patient developed a renal fluid collection, and 2 patients required post-operative angioembolization.

**Conclusion:** Robotic Partial Nephrectomy offers excellent perioperative outcomes with promising short-term oncologic control. Prospective, comparative study to conventional laparoscopic partial nephrectomy is needed.

### MP17-12 EARLY RESULTS OF ROBOTIC LYMPHADENECTOMY FOR RENAL CELL CARCINOMA: INITIAL PATIENT SERIES

R. Abaza—USA

**Background:** Laparoscopic nephrectomy for renal cell carcinoma (RCC) has gained acceptance, but lymphadenectomy (LAD) is not uniformly performed during open or laparoscopic nephrectomy. With the advent of targeted medical therapy for metastatic RCC,

LAD for identification of micrometastatic disease may merit reconsideration. The first reported series of robotic LAD for RCC with nodal yield and outcomes is presented.

**Methods:** Robotic retroperitoneal LAD was performed in 18 patients, sixteen who underwent radical and two who underwent partial nephrectomy. For right-sided renal tumors, the LAD included paracaval, retrocaval, and interaortocaval nodes, and left-sided tumors included interaortocaval and paraaortic nodes.

**Results:** Mean and median tumor size was 6.5 cm and 5.2 cm, respectively (range 2.2–18). Seven tumors were advanced with four T3a tumors and three T3b tumors with vena caval tumor thrombi. Mean operative time was 208 min (120–360 min). A mean of 11.0 lymph nodes was obtained (4–24 nodes) with 1/18 patients (6%) found to have metastasis. Mean estimated blood loss was 76 cc (10–200 cc). No patient required transfusion or intravenous narcotics. Discharge was postop day 1 in 89% and day two in 11%. Complications included one patient who developed an asymptomatic retroperitoneal lymphocele and a small bowel injury from an insulation defect in the cautery scissors tip cover repaired robotically.

**Conclusion:** Robotic LAD for RCC is feasible with reasonable nodal yields and an acceptable complication profile, but the rate of nodal positivity identified was low. Further study is needed to determine the role and benefit of robotic LAD for RCC.

### MP17-13 INITIAL SERIES OF ROBOTIC NEPHRECTOMY WITH VENA CAVAL TUMOR THROMBECTOMY

R. Abaza—USA

**Background:** Laparoscopy is increasingly being applied to urologic conditions but has yet to be applied for renal cell carcinoma (RCC) involving the vena cava (IVC). Robotic technology may facilitate such complex procedures. The first cases of robotic nephrectomy with caval tumor thrombectomy are presented.

**Methods:** Three male patients presented with right renal masses consistent with RCC. Robotic nephrectomy with IVC thrombectomy and retroperitoneal lymphadenectomy was performed in all three. The IVC and left renal vein were dissected circumferentially as a precaution after which the IVC was clamped with a curved laparoscopic Satinsky clamp tangentially across its lumen excluding the tumor thrombi. The IVC was then incised and the tumor thrombi delivered intact after which the IVC was closed with permanent suture.

**Results:** All tumors were RCC on pathology with two having sarcomatoid features. Thrombi protruded 1 cm, 2 cm and 4 cm beyond the renal vein and into the infrahepatic IVC. Mean estimated blood loss was 100 cc (range 50 cc–150 cc). Mean operative time from incision to dressing was 305 min (range, 266–360 min). Mean yield of the lymphadenectomy was 14 nodes (range 9–24) with one patient found to have a single node with metastatic disease. Two patients were discharged on postoperative day one and the other patient on day two. There were no complications, transfusions, or readmissions.

**Conclusion:** Robotic surgery was applied safely for RCC with IVC tumor thrombus. Further experience is necessary to validate this promising application and to determine whether more extensive thrombi can be treated in minimally-invasive fashion.

### MP17-14 ROBOT-ASSISTED PARTIAL NEPHRECTOMY FOR RENAL CELL CARCINOMA: COMPARISON OF SURGICAL OUTCOME WITH LAPAROSCOPIC PARTIAL NEPHRECTOMY

T. Kang, C. Song, J. Hong, H. Ahn—Korea

**Background:** To investigate the efficacy of robot-assisted partial nephrectomy (RAPN) compared to standard laparoscopic partial nephrectomy (LPN) in the management of small renal masses.

**Methods:** We analyzed surgical outcome after RAPN (n = 50) and compared it with LPN (n = 54) performed electively for small renal mass between March, 2008 and June 2009. Operative variables, perioperative complications and the functional outcomes were investigated for comparison. Glomerular filtration rate (GFR) was estimated from the diethylenepentaacetic acid renal scan taken before and at 3 months postoperatively.

**Results:** Renal cell carcinoma was diagnosed in 49 (98% and 90.7% of RAPN and LPN respectively) patients in each group and surgical margin was negative in all cases. In RAPN group, mean tumor size was significantly larger (2.64 vs. 1.81 cm,  $p < 0.0001$ ) and more tumors were intraparenchymal than exophytic (76% vs. 44.4%,  $p = 0.001$ ), while laterality (right sided tumors 58% vs. 57.4%) and polar location (58% vs. 55.6%) were similar. Total operative time was longer in RAPN group (194.7 vs. 152.0 minutes,  $p < 0.001$ ) but the warm ischemia time (27.3 vs. 24.3,  $p = 0.073$ ) and incidence of pelvocalyceal system repair were similar (46% vs. 38.9%). Overall complication rates (4.0% vs. 3.7%) and transfusion rates (4.0% and 1.9%) were also similar between the groups. Reduction in GFR (10.2 vs. 10.6 ml/min/m<sup>2</sup>) and the percent GFR (22.1% vs. 21.6%) were also similar.

**Conclusion:** Compared to standard laparoscopy, robot assistance enhances partial nephrectomy procedure especially in larger or endophytic tumors of the kidney with comparable renal functional preservation and morbidity.

### MP17-15 COMPARISON OF SURGICAL OUTCOMES OF OPEN, LAPAROSCOPIC, AND ROBOTIC PARTIAL NEPHRECTOMY

U. Boylu, M. Pinsky, A. Tracey, M. Hopkins, R. Thomas, B. Lee—USA

**Background:** To compare the surgical outcomes of open, laparoscopic, and robotic partial nephrectomy in a contemporary series in terms of ischemia time, renal function, and final pathology.

**Methods:** After obtaining Institutional Review Board approval, a retrospective chart review was performed for a total of 144 patients who underwent partial nephrectomy at the Tulane Medical Center between 1999 and 2008 (39 open, 90 laparoscopic, and 15 robotic). Age, sex, race, tumor side, tumor size, operative time, blood loss, ischemia time, pathologic grade and stage, and hospital stay were compared between open, laparoscopic, and robotic approaches.

**Results:** Open, laparoscopic, and robotic groups were comparable regarding age, sex, and tumor side. (Table 1) Tumor size was significantly higher in open group compared to laparoscopic and robotic groups ( $p = 0.03$  and  $p = 0.04$ , respectively). Operative time and blood loss were significantly higher in open group compared to laparoscopic and robotic groups. Ischemia time in robotic group (27.6 min) was significantly lower than open and laparoscopic groups. The difference in length of stay did not reach a statistically significant level among groups. There was one conversion to open surgery in laparoscopic group due to excessive bleeding from the kidney. Surgical margins were positive in 17 patients in laparoscopic group, 1 in open group, and 1 in robotic group ( $p = 0.05$ ). In follow-up, (range 6–96 months), no patient developed recurrence. Final pathology demonstrated renal cell

carcinoma in 135 (94%), cystic disease in 5 (3.4%), and angiomyolipoma in 4 (2.6%). Neither the histologic type nor the nuclear grade distribution between open, laparoscopic, and robotic groups was significant ( $p = 0.36$  and  $p = 0.29$ ). Open (n=39) Laparoscopic (n=90) Robotic (n=15) P Age  $57 \pm 1.8$   $57.8 \pm 1.3$   $60.3 \pm 2.7$  0.65 Sex (F/M) 13/26 40/50 5/10 0.42 Tumor side (R/L) 20/19 35/55 7/8 0.46 Tumor size  $4.2 \pm 0.6$   $2.8 \pm 0.2$   $2.8 \pm 0.3$  0.04 Operative time  $218.8 \pm 15.1$   $167.7 \pm 9.2$   $171.5 \pm 10.2$  0.01 Blood loss  $981.4 \pm 233.8$   $276.3 \pm 39.9$   $276 \pm 87.6$  0.01 Ischemia time  $35.7 \pm 3.0$   $38.1 \pm 1.5$   $27.6 \pm 4.4$  0.01 Length of stay  $4.6 \pm 0.4$   $3.8 \pm 0.4$   $2.8 \pm 0.3$  0.13 Positive Surgical Margin 1 (2.6%) 17 (18.9%) 1 (6.7%) 0.05 Table 1 Comparison of open, laparoscopic, and robotic partial nephrectomy demographics and outcomes.

**Conclusion:** Robotic partial nephrectomy has similar surgical outcomes compared to laparoscopic partial nephrectomy. Further studies will demonstrate its long-term efficacy.

### MP17-16 COMPARISON OF THE RENAL FUNCTIONS AFTER OPEN, LAPAROSCOPIC, AND ROBOTIC PARTIAL NEPHRECTOMY

U. Boylu, M. Pinsky, M. Hopkins, A. Tracey, B. Lee—USA

**Background:** The purpose of the study was to assess the intermediate term follow-up of surgical approach, such as open, laparoscopic, and robotic, on renal function in patients undergoing partial nephrectomy.

**Methods:** Between 1999 and 2009, a total 144 patients underwent robotic partial nephrectomy with open, laparoscopic, or robotic approach. Of these, 124 patients with solid renal masses (renal cell carcinoma, oncocytoma, angiomyolipoma) were included in the study. Estimated GFR was calculated using the standard MDRD formula. Differential functions were measured with MAG3 renal scan. Preoperative and 3 month postoperative eGFR and differential functions were compared between open, laparoscopic, and robotic groups. Mean follow-up time was 34 months (range: 6–96 months).

**Results:** The average tumor size was  $4.3 \pm 3.6$  cm in open group (n = 34),  $2.8 \pm 1.4$  cm in laparoscopy group (n = 76), and  $2.8 \pm 1.3$  cm in robotic group (n = 14) ( $p = 0.003$ ). Mean decrease in eGFR was 11.8 ml/min/1.73 m<sup>2</sup> in open group, 12.9 ml/min/1.73 m<sup>2</sup> in laparoscopy group, and 14.5 ml/min/1.73 m<sup>2</sup> in robotic group. The difference between groups was insignificant ( $p = 0.73$ ). Mean decrease in differential function was 5.4% in open group, 5.5% in laparoscopy group, and 6.4% in robotic group. There was no significant difference among groups ( $p = 0.64$ ).

**Conclusion:** Decrease in renal function following partial nephrectomy is not affected by surgical approach. Open, laparoscopic, and robotic partial nephrectomy results in similar renal functional outcomes.

### MP17-17 MARGIN ANALYSIS OF ROBOT ASSISTED PARTIAL NEPHRECTOMY AND LAPAROSCOPIC PARTIAL NEPHRECTOMY

A. Wang, S. Bhayani—USA

**Background:** Robot assisted partial nephrectomy has emerged as a minimally invasive technique, as robotic assistance facilitates complex renal reconstruction. We hypothesize that the margin size, as well as the variance of margin size, would be reduced in robot assisted partial nephrectomy (RAPN) as compared to standard

laparoscopic partial nephrectomy (LPN), while maintaining equivalence in positive surgical margin rates.

**Methods:** We compared 95 patients of a single surgeon, of whom 54 patients underwent RPN and 41 patients underwent LPN for extirpation of malignancy. Tumors known to be benign preoperatively were excluded from analysis, as these were planned enucleations. Clinicopathological parameters were evaluated.

**Results:** There were no differences in patient demographics. Mean age, BMI, and American Society of Anesthesiologist (ASA) scores were not significant between the two groups. Positive surgical margin rate, malignancy rate, and pathological tumor size were equal between the groups. The mean negative margin size was 5.1 mm for LPN and 2.1 mm for RPN,  $p = 0.0001$ ; RAPN having a smaller overall margin. The standard deviation of the margin depth was significantly smaller for RAPN, with only a 2.0 mm deviation for RAPN (variance 4.2) and a 4.9 mm deviation for LPN (variance 24.5),  $p < 0.0001$ .

**Conclusion:** Robotic assistance in partial nephrectomy appears to be associated with a more accurate dissection compared with LPN, resulting in smaller tumor margins while having equal rates of positive surgical margins. The variance of margin size is also reduced significantly.

### MP17-18 COMPARISON OF LAPAROSCOPIC VERSUS ROBOTIC ASSISTED PARTIAL NEPHRECTOMY: ONE SURGEON'S EARLY EXPERIENCE

J. Mandeville, J. Delong, A. Moizadeh—USA

**Background:** Partial nephrectomy is an effective surgical treatment for small renal masses. We compare a single surgeon's experience with consecutive laparoscopic and robotic partial nephrectomy to assess potential differences of one technique over the other.

**Methods:** A retrospective review was performed comparing 15 consecutive patients undergoing laparoscopic partial nephrectomy to the subsequent 12 patients undergoing robotic assisted partial nephrectomy ( $n = 12$ ) for small renal tumors by one surgeon. All patients had normal contralateral kidney appearance on cross sectional imaging. A similar transperitoneal technique was employed for both cohorts. After hilar control the tumor was excised and suture repair performed with or without Surgicel bolsters and Flo-seal. A 4-arm technique was used for the robotic cases using the da-Vinci surgical system. Patient demographics, tumor characteristics, intraoperative and postoperative data including tumor size, warm ischemia time, estimated blood loss (EBL) and renal function were compared using Student t-test or Wilcoxon rank-sum as appropriate.

**Results:** All cases were completed laparoscopically or with robotic assistance without conversion to open surgery. Demographic data including age, body mass index (BMI), tumor size and EBL were not statistically significantly different. Warm ischemia time was shorter in the robotic group: 28.5 minutes versus 40 minutes for the laparoscopic group ( $p = 0.001$ ). Operative time was longer in the robotic group: 253 versus 346 minutes ( $p < 0.0001$ ). Mean hospital stay and postoperative complication rates were not statistically different. Two (13%) of patients in the laparoscopic group required conversion of partial nephrectomy to radical nephrectomy while none did in the robotic group. Renal function was preserved in both groups. Final pathology revealed negative margins in all cases.

**Conclusion:** Robotic partial nephrectomy resulted in decreased warm ischemia time as compared to the conventional laparoscopic approach. Total operating time was, however, increased in the robotic group.

### MP17-19 CLINICAL PATHWAY FOR DISCHARGE ON POSTOPERATIVE DAY ONE AFTER ROBOTIC PARTIAL NEPHRECTOMY

R. Abaza—USA

**Background:** One potential benefit of minimally-invasive surgery is reduced length of hospitalization, but regardless of surgical approach, the complexity of a procedure and potential complications can limit early discharge. We present a clinical pathway targeting discharge on the first postoperative day (POD) after robotic partial nephrectomy and our early outcomes.

**Methods:** A total of four ports is used with specimen extraction typically at the periumbilical port and bupivacaine injected at all four incisions. Patients ambulate and take clear liquids the night of surgery. No intravenous narcotics are given. No drain or stent is used. The Foley catheter is removed and regular diet started the morning after surgery with discharge the same day.

**Results:** A total of 26 consecutive robotic partial nephrectomy patients were placed on the pathway. Mean patient age was 56 yrs (22–82 yrs), mean BMI 31.2 kg/m<sup>2</sup> (20–41 kg/m<sup>2</sup>), and mean tumor size 2.7 cm (1–5 cm) with one solitary kidney. Mean OR time was 203 min and warm ischemia time 16.7 min (9.5–28.5 min). Twenty-four of 26 patients (92%) were discharged on POD#1. Two were discharged on POD#3 due to nonspecific bowel complaints in one and exacerbation of pulmonary disease in another for a mean length of stay of 1.15 days. No patient experienced urine leak, delayed bleeding, or required transfusion. No patient was readmitted or had an unscheduled clinic visit within 30 days of surgery except one patient treated at an outside facility for fever and pneumonia on POD#4.

**Conclusion:** Discharge on POD#1 is feasible in most patients after robotic partial nephrectomy without an increase in complications.

### MP17-20 NON-CLAMPING VERSUS RENAL HILAR CLAMPING ROBOTIC AND LAPAROSCOPIC PARTIAL NEPHRECTOMY

S. Parekattil, Sijo J., H. Atalah, L. Su

**Background:** Minimizing warm ischemia is one of the goals during robotic and laparoscopic partial nephrectomy (RLPN) in efforts to minimize renal injury. This study compares the outcomes of standard clamping (SC) to a non-clamping (NC) technique of the renal hilum during RLPN.

**Methods:** 45 RLPN cases from 3/2007 to 6/2009 that either underwent SC (23) or NC (22) were reviewed. For NC, Habib 4×<sup>TM</sup> (Angiodynamics, NY) was utilized to create a coagulation zone 1 cm beyond the tumor margin prior to excision.

**Results:** Mean age (55 vs. 57,  $p = 0.6$ ), tumor size (2.2 vs. 2.3 cm,  $p = 0.8$ ), length of stay (3.1 vs. 3.0 days,  $p = 0.9$ ), creatinine at discharge (1.03 vs. 1.02 mg/dl,  $p = 0.9$ ), preoperative hematocrit (41% vs. 41%,  $p = 0.9$ ) and estimated blood loss (133 cc vs. 160 mL,  $p = 0.5$ ) were similar between the SC and NC groups. One positive margin was noted in SC group. No tumor recurrences/metastases occurred (mean follow-up 11 months). Mean warm ischemia in SC was 34 min. Mean operative duration was significantly decreased in NC (188 min) vs. SC (231 min),  $p = 0.005$ .

Mean hematocrit at discharge was significantly higher in NC (37%) compared to SC (34%),  $p=0.03$ . Five complications occurred in SC with 4 in NC (one with delayed renal function).

**Conclusion:** The NC RLPN technique appears to provide comparable oncologic and functional outcomes to SC technique.

Although there was no clinically significant advantage in preserving early post-operative renal function with the NC technique, this technique does appear to decrease operative time, improve postoperative hematocrit and warrants further study.

## MP18: MISCELLANEOUS

### MP18-01 INHIBITORY EFFECT OF TOTAL EXTRACT OF SAFFRON ON CELL LINE OF ADENOCARCINOMA OF THE KIDNEY

H. Ahmadnia, J. Tavakol Afshari, A. Yarmohamadi, A. Malaek Ghochani, A. Borok—Iran

**Background:** During performing many observations, researchers have been shown high cytotoxic effects of herbal substances on tumoral cells. Saffron usually used as a spice for flavoring, coloring, food and also as a fragrant material. In recent years antitumoral effects of saffron extract have been proved both in vitro and in vivo cultures.

**Methods:** In this study, cytotoxic effects of saffron extract had been evaluated on malignant cells of human renal adenocarcinoma (ACHN) via qualitative (morphologic) and quantitative (MTT assay) methods in cellular culture medium and had been compared with its effects on normal cells (L929). In morphologic method we observed and photographed the effects of different concentration of saffron extract (0, 100, 200, 400, 800, 1600 and 3200  $\mu\text{g/ml}$ ) in cellular cultures, during 72 hours and compared them with control specimens. In MTT assay both cellular classes had been examined by light absorption evaluation, in different concentration of saffron extract (0, 100, 200, 400, 800, 1600 and 3200  $\mu\text{g/ml}$ ) and in triple times (24, 48 and 72 hours), and then results had been collected for quantitative comparing of cellular growth.

**Results:** In low concentrations (lower than 200  $\mu\text{g/ml}$ ), morphologic variations had been shown cellular growth in L929 and holding cellular growth in ACHN. But in more than 200  $\mu\text{g/ml}$  concentration, both L929 and ACHN had not any cellular growth and in concentrations more than 800  $\mu\text{g/ml}$ , cytotoxic effects exhibit for both of them.

**Conclusion:** No antitumoral effect of saffron extract had been seen on human renal adenocarcinoma malignant cells.

### MP18-02 A PROSPECTIVE STUDY OF THE EFFICACY AND TOLERABILITY OF AMBULATORY HOLMIUM LASER ABLATION OF RECURRENT NON-MUSCLE-INVASIVE TRANSITIONAL CELL CARCINOMA WITH FLEXIBLE CYSTOSCOPE UNDER LOCAL ANAESTHESIA

D. Macdonald, R. Jones, H. Syed—United Kingdom

**Background:** Introduction Treatment of low volume recurrence of non-muscle invasive bladder cancer is costly in terms of patients quality of life and healthcare resource. We prospectively assessed the efficacy and tolerability of holmium laser ablation of recurrent tumour under local anaesthesia.

**Methods:** Between September 2006 and February 2009 consecutive patients with previously documented non-muscle invasive TCC bladder had ablation of recurrence using a 16F flexible cystoscope

and a 30 W Holmium laser. High grade disease was treated only if general or regional anaesthesia was contraindicated. Intraurethral 1% lignocaine gel was the sole analgesia. All patients received 500 mg ciprofloxacin. Ablation efficacy was assessed at 3 months with flexible cystoscopy. Tolerability was assessed at the time of procedure with a visual analogue pain score and questionnaire. Early complications were assessed with telephone follow-up.

**Results:** 191 tumours were ablated in 114 patients. Mean tumour size was 7.8 mm (range 1.5–20). Mean patient age was 73 years (range 47–100). Original histology (where documented) was G1Ta, G2Ta, G1T1, G2T1 and G3T1 in 54, 23, 4, 14, and 6 patients respectively. Repeat flexible cystoscopy at 3 months showed recurrent tumour at the ablation site in 10 patients (9%). Recurrent tumour was seen at sites disparate from the original ablation in 23 patients (20%). All patients were satisfied with the procedure and would be prepared to undergo the procedure again. Mean pain score on visual analogue scale was 1.1/10 (range 0–6). Dysuria, haematuria frequency and UTI were reported by 6, 4, 2 and 1 patients respectively.

**Conclusion:** Holmium laser ablation of recurrent bladder tumour under local anaesthesia has a short term efficacy of 91%. It is well tolerated with minimal side effects.

### MP18-03 BILATERAL SINGLE-STAGE LAPAROSCOPIC ADRENALECTOMY IN CUSHING'S SYNDROME-SAFE, EFFECTIVE AND CURATIVE

S. Bhat, G. Kumar—India

**Background:** In Cushing's disease and syndrome, surgical morbidity and mortality rates are high when an open technique is used. Simultaneous bilateral laparoscopic Adrenalectomy (LA) offers an excellent treatment option with reduced morbidity in these patients.

**Methods:** We retrospectively analysed charts of 18 patients who underwent Adrenalectomy for Cushing's syndrome over a period of 6 yrs from 2003 to 2009, 15 patients underwent bilateral simultaneous LA for Cushing's syndrome. Indications, approach, per operative and post operative complications were analyzed.

**Results:** Six patients had Cushing's syndrome after failed pituitary surgery, 4 had ectopic ACTH dependent syndrome and 5 had bilateral macronodular hyperplasia. Majority of the procedure were performed by lateral transabdominal approach (LTA) although in four patients a retroperitoneal endoscopic adrenalectomy (REA) was done on the right side. Two patients underwent emergency adrenalectomy due to severe debilitating muscle weakness due to hypercortisolism. Mean operative time  $\pm$  (standard deviation S.D) was 172.45  $\pm$  (72.2) min with a mean blood loss  $\pm$  (S.D) of 64.5  $\pm$  (41.14) ml. Patients were fit for discharge on the fourth

postoperative day from surgical aspect. Complication rate for the procedure was 28.5% with 2 patients developing wound infections, one had port site hernia and one developed pleural effusion. There was no mortality.

**Conclusion:** Simultaneous bilateral LA for cushingoid patients is the current “gold standard” in this subset of patients who are immunocompromised and/or are predisposed to delayed wound healing.

#### **MP18-04 ENHANCED “TUMOR PERFUSION” DOES NOT TRANSLATE INTO INCREASED FREEZE TIME DURING PERCUTANEOUS CT-GUIDED RENAL CRYOTHERAPY**

P. Sountoulides, M. Louie, D. Pick, S. Said, E. Mcdougall, R. Clayman—CA

**Background:** Cryoablation, whether laparoscopic or CT/MRI guided represents a minimally invasive alternative for the management of small renal masses. Currently in our Department more than half of the cases of cryoablation are being performed percutaneously under CT guidance. The study aims at identifying any correlation between tumor parameters, number of cryoprobes used and freeze times.

**Methods:** The charts of 16 patients treated for small renal masses by percutaneous cryoablation since June 2008 were retrospectively reviewed. Cryoablation was performed with the Galil system. The volume and the relative perfusion of the tumor (Hounsfield units of tumor relative to H.U of renal cortex and renal artery) were estimated by using the preoperative CT scans (arterial phase). The time to reach  $-20^{\circ}\text{C}$  in each freeze cycle was also recorded. We attempted to correlate the time to reach a  $-20^{\circ}\text{C}$  reading on the multiple temperature sensor (MTS) with the “perfusion rates” of the tumor, the number of probes used during cryoablation and the volume of the tumor.

**Results:** There was no statistically significant correlation between the time to reach  $-20^{\circ}\text{C}$  on the MTS probe and tumor volume ( $p < 0.69$ ) and “tumor perfusion” ( $p < 0.81$ ). On the other hand there was a statistically significant correlation between tumor volume and number of cryoprobes used ( $p < 0.01$ ).

**Conclusion:** The time to reach a minimum of  $-20^{\circ}\text{C}$  during percutaneous renal cryoablation cannot be predicted based on estimated “tumor perfusion” from a standard CT angiogram.

#### **MP18-05 SECONDARY VESICAL AMYLOIDOSIS—RARE CAUSE OF MASSIVE HEMATURIA**

S. Pereira, D. Martinho, M. Melo, A. Romão, T. Leitão, H. Correia—Portugal

**Background:** Bladder involvement by secondary amyloidosis is rare, with less than 25 reported cases, mainly associated with rheumatoid arthritis. Unlike the benign primary amyloidosis, secondary amyloidosis has a 50 to 60% mortality rate due to massive hematuria or multiorgan failure. There are no treatment guidelines, though there have been reports of attempts with dimethyl sulfoxide, formaldehyde and cyclophosphamide.

**Methods:** A 51 year old female with rheumatoid arthritis was admitted to the ER with massive hematuria. She presented severe anemia, massive bladder clot, bilateral hydronephrosis, renal insufficiency and clotting disorder. After inicial stabilization, a cystoscopy with random biopsies was performed. No lesions were visualized, but pathology revealed secondary amyloidosis (AA-type amyloid). The patient was successfully treated with vesical instillation of formaldehyde.

**Results:** There were no subsequent episodes of hematuria, but the patient passed away 2 weeks after discharge (sudden death). The autopsy revealed dilated cardiac chambers.

**Conclusion:** Although not confirmed, liver, renal and cardiac amyloid deposits could explain the clotting disorder, renal insufficiency and sudden death. Further studies are needed in order to optimize treatment strategies.

#### **MP18-06 MEN II SYNDROME: A DANGEROUS COMBINATION OF RARE DISEASES**

G. Kumar, S. Bhat—India

**Background:** Multiple endocrine neoplasia Type II syndrome includes pheochromocytoma, medullary thyroid cancer and either parathyroid tumour (MENIIa) or neuroma (MEN IIB). We report 4 cases of phaeochromocytoma who were diagnosed to have MEN II syndrome.

**Methods:** During the period of Jan-2001–May 2009, 121 patients underwent adrenalectomies amongst which four patients had MEN II syndrome. Demographics, clinical presentation, radiological and metabolic workup, treatment given and follow up were analysed retrospectively.

**Results:** Median age on presentation was 40 (37–68) with equal distribution across both sexes. Three had MEN IIa and one had MEN IIB syndrome. All patients had family history of thyroid malignancy. One kindred had underwent prophylactic thyroidectomy at 12 years. All patients had clinical features of phaeochromocytoma. 24 hr urinary VMA and metanephrines were normal. The mean radiological size in CECT was 6.5 cms. All underwent elective bilateral adrenalectomy followed by total thyroidectomy with mean interval of 5 days except for one who had opposite adrenalectomy after 8 years. Pathologically all the adrenals were benign and one patient with type II-B had cystic phaeochromocytoma. All were followed up for a period of 2 years and two patients had nodal recurrence in the neck after thyroidectomy.

**Conclusion:** Pheochromocytoma can be a part of MEN II syndrome which is a dangerous combination of rare diseases. Early diagnosis, proper treatment, screening in the family, follow up of endocrinology and oncology problems are important.

#### **MP18-07 LOCAL ANAESTHETIC HOLMIUM LASER ABLATION OF SUPERFICIAL TRANSITIONAL CELL TUMOUR RECURRENCES IN PATIENTS WITH SIGNIFICANT COMORBIDITY**

D. Wilby, G. Zisengwe, N. Smith, K. Thomas—UK

**Background:** With an aging population the problem presented by small transitional cell tumour recurrences in the elderly or unfit becomes increasingly pertinent. We report our early experience of laser ablation under local anaesthetic.

**Methods:** Over 12 months, 19 patients with superficial recurrences of TCC bladder considered to have significant co-morbidity were treated with holmium laser ablation performed via a flexible cystoscope under local anaesthetic (lignocaine gel) as a day case. Median age 77 years, All were ASA grade 4. Previous histology ranged from G1pTa to G3pT1.

**Results:** 12 patients have had 3 month check cystoscopy; 7 remained clear of tumour (58%), 5 had recurrences. Two patients experienced complications: one urinary tract infection, one patient on warfarin developed significant haematuria. All patients tolerated the procedure with pain scores of 0–1 on a visual analogue scale and 18/19 choosing to have the procedure again.

**Conclusion:** Given the tolerability of this treatment and the acceptable recurrence rates we intend to continue using and monitoring this technique in patients with significant co-morbidity. The procedure is now conducted in an out-patient clinic and we have started to use Hexvix for photodynamic diagnosis using a 'blue light' flexible cystoscope to try and reduce recurrences.

#### MP18-08 PRELIMINARY INVESTIGATIONS WITH IRREVERSIBLE ELECTROPORATION IN IN-VIVO PORCINE KIDNEYS FOR RENAL TUMOR TREATMENT

R. Leveillee, N. Salas, C. Moore, M. Jorda, M. Sierra, J. Shields—33136

**Background:** Irreversible Electroporation (IRE) is a minimally-invasive treatment modality that uses an electric field induced by high voltage direct current pulses to induce nanopores in the cell membranes and ultimately cell death. The purpose of this investigation was to assess the feasibility of IRE for renal tissue treatment in-vivo.

**Methods:** Eleven Yorkshire pigs ranging between 40–56 kg were treated with the Nanoknife™ IRE system under general anesthesia with muscular blockade (pancuronium) through a midline incision and survived 0 to 18 days. After euthanasia, the kidneys were harvested and evaluated grossly and histologically. The voltage to inter-probe distance ratio at cortex and medulla and survival times were varied for two monopolar probes. The voltage was varied for one bipolar probe.

**Results:** Congestion, hemorrhage, and cell death were observed within and up to 5 mm outside of the grossly observed lesion. Dystrophic calcification was observed within 11 to 18 days. Lesion volumes were indistinct between cortex ( $0.06\text{--}2.28\text{ cm}^3$  @ 0 days;  $1.10\text{--}1.65\text{ cm}^3$  @ 11 days) and medulla ( $0.37\text{--}1.66\text{ cm}^3$  @ 0 days;  $1.65\text{--}3.14\text{ cm}^3$  @ 11 days). Lesion volumes decreased from one ( $6.3 \pm 2.0\text{ cm}^3$ ) to ten ( $2.0 \pm 1.2\text{ cm}^3$ ) days. Pulse disruptions occurred with bipolar probes resulting in inconsistent lesion volumes.

**Conclusion:** IRE is a novel ablation modality that can create lesions of various sizes in renal tissue under a variety of parameters. Cell death is achieved within 18 days with preservation of gross architecture. Continued investigation is warranted to achieve optimal treatment parameters in the kidney.

#### MP18-09 COMPARISON OF THE ROBOTIC CAMERA HOLDER FREEHAND® TO THE CONVENTIONAL IMAGING AT THE NERVE SPARING ENDOSCOPIC EXTRAPERITONEAL RADICAL PROSTATECTOMY (NSEERPE)—A PROSPECTIVE STUDY WITH 50 CASES

J. Stolzenburg, T. Franz, K. Turner, M. Do, P. Kallidonis, E. Liatsikos

**Background:** With about 450 operations per year, endoscopic extraperitoneal radical prostatectomy (EERPE) is the standard surgical therapy of the organ-confined prostate cancer in our centres. Erroneous camera movements and communication problems with the camera holder are troublesome during this demanding procedure. Ideally the surgeon should operate the camera himself, but feasibility studies are poorly reported.

**Methods:** We compared the use of a robotic camera holder (Freehand®, Prosurgics, Bracknell, United Kingdom), controlled by head movements of the surgeon, with a human camera holder in a series of EERPE (n = 25 each group). The total operative time, time for each surgical step, number of camera movements, number of movement errors, number of times the lens was cleaned, blood

loss, integrity of the anastomosis (cystogram) and margin status were compared by Students t-test.

**Results:** The number of camera movements (136 versus 159, p = 0.016), movement errors (3.8 vs. 7.0, p = 0.002) and lens cleaning events (3.35 vs. 6.35; p = 0.003) were significantly lower in the Freehand® group, than the human camera holder group. There were no significant differences in the operative time (86 min52 vs. 83 min02s, p = 0.365), blood loss (237 ml vs. 234 ml, p = 0.953), positive margins (both 5%) or incidence of urine leak (1 patient in each group).

**Conclusion:** Use of the Freehand® robotic camera holder allows the surgeon to control the laparoscope and reduces camera errors. The laparoscopic picture was clear and stable. The device is safe to use and does not prolong the operative time or adversely affect complication rates.

#### MP18-10 BIOIMPEDANCE BODY COMPOSITION ANALYSIS PREDICTS HISTOPATHOLOGY OF SMALL RENAL CORTICAL NEOPLASMS

J. Rosales Araujo, J. Moreno, G. Haramis, Z. Okhunov, K. Badani, J. Landman—USA

**Background:** Mounting evidence has demonstrated that obesity correlates with oncologic parameters. To date, body mass index (BMI) has been used to characterize patient body composition. BMI remains a crude and insensitive metric. Bioimpedance spectroscopy (BIS) is a relatively new technology that can more precisely quantify body composition (BC). We prospectively evaluated pre-operative bioimpedance BC in patients undergoing surgery for renal cortical neoplasm (RCN).

**Methods:** With IRB approval and patient consent we prospectively evaluated patients undergoing minimally invasive renal procedures for RCN with an Imp SFB7 device. Between December 2008 to June 2009, 45 patients were enrolled. A preoperative bioimpedance BC analysis was performed in all patients. Fat mass (FM), percentage fat mass (PFM), fat free mass (FFM) and percentage fat free mass (PFFM) were obtained. We performed a multiple linear regression analysis to evaluate if these parameters could predict malignant histopathology.

**Results:** Mean patient weight was 184 lb (range 121–292 lb), height 65.4 inch (52–78 inch), FM 47.8 lb (10.1–111.5), PFM 25.5% (1–60.6), FFM 138.3 lb (range 62.7–201.2), PFFM 74.5% (range 39.4–99.4). Overall cohort histopathology revealed 36 (80%) conventional renal cell carcinomas (mean tumor size 3.9 cm, range 1.1–6.9) and 9 (20%) benign lesions (mean tumor size 4.4 cm, range 1.9–7.3). The mean FM, PFM, FFM and PFFM for malignant and benign RCN were 51.6 lb, 28.1%, 137.8 lb, 71.9% and 42.8 lb, 12.4%, 141.3, 87.6% (p = 0.049, p = 0.006, p = 0.329, p = 0.02). Regression analysis was R = 0.95. Among the evaluated variables, only PFM was able to predict malignancy (p = 0.042).

**Conclusion:** In this initial evaluation, BIS determined FFM predicted malignancy of RCN. Further evaluation is in progress to confirm these preliminary results.

#### MP18-11 EVALUATION OF APPLIED LAPAROSCOPIC UROLOGY COURSE USING VALIDATED CHECKLIST

S. Guven, C. Gurbuz, A. Gözen, L. Tunc, F. Saracoglu, Y. Ozgok

**Background:** The objective of the present study is to investigate the effectiveness of the "applied laparoscopic urology course" using a validated checklist and to determine the differences in lap-



aroscopic skills at the end of the course period among the participants starting their training in dry or wet lab.

**Methods:** In order to make urologists master challenging laparoscopic skills, a unique 3-day mini training program is established at the Gulhane Military Academy of Medicine, Surgical Research Center, Ankara, Turkey. In each course, only 30 trainees are accepted. These are divided into three sub-groups. The primary outcome of the study was the changes in the performances and task accomplishment periods of trainees at the beginning and at the end of the course. The secondary outcome; the differences in the basic skills of the trainees starting their training in the dry lab compared to those at the wet.

**Results:** The overall laparoscopic skills, which were evaluated using standardized laparoscopic suturing task score significantly improved and the time needed for task accomplishment decreased throughout the course (18.8 to 26.0  $p < 0.001$  and 9.5 minutes to 5.25 minutes  $p = 0.002$ ). According to the course design, laparoscopic skills scores and the times needed at the end of the course revealed no statistically significant changes despite the fact that the trainees had started their training at different stages.

**Conclusion:** Applied short-term laparoscopy course is an effective format particularly for laparoscopic skills in which suturing and knotting is essential. This is mainly achieved through close cooperation together in dry and wet laboratories.

## MP18-12

ABSTRACT WITHDRAWN

## MP18-13 DOES THE PRESENCE OF ROBOTIC SURGERY AFFECT DEMOGRAPHICS IN PATIENTS CHOOSING TO UNDERGO RADICAL PROSTATECTOMY? A MULTI-CENTER CONTEMPORARY ANALYSIS

P. Cheetham, D. Lee, S. Brewster, M. Truesdale, K. Badani—USA

**Background:** In the US, 62% of all prostatectomies are performed robotically (RALP), compared to a rate of less than 5% in the UK. The objective of this study was to report on differences in patient and tumour characteristics in centres where the option for RALP is present or absent.

**Methods:** Between 2007 and 2008, 69 consecutive patients underwent an open radical prostatectomy (RP) in a tertiary care academic UK center, and 78 consecutive patients underwent a robotic prostatectomy (RALP) in a similar US center. Patient demographic, clinical, and pathological data were prospectively analyzed.

**Results:** The US cohort was significantly younger ( $p < 0.01$ ), but also had a higher proportion of men in their 70's. The percentage of men with a family history of prostate cancer was not significantly different, while the UK cohort had a significantly higher percentage of men who were married and had a positive smoking history ( $p < 0.01$ ). The US cohort had a higher percentage of men with poor comorbidities (Charlson Comorbidity Index score  $> 3$ ), but the difference was not significant ( $p = 0.12$ ). The average preoperative PSA was significantly lower in the US group ( $p < 0.01$ ), however the biopsy and pathological tumor grade and stage were not significantly different between the two groups. The positive margin rate in pT2 and pT3 disease was higher in the UK cohort, but was not statistically different. Reported operating time was significantly shorter in the UK cohort ( $p < 0.01$ ). Transfusion rate was lower in the US group, but was not significantly different (1.3% vs 5.6%,  $p = 0.192$ ).

**Conclusion:** This data confirms our belief that patient demographics are different in a setting influenced by robotic surgery. Although pathologic parameters were similar, the age distribution of robotic patients was much wider, suggesting robotics encompasses men previously reluctant to undergo surgery in the open setting.

## MP18-14 CHARACTERIZATION OF RENAL ISCHEMIA USING DLP® HYPERSPECTRAL IMAGING: A COMPARISON OF ARTERY-ONLY OCCLUSION (AO) VERSUS ARTERY AND VEIN OCCLUSION (AV)

C. Tracy, R. Francis, E. Wehner, J. Smith, J. Cadeddu, K. Zuzak—USA

**Background:** Renal artery-only occlusion (AO), as opposed to artery and vein occlusion (AV), may have some benefit in reducing renal insufficiency during warm ischemia. We utilized DLP® hyperspectral imaging (HSI) to construct a “real time” tissue oxygenation “map” in order to determine whether there are differences in renal tissue oxygenation during vascular occlusion with AO versus AV.

**Methods:** Renal vascular occlusion with either AO or AV was performed for 60 minutes in seven porcine renal units. Using HSI, the percentage of oxyhemoglobin in the renal cortex was determined at 4 minute increments throughout the ischemic period and for 30 minutes following reperfusion.

**Results:** Average baseline percentage of oxyhemoglobin (% HbO<sub>2</sub>) in all animals was approximately 70%. Following vascular occlusion in both cohorts, % HbO<sub>2</sub> decreased by one-third within 2–5 minutes, with a gradual decline in % HbO<sub>2</sub> over the remaining 55 minutes. Oxyhemoglobin profiles for AO and AV occlusion diverged significantly between 16 and 24 minutes following vascular occlusion ( $p=0.0001$  and  $0.036$ , respectively), with a merging of the two curves occurring after approximately 36 minutes ( $p=0.093$ ). During reperfusion, average % HbO<sub>2</sub> improved to 72.4% after 25–30 minutes.

**Conclusion:** Renal tissue oxygenation drops rapidly following occlusion of the renal vasculature and returns to near baseline 30 minutes following reperfusion. In the porcine model, the percentage of oxyhemoglobin differs significantly between AO and AV occlusion for up to 35 minutes following ischemia onset, indicating a possible “ischemic window” where AO occlusion may provide benefit over AV occlusion.

### MP18-15 THE USE OF SPRAYED TISSEEL (FIBRINOGEN, APROTININ AND THROMBIN) AS THE SOLE HEMOSTATIC AGENT IN PORCINE LAPAROSCOPIC PARTIAL NEPHRECTOMY

D. Pick, S. Kolla, M. Louie, J. Tongson-ignacio, E. McDougall, R. Clayman—CA

**Background:** Tisseel is used to control bleeding in laparoscopic procedures. With the standard applicator, Tisseel has a thickened consistency. The Tissomat spray system allows for a thin, even application. We examine sprayed Tisseel, as the sole agent, to control hemorrhage and seal the renal collecting system after a porcine laparoscopic partial nephrectomy (pLPN).

**Methods:** Twelve Yucatan pigs underwent staged, bilateral pLPN using a longitudinal cut through the entire collecting system. In each pig, one kidney was harvested after four weeks, while the other kidney was harvested immediately. After hilar clamping pLPN was done with cold scissors in six pigs, while Ligasure was used for the other six animals. Then sprayed Tisseel was applied to the cut surface. The vascular clamp was removed and bleeding and urinary leakage was evaluated. Additional Tisseel was applied as necessary. At harvest, retrograde pyelogram (RPG) and pressure testing of the arterial and collecting systems was performed.

**Results:** All animals survived for four weeks. One urinoma was seen on RPG. Average hilar clamp time was  $27.7 \pm 10$  minutes. Average EBL was  $89 \pm 123$  ml and was similar between the cold scissors and Ligasure groups. Average arterial burst pressure was significantly different ( $p=0.0257$ ) between the chronic ( $642.2 \pm 92.5$  mm Hg) and acute ( $377.2 \pm 55.3$  mm Hg) groups. Average collecting system burst pressure was similar between the chronic ( $212.2 \pm 50.9$  mm Hg) and acute ( $180.6 \pm 39.2$  mm Hg) groups.

**Conclusion:** Sprayed Tisseel will effectively seal the arterial and collecting system following extreme laparoscopic partial nephrectomy in the porcine model.

### MP18-16 LAPAROENDOSCOPIC SINGLE-SITE (LESS) VERSUS CONVENTIONAL LAPAROSCOPIC DONOR NEPHRECTOMY

S. Rais-bahrami, A. Herati, M. Atalla, S. Andonian, L. Richstone, L. Kavoussi—USA

**Background:** LaparoEndoscopic Single-site Surgery (LESS) focuses on minimizing the incisions used for laparoscopic access. This has been adopted for laparoscopic living donor nephrectomy. We hypothesize that LESS will offer superior cosmetic outcomes, faster recovery, and equivalent efficacy as conventional laparoscopy. Our aim is to present our experience comparing a contemporary series of conventional laparoscopic donor nephrectomy to LESS donor nephrectomy comparing perioperative parameters and postoperative pain.

**Methods:** Data was prospectively gathered on 17 patients undergoing both conventional ( $n=7$ ) and LESS ( $n=10$ ) donor nephrectomy at our institution between July 2008 and June 2009. LESS donor nephrectomy was performed through a single Pfannenstiel skin incision through which a 12 mm and two 5 mm trocars were introduced. Otherwise, the procedure replicated conventional laparoscopic techniques, using a 5 mm flexible-tip laparoscope, and combining flexible with conventional working instruments including a LigaSure device and EndoGIA stapler.

**Results:** Perioperative parameters stratified by operative approach are shown in Table #1. There was no difference in any of the perioperative parameters investigated. No patients required intraoperative or postoperative blood transfusions. There was one complication in this series: a patient who underwent conventional laparoscopic donor nephrectomy with a postoperative wound infection readmitted for intravenous antibiotics and wound care. Table#1: Operative Approach Conventional LESS p-value Age (yrs) 38.5+/- 14.2 41.0+/- 11.5 0.69 ASA 1.7+/- 0.5 1.4+/- 0.5 0.23 Operative Time (min) 125+/- 32 151+/- 44 0.21 Estimated Blood Loss (mL) 121+/- 57 110+/- 38 0.60 Length of Hospitalization (days) 2.1+/- 0.4 2.3+/- 0.7 0.59 Postoperative Morphine Equivalents Used (mg) 55.6+/- 14.8 59.9+/- 40.9 0.79

**Conclusion:** LESS donor nephrectomy has equivalent operative time, blood loss, warm ischemia, and length of hospitalization when compared to conventional laparoscopic donor nephrectomy. In our early experience, patients undergoing LESS donor nephrectomy have similar postoperative analgesic requirements combining narcotics and intravenous ketorolac use. Further evaluation of these findings are currently underway in a randomized, blinded study.

### MP18-17 EXTREMELY LARGE PROSTATE SIZE MATTERS FOR FUNCTIONAL OUTCOMES FOLLOWING ROBOTIC ASSISTED RADICAL PROSTATECTOMY

T. Skolarus, S. Zhang, B. Hollenbeck

**Background:** For radical prostatectomy, the advantages of robotic surgery may facilitate more precise dissection and improve functional outcomes. While this is evident in most cases, patients with extremely large prostates, i.e., over 100 grams, may pose increased challenges due to limited working space. For this reason, we undertook a study to understand the relationship between extremely large prostate size and functional outcomes after robot-assisted prostatectomy.

**Methods:** Patients undergoing robotic-assisted radical prostatectomy from 2003 to 2009 at our institution were included in the study. Prostate volume was categorized into three groups: <50 grams, 50–100 grams and >100 grams. The primary outcome was return of function 3 months after surgery measured using

EPIC. Intraoperative and pathologic variables were also measured and compared among the groups.

**Results:** A total of 885 patients underwent robotic assisted prostatectomy (<50 gm n = 582, 50–100 gm n = 279, >100 gm n = 24). Increasing prostate weight was associated with increased age, operative time and blood loss, while positive surgical margins and pathologic Gleason score decreased. No surgical margins were positive in prostates >100 gm and there were no differences in nerve-sparing among the groups. After adjustment, postoperative irritative symptoms and sexual function were similar, however recovery of urinary continence worsened with increasing prostate size. Prostate size category (gm) <50 50–100 >100 p-value Prostate size (gm, mean) 38.9 62.0 119.6 p < 0.001 Age at surgery (years, mean) 59.4 62.0 67.4 p < 0.001 Estimated blood loss (mL, mean) 155 169 250 p = 0.01 OR time (minutes, mean) 232 248 250 p = < 0.01 Neurovascular bundle sparing (%) p = 0.17 Bilateral 64.2 61.7 54.2 Unilateral/partial 22.9 22.9 25.0 None 12.9 15.4 20.8 Pathologic Gleason score (%) p < 0.01 ≤ 6 22.0 36.2 47.6 7 74.0 58.6 38.1 8–10 4.0 5.2 14.3 Surgical margin (%) p < 0.01 Negative 81.0 88.9 100 Positive—focal 15.0 9.3 0 Positive—extensive 4.0 1.8 0 Baseline EPIC urinary-irritative subscale (mean) 89.6 83.8 74.6 p < 0.001 Baseline EPIC urinary-incontinence subscale (mean) 95.4 90.7 87.5 p < 0.001 Baseline EPIC sexual subscale (mean) 76.6 69.3 45.8 p < 0.001 3 month EPIC urinary-irritative subscale (mean)\* 88.8 87.9 88.8 p = 0.88 3 month EPIC urinary-incontinence subscale (mean)\* 62.0 49.3 44.0 p = 0.03 3 month EPIC sexual subscale (mean)\*\* 35.3 29.1 10.5 p = 0.90 \*Adjusted for baseline, age at surgery \*\*and nerve-sparing.

**Conclusion:** Extremely large prostate size increases the complexity of robotic assisted radical prostatectomy leading to longer operative times and increased blood loss. Oncologic parameters are improved in patients with larger glands, however it appears to hamper early return of continence.

### MP18-18 THE USE OF PATIENT-CONTROLLED ANALGESIA AT 60 VERSE 120 SHOCKS PER MINUTE IN EXTRACORPORAL SHOCK WAVE LITHOTRIpsy

A. Lo, N. Lee, C. Ng

**Background:** Patients' pain tolerance and analgesic demand to shockwave lithotripsy (SWL) in slower and faster shockwave delivery rates has not been investigated. Therefore, we would like to investigate on the pain perception and analgesic demand in patients treated with different shockwave delivery rate by the usage of patient-controlled analgesia (PCA).

**Methods:** Patients with radio-opaque renal stones of size 5–20 mm received SWL at either 60 SWs/min or 120 SWs/min with the routine treatment protocol with Sonolith Vision (Technomed, France). PCA alfentanil in 10 µg/ml with 4 ml per demand and effective lockout interval of 105 seconds was given during SWL. Pain was assessed using numeric rating scale (NRS) scores (0–10). PCA demand and PCA administered were recorded at every 250 J until the end of treatment at 1000 J or complete fragmentation.

**Results:** 201 suitable patients were included. 63 patients have encountered 60 SWs/min while 138 patients have received 120 SWs/min. The patient characteristics of the two groups were comparable. Pain scores over time were consistently higher in 120 SWs/min with significant difference in 750 J and 1000 J

(p < 0.05). There is no significant difference between two groups in PCA demand and dosage administered.

**Conclusion:** While having the same level of analgesic during SWL, patients treated with 60 SWs/min experienced significant less pain than those received 120 SWs/min. Slower shockwave delivery rate may result in less pain during SWL.

### MP18-19 WHAT ABOUT THE QUALITY OF RANDOMIZED CLINICAL TRIALS PRESENTED AT THE WCE MEETING?

R. Autorino, M. De sio, R. Stein, C. Quattrone, D. Sorrentino, J. Kaouk—USA

**Background:** Our aim was to assess the quality of randomized clinical trials (RCTs) presented at the annual World Congress of Endourology meeting.

**Methods:** All RCTs presented in abstract form at the WCE annual meetings in 2005 and 2007 were identified for review. A standardized evaluation form was developed based on the Consolidated Standards for the Reporting of Trials (CONSORT) statement. Statistical analysis was performed using Fisher's exact test, chi-square test or Mann-Whitney test as appropriate.

**Results:** A total of 62 RCTs (3.3 % out of 1885) were identified for review (2005: 36; 2007: 26). Almost 40% of them (2005: 16/36, 44%; 2007: 8/26, 30%) were subsequently published as a full length indexed manuscript. The most common therapeutic interventions were: BPH treatments (15, 24%); PCNL (11, 18%); Laparoscopy (8, 13%); Stents (8, 13%) and SWL (7, 11%). Approximately 41 (67%) identified the study design as RCT in the abstract title. None reported the method of randomization and allocation concealment. In studies that reported blinding (7, 11% of 62), 5 were double blinded and 2 single blinded. Adverse events were reported in 38% of cases.

**Conclusion:** Overall, few RCTs are reported at the WCE annual meeting. Most of them are recognized as RCTs in the abstract title. When applying the CONSORT criteria, necessary information to assess their methodological quality is often missing.

### MP18-20 CONTINUOUS PROCEDURE BASED ASSESSMENT: FROM SURGICAL TRAINING TO LEARNING TO BE A SURGEON IN THE NEW ERA OF THE EUROPEAN WORKING TIME DIRECTIVE

C. Brown, D. Sharma, C. Kouriefs, A. Haq, H. Patel, P. Grange—UK

**Background:** Due to the European Working Time Directive UK surgical trainees must work no longer than 48 hours a week. This has led to a shift from traditional apprenticeship based training to competency based modular training. Learning advanced laparoscopic procedures such as radical prostatectomy is a challenge.

**Methods:** Procedure based assessments provide a framework to assess practice and facilitate feedback in order to direct learning. This involves breaking complex operations into modules. Each trainee has an assessment worksheet with the modules listed. For each operation each trainee will have a specific goal e.g. port insertion and development of working space, allowing another trainee to perform e.g. division of endopelvic fascia and bladder neck. Competency is assessed by the trainer allowing certain modules to

be focused on in future operations. A colour coded work sheet allows easy adaptation of future training goals to suite individual learning needs.

**Results:** 11 surgeons have been trained using this technique. More than one surgeon can train per case resulting in fewer cases needed to meet competencies and having less impact on service delivery.

By progressing through the steps of the learning model in a logical way trainee surgeons learn safely and efficiently.

**Conclusion:** Diverting a modern work based assessment tool into a learning tool makes allows established senior surgeons and trainees with an interest in laparoscopy to learn laparoscopic radical prostatectomy without further learning curve.

## MP19: LAPAROSCOPY AND ROBOTICS—UPPER URINARY TRACT

### MP19-01 PARALLEL INCISION EXTRAVESICAL RE-IMPLANTATION IN LAPAROSCOPIC ROBOTIC-ASSISTED URINARY RECONSTRUCTION—THE “BARRY/MITCHELL” REIMPLANT

J. Sumfest

**Background:** Originally described by Barry in 1983 for extravescical ureteroneocystomy in renal transplantation, and later modified for open appendicovesicostomy by Mitchell in 1993, the parallel incision extravescical reimplant has withstood the test of time and constantly demonstrated excellent outcomes.

**Methods:** Two parallel incisions are made with monopolar cautery, each detrusor incision is approximately 2–3cm in length with an intervening detrusor bridge of the same width. A plane of dissection is developed underneath the detrusor bridge and the conduit is drawn through the tunnel. A small incision made in the apex of the mucosal bulge and three full-thickness sutures of fine absorbable suture are placed at the 3, 6, and 9 o'clock positions anastomosing the conduit to the bladder mucosa. A horizontal advancement suture is then used to both fix and advance the distal aspect of the conduit to the full-thickness of the bladder wall. A flush stoma is created and when catheterization is reassured a stomal catheter placed.

**Results:** The Barry/Mitchell reimplant was used in 8pts. All procedures were completed intracorporeally. Follow-up ranges from 3 to 48mos. All patients catheterize without difficulty and are continent.

**Conclusion:** The Barry/Mitchell reimplant is useful in achieving an anti-reflux continence mechanism in laparoscopic reconstructive procedures. Indeed, success is almost universally achieved if the mitrofanoff principle is adhered to.

### MP19-02 ROBOTIC ASSISTED LAPAROSCOPIC DISMEMBERED PYELOPLASTY (RALDP) FOR PRIMARY AND SECONDARY URETEROPELVIC JUNCTION OBSTRUCTION (UJO): A MULTI-INSTITUTIONAL EXPERIENCE

M.B. Patel, R. Ferreira Coelho, R. Munver, V. Bird, R. Leveilee, V. Patel—US

**Background:** The introduction of robotic assistance into laparoscopy has not only enabled more surgeons to attempt the laparoscopic approach to pyeloplasty, but also to perform more difficult cases of previously failed surgical repairs. Herein, we report, a multi-institutional experience w/ RALDP for primary (1°) & secondary (2°) repair of UPJO.

**Methods:** Between June 2002 and October 2008, from 3 institutions performing a high volume of robotic cases, 168 pts undergoing RALDP with stenting for UPJO were respectively reviewed. Of the 168 pts, 21 were in the 2° repair group; of which, 57% had a crossing vessel etiology, w/ 9 being initially treated with endopyelotomy. The 2° group consisted of 12 endopyelotomy failures, 1 laparoscopic and 8 open repair failures.

**Results:** There were no statistically significant differences in any parameters between pts undergoing a 1° or 2° repair. Overall, 96.9% of pts showed improved T½ after repair w/ a mean decrease of 32.5min; 72.7% showed improved renal function w/ a mean increase of 4.5% in the affected renal unit. When examining changes in GFR, 86.2% showed either improvement or no change in GFR after surgery, w/ 51.7% showing a rise in GFR by a mean of 15.1ml/min. Of the 4pts w/ renal insufficiency (defined as GFR < 60), 3 improved the GFR above 65 after surgery. There were 8 complications; more common was ileus & blood transfusion.

**Conclusion:** RALDP is an efficacious and viable option for either 1° or 2° repair of UPJO with excellent outcomes, high success rates, and low incidence of complications.

### MP19-03 PREDICTORS OF OUTCOME OF URETEROPELVIC JUNCTION OBSTRUCTION (UPJO) FOLLOWING MINIMALLY INVASIVE RECONSTRUCTION BASED ON PERI-OPERATIVE CHARACTERISTICS

A. Goh, M. Kim, R. Link—USA

**Background:** Evaluation and treatment of UPJO depends on a multiplicity of factors, including symptoms, renal function, drainage patterns, and complications. Follow-up of these patients often involves functional and anatomic renal imaging. However, interpretation of these exams can be challenging.

**Methods:** We reviewed patients who underwent either laparoscopic or robot-assisted pyeloplasty for a UPJO by a single surgeon between July 2005 and November 2008. Demographic and perioperative data were obtained. We analyzed functional and anatomic imaging before and at least four months following pyeloplasty. Pre-operative hydronephrosis was determined by retrograde pyelogram or CT scan. Post-operative hydronephrosis was mainly derived from renal scans.

**Results:** Of 40 cases of UPJO repaired, 20 were addressed by laparoscopic pyeloplasty and 20 by robot-assisted pyeloplasty. One patient had a bilateral repair. Mean age was 43.4 years (n = 39).

Five (13%) cases were secondary repairs. A crossing vessel was located in 23 cases (58%). Pain (73%) was the most common presenting complaint, followed by infection (33%), stones (13%), and azotemia (13%). Pre-operative function of the affected renal unit measured by nuclear imaging was not significantly different post-operatively ( $p=0.38$ ). Time for 50% clearance of tracer (T1/2) was significantly decreased on post-operative diuretic renal scan ( $p<0.001$ ). Improvement in renal function post-operatively was not correlated to age, presence of crossing vessel, or history of prior repair. These factors were also not significantly associated with the degree of pre-operative or post-operative hydronephrosis. Severe pre-operative hydronephrosis correlated with a longer pre-operative T1/2 ( $p=0.03$ ). The persistence of severe post-operative hydronephrosis was associated with prolonged post-operative T1/2 (mean 44.2 minutes,  $p<0.01$ ). However, the presence of severe pre-operative hydronephrosis was not predictive of persistent post-operative hydronephrosis ( $p=0.06$ ). 5 patients (13%) had transient postoperative symptoms and a prolonged T1/2, however all had a negative endoscopic evaluation for obstruction. No patients had worsening of hydronephrosis on post-operative follow-up.

**Conclusion:** Age, presence of crossing vessel, or previous repair does not correlate with the severity of hydronephrosis in UPJO. Persistent severe post-operative hydronephrosis can prolong renal clearance on diuretic renal scan but does not necessarily represent significant obstruction.

#### MP19-04 PERIOPERATIVE OUTCOMES OF LAPAROSCOPIC AND ROBOTIC SINGLE PORT SURGERY

R. Goel, W. White, G. Haber, S. Crouzet, R. Stein, J. Kaouk

**Background:** Single port laparoscopy (SPL) has expanded over the last year although technical constraints still hinder its routine application. Utility of the robotic platform to curtail these technical shortcomings has garnered attention however superiority between either approaches is debatable. Herein, we present the first comparison between single port robotic (SPR) surgeries to a SPL cohort.

**Methods:** Matched comparison of SPR to SPL procedures was performed. Patients with advanced malignancy, previous abdominal/renal surgery or solitary kidney were excluded. Single, exophytic, cortical masses were chosen for SPL/SPR partial nephrectomy and where appropriate hilar clamping was performed. Single multi-channel port access was obtained via an open Hasson technique. Flexible and bent instruments were used for the laparoscopic approach while the da Vinci-S surgical robot with 5 mm instruments was used for SPR. Perioperative and pathological data was entered into an IRB approved database.

**Results:** Thirty comparable single port cases were evaluated (21 SPL and (9) SPR. Matched single port procedures included radical prostatectomy, partial nephrectomy and dismembered pyeloplasty. A trend towards less operative time favored SPR but did not reach statistical significance. Operative familiarity was noted in all cases as continuous sutures placement was performed for both pyeloplasty and radical prostatectomy without additional port insertion. Minimal pain scores were noted for both SPL and SPR approaches. Patients selected for SPR partial nephrectomy had superficial cortical tumors that circumvented the need for hilar control. Nuclear renography following dismembered pyeloplasty demonstrated excellent drainage of the preoperatively obstructed system with no evidence of anastomotic leak. RADICAL PROSTATECTOMY SPL SPR (n=4)(n=3)OR time (min)285

$\pm 30217 \pm 72$ EBL (cc)288  $\pm 131133 \pm 104$ Anastomosis4 to 7 sutures, interruptedContinuous runningMargins(2) Positive margins(2) Focally positive(1) negativeContinence(1): 3–4 pads, (2): 1 pad (1): 0 pad (2) 1 pads/day, (1): pendingComplications(1) Rectourethral fistulaNoneVAPS0.75 (range: 0–3)1.3 (0–3)PARTIAL NEPHRECTOMY SPL SPR (n=11) (n=4)Tumor size (cm)2.6  $\pm 1.54.1 \pm 4.6$  (range 1.1–11 cm)OR time (min)215  $\pm 64143 \pm 35$ EBL (cc)491  $\pm 415234 \pm 255$  (range 25–600)Warm Ischemia Time (min)(3) 19  $\pm 7.5$  (range 11–26 min)0Complications(1) post op bleed; angioembolization(2) conversion {[1] standard lap, [1] open}NonePathology(8) RCC, (2) Oncocytoma, (1) Benign Cyst(1) Focally positiveFrozen section negative(2)AML, (2) RCCMargins negative VAPS0.6 (0–3) 1 (0–3)DISMEMBERED PYELOPLASTY SPL SPR (n=6) (n=2)OR time (min)222  $\pm 76265 \pm 92$ EBL (cc)63  $\pm 3163 \pm 53$ LOS (days)2.7 (range 2–4 days)2 (range 1–3)Suture techniqueContinuous with 2 mm needlescopic instrumentContinuousFollowup (3) MAG3: normal clearance(3)MAG3: pending(2) MAG3: normal clearanceComplications(1) umbilical herniaNone VAPS 2.7 (0–8)3

**Conclusion:** Single port robotic surgery provides a platform to further advance single port surgery. Initial experience with SPR demonstrates improved ergonomics and intracorporeal suturing capabilities with comparable peri-operative results to SPL. Comparison of surgical fatigue during SPL and SPR procedures could further substantiate robotic application. Long term assessment and further refinement of the SPR approach is warranted although early results are promising.

#### MP19-05 HOW USEFUL IS CLAVIEN CLASSIFICATION SYSTEM IN ENDOSCOPIC RESECTION OF PROSTATIC ADENOMA?

I. Efthimiou, S. Kazoulis, G. Chrisanthacopoulos, G. Skrepetis, I. Christoulakis—Greece

**Background:** Aim of the study was to classify early, negative surgical outcomes after TURP with the aid of Clavien Classification System.

**Methods:** We studied prospectively 259 patients, 53–91 years old who underwent TURP from January 2006- February 2008. Patient follow up was until the end of the first month of discharge from the hospital. All the cases were performed with monopolar resection of the prostate gland and postoperative complications were recorded according to Clavien system.

**Results:** Overall complication rate was 14.2%. 11 patients (4.2%) suffered of Grade I complications (5 with delayed catheter removal for hematuria, 4 acute urinary retention, 2 with transient acute renal failure after NSAD administration which resolved spontaneously with out the need of any intervention), 13 patients (5%) Grade II (2 UTI which required only antibiotics, 8 blood transfusion, 2 supraventricular tachycardia, 1 pulmonary embolism), 10 patients (3.86%) Grade III (5 required repetitive bedside blood clot evacuation plus or not catheter traction during the first 24 postoperative hours and three required catheter change due to clot, chip block or catheter malfunction, 1 with retrovesical catheter dislocation, 1 reoperation for residual adenoma), two patients presented with Grade IV complications due to myocardial infarction and TUR syndrome respectively. Finally there was one Grade V (death). Five cases presented multiple complications which required categorization in more than one grades. Urologic complications were in 17 cases (46%) and 20 (54%) were medical.

**Conclusion:** Clavien Classification system although it has inherent disadvantages and limitations, helps clinicians in more objective and detailed classification of postoperative complications.

### MP19-06 COMPARISON OF SURGICAL APPROACHES TO URETEROPELVIC JUNCTION OBSTRUCTION: PERCUTANEOUS ENDOPYELOTOMY VERSUS OPEN DISMEMBERED PYELOPLASTY

A. Unsal, C. Kara, M. Bayindir, B. Resorlu—Turkey

**Background:** The aim of this study is to compare the results of percutaneous endopyelotomy and open dismembered pyeloplasty for the treatment of ureteropelvic junction (UPJ) obstruction.

**Methods:** We reviewed the medical records of 26 patients with a mean age 17.5 years (8–34) who had UPJ obstruction between 2005 and 2009. Patients were divided in two groups. Group I were treated by antegrade endopyelotomy (9 patients) and Group II were treated by open dismembered pyeloplasty (17 patients). Diagnosis of UPJ obstruction was made by urinary ultrasonography, excretory urogram and/or retrograde pyelography and diuretic renal scans. Two patients in Group I and two in Group II have stones in 1–1.5 cm in size associated with UPJ obstruction.

**Results:** Mean operative time was 95 min and 65 min in Group I and II respectively. Mean hospital stay was 5.5 (3–8) days and 2.7 (2–3) days respectively. The primary success rate was 94% after open pyeloplasty and 77% after antegrade endopyelotomy. All stones in both groups were removed successfully. Two patients (22.2%) required ancillary procedures for failed endopyelotomy. Both patients had large dilated renal pelvis. One (11.1%) patient required repeat endopyelotomy, and one (11.1%) patient needed open pyeloplasty and reduction of renal pelvis. One failed patient in Group II was lost to follow-up. No significant complication was seen in the endopyelotomy group while one patient had increased fever that treated with antibiotics and two (22.2%) had prolonged drainage from nephrostomy site. Three (17.6%) patients had increased drain output for more than 3 days in pyeloplasty group.

**Conclusion:** Percutaneous endopyelotomy is a safe and effective treatment of UPJ obstruction even with renal stones. The success rates may be decreased in patients with large dilated renal pelvis.

### MP19-07 THE SURGICAL STRATEGY FOR THE IATROGENIC URETERAL TRAUMA COMPLICATING UPPER TRACT OBSTRUCTION

J. Pan, W. Xue, H. Chen, Q. Chen, Y. Chen, Y. Huang

**Background:** To study the pathological basis of the iatrogenic ureteric lesion complicating upper tract obstruction and to evaluate the efficacy of different surgical strategies in these cases.

**Methods:** From February 2007 to April 2008, 16 cases with iatrogenic ureteric lesion complicating upper tract obstruction were enrolled in this retrospective study. The average age of these patients was 49 years. After the endourologic trauma, a D-J stent had been set in place for 4–6 weeks in all the cases. The length of the obstructive portion and the thickness of the ureteric scar were evaluated by MRU. The STORZ F7.9 semi-rigid ureteroscope was used to observe the altered ureter. For the patients with no obstruction found by the ureteroscopy, an open surgery was carried out to remove the obstructive part and the specimen was examined by a pathologist. For the rest of the cases, we tried the internal ureterotomy with holium laser under the ureteroscope. After all the procedure, a F7 D-J stent was indwelled for 6 weeks. An intrave-

nous urography was done 6 months after the procedure to evaluate the results.

**Results:** The semi-rigid ureteroscope could advance without any difficulty in 12 patients, in whom the involved mucosa were flat and the lumen were unobstructed. The surgical specimen showed a thickening of the whole ureteric wall with chronic inflammation and interlace of smooth muscle cell while the mucosa was intact. In the other 4 patients, we gave up the ureteroscopy for the tight stenosis with the guide wire set in place and a holium laser endoureterotomy was carried out. 6 months later, in all the 12 patients with open surgery, no more obstruction was found by IVU while 2 cases treated by internal incision had a recurrence of ureteric stricture and hydronephrosis. We have removed the obstructive part in these 2 patients and the follow-up at 6 months after the surgery demonstrated the ureter was intact.

**Conclusion:** In some of the patients with iatrogenic ureteral lesion, the ureteric mucosa could be intact while there is a thickening of the sub-mucosa, the mucularis and the peri-ureteric tissue. For such patients the ureteral kinetic obstruction was probably the main cause and the surgical removal of the altered segment might be the reasonable choice. For the patients with a tight and relatively short stricture (<2 cm), the holium laser endoureterotomy or the balloon dilation could be proposed but with a relatively high recurrence rate. The urine extravasation might enhance the fibrosis of the ureteral scar and for the cases with an important urinoma, the PCN drainage might be a good solution.

### MP19-08 INFLUENCE OF PROLONGED URETERAL STENT DRAINAGE OF THE UPPER URINARY TRACT ON RENAL FUNCTIONAL CAPACITY

A. Chepurov, S. Zenkov, I. Mamaev, E. Pronkin

**Background:** The problem of prolonged drainage of the upper urinary tract is especially pertinent nowadays due to the steady rise of diseases, including oncological disorders that cause the ureter to become obstructed. Stent-associated infections, ureteral stent impact on functional capacity of a kidney, and urine passage and drainage system replacements are still actual and little-studied.

**Methods:** Thirty-seven patients (26 women and 11 men; aged: 25–84 years old, average age: 67.5 years old) which needed constant drainage of the upper urinary tract with an internal stent were treated in our hospitals from 1991 to 2009. Eight of these patients had only one functioning kidney. Causes of obstruction: decompression of malignant ureteral obstruction, ureteral stenosis, retroperitoneal fibrosis, urolithiasis. The treatment lasted from 1 to 17 years. The number of stents threaded into the ureter was between 4 and 43. The average drainage time with one stent was 3 months. Most patients were subject to urinoscopy to determine the urine micro flora growth and its antibiotic-sensitivity before replacing the stent, and analysis of the removed stent were studied for most patients. The parameters examined included specifying the kidney function including urea level, blood creatine, and kidney scintiscanning was carried out when there were no signs of renal insufficiency.

**Results:** All patients underwent the ureteral stent placement in the urinary tract as appropriate. This category of patients did not have any difficulties caused by the stent replacement. The examination of the nitrogen secretory function of the kidneys revealed that 24 of 37 patients did not show any signs of progressive renal azotemia. By using kidney scintiscanning, it was determined that the accumulative-secretory kidney function of the 2/3 patients was not

decreased. 14 patients had progressive renal insufficiency with the urea increased to 17 mmol/l and creatine—to 315 mkmol/l. Leucocyturia was observed in the thirty-two patients. The urine analysis in most cases revealed E.coli, and preventive antibacterial therapy was administered. With urolithiasis patients the stent got incrustated much faster and needed to be replaced off-schedule. For 13 patients ureteral stent was changed to PCN tubes.

**Conclusion:** The research revealed that this kind of drainage will not result in progressive nephrotia and it is well endured by the patients. It also secures adequate urine passage, including in patients having only one functioning kidney. The effectiveness of this kind of drainage depends on adequate dynamic control of the functional condition of a kidney, development of nephritis complications and timely antibacterial and detoxication therapy.

### MP19-09 ROBOTIC VERSUS OPEN URETERAL RE-IMPLANTATION FOR DISTAL URETER BENIGN STRICTURE DISEASE

S. Kozinn, J. Mandeville, K. Hamawy, A. Sorcini, D. Canes, A. Moizadeh—USA

**Background:** Minimally invasive techniques are currently employed for numerous urologic procedures given decreased patient morbidity and equivalent outcomes to open surgery. There is however a relative paucity of data as related to robotic assisted (RA) distal ureteral reconstruction for benign stricture disease. We sought to compare the efficacy, cost, and functional outcomes of open versus RA distal ureteral reconstruction at our institution.

**Methods:** We retrospectively identified 9 consecutive patients undergoing 10 RA reconstructive procedures since 2005. Twenty four patients undergoing open distal ureteral reconstruction over the same period were identified and 10 age-matched controls were used for comparison. Overall cost was calculated by factoring in OR time, instrument and robot costs, ICU care, and length of stay. Demographic, operative, and cost parameters were compared using Student T-test, Wilcoxon Rank Sum, or Fischer's exact test as appropriate.

**Results:** (See Table 1) Etiology of the strictures in both groups included stone disease (n = 7, 35%) and iatrogenic ureteral injury during prior abdominopelvic surgery (n = 13, 65%). All robotic procedures were completed in a minimally invasive fashion without conversion to open surgery. No Intraoperative complications were noted for either group. Six neocystotomies, 3 psoas hitches, and one Boari flap were completed in an open fashion. Four neocystotomies, 4 psoas hitches, and 2 Boari flaps were performed in the RA group. Estimated blood loss (EBL) and length of hospital stay (LOS) were significantly shorter in the robotic group. One patient in the open group required a blood transfusion. There was a trend toward increased operative time and higher BMI in the robotic surgery patients. None of the patients in either category had clinical or radiological evidence of recurrent stricture disease. The mean direct hospital cost of the procedure robotically (\$10,328) was significantly higher than the open group (\$5,841).  
Table 1 Open (n = 10) RA (n = 10) p-value Age (range) 53.7 (40–63) 51.3 (33–63) 0.589% Male 40% 53% 0.080 ASA 2 2 1.000 BMI 26.5 ± 5.2 30.4 ± 5.3 0.130 Operative Time (min) 270.0 ± 182.8 339.5 ± 48.4 0.316 EBL (mL) 327.5 ± 695.7 30.6 ± 11.0 0.001 LOS (POD discharge) 5.1 ± 2.6 2.8 ± 1.2 0.010 Median follow-up (mos) 16 (95% CI 4–22) 6.5 (95% CI 2–38) 1.000 Direct Cost \$5,841 \$10,328 0.005

**Conclusion:** Our series represents one of the largest single institution experiences with robot assisted ureteral reimplants published to date. In experienced hands, RA ureteral reconstruction appears to be an alternative to open surgery with excellent intermediate term follow up. Increased cost and surgical expertise may be the main limitations of the robotic approach.

### MP19-10 EARLY EXPERIENCE OF ROBOT-ASSISTED LAPAROSCOPIC PYELOPLASTY

J. Lee, I. Seo, D. Han, J. Rim, I. Mun, Y. Chae—Korea

**Background:** Laparoscopic pyeloplasty has proven to be less morbid but equally as effective as open pyeloplasty. However, the technical complexity has made it difficult for many surgeons to adopt. The weak point of the procedure makes up for the da Vinci robot-assisted procedure. We present our early experience with robot-assisted laparoscopic pyeloplasty.

**Methods:** Between December 2008 and June 2009, 4 selected patients underwent robot-assisted laparoscopic pyeloplasty. The mean age of 2 male and 2 female was 32 years old. Operations were performed transperitoneally using 3-robot port and 1-assist port. The robotic camera was put into the peritoneal space through a 1.5 cm umbilical incision. Double-J ureteral stent was inserted during the operation. We found aberrant vessel in two cases. The mean follow-up time was 4.3 months.

**Results:** All cases were completed successfully without open conversion. The mean operative time was 110 minutes. There was no specific operative complication, blood transfusion, and post-operative complication. The mean estimated blood loss was 198.3mL. The mean postoperative time to initiate ambulation and diet were 1 day and 2 days. The mean hospital stay was 5.5 days.

**Conclusion:** Our early experiences showed that robot-assisted laparoscopic pyeloplasty was performed safely. If its technique and experience get accumulated, it may take place of the laparoscopic and open pyeloplasties.

### MP19-11 RETROGRADE BALLON DILATATION OF PELVI-URETERIC OBSTRUCTION IN PATIENTS WITH IMPAIRED GENERAL CONDITION

K. Skrepetis, K. Tzelepis, I. Efthimiou, G. Stathouros, P. Kalomiris—Greece

**Background:** The aim of this study was to evaluate the efficacy of retrograde balloon dilatation for the pelvi-ureteric obstruction (PUJO) in patients with impaired general condition.

**Methods:** From January 2007 to February 2009 our study includes 6 patients with secondary and 2 patients with primary PUJO who underwent retrograde balloon dilatation of PUJ. The etiology of the secondary PUJO included previous stones (2 cases) and sequelae open (3 cases) and endoscopic (1 case) surgery. All patients had impaired general condition (3 of them hurt failure, 4 of them chronic respiratory obstruction and 1 with diabetes under insuline therapy). A retrograde endourological dilatation was made under fluoroscopic control. High pressure ballons were used to dilate the PUJO for either 5 or 10 min, under 5 to 10 Atm of pressure. A double J stent was then left in the ureter for 4 weeks. Evaluation included clinical and radiographic examinations and DTPA. The median follow-up was 16 months (range, 5 to 29). The procedure was considered succesful if it left the patient asymptomatic and with improved radiographic and renographic drainage.

**Results:** There were no intraoperative complications. The median hospitalization was 2.5 days (range, 2 to 4 days). The overall

success rate was 75%. All patients with secondary PUJO are asymptomatic with improvement in radiographic and renal scintigraphy examinations. In two renal units with primary PUJO the procedure was unsuccessful regarding relieving of stenosis.

**Conclusion:** Retrograde balloon dilatation is a safe and relatively effective technique for the management of secondary PUJO. Considering minimal invasiveness, low morbidity and excellent results retrograde balloon dilation may be recommended as first line treatment for impaired patients with PUJO. Balloon dilatation seems as an ineffective method in the treatment of primary PUJO.

### MP19-12 ANATOMICAL KNOWLEDGE ACQUISITION TRAINING MODULE BASED ON ROBOT ASSISTED RADICAL PROSTATECTOMY

S. Kommu, Z. Hashim, C. Eden, A. Golash, C. Luscombe, S. (sarg)—United Kingdom

**Background:** Conventional anatomical knowledge acquisition in among trainees includes formal lectures involving theory supplemented with cadaveric dissections and/or use of synthetic models. As the trainee apprentice evolves from medical student to surgical trainee, applied anatomy through active participation in the live human case is acquired. With the advent of Minimally Invasive Urological Surgery (MIUS), which includes the laparoscopic and robotic platforms, a further dimension is added to anatomical knowledge acquisition. The inherent monitor display during MIUS acts as a useful tool for tutoring. Herein we describe anatomical knowledge acquisition using the target organ of the prostate. Real-time teaching during a pre-recorded Robot Assisted Radical Prostatectomy was used as a training tool. The module was tested against the conventional approach.

**Methods:** Five trainees who underwent Conventional Anatomical Knowledge Acquisition (CAKA), which included the bias of formal lectures coupled with cadaveric dissections and/or use of synthetic models, were labelled GpA. Five other trainees i.e. GpB were taught using a case of Robot Assisted Radical Prostatectomy available from the Global Robotics Institute ([www.globalroboticsinstitute.com](http://www.globalroboticsinstitute.com)). The latter group had not undergone any form of tutorial regarding the anatomy of the prostate. The video was used for teaching solely about the anatomy of the prostate gland, the dorsal vein complex and the neurovascular bundle. Following the tutorial, GpB candidates were subjected to a 15-question test regarding prostate gland anatomy. The scores were compared to those of GpA who were subjected to the same test. GpB candidates were asked to fill out a questionnaire following reading of a section dedicated to the anatomy of the prostate in a textbook recommended by the Royal College of Surgeons of England.

**Results:** Trainees from GpB scored a mean of (12/15) 80% versus GpA who scored a mean of (10/15) 67%. Feedback from GpB indicated that the structures in the video of RARP were clear and easy to visualise. When GpB read the prostate section of the anatomical textbook, they stated that the anatomy was easier to conceptualise.

**Conclusion:** Robot Assisted Radical Prostatectomy as an operative training module for knowledge acquisition is a useful supplementary tool to conventional training platforms. Minimally Invasive Urological Surgery and its associated modes must be explored further as teaching tools for anatomy of other urological target organs such as the kidney, ureter and bladder.

### MP19-13 DOSE THE EARLY LIGATION OF THE URETER DURING SURGERY REDUCE THE RISK OF BLADDER RECURRENCE AFTER NEPHROURETERECTOMY FOR UPPER TRACT TRANSITIONAL CELL CARCINOMA?

Y. Kobayashi, T. Saika, S. Uehara, T. Watanabe, Y. Nasu, H. Kumon

**Background:** Radical nephroureterectomy with excision of a bladder cuff has been the gold standard of treatment for upper urinary tract urothelial cancer (UUT-UC). But the frequency of bladder recurrence after nephroureterectomy for UUT-UC is not rare. Based on the intraluminal seeding hypothesis, it is reasonable to assume that early ligation of the ureter distal to the tumor site during surgery might reduce subsequent bladder tumor development. However whether early ligation of the ureter during surgery reduces subsequent bladder tumor development has not been determined. In this study, we attempt to validate the effect of early ligation of the ureter during surgery.

**Methods:** A total of 229 patients underwent nephroureterectomy for UUT-UC between January 2005 and December 2007. The clinicopathologic data for the remaining 205 patients with UUT-UC were retrospectively reviewed. In a total of 76 of 205 patients, early ligation of the ureter during surgery was performed. We defined early ligation of the ureter as ligating the ureter immediately after the ligation of the renal artery. The following variables were evaluated for association with the bladder recurrence: sex, age, tumor stage, tumor grade, venous invasion, lymphatic invasion, tumor location, multifocality, surgical technique, time of ligation of the ureter and preoperative cytology. The significance of each variable was tested univariately with the log-rank test. The simultaneous effects of multiple risk factors were estimated by multiple regression analysis by using the Cox proportional hazards model.

**Results:** The median follow-up after nephroureterectomy was 16.6 months (range 0.3 to 38.8 months). Bladder tumor recurrence occurred in 82 patients (40.0%). Significant risk factors for bladder recurrence on univariate analysis were time of ligation of the ureter ( $p=0.0383$ ), preoperative urine cytology positive ( $p=0.0317$ ) and tumor location ( $p=0.0352$ ). Multivariate analysis revealed that time of ligation of the ureter, tumor location and preoperative cytology positive were significant for bladder recurrence.

**Conclusion:** Risk factors of subsequent development of bladder cancer after nephroureterectomy were time of ligation of the ureter, tumor location and preoperative cytology positive. The possibility that early ligation of the ureter during operation contributes to reduce the risk of subsequent development of bladder cancer after nephroureterectomy was showed.

### MP19-14 THE USE OF ENDOPROSTHESIS IN THE MANAGEMENT OF IATROGENIC URETERIC STRICTURES OR FISTULA CAUSED BY SURGERY COMPLICATIONS

J. Torrecilla García-Ripoll, S. Martín Martín, J. Trueba Arguiñarena, S. Alonso Menéndez, M. López Pedreira, E. Fernández del Busto—Spain

**Background:** We report our initial experience with a self-expanding nitinol stent covered with expanded polytetrafluoroethylene (ePTFE) in the treatment of ureteric strictures or fistula caused by gynecologic and abdominal surgery complications.

**Methods:** Between 2001 and 2009 we evaluated the treatment of seven patients with iatrogenic ureteral injury consequent upon



gynecological surgery (five ureteral obstructions and two ureteric fistula) and four patients with ureteric fistula secondary to surgical treatment of recto-sigma tumors. We implanted a flexible, self-expanding endoluminal endoprosthesis consisting of an expanded polytetrafluoroethylene (ePTFE) lining with an external nitinol (NiTi = Nickel: Titanium) support extending along its entire length. The endoprosthesis is compressed and attached to a dual lumen delivery catheter. The larger central catheter lumen is used for flushing and guidewire introduction. The smaller lumen contains elements of the deployment mechanism. The delivery catheter hub assembly has one port for the deployment system and one port for flushing and guidewire insertion. To facilitate accurate endoprosthesis placement, two radiopaque metallic bands are attached to the catheter shaft, marking the ends of the compressed endoprosthesis. In general the stents were introduced by using a retrograde approach under combined endoscopic and fluoroscopic guidance with patients under spinal block and sedation. Followup assessments in 18 patients, including urography, were done 3, 6, 12, 18 and 24 months after the procedure.

**Results:** Stents were placed 2 to 24 months, with a mean follow-up of 48 months. The average hospital stay was 2.1 days (1–8). There were no early post operative complications. Symptomatic vesico-ureteral reflux rate was 18% (2 cases). Four patients died of the neoplastic process 3 to 12 months after implantation.

**Conclusion:** We found that ePTFE covered nitinol stents were safe, uncomplicated and efficient for ureteral fistula and stenosis, specially in oncological patients, reducing hospital stay and offering a significant improvement in quality of life.

### MP19-15 COMPARISON OF OPTICAL RESOLUTION WITH DIGITAL AND STANDARD FIBEROPTIC URETERORENOSCOPES IN AN IN VITRO MODEL

K. Nutahara, T. Shishido, T. Okegawa, E. Higashihara—Japan

**Background:** Distal video sensor chips have been recently introduced into clinical endoscopy in the form of “chip on a stick” endoscopes. We compared two different digital flexible ureterorenoscopes with standard fiberoptic ureterorenoscope for optical resolution.

**Methods:** The two digital flexible ureterorenoscopes, Olympus URF-V and Olympus ACMI DUR-D, were compared with the standard flexible ureterorenoscope, Olympus URF-P5, in an in vitro model. We evaluated the optical resolution of each scope using resolution chart through four solutions with progressively increasing concentration of sheep blood (0, 3, 15 and 30% solutions). Four distances from the tip of each scope to the resolution chart were varied at 5, 10, 15 and 20 mm.

**Results:** The optical resolutions of URF-V, DUR-D and URF-P5 were 19.95, 11.22 and 6.31 lp/mm in the saline at 5 mm distance, respectively. At 15% concentration, the resolutions of URF-V, DUR-D and URF-P5 were 14.13, 7.94 and 5.01 lp/mm at 5 mm distance, respectively. The URF-V was showed the best optical resolution, especially less than 10 mm distances at all concentrations. Two digital flexible scopes performed equivalently in objective distances of 15 and 20 mm.

**Conclusion:** The results of this in vitro study suggest that the digital flexible ureterorenoscopes improve visibility in comparison with fiberoptic ureterorenoscope. The URF-V is maintained the good optical resolution in hematuria.

### MP19-16 BIPOLAR PERCUTANEOUS RESECTION OF RENAL CYSTS AND CALYCEAL DIVERTICULA: AN INTERMEDIATE-TERM ANALYSIS

R. Korets, M. Lee, K. Xavier, M. Gupta—USA

**Background:** Use of bipolar electrocautery has been studied in the management of benign prostatic hyperplasia, with a major advantage of bipolar energy being the ability to use isotonic saline as the irrigant solution with demonstrated minimal changes in serum sodium despite long operative times. We previously reported on the use of bipolar system in transparenchymal endocystolysis and percutaneous ablation of caliceal diverticula. percutaneous resection of renal cysts and caliceal diverticula. Herein we present our follow-up series.

**Methods:** Between November 2006 and May 2009, fifteen patients with caliceal diverticula and renal cysts underwent percutaneous ablation using bipolar resection system and saline irrigation. (Group 1) These were compared to a cohort of 8 patients who underwent traditional ablation with a monopolar resectoscope, roller ball electrode, and glycine irrigation. (Group 2) Parameters compared included operative time, change in perioperative hematocrit and sodium and surgeon’s subjective analysis of completeness of ablation without perforation and extravasation.

**Results:** There were no perioperative or postoperative complications. Subjectively surgeons felt the bipolar equipment allowed for more thorough ablation and for fewer perforations of the lining. Mean percent decrease in hematocrit was 2.75 in group 1 and 4.4 group 2 ( $p=0.11$ ). Mean decrease in sodium was  $-0.56$  mEq/L in group 1 and 4.0 mEq/L in group 2 ( $p=0.001$ ).

**Conclusion:** Percutaneous ablation of caliceal diverticula and renal cysts using bipolar resection system is feasible and appears to have efficacy similar to that of the monopolar system. Use of isotonic saline as the irrigation medium decreases risk of postoperative hyponatremia associated with hypo-osmolar irrigation utilized in monopolar resection.

### MP19-17 THE FACTORS AFFECTING NON-UROLOGIC POSTOPERATIVE COMPLICATIONS AFTER A LAPAROSCOPIC SURGERY IN UROLOGIC AREA

J. Lee, S. Lee, H. Lee, J. Kim, S. Jeon

**Background:** We examined the factors related to complications and isolated the most significant ones.

**Methods:** We analyzed the medical records of 154 patients who had received a laparoscopic surgery between March 2004 and March 2008. We surveyed their age, anesthetic time, American Society of Anesthesiologists Physical Status (ASA) classification, operative difficulty, blood loss (ml), body mass index (BMI) and complications. Complications were divided into 5 groups based on the modified Clavien classification. We performed the Armitage Trend Test to search out the relations between the factors and the complications. We performed a univariate analysis and a multivariate analysis to find out the risk ratio of each of the factors and the most significant factors.

**Results:** Complications tend to increase as the anesthetic risk and anesthetic time increased ( $p=0.011$ ,  $0.013$ ). Operative difficulty and blood loss were related to complications ( $p=0.018$ ,  $p<0.001$ ). The univariate analysis revealed that blood loss of more than 400 ml had a risk ratio of 18.2 compared to less than 200 ml. Moderate and hard operative difficulties had a significant risk ratio of around 4, and the high anesthetic risk had a high risk

rate of around 5. The multivariate analysis showed that blood loss and high anesthetic risk are independent risk factors of complications.

**Conclusion:** Blood loss and high anesthetic risk proved to be independent factors which are associated with complications. Surgeons must keep in mind of patient's anesthetic risk and try to minimize blood loss during operation to reduce complications after a laparoscopic surgery.

### MP19-18 COMPARISON OF MALIGNANCY IN COMPLEX CYSTIC VERSUS SOLID SMALL RENAL MASSES

V. Ta, S. Wu, D. Rebuck, K. Perry, N. Smith, R. Nadler

**Background:** Widespread use of cross-sectional imaging has led to and increase in the detection of incidental renal masses. Nephrectomy has been traditionally recommended for enhancing renal masses due to the potential for malignancy. This course of management may be less beneficial for small renal masses (SRMs) since some reports suggest that many SRMs are benign. Clinical decisions would be improved by better understanding radiographic predictors of malignancy. In this study, we sought to determine if enhancing complex cystic SRMs are more likely to be benign than solid SRMs.

**Methods:** Cases were identified by searching the electronic medical records at Northwestern Memorial Hospital for all patients who underwent surgical excision of a renal mass between October, 2002, and May, 2008. The surgical pathology reports were retrospectively reviewed, and cases were excluded if the greatest dimension of the solid component of the renal mass was  $>3.0$  cm. SRMs were classified as a solid tumor or complex cystic lesion  $\leq 3.0$  cm.

**Results:** Of 702 surgical treatments reviewed, 343 cases involved excision of renal masses  $\leq 3.0$  cm. Eighty two of these masses (24%) were cystic and of these, 72% were found to be malignant. In comparison, 261 masses (76%) were solid and 74% of these were malignant. There was no statistically significant difference ( $p = .77$ ) of risk of malignancy between solid and complex cystic SRMs.

**Conclusion:** These data suggest that complex cystic SRMs are as likely as solid SRMs to be malignant. The presence of complex cystic features on renal imaging of SRMs should not be thought to predict a benign pathology.

### MP19-19 CORRELATION OF GFR TO NEPHRON LOSS IN LIVING RENAL DONORS

J. Page, S. Strup—USA

**Background:** Glomerular Filtration Rate (GFR) has been reported and utilized to evaluate nephron loss following radical and partial nephrectomy. GFR prior to and following donor nephrectomy was compared to evaluate correlation of GFR to 50% renal volume loss.

**Methods:** 55 consecutive hand-assisted laparoscopic donor nephrectomies (HALDN) performed between 2006–2009 were

retrospectively evaluated. All donors underwent extensive preoperative screening including CT angiography prior to donation. GFR was calculated using the Modification of Diet in Renal Disease (MDRD) equation for 51 pts having preoperative, 24 hours postoperative and 7–21 day postoperative creatinine values. Of these, 33 patients had GFR values  $>6$  months postoperatively which were compared to those at 1–3 weeks.

**Results:** 51 patients demonstrated an average 41.7% (range 15.7–56.6%; median 43%;  $p < .05$ ) decrease in GFR at postoperative day one following donor nephrectomy. 1–3 weeks postoperatively average GFR decrease was 34.5% (range 7.8–52.5%; median 33.7%;  $p < .05$ ). This was statistically improved versus GFR at postop day 1 ( $p < .05$ ). At  $>6$  months 33 patients showed no difference between GFR decrease at 1–3 weeks and GFR at  $>6$  months (34.2% loss vs. 32.8% respectively;  $p = .25$ )

**Conclusion:** GFR decrease does not correlate with 50% volume renal loss following the immediate postoperative period. GFR improves 1–3 weeks post-nephrectomy but insignificant gains are made thereafter.

### MP19-20 HISTOTRIPTY OF RENAL VX-2 TUMOR IN A RABBIT MODEL: FEASIBILITY

J. Wheat, T. Hall, K. Wojno, C. Cain, W. Roberts—USA

**Background:** We have previously demonstrated that histotripsy, a non-invasive focused ultrasound technology can produce non-thermal, mechanical tissue fractionation (ablation) in normal biologic tissues. The purpose of this study was to assess local histotripsy bioeffects on tumor tissue in-vivo.

**Methods:** VX2 tumor volumes ( $8\text{mm}^3$ ) were implanted under the renal capsule of the left kidney in 10 rabbits using an open surgical approach. In five rabbits diagnostic ultrasound was used to localize the tumors, two weeks following implantation. Targeted volumes within the tumor were treated with histotripsy by delivering acoustic energy from a 1 MHz, 4-element extracorporeal transducer in the form of 5 microsecond pulses at 500 Hz for 5 minutes. Four kidneys were harvested immediately after treatment and one 24 hours later. In five control rabbits the kidneys were harvested one to two weeks after implantation.

**Results:** In all rabbits, implanted tumors were invasive into renal tissue and exhibited central necrosis with faint cellular staining, shrunken cell walls, and lack of nuclei. In 3 of the 5 kidneys treated with histotripsy, zones of fractionated tumor containing acellular debris and finely disrupted cellular architecture could be seen histologically and spatially distinct from the central tumor necrosis.

**Conclusion:** Histotripsy is capable of producing fractionation of malignant as well as benign tissues. These results provide a starting point for more elaborate studies to assess the local and systemic response when applying histotripsy to malignant tissues.

## MP20: LAPAROSCOPIC—KIDNEY 2

### MP20-01 MICROPARTICULATE ICE SLURRY FOR RENAL HYPOTHERMIA: LAPAROSCOPIC PARTIAL NEPHRECTOMY IN A PORCINE MODEL

S. Shikanov, M. Wille, M. Large, A. Razmaria, D. Lifshitz, A. Shalhav—USA

**Background:** Microparticulate ice slurry is a highly fluidic coolant prepared from ice and saline that may be used for local hypothermia during laparoscopy. This study evaluated the ice slurry for renal cooling during laparoscopic partial nephrectomy (LPN) in an animal model, compared to surface cooling with near-frozen saline and warm ischemia (WI).

**Methods:** An acute single-kidney (right nephrectomy) porcine model was used. In Phase 1, three groups comprising 6 animals each underwent left LPN—90 min ischemia and 90 min renal cooling, with either slurry (Slurry 1), saline (Saline1) or WI. In Phase 2, to simulate more extreme conditions, we extended ischemia time to 120 min and reduced cooling to 10 min with either ice slurry (Slurry 2, n=6) or saline (Saline 2, n=6) during LPN. Renal and core temperature were recorded intra-operatively, serum Creatinine was measured at 1, 3, 7, 14 days post-surgery.

**Results:** The ice slurry was easily produced and delivered. Irrigation and suctioning of near-frozen saline caused frequent surgery interruption. Nadir renal temperature (Mean  $\pm$  SD) was  $8 \pm 4$ C in Slurry 1 versus  $22.5 \pm 3$ C in Saline 1 group ( $p < 0.0001$ ), and  $9 \pm 1$ C versus  $22 \pm 2$ C in Slurry 2 and Saline 2 groups, respectively. Renal re-warming to 30C took  $61 \pm 7$  min in Slurry 2 versus  $24 \pm 6$  min in Saline 2 ( $p < 0.0001$ ) groups. Nadir core temperature was 37C in Slurry groups versus 35C in Saline groups ( $p < 0.0001$ ). Serum Creatinine did not differ between Slurry 1 and Saline 1 (but was 7-fold lower compared to WI,  $p < 0.0001$ ) groups and Slurry 2 and Saline 2 groups at any time.

**Conclusion:** Microparticulate ice slurry provides superior renal and less systemic hypothermia compared to near-frozen saline during LPN in porcine model. The similar renal function outcomes may be due to extreme resilience of porcine kidneys to ischemia.

### MP20-02 EXTRAPERITONEAL LAPAROSCOPIC RETROPERITONEAL RADICAL LYMPHADENECTOMY IN 3 CASES

Y. Changjun

**Background:** To investigate surgical techniques and the clinical feasibility of extraperitoneal laparoscopic retroperitoneal lymph node dissection (EL-RLND) in right side.

**Methods:** Three patients with primary testicular nonseminomatous germ cell tumors (NSGCT) received EL—RLND at weeks after orchiectomy. The patients were given general anesthesia and placed in supine position with 15 degree tilted up in right side. Five ports were introduced and Gerota's fascia was incised to exposed the major vessels along the midline. The remnant seminal duct was dissected and clipped above the inguinal ring. The gonad vein was isolated till the level of its root and then divided. Lymphadenectomy was then performed along the vena cava. The boundaries of dissection included renal vein (proximal), bifurcation of common iliac vessel (distal), ureter (lateral) and para-aorta area (medial).

The specimen were retrieved through the ports and drainage tube was placed after the operation.

**Results:** The EL-RLND was successfully performed in all the 3 patients. The operating time was 180 min, the intraoperative blood loss was 350 ml, the postoperative intestinal function recovery time was 2 days, and the average hospital stay was 7 days. Follow-up revealed no evidence of recurrence or distant metastasis.

**Conclusion:** Retroperitoneal laparoscopic retroperitoneal radical lymphadenectomy which can be further applied is an operation for nonseminomatous testis cancer with minimal invasiveness, quick recovery. Because it is a difficult and complicated procedure performed near the large vessels, EL—RLND needs more experiences on laparoscopic techniques to minimize complications.

### MP20-03 RISK FACTORS FOR PERSISTENT HYPERTENSION AFTER LAPAROSCOPIC ADRENALECTOMY IN PATIENTS WITH ALDOSTERONE PRODUCING ADENOMA

T. Kwon, T. Kim, E. Yoo, Y. Park, J. Kim, H. Kim—Korea

**Background:** Hypertension due to aldosterone producing adenoma can be cured by adrenalectomy. However, some patients with aldosterone producing adenoma suffered from persistent hypertension even after adrenalectomy. We analyzed the efficacy of laparoscopic adrenalectomy in patients with hypertension and potential risk factors for postoperative persistent hypertension in aldosterone producing adenoma.

**Methods:** Between January 2002 and May 2008, a total of 31 patients with aldosterone producing adenoma underwent laparoscopic adrenalectomy. The patients' medical records were analyzed retrospectively including perioperative parameters and blood pressure changes.

**Results:** The patients' mean age was 45.6 (28–64) years and there were 12 men and 19 women. Mean operation time was 161.6 (90–230) minutes and mean blood loss was 141.9 (50–500) ml. There was no intraoperative or postoperative complication. During mean follow-up of 23.4 (13–84) months, 22 patients (70.9%) required no further antihypertensive treatment. Remaining 9 patients (29.1%) still required anti-hypertensive medication. Four of the 9 patients could reduce their dosage of anti-hypertensive medications after operation. Sex and tumor size were statistically significant factors for persistent postoperative hypertension ( $p = 0.041$  and  $0.026$ , respectively). There was no relationship between persistent postoperative hypertension and age, duration and dosage of preoperative anti-hypertensive medication or family history of hypertension.

**Conclusion:** Laparoscopic adrenalectomy is an effective and safe treatment in patients with aldosterone producing adenoma. Male and larger tumor size ( $>2$  cm) seems to be predictable factors of persisting postoperative hypertension.

### MP20-04 IMPACT OF LYMPH NODE DISSECTION ON DISEASE-FREE SURVIVAL IN PATIENTS WITH UROTHELIAL CARCINOMA OF THE RENAL PELVIS; COMPARISON BETWEEN LAPAROSCOPIC AND OPEN SURGERY

Y. Matsukawa, R. Hattori, Y. Yoshino, O. Kamihira, T. Kinukawa, M. Gotoh

**Background:** Laparoscopic surgery has widely been applied to nephroureterectomy for urothelial carcinoma (UC) of the renal pelvis. Although several recent reports support the benefits of extended lymph node dissection (LND) combined with nephroureterectomy, this procedure is technically difficult under laparoscopy. To compare an oncological outcome of laparoscopic nephroureterectomy (LNU) and open nephroureterectomy (ONU) for UC, impact of LND should be taken into consideration. In this study we assessed disease-free survival after nephroureterectomy with a bladder cuff and simultaneous lymph node dissection and compared the results between conventional ONU and LNU.

**Methods:** We retrospectively reviewed the database of 226 patients undergoing nephroureterectomy with a bladder cuff and LND for UC of the renal pelvis with clinical stages of T1-3N0M0, between August 1997 and April 2008. Of these patients, 108 underwent LNU via a retroperitoneal approach and 118 underwent ONU. We classified LND into 3 categories (extended, limited, and no LND) according to the extent of dissection. Extended LND was defined as dissecting renal hilus and para-aortic nodes for the left, and as dissecting renal hilus, para-caval, and inter-aorto-caval nodes for the right. Para-aortic, para-caval and inter-aorto-caval nodes were dissected with the level from the renal hilus to the inferior mesenteric artery. Limited LND indicated renal hilus node dissection alone. An actuarial 5-year disease-free survival (DFS) rate was assessed as survival without distant metastasis and local recurrence except bladder tumors.

**Results:** Patients mean age was 66.0 years in LNU group and 67.5 years in ONU group. Mean follow-up periods were 50 months for LNU group and 65 months for ONU group. Metastasis of the resected lymph nodes was pathologically positive in 6 patients (5.6%) in LNU group and 7 (5.9%) in ONU group with no statistical difference between the 2 groups. The numbers of patients undergoing extended LND, limited LND, and no LND were 30, 48, and 30 in LNU group, and 72, 26, and 20 in ONU group, respectively. Number of patients undergoing extended LND was significantly higher in ONU group than in LNU group. Actuarial 5-year DFS rate was 80.2% in LNU group and 86.1% in ONU group, which was not statistically different. Furthermore we compared the impact of the extent of LND on DFS among 3 groups. In LNU group, 5-year DFS rate was 84.4% in patients with extended LND, 82.4% in those with limited LND, and 66.3% in those with no LND. In ONU group, 5-year DFS rate was 91.3% in patients with extended LND, 86.3% in those with limited LND, 71.7% in those with no LND. DFS in patients with extended LND was significantly higher than that in those with limited LND or no LND.

**Conclusion:** Oncological outcomes of LNU and ONU are comparable on condition that appropriate LND is simultaneously conducted, and extended LND would be preferable for patients with advanced stages in LNU as well as in ONU.

#### **MP20-05 SIMULTANEOUS TRANSPERITONEAL AND RETROPERITONEAL HAND-ASSISTED LAPAROSCOPIC NEPHROURETERECTOMY WITH BLADDER CUFF EXCISION**

S. Jung, M. Gil, S. Kim, J. Ha, S. Yoon, J. Chung—South Korea

**Background:** The goals of managing upper urinary tract tumors are to control cancer, as well as to improve the quality of life including reducing pain and skin incision. The aims of this study are to present the clinical outcomes of 25 patients who underwent simultaneous transperitoneal and retroperitoneal hand-assisted

laparoscopic nephroureterectomy (HALNU) and to evaluate efficiency of this operative method.

**Methods:** HALNU was performed for 25 cases of cT1-2N0M0 upper urinary tract tumors. We evaluated the operation times, blood loss, transfusion episodes, severity of pains, difference of pain control method, hospital stays, diet resumption, complications and recurrences of tumors. HALNU was performed according to the simultaneous transperitoneal and retroperitoneal approach with paraumbilical muscle-splitting skin incision. The nephrectomy was done by transperitoneal hand-assisted laparoscopic approach. The lower ureter was resected retroperitoneally by open surgical approach through the same paraumbilical skin incision, after suturing of peritoneal opening. The resected specimen was removed through the same skin incision retroperitoneally.

**Results:** Parameters: HALNU Lt / Rt 11 / 14 Op.times (mins) 203 ± 87 (185 ~ 295) Hosp.stays (days) 7.5 (6 ~ 11) Blood loss (cc) 155 ± 135 (95 ~ 330) NSAID(person) 25 Diet resumption (days) 2.5 ± 3.5 (1 ~ 5) Drain remove (days) 2.7 (2 ~ 5) Conversion to open surgery 0 Transfusions 0 complications 3 Recurrences 1

**Conclusion:** HALNU has good operative outcomes. During follow up periods, we had no recurrent cases. We could achieve the goals of cancer control, as well as improving the quality of life including reducing pain and small skin incision.

#### **MP20-06 LAPAROSCOPIC LYMPHADENECTOMY FOR NODAL RECURRENCE FOLLOWING RADICAL PROSTATECTOMY: THE ROLE OF INTEGRATED 18F-CHOLINE PET-CT**

G. Simone, R. Papalia, S. Guaglianone, A. Bove, E. Forastiere, M. Gallucci

**Background:** We report the feasibility of laparoscopic lymph node dissection (lap-LND) for nodal recurrence of prostate cancer following radical prostatectomy and the accuracy of integrated 18F-choline PET-CT matching the imaging with the pathologic reports.

**Methods:** We retrospectively reviewed results of a preliminary series of 8 patients treated with lap-LND on the base of a suspicious nodal relapse following radical prostatectomy detected by integrated 18F-choline PET-CT. Four patients were treated with androgen deprivation therapy (ADT) at the time of PET-CT while 4 patients were untreated. All patients selected for LND had PSA increasing levels with DRE, CT scan and bone scintigraphy negative for clinical signs of recurrences. The LND template was planned on the base of PET-CT and was not extended to PET-CT negative lymph node. ADT was not administered to any patient up to PSA double-folding following nadir.

**Results:** Median preoperative PSA level was 4.2 ng/mL (range 0.3 to 8.27) in the group of patients not receiving ADT at the time of PET-CT and 1.75 (range 1.3 to 2.5) in the group of patients treated with ADT. The comparison of PET-CT findings with histological evaluation of lymph nodes removed highlighted a 100% concordance. With regard to the effectiveness of lap-LND in patients not receiving ADT at the time of PET-CT, the median time to nadir was 2.2 months and the median time to PSA relapse (considered as double folding following the nadir) was 8 months. In the group of patients treated with ADT at the time of PET-CT the median time to nadir was 1.2 months and the median time to PSA relapse was 6 months.

**Conclusion:** The integrated 18F-choline PET-CT detected nodal recurrences with a 100% accuracy. Although it can be assumed as an useful guide to define the appropriate template of lap-LND the

effectiveness of surgery in these patients need to be further investigated.

### MP20-07 FACTORS AFFECTING BLOOD LOSS DURING PARTIAL NEPHRECTOMY

U. Boylu, A. Tracey, M. Pinsky, M. Hopkins, R. Thomas, B. Lee—USA

**Background:** For treatment of small renal masses, partial nephrectomy has become a standard of care. The purpose of the study was to identify risk factors potentially associated with increased blood loss during partial nephrectomy.

**Methods:** After obtaining Institutional Review Board approval, a retrospective chart review was performed for a total of 144 patients who underwent partial nephrectomy at the Tulane Medical Center between 1999 and 2008 (39 open, 90 laparoscopic, and 15 robotic). Mean follow-up time was 34 months (range: 6–96 months). Effects of age, gender, race, tumor side, tumor size, ischemia time, operative time, and medical comorbidities (diabetes, coronary artery disease, hypertension, peripheral vascular disease (PVD), hypothyroidism, myocardial infarction, and atrial fibrillation) on intraoperative blood loss were evaluated with statistical analysis.

**Results:** Median estimated blood loss was 200 ml (interquartile range: 100–500). There were positive correlations between blood loss and tumor size ( $r=0.24$ ,  $p=0.01$ ) and operative time ( $r=0.39$ ,  $p=0.02$ ). Factorial ANOVA revealed that simultaneous presence of hypertension and PVD significantly increased blood loss ( $R^2=0.098$ ,  $p=0.001$ ). In these 5 patients who had hypertension and PVD risk factors, mean blood loss was 2187 ml (tumor size 2.5–5.4 cm) compared to the rest of the cohort ( $p=0.032$ ). Other comorbidities did not demonstrate a statistically significant effect on hemorrhage during partial nephrectomy.

**Conclusion:** The operative time and the tumor size are positively correlated with blood loss during partial nephrectomy. The presence of hypertension and PVD simultaneously significantly increases the risk of hemorrhage during partial nephrectomy.

### MP20-08 CONTEMPORARY SURGICAL MANAGEMENT AND RESULTS OF EXTRA-ADRENAL PHEOCHROMOCYTOMA: THE ROLE OF OPEN AND LAPAROSCOPIC APPROACHES

E. Metrebian, T. Pinheiro, F. Lima, F. Messetti, V. Ortiz, C. Andreoni

**Background:** Extra-Adrenal Pheochromocytomas (EAP) are uncommon chromaffin cell neoplasms that develop from the neural crest cells. The standard of care for treatment of these tumors is complete surgical resection to prevent complications associated with catecholamine excess production. Improvements in laparoscopic techniques, surgeon's skills and instrumentation have expanded the role of laparoscopic approaches in the treatment of EAP. We report our experience with surgical management of abdominal EAP with open and laparoscopic resection.

**Methods:** Eight patients with EAP underwent surgical removal. Biochemical testing included plasma and urine catecholamines measurements. All patients were evaluated with computed tomography; magnetic resonance imaging and metaiodobenzylguanidine (MIBG) scintigraphy were performed in selected patients. Alpha-adrenergic blockade was initiated prior to surgery. Open

surgery was performed in four patients and the other 4 patients underwent a laparoscopic procedure.

**Results:** Mean age was 30 years. All the patients presented with hypertension. One patient was pregnant and other patient presented with malignant EAP with multiple tumors. Surgical removal was successful in all cases. In laparoscopic cases there were no conversions to open surgery, and mean operative time was 142 minutes. There has been no evidence of tumor recurrence during followup.

**Conclusion:** Surgical resection of EAP requires careful preoperative planning because of frequent intimacy to major vascular vessels and multicentricity. Laparoscopic surgery can be safely performed by experienced surgeons, and is associated with decreased perioperative morbidity. Open surgery is generally reserved for very large tumors or presence of anatomic factors that could make laparoscopic resection difficult.

### MP20-09 ONCOLOGIC OUTCOMES OF SURGICAL MARGIN POSITIVE PATIENTS FOLLOWING PARTIAL NEPHRECTOMY

M. Pinsky, U. Boylu, A. Tracey, M. Hopkins, B. Lee—USA

**Background:** Partial nephrectomy has become a standard of care for treatment of renal cell carcinoma (RCC). The purpose of this study is to assess oncologic outcomes of patients with positive surgical margins after partial nephrectomy with intermediate follow-up.

**Methods:** After Institutional Review Board approval, a retrospective review was conducted for 144 partial nephrectomies (39 open, 90 laparoscopic, 15 robotic) performed from February 1999 to May 2009 to review pathology and surgical margin status. Records of 17 patients (12%) with positive margins who had follow-up of greater than 6 months were analyzed (1 open and 16 laparoscopic cases) in a retrospective review of their postoperative follow-up. Postoperative follow-up methods included CT scan, MRI, renal ultrasound, chest x-ray, and routine chemistries. Kaplan-Meier survival analysis of these patients was then performed.

**Results:** Mean follow-up time was 34 months (range: 6–96 months). 2 (12%) patients died, both from unrelated non-cancer causes. None of the patients demonstrated any sign of recurrence. Estimated overall survival for patients with positive surgical margins is 90.7 months (95% CI: 76.6 to 104.8 months).

**Conclusion:** Oncologic surgical principles should always be adhered to with a goal of negative margins. A detailed discussion of options should always ensue in the setting of positive margins including conservative management with close follow-up imaging, re-resection, or completion nephrectomy.

### MP20-10 COMPARISON OF LAPAROSCOPIC AND OPEN PARTIAL NEPHRECTOMY IN T1A RENAL CELL CARCINOMAS: A MULTICENTER ANALYSIS IN KOREA

S. Byun, S. Kang, T. Kwon, I. Seo, T. Hwang, K. Rha

**Background:** We analyzed series of laparoscopic partial nephrectomy (LPN) and open partial nephrectomy (OPN) to compare outcomes of the 2 procedures in patients with T1a renal cell carcinoma (RCC).

**Methods:** From January 1998 to May 2009, 316 LPNs and 328 OPN were performed for patients with small renal tumor in 13

institutions in Korea. Out of those patients, 194 and 265 patients were confirmed to have pT1a RCC, respectively. The cohorts were compared with regard to demographics, perioperative data, and outcomes.

**Results:** Demographic data were similar between the two groups. Although tumor location was more exophytic in the laparoscopic cohort (56% vs 43%,  $p=0.008$ ), the OPN cohort demonstrated shorter ischemia times (23.2 vs 31.3 min,  $P < 0.001$ ). The LPN was associated with less blood loss (296 vs 425 mL,  $P < 0.001$ ). Nine and seven patients had positive surgical margin in the LPN and OPN groups respectively. Intraoperative complications and postoperative complications were similar. Of note, two LPN (1.0%) patients had open conversion and nephrectomy was performed because of intraoperative hemorrhage. Recurrence free survival rates of both cohorts were not significantly different ( $p > 0.05$ ).

**Conclusion:** The LPN group demonstrated significantly less blood loss while showing similar rates of recurrence-free survival and complication compared with OPN group. Thus, LPN may be an acceptable alternative to OPN in patients with small RCC.

### MP20-11 EVALUATION ROBOTIC-ASSISTED LAPAROSCOPIC ADRENALECTOMY: OUR FIRST EXPERIENCE OF 10 PATIENTS

L. Yong Seong, S. Ha Jeong, C. Sang Hoon, L. Young Goo

**Background:** Robotic-assisted laparoscopic adrenalectomy (RLA) has become an accepted surgical procedure for resection of benign adrenal lesions recently. We reviewed our experience and report our results.

**Methods:** 10 patients (4 male and 6 female, 6 right and 4 left, age 28–56 years old) underwent RLA from June 2008 to May 2009. We used transperitoneal approach with 4 or 5 ports (3 robot ports, 1 or 2 assistant ports). In 6 right RLA, after hepatocolic ligament division, we dissected triangle area (liver undersurface, kidney upper pole, inferior vena cava) and transected adrenal vein. The en-block adrenal gland along with its surrounding fat was removed.

**Results:** All procedures were completed with no intra-operative complications. The mean operative time was 115 minutes (90–160). Estimated blood loss was 150 ml (50–210). Mean hospitalization day was 7 days. Pathology was all benign lesions.

**Conclusion:** Robotic-assisted laparoscopic adrenalectomy is feasible, safe and effective treatment method of adrenal benign lesions.

### MP20-12 EVALUATION OF THE SAFETY OF PERIOPERATIVE ENOXAPARIN ADMINISTRATION IN PATIENTS UNDERGOING ROBOTIC-ASSISTED LAPAROSCOPIC RADICAL PROSTATECTOMY

J. Yates, J. Uberoi, I. Sawczuk, D. Golombos, M. Gross, R. Munver—United States

**Background:** Patients undergoing robotic-assisted laparoscopic radical prostatectomy (RALP) are at increased risk for deep venous thrombosis (DVT) due to advanced age, surgery for pelvic malignancy, and procedure duration. We evaluated the safety of perioperative enoxaparin for patients undergoing RALP.

**Methods:** This prospective randomized study included 112 consecutive patients with localized prostate cancer that underwent RALP. Patients either received preoperative enoxaparin (40 mg subcutaneously) one hour prior to surgery and another dose in the

morning of the first postoperative day (enoxaparin group), or did not receive enoxaparin (control group). All patients had lower extremity sequential compression devices during surgery. Perioperative data included blood loss, operative time, subjective assessment of intraoperative bleeding, and blood transfusion rates.

**Results:** Of 112 patients, 58 received perioperative enoxaparin and 54 did not. Mean patient age was 59 (range 42–73) [enoxaparin group] and 60 (range 49–71) [control group]. Blood loss was 169 mL (range 25–450) [enoxaparin group] and 154 mL (50–350) [control group]. No patients required blood transfusions. Mean operative time was 127 min (range 72–182) [enoxaparin group] and 132 min (range 95–175) [control group]. Blood loss and operative times were not statistically significant between the two groups. Subjectively, surgeons rated the enoxaparin group as having increased intraoperative bleeding based on blinded video review of each procedure. One patient in the control group developed postoperative DVT that required anticoagulation.

**Conclusion:** Perioperative enoxaparin administration was associated with a subjective perception of increased intraoperative bleeding, although the mean blood loss was not statistically significant between the groups. Enoxaparin administration appears safe for patients undergoing RALP and may be considered for patients that are at increased risk.

### MP20-13 DELAYED HEMORRHAGE AFTER LAPAROSCOPIC PARTIAL NEPHRECTOMY: FREQUENCY AND ANGIOGRAPHIC FINDINGS

S. Montag, C. Seideman, A. Rastinehad, M. Vira, L. Richstone, L. Kavoussi

**Background:** Postoperative hemorrhage is a well recognized complication of laparoscopic partial nephrectomy (LPN). The significance of delayed post-operative bleeding following LPN is not well documented. We sought to determine the frequency of delayed post-operative hemorrhage requiring selective angioembolization (SAE) after LPN, describe the clinical presentation and characterize the angiographic findings encountered in this setting.

**Methods:** Prospective data from 640 LPN performed between August 1993 through May 2009 were retrospectively analyzed. Patients with delayed postoperative hemorrhage (defined as  $>7$  days after discharge) requiring SAE were identified. Clinicopathological, preoperative and perioperative factors were reviewed. Selective catheterization and angiography of the renal artery at the site of LPN were performed when hematuria persisted, the patient showed hemodynamic instability or significant drop in hematocrit level. The feeding arteries of the bleeding site were identified and embolized with coils.

**Results:** Selective angioembolization was required in 14 patients (2.2%) for delayed postoperative bleeding. Of the 640 cases 68 (10.6%) were done off-clamp and one of these patients (1.5%) had a delayed hemorrhage, which was successfully embolized. The mean tumor size was 2.78 cm, mean warm ischemia time was 21.3 minutes, mean estimated blood loss 275 cc. Percutaneous angiography demonstrated pseudoaneurysm in 10 patients and arterial contrast extravasation in 4 patients two of whom also had an arteriovenous fistula. Creatinine levels remained stable in all patients.

**Conclusion:** Clinically significant delayed postoperative bleeding following LPN is an unusual event. When required, SAE is a safe

and effective modality that allows for maximal renal preservation in this setting.

#### **MP20-14 EARLY EXPERIENCE WITH LAPAROSCOPIC SURGERY OF TWO YOUNG UROLOGISTS**

F. Vicentini, M. Hisano—Brazil

**Background:** To report the experience with laparoscopic surgery of two beginners urologists within 3 years after the end of the residency program.

**Methods:** We reviewed the records of the patients that underwent to laparoscopic surgery for any type of urological disease performed by at least one of the authors without a senior urologist supervisor within three years after the end of the residency program. We analyzed age, sex, pathology, type of surgery, access (retroperitoneal (RP), transperitoneal (TP) or extraperitoneal (EP)), intra and postoperative complications, transfusion rate and surgical time.

**Results:** Fifty patients (36 male) with mean age of 54.6 years (23 to 84) underwent to fifty laparoscopic procedures between November 2006 and June 2009, with a mean follow up of 7.4 months (1 to 31). We performed 3 adrenalectomies (TP), 3 radical prostatectomies with linfoadenectomy (EP), 11 transvesical prostatectomies (EP), 5 radical nephrectomies (RP), 2 partial nephrectomies (1TP, 1 RP), 5 pyelolithotomies (4 TP, 1 RP), 8 ureterolithotomies (6 RP, 2 TP), 2 intraperitonization of ureters (TP), 8 pyeloplasties (TP), 1 radical nephroureterectomy (TP), 1 orchidopexy and 1 colpopromontofixation. Surgical time ranged from 60 to 360 minutes (average 186 min). Intraoperative bleeding varied from 20 to 1000 ml (median=100 ml). Hospitalization varied from 36 to 1080 hours (median=62 h). We had 3 cases of conversion to open surgery. As complications, we had one case of nephrectomy during a pyelolithotomy due to bleeding, one case of stone migration during an ureterolithotomy and one case of a puntiform lesion of the common iliac artery during an ureterolithotomy, controlled with a stitch. Intraoperative transfusion rate was 4% (2 cases) during an adrenalectomy and a pyelolithotomy and postoperatively was 2% (1 case) after transvesical prostatectomy (4th P.O.). Postoperatively, one patient had a urinary fistula after a pyelolithotomy, one had prolonged hematuria after a transvesical prostatectomy and one had a ureter stenosis after an ureterolithotomy. No deaths occurred.

**Conclusion:** It is possible to perform many different types of laparoscopic procedures in urology with safety and efficiency after a good residency program, even without the supervision of a senior urologist.

#### **MP20-15 PERIOPERATIVE AND ONCOLOGICAL EVALUATION OF 4 DIFFERENT APPROACHES FOR RADICAL PROSTATECTOMY: PERINEAL, OPEN, LAPAROSCOPIC AND ROBOTIC**

C. Andreoni, R. Natalin, C. Paiva, C. Utida, V. Ortiz

**Background:** There are still controversies regarding the best approach for radical prostatectomy. Herein, we report on the comparison of perioperative parameters among the 4 approaches available.

**Methods:** Our prospective database for radical prostatectomy was assessed for data retrieval for the last 40 procedures performed for each approach. In the preoperative time was evaluated:

age, body mass index, prostate weight, PSA, Gleason score and clinical stage. Perioperative features were assessed for operating time (h), intraoperative bleeding (ml), time to diet (h), hospital length of stay (h) and complications as well as immediate oncological results.

**Results:** 160 procedures were evaluated and 4 groups had similar preoperative parameters. The open approach had the longest OR time, higher blood loss, longer time to diet, longer time to drain removal, longer time to deambulate and longer length of hospital stay than the other 3 approaches, statistically significant. Both pure laparoscopy and robotic had the best perioperative results. Robotic surgery had significantly less indwelling catheter time. There were no differences regarding complications. There were no histological differences, but open prostatectomy tends to have higher positive margins rate at the apex.

**Conclusion:** The open approach has a more morbid postoperative and either pure laparoscopy or robotic have more favorable postoperative time. There is a trend towards open prostatectomy to have higher positive margins at the apex.

#### **MP20-16 PRELIMINARY ONCOLOGIC OUTCOME OF LAPAROSCOPIC ADRENALECTOMY FOR ISOLATED ADRENAL METASTASIS**

R. Papalia, G. Simone, S. Guaglianone, A. Bove, E. Forastiere, M. Gallucci

**Background:** We report the oncological outcome of laparoscopic treatment of adrenal metastases.

**Methods:** Between October 2002 and May 2009 a total of 19 transperitoneal laparoscopic adrenalectomies (LA) for suspected metastasis of adrenal glands were performed in 16 patients with history of extra-adrenal primary tumors. Preoperative data, perioperative results and follow up were retrospectively evaluated.

**Results:** The mean operative time was 48 minutes (range 35–63) for unilateral procedure and 115 minutes (range 75 to 160) for single setting bilateral procedures. The mean blood loss was 60 ml (range 30–150 ml) for unilateral adrenalectomies and 80 ml (50–300 ml) for bilateral ones. No major complication occurred. The median time to discharge was 3 days (range 2 to 6). The median tumor size was 5,5 cm (range 3.5 to 10). The pathologic analysis revealed renal cell carcinoma metastases in 10 patients and transitional cell carcinoma metastases in two men who underwent bilateral laparoscopic adrenalectomy. Metastasis from papillary renal cell carcinoma, poorly differentiate lung carcinoma, colorectal carcinoma and melanoma were respectively detected in the other four patients. Surgical margins were negative in all patients and local recurrence occurred in one patient. At a median follow-up of 21 months 75% of patients were alive and 31,25% were disease free. The mean time to recurrence was 13 months (range 4–50).

**Conclusion:** Laparoscopic removal of adrenal metastasis is minimally invasive and oncologically effective. The final outcome of patients mainly depends on the primary tumor histology and on the chances of treatment of metastases subsequently developed.

#### **MP20-17 THE EFFECT OF TRAINING PERIOD TO SUCCESS AND COMPLICATION RATES OF LAPAROSCOPIC PROCEDURES**

U. Altug, F. Yalcinkaya, F. Demirel, M. Topcuoglu

**Background:** We compared the difficulty and complications of laparoscopic operations before and after a training period. The effect of increasing experience on laparoscopic procedures were evaluated.

**Methods:** 420 urological laparoscopic procedures have been assessed between years 2002–2009. All procedures were performed by three surgeons. The first 214 cases has been named as group 1 (2002–2007), second 206 cases have been named as group 2 (2007–2009). Group 2 cases were performed after a training period. (U. A had long term, F. Y and F. D had short term training in a conversant institute). Both groups were assessed as easy operation group (EOG) and difficult operation group (DOG) according to European Scoring System. Encountered complications were separated as major and minor.

**Results:** For group 1, 69 cases were in DOG (%32). It was 115 for group 2 (%56). According to ESS, mean score per case was 6.6 for group 1 and 9.5 for group 2. Even though increasing of difficulty level there was no statistically significant difference between groups for major complication rates. According to Clavien Grading System 32 complications were observed in group 1 and 25 were observed in next group. Crucial complications which were determined as grade 3a and over (3b, 4a, 4b, 5) were 9 in group 1 and 6 in group 2.

**Conclusion:** We investigated our laparoscopic procedures in terms of difficulty level and compared complications before and after a training period. An intensive education programme focused on laparoscopic skills by a sophisticated centre with wide range of laparoscopic procedures will contribute to perform more difficult cases with fewer complications.

#### MP20-18 COMPARISON OF LAPAROSCOPY TRAINING USING THE BOX TRAINER VERSUS THE VIRTUAL TRAINER Y. Mohammadi, M. Lerner, A. Sethi, S. Lucas, C. Sundaram—USA

**Background:** The objective of this study was to evaluate if training on a virtual reality laparoscopic simulator improved the performance on a laparoscopic box trainer.

**Methods:** A total of 36 subjects were trained using the box trainer (control group) and 17 participants were trained with the use of the virtual simulator (experimental group). Participants in the experimental group completed 1 session of 5 exercises on the box trainer, followed by 4 sessions on the virtual simulator, and concluded with a final session on the box trainer. Participants in the control group completed 6 sessions on the virtual simulator without using the box trainer. All exercises were monitored and scored for time and accuracy for a total of 9 variables. Participants completed a self evaluation survey after each session and a user satisfaction questionnaire at the end of the training.

**Results:** There was no statistically significant difference between the improvement in accuracy of the experimental group versus the control group. The pegboard time was the only exercise parameter that was significantly different ( $p=0.0495$ ) between the experimental and control group. Of the controls, 66.7% believed their performance was adequately measured versus 87.5% of the experimental group. The experimental group developed more interest in urology as a result of their experience than the control group (100% vs 46.7%, respectively). No statistically significant difference between the self-evaluation progress of the experimental group and control group exists.

**Conclusion:** We conclude that virtual simulator is a reasonable alternative to the box trainer for laparoscopic skill training.

#### MP20-19 LAPAROSCOPIC RENAL SURGERY (LRS) IN PATIENTS UNDER HEMODIALYSIS TREATMENT: NO PROBLEM

O. Sanli, T. Tefik, A. Atar, T. Mut, M. Tunc, C. Özsoy—Turkey

**Background:** Laparoscopic procedures may augment metabolic problems due to CO<sub>2</sub> retention in patients under hemodialysis. Therefore, both urologist and anesthesiologists may be reluctant to perform LRS to these patients. Herein, we report our experience with LRS in patients under hemodialysis in comparison with normal counterparts.

**Methods:** 16 patients (19 renal units, Group 1) under hemodialysis underwent LRS. Renal ablative surgery was indicated due to nonfunctioning kidney in 16 and suspected malignancy in 3 renal units. Radical nephrectomy (RN), simple nephrectomy (SN), simple nephroureterectomy (SNU) was performed in 3, 6 and 8 cases, respectively. For comparison, 103 patients (Group 2) without CRF who had undergone LRS were evaluated. In this group, RN, SN, SNU was performed in 46, 46 and 11 patients, respectively.

**Results:** The mean age ( $37.6 \pm 13.0$  vs.  $49.0 \pm 18.8$ ,  $p=0.01$ ) and BMI ( $22.3 \pm 4.6$  vs.  $25.8 \pm 5.4$ ,  $p < 0.005$ ) were lower of the patients in Group 1; whereas ASA score ( $2.1 \pm 0.9$  vs.  $1.5 \pm 0.7$ ,  $p < 0.005$ ) was lower in Group 2. Estimated blood loss ( $111 \pm 116.6$  vs.  $253 \pm 390.3$  ml,  $p=0.029$ ) was higher in Group 2. Both groups were comparable in regard to mean operation time ( $133.5 \pm 81.5$  vs.  $128.5 \pm 53.8$ ,  $p=0.78$ ), hematocrit drop ( $4.78 \pm 4.0$  vs.  $3.73 \pm 3.0$ ,  $p=0.20$ ) and hospital stay ( $3.7 \pm 3.3$  vs.  $3.5 \pm 2.4$  days,  $p=0.52$ ). 4 major, 20 minor complications (23.3%) in Group 2 and 3 minor complications (15.8%) were encountered in Group 1. Of note, no case in Group 1 was converted to open surgery due to metabolic problems.

**Conclusion:** LRS in patients under hemodialysis may be performed safely under expertise of an experienced laparoscopy team.

#### MP20-20 HOMODYNAMIC CHANGES AFTER RETROPERITONEAL CO<sub>2</sub> INSUFFLATION FOR POSTERIOR RETROPERITONEOSCOPIC ADRENALECTOMY

S. Soleymani

**Background:** Intraoperative complications and hemodynamic alterations during posterior capnoretroperitoneoscopic adrenalectomy in the prone position were investigated in 16 consecutive patients using invasive hemodynamic monitoring.

**Methods:** Under general anesthesia with propofol and fentanyl, hemodynamic changes were made before (M1) and during retroperitoneal CO<sub>2</sub> insufflation (15 mm Hg [M2]; 20 mm Hg [M3]). Retroperitoneal insufflation resulted in a significant increase of cardiac output (+72%), stroke volume (+42%), mean arterial pressure (+39%), and mean pulmonary arterial pressure (+36%). Although retroperitoneal inflation was accompanied by a significant increase of central venous pressure (+37%), an increase of preload may have led to higher filling pressures. Heart rate, systemic vascular resistance, and pulmonary vascular resistance did not show significant changes. One pneumothorax and two cutaneous emphysemas occurred. We have demonstrated, in small number of patients, that retroperitoneal CO<sub>2</sub> insufflation for pos-



terior capnoretroperitoneoscopic adrenalectomy in the prone position results in hemodynamic changes without apparent adverse effects.

**Results:** It is not known whether this impairment of circulatory function can be avoided during retroperitoneal subphrenic CO<sub>2</sub> insufflation. Since the retroperitoneal cavity, which is artificially created by the surgeon, is much smaller than the abdominal cavity,

we hypothesized that hemodynamic changes should be less marked during retroperitoneoscopic adrenalectomy.

**Conclusion:** There are no studies on the hemodynamic changes after retroperitoneal, subphrenic inflation of CO<sub>2</sub> in humans in the prone position. We, therefore, studied these changes in 16 consecutive patients undergoing posterior retroperitoneoscopic adrenalectomy.

## MP21: PEDIATRIC AND UPPER TRACT

### MP21-01 BILATERAL CRYPTORCHIDISM IN SILVER-RUSSELL SYNDROME: THE FIRST EXPERIENCE OF LAPAROSCOPIC ORCHIOPEXY

K. Yoo, S. Jeon, J. Lee, J. Kim

**Background:** Silver-Russel syndrome (SRS) is a disorder present at birth that involves poor growth, low birth weight, differences in the size of the two sides of the body, and genital anomalies. The bilateral cryptorchidism is a rare manifestation of this syndrome, and until now has been not described in Korea. We report a patient presenting with a bilateral cryptorchidism, which diagnosis, treatment; for the first time, and a laparoscopic orchiopexy.

**Methods:** A 17-month-old child presented with cardiac anomalies, an umbilical hernia, intrauterine growth restriction, a triangular-shaped face, scaphocephaly, late closure of the anterior fontanel, and genital anomalies visited to outpatient clinic with an empty scrotum. A laparoscopic approach was planned to perform the orchiopexy and bilateral testes were located 30 mm proximal to the internal inguinal ring. Bilateral laparoscopic Fowler-Stephens orchiopexy was performed.

**Results:** Bilateral laparoscopic Fowler-Stephens orchiopexy was successful. After creation of a new ring lateral to the bladder, both testes were situated in the scrotum. The testicular atrophy, testicular retraction and hematoma formation after operation were not detected 4 months later.

**Conclusion:** We report a case of bilateral cryptorchidism without other genital abnormality in SRS. This report provides an overview of the genital abnormality of SRS, and describes, for the first time, a laparoscopic orchiopexy in SRS.

### MP21-02 THE ENDOSCOPIC THERAPY FOR MELAMINE-ASSOCIATED UROLITHIASIS IN CHILDREN. DEPARTMENT OF UROLOGY, FIRST AFFILIATED HOSPITAL OF GANNAN MEDICAL UNIVERSITY, JIANGXI PROVINCIAL MODERN TREATMENT CENTER OF UROLITHIASIS, GANZHOU, JIANGXI, 341000, CHINA

Z. Xiao-feng, Y. Yuan-hu, X. Ri-hai—China

**Background:** To evaluate the safety and efficacy of endoscopic therapy for urolithiasis in the children drinking highly melamine-tainted powdered formula.

**Methods:** From September 2008 until now, a total of 27 cases with urolithiasis underwent endoscopic therapy. They included 17 boys and 10 girls, aged from 12 months to 46 months (median, 29 months). Of these cases, 2 were unilateral renal calculi combined

with proximal ureteral calculi, 1 was bilateral renal calculus with unilateral proximal ureteral calculus, 1 was unilateral renal calculus with vesical calculus, 4 were unilateral renal calculi, 14 were unilateral ureteral calculi, of which 1 also had distal urethral calculus, 2 were bilateral ureteral calculi, 1 was vesical calculus and 2 were urethral calculi. Ureterorenolithotripsies (URLs) were performed on 9 patients with middle and distal ureteral calculi, Mini-percutaneous Nephrolithotomies (MPCNLs) were performed on 13 cases with renal calculus or proximal ureteral calculus. Two children with unilateral renal calculi combined with proximal ureteral calculi underwent URL and MPCNL simultaneously. The children with vesical or urethral calculi were treated using ureteroscopy.

**Results:** All the operations were successfully performed. Recurrence of ureteral calculi were found in 2 children at postoperative follow-up and URLs were performed again. No fragment of stone larger than 0.3 cm in diameter was found post-operatively by B ultrasound or KUB. There was no major perioperative complication.

**Conclusion:** Endoscopic therapy is a minimally invasive, safe and effective treatment for urolithiasis in children drinking highly melamine-tainted powdered formula.

### MP21-03 EFFECT OF UNILATERAL ORCHIECTOMY ON CONTRALATERAL TESTICULAR DAMAGE IN UNILATERAL TESTICULAR TORSION

S. Paick, H. Kim, M. Baek, Y. Lho, B. Lee, H. Choi—Korea

**Background:** To investigate the effects of the unilateral orchiectomy compared with the detorsion on the contralateral testicular damage in unilateral testicular torsion of the rat.

**Methods:** Eight-week-old Sprague-Dawley rats were divided into 7 groups of 7 rats each; Sham, 1 hr torsion-detorsion (T/D), 1 hr T/D, 24 hr T/D, 1 hr torsion-orchiectomy (T/O), 4 hr T/O and 24 hr T/O. The contralateral testes were taken 4 weeks after surgery for histologic examination. The mean seminiferous tubular diameter (MSTD), mean testicular biopsy score (MTBS) and mean number of TUNEL positive cell (MNTPC) were determined.

**Results:** Unilateral testicular T/D and T/O caused a significant decrease in the MSTD, MTBS and increase in the MNTPC on the contralateral testes. These changes occurred even after 1 hr torsion and more increased as the duration of torsion was increased. However, T/O caused significantly small changes compared with

T/D in the MSTD, MTBS and no apoptosis on the contralateral testes in 1 hr torsion, but not in 4 and 24 hr torsion.

**Conclusion:** Unilateral orchiectomy showed significant protective effects on the contralateral testicular damages compared with detorsion in unilateral testicular torsion of the rat. However these effects occurred only in 1 hr not in 4 and 24 hr torsion.

#### MP21-04 PERCUTANEOUS MANAGEMENT OF NEPHROLITHIASIS IN CHILDREN AND ADOLESCENTS WITH SPINAL CORD LESION

B. Gayed, M. Smaldone, K. Shahrour, K. Sternberg, A. Mohamed, M. Ost

**Background:** Children and adolescents with spinal cord anomalies and nephrolithiasis represent an endourologic management challenge. We report our early institutional experience with PCNL in this complex patient population.

**Methods:** We identified all patients with spinal cord lesions undergoing percutaneous management of urolithiasis at our institution between January 2002 and February 2009. Patient demographics, pre-operative imaging, stone characteristics, peri-operative outcomes, stone free rates, and progression to adjuvant procedures were reviewed. Our technique for obtaining percutaneous access is similar to what has previously been described in pediatric and adult populations. Stone free status was defined as no radiologic evidence of recurrent stone burden on repeat imaging.

**Results:** We identified 11 patients (63.6% female) with spinal cord anomalies (64% myelomeningoceles, 9% traumatic spinal cord injuries, 27% other) undergoing percutaneous nephrolithotomy for nephrolithiasis. The mean age in our cohort was  $16.2 \pm 4.1$  years (range 10–22 years), and the mean calculus burden was  $1.78 \pm 1.0$  cm (complete staghorn 45.5%, partial staghorn 27.2%). Percutaneous access was urologist obtained in 81.8% of patients, and two children underwent pre operative nephrostomy tube placement in interventional radiology. A 30 Fr access sheath through a single tract was utilized following balloon or amplatz dilation in 63.6% and 27.3% of patients respectively, and a “mini perc” 11Fr access sheath was used in one patient. There were no intra operative complications, and one child required an intra-operative blood transfusion. Post operative complications included urosepsis (9.1%), hemorrhage requiring transfusion (18.2%), and one child required angiographic embolization for persistent post operative bleeding. Following PCNL monotherapy, four patients (36.3%) required second look nephroscopy for stone clearance and additional adjunct procedures (ureteroscopy 27.2%, shock wave lithotripsy 27.2%) were utilized in four patients to treat residual post operative stone burden. With a mean follow up of  $13.9 \pm 13.3$  months, 54.5% of patients are radiographically stone free while 45.5% have small (<5 mm) non-obstructive residual stone burden being managed conservatively.

**Conclusion:** Our early experience indicates that single tract percutaneous management of urolithiasis in children and young adults with spinal cord anomalies is a feasible option for pediatric endourologists. Families must be counseled that multiple procedures may be necessary to achieve stone free status. Familiarity with complex anatomy and prompt clinical recognition of post operative sequelae are necessary to optimize stone free and complication rates.

#### MP21-05 INCIDENCE OF URINARY TRACT INFECTIONS IN CHILDREN AFTER SUCCESSFUL CORRECTION OF VESICOURETERAL REFLUX: COMPARISON OF ENDOSCOPIC INJECTION AND OPEN SURGERY

O. Tanriverdi, M. Sýlay, M. Kadihasanoglu, H. Sirin, K. Horasanli, C. Miroglu

**Background:** Although the intervention to resolve vesicoureteral reflux (VUR) is recommended to prevent recurrent urinary tract infections (UTI), there is little information concerning the incidence of infection after therapy. Currently, endoscopic injection is considered as an alternative to medical and open surgical management of VUR. Our aim was to compare the incidence of UTI in children with corrected VUR after successful endoscopic treatment versus ureteral reimplantation.

**Methods:** We reviewed the charts of 112 patients who had undergone open surgery or endoscopic treatment for VUR between 2001 and 2006. Only patients cured of VUR which is detected postoperatively by voiding cystourethrography were enrolled into the study. Patients with fetal hydronephrosis, renal transplantation, neurogenic bladder, duplication anomalies, open plus endoscopic procedures and with voiding dysfunction or dysfunctional elimination syndrome were excluded. Data collected included age, gender, preoperative grades of VUR, the presence of renal scar, urinalysis and urine culture results. Patients were then divided into two groups according to the procedure performed.

**Results:** There were 25 children (17 girls, 8 boys) in the open surgery group (group-1) and 19 children (17 girls, 2 boys) in the endoscopy group (group-2). No statistically significant difference was detected regarding patients' age, gender and preoperative reflux grade ( $p > 0.05$ ). The preoperative presence of renal scar was significantly higher in the open surgery group (80% vs 42.1%  $p = 0.01$ ). Mean follow-up was  $39.56 \pm 16.11$  months for the open surgery group and  $44.58 \pm 29.07$  months for the endoscopy group. The rates for UTI and febrile UTI were comparable between the groups ( $p > 0.05$ ).  
Table 1: Patient demographics  
Group 1 Group 2 p value  
Female (%) 68.0 88.5 0.148  
Age (mean±SD)  $6.20 \pm 3.44$   $7.61 \pm 4.19$  0.405  
Mean follow up (months)  $39.56 \pm 16.11$   $44.58 \pm 29.07$  0.504  
Mean preoperative reflux grade  $3.34 \pm 0.86$   $3.16 \pm 0.69$  0.441  
preoperative renal scar on DMSA (%) 80.0 42.1 0.01  
Table 2: Rates for febrile and non-febrile UTI  
Group 1 Group 2 p value  
Non-febrile UTI (%) 44.0 26.3 0.227  
Febrile UTI (%) 16.0 10.5 0.684

**Conclusion:** Children successfully cured from VUR with endoscopic treatment exhibited lower but not statistically significant incidence of febrile and non-febrile UTI compared to those cured with open surgery. These findings demonstrated that both endoscopic and open surgery seems to be efficacious to prevent from UTI.

#### MP21-06 THE EFFECT OF RESTRICTIVE BARIATRIC SURGERY ON KIDNEY STONE RISK FACTORS

M. Semins, S. Donahue, K. Steele, J. Asplin, J. Berkowitz, B. Matlaga—USA

**Background:** Bariatric surgical procedures are being increasingly utilized in the treatment of patients with morbid obesity. Malabsorptive procedures, such as Roux-en-Y gastric bypass, are associated with an increased risk for kidney stone disease. The risk of kidney stone disease following restrictive procedures, such as gastric banding, is not well characterized. Therefore, we performed a study to characterize the metabolic risk factors of patients who underwent gastric banding procedures for bariatric indications.

**Methods:** We enrolled 16 patients (1 male and 15 female) who underwent a bariatric gastric restrictive procedure at our institution. Median patient age was 47 years (range, 36–57). Of the 16 patients, 10 underwent gastric banding and 6 underwent sleeve gastrectomy. The median time between surgery and urine collection was 1.14 years; for all patients, at least 6 months had elapsed between surgery and urine collection.

**Results:** The following table summarizes selected 24 hour urinary metabolic findings: Volume (L) Calcium (mg) Oxalate (mg) Citrate (mg) pH Uric Acid (g) Sodium (mg) SS CaOxSS CaPSS UA Median 1.43135.331.5564.65.80.631195.65.330.941.30 Minimum 0.7929.815.943.25.40.21451.91.080.060.14 Maximum 2.88285.375.02101.56.71.071335.510.332.382.19 The median weight loss was 21.8 kg (range, 4.9–34.9). The median pre-operative BMI was 44.3 (range, 37.6–67.0), and the median post-operative BMI was 36.1 (range, 29.1–58.8).

**Conclusion:** Gastric banding does not appear to be associated with an increased risk for kidney stone disease. Additional long-term prospective studies with larger sample sizes are required to confirm these findings.

### MP21-07 THE PRELIMINARY RESULTS OF TREATMENT OUTCOMES ON 60 VERSE 120 SHOCK WAVES PER MINUTES IN AN ELECTROCONDUCTIVE LITHOTRIPTOR

A. Lo, M. Gohel, K. Wong, C. Ng

**Background:** Studies have shown that slower shock wave (SW) delivery rate may be advantageous to stone fragmentation. However, treatment outcomes may be difference in different lithotriptors. Therefore, we would like to investigate the effects of different SW delivery rate in an electroconductive lithotripter.

**Methods:** Adult patients with a solitary, previously untreated kidney stone were prospectively randomized to receive shock wave lithotripsy (SWL) at either 60 SWs/min or 120 SWs/min with Sonolith Vision (Technomed, France). Successful treatment outcome is defined as either stone free or fragments <4 mm at 12 weeks after treatment.

**Results:** 54 suitable patients with a mean age of 51.3 (30–66) years were recruited. Stone length measured in maximum diameter was  $8.75 \pm 2.67$  (5.01–15.44) mm. Successful rates were 40.7% and 48.1% in patients receiving 60 SWs/min and 120 SWs/min respectively ( $p > 0/05$ ). Of patients with stone in maximum length <10 mm, the outcome of 50% of patients in 60 SWs/min group were successful compared to 65% in 120 SWs/min group. For stone with maximum length of  $\geq 10$  mm, the successful rates were 22.2% in 60 SWs/min group and 0% in 120 SWs/min group respectively. Expectedly, smaller size stone length was associated with better successful rate.

**Conclusion:** There was no significant difference in the overall stone treatment outcome between 60 SWs/min and 120 SWs/min. However, there is a trend suggesting that slower shock wave may result in better result in stone  $\geq 10$  mm. Further study will be needed to confirm our findings.

### MP21-08 MULTIPLE ANEURYSMS IN PATIENTS WITH CHRONIC RENAL FAILURE UNDERGOING ANGIO-EMBOLISATION FOR BLEEDING FOLLOWING PERCUTANEOUS RENAL INTERVENTION: WHAT ARE WE DEALING WITH?

R. Mavuduru, D. Sarkar, S. Singh, M. Agarwal, A. Lal, A. Mandal—India

**Background:** Patients with CRF are more prone for bleeding following per-cutaneous renal intervention as compared to those with normal renal function. Causes are multi-factorial. Finding multiple aneurysms in these patients following initial angi-embolisation away from puncture site is very unusual.

**Methods:** Clinical and radiological findings of all the patients who underwent renal angiography for post intervention bleed during Jan 2004 to July 2008 were reviewed and analysed.

**Results:** Total of 29 patients required angiography for post intervention bleed. Six patients had recurrent bleeding for which they underwent repeat angiography. Four of these patients had appearance of multiple new aneurysms away from the site of PCN/PNL puncture and site of previous bleeding. All the patients had CRF (Creatinine >3 mg/dl), were on prolonged preoperative urinary diversion, multiple positive urine cultures. Three patients had candiduria. None of these patients had re-bleeding after repeat embolisation and treatment with antifungal.

**Conclusion:** Development of multiple aneurysms at sites away from punctures in patients with CRF following per-cutaneous intervention is very unusual. Its causation including infection with bacteria and fungus, reaction of embolising material and angiopathy needs to be explored.

### MP21-09 CONTEMPORARY EXPERIENCE IN THE MANAGEMENT OF ANGIOMYOLIPOMA

M. Jorge, J. Rosales, Z. Okhunov, J. Landman, J. Mckiernan, K. Badani—USA

**Background:** Propose: We review our single center experience in the management of renal angiomyolipoma (AML) including patient outcomes and long-term follow-up in patients treated with active surveillance or invasive treatment protocols.

**Methods:** We evaluated our prospectively established urologic oncology database and identified the records of 91 patients with the diagnosis of renal AML who presented between June 1985 and February 2009. Clinical, radiographic and pathological data were recorded. We recorded patient and tumor characteristics, presentation, treatment efficacy, additional procedures required and complications. Patients were stratified according to the presenting size of AML to compare outcomes by tumor size.

**Results:** A total of 91 patients with 96 AML were identified. 90 Lesions were in a sporadic presentation in this group the mean patient age was 58 years (range 32–86), and there were 65 females (74.37%) in the cohort. Presentation was symptomatic in 16 (17.6%) patients and an incidental finding in 75 (82.4%) patients. Forty Five (51.7%) lesions were initially treated with active surveillance, 4 (4.6%) embolization and 38 (44.7%) surgical procedures. Clinical follow-up was available for all patients with a median length of 44.1 months (range 1–282.3). A Growth rate of 0.088 cm/year was found for the observation group. We divided the patients in two groups according to initial tumor size at presentation and finding that patients with tumors >4 cm, were more symptomatic, in younger and underwent to interventional treatment.

**Conclusion:** Angiomyolipoma is a renal tumor normally with a benign course. Observation protocol is feasible approach for small, sporadic AML, with a small rate of complications. Nephron sparing approaches should be performed whenever possible.

### MP21-10 PERCUTANEOUS MANAGEMENT OF RENAL AND PERINEPHRIC ABSCESSSES

T. Hares, V. Joshi

**Background:** Suppurative infections involving kidney are difficult to diagnose and treat. Such abscesses can be treated in various fashions. Conventional treatment of renal and perinephric abscesses has been surgical exploration, drainage and marsupialisation of the kidney.

**Methods:** We retrospectively reviewed the records of 15 cases with renal and/or perinephric abscesses and like to share our experience with evaluation, management and outcomes of these patients.

**Results:** Of 12 patients with renal/or perinephric abscesses, 91% had one contributory factor, 58% had diabetes, and 33% had nephrolithiasis. The abscess was intranephric in 17% of cases, intranephric and perinephric in 8%, perinephric only in 78%. Large abscesses (more than 5 cm) were seen in 42% of patients and 58% had medium size abscesses (i.e. between 3–5 cm). All 12 patients were treated with percutaneous drainage of abscess and 7(58%) had positive culture. Three of the 12 patients with positive abscess cultures had the same organism in the urine. No patient had positive blood culture. All patients received broad-spectrum intravenous antibiotics. One patient each required additional procedure of nephrectomy, percutaneous nephrolithotripsy and antegrade ureteroscopy. At follow up all patients had complete radiographic resolution of the abscess without further complication.

**Conclusion:** Our series suggest that percutaneous drainage is as effective as open surgery for large and medium size renal abscesses with minimal mobility and excellent functional and anatomical outcome.

#### MP21-11 LATE DIAGNOSIS AND TREATMENT OF RENAL PSEUDOANEURYSM IN PEDIATRIC PATIENT: COMPLICATION OF PERCUTANEOUS NEPHROLITHOTOMY

M. Istanbuluoglu, E. Yildirim, T. Cicek, B. Ozturk

**Background:** The aim of the Percutaneous nephrolithotomy (PNL) operation is to cure the patients with renal and upper ureteral stones with minimal morbidity. Although PNL is a minimally invasive method, occasionally bleeding complication (0.4%–3%) which requires endovascular embolization can occur. Here, we present late diagnosis and treatment of a pseudoaneurysm after PNL procedure.

**Methods:** 14 year-old female patient underwent PNL procedure for right nephrolithiasis (stone size 650 mm<sup>2</sup>). Dilatation was performed with Amplatz dilators and a 30F Amplatz sheath was placed, through which a 26F rigid nephroscope was inserted and the stone fragmentation was carried out with pneumatic lithotripter.

**Results:** The procedure time was 45 minutes and stone free status. The patient was discharged in postoperative second day and she was free of symptoms. The patient was admitted with massive hematuria at postoperative 7<sup>th</sup> day and her hemoglobin was 8.5 mg/dl. We suspected a pseudoaneurysm formation and performed selective renal angiography. However, renal angiography revealed neither a pseudoaneurysm nor arteriovenous fistula formation. The hematuria were stopped and the patient discharged. But the patient admitted with rebleeding 5 days later and second angiography were performed. The second angiography revealed a pseudoaneurysm, 1 cm in diameter, originating from renal artery lower parenchymal branch. The pseudoaneurysm was embolized with platinum coils and bleeding was stopped.

**Conclusion:** Intermittent bleeding can be seen after PNL procedure. In this situations, renal angiography should be performed at

the time of active bleeding and, use of an arterial vasodilator agent (i.e papaverine) should prevent negative angiography.

#### MP21-12 UNSATISFACTORY SCREENING OF URINE WITH THE NEXT GENERATION URINE FLOW CYTOMETER (UF-1000I) FOR SIGNIFICANT BACTERIURIA

G. Bonkat, M. Rieken, A. Feike, S. Wyler, T. Gasser, A. Bachmann

**Background:** Urinary tract infection (UTI) is a common cause of human illness, and failure to diagnose and treat it properly can lead to further chronic morbidity. Patients with indwelling urological devices are at major risk. Quantitative urine culture and identification are assumed to be the standard laboratory procedures for definitive diagnosis of UTI. The aim of this study was to assess the frequency of bacteriuria in patients with an indwelling ureteral stent using the next generation urine flow cytometer (UF-1000i). Furthermore, the value of conventional urine culture compared to urine flow cytometry was evaluated.

**Methods:** A total of 198 patients undergoing removal of a ureteral stent were enrolled. Urine samples were obtained via clean catch technique or single catheterization prior to stent removal. Urine flow cytometry was performed by the Sysmex UF-1000i (TOA Medical Electronics, Kobe, Japan). Significant bacteriuria was defined by bacterial count >100/ml. The conventional culture results for urine specimens were interpreted according to Wilson et al. with the exception of grampositive flora (Coagulase-negative staphylococci, Lactobacillus spp., Corynebacterium spp.) up to ≤104 CFU/ml, which was considered as contamination.

**Results:** The Sysmex UF-1000i showed a detection rate of significant bacteriuria in 13% (n = 25), whereas positive urine culture could be detected in 18% of patients (n = 35). Conventional urine culture revealed bacterial growth in all patients with significant bacterial count in urine flow cytometry (UF). The sensitivity and specificity of UF for detection of significant bacteriuria were 71% and 100%, respectively. Compared to conventional urine culture the positive predictive value of UF was 1.0, the negative predictive value 0.94, respectively.

**Conclusion:** Culture remains the gold standard for the detection of bacteriuria in urine samples. The use of the UF-1000i cytometer does not accurately predict the outcome of urine cultures. Therefore UF remains unsuitable for the safe screening of urine samples for bacteriuria.

#### MP21-13 ANALYSIS OF INFECTIOUS STONES: VARIABILITY OF LABORATORY ANALYSIS

A. Krambeck, N. Khan, M. Jackson, J. Lingeman, J. Williams Jr—United States

**Background:** The goal of this study was to determine the accuracy of infection stone composition analysis by major commercial laboratories.

**Methods:** Forty-six human renal stones with infrared spectroscopy (IR) determined composition were fragmented into six aliquots and studied with micro computed tomography (CT). Only 26 stones had fragments similar enough to be considered identical. The fragments were submitted to 1 research and 5 commercial laboratories for blinded analysis.

**Results:** Of the 26 stones, 5(19.2%) had an original IR interpretation of struvite mixed with either carbonate apatite (CA) or ammonium acid urate (AAU) prior to fragmentation. Of these stones, only 2(40%) were identified as having struvite by all

blinded laboratories; however, in none of the stones did all laboratories identify struvite as the main component. Of the 5 stones, 3 (60%) were also reported as having calcium oxalate monohydrate (COM). Furthermore, struvite was reported as a component by some, but not all, laboratories for 4 stones not thought to contain struvite pre-fragmentation: 3 apatite and 1 atazanavir. The atazanavir was reported as a total of 7 different crystal components and only 1 laboratory identified the atazanavir component. Overall, there was disagreement over the presence or absence of struvite in 7/26 (26.9%) stones.

**Conclusion:** This study demonstrates a tremendous variability in analysis of infection stones. The presence of struvite was not agreed upon by all the labs in over 1/4 of the cohort. Furthermore, the presence of a metabolic component mixed with struvite was also not agreed upon in 10%.

### MP21-14 ENDOSCOPIC MANAGEMENT OF PLASTIC FOREIGN BODY DURING PERCUTANEOUS NEPHROLITHOTOMY

S. Guven, A. Ozturk, O. Kilic, U. Ozdemir, M. Piskin, M. Kilinc

**Background:** Foreign bodies can present as a nidus for infection or stone formation or mimic a renal neoplasm. In this video, we will report an unusual case; a plastic foreign body, left behind previously during open renal surgery, noticed during PNL conducted due to kidney stones, and removed percutaneously.

**Methods:** A 38-year-old patient was referred to our department for management of a renal pelvis stone. The patient had undergone open pyelolithotomy in another institution 2 years before for the treatment of renal calculus and had an uneventful recovery. No information about the previously performed surgical procedure was available. The patient was evaluated with a plain film of the abdomen and found to have two calcifications lateral to the right transverse process of the L2-L3 vertebrae, compatible with a renal calculi. A computerized tomography showed both radiopaque images inside the collecting system of the right kidney. There were several stones, the biggest one with a diameter of 23 millimeters in the sub-pole in the collecting system of the right kidney. A percutaneous nephrolithotomy was performed.

**Results:** During percutaneous nephrolithotomy an unusual material was seen in the lower pole infundibulum covering the stone. The appearance of the material seen at nephroscopy was unlike renal fat but not dissimilar to noncalcified matrix. Extraction of this foreign body took 10 minutes and subsequently revealed a 3×3 cm length of plastic object. After its removal, the rest of the operation preceded uneventfully. The postoperative period was uneventful. Abdominal plain film and ultrasound after surgery showed no residual calculus and the patient was pain free.

**Conclusion:** In the case of radiolucent objects such as it is in the present case, diagnosis can be challenging and misleading. In the present case the foreign body was determined with direct visualization during nephroscopy. During the process of PCNL both the stones and the foreign body were removed successfully in a single operative setting.

### MP21-15 PERCUTANEOUS NEPHROLITHOTOMY UNDER SPINAL ANESTHESIA IN TREATMENT OF STAGHORN CALCULI

S. Mousavi-bahar, B. Borzouei, H. Babolhaeji—Iran

**Background:** Usually, percutaneous nephrolithotomy (PCNL) procedures are performed under general anesthesia. The aim of our

study was to avoid all potential risks of general anesthesia in patients undergoing PCNL.

**Methods:** 91 patients with renal staghorn calculi were included in this study from March 2002 to May 2009. Staghorn calculi were classified as partial or complete. All patients received spinal anesthetics and underwent PCNL. The incidence of complications, transfusion requirements, and stone-free rates were recorded.

**Results:** The male/female ratio was 3.55; the left/right ratio was 2.03. The mean patients' age was  $47.8 \pm 13.6$  years (mode 41, min 22, and max 77). 71 patients (78%) had partial, and 20 patients (22%) had complete staghorn calculi. Two tracks were needed in 9 cases and three tracks in 1 case to complete stone removal. The mean operation time was  $63.7 \pm 20.2$  minutes (mode 60, min 30, and max 120). Overall stone-free rate was 82.4%. Patients with residual stones were 16.5% and managed by rePCNL. Only 1 patient required to change from spinal to general anesthesia due to severity of nausea and hypotension. The incidence of complications was 9.9%. Nausea occurred in 2 patients, bleeding during operation in 4 patients, perforation of pelvicalyceal system in 1 patient, and both perforation and bleeding in 2 patients with no serious sequelae. No transfusion requirement was reported.

**Conclusion:** PCNL under spinal anesthesia is a feasible, safe, and well-tolerated for management of patients undergoing PCNL due to staghorn calculi. The method is particularly valuable for patients with significant comorbidities (such as pulmonary diseases).

### MP21-16 RENAL ACCESS BY UROLOGIST OR RADIOLOGIST DURING PERCUTANEOUS NEPHROLITHOTOMY

J. Tomaszewski, M. Smaldone, T. Averch, K. Shahrouh, S. Jackman

**Background:** We evaluated percutaneous access for percutaneous nephrolithotomy (PCNL) obtained by interventional radiologists or urologists at a single academic institution, and compared access outcomes and complications.

**Methods:** The records of 221 patients undergoing PCNL at the University of Pittsburgh Medical Center between 2000 and 2007 were retrospectively reviewed. Patients were stratified according to percutaneous access by a group of interventional radiologists (group 1) or urologists (group 2) in 37 and 184 patients, respectively. A predicted access difficulty score was calculated using demographic, stone, and operative variables. Percutaneous access was obtained by interventional radiologists a mean  $25 \pm 30$  days prior to definitive stone treatment. Percutaneous access complications and stone free rates were compared between groups.

**Results:** Mean patient age was  $58 \pm 17$  years (62% male, range 25–95 years) and  $53 \pm 16$  (51% male, range 19–90 years) in groups 1 and 2, respectively. Utilization of multiple access tracts (5.4% vs. 4.3%;  $p=0.54$ ), mean stone diameter ( $3.6 \pm 1.9$  cm vs.  $3.5 \pm 1.8$  cm;  $p=0.97$ ) and percentage of supracostal tracts (35% vs. 36%;  $p=0.63$ ) were comparable between groups. Mean access difficulty scores were comparable between groups. The percentage of staghorn calculi (30% vs. 39%;  $p=0.28$ ) and number of obese (BMI >30) patients (38% vs. 30%;  $p=0.34$ ) were also comparable between groups 1 and 2. The complication rate was the same in the two groups (13.5% vs. 14.3%;  $p=0.52$ ). Stone free rates were greater in the urology group (76% vs. 80%;  $p=0.22$ ). Radiologist obtained access could not be used in 35% of patients, requiring additional access tract placement at the time of surgery.

**Conclusion:** Despite similar stone complexity and access difficulty, urologist obtained access was associated with a non-

statistically significant improvement in stone free rate. Given comparable complication rates and the high failure rate of radiologist obtained access, urologists are able to safely and effectively obtain percutaneous access for PCNL.

### MP21-17 THE RADIO GRAPHIC APPEARANCE OF THE CALCULI IN PUT FILM & ITS EFFECTS ON THE RESULT OF EXTRA CORPORAAL SHOCK WAVE LITHOTRIPSY

M. Etafy

**Background:** (ESWL) has been in clinical use since 1982 and has replaced other treatment modalities for upper urinary calculi.

**Methods:** 112 renal stones were treated by ESWL at Alzahraa lithotripsy center from 1/9/2004 till 1/6/2006 Plain Xray film on the abdomen & pelvis. (PUT) for all patients.

**Results:** The results were classified into these groups based on imaging studies:- As regards group A (homogeneity) 49 patients had homogenous stones among whom 26 (53%) were stone free after ESWL & 23 (47%) were non stone free with insignificant p-value. In non homogenous group there were 63 patients where 54 patients (86%) became stone free & 9 patients (14%) were non stone free with highly significant p-value. If we conclude smoothness (group B) of the stones, there were 41 patients with smooth stones. 25 patients of them (61%) became stone free where as 16 were non stone free (39%) with insignificant p-value. There were 71 patients with rough stones among whom 55 cases (77%) were stone free with significant p-value & 16 (23%) were non stone free with insignificant p-value. As regards group C the calculi with a less density than the last rib density had (82%) stone free rate with highly significant p-value. The calculi with an equal density to the last rib density had (69%) stone free rate with insignificant p-value, whereas the calculi that were denser to the bone, the stone free rate was 56% with insignificant p-value.

**Conclusion:** The efficacy of ESWL in treatment of different types of kidney stones is related to the radiological characteristics of the stone which are homogeneity, smoothness and its radiodensity degree in relation to last rib Stones which are non homogenous, rough or less dense in KUB film are more likely to disintegrate by ESWL.

### MP21-18 CLOSED EXTERNAL END DOUBLE J CATHETER AS A NEPHROSTENT IN PYELOPLASTY FOR VERY SMALL CHILDREN WITH URETERO-PELVIC JUNCTION OBSTRUCTION

S. Rabani—Iran

**Background:** UPJO is a relatively common congenital anomaly that may need pyeloplasty to prevent renal function deterioration. The purpose of this study was to describe a modified use of JJ catheter in very small children.

**Methods:** A series of 12 children between 3 and 10 months, underwent stenting open pyeloplasty. In each patient a 6 french Foley catheter was placed within the bladder, with one ml sterile methylene blue, and then the catheter was clamped during the operation time. During a dismembered pyeloplasty, a small (3F) double j stent was placed through the flank into renal pelvis, passing the flank skin, muscles and entering via lower pole posteriorly to pass the anastomosis and entering the ureter and urinary bladder, confirmed by observing methylene blue within the wound. The external end of the JJ catheter was doubled up and sutured to the flank skin and then removed 4 weeks later.

**Results:** No procedure related complication (s) such as extravasation, infection and stent displacement was seen. The duration of follow up was 6 months to 3 years (the median follow-up time was 13 months).

**Conclusion:** This method of stenting pyeloplasty is easily tolerated and causes no need for endoscopic removal of the catheter, is an invaluable technique of pyeloplasty with stenting in very small children and needs no external appliance.

**Key words:** upjo, pyeloplasty, double j stent.

### MP21-19 SIMILARITIES AND DIFFERENCES BETWEEN TWO DIFFERENT CENTERS IN PERCUTANEOUS NEPHROLITHOTOMY FOR LARGE STONES IN HORSESHOE KIDNEYS

A. Skolarikos, A. Tefekli, A. Bisas, E. Sari, A. Muslumanoglu, C. Deliveliotis—Turkey

**Background:** To evaluate the differences in the outcome of percutaneous nephrolithotomy (PCNL) in horseshoe kidneys performed at two different independent centers.

**Methods:** We retrospectively reviewed all patients presenting to our centres with a horseshoe kidney and urolithiasis treated by PCNL. The stone burden, surgical details, incidence of intraoperative and postoperative complications and use of auxiliary procedures (second-look PCNL, ureteroscopy, and ESWL), hospital stay, transfusion requirements, and stone-free rates at discharge were recorded and compared differently for the two centers; a) Greek b) Turkish.

**Results:** A total of 31 patients performed by group –a– were compared to 27 patients performed by group –b–. All PCNL procedures in both groups were performed in a one-session technique with fluoroscopic guidance in a prone position. There were no differences in mean patient age (42.8 vs 36.7;  $p = 0.085$ ), comorbidities (7 vs 4 patients;  $p = 0.753$ ), mean BMI (25.48 vs 25.78;  $p = 0.784$ ), mean stone burden ( $7.06 \text{ cm}^2$  vs  $8.2 \text{ cm}^2$ ;  $p = 0.526$ ), the site of the stone ( $p = 0.617$ ), the calyx punctured ( $p = 0.472$ ), and the number of accesses ( $p = 0.629$ ). There was a difference in using the safety guidewire (5/31 vs 27/27 patients;  $p < 0.0010$ ), which may have reflected a difference in mean fluoroscopy time (3.5 vs 7.7 min;  $p < 0.001$ ). There was no difference in intraoperative bleeding or need for blood transfusion (4/31 vs 4/27  $p = 0.838$ ). There was no difference in the incidence of postoperative complications including postoperative fever (7/31 vs 2/27;  $p = 0.154$ ), sepsis (1/31 vs 1/27;  $p = 1.000$ ) or urine leak (0/31 vs 2/27;  $p = 0.212$ ). Flexible nephroscopy was equally performed in both groups (9/31 vs 10/27;  $p = 0.582$ ). Patients on both groups required at similar rates ancillary procedures to become stone free (8/31 vs 8/27;  $p = 0.776$ ). Mean hospital stay was also similar in two groups (65.8 vs 75.2 hours; 0.458). Finally there was no difference in stone free-rates at discharge (20/31 vs 18/27;  $p = 0.863$ ) and at 3 months postoperatively (28/31 vs 26/27;  $p = 0.615$ ).

**Conclusion:** Percutaneous nephrolithotripsy for stones in horseshoe kidneys seems to be well established among different centers, achieving high success rates with the expense of complications.

### MP21-20 THE COMPARISON OF DIGITAL AND CONVENTIONAL FLEXIBLE URETERORENOSCOPY OUTCOMES

M. Binbay, A. Muslumanoglu, E. Yuruk, T. Akman, F. Ozgor, A. Tefekli—Turkey

**Background:** In the recent years the main drawback of flexible ureterorenoscopy, limited visualization and fragility of fiber-based

optics, was resolved by application of digital image acquisition to flexible ureterorenoscopes which provided a substantial improvement in image size and clarity. We aimed to compare the outcomes of new generation digital flexible ureterorenoscopies and conventional fiberoptic flexible ureterorenoscopies.

**Methods:** Between September 2008 and July 2009, a total of 43 patients (mean age:  $44.5 \pm 18.1$  years) underwent retrograde intrarenal surgery using either new generation digital flexible ureterorenoscope (ACMI DUR-D) (Group 1, n: 22) or conventional fiberoptic flexible ureterorenoscope (Storz Flex-X) (Group 2, n: 21). All procedures were performed by the same surgeon. Holmium: YAG laser with  $200\mu\text{m}$  probe was used for stone fragmentation. Success was defined as removal of all fragments with basket catheter or leaving fragments smaller than 2 mm for spontaneous passage.

**Results:** Mean patient age, body mass index, stone size or location was similar in both groups. Bleeding (n: 2) or ureteral perforation (in one patient, during access sheath placement) were intraoperative complications noted in Group 2. Serum creatinine level was elevated postoperatively in one patient in Group 1, and postoperative hema-

turia was seen in two patients in Group 2. Results were summarized on Table. Comparison of Digital and Conventional Ureterorenoscopies by means of patient demographics and operative findings (statistical significance:  $p < 0.05$ ) Digital Conventional p Number of patients 22 21 Mean age (year)  $43.9 \pm 18.7$   $45.2 \pm 18$  0.893 Mean stone size (mm<sup>2</sup>)  $86.9 \pm 17$   $94 \pm 60$  0.561 Body-Mass Index  $24 \pm 2.7$   $23.9 \pm 2.2$  0.859 Stone Location 0.461 upper calyx 4 2 middle calyx 1 4 lower calyx 16 14 proximal ureter 1 1 Mean operation time (min)  $37.2 \pm 10$   $45.9 \pm 13$  0.014 Access sheath placement 8 (36.4%) 8 (38.1%) 0.908 Use of DJ catheter 0 0 0.451 Success 0.185 Stone-free 7 (31.8%) 2 (9.5%) Fragments <2 mm 14 (63.6%) 17 (81%) Residual stone 1 (4.5%) 2 (9.5%) Need for auxiliary treatment 1(4.5) 1(4.8) 1 Mean hospitalization time (days)  $1 \pm 0.29$   $1.4 \pm 0.74$  0.05 Complication Per-operative 0 3 (14.2%) 0.185 Post-operative 1 (4.5%) 2 (9.6%) 0.584.

**Conclusion:** The use of digital flexible ureterorenoscopes, with providing excellent image quality, improves the operation time. However overall success or complication rates does not differ significantly.

## MP22: ENDOUROLOGY FOR NEPHROLITHIASIS

### MP22-01 THE MODIFIED AMPLATZ PCNL SHEATH—INITIAL EXPERIENCE

S. Umraniar, P. Kumar, R. Kulkarni, E. Bellamy, P. Rao, M. Kulkarni

**Background:** To assess the clinical feasibility of a modified Amplatz sheath in PCNL. The modification, consisting of an accessory side port (hole) measuring 10 mm/6 mm near the internal end of a standard Amplatz sheath, enables the passage of a flexible endoscope to access stones embedded in deep calyces.

**Methods:** The modified sheath was used in 5 patients undergoing PCNL for large volume stones with an average stone burden of 2.5 cms. A rigid nephroscope was used for the fragmentation of calculi within the pelvis and accessible calyces. Stones within middle and anterior lower calyces were then accessed with a flexible cystoscope through the side port without manipulating the position of the sheath and stone fragmentation performed with Holmium-YAG laser.

**Results:** Complete fragmentation and clearance was achieved in all patients. The side port allows easier access to acutely angulated calyces without re-positioning of the sheath and reduces the need for additional punctures to access these calyces. No obvious shortcomings were noted.

**Conclusion:** This accessory side port in a Amplatz sheath appear to be a very useful modification which hopefully reduces the need for additional punctures and improves stone clearance. Further study in larger numbers is recommended.

### MP22-02 NON-CONTACT INFRARED TEMPERATURE MEASUREMENT OF ULTRASONIC LITHOTRIPSY PROBES—A COMPARISON OF 3 DIFFERENT LITHOTRIPTERS DURING PERCUTANEOUS NEPHROLITHOLAPAXY (PCNL)

C. Keil, P. Olbert, A. Hegele, A. Schrader, R. Hofmann

**Background:** Ultrasonic lithotripters are used for percutaneous fragmentation and removal of renal calculi during PCNL. This proof of principle study was conducted to examine the temperatures of probe and handpiece during clinical lithotripsy with three different ultrasonic lithotripters using non-contact infrared camera technology.

**Methods:** Two patients with large renal stones underwent PCNL. In the first operation a Vario handpiece (EMS, Nyon, Switzerland/software 3.0) and a LUS2 (Olympus), in the second a US3 handpiece (EMS) was used to perform lithotripsy of 6 minutes. Temperature was measured at the handpiece using an infrared thermocamera (Fluke Ti20) at intervals of a minute. Fragment removal by suction was achieved using a LUS2 pump (level 1, 120 ml/min). During the second operation the ultrasonic power was raised from the manufacturer's advised maximum of 60% to 100% after 6 minutes with a temperature check every minute.

**Results:** After six minutes temperatures measured were  $46.6^\circ\text{C}$  for the Vario,  $40.6^\circ\text{C}$  for the US3 at powerlevel of 60% and  $31.7^\circ\text{C}$  for the LUS2. After changing to 100% power the temperature rose to  $62.1^\circ\text{C}$  using the US3 within 4 minutes. The temperature at the tip of the probe never exceeded the surrounding temperature regardless of the type of ultrasonic lithotrite.

**Conclusion:** The higher efficiency of EMS tools compared to the LUS2 is closely related to the rise of temperature at the handpieces. As no rise in the temperature at the tip of the probes could be measured, risks for patients are unlikely to occur. Increasing the ultrasonic-power using the US3 led to critical handpiece temperatures in the course of a very short time.

### MP22-03 PCNL IN PATIENTS IN PATIENTS WHO PREVIOUSLY UNDERWENT OPEN STONE SURGERY

T. Hareh, J. V d j, K. Sushil, S. Moteria, A. Jitendra

**Background:** Ours is a stone belt area (saurashtra) with very high stone prevalence rate as well as recurrence rate. Though nowadays, open stone surgery (OSS) is rare, in the past open stone surgery was the mainstay for urolithiasis. We encounter many cases who underwent open stone surgery now managed with PCNL. The aim of the study was to determine the possible impact of OSS on subsequent PCNL.

**Methods:** We reviewed 1980 patients record who underwent PCNL at our institute from 2003 to june 2009. We compared patients who had past history of OSS in the same renal unit undergoing PCNL and assessed various intraoperative, postoperative parameters like difficulty in PCS access, tract dilatation, bleeding, operative time, need for secondary procedurs, stone ree rate and other complications.

**Results:** Out of 1980 PCNL patients, we had 32 patients with past history of nephrolithotomy, 210 patients with past history of pyelolithotomy, 12 patients had anatomic nephrolithotomy. The group did not differ in terms of age or stone burden. The operative time ( $102 \pm 36$  v  $76 \pm 24$  min), secondary procedures (16 v 9), pelvicalyceal access time, tract dilatation timewere significantly higher in OSS group. However, stone free rate (96 v 95) and post operative complication (8 v 7%) did not differ significantly.

**Conclusion:** PCNL in a patients with past history of OSS may take longer time with some technical difficulty probably due to scar tissue and anatomic changes in the kidney. However, efficacy and safety of PCNL is this group of patients is equal to virgin PCNL case.

#### MP22-04 A RANDOMIZED PLACEBO CONTROL TRIAL TO STUDY THE IN VIVO EFFECT OF A CHINESE HERB, SHI WAI, IN MALE URINARY STONE FORMER

C. Ng, K. Ip, N. Poon, D. Gohel

**Background:** To investigate the in vivo effect of Shi Wai (Pyrrosia Sheareri), a commonly used traditional chinese medicine for stone disease, in male patients suffered from idiopathic urinary calculi.

**Methods:** This was a single centre, randomized, double blinded, placebo controlled study. Male patients of age 30–70 years old with history of idiopathic urinary calculi were recruited for this study. 50 ml of early morning urine was collected from each subject prior to treatment. Then they were randomized to receive either 1.5 gm Shi Wei or placebo daily for 7 consecutive days. Post-treatment early morning urine sample was collected again for analysis. All urine samples received biochemical and crystallization (crystal quality and quantity) analysis. Results of the two groups were then compared.

**Results:** 120 patients were recruited for this study. 21 patients were excluded for study due to violation of protocol, unsatisfactory quality of urine sample secondary to significant haematuria, pyuria or amorphous crystal. For the remaining 99 patients (48 in Shi Wei group and 51 in placebo groups), there was significant increase in urine magnesium level in the Shi Wei group ( $p < 0.05$ ). Otherwise there were no significant differences in other urinary biochemical composition and crystallization process. There were only 6 minor side effects (Shi Wei–2 and Placebo–4).

**Conclusion:** Shi Wei can modify the urine biochemistry by increasing the urine magnesium level. This may result in decrease in risk of stone recurrence.

#### MP22-05 ORDNANCE GELATINE AS AN IN VITRO TISSUE SIMULATION SCAFFOLD FOR SWL RESEARCH

C. Mendez Probst, M. Vanjecek, P. Cadieux, H. Razvi

**Background:** Shock wave lithotripsy research has historically involved wet coupling lithotriptors using a mesh basket model. This model however, does not take into account the attenuation of energy through tissue. Ordnance gelatin (OG) displays strength and viscous properties similar to human tissue and as such is the current standard for ballistic tissue injury research. We present our initial experience using an OG tissue simulating scaffold for dry coupling SWL research.

**Methods:** Using 10% OG prepared as described by Fackler et al. in a disc-shaped mold (5 stone wells/gel), we tested a single use model using a Modulith SLX-F2 lithotripter and artificial stones. The gels are inexpensive to make (approximately \$5/gel) and require only 2 hours preparation time. Following a test of concept run on an empty gel mold, we shocked 30 stones pre-soaked for 24 hours in 3 cc of human pooled urine. Fifteen stones were shocked with the narrow focus (NF) and 15 stones with the wide focus (WF), using energy level of 8, 2 Hz frequency and 1000 shocks. Fragmentation coefficients (FC) were calculated after discarding fragments of  $< 3$  mm.

**Results:** Each gel completed a test cycle of 5000 shocks (1000/well), without loss of gel integrity or fluid leakage. The mean FC was 77.9% (24–100) NF and 72% (25–100) WF.

**Conclusion:** Ordnance gel provides a reproducible, easily manufactured and inexpensive model for dry coupling lithotripsy research.

#### MP22-06 ENDOSCOPIC GUIDED PERCUTANEOUS ACCESS DURING PERCUTANEOUS NEPHROLITHOTOMY: IS IT OF ANY CLINICAL ADVANTAGE?

S. Beck, N. Jain, A. Kaplan, G. Box, R. Clayman, E. Mcdougall—USA

**Background:** Endoscopic guided renal access during percutaneous nephrolithotomy (PCNL) has been utilized where conventional fluoroscopic access would be difficult. A retrospective analysis was performed to determine if this technique provided any advantage over conventional PCNL access.

**Methods:** An endoscopic PCNL group (E) ( $n = 51$ ) was compared to a standard PCNL (S) ( $n = 70$ ) group. All PCNL access was performed by the senior authors (RVC and EMM) from 2002–2007 ( $N = 121$ ). The two groups were similar with regards to age, BMI, ASA score, & stone parameters with average stone volume being  $17 \text{ cm}^3$ - E group &  $16 \text{ cm}^3$  in the S group.

**Results:** There was a statistically significant difference in patient outcomes, favoring the endoscopic group: estimated blood loss was 211 ml vs. 158 ml for the E group ( $p = 0.03$ ), while postoperative transfusion rates were 21.4% vs. 7.8% for the E group ( $p = 0.05$ ). More patients in the E group presented with non-hydronephrotic system (27.1% vs. 11.7%,  $p = 0.04$ ), and more in the E group (80%) had a supracostal tract created compared to 44% in the S group ( $p = 0.0003$ ) which did not correlate with any difference in the percentage of chest tubes placed for pleural effusions (S group 4.2% vs. E group 3.9%,  $p = 0.92$ ). There was no statistical difference with regards to intraoperative or perioperative complications, embolization, narcotic usage, or change in GFR. There was no significant difference in stone free rates ( $< 1$  mm) (46% S



group vs. 35% in E group,  $p = 0.26$ ) as well as in the percentage of patients left with significant stone fragments ( $>4$  mm) (S group 26% vs. E group 31%,  $p = 0.56$ ). Average remaining stone fragment size in each group was 0.38 cm (S) vs. 0.31 cm (E), which correlated with increased retreatment rates in the standard group (36% versus 24%  $p = 0.19$ ). There was a trend towards significantly longer operative time (19 min,  $p = 0.1$ ) in the E group.

**Conclusion:** Endoscopic PCNL provides for precise renal access; in this retrospective study there were significant improvements in clinical outcomes with minimal increase in operative time. A randomized study is needed to accurately determine the potential value of this approach.

### MP22-07 COMPARISON OF MEDICARE REIMBURSEMENT FOR TREATMENT OF LARGE SOLITARY RENAL CALCULI BY URETEROSCOPY AND PCNL

J. Johannes, N. Leone, S. Hubosky, D. Bagley—USA

**Background:** Recommendations for the management of solitary renal stones  $>2$  cm in the urologic literature favor a percutaneous approach over ureteroscopic. The total Medicare reimbursement varies substantially between these two different surgical approaches. The goal of this analysis is to calculate and compare the cost to Medicare for ureteroscopic or percutaneous management of large solitary renal stones taking into account retreatment rates.

**Methods:** We retrospectively analyzed consecutive patients undergoing definitive ureteroscopic treatment of a solitary renal stone  $>2$  cm at our institution. Post-operative courses were reviewed and need for retreatment of residual stone was recorded. We analyzed the Medicare reimbursement for these procedures at our institution based on physician and facility fees and compared this cost with the reimbursement for PCNL.

**Results:** 18 consecutive patients were treated for solitary renal stones with largest cross-sectional diameter between 20 and 40 mm. 5 required retreatment (4 patients required one retreatment, 1 required two retreatments). The mean treatments per patient was 1.33. Using the Medicare rate for professional and facility reimbursement at our institution, the average Medicare reimbursement per patient was \$2721.85. Had these patients undergone inpatient PCNL assuming a 100% stone-free rate as compared to approximately 80% rate in the literature, an average Medicare reimbursement of \$10792.77 would have been collected per patient.

**Conclusion:** Treatment of solitary renal calculi  $>2$  cm by ureteroscopy is a clinically successful alternative to PCNL based on retreatment rate. Given current Medicare reimbursement rates, costs to Medicare are substantially lower than that of PCNL.

### MP22-08 OSTEOPOINTINE GENE POLYMORPHISM IN TURKISH UROLITHIASIS PATIENTS

E. Sönmezay, V. Tugcu, N. Gurbuz, A. Bitkin, T. Tarhan, A. Tasci

**Background:** Osteopontin (OPN) is expressed in a variety of different cell types in activated T cells, natural killer (NK) cells and macrophages. OPN was also identified as an organized matrix in calcium oxalate renal stones and purified from human urine. OPN plays an important role during the formation of urinary calculi, and its potent calcium-binding ability and cell-adhesive action make it a protein that is essential during the process of calcification in vivo. The aim of this study was to investigate possible association of a single nucleotide polymorphism (C to T) at position 9250 in exon of

the OPN gene (OPN gene 9250) with urolithiasis in patients and healthy volunteers.

**Methods:** A total of 60 (42 men and 18 women) urolithiasis patients and 50 (33 men and 17 women) healthy controls were studied. Genomic DNA was extracted from peripheral blood leukocytes. OPN gene 9250 polymorphism was detected by polymerase chain reaction and restriction fragment length polymorphism (PCR-RFLP). Chi-square test was used for comparison between patients and controls.

**Results:** The gene frequencies of C/C, C/T, and T/T at position 9250 on the Eta-1/osteopontin gene in urolithiasis patients were %35,18, %50, %14,81 respectively. The gene frequencies of C/C, C/T, and T/T at position 9250 on the Eta-1/osteopontin gene in healthy controls patients were %83,4, %0, %16,6 respectively. The frequency of CC genotype of the OPN gene 9250 was significantly lower (35,18% vs 83,4%,  $P < 0.05$ ) and the frequency of CT genotype of the OPN gene 9250 was significantly higher (50% vs 0%,  $P < 0.05$ ) in urolithiasis patients than in controls.

**Conclusion:** OPN gene 9250 polymorphism appears to be associated with susceptibility in urolithiasis patients.

### MP22-09 PERCUTANEOUS APPROACH FOR THE MANAGEMENT OF FORGOTTEN AND FRAGMENTED J-STENTS

L. Tahmaz, S. Bedir, M. Zor, S. Basal, I. Karabuga, M. Dayanc

**Background:** Forgotten ureteral stents represent a difficult problem for urologists, and a consensus on the best therapeutic approach is lacking. We present our experience with endoscopic management of this challenging problem.

**Methods:** We retrospectively reviewed the data of the five cases with forgotten J-stents in the last three years. All patients age were ranged between 21 years to 25 years, and the mean duration of stents in the urinary system was ranged between 6 months to 3 years.

**Results:** The stents were severely calcified and encrusted in all patients. In one case non-affected kidney was atrophic. One had also renal pelvis stone with fragmented J-stent and the last case had pelvic ectopic kidney with previous nephrolithotomy history. Four patients were treated with percutaneous nephrolithotomy (PCNL) alone. The last case that had pelvic ectopic kidney was treated with a combination of percutaneous and laparoscopic approaches. All stents and the associated stones were eventually removed without any complications.

**Conclusion:** Combined endourological techniques can achieve safe removal of forgotten stents if treatment is tailored to the volume of encrustation and associated stone. Imaging evaluation and documentation of urine cultures with negative findings are imperative prior to any attempt to remove the stent.

### MP22-10 EXTRAPERITONEAL LAPAROSCOPY-ASSISTED PERCUTANEOUS NEPHROLITHOTOMY IN A PATIENT WITH OSTEOGENESIS IMPERFECTA

L. Tahmaz, S. Basal, M. Zor, Y. Ozgok, M. Kilciler, M. Dayanc

**Background:** OI patients represent a challenge for all physicians, as they do for anesthetists and urologists when they develop symptomatic stones in the urinary tract. We recently treated an OI patient with renal pelvic stone by extraperitoneal laparoscopy-assisted percutaneous nephrolithotomy (PCNL).

**Methods:** An 18 years old paraplegic female patient with OI admitted to our clinic with right-sided flank pain. She pointed out that she had right kidney stone for last 2 years, and because of risks of

general anesthesia and surgical procedures, surveillance recommended. Intravenous pyelography revealed right renal calculus with grade 1–2 hydronephrosis. Renal function tests were normal. Stone burden was 144 mm<sup>2</sup> and the patient had severe left sided scoliosis. We performed extraperitoneal laparoscopy-assisted PCNL without any preoperative and postoperative complications.

**Results:** The operation time was 95 minutes and no blood transfusion required. The nephrostomy tube and retroperitoneal drain were removed after 2 and 3 days after the procedure, respectively. The patient is doing well at a follow-up of 6 months.

**Conclusion:** Extraperitoneal laparoscopy-assisted PCNL approach may decrease the risk of surgery as an alternative treatment modality for OI patients. Such cases should be operated at significant experienced centers in the field of endourology, where all the equipment and the specialized personnel are readily available.

### MP22-11 URIC ACID STONE FORMERS—NEED TO UPDATE PROTOCOLS FOR METABOLIC EVALUATION?

H. Joshi, N. Baban, J. Greenwood—UK

**Background:** New evidence is emerging regarding the role of metabolic abnormalities (insulin resistance, lipotoxicity) in the pathogenesis of idiopathic uric acid stones. However, none of the current protocols for the metabolic stone evaluation address these issues. We report our results of biochemical evaluation in such patients.

**Methods:** We reviewed details of the clinical and metabolic evaluation of uric acid stone formers from 2003–2007. Detailed analyses of features suggestive of metabolic syndrome including serum urate levels, presence of diabetes and lipid abnormalities were performed. The results were compared with non-stone formers.

**Results:** There were 403 patients who underwent treatment and stone analyses for urinary calculi. Of these, 41 were found to have uric acid stones (Male = 36, Female = 5, median age 65 years). 31% of these patients were diabetic (4.4% in general population) with 23% developing DM after stone analysis. 46% of the diabetics had hyperlipidaemia compared with 7% of the non diabetics. 28% of patients showed features of metabolic syndrome.

**Conclusion:** A significant proportion of patients with uric acid stones have evidence of impaired glucose and lipid metabolism that are associated with cardiovascular disease. Complete metabolic evaluation should be considered in these patients in addition to the existing guidelines.

### MP22-12 SURROUNDING FLUID ENVIRONMENT IMPACTS STONE FRAGMENTATION RATE: AN IN VITRO MODEL USING A HARD ARTIFICIAL CALCULUS

C. Mendez Probst, M. Vanjcek, P. Cadieux, H. Razvi—Canada

**Background:** Studies have suggested that stone fragmentation rates can be affected by various fluid media, although evidence to support a causative role for specific gravity (SG) is inconclusive. Our aim is to further explore the impact fluid media and SGs have on stone fragmentation using a variable focus lithotripter.

**Methods:** Artificial stones, pre-soaked in human pooled urine for 24 hrs, were placed in a 10% ordnance gelatin tissue simulating scaffold with 3 cc of either synthetic urine (SG 1.01 and 1.02), Pentaspan (SG 1.01), 100% contrast (SG 1.22), 30% contrast (in saline [SG 1.07]), 100% ethanol (SG 0.794) or lubricating jelly (SG 1.015) and shocked using an Storz SLX-F2 electromagnetic lithotripter (rate 2 Hz, energy 8, 1000 shocks). Fifteen stones each

were shocked using narrow (NFG) and wide foci (WFG) for each fluid group. Fragments >3 mm in diameter were weighed and fragmentation coefficients (FC) calculated.

**Results:** WFG: FC of lubricating jelly was significantly lower when compared to all other mediums ( $p < 0.001$ ); Ethanol FC was lower than both contrasts ( $p < 0.05$ ); All other medium FCs were not significantly different. NFG: FC of lubricating jelly was significantly lower than all other mediums ( $p < 0.001$ ); Ethanol FC was lower than Pentaspan, both synthetic urines and contrasts ( $p < 0.001$ ) and synthetic urine SG 1.01 FC was lower than 30% contrast ( $p < 0.05$ ).

**Conclusion:** Different fluid mediums can significantly improve or reduce FC in-vitro although SG impact appears to fit within a narrow range. Contrast (30%) increases FC but only in the NF.

### MP22-13 PERCUTANEOUS ACCESS FOR INTRARENAL SURGERY: THE LEARNING CURVE

O. Negrete-pulido, M. Molina-torres, A. Loske, J. Gutierrez-Aceves

**Background:** Fluoroscopically guided techniques to access the kidney percutaneously with low exposure to radiation have been used successfully for many years in our training center. The purpose of this study was to analyze the learning process and to establish the number of procedures required for a non-experienced urologist to obtain competence at performing a percutaneous renal access.

**Methods:** 82 percutaneous renal accesses in patients with renal stones or UPJ obstruction were evaluated. The time required to perform a correct puncture and the fluoroscopic screening time were recorded for each renal access. Descriptive analysis, analysis of variance and a Markov chain were used to analyze the results.

**Results:** The rate of success increased from 82.5% to 97.6% after the first 40 punctures. Puncture time and fluoroscopy time decreased as the number of procedures increased. Incidence of complications was 30% for the first 20 cases, decreasing to 10% in the next 20 cases and 3.7% in the last 33 cases.

**Conclusion:** The fluoroscopy-guided approach used in this study is an effective and reproducible technique. Our analysis revealed that at least 40 punctures are needed to acquire reliable competence in obtaining access to the kidney.

### MP22-14 COMPARATIVE STUDY THE CLINICAL VALUE OF SINGLE B-MODE ULTRASOUND AND B-MODE ULTRASOUND COMBINED COLOR DOPPLER ULTRASOUND IN THE GUIDANCE OF MINI-INVASIVE PERCUTANEOUS NEPHROLITHOTOMY (M-PCNL) TO DECREASE THE HEMORRHAGIC COMPLICATIONS

X. Gao, M. Lu, X. Pu

**Background:** To compare the clinical value of single B-mode ultrasound and B-mode ultrasound combined Color Doppler ultrasound in the guidance of mini-invasive percutaneous nephrolithotomy (m-PCNL) to decrease the hemorrhagic complications.

**Methods:** From April 2004 to April 2007, 297 patients with renal stones underwent m-PCNL were retrospectively categorized into two groups. Group 1 (187 patients) underwent m-PCNL with single B-mode ultrasound guidance and group 2 underwent m-PCNL with combined B-mode ultrasound and color ultrasound guidance. The age, height, weight, preoperative hemoglobin level, stone burden, operating time, stone free rate, length of

postoperative hospital stay, postoperative urinary tract infection rate, blood transfusion rate and hemorrhagic complications were recorded and compared.

**Results:** No statistically significant differences in age, height, weight, stone burden, operating time, stone free rate, length of postoperative hospital stay or other complications were found between the two groups. In group 2, a statistically significant decrease in the transfusion rate was determined compared with group 1 ( $p < 0.05$ ). In group 1, 5 patient (2.6%) needed blood transfusion, 2 patients (1.1%) suffered from renal arteriovenous fistula and needed embolotherapy, 2 patients (1.1%) suffered from hemorrhage and needed embolotherapy after operation, 16 patients (8.6%) suffered from capillary hemorrhage during operation and no hemorrhage after operation.

**Conclusion:** Using combined B-mode ultrasound and color ultrasound guidance in m-PCNL can obviously and real-timely detect and avoid the renal blood vessels during the puncture and decrease the hemorrhagic complications, especially in the patients with solitary and compensative kidney.

### MP22-15 MINIMALLY INVASIVE PERCUTANEOUS NEPHROLITHOTOMY (MPNL) IN TREATMENT OF CALCULI IN HORSESHOE KIDNEY

A. Jitendra, R. Dipak

**Background:** Because of abnormal anatomical position, management of calculi in horseshoe kidneys often challenging, we present our experience with minimally invasive percutaneous nephrolithotomy (MPNL) in such cases.

**Methods:** We performed MPNL in 16 patients with 19 stone bearing horseshoe kidneys. IVU & CTU were done to evaluate location & size of stones. After appropriate preoperative evaluation all MPNL procedure were done in standard one session technique. Procedures were evaluated for intraoperative & postoperative complications with use of auxiliary procedure - use of drain, length of hospital stay & stone free rate.

**Results:** The mean age was  $39.55 \pm 15.15$  years. Three patients had bilateral stones. Operation time lasted 35–135 minute, average of 85 minutes. No blood transfusion given to any cases. Nephrostomy tube was kept in 10 cases & tubeless procedure was done in 9 cases. No significant complication seen. 3 cases were having fever & recovered with symptomatic treatment. J. stent was kept in all cases & removed after 4 week. The immediate stonefree rate was 93.50%. All patients were discharged within 3 days.

**Conclusion:** Minimally invasive percutaneous nephrolithotomy (MPNL) is better effective & less invasive & safer operation even in patients with calculi in horseshoe kidneys.

### MP22-16 TUBELESS PERCUTANEOUS RENAL SURGERY IN SUPINE POSITION: INITIAL EXPERIENCE AND COMPARISON WITH NON TUBELESS TECHNIQUE

S. Benjamin, F. Vargas, F. Araya, J. De la torre, P. Valdevenito, E. Maldonado—Chile

**Background:** Supine position is an accepted and growing alternative for percutaneous renal surgery (PCRS). Recently, tubeless surgery has gained interest due to safety data. We present our initial operative outcomes and comparative data among patients undergoing PCRS in supine position, both tubeless and non-tubeless.

**Methods:** A prospective, observational study of all our cases of PCRS in supine position was performed. Demographic and operative data, including age, BMI, stone volume, operative time,

complications, length of stay, were recorded. Patients were divided in 2 groups: 1. standard non tubeless (NTL) and 2. tubeless (TL).

**Results:** From August 2005 to June 2009, 87 renal units in 85 patients, were operated by a single surgeon. Group 1 consisted of 67 renal units, including 4 cases of endopyelotomy and an upper calyx diverticulum. Group 2 consisted of 20 cases, including an antegrade ureteroileal stenosis dilation in a solitary kidney Bricker patient. Both groups were comparable in terms of stone burden ( $425 \text{ mm}^2$  NTL vs  $570 \text{ mm}^2$ ), BMI, mean operative time (80 min NTL vs 62 min TL). NTL patients were performed under regional anaesthesia in 25,3% vs 85% for the TL group. NTL group resulted in 72,3% stone free or residual fragments  $< 5 \text{ mms}$  vs 94.7% in TL group. Complication rate was similar, 2 patients in NTL group had transfusion (2.9%) vs none in TL group. 5.9% in NTL group had infection vs 10% in TL group (n.s). One patient (1.5%) needed conversion to open in NTL group vs none in TL group. NTL group included 4 cases of antegrade endopyelotomy, and one case of stone containing upper calyx diverticulum, all treated successfully. One patient in NTL group had simultaneous bilateral PCNL. Discharge was significantly earlier in the TL group (median POD 1 (1–3) vs POD 4 (3–17) ( $p < 0.005$ ).

**Conclusion:** Tubeless PCRS is safe and effective when performed in selected cases, it can be done under regional anaesthesia, allows simultaneous lower tract instrumentation, and shortens length of stay.

### MP22-17 UNIQUE SCORING SYSTEM FOR SELECTING A LITHOTRIPTER

M. Hanna, M. Medhat, R. Prem

**Background:** The presence of many Lithotripters in the market with different specifications makes selection of a Lithotripter a difficult task. For this reason we designed a unique scoring system to help making the proper decision which suites our requirements.

**Methods:** Two stage scoring system, first stage help to decide which lithotripters we should see. Second stage to assess clinical efficacy First stage was constructed by giving points to each criterion. These criteria were divided to primary and secondary according to the importance of this criterion in our set-up. The primary criterion (Technology of Shock wave, Localization, Work station, Service) was given twofold points of the secondary (Accessories, Health and Safety, Unit circumstances) Second stage scores were awarded during presentation days for actual treatment result, practical assessment of criteria used in the first stage and publications from renowned units.

**Results:** On applying the first stage of the scoring system on 12 different Lithotripters we managed to exclude 9 of them as they were beyond our requirements. The 3 top-listed Lithotripters were reassessed using the second stage our scoring system, resulting in one obvious selection which meets most of our needs.

**Conclusion:** The scoring system made our tasks very clear and less affected by the marketing propaganda. We have found this scoring system to be very efficient and helpful to make the proper choice. We recommend that our scoring system or a similar should be used in selecting the Lithotripter which fulfils the unit requirements.

### MP22-18 DOES THE PRESENCE AND SEVERITY OF HYDRONEPHROSIS HAVE AN IMPACT ON THE OUTCOMES OF PERCUTANEOUS NEPHROLITHOTOMY PROCEDURES?

O. Tanriverdi, M. Kendirci, M. Kadihasanoglu, M. Aydin, H. Sirin, C. Miroglu

**Background:** To investigate the impact of preoperative hydronephrosis on the outcomes of the percutaneous nephrolithotomy (PCNL) procedures.

**Methods:** Between 2005 and 2009, 409 PCNL procedures were divided into four groups based on the presence or the severity of preoperative hydronephrosis: Group-1 (n = 163): PCNLs without any hydronephrosis, group-2 (n = 144): PCNLs with mild hydronephrosis, group-3 (n = 76): PCNLs with moderate hydronephrosis, and group-4 (n = 26): PCNLs with severe hydronephrosis. All PCNL procedures were performed by the two surgeons at the same clinic. All the groups were statistically compared regarding to a number of parameters.  $p < 0.05$  was considered as significant.

**Results:** Records for 409 PCNL procedures were available for the analyses. Patients in the group-3 were found to be younger, but in group-4 older than others. Gender and BMI of the patients, lateralization of the procedure, mean number of access, and mean stone clearance, blood transfusion and complication rates were comparable among the groups ( $p > 0.05$ ). Additionally, no statistically significant difference was found among the groups regarding mean fluoroscopy times ( $p = 0.786$ ), but mean operation time of the group-3 was significantly longer than the other groups ( $p < 0.05$ ). Furthermore, the patients with higher grade of hydronephrosis were less likely treated with ESWL before the PCNL.

**Conclusion:** These data demonstrate that neither the presence nor the severity of hydronephrosis exhibited significant impact on the outcomes of PCNL procedures.

#### MP22-19 NOVEL USE OF A COAXIAL FILM-BASED OCCLUSION DEVICE FOR OPTIMAL ACCESS DURING PERCUTANEOUS NEPHROLITHOTOMY

M. Gupta, M. Rothberg, M. Wosnitzer—United States

**Background:** Intercostal renal access during percutaneous nephrolithotomy (PCNL) is associated with an increased incidence of pneumothorax, hydrothorax, or hemothorax post-operatively. We sought to utilize a new coaxial film-based occlusion device, the Coaxial Accordion™ (Percsys, Mountain View, CA), in a novel fashion to lower the kidney in situations when intercostal access appeared to be unavoidable and to establish a more ideal subcostal renal access.

**Methods:** Five patients were identified at the time of PCNL who either had relatively superiorly located kidneys (2 patients) or who required upper pole access (3 patients). In each instance, the patient would have required intercostal access to reach the intended calyx of entry. In two cases the access would have been supra-11th and the other 3 supra-12th rib. The 15 mm Coaxial Accordion™ occlusion device was deployed within the renal pelvis as it normally is done to prevent stone migration. During the process of percu-

taneous needle access, gentle traction was held at the ureteropelvic junction to prevent upward movement of the kidney with ventilation.

**Results:** In two patients, this technique was used to establish access at the 11th intercostal space instead of the 10th. In three patients, the kidney was mobilized and lowered to establish subcostal renal access, completely avoiding the potential morbidity of intercostal access. No injury to the UPJ, renal pelvis, or ureter was identified upon endoscopy due to the atraumatic nature of this device. In all five patients, stone-free status was achieved and no stone migration occurred. Mean operative time and hospital stay were similar to patients undergoing PCNL without use of the technique.

**Conclusion:** Deployment of a coaxial film-based occlusion device can be used to lower the kidney during percutaneous needle placement, potentially avoiding complications associated with intercostal renal access.

#### MP22-20 PERCUTANEOUS NEPHROLITHOTRIPTY (PCNL) FOR PATIENTS WITH PREVIOUS OPEN RENAL SURGERY: IS THERE ANY PROGNOSTIC FACTOR?

S. Ben Rhouma, S. Sallami, M. Basli, A. Horchani, Y. Nouira

**Background:** To investigate the efficacy and complication rates of Percutaneous Nephrolithotomy (PCNL) performed in patients who previously underwent open renal surgery.

**Methods:** Between October 1998 and September 2008, 258 patients with renal calculi in which PCNL was performed were divided into two groups. Group A comprised 211 patients who had no previous open renal surgery and group B included 47 who had previous open renal surgery. In each group of patients the stone size, position, operation time, number of tracts, hospitalization time, residual stones and complication rates were recorded and were compared with each other.

**Results:** No significant differences were between the two groups concerning: hospitalization time, stone free rate, residual stones, pre and post-operative complications (table). Group A Group A P value Hospitalization time  $2.7 \pm 2.1$   $3.5 \pm 2.7$  0.21 Stone free rate 74.9% (n = 158) 66% (n = 31) 0.28 Pelvis perforation 24 3 0.45 Per-operative heavy bleeding 9 (one nephrectomy) 1 0.78 Significant residual stones 43 12 0.56 Access to renal stone was considered more difficult in group B than in group A. Operation time is longer and transfusion rate is lower in PCNL after open surgery (0.04 and 0.03 respectively).

**Conclusion:** Due to the formation of fibrosis in patients who had previous open renal surgery access difficulties can be seen. PCNL can be performed with low complication and high success rates in patients who previous open renal surgery was performed.

## MP23: LOWER URINARY TRACT

### MP23-01 PATIENT-REPORTED OUTCOMES AFTER POLYDIMETHYLSILOXANE INJECTION IN MALE PATIENTS WITH POSTOPERATIVE STRESS URINARY INCONTINENCE

D. Tienforti, E. Sacco, A. D'addressi, F. Pinto, M. Gardi, A. Tarquini, P. Bassi

**Background:** We aimed to assess patient-reported outcomes (PROs) after polydimethylsiloxane (PDS) injection in male patients with postoperative stress urinary incontinence (SUI).

**Methods:** We retrospectively evaluated 35 consecutive men (mean age of 69 years) suffering from postoperative SUI and treated since July 2006 to February 2009 with transurethral injections of PDS, using a standard Macroplastique needle (5 Fr). Thirtythree patients had undergone radical prostatectomy, 2 TURP and 5 received postoperative pelvic radiotherapy. Pad use and Stamey grading of the incontinence (0 to 3) were assessed prior to injection and again at last follow up. PROs were assessed using questionnaire including 3 standardized items exploring on Likert-like scales (higher score=better outcome) Patient Global Impression of Improvement (PGI-I; score 1–7), Patient-Reported Satisfaction (PSat; score 0–5) from the treatment and Patient-Reported Success (PSuc; score 0–5) of the procedure.

**Results:** Thirtythree patients were available for evaluation. Mean follow-up was 14 months (range 2–31). Mean Stamey grade before treatment was 2,1. Thirteen patients underwent more than 1 injection. Mean PDS volume injected for patient was 5,42 ml (2.5–12). Overall improvement rate (PGI-I score  $\geq 5$ ) was 12% (4/33); mean PGI-I score was 3,92. Overall satisfaction rate (PSat score  $\geq 3$ ) was 12% (4/33); mean PSat score was 1.50. Overall success rate (PSuc score  $\geq 3$ ) was 11% (3/33); mean PSuc score was 1.20. Only 6 patients (18%) would recommend the treatment to someone else and only 8 patients (24%) would undergo the treatment again. Six patients (18%) underwent other surgical treatments.

**Conclusion:** Patient-reported outcomes after bulking therapy using PDS are unsatisfactory in our series of male patients with postoperative SUI.

### MP23-02 EVALUATION OF LONG-TERM RESULTS OF BOTULINUM-A TOXIN INJECTIONS INTO THE DETRUSOR MUSCLE FOR IDIOPATHIC OVERACTIVE BLADDER SYNDROME (OAB)

C. Frohme, Z. Varga, A. Schrader, P. Olbert, R. Hofmann, A. Hegele—Germany

**Background:** Quality of life is negatively affected by the symptoms of OAB. Standard treatment is the application of anticholinergics associated with nasty adverse effects. If conservative management failed highly invasive treatment like bladder augmentation is indicated. The aim of our prospective ongoing study was to evaluate the efficacy and safety of singular or repeated botulinum-A toxin injections in the bladder detrusor muscle in patients suffering idiopathic OAB resistant to conventional treatment options.

**Methods:** From 5/2005–12/2007 a total of 30 female patients (mean age 68, range 18 to 84) with OAB were treated with injections of 500 MU botulinum-A toxin (Dysport®) in the detrusor muscle at 20 sites under cystoscopic guidance including the tri-

gonal area. Micturition diary, full urodynamics, and urine probes were performed in all participants before treatment. Subjective satisfaction, data from micturition diary, side effects and the duration of effect persistence were evaluated prospectively (baseline and after 3 and 12 months). Special attention was given to bladder capacity, post-void residual urine, urgency, frequency/nocturia, effect duration and the performance of life quality.

**Results:** The median follow up was 9.5 months (range 3 to 21). Mean frequency decreased from 12 to 5 micturitions daily in 67% and nocturia decreased in 44% of the patients. Urgency disappeared in 74% of the patients within 28 days after therapy. Mean effect duration until OAB symptoms revival was 6 months (range 1 to 17 months). Using a visual analog scale (1–10) subjective improvement in quality of life was achieved in 25 of the patients (mean 2 to 7). Except temporary urine retention in 2 cases (6.7%) no severe side effects occurred.

**Conclusion:** The results of our prospective study show that the endoscopic application of botulinum-A toxin into the detrusor muscle is a safe and highly effective treatment option in patients with OAB refractory to conventional treatments. Botulinum-A toxin injections maybe close the therapeutic gap between oral medication and bladder surgery in OAB patients. However, additional studies are necessary to standardize this new treatment option concerning for example dose and number of application sites.

### MP23-03 EFFICACY OF REPEATED BOTULINUM TOXIN TYPE A (BTX-A) INJECTIONS INTO THE BLADDER MUSCLE DUE TO IDIOPATHIC OVERACTIVE BLADDER SYNDROME (OAB)

C. Frohme, Z. Varga, A. Schrader, P. Olbert, R. Hofmann, A. Hegele—Germany

**Background:** BTX-A injection into the detrusor muscle represents a safe, effective and minimal invasive therapy for OAB if application of anticholinergics is not successful or associated with adverse side effects. Up to date only a few data are available for the efficacy of repeated BTX-A injections in OAB so the aim of our ongoing prospective study is to clarify this point of interest.

**Methods:** 15 pat. (median age 65 y.) with OAB were treated 35× with BTX-A (500 MU Dysport®, 20 injection sites). 1 pat. was treated 4 times, 3 pat. were treated 3 times and 11 pat. were treated twice. Micturition diary, full urodynamics, and urine probes were performed in all pat. before treatment. Subjective satisfaction, data from micturition diary, side effects and the duration of effect persistence were evaluated prospectively.

**Results:** Median follow up was 34 months. After first BTX-A injection the median effect duration was 9 months. In 15 pat. second local BTX-A application showed a median effect duration of 6 months. Third BTX-A injections in 3 pat. showed a median effect duration of 9 months and one pat. presents still the positive BTX-A effects after fourth application of actual 13 months. Mean frequency decreased from 15 to 5 micturitions daily and 6 to 3 during the night. Urge incontinence episodes suspend in 50% of the pat. Quality of life (QoL) was improved in all patients. No relevant side effects occurred after repeated injections.

**Conclusion:** Endoscopic application of BTX-A into the detrusor muscle represents a safe and effective therapy option in OAB re-

fractory to anticholinergics. Our prospective data show that repeated application of BTX-A is feasible, safe and equivalent effective compared to first BTX-A injection concerning duration, symptom reduction and improvement in QoL.

#### **MP23-04 IS THE EXTENSOR DIGITORUM BREVIS TEST USEFUL IN PREDICTING RESISTANCE TO TREATMENT WITH BOTULINUM TOXIN-A IN PATIENTS WITH OVERACTIVE BLADDER?**

P. Sangster, V. Kalsi, A. Sahai, C. Cordivari, C. Fowler, P. Dasgupta—UK

**Background:** As the use of Botulinum toxin-A (BTX-A) treatment for overactive bladder syndrome becomes more popular, concern regarding the development of immunoresistance to the drug increases. We investigated the use of the extensor digitorum brevis (EDB) test to predict resistance in this clinical setting.

**Methods:** Five patients (3 female; 2 male; mean age 38 years) with a diagnosis of idiopathic detrusor overactivity who perceived no improvement following 200U BTX-A injections were recruited for this study. Complex muscle action potential (cMAPs) amplitude measurements were taken before and one week after injections of 50 mu BTX-A into the EDB. Patients were considered not to have antibodies and thus resistance, when the amplitude of the cMAP fell by more than 50% compared to the pre-BTX injection amplitude.

**Results:** All 5 patients were found to have >50% decrement (mean 75%) in their cMAP following BTX-A administration into the EDB suggesting that they did not have resistance to BTX-A. Based on these results, this group of patients had further intra-detrusor BTX-A injections (200–300 U) and in all cases perceived an improvement in their bladder symptoms. This was confirmed when comparing their voiding diary and QoL data between injections.

**Conclusion:** In those patients where treatment has failed, our data suggests that the EDB test maybe useful in deciding if immunoresistance has occurred. In cases where the test is negative, at least one further injection is warranted, as successful outcomes are obtainable.

#### **MP23-05 TREATMENT OF MODERATE TO SEVERE FEMALE STRESS URINARY INCONTINENCE WITH THE ADJUSTABLE CONTINENCE THERAPY DEVICE (ACT) AFTER FAILED SURGICAL REPAIR**

P. Sassani, S. Aboseif, J. Gleason, E. Franke, S. Nash, J. Slutsky—USA

**Background:** Mid urethral slings are considered to be the treatment of choice for genuine stress urinary incontinence. Treatment of recurrent incontinence after failed surgical procedure is more complicated and repeat surgery has higher rates of complications and limited efficacy. We determined the technical feasibility, efficacy, adjustability, and safety of adjustable continence therapy device for treatment of moderate to severe recurrent urinary incontinence after failed surgical procedure.

**Methods:** Female patients with moderate to severe recurrent stress urinary incontinence who had at least one surgical procedure for incontinence were enrolled. Moderate and severe incontinence defined as 11–50 and >50 gram of urine loss in provocative pad test respectively. All patients underwent percutaneous placement of Adjustable Continence Therapy (ACT) device (Uromedica, Plymouth, Minnesota). Baseline and regular follow up tests to determine subjective and objective improvement were performed.

Device adjustments were performed percutaneously in the clinic postoperatively. FDA protocol was followed to record all adverse effects and complications.

**Results:** A total of 89 patients have undergone implantation with 1–3 years of follow up. Data is available on 77 patients at one year. Of the patients 47% (34 of 72) were dry (less than 2 gm on provocative pad weight testing) at 1 year and 91% (66 of 72) improved (50% or more reduction in provocative pad weight testing) after 1 year follow up. Stamey score improved from 2.21 to 0.94 at one year ( $p < 0.001$ ). Incontinence Quality of Life questionnaire score improved from 33.9 to 71.6 in one year ( $p < 0.001$ ). Urogenital Distress Inventory reduced from 60.7 to 33.3 ( $p < 0.001$ ) in one year. Incontinence Impact questionnaire score reduced from 57.0 to 21.6 ( $p < 0.001$ ). Diary incontinence episodes per day improved from 8.1 to 3.9 ( $P < 0.001$ ). Diary wet pads number per day improved from 4.3 to 1.9 ( $P < 0.001$ ). The mean number of adjustment visits at 1 year was 2.03. Explantation was required in 21.7% of patients (18 of 83). Fifty percent of those patients (9) were re-implanted.

**Conclusion:** The ACT device is an effective, simple, safe and minimally invasive treatment for moderate and severe recurrent female stress urinary incontinence after failed surgical treatment. The device can be easily adjusted percutaneously to enhance efficacy. Complications are usually easily manageable. Explantation is an easy office procedure and does not preclude future repeat implantation.

#### **MP23-06 URINARY OUTCOMES FOLLOWING PHOTO-SELECTIVE VAPORIZATION OF THE PROSTATE (PVP)**

J. Wei, N. Casanova, R. Jackson, L. Wallner, R. Dunn

**Background:** PVP is rapidly replacing TURP in the US; however, studies reporting urinary complications have been limited. We examined urinary incontinence (UI) and delayed bleeding among 104 men who underwent a Greenlight PVP between 2007 and 2009.

**Methods:** Measures of LUTS (IPSS), UI (Incontinence Symptom Index) and post operative bleeding (gross hematuria requiring medical attention after discharge (GH)), were abstracted using explicit chart review. Associations with prostate size and 5-alpha-reductase inhibitors (5ARI) were examined.

**Results:** The mean age and prostate size was 68 y and 79 g, respectively. Average follow-up was 4 months. Although 79% of patients had an improvement in LUTS (IPSS change >4), the prevalence of any UI (ISI >4) was 27%, but only 55% of those subjects had bothersome UI. Incontinence was correlated with failure to respond to PVP (table,  $p = 0.01$ ). GH occurred in 19% and was associated with prostate size ( $p = 0.04$ ) but not 5ARI use ( $p > 0.99$ ). 9% required emergency department visits, and 5% required hospital admissions. Table. Relationship between post-operative LUTS and urinary incontinence Post-operative ISI Post-operative IPSS <4 5+None/Low: 0–7 88% 12% Moderate: 8–18 57% 43% High: 19–32 25% 75%.

**Conclusion:** UI occurred frequently but was not often bothersome. Greater residual LUTS was associated with more UI. The rate of post operative bleeding is comparable to TURP after accounting for larger prostate sizes.

#### **MP23-07 SIS(SUBMUCOSAL INTESTINAL SUINE) FOR THE TREATMENT OF URINARY STRESS INCONTINENCE IN OBESE WOMEN**

M. Baptistussi, M. Morihisa, E. Gewher, A. Martins—Brasil

**Background:** Urinary incontinence develops in between 5% and 25% of women, and has been positively associated with obesity in numerous studies. The aim of this study was to determine whether SIS was a successful procedure for cure of stress urinary incontinence in obese women.

**Methods:** TWENTY-ONE obese women with BMI >35 were treated for urinary genuine stress incontinence with the tension free vaginal procedure under intravenous anesthesia. The mean age of patients was 49.2 years (30–59). All patients underwent conventional urodynamics for evaluation of lower urinary tract function and 2 hours pad test were performed before the procedure.

**Results:** The follow-up range was six to twelve months postoperatively. NINETEEN patients were cured, and two noted improvement in her symptoms. There were no bladder perforations and in generally no major surgical complications occurred. The postoperative hospitalization was 24 to 48 hours.

**Conclusion:** The SIS is effective in women with genuine stress incontinence and BMI >35. The procedure is safe and minimally invasive. However, long-term follow-up is needed to determine whether this surgery achieves long-lasting results.

### MP23-08 GOSERELIN ACETATE COMBINED PKRP FOR BENIGN PROSTATIC HYPERPLASIA IN PATIENTS WITH HIGH SURGICAL RISK

W. Xue, J. Pan, H. Chen, Q. Chen, Y. Chen, Y. Huang

**Background:** To evaluate the feasibility and the clinical outcome of the transurethral resection of prostate by plasmakinetic TUR system in the BPH patients with high surgical risk pretreated by short-term (3 months) subcutaneous administration of goserelin acetate.

**Methods:** 13 cases of benign prostatic hyperplasia with surgical indication were enrolled in the study. The mean age was 78.2 years (65–88). 2 cases had normal erectile function before the treatment. All the cases were classified as degree III according to the ASA 5 classification system. Before the treatment, a DRE and serum PSA level examination were performed in the clinic. For the patients suspected of prostate neoplasm, the transrectal puncture biopsy of the prostate was carried out to eliminate the prostate cancer. A 3.6 mg goserelin acetate was given subcutaneously for 3 consecutive months. A transrectal Doppler ultrasonography of the prostate was done to evaluate the prostate volume, the maximum intra-prostatic blood velocity and vessel resistance before and after the 3 months' medical treatment. The bipolar plasmakinetic system (Gyrus) was used for the transurethral resection of prostate. The adverse effect during the goserelin acetate treatment, the operative time, the intra-operative and post-operative complications, the post-operative natremia, the hospital stay and the catheter time were recorded in all the patients. The mean follow-up was 10 months (range 3 to 14 months). The paired samples test of the prostate volume, the maximum intra-prostatic blood velocity, vessel resistance and the drop of the hemoglobin were processed by SPSS 10.0.

**Results:** The average serum total PSA was 6.98 ng/ml and the PSAD was 0.1 before the goserelin acetate treatment. The mean prostate volume was 68.65 ml before the goserelin acetate administration and 47.40 ml after 3 consecutive months' treatment, respectively ( $P < 0.01$ ). The mean maximal intra-prostatic blood velocity was reduced from 24.05 ml/s to 13.05 ml/s, respectively ( $P < 0.01$ ). The intra-prostatic vessel resistance index was reduced from 0.73 to 0.65, respectively ( $P < 0.01$ ). No patient discontinued

the treatment due to important side effects. Loss of potency occurred in all the 2 cases previously potent during the treatment while the erection came back in one patient after the cessation of the goserelin acetate administration. The mean operative time was 35 minutes. There was no perioperative complication. The mean hemoglobin drop was 0.95 g/dl. The urinary catheter was removed successfully in 11 patients 72 hours after the procedure. In the other 2 patients, a urinary retention occurred after the removal of the urinary catheter probably because of the detrusor muscle weakness. The mean hospital stay was 3 days. One patient presented urethral stricture 3 months after the procedure and retreated by the endourethrotomy with regular urethral dilation.

**Conclusion:** Short-term (3 months) administration of goserelin acetate significantly decreased the prostate volume as well as the blood supply of the prostatic tissue which assured a safer transurethral resection of prostate by the plasmakinetic TUR system in patients previously non operable with the classic monopolar system. The combination therapy might result in a shorter operative time, fewer blood loss, lower medical side effect, and lower surgical complication rate for these patients. It is a reasonable and cost-effective choice for the urologists when treating the BPH patients with high surgical risk.

### MP23-09 PROGRESSION OF SURGICALLY TREATED BPH PATIENTS WITH RENAL INSUFFICIENCY

T. Hareh

**Background:** To assess the progression of RI patients, evaluate comorbidity, analyzing the technical problems of surgery, precaution to be taken and there by proposing a management algorithm.

**Methods:** A total of 42 RI patients were evaluated retrospectively who have S. Creatinine >1.5 and brought them into 3 groups, group-I with primary renal insufficiency (? Cause, CRF, ESRD), group-II with obstructive uropathy and group-III with both primary RI & obstructive uropathy and evaluate depending on the duration of symptom manifestation. All patients were analyzed with serum electrolytes, s.creatinine, usg, uroflow, qol and Improvement in comorbidity. All these cases were treated surgically by TURP and were Followed upto minimum 2 months. Morbidity status during perioperative period assessed.

**Results:** Three comparable groups of patients were formed and results analyzed. Average age of presentation is 64 yrs with commonest comorbidity being IHD and COPD and more than 54% of these patients presented late in their disease process with an average of 14.5 months. Bladder decompression in these patients helped in reducing the back pressure effects, normalizing/stabilizing the s.cr levels improvement in comorbidity. Minimum of 1 week and maximum of 30 weeks bladder drainage was noted. All patients of group3, two patients in group 2 and 66% of group1 showed irreversible progression. Most of the patients who improved had their bladder decompressed prior to TURP. Preoperative morbidity were common in chronic cases with long standing obstruction Especially in group 2 patients where as Intra op technical problems were more in group 3 Patients. Mortality noted in 1 patients. All other technical problems and qol were comparable to normal patients with BPH.

**Conclusion:** Late presentation (chronic) with obstructive uropathy had more severe post op. course especially when associated with comorbidity. Primary RI in these patients adds oil to the flames. Early intervention with preliminary bladder drainage in patients

with S.Creatinine >1.5 reduces perioperative morbidity both primary and comorbidity and stabilizes the progression and decreases mortality.

**MP23-10 ABLATIVE EFFICIENCY OF LITHIUM TRIBORATE LASER VAPORISATION AND CONVENTIONAL TRANSURETHRAL RESECTION OF THE PROSTATE: A COMPARISON USING TRANSRECTAL THREE-DIMENSIONAL ULTRASOUND VOLUMETRY**

L. Hefermehl, D. Strebelt, O. Gross, T. Sulser, H. Seifert, T. Hermanns—Switzerland

**Background:** Functional short-term outcome after Greenlight Laser vaporisation (LV) of the prostate has been shown to be similar to that of conventional transurethral resection of the prostate (TURP). However, long-term results after LV are still lacking. A sufficiently extensive deobstruction seems to be a prerequisite for a long-lasting improvement of voiding dysfunction. Unlike TURP the effectiveness of LV cannot be assessed by weighing the removed tissue. To investigate the efficiency of tissue ablation following 120 W Lithium triborate (LBO) LV and TURP transrectal three-dimensional (3D) ultrasound was performed.

**Methods:** Between March 2008 and May 2009 58 patients underwent routine LBO-LV (n = 34, 59%) and TURP (n = 24, 41%). 3D ultrasound was performed preoperatively, after catheter removal and after 6 weeks using a Pro Focus 2202 ultrasound scanner coupled to a magnetic probe-mover (BK Medical). BK-3D-view software was used for planimetric volumetry of the prostate. Statistical analysis was performed using Mann-Whitney test. All p-values <0.05 were considered significant.

**Results:** Median prostate volume was 47.8 ml (range 24.4–160.2 ml) in the LV group and 44.9 ml (23.2–128.5 ml) in the TURP group (p = 0.9). Median laser energy applied during LV was 201 kJ (39–636 kJ). Median weight and real volume of the resected tissue in the TURP group was 16.8 g and 17.6 ml, respectively. After catheter removal, median reduction of the prostate volume was significantly lower in the LV group (LV: 7.9 ml (0.7–39.1 ml), TURP: 15.8 ml (4.7–47.5 ml), p = 0.002). After 6 weeks, volume reduction was still higher in the TURP group but not statistically significant anymore (LV: 16 ml (2.1–51.3 ml), TURP: 18.4 ml (8.3–47.9 ml), p = 0.18). Median reduction of the prostate volume measured 6 weeks postoperatively was 32% in the LV group and 43% in the TURP group. The increase of volume reduction between catheter removal and 6 weeks measurement was statistically significant after LV (7.9 ml to 16 ml; p < 10<sup>-06</sup>) but not after TURP (15.8 to 18.4 ml; p = 0.06).

**Conclusion:** Our data demonstrate that 120 W LBO-LV is an efficient procedure for prostatic de-obstruction evidenced by a volume reduction not significantly different to that after TURP. The lower volume reduction measured after catheter removal suggests that prostatic swelling occurs early after LV. Relevant swelling of the prostate might be responsible for some of the typical complications (e.g. urinary retention, dysuria) of LV.

**MP23-11 TEMPRO BIPOLAR RADIO FREQUENCY THERMAL TREATMENT FOR CHRONIC PROSTATITIS: INITIAL RESULTS CH.BECK, A.BECK, DORTMUND, GERMANY**

C. Beck, A. Beck—Germany

**Background:** Chronic prostatitis/chronic pelvic pain syndrome (CP/CPPS) is a major health care burden we find in our daily urological practice. Several conservative types of treatments are

available but many patients are not relieved of their painful symptoms for long periods of time. Therefore, we started a trial using the Tempro system (Direx-Initia) to treat Chronic Prostatitis on our patients. We are here reporting our initial results with patients that have completed at least a 12 months follow up.

**Methods:** We used the Radiofrequency Thermal Treatment with a treatment protocol of 53.5 degrees Celsius for 60 minutes. All patients had symptoms at least 3 to 6 months, and have tried different drugs, such as Ciprofloxacin, Tamsulosine and NSAID, without success. The way to analyze quantitatively the potential improvement, was using the NIH Symptoms Score. We have treated 60 relatively young patients, ages between 28 to 57 years (average 42 years). The mean prostate size was 40 cc, out of which 33% were NIH Category II and 67% were Category IIIA. In fact we have also treated several patients Category IIIB, but since 90% of them failed, we stopped treating these type of patients.

**Results:** The results after 12 months are as follows: Patients whose score decreased 50% or more were 26 (43%) and the ones that did not decrease 50% or more were 34 (57%) The mean Total CPSI Score improved from 23.1 to 16.3 (30%). Mean pain domain score improved from 11.7 to 6.9 (41%) and Quality of life domain score from 6.7 to 4.7 (30%) Acute complications were: 4 UTI treated with Antibiotics, 2 “de novo” voiding symptoms with Conservative management and 3 Urinary retentions, treated with indwelling catheters for 3–5 days.

**Conclusion:** Considering that Chronic Prostatitis is a challenging illness, these initial results, with an overall success rate of 43% are very encouraging. Perineal and/or perianal pain, as well as orchalgia, are substantially improved in the majority of the patients. The Tempro treatments it is a simple, safe and effective procedure with minimal side effects. Longer follow up and a larger trial is required to explore in depth the potential of this treatment.

**MP23-12 EVALUATION OF EFFICACY AND SAFETY OF KTP PHOTOSELECTIVE VAPORIZATION OF THE PROSTATE FOR THE TREATMENT OF BENIGN PROSTATIC HYPERPLASIA: THE 3-YEAR RESULTS**

Y. Seungok, J. Tae Young, L. Jeongki, K. Yun Beom

**Background:** The aim of study was conducted to evaluate, with using the 3-year follow-up data, the clinical efficacy and safety of performing photoselective vaporization of the prostate (PVP) for the treatment of symptomatic benign prostatic hyperplasia (BPH).

**Methods:** We analyzed the clinical data of 48 men treated by PVP. The parameters were the changes from baseline of the International Prostate Symptom Score (IPSS), the quality of life (QoL) score, the maximum urinary flow rate (Qmax) and the postvoid residual volume (PVR). The patients were evaluated preoperatively and then at post-operative 1, 3, 6, 12 and 24 months. Their complications were also evaluated.

**Results:** The mean prostate volume was 35.6 ml. The mean operation time was 34.2 minutes and there was no significant blood loss or fluid absorption during or immediately after PVP. Significant improvements in the IPSS, the QoL score, the Qmax were noted as early as 1 month after PVP treatment. After 24-month follow-up, the mean IPSS decreased from 17.2 to 10.8 and the QoL score decreased from 4.7 to 2.2 while the mean Qmax changed from 9.4 to 13.8 ml/sec. The complications were retrograde ejaculation (29.2%), transient catheterization (6.3%), transient dysuria (4.2%), urethral stricture (2.1%).



**Conclusion:** Our experience suggests that GreenLight laser PVP is safe and effective for treating BPH.

### MP23-13 SIMULTANEOUS SURGICAL TREATMENT OF BENIGN PROSTATIC HYPERPLASIA AND INGUINAL HERNIA (REPORT OF 182 CASES)

C. Xiaoming, W. Dongwen, L. Chun

**Background:** To discuss the surgical method of benign prostatic hyperplasia (BPH) with inguinal hernia.

**Methods:** Since Jan 2004 to Dec 2008, 182 cases with benign prostatic hyperplasia (BPH) with inguinal hernia were treated with transurethral resection of the prostate (TURP), inguinal hernia were treated with herniorrhaphy at the same time.

**Results:** All patients had been followed up for six months to two years, in which recurrence of hernia and wound infection or other complication were not found. Qmax was more than 14 ml/s after operations, and IPSS were less than 9 scores for all patients. The mean time of hospitalization was 5.5 days.

**Conclusion:** TURP combined with herniorrhaphy at the same time is a simple and effective method, and it is recommendable.

### MP23-14 SAFETY AND EFFICACY OF GREENLIGHT LASER VAPORIZATION OF THE PROSTATE IN PATIENTS WITH ONGOING ORAL ANTICOAGULATION—LONG-TERM RESULTS AFTER MORE THAN 700 INTERVENTIONS

M. Rieken, G. Bonkat, S. Wyler, T. Gasser, A. Bachmann—Switzerland

**Background:** Photoselective vaporization of the prostate (PVP) is an established treatment modality for patients with symptomatic prostate enlargement. The specific physical properties of the laser lead to excellent haemostasis. We evaluated the safety and long-term outcome of PVP in patients with ongoing acetylsalicylic acid, clopidogrel and phenprocoumon.

**Methods:** Data from 715 patients with lower urinary tract symptoms due to prostate enlargement, who underwent PVP with the 80-W KTP or the 120-W HPS laser between September 2002 and January 2009 were analyzed. Perioperative parameter, functional outcome and complications were compared between patients with and without oral anticoagulation (oac).

**Results:** In 283 of 715 patients (39.5%) PVP was performed under oac. In this group, acetylsalicylic acid, clopidogrel and phenprocoumon were administered in 62.5%, 7.1% and 32.9% of the cases, respectively. Mean prostate volume ( $56.4 \pm 30.9$  vs.  $56.6 \pm 29.1$  ml), mean operation time ( $63.8 \pm 28.2$  vs.  $63.6 \pm 28.9$  min) and mean delivered energy per prostate ( $210 \pm 100$  kJ vs.  $200 \pm 103$  kJ) were comparable between the two groups. Intraoperative bleeding, primarily leading to impaired visibility, was observed more frequently in the oac group (4.6% vs. 0.4%,  $p < 0.05$ ). No intraoperative blood transfusions were necessary in both groups. Voiding symptoms and micturition parameters significantly improved in both groups compared to the preoperative values ( $p < 0.05$ ). No significant difference could be observed between both groups concerning functional outcome, complications and rate of reoperations.

**Conclusion:** Our data confirm the excellent haemostatic properties and the low complication rate of PVP in patients with ongoing oac. Thus, PVP could be recommended as primary surgical treatment option for patients with symptomatic prostate enlargement at high risk of bleeding.

### MP23-15 SELF-EXPANDING STENT INSERTION FOR RECURRENT BULBAR URETHRAL STRICTURES: UP TO 15-YEAR FOLLOW-UP

M. Sercelik, I. Bozkurt, K. Zengin, K. Oskay, O. Yigitbasi—Turkey

**Background:** Because it is difficult to treat and has a poor prognosis, urethral stricture is one of the most challenging problems in urology. Since 1990, we have treated recurrent bulbar urethral strictures of various causes using a permanent self-expanding metallic stent (Urolume™, American Medical Systems, MI, USA). The aim of the present study was to evaluate the safety and efficacy of the Urolume stent, based on a follow-up of up to 15-years. The Urolume stents used were 20–30 mm long and expandable up to 14 mm (43F).

**Methods:** Between October 1990 and October 1999, 65 Urolume stents were placed in 60 men (mean age 45.2 years) with an urethral stricture (mostly caused by trauma) present for a mean of 4.3 years, and who had previously undergone different unsuccessful treatments.

**Results:** Four stents were removed because of discomfort or pain. In three patients (5%) the stricture recurred in the urethra next to the stent and treated with a second stent. In six (10%) patients, hyperplastic tissue inside stent caused temporary stenosis and resolved by optical internal urethrotomy or transurethral resection. Mean (range) maximum urinary flow rate before stent implantation was 4.4 (2–7) mL/s (60 men). At 10 year after implantation it was 15.2 (9–21) mL/s (39 men). Most patients noticed some dribbling incontinence for the first 3 years but persisted only in half. Six patients mentioned urge and/or stress incontinence in last visit.

**Conclusion:** Urethral stent implantation provides a good treatment option for recurrent bulbar urethral stricture.

### MP23-16 ELECTROSPUN POLYMER SCAFFOLDS—NOT AN IDEAL MATERIAL FOR BLADDER AND URETHRAL SUBSTITUTION IN A RABBIT MODEL

D. Pick, S. Kolla, J. Gelman, M. Louie, E. Mcdougall, R. Clayman—CA

**Background:** Bladder augmentation and urethral reconstruction using donor tissues is associated with donor site morbidity and complications. We determine the feasibility of using electrospun poly caprolactone (PCL) scaffolds for urethral and bladder substitution in a rabbit model.

**Methods:** A total of eight rabbits underwent either bladder or urethral substitution with PCL grafts (bladder group-4; urethra group-4). Initial evaluation before graft placement included cystoscopy, and cystourethrogram to confirm normal urethral and bladder anatomy. PCL graft was used to replace a 5×5 cm excised segment of bladder in the bladder group and a 3 cm long segment of pendulous urethra in the urethra group. The animals were euthanized at 3- or 9-months after evaluation with cystoscopy and cystourethrogram. The bladder and urethral grafts were then harvested and underwent histopathological evaluation.

**Results:** In the bladder group, one rabbit died 8-days after the procedure due to bladder perforation. All the other rabbits in the bladder group (n = 3) were harvested at 3-months and showed graft contracture and stone formation and no epithelialization of the graft on histology. Of the four rabbits in the urethra group two were harvested at 3-months and two at 9-months. There was no stricture formation at the graft site in any of the urethral group rabbits.

There was calcification, false passage and focal scarring seen in one rabbit in both the 3- and 9-month urethral groups, two other rabbits had normal findings.

**Conclusion:** Electrospun PCL grafts for bladder and urethral replacement in the rabbit results in an unsatisfactory outcome due to graft contraction, stone formation and scarring.

### **MP23-17 CHANGES OF VOIDING SYMPTOMS DUE TO LONG-TERM URETERAL DOUBLE-J STENTING**

J. Lim, Y. Kim, E. Hwang, S. So, D. Han, E. Kim

**Background:** Many studies were reported that ureteral double-J stenting was associated with changes of voiding symptoms. But most studied effects of short-term ureteral stenting. We report the changes of voiding symptoms and quality of life in patients with long-term ureteral stenting.

**Methods:** A study with 20 patients (median age 57.7 years) received double-J ureteral stent between December 2002 and June 2008 was performed. All patients kept the stent for long period of over 12 months (mean period 21.1 months). They were consisted of cervical cancer (12), bladder cancer (2), endometrial cancer (1), colon cancer (1), rectal cancer (1) and retroperitoneal fibrosis (4). Questionnaires used International Prostatic Symptom Score and were obtained at preoperative, postoperative 6 and 12 months. Uroflowmetry was also performed.

**Results:** All patients reported one or more urinary symptoms. Storage symptoms showed more significant change than voiding symptoms ( $p=0.045$ ). In group of intrapelvic radiotherapy, storage symptoms were more significant change than in non-therapy group ( $p=0.037$ ). Bacteriuria was not associated with urinary symptoms ( $p=0.60$ ). Peak flow rate was not changed by ureteral stenting ( $p=0.34$ ). Quality of life was significantly aggravated after 6 months, but was not more aggravated after 12 months.

**Conclusion:** Long-term placement of ureteral stenting effected on storage symptom more than on voiding symptom. But urinary symptoms were stable as time goes by, so long-term placement of ureteral stenting was tolerable for patients.

### **MP23-18 SUPRACERVICAL ROBOTIC ASSISTED SACROCOLPOPEXY AND ROBOTIC HYSTERECTOMY AS TREATMENT FOR PELVIC ORGAN PROLAPSE: PRELIMINARY RESULTS**

A. Benson, B. Kramer, E. Nelson, B. Schwartz—United States

**Background:** Supracervical robotic assisted laparoscopic sacrocolpopexy (SRALS) is a new surgical treatment for pelvic organ prolapse that secures the cervical remnant to the sacral promontory. We present our initial experience with SRALS in the same setting as supracervical robotic assisted hysterectomy (SRAH).

**Methods:** Women with vaginal vault prolapse and significant apical defects as defined by a Baden-Walker score of 3 or greater that had not undergone hysterectomy were offered SRALS in combination with SRAH. Chart review was performed to analyze operative and peri-operative data. Outcomes were compared to patients who underwent RALS without any other procedure.

**Results:** From July 2005 through June 2009, 33 patients underwent RALS, including 12 patients who underwent SRALS. All SRALS were performed following SRAH in the same setting. Blood loss was negligible. Thirty-one patients were discharged on postoperative day one. One patient in the RALS group had an apical recurrence. There were no recurrences in the SRALS group. Operative time was longer for SRALS as these procedures were performed in conjunction with SRAH.

**Conclusion:** SRALS is effective to repair apical vaginal defects in patients with significant pelvic organ prolapse who have not undergone previous hysterectomy. The cervical buttress provides excellent support for the graft sutures and strength to the repair. Complications are few. Greater follow-up and numbers are needed to further establish the role of this procedure.

### **MP23-19 BUILDING A BETTER BLADDER: PRESSURE-FLOW URODYNAMIC STUDIES IN CADAVERIC ORTHOTOPIC NEOBLADDERS**

A. George, A. Herati, A. Srinivasan, L. Kavoussi, M. Vira, L. Richstone—USA

**Background:** Intracorporeal neobladder construction has been previously described but is limited due to excessive operative time and need for an advanced laparoscopic skillset. We investigated traditional and novel neobladder configurations, built with techniques to simplify intracorporeal construction. The aim of this study was to determine the pressure-flow characteristics of these neobladders to support their subsequent investigation in animal and human studies.

**Methods:** Four neobladder configurations were constructed, each created with 20 cm of human cadaveric small intestine. The standard hand sewn Studer pouch was compared with a W-pouch with stapled anastomoses, a U-pouch with stapled anastomoses, and a “doughnut” configuration, all made with afferent limbs. Pressure-flow studies were completed using the Aquarius TT UDS system (Laborie Medical Technologies, Toronto, Ontario) and each was filled to a pressure of 50 cm H<sub>2</sub>O. Neobladder capacity, change in pressure, and overall compliance were determined.

**Results:** The cystometric capacities of the stapled U-pouch, W-pouch, “doughnut” pouch, and Studer pouch were 167.3 ml, 177.5 ml, 114 ml, and 145.2 ml respectively. The first increase in intravesical pressure was at 90.3 ml, 103 ml, 50 ml, and 85 ml. The greatest compliance of 3.81 ml/cm H<sub>2</sub>O was demonstrated in the U-pouch, with the W-pouch revealing a compliance of 3.44 ml/cm H<sub>2</sub>O. The least compliant neobladder was the “doughnut” pouch (2.24 ml/cmH<sub>2</sub>O) followed by the standard Studer pouch (2.94 ml/cm H<sub>2</sub>O).

**Conclusion:** The construction of an orthotopic neobladder must not only be technically feasible but maintain adequate capacity and compliance for optimal functioning. Pressure-flow studies demonstrated equivalent results in alternate neobladder configurations. Additional data is needed to determine feasibility in vivo.

## MP24: ENDOUROLOGY—UPPER URINARY TRACT

### MP24-01 URETEROSCOPIC INSTRUMENT DAMAGE; EXPERIENCE AFTER 5,500 URETEROSCOPIES

P. Geavlete, D. Georgescu, R. Multescu, B. Geavlete—Romania

**Background:** Damage of the endoscopes or accessory instruments during ureteroscopy as well as other endourological interventions represents an intraoperative incident sometimes imposing the termination of the procedure or supplementary maneuvers for endoscopic removal. Our study aimed to review such incidents after a significant experience.

**Methods:** Between June 1994 and February 2009, 5102 patients underwent retrograde ureteroscopy (5534 ureteroscopic procedures). Retrograde flexible ureteroscopy was performed in 173 cases, while 5361 procedures were performed using the semirigid ureteroscope. The instrumental damage encountered during all these procedures was reviewed.

**Results:** Severe damages to the endoscopes requiring their replacement was encountered in 6 cases (0.1%); deterioration of the optical system (1 case) and complete breakage (1 case) of the semirigid 10F ureteroscopes, respectively deterioration of the outer sheath (1 case), perforation of the working channel (1 case) and breakage of the majority of fibers composing the optical system (2 cases) of the flexible ureteroscopes. Damage of the accessory instruments occurred in other 18 cases (0.3%): basket fracture (5 cases, 1 for impacted calculus release), grasping extractors' breakage (4 cases), balloon dilator tearing (1 case), guidewire fracture (4 cases) and lithotripsy probes breakage (4 cases). 10 of these cases necessitated active removal maneuvers of the foreign bodies (parts of accessory instruments).

**Conclusion:** Instrumental damage during ureteroscopic procedures is not a very frequent intraoperative incident in a center with high experience in this field. However, analysis of these cases is crucial in order to avoid future similar accidents.

### MP24-02 “CHIP ON A STICK” TECHNOLOGY—FIRST ROMANIAN EXPERIENCE

P. Geavlete, R. Multescu, V. Mirciulescu, B. Geavlete—Romania

**Background:** Introduction of digital endoscopes provided a new standard for image quality in endourology. Our study aimed to analyze the performances of digital ureteroscopy, performed for the first time in Romania.

**Methods:** We evaluated 47 digital semirigid ureteroscopies for ureteral lithiasis performed in our department: 31 as primary interventions (Group I) and 16 after previous JJ ureteral stenting (Group II). An Olympus Endoeye semirigid digital ureteroscope was used in all cases. Maneuverability and image quality were noted by the same urologist with 1 to 5 points. A similar analysis was performed during 47 ureteroscopies using a Storz conventional ureteroscope (Group III).

**Results:** The success rate was 83.9% (26/31 cases) in Group I, 100% (16/16 cases) in Group II and 97.9% (46/47 cases) in Group III. In 5 cases of Group II, the larger diameter of the digital ureteroscope (12F at the tip) impeded the calculus approach, imposing conventional semirigid ureteroscopy. In 1 case of Group III, pyelocaliceal migration of a large stone fragment imposed flexible ureteroscopic approach. The scores noted in the 3 groups were

4.48, 4.50 and 3.53 for visibility and 3.93, 4.38 and 4.57 for maneuverability.

**Conclusion:** The new digital ureteroscopes offer an image of superior quality by comparison to the conventional ones. Although the large caliber at the tip of the semirigid video-ureteroscopes may reduce their maneuverability and accessibility, the method proved to be safe and efficient.

### MP24-03 DRILLING THROUGH THE IMPACTION: POSSIBLE USE OF AN ATHERECTOMY DRILLING DEVICE FOR UROLITHIASIS

D. Lifshitz, A. Razmaria, S. Shikanov, A. Shalhav, K. Zorn

**Background:** The Rotablator<sup>®</sup> (Boston Scientific) is an angioplasty device which is passed over a wire. It uses a high speed rotational “burr” (2 mm in diameter) that is coated with microscopic diamond particles and cooled by saline. It rotates at high speed (approximately 200,000 rpm) breaking up blockage into minute (smaller than red blood cells) fragments. We investigated, in vitro, the possible use of the Rotablator<sup>®</sup> for urinary stone disease.

**Methods:** Human stones of different sizes and composition were used for the experiment. Stone impaction in vitro was modeled by wedging the stones into the proximal part of a silicon Foley catheter. Likewise, an ex-vivo study was performed on stones placed into a freshly harvested swine ureter using a nitinol basket. Data regarding the drill time, remaining stone size, and ureteral damage was collected.

**Results:** Overall 15 stones were treated (10 in vitro and 5 ex-vivo). The device drilled through all the stones allowing complete passage of the burr. The pre-treatment mean stone size for the silicon and ureteral testing was 65 mm<sup>2</sup> and 34 mm<sup>2</sup>, respectively. The post-treatment size was 54 mm<sup>2</sup> and 24 mm<sup>2</sup>, respectively. No change, but the drilled hole, was noted in 4 stones. Average treatment time was 100 seconds. No visual macroscopic ureteral damage was observed.

**Conclusion:** In vitro the Rotablator<sup>®</sup> is capable of drilling through stones with minimal damage. However, stone fragmentation is minimal. Further studies are required to investigate the use of the Rotablator<sup>®</sup> for a fluoroscopic-guided, over a wire, stone lithotripsy.

### MP24-04 CREATION OF A FLUID CHAMBER WITH THE ACCORDION DEVICE INCREASES FRAGMENTATION DURING URETERAL ESWL: IN VITRO AND EX VIVO RESULTS

J. Ditrolio, M.D., P. Ciccone, M.D., M. Lasalle, M.D., R. Bhalla, M.D.—USA

**Background:** A fluid-filled chamber is postulated to increase cavitation during ESWL, which increases stone fragmentation. The objective of this study was to measure fragmentation efficacy during use of a stone device that forms such a chamber.

**Methods:** In vitro model: stones (UltraCal-30) were advanced into an artificial ureter and placed in the focusing cup of a Modulith SLX (Storz Medical) filled with deionized water. A single ESWL session (energy level 9 for 1000 shocks) was applied with either a 10 mm Accordion device (PercSys) distal to the stone or no device

present in five replications. Ex vivo model: stones were advanced within an explanted porcine ureter and placed upon the treatment head of a Compact Delta (Dornier), sandwiched between pouches of saline. A clinical cycle of ESWL (total of 2400 shocks) was replicated three times each with either a 10 mm Accordion device immediately distal to the stone or no device present. Fragmentation coefficient (FC) was determined as  $FC = 100 (\text{Weight initial} - \text{Weight following}) / \text{Weight initial}$ . Significance was determined using Student's t-Test.

**Results:** Mean FC following a single application was 63 with an Accordion device distal to the stone versus 47 without the device ( $p = 0.04$ ) in the in vitro model. The sessions in excised ureters resulted in an FC of 33 with the device present versus only 9 without the device ( $p = 0.008$ ).

**Conclusion:** Tenting tissue away from the stone surface by the Accordion device created a fluid interface in both simulated ureters and excised porcine ureters and significantly increased the fragmentation coefficient of ESWL.

#### **MP24-05 COMPARATIVE EVALUATION OF EFFICACY OF USE TAMULOCIN AND/OR TAMULOCIN PLUS DEXAMETAZON FOR EXPLUSIVE THERAPY OF DISTAL URETERAL CALCULI AFTER EXTRA CORPORAL SHOCK WAVE LITHOTRIPSY (ESWL)**

R. Mahdavi Zafarghandi, M. Mahdavi Zafarghandi—Iran

**Background:** To evaluate and compare the clinical efficacy of the tamsulocin and tamsulocin plus dexametazone for explusive therapy is patients with distal ureteral stone after extra corpora shock wave lithotripsy (steinstrasse).

**Methods:** A total 45 patients between 20 to 68 years old who had distal ureter steinstrasse were included in this study. Patients randomized in 2 groups : Group I patients (N = 23) received tamsulocin (0.4 mg/day) and group II comprised 35 patients were treated with tamsulosin (0.4 mg/day) plus dexametazone (4 mg/day). These medication plus hydration and analgesic recommended for all cases for up one months. KUB and ultrasonography of urinary tract performed every week. The primary end point was the expulsion rate. Expulsion time, The number of pain episodes, use of analgesic, need for admission, analgesic dosage, side effect of drugs were secondary end point.

**Results:** The expulsion rate was significantly higher in group 2 (85%) Than in group I (62%,  $p = 0.01$ ) and stone passage need shorter time in group 2 in compare with group I. There were not significant difference between 2 groups in the number of pain episodes, number of admission, dosage of analgesic and drugs side effect.

**Conclusion:** A conservative approach should be considered as an option in the management of distal-ureteral stone (steinstrasse) The use of dexametazon plus tamsulocin seemed to induce more rapid stone expulsion.

#### **MP24-06 CAN THE ACCORDION STONE DEVICE ASSIST IN UPPER URETERAL ESWL? PILOT CLINICAL EXPERIENCE WITH A NOVEL USE OF THE DEVICE?**

R. David

**Background:** Extracorporeal shock wave lithotripsy (ESWL) of proximal ureteral stones has limited success rates. Our objective was to determine whether an Accordion stone device might facilitate ESWL by tenting urothelium adjacent to the stone and creating an expansion chamber to increase fragmentation.

**Methods:** With IRB approval and patient consent, five patients were evaluated for stone fragmentation during ESWL with a 10 mm Accordion stone device (PercSys) positioned either bracketing (2 patients) or immediately distal to the stone (3 patients). Stones ranged in size from 5 to 8 mm. After ESWL treatment (2000 shocks), the extent of fragmentation noted with fluoroscopic imaging was ranked as either low (minimal fragmentation), moderate (>60% of fragments >2 mm), or extensive (<40% fragments >2 mm).

**Results:** In all five patients, the radiopaque Accordion device assisted targeting the stones. It held contrast above the stone throughout the procedure, and swept fragments from the ureter afterwards. Bracketing the stone with the film occlusion resulted in one moderate and one extensive stone fragmentation; positioning the occlusion distal to the stone resulted in one moderate and two extensive fragmentation rankings. There were no patient complications nor damage to the devices employed. All 5 patients cleared their stones.

**Conclusion:** The Accordion device appears to have assisted stone fragmentation whether bracketing or just distal to the stone. The Accordion provided guidance in localizing stones, did not interfere with the application of shock waves, and reduced residual stone volume by sweeping fragments out of the ureter after effective fragmentation in 5 of 5 patients. These results warrant further clinical investigation.

#### **MP24-07 MULTI-INSTITUTIONAL ONE YEAR FOLLOW UP EXPERIENCE WITH THE RESONANCE™ METALLIC STENT FOR THE MANAGEMENT OF EXTRINSIC URETERAL OBSTRUCTION**

C. Allam, D. Soderdahl, R. Marcovich, J. Hernandez—USA

**Background:** Management of extrinsic ureteral compression presents therapeutic challenges. Because of the inherent properties of plastic stents a significant failure rate is observed for this indication. The Resonance™ metallic stent (Cook Urological, IN, USA) purports to increase radial strength, reduce encrustation, and provide long term relief from extrinsic obstruction. We reviewed our experience with use of this metallic ureteral stent in treatment of extrinsic ureteral obstruction.

**Methods:** An IRB approved retrospective chart review was performed at 2 centers. Patients underwent Resonance™ stent placement for treatment of extrinsic ureteral compression with mean follow up of 12 months. Data collected included indication, changes in renal function, tolerance, durability, and complications.

**Results:** A total of 20 stents were inserted in a retrograde fashion in 15 patients from June 2007 to August 2008. Extrinsic obstruction was due to malignancy in all patients. The Resonance™ provided functional obstruction relief in 8 patients (10 renal units) for at least 10 months. Two additional patients (2 stents) died with functional stents. Three patients (4 stents) developed progressive ureteral obstruction requiring additional procedures. Renal function was preserved or improved in all but three patients. Three patients had stents removed for pain, infection or migration.

**Conclusion:** Our experience with this metallic stent supports its use in management of long-term extrinsic ureteral compression in the majority of patients. These stents were generally well-tolerated and renal function was preserved. Further study is indicated to determine the optimal indications for this stent and to document continued long-term efficacy.

### MP24-08 A MONTH WITH A DOUBLE-J STENT: THE SHORT TERM MORBIDITY AND OUTCOMES OF URETERIC STENTING

T. Haresh

**Background:** To review the short-term morbidity and complications associated with DJ stents and their effect on hydronephrosis. **Methods:** In a prospective study, 100 patients (73 males and 27 females) (100 renal units) who underwent DJ stenting were evaluated. Transplant recipients, patients less than 14 years of age, those on regular stent change or having bilateral stents or endopyelotomy stents, and those having no documented sterile urine pre-operatively were excluded. 93 patients underwent stenting at the time of another procedure (PCNL, URS, pyeloplasty) while 7 underwent stenting only. All patients received prophylactic antibiotics at the time of the procedure (cephalosporins only: 22, cephalosporins and aminoglycosides: 75, fluoroquinolones: 3). Other than patients requiring early removal, all were given suppressive dose of fluoroquinolones till stent removal. Stents were removed after an average of 29 days (minimum 5 days, maximum 37 days). Before stent removal symptoms were assessed with a visual analogue score, hydronephrosis was reassessed by ultrasonography and plain abdominal X-ray confirmed stent position. All had a urine culture before stent removal.

**Results:** Twenty-three patients had fever after stent insertion (20 responded to antibiotic treatment, 3 required stent removal), 22 had flank pain on voiding (17 transiently, 4 persistent at one month, 1 required stent removal at 8 days), 19 had frequency and/or urgency (14 transiently, 5 persistent at one month), 2 had distal migration of the stent into the upper ureter. Of the 72 patients who had hydronephrosis pre-operatively, 68 (94%) showed a decrease and 4 (6%) no change in the degree of hydronephrosis. Thirty-two patients had at least one symptom.

**Conclusion:** Although ureteric stents have proved their utility in relieving ureteric obstruction, they have a significant short-term morbidity and the indications for stenting should be carefully considered in every patient.

### MP24-09 THE EFFECT OF PROTAMINE SULFATE ON PORCINE URETERAL PERMEABILITY

D. Pick, S. Shelkovich, M. Louie, A. Kaplan, E. McDougall, R. Clayman—CA

**Background:** Intraluminal administration of pharmacological agents to relax the ureter before endourological procedures could ease access and decrease procedural morbidity. The urothelium, however, is a barrier to the passage of medications into the ureteral smooth muscle. Herein we quantify the effect of protamine to alter the permeability of this barrier using an ex-vivo ureteral apparatus to control the intraluminal and extraluminal ureteral environments, and measure peristalsis before and after drug administration.

**Methods:** Freshly harvested 4 cm porcine tubular ureteral segments were placed in an organ bath with gassed Krebs solution. Both ureteral ends were cannulated. An in-series pressure transducer was placed at the inflow end. Outflow drained by gravity. Intraluminal flow (1 ml/min) was maintained by a constant pressure, gravity fed reservoir. Agents were added to the extraluminal organ bath or the intraluminal elevated reservoir fluids. Phenylephrine 10  $\mu$ M was added to the external bath to induce peristalsis. After this, nifedipine was added to the intraluminal reservoir or to the external bath. The concentration of nifedipine required to block

peristalsis was measured. Protamine (10 mg/ml, 20 min) was then used to denude the urothelium and the study repeated.

**Results:** Nifedipine was observed to block ureteral peristalsis, and effective intraluminal concentrations were 10 times higher ( $p < 0.0001$ ) than extraluminal concentrations. Protamine significantly ( $p < 0.0001$ ) reduced the intraluminal nifedipine needed by 10 fold, but given alone did not block ureteral peristalsis.

**Conclusion:** Protamine appears to increase urothelial permeability in the ureter. Pretreatment of the intraluminal pig ureter with protamine significantly decreased the concentration of nifedipine needed to block peristalsis. Protamine appears to increase urothelial permeability; clinical applications of this observation suggest further study.

### MP24-10 ECIRS (ENDOSCOPIC COMBINED INTRA-RENAL SURGERY) FOR UROLITHIASIS IN GALDAKAO-MODIFIED SUPINE VALDIVIA POSITION : OUR EXPERIENCE

C. Scoffone, P. Massimiliano, C. Cracco, M. Cossu, S. Grande, R. Scarpa—Italy

**Background:** PCNL, the gold standard for the management of large or otherwise complex urolithiasis, was initially performed with the patient in the supine-oblique position, but later on the prone position became the conventional one, in spite of its cardiocirculatory, respiratory and neurological drawbacks. Among all the various safe and effective changes in patient positioning for PCNL proposed over the years, the Galdakao-modified supine Valdivia position seems the most profitable one under many respects. Here we describe our experience of ECIRS in Galdakao-modified supine Valdivia position.

**Methods:** From April 2004 to October 2008 a total of 172 consecutive ECIRS in Galdakao-modified supine Valdivia position for large or complex urolithiasis were performed. All the relative data were analysed retrospectively. Technical details about percutaneous access, endoscopic instruments and accessories employed, postoperative renal and ureteral drainage are described.

**Results:** Of the 172 patients (119 males, 53 females), mean age was 52.9 yrs + 13.8 S.D., classified according to their BMI and ASA risk, 60.6% were symptomatic for renal colics, hematuria, recurrent urinary tract infections with fever. Mean stone size + S.D was 42.8 + 38.4 mm. As to stone location, 31.4% were caliceal, 29.1% pelvic, 39.5% multiple/staghorn; 4.3% also ureteral. Mean operative time was 69,6 + 53.3 minutes S.D. Retrograde ureteroscopy was essential for completeness of the procedure in 36.5% of cases. Stone-free rate after the first treatment was 81.5%, 87.9% after a second early treatment during the same hospital stay (mean 4.7 days + 2 S.D.). There were no splanchnic injuries; 8 postoperative hematurias, 6 blood transfusions, 2 parietal hematoma, 3 artero-venous fistulas which underwent selective embolization, 46 postoperative hypertermias and one hypotermias.

**Conclusion:** The data presented here suggest that ECIRS for large and/or complex urolithiasis performed in the Galdakao-modified supine Valdivia position maintains its feature of safe and effective procedure, in addition to a great versatility in terms of combined antero-retrograde approach, a high rate of one-step resolution of the calculosis, and in absence of anaesthesiological disadvantages or additional complications.

### MP24-11 IRRIGATION FLOW DIFFERENCES IN FLEXIBLE URETEROSCOPES OF THE NEWEST GENERATION

S. Kruck, J. Bedke, D. Schilling, K. Sievert, A. Stenzl, U. Nagele

**Background:** The development of new-generation flexible ureteroscopes has improved diagnostic and therapeutic endourological procedures. Despite technical improvement irrigation flow and quality of vision is often unsatisfactory. This study describes inter-manufactural differences in the latest available flexible ureteroscopes in terms of irrigation flow in correlation to different deflection angles and the use of 1.9 Fr. stone baskets.

**Methods:** Irrigation flow measurements in four new-generation flexible ureterorenoscopes (3.6 Fr. working channels) in 0°, 90° and 180° deflection with an empty working channel and with inserted 1.9 Fr. stone baskets.

**Results:** Mean flow rates with empty instruments (StDev) counted 50 ml/min (0.8), 50 (1.0), 48 (1.7) and 44 (0.7) for ACMI, Wolf, Storz and Olympus, respectively. Stone baskets significantly reduced irrigation flows in all tested ureteroscopes ( $p < 0.05$ ). In channels with inserted baskets, highest flow rates were measured for ACMI and Wolf with 12 ml/min (0.7) each, compared to Storz (10 ml/min, 0.5) and Olympus (9 ml/min, 0.7). Lowest reduction of flow rate was detected in the ACMI and the Wolf ureteroscope (76.0%, 38 ml/min each). For Storz and Olympus the flow decreased for 79.2% (38 ml/min) and 79.5% (35 ml/min), respectively. Measurements after flexion showed no significant differences between the ureteroscopes.

**Conclusion:** Tested flexible ureteroscopes offer new product developments, including excellent deflection capacities. We showed significant inter-manufactural differences in terms of irrigation flow resulting in significant alterations in endoscopic view.

### MP24-12 URETERIC STENTS AND THE ELECTRONIC REGISTRY: DO THEY WORK?

A. Patel, R. Zakri, N. Shrotri

**Background:** Indications for ureteric stent placement have expanded significantly becoming standard indispensable urologic tools. This mandates not only awareness of potential complications but also stringent methods ensuring safe and timely completion of stent insertion cycles.

**Methods:** We retrospectively audited our electronic stent registry. Between January 2007–June 2009, 416 patients were manually recorded onto the register and flagged automatically at end of stent life. Patients classified: Group I <6 month stent and Group II >6 month. 289 completed stent cycles analysed in conjunction with patient records and theatre logbooks. Data collection and entry methods scrutinized.

**Results:** 57.5% male: 42.5% female. Commonest stenting indication: Group I ( $n = 229$ ) obstructing stone (113/229) and Group II ( $n = 44$ ) malignancy (15/44). Mean duration stent-in-situ 225 days. 27 patients Group I, (average 62.3 days longer, median 34), and 7 patients Group II, (average 23.6 days longer, median 23), with stents longer than designated duration. 100 recordings of 'unspecified' diagnosis indicating poor communication. Further analysis of June 2008 to November 2008 revealed 162 stents inserted in theatre. 92.6% (150) episodes were captured by the stent registry. Of missed episodes, 4 patients died, 3 stents inserted elsewhere and 4 missed by register without cause.

**Conclusion:** Our electronic stent registry was noted to be effective in stent cycle implementation, success and safety. Automatic stent removal reminder avoids forgotten stents but dependent on frequency of database review and cumbersome operator data entry. Removal date scheduling before discharge and barcode acquisition

possible methods of streamlining stent registration in our hospital. Online registry recommended by BAUS is also being explored.

### MP24-13 A VALIDATED QUESTIONNAIRE STUDY COMPARING STENT-RELATED SYMPTOMS BETWEEN CONVENTIONAL JJ STENTS AND A NOVEL THERMO-EXPANDABLE SEGMENTAL URETERIC METAL STENT

D. Patel, Z. Maan, T. El-husseiny, A. Papatsoris, J. Masood, N. Buchholz—UK

**Background:** JJ stents have revolutionized the minimally invasive management of malignant and benign ureteric strictures, especially in high risk patients. However, JJ stents are associated with significant morbidity and reduced quality of life. More recently, a permanent thermo-expandable nickel-titanium alloy segmental ureteric stent (Memokath™ PNN Medical, Denmark) was introduced. This may improve patients' quality of life (QOL) by reducing morbidity. We compare symptoms and quality of life in patients with ureteric strictures treated with either JJ or Memokath™ stents.

**Methods:** Over a one year period, validated ureteral stent symptom questionnaires (USSQ) were sent to 70 consecutive patients 4 weeks after insertion of JJ or Memokath™ stents. During this period, a sub-group of patients underwent insertion of both stents and hence completed two questionnaires. The USSQ is a self-administered multidimensional measure designed to evaluate stent-related morbidity in 6 sections: urinary symptoms, body pain, general health, work performance, sexual matters, and additional problems. Statistical analysis was used to compare differences in these outcome measures between the two stents.

**Results:** The response rate was 58.5%. Memokath stents were significantly better for the domains of stent related pain, urinary symptoms index and general health compared with JJ stents and also significantly outperformed the JJ stent group in terms of light and heavy activity. Patients opted clearly in favour of Memokath stents for future stent insertion.

**Conclusion:** Patients with Memokath stents have an improved QOL because stent related morbidity is significantly lower than conventional JJ stents. Also these stents don't require frequent exchanges and are more cost-effective.

### MP24-14 PARALLEL METALLIC AND POLYMERIC URETERAL STENTING FOR URETEROENTERIC STRICTURE

M. Wuerstle, J. Gleason, G. Chien—USA

**Background:** The metallic double-pigtail ureteral stent is utilized in ureteral obstruction for up to 12 months. Placement/exchange methods have unique technical considerations due to its coaxial system. The stent without patent lumen ends is pushed through the sheath and subsequent exchanges require parallel guidewire placement or complete removal and reinsertion. Although reports are mixed for benign ureteral obstruction, metallic stents are feasible for patients with failed polymeric stents or intolerance of percutaneous nephrostomy tubes. Specifically with ureteroenteric stricture, stent placement/exchange can be complicated by difficult retrograde access. We subsequently devised a technique using parallel metallic and polymeric stents for ureteroenteric stricture to permit solely retrograde approach with parallel guidewire insertion for future exchange.

**Methods:** Cystoscope is introduced through the reconstructed urinary diversion. Any prior stent is extracted and two guidewires are positioned into the collecting system. A metallic double-pigtail

ureteral stent (6 Fr) is placed using the coaxial system passed over one guidewire. Final stent positioning is accomplished using hollow sheath and stent pusher. The second guidewire serves to place a parallel polymeric ureteral stent (6 Fr), then both distal coils are visualized cystoscopically and proximal coils confirmed fluoroscopically.

**Results:** We have performed this method on three patients from November 2008 to April 2009. During future metallic stent exchange, the distal end of the polymeric stent is grasped cystoscopically and guidewire is threaded through the lumen into the collecting system. This was accomplished in all three patients.

**Conclusion:** Parallel metallic and polymeric ureteral stenting permits retrograde access, facilitates metallic stent removal (without patent lumen ends) and allows metallic stent replacement without requiring new intubation of ureteral orifice.

### MP24-15 THE EFFECT OF TAMBUSOLIN ON EXPULSION OF URETERAL STONES AFTER EXTRACORPOREAL SHOCK WAVE LITHOTRIPSY

Y. Seungok, L. Jeongki, J. Tae young, K. Yun beom

**Background:** We prospectively evaluated the efficacy of tamsulosin on expulsion of ureteral stones after extracorporeal shock wave lithotripsy (ESWL).

**Methods:** Fifty-five patients (30 with upper ureteral stones and 25 with lower ureteral stones) treated with ESWL for stones <10 mm were randomly divided into two groups. Tamsulosin (0.2 mg orally once daily) was administered to group 1; group 2 received no medications. All patients were evaluated with respect to the number of episodes of ureteral colic, the expulsion rates of stones after ESWL, and the mean number of sessions of ESWL until complete expulsion of stones.

**Results:** The complete expulsion rates of upper and lower ureteral stones did not differ significantly between groups 1 and 2 during each session of ESWL; however, the mean session of ESWL was lower in group 1 than in group 2. For upper ureteral stones, 1.7 sessions were necessary per patient in group 1, while 2.4 sessions were required for the patients in group 2. For lower ureteral stones, 2.1 sessions were necessary per patient in group 1, while 2.8 sessions were required for the patients in group 2. There were significant decreases in the number of episodes of pain in group 1 with lower ureteral stones. There were no side effects associated with tamsulosin.

**Conclusion:** The use of tamsulosin in the treatment of upper and lower ureteral stones after ESWL can decrease the mean number of sessions of ESWL and the number of episodes of pain, but cannot improve the expulsion rate. Further research regarding the cost-effectiveness of tamsulosin after ESWL is needed.

### MP24-16 URETERAL METAL STENTS: TEN YEARS EXPERIENCE FOR THE TREATMENT OF MALIGNANT URETERAL OBSTRUCTION

P. Kallidonis, K. Katsanos, D. Karnabatidis, I. Kyriazis, A. Al aown, E. Liatsikos

**Background:** Ureteral patency in malignant ureteral obstruction represents a therapeutic challenge. We report our long-term experience in the palliative treatment of extrinsic malignant ureteral obstruction with percutaneous placement of metal mesh stents (MSs).

**Methods:** From January 1996 to December 2005, 90 patients (mean age 59 years, range 35–80) with ureteral obstruction due to extrinsic ureteral compression and/or encasement by primary or metastatic

tumors or retroperitoneal lymphadenopathy underwent implantation of self-expandable MSs. In total, 119 ureters were managed. Follow up schedule included urinalyses, blood biochemistry, transabdominal ultrasonography or intravenous urography.

**Results:** Technical success of percutaneous antegrade insertion of ureteral self MSs was 100%. Renal biochemistry normalized and hydronephrosis gradually resolved 1–2 weeks after stent insertion. Median follow-up period was 15 months (range, 8–38 months). Hyperplastic reaction and/or encrustation or tumor in-growth occurred in 45 stents. Secondary interventions such as repeat balloon dilation and co-axial stenting were performed to improve patency. Migration was observed in 13 metal stents. The primary and secondary patency rates during the follow-up period were 51.2% and 62.1%, respectively. Insertion of double-pigtail or external-internal stent was performed in 45 cases that the secondary interventions did not assure patency.

**Conclusion:** Internal drainage of extrinsic malignant ureteral obstructions with MSs proved to provide long-term decompression of the upper urinary tract in limited cases. Certain problems limit the application MSs in the ureter. Further studies are warranted to identify independent predictors of ureteral patency following application of metal stents for malignant obstruction.

### MP24-17 EVALUATION OF THE EFFECT OF ENDEAVOR DRUG ELUTING STENT IN THE PORCINE URETER

P. Kallidonis, I. Kyriazis, A. Al aown, S. Spiliopoulos, C. Kaloogeropoulou, E. Liatsikos

**Background:** Drug eluting stents (DES) proved to minimize neointimal hyperplasia in coronary vessels. Hyperplastic reaction protruding through the stent struts is the most common unwelcome event related to the use of metal mesh stents in the ureter for the management of challenging obstructions. We evaluated the effect of Endeavor Resolute (Medtronic Inc, USA) DES in porcine ureter.

**Methods:** A DES and a bare MS were inserted in the each ureter of eight pigs. The insertion was performed by retrograde approach. Preoperative ultrasonography (US) and intraoperative intravenous pyelography (IVU) were performed. Immediately after the intervention CT took place. The follow-up included US every 3 days, CT every week for the following 4 weeks. Radionuclide scan was performed for the evaluation of the function status of the stented renal units. Histopathologic examination of the stented ureters embedded in methymethacrylate was performed.

**Results:** Hyperplastic reaction was present in both stent types. In the cases of bare MSs 5 ureters were completely obstructed while ureters stented with DES presented to have hyperplastic tissue which did not result in obstruction. The function of the 5 renal units with obstructed stented ureter was compromised. Although, hyperplastic reaction was present in all cases, pathology examination revealed significant more hyperplastic reaction and inflammation in the case of bare MSs.

**Conclusion:** DESs in the pig ureter were associated with reduced hyperplastic reaction which represents the most common complication of the MS use in the ureter. The clinical use of DESs seems to be an interesting option.

### MP24-18 THE CAPABILITY OF ANTIRETROPULSION DEVICES TO REDIRECT FLUID IRRIGATION DURING URETEROSCOPY

B. Chew, B. Poh, L. Jonat, D. Lange—Canada

**Background:** Backstop devices are utilized to hold a stone in place and prevent retropulsion/migration during intracorporeal lithotripsy. We sought to evaluate how these devices affect the flow of irrigation to the kidney and bladder during ureteroscopy.

**Methods:** A ureter was simulated by a plastic tube (7 mm inner diameter) with one end sealed to simulate the ureteral orifice. The Accordion (PercSys), Stone Cone (Boston Scientific), or NTrap (Cook) devices were deployed in the tube, and fluid was infused through a flexible ureteroscope (ACMI DUR-8) held within 10 mm of the devices. Fluid was delivered at 150 and 300 mmHg for one minute and the volumes of fluid that exited from the proximal (kidney) and distal (bladder) ends of the plastic tube were measured and repeated 5 times.

**Results:** The Accordion significantly reduced the amount of irrigation that reached the kidney by 51.8% ( $P < 0.001$ ) and increased backflow to the bladder compared to the other devices ( $P < 0.001$ ). The Accordion allowed only 13.3% of the irrigation to reach the kidney with the other 86.7% rebounding back into the bladder and potentially taking small fragments with it at 300 mmHg of pressure irrigation. Both NTrap and StoneCone transferred all irrigation to the kidney at both 150 and 300 mmHg with no backflow of irrigation to the bladder.

**Conclusion:** The Accordion reduces the amount of irrigation that reaches the kidney during ureteroscopy and significantly increases the backflow or irrigation that potentially increases the amount of fragments washed into the bladder compared to NTrap and StoneCone.

#### MP24-19 INTRAOPERATIVE STENTING OF THE UPPER URINARY TRACT IS NOT NECESSARY AFTER RESECTION OF THE URETERIC ORIFICE DURING TUR-B

A. Neisius, R. Gillitzer, S. Keber, C. Hampel, J. Thüroff—Germany

**Background:** Insertion of a ureteric DJ-stent is common practice when transurethral resection of a bladder tumor (TUR-B) included resection of the ureteric orifice. We retrospectively analysed our TUR-B database and identified cases, in whom the ureteric orifice was resected. Of these, we compared cases with and without placement of a ureteric stent concerning postoperative complications, stricture formation and tumor development in the upper urinary tract.

**Methods:** From 3/1998 until 5/2008 196 cases (149 males, 47 females) had resection of the ureteric orifice during TUR-B of superficial bladder cancer. Intraoperative insertion of a ureteric stent (group “stent”) was compared without stenting (group “no stent”). Mean follow-up was 41.4 months (3–122 mo.).

**Results:** 150/196 cases had a bladder tumor directly at the ureteric orifice, 46 (23.5%) had a tumor growing out of the ureteric orifice. In 74/196 (37.7%) a DJ-stent was inserted intraoperatively. 15/122 (12.3%) renal units without a DJ-stent revealed hydronephrosis on postoperative renal ultrasound, 13/122 (10.6%) required drainage.

#### MP24: ENDOUROLOGY—UPPER URINARY TRACT

Strictures developed in 14/74 (18.9%) with and in 4/122 (3.3%) without DJ-stent ( $p < 0.001$ ). Upper urinary tract tumors developed subsequently in 5/74 (6.8%) with and in 6/122 (4.9%) without a DJ-stent ( $p = 0.75$ ).

**Conclusion:** Resection of the ureteric orifice during TUR-B for superficial bladder cancer does not necessarily require intraoperative insertion of a DJ-stent. We found a strong association between insertion of a DJ-stent and an increased rate of ureteric orifice strictures, although stent insertion might be biased by the surgeon toward more severe cases. DJ-stents do not seem to be associated with an increased risk of de-novo tumor development in the upper urinary tract.

#### MP24-20 ABILITY OF ANTIRETROPULSION DEVICES TO PREVENT INTRARENAL PRESSURE RISE IN EX VIVO PORCINE MODEL

M. Rothberg, L. Suh, M. Gupta—USA

**Background:** Pressurized saline irrigation during ureteroscopy for ureteral calculi risks significant intrarenal pressure increase, leading to post-operative pain, sepsis, and renal injury due to pyelovenous and pyelolymphatic backflow. We sought to determine whether two commonly used antiretropulsion devices designed to prevent stone migration during ureteroscopic lithotripsy procedures have a beneficial, deleterious, or inconsequential effect on intrarenal pressures during ureteroscopic lithotripsy.

**Methods:** A 16-gauge angiocatheter was placed into the collecting system of an ex-vivo intact porcine kidney, ureter, and bladder model for real-time continuous pressure monitoring. A flexible ureteroscope was then positioned within the proximal, mid, and distal ureter via the ureteral orifice. Multiple trials were performed with saline irrigation at gravity (84 cm H<sub>2</sub>O) and steady-state pressures of 150 and 300 mmHg. Upon deployment of each device 1 cm from the ureteroscope tip, percent pressure changes were measured.

**Results:** The mean percent reduction in intrarenal pressure from baseline and 95% confidence intervals are presented in tabular format (shaded regions are statistically significant):

Proximal	Mid	Distal	Gravity	150 mmHg	300 mmHg
10%	42%	33%	48%	51%	56%
27%	34%	3%	95%	CI 8.6–11.4	41.3–42.7
25.2–40.8	39.6–56.4	50.2–51.8	54.7–57.3	25.6–28.4	34
0.2–5.8	Film-based 68%	33%	48%	65%	62%
68%	61%	54%	67%	95%	CI 66.6–69.4
33	47.1–49.9	65	59.6–64.4	66.1–69.9	60.3–61.7
52.1–55.9	65.6–68.4				

**Conclusion:** The spiral device failed to prevent intrarenal pressure increases with pressurized saline irrigation, while the film-based device provided superior ability to diminish intrarenal pressures at all three irrigation pressures. In some instances the film-based device completely occluded the ureter, preventing any pressure transmission from irrigation fluid into the collecting system.



# O1: TRAINING AND LEARNING CURVE

## O1-01 TRAINING OF MODIFIED TUR BEFORE ROBOTIC HIGH INTENSITY FOCUSED ULTRASOUND (RHIFU): COMPARISON OF RESULTS AFTER KNOWLEDGE TRANSFER

V. Solovov, S. Thueroff, A. Neumayr, S. Dvoynikov, C. Chaussy, M. Vozdvishensky—Russia

**Background:** Prostate cancer (PCa) therapy by rHIFU (Ablatherm® EDAP-TMS, Lyon, France) is a technology used since '96, meanwhile spread over 230 urological departments worldwide. Standardized teaching as application procedures ensure fast, safe and high quality rHIFU procedures with short, low risk learning curve. We evaluated effects of structured TUR & rHIFU training.

**Methods:** Site(D), as high volume rHIFU training center (>200 tx/y) trained new site(RUS) in 3 sessions in 2008 in use of rHIFU, as well as for “pre-rHIFU-TUR”. First session was for rHIFU training, 2nd & 3rd focused on TUR. Comparison of significant criteria achieved since then. Site(D), based on 13 years experience, compared itself with the new center(RUS), performing rHIFU since 1 year. Prospective data collection.

**Results:** Comparison of inclusion criteria, oncological results and side effect rate show—as major difference—2/3rd T3 cases in Samara vs 1/3rd in Munich, as different Gleason score evaluation between Samara and Munich with a preference to higher Gleason scores in Munich. Treatment strategy, performance and parameters as short term outcome (PSANadir) are excellent and almost identical (see table).

**Conclusion:** Prospective data comparison between two sites in (D) as (RUS)—using TUR&rHIFU for the treatment of all stages of PCa—show, that knowledge transfer by standardized teaching by a training site to a new site is safe and ensures high quality rHIFU treatments without long or risky learning curve for the new user or patients. Side effects as efficacy showed in the new site (RUS) excellent results compared to the experienced training site. Additional training, focusing on “specific TUR” before HIFU showed positive input in safety and efficacy of the combined treatment.

## O1-02 SUBAQUATIC ANTI GRAVITY MICROENVIRONMENT (SAGM) BASIC SKILLS TASKING USING A LAPAROENDOSCOPIC SINGLE-SITE SURGERY (LESS) UROLOGICAL TRAINING PLATFORM

S. Kommu, D. Cartlidge, Z. Hashim, A. Golash, C. Luscombe, S. (sarg)—United Kingdom

**Background:** Surgical trainees interested in minimally invasive urological surgery, and indeed their mentors, are under increasing pressure to acquire, maintain and transfer optimal laparoscopic and robotic urological skills. Recent developments such as Laparoendoscopic Single-Site Surgery (LESS) have led to its uptake in several centres of excellence. These approaches, with their inherent complex skills sets coupled with financial constraints place further demands on the trainee and mentor alike. This has led to current demands for the exploration of novel ways of helping the trainee to achieve the necessary skill set in a much quicker way in a cost conscious manner. Herein, we built and tested a Subaquatic Gravity Free Basic Skills Tasking Module for Laparoendoscopic Single-Site Surgery (LESS) for the urological trainee.

**Methods:** A box module with target skills tasks set underwater in a secure transparent unit was built. Articulating instruments and a multichannel port were attached to the training platform to replicate the movements as encountered during Laparoendoscopic Single-Site Surgery (LESS). The study involved two platforms for skill acquisition. One platform involved the Subaquatic Anti Gravity Microenvironment (SAGM) with its inherent gravity free medium. The other platform was devoid of SAGM and used the Conventional Microenvironment with inherent gravity (CM). Four trainees without prior laparoscopic skills were enrolled to test the modules. Skills tasks were split into basic, intermediate and advanced. Two trainees practiced on SAGM platform and two on CM platform. For SAGM Trainees, the basic task involved stacking 10 coins in the subaquatic environment. The intermediate task involved tying 5 knots and the advanced task involved performing a subaquatic vesicourethral anatomises (VUA). For the CM Trainees, the tasks were the same but without the subaquatic environment. Both groups were tested on a LESS Training kit with an index task, which involved cutting a star and stitching it over a template. The times for task completion were tallied. Feedback and video analysis were done.

**Results:** Trainees who practiced in the SAGM platform were 2.5 times quicker at completing the index target task as compared with those who trained on the CM platform. The SAGM Trainees completed the basic, intermediate and advanced tasks 1.2, 1.8 and 2.1 times respectively quicker than the CM Trainees. Feedback and video analysis found that the subaquatic gravity free microenvironment allowed the trainee to gauge the movement of the instruments with better ease and precision than those who practiced in the conventional mode. The interplay of handling the needle with the articulating instruments in the SAGM platform allowed the trainees using this mode to acquire the skills sets required for LESS significantly quicker than the conventional mode trainees.

**Conclusion:** Subaquatic gravity free skills tasking using a Laparoendoscopic Single-Site Surgery (LESS) urological training platform appears to significantly shorten the learning curve for target skill acquisition. This approach may have a potential application in acquiring the necessary skills for LESS in the ex vivo setting prior to undertaking the live human LESS Urological case. The SAGM approach should be tested further and could act as a useful supplementary tool for enhancing the rate of skill acquisition.

## O1-03 TRANSURETHRAL BLADDER ACCESS (TUBA) FOR NATURAL ORIFICE TRANSLUMENAL ENDOSCOPIC SURGERY (NOTES) IN A PORCINE MODEL

H. Kübler, A. Schneider, D. Wilhelm, A. Meining, J. Gschwend, H. Feussner

**Background:** Natural orifice transluminal endoscopic surgery (NOTES) is an evolving concept combining techniques of minimal invasive surgery with flexible endoscopy, potentially representing a major paradigm shift to scarless surgery and trauma reduction. NOTES allows surgical treatment without any incision of the abdominal wall, and therefore aims to further reduce the drawbacks of open surgery, such as postoperative pain, wound infection, and incisional hernias. A transvesical approach as a route of access to the peritoneal cavity in performing NOTES has not been well

studied, although this approach may be preferable to the more commonly used transgastric and transvaginal approaches. The aim of the present study was to assess the feasibility and the safety of the transurethral bladder access (TUBA) to the peritoneal cavity in an acute porcine model.

**Methods:** Transvesical peritoneoscopy was performed in an acute study in 10 female pigs ( $39.3 \pm 3.04$  kg). Maintenance of anaesthesia was achieved by bolus application of fentanyl until the start of the experiments and continuous infusion of 25–35 mg/kg/h pentobarbitone at a constant flow rate prior and throughout the experimental procedures. In order to get access to the peritoneal cavity with a flexible endoscope the urethra, the external urinary sphincter and the transmural bladder wall perforation were dilated up to 36 Charr using metallic dilatation catheters. Urodynamics (urethral pressure profilometry) were performed before, during and after dilatation to assess functional alteration of the external urinary sphincter. After euthanasia of the animals with 20 ml pentobarbitone and 40 ml KCl, the urinary tract was macroscopically inspected.

**Results:** The transurethral bladder access to the peritoneal cavity was successfully performed in all animals without complications. There was no bleeding or laceration of adjacent organs. After dilatation of the lower urinary tract up to 30 Charr and 36 Charr respectively we could observe a reduction of the urethral pressure that recovered over time. Dilatation of the bladder wall perforation up to 36 Charr allows access to the peritoneal cavity with a flexible endoscope for diagnostic endoscopy.

**Conclusion:** The transurethral bladder access (TUBA) is a feasible and safe approach to the peritoneal cavity in an acute porcine model. This study provides support for further studies using TUBA as an appropriate approach for minimal invasive, thermoablative interventions for small renal masses.

#### O1-04 THE IMPORTANCE OF THE EXPERIENCE OF SURGICAL TEAM ON THE OPERATIVE AND ONCOLOGIC RESULTS OF LAPAROSCOPIC RADICAL PROSTATECTOMY

T. Erdogru, M. Ucar, O. Celik, T. Ipekci, I. Duman, S. Altınova, M. Baykara—Turkey

**Background:** Primary disadvantages of Laparoscopic radical prostatectomy (LRP) are learning curve for the surgeon and transfer of the technique. However, importance of the experience of the laparoscopic team on the operative and oncologic outcomes has not been analyzed. We analyzed and compared our results of the single surgeon experience with the different experienced surgical team for LRP.

**Methods:** After completing his training, the surgeon (TE) implemented the procedure in his home academic center. We compared the operative parameters and oncologic outcomes in his independent practice with the 1st (G-1) and last 50 patients (G-2) at the same academic center with inexperienced and experienced surgical teams and the other 50 patients (G-3) with other inexperienced team at a different center.

**Results:** There was no significantly difference in the age, PSA, prostate volume between the three groups. While there was a conversion to open surgery in Group-1, no conversion was in Group-2 and -3. Operative parameters were summarized in the table. Positive surgical margin status between the both group were 4/28 (14%) vs. 3/34 (8%) vs. 1/33 (3%) for pT2 and 12/22 (54%) vs. 7/16 (43%) vs. 6/17 (35%) for pT3, respectively.

**Conclusion:** The transfer of the technique and the success of the procedure are highly dependent on the quality of laparoscopic training. Despite the surgeon experience, the experience of the surgical team for the harmonic surgical motivation is very crucial for the better results on surgical performance. However the oncologic safety is completely depend on the surgeons' experience.

#### O1-05 ROBOTIC-ASSISTED LAPAROSCOPIC SKILLS DEVELOPMENT: FORMAL VERSUS INFORMAL TRAINING

A. Benson, B. Kramer, M. Boehler, C. Schwind, B. Schwartz

**Background:** The learning curve for robotic surgery is not completely defined and ideal training components have yet to be identified. We attempted to determine whether skill development would be accelerated with formal, organized instruction in robotic surgical techniques versus informal practice alone.

**Methods:** Forty-three third year medical students naive to robotic surgery were randomized into two groups and tested on three tasks using the robotic platform. Between the testing sessions, the students were given an equally timed practice session. The formal training group participated in an organized, formal training session with instruction from an attending robotic surgeon while the informal training group participated in unstructured, undirected practice with the robot. The results were compared based on technical score and time to completion of each task.

**Results:** There was no difference between groups in pre-practice testing for any task. In post-practice testing, there was no difference between groups for the ring transfer tasks. However, for the suture placement and knot tying task, the technical score of the formal training group was significantly better than the informal training group ( $p < 0.001$ ), yet time to completion was not different.

**Conclusion:** While formal training may not be necessary for basic skills, our data suggest that specific, formal instruction for more advanced skills, such as suture placement and knot tying, is important in developing skills needed for effective robotic surgery. These findings may be important in formulating potential skills labs or training courses for robotic surgery.

#### O1-06 ANALYSIS OF COMPLICATIONS OF LAPAROSCOPIC PARTIAL NEPHRECTOMY IN A CONTEMPORARY SERIES FROM A LAPAROSCOPY DEDICATED CENTER

N. Benoist, O. Stakhovskiy, E. Barret, M. Galiano, X. Cathelineau, G. Vallancien—France

**Background:** To analyze complications in a series of patients undergoing laparoscopic partial nephrectomy (LPN) for renal tumors.

**Methods:** Between January 2000 and December 2007, 860 nephrectomies were performed in our institution. Out of these, 129 patients underwent laparoscopic partial nephrectomy and composed the population of the study. Median patient age was 59 (24–84) and mean tumor size was 28.3 mm (10.69). Data on complications was comprehensively performed and prospectively collected in a computerized database and retrospectively analyzed. Complications and follow-up update was comprehensively performed. Surgical approach to hilar clamping and tumor bed management included clamp with no suture, and clamp and suture. Variables evaluated for the study were intraoperative, postoperative (up to 30 days after LPN) and delayed complications (after 30 days). Complications were graded using a 5-tiered scale based on the severity of impact or intensity of therapy required.

**Results:** A total of 131 partial nephrectomies were performed in 129 patients. Median hilar clamping and ischemic time was 28 min (17.40). A total of 34 (25.9%) complications occurred in 20.1% of patients (26). No perioperative death occurred. With 25.9% of complications we observed 8, 20 and 6 intraoperative, postoperative and delayed events, respectively. Hemorrhage was the most frequent complication observed and it occurred intraoperatively, postoperatively and delayed in 6, 11 and 5 patients. Urinary upper tract was affected for in 53 (40%) LPN. 3 patients presented with urine leakage.

**Conclusion:** LPN is a challenging urologic operation with particular vascular characteristics and potential complications. Intraoperative morbidity is more frequently observed and considerable laparoscopic experience is desirable to solve these complications.

### O1-07 IS LAPAROSCOPIC PARTIAL NEPHRECTOMY EQUIVALENT TO THE OPEN PROCEDURE? 5 YEARS ONCOLOGIC AND FUNCTIONAL OUTCOMES OF A PROSPECTIVE STUDY IN 250 CASES

F. Greco, S. Wagner, M. Hoda, A. Hamza, P. Fornara

**Background:** To evaluate the functional and oncologic outcomes of laparoscopic partial nephrectomy (LPN) in comparing with open partial nephrectomy (OPN) for renal tumour.

**Methods:** Between July 1997 and January 2004 125 LPN and 125 OPN have been performed in our Clinic. Preoperatively all the patients underwent an intravenous pyelography, a computed tomography (CT) to have detailed informations about tumour size, location, extent of parenchymal infiltration, proximity to the pelviciceal system. Demographic data (age, gender), perioperative and postoperative parameters, including operating time, estimated blood loss, complications, length of hospital stay, renal function, histological tumour staging and grading, metastases rates were collected and analysed.

**Results:** The mean operative time for LPN and OPN was 135 min and 165 min, respectively. Mean warm ischemia time was 30 min (7–53 min) in the LPN and 28 min (6–50) in the OPN group. After 5 years from the operation the biochemical markers of glomerular filtration were completely normalized, demonstrating the absence of renal injury. The definitive pathologic results showed an incidence of 68% for renal clear-cell tumour, 13% for chromophobe tumour, 17% angiomyolipoma and 2% for benign complex cyst. The overall and cancer specific survival rates at 5 years were 88% and 100%, respectively in the laparoscopic group and 86% and 98% in the open group.

**Conclusion:** Laparoscopic partial nephrectomy, if performed by a skilled laparoscopist in expert centers, can report oncologic and functional outcomes that present no relevant differences in comparing with the open procedure.

### O1-08 A STRATIFICATION SYSTEM FOR PREDICTING SUITABILITY FOR DAYCASE LAPAROSCOPIC UPPER URINARY TRACT UROLOGICAL SURGERY

S. Kommu, A. Chakravarti, T. Finnigan, C. Luscombe, A. Golash—United Kingdom

**Background:** Laparoscopic upper urinary tract urological surgery in the form of Laparoscopic Nephrectomy/Nephroureterectomy (LN) and Laparoscopic Pyeloplasty (LP) is a minimally invasive urological procedure, which can be done safely and effectively as a day case in selected patients. From a strictly health economic point

of view it is also advantageous as hospital stay is reduced. The successful delivery of this type of service depends on the triad of surgeon, patient and infrastructure. We aimed to stratify those factors, which could predict suitability for daycase LN, and LP.

**Methods:** Patients who underwent daycase LN and LP were identified. Their records were reviewed retrospectively. A proforma was devised to include 3 facets. Facet 1 involved Patient Health. This included ASA status and comorbid history. Facet 2 involved Home Patient Ambulatory Support (HPAS). This included presence of a friend or relative at home to support the patient, home architecture including need for climbing stairs and infrastructure for summoning help e.g. availability of telephone. Facet 3 involved Nursing Support Services including geographical proximity to a district nurse. Each facet was scored for a minimum of 0 and a maximum of 10.

**Results:** Patients who had a score of 25 or more had a greater than 90% chance of success. Patients with a score of less than 10 are deemed unsuitable for daycase LN or LP.

**Conclusion:** Stratification systems such as the preliminary system described could act as useful adjuncts to help with deciphering the suitability of patients for daycase intermediate and major laparoscopic urological surgery.

### O1-09 SEXUAL FUNCTION AFTER LAPAROSCOPIC ASSISTED TENSION-FREE VAGINAL MESH FOR SURGICAL CORRECTION OF PELVIC ORGAN PROLAPSE

Toyohiko Watanabe\*, Miyabi Inoue, Ayano Ishii, Toyoko Yamato, Katsutoshi Uematsu, Katsumi Sasaki, Yasuyuki Kobayashi, Shinya Uehara, Takashi Saika, Yasutomo Nasu, Hiromi Kumon, Okayama, Japan

**Introduction and Objective:** The polypropylene mesh is now available to augment surgery for pelvic organ prolapse (POP) in Japan. We developed and reported an innovative approach to placing polypropylene mesh transvaginally for surgical correction of POP with laparoscopic assists. In this study we prospectively estimated sexual function before and after laparoscopic assisted tension-free vaginal mesh for POP.

**Methods:** From June 2007 to March 2009, 14 sexually active patients with POP underwent laparoscopic assisted tension-free vaginal mesh. All patients were evaluated before and at 3, 6 months and 1 year after surgery. Female sexual function was evaluated with the Female Sexual Function Index (FSFI) which was a 19-question, self-report measure, organized in a 6-domain structure, including desire, subjective arousal, lubrication, orgasm, satisfaction, and pain.

**Results:** Mean age at surgery was  $66.4 \pm 6.4$  years, median parity was  $2.1 \pm 0.3$ , and mean body mass index was  $24.5 \pm 2.4$ . Mean blood loss was less than 25 ml for all cases except for one patient with 300 ml blood loss. Before surgery, sexual activity was significantly reduced in POP patients comparing to control group without POP. Total FSFI scores improved significantly improved from  $10.2 \pm 7.9$  at baseline to  $18.2 \pm 8.1$  at 6 months,  $21.4 \pm 7.3$  at 1-year after surgery. Frequency of sexual activity also improved 0.97 per month at baseline to 1.78 at 1-year after surgery.

**Conclusions:** Pelvic organ prolapse appears to have a significant negative impact on female sexual function. Laparoscopic assisted tension-free vaginal mesh can contribute to an anatomical correction of POP, but also an improvement of sexual function.

### O1-10 THE PERSONAL HISTORY OF A FAR TOO SHORT PROFESSIONAL CAREER IN MINIMAL-INVASIVE UROLOGICAL SURGERY

M. Weber, X. Krah, A. Schneider, K. Miller, D. Froheberg, R. Hautmann

**Background:** We will depicts the main-authors time in Endourology from internship 1984 to a sudden car-accident in 2003  
**Methods:** *J.*

**Results:** *J.*

**Conclusion** *J.*

## O2: LOCALIZED PROSTATE CANCER

### O2-02 CLASSIFICATION AND TRENDS OF COMPLICATIONS IN 2500 ROBOTIC-ASSISTED RADICAL PROSTATECTOMIES

K. J Palmer, R. Ferreira Coelho, B. Rocco, S. Chauhan, G. Coughlin, V. Patel—US

**Background:** The aim of this study was to assess trends in the incidence and to classify surgical complications following Robotic-Assisted Radical Prostatectomy (RARP) in 2500 consecutive patients.

**Methods:** We analyzed 2500 patients who underwent RARP performed by a single surgeon. The approach in all cases was transperitoneal with a six-trocar technique using the da Vinci surgical system (Intuitive Surgical Inc., Sunnyvale, CA, US). The data were collected prospectively in a customized database. Complications were classified using the Clavien's grading system. To evaluate trends regarding complications and radiological anastomotic leaks we compared 8 groups of 300 patients categorized according to the surgeon's experience (number of cases).

**Results:** Our mean operative time was  $95 \pm 12.09$  minutes, ranging from 45 to 360 minutes. The mean estimated blood loss was  $113 \pm 36.6$  (25–500 ml). Our conversion rate was 0.04%, comprising one procedure converted to standard laparoscopy due to robot malfunction. The overall complication rate was 5.08% (127/2500). The incidence of grade I complications was 2.24%, grade II = 1.8%, grade IIIa = 0.08%, grade IIIb = 0.48% and grade IVa = 0.40%. There weren't any cases of multiple organ dysfunction or death (Grade IVb and V). There was a significant decrease in the overall complication rates ( $p = 0.0034$ ) and in the number of anastomotic leaks ( $p < 0.001$ ) as the surgeon's experience increases.

**Conclusion:** RARP is a safe treatment option for prostate cancer. The overall complication rates are similar to large open prostatectomy series of over 1000 patients. The complication rates trend to decrease as the surgeon's experience increases.

### O2-03 LONG-TERM ONCOLOGICAL FOLLOW-UP AFTER LAPAROSCOPIC RADICAL PROSTATECTOMY: THE HEILBRONN EXPERIENCE

M. Hruza, B. Flinspach, M. Schulze, D. Teber, J. Rassweiler—Germany

**Background:** Within 10 years, more than 2300 cases of laparoscopic radical prostatectomy (LRP) have been performed in the Heilbronn Department of Urology. To our knowledge, we are the first institution that presents an 8-years follow-up of a large cohort of patients after LRP.

**Methods:** Long-term follow-up of 370 of our first 500 consecutive patients (74.0 %) was available for this study. Median follow-up

was 89 months (range 74–115). 120 of the patients had a follow-up of more than 8 years.

**Results:** Biochemical recurrence-free survival was 81.9% at 5 years and 73.1% at 8 years in patients staged clinically organ confined preoperatively and 74.8% at 5 years and 61.5% in men staged clinically non-organ confined. However, clinical and pathological staging did not match in about one third of our patients. For men staged pT2, biochemical recurrence-free survival was 88.3% at 5 and 80.2% at 8 years, for pT3a, it was 68.0% and 52.2% and for pT3b/4, it was 62.7% and 50.6%. At 8 years, absence of clinical progression, defined as local recurrence or distal metastases detected with any imaging modalities, occurred in 97.2% of patients with pT2 tumors, in 84.4% with pT3a tumors and in 78.0% with pT3b/4 tumors. Overall survival was 94.9% at 5 years and 93.2% at the end of the follow-up. 8 patients died from prostatic cancer, 17 died from other causes: Myocardial infarction (4 patients), plasmocytoma, pancreatic malignoma, aneurysm of a cerebral arteria, carcinoma of the liver (2 patients), carcinoma of the rectum, stroke (2 patients), malignoma of the oesophagus, brain tumor, cardiac death, transitional cell carcinoma of the urinary bladder, renal cell carcinoma. Prostate cancer-specific survival in our cohort was 98.6% at 5 years and 97.8% at the end of the follow-up. All of the 8 patients who died from progression of prostatic cancer had been staged pT3 or pT4, in 7 of them the Gleason Score was  $>7$ .

**Conclusion:** In our cohort, biochemical and clinical recurrence-free survival rates are high after LRP, prostate cancer-specific mortality is very low. In patients with organ-confined disease, PSA elevation-free survival and clinical progression-free survival were significantly higher compared to patients staged pT3 or pT4.

### O2-04 COMPARISON OF PSA RECURRENCE BETWEEN HIGH RISK AND LOW RISK DISEASE GROUPS IN A ROBOTIC PROSTATECTOMY COHORT

A. Caire, M. Lipkin, D. Zilberman, M. Ferrandino, R. Thomas, D. Albala

**Background:** This study sought to analyze the outcomes abetween disease risk groups in patients undergoing robot-assisted radical prostatectomy.

**Methods:** A cohort of 455 patients who underwent robotic radical prostatectomy from 2003 to 2008 was retrieved from the Duke Prostate Center database. Race, body mass index (BMI), age at surgery, prostate weight, pathological Gleason sum, and pathological tumor stage were evaluated in the high risk group. High risk disease was defined as having at least one of the following: a PSA  $>20$ , biopsy Gleason sum  $>7$ , or clinical tumor stage  $>T1c$ . The high risk disease group was then compared to a low risk disease group comparing PSA recurrence rates. Low risk disease was defined as a PSA

<10, biopsy Gleason <7, and a clinical tumor stage of T1c. A Kaplan Meier analysis was performed between the two groups.

**Results:** The high risk disease group consisted of 75 patients with a median age of 58.2. The median follow time for the high risk disease was 2 years. The median BMI was 28.2 and the median prostate weight was 40.0 in the high risk group. There was no significant difference in PSA recurrence rates between high and low risk groups ( $p=0.740$ ).

**Conclusion:** Robot-assisted radical prostatectomy offers competitive survival rates between low and high risk disease states. Patients with high risk preoperative characteristics can have effective oncological outcomes with robot-assisted radical prostatectomy.

### O2-05 TIME TO FAILURE AFTER SINGULAR TREATMENT OF PROSTATE CANCER BY HIGH-INTENSITY FOCUSED ULTRASOUND (HIFU)

D. Pfeiffer, C. Cellarius, C. Netsch, A. Gross—Germany

**Background:** The outcome after HIFU treatment of prostate cancer is determined by PSA and repeated biopsies. We analysed whether this monitoring strategy allows an early detection of treatment failures.

**Methods:** 184 of 191 men, treated from 12/02 to 10/06, were enrolled. Median age was 70 yrs. (range, 51–82). Median PSA at diagnosis was 7.2 ng/dl (0.4–77). Tumours of all risk groups were treated. The Ablatherm device (Edap, France) was used. Patients were scheduled for PSA checks after 2, 3 and 6 mos. and then quarterly. Two patterns of PSA failure were recorded: 1—PSA nadir + 1.2 ng/ml (Stuttgart definition) and 2—PSA rise to a minimum of 0.5 ng/ml, if PSA-DT was <6 mos. Biopsies were performed after 6 mos. and in case of rising PSA. Treatment failure was defined as biochemical, positive biopsy and/or metastasis.

**Results:** PSA decreased to a median nadir of 0.09 ng/ml (range, 0.01–26.5 ng/ml). 109/141 control biopsies (77%) were negative. 133 men (72.3%) remained treatment failure-free over a median period of 72 weeks (quartiles, 61–88 weeks). The median PSA nadir was 0.05 (quartiles, 0.02–0.1) and final PSA was 0.1 (0.04–0.31). 51 men (27.7%) exhibited treatment failures. Time to failure was median 30 weeks (quartiles, 23–49 weeks). This subgroup showed a higher nadir PSA (median, 0.56; quartiles, 0.16–1.83) and final PSA (2.83; 1.3–4.6). The noted failures were biochemical in 17, local in 29 and from metastasis in 5 patients.

**Conclusion:** Successful HIFU treatment results in low and stable PSA values and a sufficient local tumour control. Most treatment failures occur within one year. Therefore, additional therapies can be introduced without delay.

### O2-06 PSA NADIR DEVELOPMENT AFTER LOCAL THERAPY BY ROBOTIC HIGH INTENSITY FOCUSED ULTRASOUND THERAPY (RHIFU) OF T1-2 PROSTATE CANCER

A. Neumayr, S. Thueroff, R. Nanieva, W. Steil, C. Leeser, C. Chaussy

**Background:** PSA Nadir after definitive therapy of prostatic cancer (PCa) is a valuable prognostic indicator for a successful therapy. This has been evaluated as well for the HIFU therapy. Two major modifications (TUR directly before HIFU and TUR one month before HIFU)—induced by clinical development— Influenced side effect rate. We evaluated, how therapeutic efficacy—measured by “PSA Nadir”—in genuine HIFU treated T1-2 PCa patients - in our institution developed within the last 10 years.

**Methods:** Data analysis out of the prospective Harlachung HIFU Database (since 1996). 3 patient cohorts ('98–00: HIFU only); ('01–04: TUR&HIFU); ('05–07: TUR 1 month before HIFU) with localized Pca (T 1–2), without permanent PSA influencing medication or other PCa therapy, treated completely by Ablatherm® (transrectal, robotic HIFU at 3MHz, EDAP-Lyon-France). Analysis of Initial PSA at diagnosis, PSA and prostatic volume before TUR/HIFU as PSA Nadir (median, average, min, max) after HIFU.

**Results:** Year of treatment 9899000102030405060708 Evaluable T1-235564765591301006570114125PSAi median88897.98.57.57.589.38PSAtr median877.986.87.57.15.84.14.44.1prostVol at HIFU (cc)1921192118202420252221PSA Nadir median 10.60.50.10.10.10.20.10.10.1

**Conclusion:** Stable decrease of PSA Nadir within the last 10 years, caused by combination of TUR&HIFU since 2000 allowing radical, complete HIFU treatments. Decrease of PSA between diagnosis and HIFU since 2005 demonstrates the effect of TUR on PSA, if performed one month before HIFU (any hormonal ablation excluded!) PSA Nadir of 0.1 ng/ml after TUR&HIFU therapy of localized PCa allows a positive prognosis for these patients, because “PSA Nadir <0.2 ng/ml” is correlated to >78% 5 years NED rate.

### O2-07 BIOCHEMICAL AND BIOPSY OUTCOMES FOLLOWING RADICAL HIGH INTENSITY FOCUSED ULTRASOUND (HIFU) OF PREVIOUSLY UNTREATED PROSTATE CANCER (PCA)

C. Robertson, R. Ganzer, J. Ward, S. Brown, X. Rébillard, A. Blana—USA

**Background:** HIFU is a versatile PCa treatment with the extent of ablation controllable in real time with potential for nerve sparing or focal approaches. Radical HIFU is the complete ablation of all prostatic tissue hallmarked by a post treatment PSA nadir <0.2 ng/ml. The objective of this study is the examination of biochemical and biopsy outcomes in subjects with localized PCa who had undergone Radical HIFU.

**Methods:** Case subjects were examined from the @-Registry. All patients with T1-2 PCa were included if they had undergone Radical HIFU as evidenced by PSA nadir ≤0.2 ng/ml. Patients who had undergone previous or concurrent intervention for PCa (including radiation therapy or hormonal therapy) were excluded. Kaplan-Meier analysis was performed to determine biochemical disease free survival (BDFS) stratified by risk group with failure defined according to the Stuttgart definition (nadir + 1.2 ng/ml), a definition validated as a predictor of clinical failure following Radical HIFU.

**Results:** Of the 2872 cases reviewed, 456 patients met the inclusion criteria. The average age and pre treatment PSA were 69.3 ± 6.2 years and 7.5 ± 5.0 ng/ml, respectively. The median Gleason and stage were 6 and T2a, respectively. Patients were followed for 46.4 ± 31.4 months (median 44.8). BDFS and biopsy outcomes are summarized in the table. Follow-up biopsies were performed in 326 patients. D'Amico Risk group BDFS@ 5-years Patients at risk BDFS@ 7-years Patients at risk Negative Biopsy Rate All (n = 456) 86% 16784% 6790% Low (n = 200) 92% 7592% 3193% Moderate (n = 205) 81% 7077% 2389% High (n = 51) 81% 2275% 1384%

**Conclusion:** Radical HIFU provides a high level of cancer control in T1-T2 NX M0 PCa as evidenced by high negative biopsy rates and high BDFS rates. Radical HIFU is an effective treatment choice for localized PCa.

**O2-08 PROSTATE CARCINOMA—LONG TERM RESULTS OF FUNCTIONAL OUTCOME AFTER INTERSTITIAL BRACHYTHERAPY AND RADICAL PROSTATECTOMY—A 13 YEAR FOLLOW UP**  
T. Lingenfelder, E. Heinrich, C. Bolenz, F. Wenz, M. Michel, L. Trojan

**Background:** Radical prostatectomy (RP) represents the standard for treatment of localized prostate carcinoma (PCa), brachytherapy (BT) is established as minimal-invasive treatment for low risk PCa. Aim of the study was to determine long-term outcome of functional parameters over a period of 13 years.

**Methods:** 412 patients were treated by BT for PCa between 1991 and 2005. 872 patients were treated by RP between 1995 and 2003. Patients were evaluated by written questionnaire (EORTC, modified ICS male) concerning side-effects on bladder and sexual function.

**Results:** Mean follow-up in both groups was 4 years. Mean age of BT and RP treated patients was 68 and 64 years. 71.7% (n = 620) of RP treated patients had non-nerve-sparing surgery. 89.3% (n = 303) of BT and 90.6% (n = 770) of RP had tumor-stage T1a-2b. Significant better results of increased voiding-frequency (BT 67.8% vs. RP 60.4%), nocturia (BT 43.7% vs. RP 28.9%), urge-symptoms (BT 47.4% vs. RP 36.4%) were recognized in RP group. Significant better results of continence were achieved in BT group (BT 11.6% vs. RP 15.6%). The group with nerve-sparing RP showed similar results to BT (BT 11.6%, nerve-sparing RP 11.2%). Absence of erections was reported by 43% of BT, 85% of RP without nerve-sparing, 45% of RP with unilateral nerve-sparing, 38% of RP with bilateral nerve-sparing.

**Conclusion:** BT causes significant higher rates of irritative voiding symptoms. Continence and preservation of erectile function seems superior in BT compared to RP without nerve-sparing. Differences became minor or insignificant in RP with bilateral nerve-sparing.

**O2-09 A MULTICENTER EVALUATION OF THE INITIAL PHASE OF ROBOT ASSISTED RADICAL PROSTATECTOMY (RALP): CORRELATION TO LAPAROSCOPIC PREVIOUS KNOWLEDGE**

T. Herrmann, R. Rabenalt, J. Witt, A. Georgiou, J. Stolzenburg, M. Burchardt—Germany

**Background:** Controversy exists about the necessity or helpfulness of laparoscopic experience prior to robot assisted laparoscopic surgery. Traditionally Europe is a field where urologic laparoscopic techniques gained importance in the last years due to the several namable pioneers of the technique in the field of radical prostatectomy. We analyze the complications and intra- and perioperative results of the early training phase within the 30 first surgeries of RALP in three centers with different previous open and laparoscopic experience.

**Methods:** Patients data, intra and postoperative records and results were collected prospectively for the first 30 patients treated with RALP by 3 single surgeons in 3 different centers. From Gronau a community based hospital, the surgeon started possessing mainly open radical prostatectomy experience, at the MHH, Hannover, the surgeon with mainly laparoscopic experience in radical prostatectomy was in the mid phase of the EERPE learning curve (132 patients) and finally from the University of Leipzig a surgeon with high volume laparoscopic experience of more than 450 EERPE's. The initial learning curve of the first 30 consecutive cases contained

both the mentored surgeries from the mentor based training programme and the first "all alone" surgeries.

**Results:** All centers completed their cases without conversion. OT-time (development) although varied significantly was in favour of the high volume endoscopic surgeon. No intraoperative complications were seen, and postoperative complication were dominated by lymphocele in the extraperitoneal centers, while two anastomotic disruption were reported. Oncological results showed positive surgical margins in 7.6%, 16% and 3.7% respectively in pT2 and 50%, 50% and 33% for pT3 respectively.

**Conclusion:** Parameters indicative of the learning curve are comparable to existing published initial series of other robotic centres. Novice robotic-assisted laparoscopic surgeons can safely learn RALP by a structured, mentor based, modular surgical training programme without putting patients at risk even in the early phase. The impact of a high volume of previous endoscopic surgery is significant. The complication rates in early patient series are low and comparable to those of published series in the current literature.

**O2-10 NOTES RADICAL PROSTATECTOMY: EVOLUTION OF THE TECHNIQUE**

M. Humphreys, J. Sauer, A. Krambeck, J. Lingeman, E. Castle, P. Andrews

**Background:** Innovations in minimally-invasive surgery have lead to the development of incision free Natural Orifice Transluminal Endoscopic Surgery (NOTES™). The purpose of this report is to describe the evolution of a technique for NOTES Radical Prostatectomy (NOTES-RP).

**Methods:** NOTES-RP was performed on six male cadavers. The technique for radical resection has previously been described. Different techniques were explored for the vesicourethral anastomosis. The first case a foley catheter under tension was used. The second cadaver, four interrupted sutures were placed using the SR-5 LS suture device (LSI Solutions, Victor, NY) with extracorporeal knots. The next two cadavers, a modified Running Device and adapted Ti-Knot knot replacement device were used (LSI Solutions, Victor, NY) through a prototype offset endoscope and cannula to achieve water tight anastomoses. In the last two cadavers, modified versions of the previously described equipment was used. Prostate tissue was morcellated from the second cadaver, while in the other cadavers it was removed intact for examination of surgical margins.

**Results:** NOTES-RP was successfully performed in all cadavers. Pathologic examination demonstrated complete removal of prostate tissue with preservation of neurovascular bundles and the urinary sphincter. Digital cystograms in the last two cadavers illustrated the hermetic vesicourethral anastomosis that is achievable through this small, but assessable natural orifice.

**Conclusion:** The present research demonstrates the feasibility of NOTES-RP in human cadavers. While further testing and instrument modification are necessary prior to clinical application, the success demonstrated provides optimism regarding the potential of NOTES-RP in the future.

**O2-11 BILATERAL NERVE-SPARING EXTRAPERITONEAL RADICAL PROSTATECTOMY: POTENCY RATES**

José Travassos, Augusto Xavier, Álvaro M. Figueiredo F<sup>o</sup> Facs, Kelly de Juan

**Introduction:** Wide variations exist in the methods for reporting potency following radical prostatectomy. In this group we used a

validated questionnaire (IIEF) pre and post operatively to assess relative return to normal sexual function after bilateral nerve-sparing videolaparoscopic extraperitoneal radical prostatectomy.

**Methods:** 170 patients with ages ranging from 45 to 70 years old were evaluated using the IIEF pre operatively and 3, 6, 9, 12 and 18 months after surgery. All the procedures were performed by the same surgeon using bilateral nerve-sparing technique. No thermal energy devices were utilized for coagulation and clipping was minimal in order to better preserve the neurovascular bundles.

**Results:** Preoperatively 150 patients had no sexual dysfunction and a 28.2 average according to IIEF score. 13 patients were classified in the mild category with 21.8 average score. 5 patients were in the mild to moderate group and scored an average of 17 points. 2 patients were classified moderate group and scored 10.

None were classified in the severe group preoperatively. After 1 year 115 (67.7%) patients were classified in the no dysfunction group and scored an average of 25.3. 14 (8.2%) patients were in the mild erectile dysfunction group scored 16.9. 24 (14.1%) patients in the mild to moderate group scored 12. 11 (6.5%) patients in the moderate group scored 7. 6 (3.5%) patients migrated to the severe dysfunction group, scoring 2 points. 29% of the patients that have had sexual intercourse used medication to improve or obtain erections. Improvements were observed even after 18 months, about 10% migrated to a better classification in the IIFE.

**Conclusions:** Careful preservation of the neurovascular bundles provides good potency recovery rates but no final conclusion should be established before one year of follow up.

## O3: RENAL CELL CARCINOMA AND UPPER TRACT

### O3-01 RENAL CELL CARCINOMA WITH MACROSCOPIC LEVEL I TUMOR THROMBUS EXTENSION IN TO THE RENAL VEIN: OUR 7 CASES EXPERIENCE

O. Castillo, R. Campos, I. Vidal-mora, A. Foneron, G. Rubio, M. Feria—Flores

**Background:** Owing to the established benefits of laparoscopic resection for renal masses, a number of groups have extended the indications of laparoscopic radical nephrectomy. The existence of renal vein tumor thrombus presents a technical challenge in securing hilar control during the resection of a renal mass. Our aim is to present our series of laparoscopic radical nephrectomy in patients with level I tumor thrombus.

**Methods:** From January to December 2007, seven patients at our institution underwent laparoscopic radical nephrectomy for renal masses that compromise de renal vein. All the patients had diagnosis of level I macroscopic renal vein tumor thrombus. Mean age was 66.8 years (55–83), mean body mass index was 24.76 kg/m<sup>2</sup> (18.0–33.9). In all cases, the chosen surgical technique was determined by tumor characteristics, and surgeon's preferences.

**Results:** The procedure was successfully performed in 7 patients. The surgery was performed hand assisted in 3 patients, and pure laparoscopic in 4 others. The mean operative time was 108.3 minutes (90–150), mean estimated blood loss was 108.33 mL (50–200), mean hospital stay was 2.8 days (2–4).

**Conclusion:** Despite longer follow up reports are needed to fully evaluated the survival of these patients. In this study we demonstrated the technical feasibility, safety, and oncological adequacy of laparoscopic techniques among patients with level I renal vein tumor thrombus.

### O3-02 LESS RADICAL AND PARTIAL NEPHRECTOMY: INITIAL EXPERIENCE

J. Watson, E. Barret, R. Sanchez-salas, F. Rozet, X. Cathelineau, G. Vallancien—France

**Background:** Radical or Partial nephrectomy (PN) for enhancing renal masses provides adequate cancer control outcomes. Laparoscopic single site (LESS) surgeries are evolving approaches

to advance minimally invasive surgery. To present our initial experience with LESS nephrectomy.

**Methods:** From January 2009 to June 2009, 12 consecutive patients with mean age 66 years (43–75), underwent LESS nephrectomy. Technique: A transperitoneal transumbilical approach was employed for all cases with a keyhole trocar placement for access. A 3-cm omega shaped was performed at the umbilicus, where 2 or 3 trocars of 5 mm and a 10 mm trocar were positioned (keyhole). Operations performed were: radical nephrectomy (RN) in 6 cases, and partial nephrectomy (PN) in 6 cases for mean size tumors of 53 mm (45–60) and 25 mm (18–29), respectively. Tumors were localized at the right kidney in 6 cases and the left kidney in 6 cases. Interventions were performed with a 5 mm 30-endoscope, conventional laparoscopic instruments and SonoSurg ultrasonic scissors (Olympus\*). Final specimens were extracted by the umbilical incision. Haemostatic adjuvants were used in all PN cases and vascular clamping was necessary in 2 of these cases. Frozen section was routinely performed. Perioperative and pathologic data were entered and prospectively recorded.

**Results:** Mean operative time was 136 min (90–180). Mean blood loss was 200 ml (0–700). A vascular clamping mean time of 28 min (21–35) was needed in 2 cases. For RN vascular pedicles were controlled with hem-o-lok clips (Weck\*) in 4 cases and an endo-GIA stapler in 2 cases. A conversion to open surgery was necessary in one case due to vascular stapler malfunction. In all other cases, the interventions were uneventfully completed by laparoscopy. Postoperative complications included: An episode of prolonged ileus and 1 hematoma lodge in the heminefrectomy cases. These patients received medical treatment and the one with the hematoma had a single unit blood transfusion. Final pathology reported renal carcinoma in ten cases and 2 benign lesions. Surgical margins were negative for all cases.

**Conclusion:** LESS partial and radical nephrectomies are feasible for highly selected patients. Further evaluation is mandatory.

### O3-03 LAPAROSCOPIC CRYOABLATION OF RENAL MASSES: WHICH LESIONS FAIL?

T. Yoost, N. Hamilton, H. Clarke, T. Keane, S. Savage—United States

**Background:** Laparoscopic renal cryoablation (LRC) is an evolving option for renal tumors. We analyzed 47 lesions that underwent LRC to identify potential predictive characteristics of those lesions which failed this approach.

**Methods:** We reviewed 45 consecutive patients with 47 masses who underwent LRC between 2003 and 2008 by 2 surgeons using a hand-assisted or a purely laparoscopic technique. We analyzed patient age, ASA, and pre and postoperative creatinine, tumor size, location, number of cryoprobes used, and histology of the lesions. We reviewed follow-up imaging to identify characteristics of those lesions which failed. Failure was defined as persistent enhancement and/or no decrease in size within 6 months. Analysis was performed using the student t-test.

**Results:** The median follow-up was 13 months. Median age and ASA were 69 and 3. Mean lesion size was 2.7 cm (range 1.2–5.4) with 25 anterior and 22 lateral or posterior. Mean cryoprobes used were 3 (range 1–6). Biopsy samples from 40/47 lesions showed renal cell carcinoma in 23, oncocytoma in 7, and 10 were benign or inconclusive. Treatment failure was noted in 8/47 lesions (17%), 7/8 (87.5%) of the failed lesions had broad-based contact with the renal sinus. Broad-based lesions with contact to the renal sinus were successfully treated 53.3% of the time, while lesions which lacked contact was treated successfully 96.9% of the time ( $p < 0.01$ ).

**Conclusion:** Careful selection is necessary for successful treatment using LRC. Our results suggest that broad-based renal sinus contact may predict a significant risk of failure and should be considered.

### **O3-04 HAND-ASSISTED LAPAROSCOPIC LIVING-DONOR NEPHRECTOMY VERSUS OPEN SURGERY: EVALUATION OF SURGICAL TRAUMA AND LATE GRAFT FUNCTION IN 82 PATIENTS**

F. Greco, A. Hamza, S. Wagner, M. Hoda, A. Inferrera, P. Fornara

**Background:** In the half century that has passed since the first successful procedure, living-donor renal transplantation has shown superiority over cadaveric donor renal transplantation. Because laparoscopy is generally less invasive than an open surgical technique, laparoscopy may be preferable if it can be demonstrated to achieve the same result, with the same safety for the patient, with a less operative trauma. With this study, we propose to evaluate differences in invasiveness and graft function of the hand-assisted laparoscopic technique and the open technique in living-donor nephrectomy.

**Methods:** This study is a retrospective, non-randomized single-center analysis. Between 1995 and January 2008, 82 patients with end-stage renal disease have received kidney transplantation from living donors. Open living donor nephrectomy was performed in 37 donors, whereas 45 donors had undergone laparoscopic hand-assisted nephrectomy. Demographic data, perioperative and post-operative data such as the markers of the acute phase (C-reactive protein; Serum Amyloide A) as well as biochemical markers of glomerular filtration (serum creatinine, serum cystatin C) at different perioperative timepoints, were compared.

**Results:** The mean operative times for HALLDN and OLDN were 165 min and 195 min, respectively. The average time of warm ischemia was 45 seconds for laparoscopy and 87 seconds for open surgery. The evaluation of acute phase markers demonstrated the

### **O3: RENAL CELL CARCINOMA AND UPPER TRACT**

minimal invasiveness of laparoscopy, with same late graft function in comparing with open surgery.

**Conclusion:** Hand-assisted living-donor nephrectomy has shorter operation times and warm ischemia times than does open surgery, offering at least same functional results and decreasing the surgical complications in comparing with a completely laparoscopic technique.

### **O3-05 INTRACORPOREAL RETRACTION DURING SINGLE PORT TRANSUMBILICAL LAPAROSCOPIC SURGERY**

A. Mikhail, A. Figueroa, L. Bryant, K. Tamaddon, J. Yew, L. Maynes

**Background:** With the advent of newer technology and instrumentation, single incision surgery has become increasingly apparent. We therefore present our experience with intracorporeal retraction during single port transumbilical endoscopic surgery.

**Methods:** Fifteen patients underwent single incision laparoscopic surgery including one patient that underwent a laparoscopic nephroureterectomy, 7 laparoscopic nephrectomies, and 6 laparoscopic pyeloplasties, and 1 ureterolysis. During these procedures a single Triport system (Advanced Surgical Concepts, Dublin Ireland) was used in 13 cases. Ports were placed using a Hassan technique. For Right sided cases or cases where a drain was to be placed an additional 5 mm port was also used. Intracorporeal retraction was achieved with bolstering sutures placed in the lower and/or upper poles then taken through the anterior abdominal wall in a pulley system fashion. With each pull to elevate the kidney, the suture was locked in place with clips. In some cases, the bolstering suture was brought out of the peritoneal cavity via a suture passer and anchored with a hemostat with each upward pull. Also vessel loops were used for ureteral retraction as well.

**Results:** Fifteen patients (6 female and 9 male) with an average age of  $44.9 + 18.6$  (16–74) years underwent a laparoscopic surgery via single incision technique comprising 10 left sided and 5 right sided cases. Average BMI was  $28.2 + 3.6$  (21.5–33.65)  $\text{kg/m}^2$ . Average operative time was  $194.7 + 46.3$  (137–285) minutes with an average blood loss of  $96.7 + 157.2$  (25–650) ml. Mean length of hospitalization was  $1.4 + 0.7$  (1–3) days. Average follow up was  $7.3 + 2.9$  (2–11) months. Two patients required conversion to standard laparoscopic surgery due to bleeding (1 nephrectomy case) technical difficulty (1 pyeloplasty case). No post operative complications occurred.

**Conclusion:** Single incision surgery offers patients an aesthetic improvement to standard laparoscopic incisions with potentially less post operative analgesic requirements. Its learning curve may prevent its wide spread use, however, with newer techniques for intracorporeal retraction and judicious use of an additional 5 mm port for Right sided tumors, this single incision technique may be deemed feasible. Longer follow-up with a larger cohort of patients will be required to verify the durability of this procedure with regards to pain control and overall feasibility.

### **O3-06 THE EXPERIENCES IN LAPAROSCOPIC URETEROLITHOTOMY: MULTICENTRIC ANALYSIS OF CASES, BASED ON “TURKUROLAP GROUP”**

E. Huri, E. Basok, Ö. Ugurlu, C. Gürbüz, T. Akgül, Y. Ozgok—Turkey

**Background:** The indication of laparoscopic surgery for ureter stones was restricted to the special cases, big size or impact stones.



We presented special cases who underwent laparoscopic ureterolithotomy in various clinics.

**Methods:** Forty-one patients were included to the study from 5 urology clinics in which routine laparoscopic surgery has been performing. Following history, physical examination, urine analysis, creatinin, intravenous urography, ultrasonograph, age, gender, stone size, hydronephrosis, previous ESWL, previous ureteroscopic stone therapy, laparoscopic approach, operation time, ureteric incision, insert double-j stent, amount of drainage, hospitalization period, complication were evaluated.

**Results:** Mean age was 41.8 in 30 male, 11 female patients. Mean ureter stone volume was 227.7 mm<sup>2</sup>. Retroperitoneoscopic was preferred in 35, transperitoneal in 6. In 4, Grade (G) I, 22 GII, 12 GIII were detected. In 6, previous ESWL was applied. Ureter was incised by cold knife in 5, scissor in 16, j-hook in 3, monopolar-bipolar cut in 17 patients. In 6 patients, double-j stent was inserted while in 1 operation was converted to open. Mean operation time was 124 minutes. Mean amount of drainage was 220 cc. Mean hospitalization time was 4.8 days. In 5 (12.5%) of 7, persistent drainage was detected as a major complication treated via insertion d-j stent. All patients were discharged as a stone free status.

**Conclusion:** Laparoscopic ureterolithotomy is a feasible and effective procedure especially for stones that could not treat easily with ureteroscopic approach. Increased hospitalization and operation time could be related with difficulties of stone removal while success was achieved in each patient.

### O3-07 THE TECHNIQUE AND SKILL IMPROVEMENT OF LAPAROSCOPIC LIVE DONOR NEPHRECTOMY VIA RETROPERITONEAL APPROACH (WITH 150 CASES REPORT)

L. Ma, L. Zhao, X. Hou, G. Wang, K. Hong, Y. Liu—China

**Background:** To summarize the technique and skill improvement of laparoscopic live donor nephrectomy via retroperitoneal approach in our hospital.

**Methods:** 150 patients underwent laparoscopic live donor nephrectomy via retroperitoneal approach at our institution from December 2003 to June 2009. Under general anesthesia, all donors were placed in lateral decubitus. We used three transretroperitoneal trocars whose diameter was 12 mm, 10 mm and 5 mm through different ports of the waist. The skill of the dissociation of donor kidney and vessel of kidney: a. Clean up the extroperitoneal fatty tissue of the hyperpimelic patients. Cut off the Geort fascia for 3–4 cm in front of the major psoas muscle. The incision couldn't be too large! Dissociate the donor kidney completely inside the adipose capsule. It would not influence our operation if the adipose capsule was adhered to the tissue around. b. Remove the fatty tissue between the major psoas muscle and the kidney. It would be very easy to reveal and liberate the renal vessel. c. Separate and deligate the genital vein and the lumbar vein between the major psoas muscle and the kidney. d. Liberating the ureter for about 7–8 cm away from the anus perineum of donor kidney in advance would make it much easier to separate the renal pedicle. Skill improvement: A. Genital vein, lumbar vein and adrenal veins were cut with ultrasound knife. It would be much expensive to cut these veins with endoscopic articulating linear stapler. Beside, cutting with Ti-clip would influence the occlusion of renal arteries and veins with hem-o-lok. B. The dissected donor kidney and ureter were taken out through an incision about 6 cm extended from the first trocar port. The incision should be suitable to the

muscle fiber in order to reduce muscle fiber and nerve injury. C. In order to decrease the warm ischemia time, we usually cut open skin and subcutaneous tissue prior to the disconnect of renal arteries and veins.

**Results:** All the 150 nephrosectomy operation were successfully performed, mean operative time was 80 min (50–180 min), and mean blood loss during operation was 70 ml (10–200 ml), none of the donors needed blood transfusion. Warm ischemia time was 3–5 min, postoperative length of stay averaged 5.5 d (3–9 d). At the mean follow-up, all the donors were healthy and no complication occurred. All the renal transplantation were successfully performed.

**Conclusion:** Mastered the skills of laparoscopic live donor nephrectomy via retroperitoneal approach and combined with technical improvement, we have made the operation safe and effective.

### O3-08 FAST-TRACK LAPAROSCOPIC NEPHRECTOMY-THE NEED FOR TEAMWORK

L. Lund, M. Jønler, M. Jakobsen, J. Dich—Denmark

**Background:** Factors which can affect early recovery after laparoscopic procedures include ileus, pain, nausea, emesis, and fatigue. The objective of this study was to evaluate the impact of a multimodal fast-track program with/without dedicated follow-up at the ward after laparoscopic nephrectomy between two comparable groups.

**Methods:** Two consecutive cohorts of patients were followed and reviewed after surgery. Forty-one patients undergoing laparoscopic nephrectomy received a fast track program with follow-up at the ward and were compared to a laparoscopic group with 38 patients without follow-up. A standardized programme has been made and it was very important that all members of the team followed that programme. All patients had a thoroughly work-up before surgery with out-patient consultation with both the surgeon and a nurse. The day after admission the patients underwent surgery and received a standardized anaesthetic technique: they received premedication with antibiotic, dexamethason was administered at the start of anaesthesia and odansetron at the end, local anesthesia was administered at port-sites. Two hours after returning from the recovery room the patients started a mobilization program and began to drink and eat. During the postoperative period, several objectives were assessed at specific time intervals e.g. pain, nausea and patient satisfaction with pain management and quality of recovery, and side effects and re-admissions.

**Results:** In the first group there were 41 patients, 22 men and 19 women median age 63 years (17–87 years), and in the group with no follow-up at the ward there were 38 patients, 23 men and 15 women median age 63 years (33–86 years). In the fast track group 96% of the patients were discharged after 1.2 days after surgery compared to 3.4 days in the group with-out follow-up. There were no per-operative complications but 2 medical and 1 surgical post-operative. None received blood transfusions. The mortality was zero. The re-admission was 20% in both groups.

**Conclusion:** A multimodal approach to laparoscopic nephrectomy has shown to be very effective and safe with shorter hospital stay, as well as better pain control and patient satisfaction. There is a need for constant follow-up by interested personal in order to minimize the hospital stay. This fast track regime has great socio-economic impact e.g. less use of beds at the ward and earlier return to work.

### O3-09 THE ANALYSIS OF RISK FACTORS AFFECTING MINI-PERCUTANEOUS NEPHROLITHOTOMY (MPCNL) FOR OLDER THAN 70 YEARS AND THE CORRESPONDING STRATEGY (REPORT OF 34 CASES)

Z. Xiao-feng, L. Da-zhi, L. Yun-feng—China

**Background:** To analyze the risk factors affecting mini-percutaneous nephrolithotomy (MPCNL) in the population of patients over the age of 70, and explore the corresponding strategy.

**Methods:** Review the clinical data of 34 patients over the age of 70 years who underwent MPCNL procedures. They included 21 male and 13 female, aged from 71 years to 84 years (median, 76 years). Twenty one cases were renal calculi, 7 were upper and middle ureteral calculi, 6 were renal calculi with upper ureteral calculi. The calculi were located on the left side in 15 cases, on the right side in 17 cases and both sides in 2 cases. Two patients had previously open surgery and 25 patients had renal inadequacy, hypertension, diabetes, chronic obstructive pulmonary disease or electrocardiographic abnormality. The average of ASA classification was . The smallest size of the calculi was 0.8 cm×0.9 cm, the largest was 3.2 cm×3.5 cm (mean, 1.4 cm×2.5 cm).

**Results:** All patients with comorbidities are related to internal medicine specialist for their consultation before and after operation. All the procedures were successful, the operative time was limited no more than 90 min. Of these cases, 6 need secondary procedures, 11 cases underwent MPCNLs in supine position and 2 simultaneously received bilateral MPCNLs. The overall stone-free rate was 89.8%. All the patients were tolerated well and no major complications occurred. The comorbidities were not aggravated and the postoperative recovery was fine too.

**Conclusion:** Our clinical data confirmed that MPCNL appears to be a feasible, safe, and effective procedure in the population of patients over the age of 70 years with upper-urinary-tract calculi. Renal inadequacy, severe hypertension, diabetes and long operative time much influence the postoperative outcomes. Correct

choice of operative time, operative time reasonable control, and well controlled comorbidities do not increase the operative risk. Supine position MPCNL on patients with chronic obstructive pulmonary disease can reduce the operative risk.

### O3-10 CHANGING TRENDS IN THE USE OF URETEROSCOPIC INSTRUMENTS FROM 1996 TO 2008

D. Bagley, N. Leone, M. Garcia-roig—USA

**Background:** Despite ongoing advances in the field of endourology, there are few reports describing specific changes adopted by urologists that have come as a result. We investigated the progression of single surgeon's clinical practice over a 12 year period, noting differences in ureteroscopes, ancillary equipment, and indications for surgery over that time.

**Methods:** The records of 1181 patients undergoing ureteroscopy by a single surgeon were reviewed. Consecutive patients from the years 1996 (n=200), 1998 (n=179), 2000 (n=198), 2002 (n=127), 2004 (n=137), 2006 (n=200), and 2008 (n=140) were included in the study. Patients remained grouped by the year of their procedure for comparison. Compared variables included the indication for surgery, type of anesthesia, method of ureteral dilation and stabilization, specific ureteroscopes used, type and number of working instruments employed, and the method of post-procedure ureteral drainage.

**Results:** A change favoring smaller, more flexible ureteroscopes was seen. An increase in the percentage of surgeries performed for upper tract tumors paralleled decreasing trends in urolithiasis and UPJ obstruction surgery. A divergence in the devices used for calculi and upper tract tumors was seen.

**Conclusion:** Over the past 12 years, technological advancements in the field of endourologic surgery has resulted in shifting clinical practice for endourologists, with trends favoring smaller, actively flexible ureteroscopes, intrarenal surgery, and nitinol basket use.

## O4: LOWER URINARY TRACT

### O4-01 ENDOSCOPIC TREATMENT OF VESICoureTRAL REFLUX BY COLLAGEN IN CHILDREN (15 YEARS EXPERIENCE)

I. Babanin, I. Kazanskaya, Z. Sabirzianova—Russia

**Background:** To investigate the results of endoscopic treatment of vesicoureteral reflux (VUR), depending on its type, with the instable bulking agent—collagen.

**Methods:** From 1995 till 2008 more than 1000 endoscopic implantations of collagen (concentration 72 mg/ml) were done in 850 children with vesicoureteral reflux in the age from 3 month to 9 years. Selection of the method of the endoscopic correction of VUR depended on variation of the division of ureter—functional or organic type.

**Results:** Functional type was characterized with VUR grade 1–3, bladder overactivity, decreasing of pressure gradient in ureterovesical junction during the bladder filling; in endoscopic sign ureteral orifices were in typical place and looked like normal. Organic type was characterized by VUR grade 3–4, severe bladder

dysfunction; disappearing of pressure gradient, orifice was asymmetric. In 450 cases of functional type 2 ml of collagen was implanted under the orifice. In others (organic type) we used balloon catheter for transposition of orifice in moment of collagen's implantation. In 23% it was necessary to make correction twice. The effectiveness of functional type correction was about 86%, of organic—72%. There were no any complications in all patients.

**Conclusion:** Such approach of the selection the method of endoscopic treatment VUR with the use of a biological implant collagen made it possible to obtain high efficiency of treatment and eliminated the need of applying synthetic materials in children.

### O4-02 THE FEASIBILITY OF HIGH RESOLUTION OPTICAL COHERENCE TOMOGRAPHY TO DETECT UR-OCYSTITIS CYSTICA IN HUMAN BLADDER

J. Bornemann, G. Joachim, F. Spöler, A. Naami, R. Knüchel-clarke, G. Jakse—Germany

**Background:** The feasibility of high resolution optical coherence tomography (HR-OCT) as a non-invasive imaging technique was shown in many cases in the past. With image resolutions down to 1  $\mu\text{m}$  and imaging depths in the range of 1–3 mm this method has now the potential to classify and distinguish the layers in healthy and morphological altered bladder tissue. The objective of our study is to show the feasibility to detect urocystitis cystica in the way of virtual histology.

**Methods:** An OCT system comprising a Ti:Sapphire femtosecond laser to support a resolution of 3  $\mu\text{m}$  axial  $\times$  7  $\mu\text{m}$  lateral was employed to image 48 fresh human bladder tissue specimens from cystectomies. The OCT tomograms were double blinded evaluated and finally referenced to histological sections using standard HE staining.

**Results:** In greyscale OCT tomograms urocystitis cystica appears as a cavernous dark structure surrounded by more scattering brighter tissue. In 10 histological sections of 48 specimens urocystitis cystica could be detected by light microscopy. 9 of these 10 specimens were correctly identified by OCT tomograms before (90%), one sample was categorized as nonexisting urothelium. Histology OCT urocystitis OCT urothelium OCT tumor OCT CIS OCT no urothelium total urocystitis cystica 9 0 0 0 1 10 normal urothelium 0 29 0 0 0 29 tumor 0 0 4 0 0 4 CIS 0 1 0 2 0 3 Total 9 30 4 2 1 46.

**Conclusion:** HR-OCT is a promising modality for the evaluation of bladder microstructures with the possibility to differentiate Cystitis cystica from normal and cancerous tissue HR-OCT. This might be helpful for the selection of endoscopic bladder biopsies. DFG supported, grant no. Kn 263/10-1, Ja 482/5-1, Ku 540/47-2.

#### O4-03 MAXIMISING THE POTENTIAL OF PHOTODYNAMIC DIAGNOSIS (PDD) IN THE MANAGEMENT OF BLADDER CANCER

K. Thomas, D. Wilby, T. O'Brien—UK

**Background:** Photodynamic diagnosis (PDD) or 'blue-light' cystoscopy is increasingly accepted as allowing a more complete assessment of a bladder tumour than conventional 'white light' cystoscopy. It can also aid complete resection.

**Methods:** Four studies using PDD 1. Treatment of multifocal recurrent papillary bladder tumour 2. Investigation of occult positive urinary cytology 3. Assessment of bladder post-BCG 4. A randomised controlled trial in patients with new bladder tumours of blue light TURBT + mitomycin versus white light TURBT + mitomycin

**Results:** 1. Extra tumours identified on PDD in 56% of patients 2. Bladder tumour identified in ~30% of patients with occult positive cytology. 3. Post-BCG false positive biopsies are very common so no longer used routinely. 4. The randomised trial has recruited 200 patients and will close in spring 2010. PDD shows the pathological anatomy of bladder tumour often includes a barely visible 'skirt' of tumour extending from the central tumour; we routinely take a 5 mm margin ensuring complete resection. PDD is not recommended for early re-resection post TURBT as inflammation after the first resection always causes false positive fluorescence.

**Conclusion:** PDD offers numerous exciting possibilities to improve bladder cancer management through better detection and more complete surgical treatment.

#### O4-04 VIRTUAL URETROSCOPY: NORMAL ANATOMY, VARIANTS & CLINICAL IMPACT

E. Ehab Rifat Tawfik, A. Moustafa

**Background:** To evaluate the clinical impact of the virtual ureteroscopy for detection of small ureteric urothelial tumors and in evaluation of the ureterovesical junction in bladder neoplasia.

**Methods:** The study included 67 patients 30 to 72 years mean age = 48 years. Volumetric MDCT examination of the urinary system was done pre and post I.V. administration of non-ionic contrast medium. 60 ml of contrast was given using the automatic pump injector at a rate of 4 ml/sec. Early arterial phase and delayed scans were obtained about 10 minutes from the time of the initial contrast injection. Virtual ureteroscopy was carried out from the pelvicalyceal system till bladder via navigation through ureters. Images were correlated with axial reference images. Conventional ureteroscopy was done for all patients.

**Results:** The MDCT allowed a volume that is easily manipulated. Virtual ureteroscopy images were informative, identical with conventional ureteroscopy. Detection of early urothelial ureteric neoplasia was easy. Accurate estimation of ureteric orifice implication at the vesicoureteric junction being implicated or spared in 24/25 patients (96%). It could be adopted in teaching purposes. It could be standardized for the evaluation of the bladder neoplasia to assess the vesico-ureteric junction involvement.

**Conclusion:** This technique enables better patient management and prognosis. The technique is relatively non-invasive, less hazardous to patient, giving precise data. Nevertheless it displays the magnitude of the urothelial pathology, its extension and staging in one stop examination. Limitations no biopsy.

**Key words:** Ureteroscopy virtual Computed tomography.

#### O4-05 THULIUM LASER ENUCLEATION OF THE PROSTATE 5 YEAR RESULTS

G. Watson, P. Verma—UK

**Background:** Our first 50 patients having thulium laser enucleation have now completed 5 years of follow-up.

**Methods:** Initially the prostate lobes were carved into sections thought small enough to remove using a Storz curette but latterly we have used monopolar and the bipolar resection of the lobes lying freely within the bladder. One cohort of the patients were treated in the context of a randomised trial compared to holmium laser and bipolar probe enucleation (Gyrus). The thulium laser was equivalent to the holmium laser and the Gyrus bipolar probe in terms of bleeding and catheter time.

**Results:** The flow rates, postmicturition residuals and symptom scores all improved significantly compared to preoperatively but with no differences between the modalities used.

**Conclusion:** We conclude that enucleation is a robust technique and that there is little to choose between the devices which can be used.

#### O4-06 THULIUM:YAG VAPOENUCLEATION IN PATIENTS WITH LARGE PROSTATES (>100 G)

K. Harrer, C. Netsch, A. Gross, A. Häcker, M. Michel, T. Bach

**Background:** RevoLix-Laser prostatectomy currently establishes itself as a promising treatment alternative for benign prostatic hyperplasia (BPH). Aim of this study was to evaluate feasibility, efficiency and complication rates of VapoEnucleation for patients with very large prostates (>100 g, group I) and compare them to patients with smaller glands (group II).

**Methods:** VapoEnucleation was performed using a 120 Watt Thulium:YAG 2 micron continuous wave laser in combination

with a reusable bare-ended laser fibre. VapoEnucleation was carried out using a continuous flow laser resectoscope in combination with a tissue morcellator. Measured outcomes were i.a. catheter time, improvement of post-voiding residual urine (PVR), International Prostate Symptom Score (IPSS) and Quality of Life Index (QoL).

**Results:** 74 consecutive patients with BPH were treated with the 120 W Revolix-Laser, thereof 41 patients with a prostate volume over 100 g. We performed VapoEnucleation in all patients. Mean prostatic volume was 127 ml in group I and 66 ml in group II. Preoperative characteristics were comparable between both groups. PVR, IPSS and QoL improved equally after RevoLix-Laser for small and large glands. No transfusions were necessary. Complication rates and catheter time were comparable.

**Conclusion:** These results indicate that transurethral RevoLix prostatectomy is efficient independently of prostate volume with a high level of satisfaction and low complication rates. Follow-up data is needed to prove these promising results.

#### O4-07 ENUCLEATION OF THE PROSTATE WITH THE 2-M CONTINUOUS WAVE THULIUM LASER IN DIFFERENT EXPERIENCED SURGEONS

C. Netsch, K. Oberhagemann, A. Gross—Germany

**Background:** Thulium laser enucleation of the prostate (ThuLEP) has been introduced as an alternative to Holmium laser enucleation of the prostate assuming a steeper learning curve of the procedure. We prospectively evaluated resident's learning curve for ThuLEP in comparison with two experienced surgeons.

**Methods:** ThuLEP was performed in 94 patients by 3 surgeons, an expert in ThuLEP (A, 52 patients), a surgeon with TURP experience (B, 22 patients), and a resident (C, 20 patients) without any experience in TURP/ThuLEP. ThuLEP was realized with a 120 watt 2  $\mu$ m continuous wave thulium:YAG laser (RevoLix®). Mean enucleation/morcellation efficiency and mean % of resected tissue were analysed and compared.

**Results:** Mean prostatic volume was  $26.6 \pm 9.57$  cc in surgeon C and was significantly lower than that of surgeon A ( $51.37 \pm 27.24$ ;  $p = 0.001$ ) and B ( $53.14 \pm 32.23$ ;  $p = 0.007$ ). Enucleation efficiency was  $1.34 \pm 0.7$  (A),  $0.71 \pm 0.39$  (B) and  $0.19 \pm 0.11$  (C) gm per minute and differed significantly between each surgeon ( $p = 0.000$ ). There was no significant difference in mean percentage of resected tissue between each surgeon. Morcellation efficiency was  $1.44 \pm 1.3$  (C) gm per minute in surgeon C and was significantly lower than that of surgeon A ( $2.93 \pm 1.69$ ;  $p = 0.033$ ) and B ( $3.15 \pm 1.75$ ;  $p = 0.029$ ). Morcellation ( $r = 0.55$ )/enucleation efficiency ( $r = 0.82$ ) correlated significantly with resected tissue weight in surgeon A ( $p = 0.000$ ).

**Conclusion:** Our preliminary data suggest reasonable efficiency of ThuLEP on each level of experience. However, previous experience in classical TURP is obviously beneficial.

#### O4-08 SALVAGE CRYOABLATION OF PROSTATE CANCER USING 17 G CRYONEEDLE TECHNOLOGY 7 YEAR GERMAN EXPERIENCE

U. Witzsch, G. Voss, E. Becht

**Background:** Therapeutic options after failure of 1st line therapy for localized prostate cancer (PC) are limited. Mostly unsatisfying results are combined with severe side effects. Improvements in transrectal ultrasound (TRUS) technology and the introduction of the 17 G cryoneedles (Galil-Medical, USA) enable for an urol-

ogist to monitor and precisely control ice formation during the prostate gland cryoablation. We show our results of alternative salvage therapy in localized prostate cancer.

**Methods:** Between 9/2001 and 2/2008, we did 165 prostate cryoablation procedures. 102/165 patients (pts.) had been treated for salvage therapy: Rising PSA after radiation therapy (either LDR or HDR Brachytherapy ( $n = 10$ ) or external beam radiation therapy  $n = 40$  local recurrence after radical prostatectomy (RP)  $n = 24$  rising PSA after initial hormone therapy  $n = 17$  recurrence after cryotherapy  $n = 10$  recurrence after HIFU  $n = 1$  Pts. were classified as "favourable" if they had PSA  $< 10$  ng/ml, Gleason  $< 7$ , Tumour stage  $< T3$ , 10 pts. were pts. with favourable characteristics. Pts. were classified as "unfavourable" if they did not meet all 3 stated parameters. 41 of the pts. were salvage pts. with unfavourable characteristics. 50 pts. were failures after any kind of radiation therapy Median PSA was 5,6 ng/ml and median Gleason score was 8 All pts. had positive biopsies and negative metastatic work up prior to cryoablation. From 9 to 19 17-G, cryoneedles were percutaneously placed in the prostate under TRUS guidance. 2 cryoneedles and a thermo sensor were placed in Denonvillier's fascia for temperature monitoring and active thawing. While freezing rectal temperature was closely monitored and when a reading of below  $20^{\circ}$  C was noted, rectal warming was activated simultaneously A "pull back" (of 15 mm median) was done for prostates longer than 35 mm (32pts.) Median treatment time was 115 min.

**Results:** PSA %  $< 0,1$  ng./ml  $> 0,1 - < 0,5$  ng./ml median years 138% 15% 46% 0,12 34% 14% 52% 0,33 45% 18% 36% 0,13 37% 0,15 31% 25% 44% 0,36 30% 20% 50% 0,4 Pts. after radiation therapy are suffering from a higher rate of irritative symptoms. Pts. after RP remain low in PSA and side effects. No incontinence was observed. The minority of the remaining salvage pts. stay on low PSA levels. This might be due to occult metastasis at the time of restaging. Except one fistula no SAE occurred. If the seminal vesicles are treated intermittent ureteral obstruction is probable.

**Conclusion:** Although most of the pts. were at high risk for progression, the results are encouraging. 3rd generation cryoablation of the prostate enables urologists to use an minimal invasive treatment for pts. who had failed other therapeutic options for localized PC.

#### O4-09 CRYOABLATION OF PRIMARY LOCALIZED PROSTATE CANCER USING 17 GAUGE CRYONEEDLES TECHNOLOGY 7 YEAR EUROPEAN EXPERIENCE

U. Witzsch, E. Becht, G. Voss

**Background:** Gold standard for treatment of localized prostate cancer is the radical prostatectomy. "Minimal invasive" therapies, radiation and hormonal ablation seemed to be less effective especially in high risk patients. Because prostate gland cryoablation for organ-confined disease has evolved dramatically during the last two decades, with significant reductions in complication rates and with improved outcomes a new option is given for localized therapy if radical prostatectomy is not indicated. We show our experience of the last 7 years.

**Methods:** Between September 2001 and February 2008, 165 prostate cryoablation procedures were performed in Krankenhaus Nordwest, Frankfurt, Germany. 38% ( $n = 63$ ) of those patients (pts.) were considered primary including those having a neoadjuvant hormone therapy for max. 3 months. 60 pts. had contraindications for radical prostatectomy due to comorbidity or age  $> 70$  years. Pts. were classified as "favourable" if they had PSA  $< 10$  ng/

ml, Gleason <7, Tumour stage <T3, 22% of the pts. were patients with favourable characteristics. Pts. were classified as “unfavourable” if they did not met all three of the stated parameters. In this series 78% of the patients were primary patients with unfavourable characteristics. Median initial PSA was 9.6 ng/ml. Median Gleason score 8. Between 10 to 19 17-gauge, cryoneedles were percutaneously placed in the prostate under transrectal ultrasound guidance. Two cryoneedles and a thermo sensor were placed in the area between the rectal wall and Denonvillier’s fascia for temperature monitoring and active warming. During the freezing process rectal temperature was closely monitored and when a reading of below 20° C was noted, rectal warming was activated simultaneously. A “pull back” (of 20 mm median) was done for prostates longer than 35 mm (59%.) Median treatment time was 135 minutes.

**Results:** PSA <0,1 ng./ml >0,1- 0,5 >0,5 ng./ml Median 1 Y36% 18% 45% 0,32 Y42% 27% 31% 0,13Y43% 26% 30% 0, 14Y 44% 38% 19% 0, 35Y 37% 42% 21%0, 16Y 36% 45%18% 0, 2 There were no SAE seen. We did not observe any fistula in our patients. Most common side effect was a gross haematuria which ceased the next day without special therapy. Two patients reported a low grade incontinence (one with obesity and severe diabetes another 80 years old with cerebral disorders). Erectile function can not be judged because most of the pts. were impotent before cryotherapy.

**Conclusion:** Third generation cryoablation of the prostate is a minimally invasive alternative primary treatment for pts. suffering from prostate cancer who are contraindicated for radical prostatectomy due to comorbidity. Even in this series 78% of the patients were unfavorable (high risk) the results are encouraging.

#### O4-10 THE HOLMIUM LASER IN OPERATIVE TREATMENT OF PEYRONIE’S DISEASE

A. Assubayev, A. Bayzhanov, B. Shalekenov, E. Kuandykov, T. Anafin, S. Shalekenov

**Background:** The purpose of the given research was to develop and to study efficiency of Peyronie’s disease treatment with the operative methods, which was developed by us with use of holmium laser energy.

**Methods:** 14 patients were included in research. Average age was 56.7. Duration of illness was from 1, 10 till 3, 8 years before operation. All patients had a corner of erectile deformation more than 30°. All patients had preserved erectile function. 7 patients marked impossibility of introjection due to a significant curvature of penis. 6 patients had the steady pain syndrome which couldn’t be stopped by conservative actions.

**Results:** The best results were received at curvature of penis up to 45°, moderate results were fixed at curvature up to 60°. If the corner of deformation was more than 60°—the changes were absent. In none of the cases the deterioration of erectile function and contraction of penis was observed. Among 7 men who marked difficulty of penetration before operation, 5 patients observed improvement of a sexual life after operation, because of the reduction of erectile deformation corner of penis, 2 patients had not marked such changes. However it is necessary to notice, that the given patients had an initial erectile deformation corner more than 60°. After operation all 6 patients observed stopping of pain syndrome. 12 patients have continued a sexual life in 25–30 days.

**Conclusion:** Thus, application of the holmium laser in surgical treatment of patients with Peyronie’s disease is a perspective direction and possesses the following advantages: technical simplicity of operation, small trauma, the minimal depth of influence, hence, absence of risk of cavernous bodies tissue damaging, absence intraoperative, postoperative bleedings, the minimal terms of rehabilitation.

## O5: UPPER URINARY TRACT

#### O5-01 EXTRACORPOREAL SHOCK WAVE LITHOTRIPSY (ESWL) IN THE MANAGEMENT OF INFANT UROLITHIASIS

M. Dönmez, O. Kaygisiz, S. Tekgül—Turkey

**Background:** We investigate the efficiency of ESWL in the treatment of urinary calculi in children under 2 years old.

**Methods:** Between January 2006 and June 2008, 40 patients (29 boy, 11 girl, median age: 10 months range: 10 days–24 months), 55 renal units were treated with ESWL for urolithiasis under sedation. There were 14 lower caliceal, 15 mid caliceal, 6 upper caliceal stones, 21 in the renal pelvis, one in the proximal ureter. The mean stone burden was  $76,8 \pm 55 \text{ mm}^2$  (16–247). Efficiency of treatment is calculated with Efficiency quotient (EQ: stone-free% X 100/ (100% + %re-treatment rate + % auxiliary procedures) formula.

**Results:** 45 ESWL sessions (mean:  $1.33 \pm 0.67$ , range 1–4) were performed. Stone free (SF) rate was 82.2% (37/45), clinical insignificant residual fragment (CIRF) rate was 17,7% and none ESWL failure was observed. Mean EQ was 0.64. There was no significant statistical association between the locations, size and the number of successfully treated calculi (table). SF CIRF Total

Renal Units (n) 37 8 45 Median Age (months) 11 9 10 Mean Calculus Size ( $\text{mm}^2$ ) 77, 76.72, 62.76, 8 Mean SWL Session 1.29 1.37 1.33 Mean Shock Number 1400 1375 1382 Mean Maximum Energy 1.59 1.4 1.53 Mean Average Energy 1 0, 97.0, 99 Calculus Localization (%) Pelvis 85.7% 14.28% 21 Lower pole 78.6% 21.4% 14 Middle pole 80% 20% 15 Upper pole 83.3% 16.7% 61 Proximal ureter 100%

**Conclusion:** ESWL is a non-invasive effective treatment method in infant age group which is able to eliminate 82.2% of the treated calculi and the rest presented partial response.

#### O5-02 EXPERIENCE IN PERCUTANEOUS NEPHROLITHOTOMY IN 47 INFANTS WITH MELAMINE-RELATED UPPER URINARY CALCULI

J. Li, W. Hu, B. Yang, X. Huang, X. Wang—China

**Background:** In the September 2008, the melamine-contaminated milk scandal was exposed to the mass media, the melamine contamination of infant formula and milk products in China placed thousands of children at risk for renal-stone. Almost all of the

hospitalized children were infants. In the present study, we summarize our experience in percutaneous nephrolithotomy (PNL) treatment for infant patients with melamine-related upper urinary calculi and investigate its efficacy, safety and indications in infant patients.

**Methods:** Between Sep. 2008 and Apr. 2009, 47 patients younger than 3 yrs undergoing PNL in our institution were enrolled in this prospective study. They were all with upper urinary calculi and a confirmed history of consuming MTMP (melamine-contaminated milk product, and ultrasonographic evidence of renal or upper ureteral calculi. This series consisted of 30 male and 17 female infants with a mean age of 25 months (range 7~36 months), who underwent a total of 57 PNLs. Right-side, left-side, and bilateral PNL were performed in 19, 18, and 10 cases, respectively. The stones included 50 renal calculi (10~32 mm in diameter, median 19 mm) and 8 upper ureteral calculi (8~14 mm in diameter, median 9.8 mm). In 1 case, bilateral renal calculi and left upper ureteral stone were found. Bilateral renal calculi in 10 cases were treated on separate occasions at an interval of 7 days, on consideration of the infant patient's tolerability. All patients were assessed clinically and with imaging.

**Results:** 40 patients (85.1%) had a history of conservative treatment for same-sided urolithiasis. The percutaneous renal access was successfully established in 57 PNL under ultrasound guidance and immediate lithotripsy was performed. We performed low pressure system PNL using a peel-away sheath. The tract was dilated up to 12 ~ 16F in all the infants. Rigid nephroscopes were used with a variety of lithotripsy modalities. The mean operative time was  $13.6 \pm 1.6$  minutes (range 18~28 minutes), which include accessing time  $1.7 \pm 0.4$  mins and stone management duration  $11.9 \pm 1.9$  mins. None of the patients required a second-look procedure. No major bleeding, or intraoperative problems occurred in these operations. There were no severe complications. No deaths and blood transfusion occurred. 68.4% (39/57) of the patients were found a decrease in the hemoglobin level. The hemoglobin drop ranged from 0.5 to 1.8 g/dL (mean 0.97 g/dL). In most of the patients, the hemoglobin level decreased less than 1 g/dL. Two infants had fever for 2 days, but they responded to intravenous antibiotic very well. Complete stone-free was achieved in 51 renal units (89.5%). The mean length of stay (LOS) was 12 days (range 10 ~ 17 days).

**Conclusion:** PNL remains a highly effective technique for melamine-related upper urinary calculi in infants which had a special metabolic risk factor. As a high-risk operation, especially to infant group, PNL should be strictly be based on indications. We recommend the following relative indications for PNL as the first line of option in infant group with melamine-related calculi of upper urinary tract: 1. infants with a large stone burden bigger than 1.5 cm in diameter, 2. multiple renal calculi, 3. partial or complete staghorn stones, 4. stones inducing high-grade obstruction, 5. stones that have failed ESWL or other attempts.

### O5-03 SUPINE VS PRONE PERCUTANEOUS NEPHROLITHOTRIPTY (PCNL): A RETROSPECTIVE ANALYSIS ON 65 PROCEDURES

U. Anceschi, C. Molinari, C. Anceschi, M. Gallucci

**Background:** Percutaneous nephrolithotripsy (PCNL) is the gold standard treatment for renal stones  $\geq 2.5$  cm. This procedure is routinely performed from most of the urologist in the prone position. Supine position offers both operative and anesthesiologic

advantages in high risk patients affected by obesity, respiratory chronic insufficiency or cardiovascular diseases. Aim of our study was to compare retrospectively the supine approach to PCNL (sPCNL) with the standard approach (prone) (pPCNL) on a population of 65 patients.

**Methods:** Between November 2008–March 2009 we performed 65 PCNL. The patients were divided in two groups: group A: 25 patients underwent sPCNL. Among this group 15 patients underwent spinal anesthesia group B: 40 patients underwent pPCNL (5 patients with spinal anesthesia). Perioperative data were collected retrospectively. The groups were compared on the following parameters: Body Mass Index (BMI); Mean Operative time, (OT) stone free rate (SFR); postoperative complications rate; blood transfusion rate (BTR) median hospital stay (MHS). For the statistical analysis we used the Chi square and the t student test.

**Results:** Median BMI values was 28 in the A group range (24–30); and 26 (range 23–30) in the B group. Median operative time was 35 mins in the A group vs 40 mins in the B group. ( $p = 0.2$ ). At 6 months follow up, SFR was respectively 88% in the sPCNL (22 pz) and 92.5% (37 pz) in the pPCNL. ( $p = 0.15$ ). Median hospital stay was similar in both groups (A: 4 days vs B: 3 days) ( $p = 0.17$ ). BTR was insignificant (only 1 case in the B group). We reported in both groups 2 cases of postoperative fever; in the A group we had 1 case of severe postoperative anemia caused by an artero-venous fistula (AVF) treated successfully with an immediate superselective embolization.

**Conclusion:** No statistically significant difference was reported between both group. According to our experience, sPCNL represents a safe approach especially in patients with high BMI value. sPCNL offers several advantages such as the possibility of performing a spinal anesthesia; a reduced time of patient positioning; an improved control of the airways breathing. However further evidence is needed to understand whether sPCNL is the best approach to perform PCNL.

### O5-04 PERCUTANEOUS NEPHROLITHOTOMY (PCNL) UNDER SPINAL ANESTHESIA (SA) WITH MARCAINE

S. Rabani—Iran

**Background:** The efficacy of PCNL in the treatment of renal stones has been proven in its indications. The main method of anesthesia in this procedure is general anesthesia. We used spinal anesthesia as an alternative method of anesthesia with many benefits. This study was intended to show the possibility of SA as a more comfortable method of anesthesia for the surgeon, the anesthesiologist and the patient via more cooperation of the patient during changing the position and prevention of some complications mostly in upper extremities and neck.

**Methods:** A total of 112 patients underwent PCNL under SA with marcaine, from 2005 till Feb. 2009. Their mean age was 36 years (22–48), at first the syringe was stained by epineprine and then 2–3.5 ml marcaine was used for SA and if needed analgesics, sedatives or both were added. The rest of the procedure was done as routine.

**Results:** Stone clearance was achieved in 82% of the patients and the rest were managed by ESWL. The mean operation time was 126 minutes (90–220), 36% of the patients needed sedation, analgesia, or both specially in large burden stones. 6% of the patients had upper pole stones. Blood transfusion was needed only in one patient. No significant complication was seen in this study.

**Conclusion:** PCNL under SA produces the opportunity of more patient cooperation during changing the position and precludes some morbidities that may happen under general anesthesia, because the patient is awake and able to portend.

#### **O5-05 MINIMAL INVASIVE PCNL IN THE TREATMENT OF NEPHROLITHIASIS—ANALYSIS OF EFFICIENCY AND MORBIDITY AFTER 443 CONSECUTIVE PATIENTS. DEPARTMENT OF UROLOGY, SILOAH ST.TRUDPERT HOSPITAL, PFORZHEIM, GERMANY**

V. Zimmermanns, P. Liske, C. Hofmann, S. Lahme

**Background:** Extracorporeal shock wave lithotripsy (SWL) or percutaneous nephrolithotomy (PCNL) are the treatment modalities of choice in nephrolithiasis. SWL however is associated with a relatively high probability of residual fragments, whereas PCNL demonstrates better results, but is more prone to complications. To reduce the invasiveness and consequentially the complication rate a miniaturized 18F instrument for PCNL (MPCNL) has been developed. 443 consecutive patients were prospectively evaluated to determine the status of the method.

**Methods:** 443 patients (mean age  $53.8 \pm 12.9$ ) were treated. Data on the stone size and location, stone-free rate, blood transfusions, operating time and complications were recorded. A subgroup with a stone mass larger than  $5 \text{ cm}^2$  on the plain x-ray film ( $n = 139$ ) was analyzed separately to determine the applicability to larger stone loads.

**Results:** In 440 patients access was possible. On average retreatment rate was 0.29 (subgroup: 0.37). The mean stone size was  $4.4 \text{ cm}^2$  (subgroup:  $9.4 \text{ cm}^2$ ). The average operating time was  $66 \pm 47 \text{ min}$ . (subgroup:  $75 \pm 25 \text{ min}$ ). Overall stonefree rate was 92.7% (subgroup: 92.1%). Blood transfusion were needed in seven cases (1.7%, subgroup: 1.4%). Febrile pyelonephritis was observed in 29 patients (6.5%, subgroup: 7.9%). Except one arterio-venous fistula, which had to be treated by interventional radiology, no major complications were observed.

**Conclusion:** MPCNL was a reliable alternative to SWL for renal calculi with a size from 1 to 3 cm located in the renal pelvis and calices, especially the lower calix. Advantages are short treatment time and the high stone-free rate. Complication rate is similar to that of SWL and significantly lower when compared to conventional PCNL. Despite the reduced diameter of the instruments treatment of larger stone burden is possible with just slightly increased operating time. As high stone-free rate and low level of complications are maintained, MPCNL is worth to be considered alternatively to conventional PCNL in suitable cases.

#### **O5-06 MULTI TRACT TUBELESS MINIMAL INVASIVE PNL (MIP) WITH HAEMOSTATIC GELATINE MATRIX SEALANTS IN STAGHORN STONES**

T. Herrmann, D. Schilling, F. Imkamp, C. Von klot, U. Walcher, U. Nagele—Germany

**Background:** The concept of tubeless minimal invasive Mini-PNL (MIP) with Gelatine matrix haemostatic sealants (GMHS) has been proved to guarantee a high probability of stone free rate and planable schedule for the patients. We evaluated the clinical feasibility of tubeless MIP performed in a multi tract modality as a treatment for complete or partial staghorn calculi in order to combine efficiency of PNL with the low morbidity of MIP. The presented study reports the results of the first 10 consecutive patients under this concept.

**Methods:** Between April 2006 and August 2008, 10 patients were treated with the intention of tubeless multitract Mini-PCNL (2 or more tracts) with GMHS for staghorn (6/10) or complex caliceal (4/10) calculi. The average stone burden was  $6 \text{ cm}^2$  [0.88; 38.22]. A double-J stent was inserted antegradely following complete stone removal and the access tract was sealed by GMHS, or the patient was put on nephrostomy for further intervention.

**Results:** 7 patients could be treated with primarily tubeless MIP, 3 patients were put on nephrostomy for second look procedure. The mean OR-time was 115 min [49, 179] 136 minutes. 5 patients were stone free after one multitract MIP. 3 patients required Re-MIP, 2 Re-URS due to residual fragments in the kidney or ureter resulting in an overall stone free status in all of the patients. Median haemoglobin decrease was 1.8 mg/dl [0.5; 6.4], only 1 blood unit was protectively necessary due coronary heart disease. All patients had an uneventful follow-up until double-J catheter removal.

**Conclusion:** Tubeless multitract minimal invasive PNL is a feasible option for the treatment of partial or complete staghorn stones. OR-time and stone free rates were adequate. The results regarding complications especially blood loss and patient discomfort are promising.

#### **O5-07 OUTCOME OF PERCUTANEOUS MANAGEMENT OF STAGHORN CALCULI: CAN ACCESS NUMBER BE PREDICTED?**

T. Akman, E. Sari, M. Binbay, E. Yuruk, A. Muslumanoglu, A. Tefekli—Turkey

**Background:** To investigate the outcome of percutaneous nephrolithotomy (PCNL) in the management of staghorn calculi and to assess whether we can predict the required access number for success or not.

**Methods:** The records of 413 patients with staghorn calculi who underwent percutaneous nephrolithotomy were reviewed retrospectively. Of the 413 patients, 223 (54%) had complete and 190 (46%) partial staghorn calculi. A total 244 (59%) patients were managed by single access (group-1), and 169 (41%) patients underwent multiple accesses, the number ranging from 2 to 6 (group-2). Both groups were compared in terms of per-operative findings and post-operative outcomes. Patients and stone-related factor affecting the number of accesses performed were analyzed.

**Results:** The mean number of percutaneous access was  $2.42 \pm 0.74$  (range 2–6) in group 2. Mean duration of fluoroscopy and operation times were significantly longer in group-2 ( $p = 0.002$ ,  $p < 0.0001$ , respectively). Supracostal access was required in 30.7% in group-2, and in 6.9% in group-1 ( $p = 0.001$ ). Success was achieved in 70.1% in group 1 and in 81.1% for group-2 after one session of PNL ( $p = 0.012$ ). The most common complications were bleeding for both groups and it is higher in group-2 ( $p < 0.0001$ ). Neither the stone size nor the degree of hydronephrosis could predict the number of accesses but the incidence previous open surgery was higher in group 2 ( $p = 0.008$ ).

**Conclusion:** PCNL with multiple accesses is a highly successful alternative with considerable complication rates in the management of staghorn calculi. Our results further indicated that only the history of previous open surgery predicted the need for multiple accesses.

#### **O5-08 PERCUTANEOUS NEPHROLITHOTOMY IN AUTOSOMAL DOMINANT POLYCYSTIC KIDNEY DISEASE PATIENTS; THE HIGHEST EFFECT, THE LEAST MORBIDITY**

M. Khorrami, M. Sarrafian, K. Nouri mahdavi, F. Tadaion, F. Farahini isfahani

**Background:** We evaluated the role of percutaneous nephrolithotomy (PNL) in patients with autosomal dominant polycystic kidney disease (ADPKD).

**Methods:** Four ADPKD patients underwent PNL between 2003 and 2008. The mean age of the patients was 42.8 years and three of them were male. The renal stones diameter was 3.2 cm on average. PNL was done under C-arm in prone position under general anesthesia. Tract was dilated with metal telescoping dilator and pneumatic probe was used for lithotripsy. After procedure a nephrostomy tube was located in pelvis.

**Results:** All patients became stone-free after surgery. Nephrostomy tube was kept for an average of three days after surgery. No major complication was observed during and after surgery. Serum creatinine and hemoglobin levels did not significantly change after surgery. The only complication observed in the patients was urine leak from the site of nephrostomy tract after removal, which lasted for 31.5 hours, on average. This was significant, compared to that in patients with normal kidneys who underwent PNL. (31.5 hours versus 6 hours)

**Conclusion:** PNL is a safe and effective method for removal of renal stones in ADPKD patients with no significant complication. Urine leak from nephrostomy site is longer than normal kidney but it is self limited.

#### O5-09 PERCUTANEOUS NEPHROLITHOTOMY IN HORSESHOE KIDNEYS: FACTORS AFFECTING STONE-FREE RATES

A. Skolarikos, A. Tefekli, A. Bisas, M. Binbay, A. Muslumanoğlu, C. Deliveliotis—Turkey

**Background:** To evaluate those factors which affect stone-free rates following percutaneous nephrolithotomy in horseshoe kidneys.

**Methods:** We retrospectively evaluated the immediate postoperative stone-free rate of PCNL performed in 58 horseshoe kidneys at two urological centres. Univariate and multivariate analysis were performed to identify those factors which affect stone free-rate.

**Results:** At patient discharge stone-free rate was 65.5%. Stone free-rate was not correlated to the urological team who performed PCNL ( $p=0.863$ ), patient gender ( $p=0.299$ ), associated comorbidities ( $p=0.731$ ), overweight ( $p=0.785$ ) or obesity ( $p=0.328$ ), history of recurrent infections ( $p=0.683$ ), history of prior stone formation ( $p=0.339$ ), history of prior open surgery ( $p=0.764$ ), and degree of hydronephrosis prior to PCNL ( $p=0.104$ ). Stone classification as simple or complex ( $p=0.01$ ), stone burden  $>5\text{ cm}^2$  ( $p=0.013$ ), stone burden  $>10\text{ cm}^2$  ( $p=0.012$ ), multiple stones ( $p=0.006$ ), and staghorn stones ( $p < 0.001$ ) were related to adverse outcome in univariate analysis.

Stone-free rate was unaffected by the puncture site related to costal margin (subcostal vs supracostal  $p=0.487$ ), to the punctured calyx ( $p=0.197$ ), or the number of percutaneous accesses ( $p=0.339$ ). When one access was performed, the puncture of the upper calyx was associated with a slightly lower stone free-rate, although statistical significance was not reached ( $p=0.06$ ). The use of flexible nephroscope did not increase stone clearance rate ( $p=0.07$ ). Intraoperative bleeding ( $p=0.110$ ) and the need for intraoperative transfusion ( $p=0.126$ ) did not affect stone-free rate. Finally, stone-free rate was also unaffected by the stone composition. Logistic regression analysis revealed the existence of staghorn calculi as the only significant factor to predict stone free-rate ( $p=0.002$ ). The odds of a patient who has staghorn calculi in the horseshoe kidney to have a lower stone-free rate following a PCNL are 45 times higher than those of a patient without staghorn calculi in the horseshoe kidney.

**Conclusion:** Stone parameters are important when treating calculi in horseshoe kidneys. Staghorn calculi are associated with the lower stone-free rate post-PCNL.

#### O5-10 THE ROLE OF FLEXIBLE URETERORENOSCOPY WITH HOLMIUM LASER IN TREATING RENAL STONE MORE THAN 2 CM: NEW ERA

S. Alqahtani, D. Legraverand, M. Ndoye, J. Rode, B. Merlet, O. Traxer—France

**Background:** We evaluate the use of minimal invasive flexible ureterorenoscopy with holmium laser for the renal stone burden greater than 2 cm.

**Methods:** We evaluated 114 patients (117 renal units) retrospectively with urinary calculi of 20–58 mm (mean 26.7) underwent Flexible URS with holmium laser. The outcome was determined at 4 weeks after session on KUB and NCCT or by a second look by F-URS if needed. The Flexible URS success was defined as stone free (SF) or remaining stone fragments less than 2 mm which considered as clinically insignificant residual fragments (CIRF).

**Results:** Of our data we obtain (SF) in 33 renal units (28.2%), 31 (27.4%) had (CIRF) and 52 (44.4%) had residual fragment after the first F-URS session with holmium laser. Stones of patients rendered stone free in 84 patients (73%) after the second session. The success rate for F-URS was 55.6%, 83.8% and 93.2% at the first, second and third session of F-URS respectively.

**Conclusion:** The use of F-URS with holmium laser in treating renal calculi more than 2 cm is feasible and safe. This technique could be proposed for the patient with complex as one of the modalities of treatment as it has excellent results, low rate of complications and short hospital stay.



## O6: BLADDER AND PROSTATE CANCER

### O6-01 IN BLOC LAPAROSCOPIC RADICAL CYSTECTOMY AND NEPHROURETERECTOMY FOR UPPER AND LOWER TRANSITIONAL TUMORS

O. Castillo, I. Vidal-mora, A. Foneron, R. Campos, G. Rubio, F. Sepulveda

**Background:** We present our experience with laparoscopic radical cystoprostatectomy and unilateral nephroureterectomy for organ-confined, muscle-invasive transitional cell carcinoma (TCC) of the bladder in two patients with simultaneous upper and lower transitional tumors.

**Methods:** A women of 72 years old and one man of 62 years old with organ-confined, muscle-invasive TCC of the urinary bladder and simultaneous ureteral tumors underwent laparoscopic bilateral pelvic lymphadenectomy, radical cystoprostatectomy and unilateral nephroureterectomy. Urine spillage was avoided and in bloc urothelial integrity between the bladder and the renal specimens was maintained throughout the procedure. The intact, entrapped specimens were removed in bloc via a midline incision at the end of the procedure.

**Results:** The total operative time was 260 and 360 min, respectively, including repositioning and re-draping between each major step. Blood loss was 400 and 800 mL, respectively. There were no intraoperative complications. The first patient resumed oral intake 3 days after surgery and was discharged home after 12 days. She complete 22 months of follow up without evidence of local or remotely recurrence. The second patient evolved with an intra abdominal sepsis and intestinal fistula, which required re operation. He was discharged 60 days after surgery.

**Conclusion:** The multiple laparoscopic surgical resections in experienced hands is a feasible technique with encouraging results. The detailed preoperative evaluation and selection of appropriate patient is mandatory to carry out this procedure.

### O6-02 LAPAROSCOPIC RADICAL CYSTECTOMY WITH EXTRACORPOREALLY ILEAL Y-SHAPED ORTHOTOPIC NEOBLADDER CONSTRUCTED WITH NONABSORBABLE MECHANICS SUTURE: OUR INITIAL EXPERIENCE

O. Castillo, R. Campos, I. Vidal-mora, A. Foneron, G. Rubio, M. Feria—Flores

**Background:** Our objective is to describe the technique and present the preliminary results of patients who underwent laparoscopic radical cystectomy with extracorporeally ileal Y-shaped orthotopic neobladder, constructed with nonabsorbable mechanics suture.

**Methods:** Between November 2005 and December 2008, 12 patients underwent this procedure. Surgical technique is described. Data analyzed was: operation room time, urinary diversion time, intra-operative and postoperative complications, day and nighttime continence and postoperative voiding frequency.

**Results:** Mean operation room time was 271 minutes (range 220–300) and mean time of urinary diversion was 54.5 minutes (range 40–75). There were no intra-operative complications and hospital stay was 6 days (range 5–7). During follow-up there were two late postoperative complications; a urinary tract infection which was treated with antibiotic therapy and a stenosis of the uretero- neo-

bladder anastomosis presented three months after surgery, which was resolved with percutaneous balloon dilatation with good functional outcome. There were no stones in the neobladder and daytime continence was complete in 7 patients. Nighttime continence was complete in 5, and 2 patients have a partial continence. One patient was managed with clean intermittent catheterization.

**Conclusion:** The ileal Y-shaped orthotopic neobladder constructed with nonabsorbable mechanics suture, is a reproducible, fast and secure technique with promising functional results. Long term follow-up studies are needed to determine their long-term results.

### O6-03 IS STRICT PERIOPERATIVE BOWEL MANAGEMENT IN LAPAROSCOPIC SURGERY FOR UPPER ABDOMINAL CAVITY IMPORTANT?

H. Yanaihara, H. Sakamoto, M. Matsushima, M. Horinaga, Y. Nakahira, H. Asakura—Japan

**Background:** Routine application of fixed perioperative orders, including bowel management, is important to arrange limited money and human resources for efficient patient care. However, justification of routine order is usually concealed from open discussion because routine order does not make a huge problem.

**Methods:** We investigate 75 cases retrospectively who underwent laparoscopic surgery from 2005, performed by a single surgeon. Bowel preparation using laxative and/or enema has been done for 9 cases (3 for adrenal gland, 6 for kidney). Restriction of oral clear liquid intake was obligated on the day of operation. We have started avoiding bowel preparation since May 2006. Since then, 66 cases (18 adrenal gland, 43 for kidney, 5 for others) were operated without bowel preparation and were allowed to intake clear liquid right after fully awaking from anesthesia.

**Results:** No case who avoided preoperative bowel preparation experienced severe bowel complication. Most of patients could take normal diet from the first postoperative day. Intraoperative bowel condition did not disturb laparoscopic view. No aspiration pneumonia has been experienced. Body temperature returned to normal range within a few days in all cases. No difference was observed after cessation of bowel care.

**Conclusion:** Routine bowel preparation was supposed not to be important for laparoscopic surgery. Early fluid intake has not been harmful. Each steps of routine management should be assessed, although further investigation should be planned to justify our management.

### O6-04 ONCOLOGIC RESULTS FOR EXTRAPERITONEAL VERSUS TRANSPERITONEAL RADICAL PROSTATECTOMY

R. Sanchez-salas, F. Bianco, X. Cathelineau, F. Rozet, E. Barret, G. Vallancien—France

**Background:** To compare oncological results of laparoscopic radical prostatectomy (LRP) performed by either an extraperitoneal (EA) or a transperitoneal (TA) approach.

**Methods:** Between January 1998 and June 2008, 3260 consecutive patients mean age 62 years (42, 76) underwent LRP for prostate cancer, 1362 by TA, and 1898 by EA. Demographic and perioperative data were recorded. The Fisher test and chi2-test were used for statistical analysis. Differences were considered signifi-

cant when  $p < 0.05$ . Kaplan-Meier curves were generated to estimate time to BCR, defined as PSA of 0.2 ng/ml and rising. Log rank test was used to compare pathologic variables. Cox regression analysis estimated variables associated with time to BCR.

**Results:** There were no significant differences between the two groups in terms of preoperative characteristics. Operating time was equivalent with both techniques (205.5 min vs. 190.0 min,  $p = 0.5$  for trans and extraperitoneal, respectively). There was no difference in transfusion rate (3.5% vs. 4%, TA vs. EA, respectively,  $p = 0.6$ ). There was no difference in hospital stay, medical and surgical complications. Respectively, in TA and EA groups, there were 1038 and 1388 pT2 tumors. There were no differences in terms of positive surgical margins between the two groups, 15.2% and 13.8% in pT2 tumors and 30.5% and 27.2% in pT3 tumors. Surgical technique was not verified in the multivariable analysis as an independent variable predicting survival. Nerve sparing was performed in 80% and 89% of transperitoneal and extraperitoneal, respectively. At a mean follow-up of 3.3 years (1,10) respectively, in the transperitoneal and extraperitoneal groups there are 75% and 80% of recurrence free patients.

**Conclusion:** EA offers the equivalent long term oncological outcomes as TA. LRP offers reliable oncologic outcomes.

#### **O6-05 INTERMEDIATE TO LONG-TERM ONCOLOGIC OUTCOME FOLLOWING LAPAROSCOPIC RADICAL PROSTATECTOMY FOR CLINICALLY LOCALIZED PROSTATE CANCER**

A. Mortezaei, M. Baumgartner, T. Hermanns, T. Sulser, H. Seifert

**Background:** In the most representative series of laparoscopic radical prostatectomy (LRP) follow-up is not long enough to give a definitive oncologic evaluation of its surgical efficacy. We evaluated the intermediate- to long-term oncologic outcome in an initial series of LRP for clinically localized prostate cancer.

**Methods:** Between July 1999 and October 2001 100 consecutive patients with clinically localized prostate cancer (median age 64 y; range 46–76 y) underwent LRP performed by a single surgeon. Median PSA level was 7.27  $\mu\text{g/l}$  (range 0.39–62.1). 53 patients presented with clinically stage T1 disease and 69 patients had a Gleason sum of  $\leq 6$  on biopsy. Pelvic lymph node dissection was performed in 39 cases, unilateral or bilateral nerve sparing was performed in 42 and 20 patients, respectively. Progression of disease (PD) was defined as a PSA of  $\geq 0.1$  ng/ml with confirmatory rise.

**Results:** The rate of positive surgical margins was 16.5% and 40%, for pT2 and pT3 tumours, respectively. For Gleason  $\leq 6$  and  $> 6$  tumours positive margin rate was 18.5% and 32.6% respectively. Median follow-up was 92 months (range 39.6–114.2). In Patients reaching a PSA Nadir of  $< 0.1$  ng/ml after surgery PD occurred after a median time of 34.7 months (range 6.2–78.1). The overall 5-yr and 8-yr probability of freedom from progression (PFP) was 81.8% and 79.4%, respectively. For patients with pT2 and pT3 tumours the 8 year PFP was 83% and 79.4%, respectively. The 8 year PFP was 98.1% for patients with Gleason sum of  $\leq 6$  and 57.6% for Gleason sum of  $> 6$ .

**Conclusion:** Our Data show that LRP effectively controlled the disease in 79.4% of men with prostate cancer. Although the results presented are from a very initial series surgical margin status and oncologic results after follow-up up to 114 months seem to be favorable.

#### **O6-06 PROSPECTIVE RANDOMIZED TRIAL TO EVALUATE THE INFLUENCE OF THE BLADDER NECK SUSPENSION ON EARLY CONTINENCE AFTER RADICAL PROSTATECTOMY**

J. Stolzenburg, M. Nicolaus, M. Do, A. Dietel, E. Liatsikos

**Background:** The aim of this prospective randomized trial was to evaluate the influence of the bladder neck suspension (BNS) on early continence after endoscopic extraperitoneal radical prostatectomy (EERPE).

**Methods:** 170 consecutive patients with localized prostate cancer were included in this study. 90 patients underwent “wide excision” EERPE, 80 patients had a nerve sparing EERPE (nsEERPE). Half of each group had a standardized BNS using three sutures in a typical manner. The catheter was removed on the 5th p.o. day in all patients. Continence was evaluated by a pad test (24 hours) on the seventh p.o. day and a standardized questionnaire three months postoperatively.

**Results:** The pad test shows an average daily urine loss of 291.27 g (with BNS) versus 324.96 g (without BNS) in the group of “wide excision” EERPE ( $P < 0.78$ ), 74.70 g (with BNS) versus 68.23 g (without BNS) in the group of nsEERPE ( $P < 0.46$ ). Three months p.o. the mean number of daily used pads was 2.52 (with BNS) versus 1.91 (without BNS) in the “wide excision” EERPE group and 0.96 (with BNS) versus 0.85 (without BNS) in the group of nsEERPE group.

**Conclusion:** The present study shows no significant influence of the bladder neck suspension on early continence, neither after nerve sparing EERPE, nor after “wide excision” EERPE. There is a significantly better early continence in the group of nerve sparing patients, regardless of the bladder neck suspension.

#### **O6-07 PERI-CATHETER PAD USE IMMEDIATELY POST-OP AS A NOVEL PREDICTOR OF EARLY RETURN OF URINARY CONTINENCE AFTER ROBOTIC PROSTATECTOMY**

D. Lee, P. Cheetham, M. Truesdale, K. Badani—USA

**Background:** Immediate urinary incontinence after robotic prostatectomy (RALP) remains a significant concern. We sought to evaluate peri-catheter pad-use during the first week post-op as a novel predictor of early urinary continence after RALP.

**Methods:** A prospective analysis was performed in 96 consecutive men who underwent RALP by a single surgeon. Of these, 62 men had follow-up data on daily pad use with catheter in place for the first week post-operative. Catheters were removed one week after RALP, and pad-use was defined as number of pads soaked during 24 hours around the catheter. Continence was defined as men using zero pads per day.

**Results:** Overall, 57 (91.9%) of the men achieved continence, and forty-nine (51%) of the men achieved continence before six weeks. While catheter was in place, 35 (56.5%) used zero pads and 27 (43.5%) used 1 or more pads. Ninety-two percent of those who had zero peri-catheter pad-use were continent before six weeks, compared to 8.1% of men using 1 pad or more ( $p < 0.01$ ). The time to continence was significantly shorter for those who had zero peri-catheter pad-use versus those who used one pad or more ( $p < 0.01$ ). After adjusting for IPSS, age, and nerve sparing, peri-catheter pad-use independently predicted continence return at six weeks and at the last follow-up period (HR = 0.02, HR = 0.13, respectively,  $p < 0.01$ ).

**Conclusion:** Number of pads used during catheterization immediately post-op is an independent predictor of early return of urinary continence. This parameter represents a novel tool and could be used in counseling men on early expectations.

### 06-08 NEOADJUVANT ANDROGEN SUPPRESSION IN HIGH INTENSITY FOCUSED ULTRASOUND THERAPY FOR LOCALIZED PROSTATE CANCER

W. Kim, S. Jeon, J. Choi, H. Kim, B. Jeong, S. Seo

**Background:** To investigate the usefulness of neoadjuvant androgen suppression (NAS) in high intensity focused ultrasound (HIFU) therapy for the treatment of clinically localized prostate cancer.

**Methods:** A total of 88 patients underwent HIFU for the treatment of clinically localized prostate cancer. Among them, 51 (57.9%) had received NAS and 37 (42.1%) had not. We compared the overall HIFU failure free survival rates between two groups. And to know whether the prostate volume affects the effectiveness of NAS, we divided all the patients into two groups according to the prostate volume (Group A: 30 cc or more vs Group B: less than 30 cc), and compared the PSA failure rates, respectively. HIFU failure was defined as increase of 2 ng/ml or more above the PSA nadir and/or a positive biopsy and/or salvage therapy induction.

**Results:** The mean follow up period was 35.6 (7.2–58.7) months. There were no significant differences in the patient's mean age, mean serum PSA level and mean prostate volume between NAS group and non NAS group. Overall 3 year HIFU failure free survival rate was 62.1%. The 3 year HIFU failure free survival rate was significantly higher in NAS group (77.1% vs 54.0%) ( $p=0.038$ ). When we compared the treatment failure rates according to the prostate volume, there was no significant difference between NAS group and non NAS group in the small prostate volume patients (Group B). But in group A, NAS showed higher HIFU failure free survival rate than non NAS (71.4% vs 55.6%) ( $p=0.059$ ).

**Conclusion:** In this unrandomized comparison between NAS and non NAS before HIFU for clinically localized prostate cancer, NAS improved HIFU failure free survival rate significantly, especially in large prostate volume patients.

### 06-09 THE SECOND STEP IN VITRO TRIAL OF ANKA FERD BLOODSTOPPER: COMPARISON WITH THE OTHER HEMOSTATIC AGENTS, GLUBRAN 2, FLOSEAL AND CELOX

E. Huri, T. Akgül, O. Yucel, M. Astarci, H. Üstün, C. Germiyanoglu—Turkey

**Background:** We investigated the efficacy of Ankaferd compared with the other hemostatic agents (Glubran 2, Floseal and Celox).

**Methods:** Fourty Wistar rats; divided into five groups. Group T (traditional), partial nephrectomy (PN) with hilar control. Group G (Glubran 2), conventional PN followed application of Glubran 2, Group F (FloSeal), FloSeal application to excised area of kidney, Group C (Celox), Celox was applied, Group A (Ankaferd-ABS), Ankaferd, a novel hemostatic agent, was used. Warm ischemia time (WIT), hemostasis time (HT), were recorded. Histopathologic features were compared among the groups. Kruskal-Wallis and Mann-Whitney U tests were used for statistical analysis.

**Results:** WIT (sec) for GT, 150.4 (SD:10.2), GG, 43.3 (SD:1.7), GF, 52.1 (SD:1.7), GC, 66.6 (SD:2.2) and GA, 81.5 (SD:6.5), there were significant differences ( $p<0.001$ ). In GA, significant less

WIT was detected while the difference compared with the other groups was also significant ( $p<0.001$ ). HT, in GT, 140.1 (SD:10.2), GG, 32.9 (SD:1.2), GF, 40.9 (SD:1.1), GC, 55.8 (SD:1.8) and GA, 70.1 (SD:6.6) were detected with significant differences (95% CI) ( $p<0.001$ ). In GA, decreased HT was confirmed, compared with GT while increased HT detected compared with the other groups (GG, GC, GF) ( $p<0.001$ ). Fibrosis, adhesion and calcification were not demonstrated in GA compared with the other groups significantly ( $p<0.001$ ). Increased fibrosis and adhesion was shown in GF. Erythrocyte aggregation and microvascular proliferation were observed in GG,GF,GA significantly higher ( $p<0.001$ ).

**Conclusion:** A novel hemostatic agent, ABS, as effective as the other licenced hemostatic agents with comparable WIT and HT and better results of histopathologic findings.

### 06-10 NEPHROSTOMY FOR MALIGNANT URINARY TRACT OBSTRUCTION. IS IT WORTH IT?

R. Jordan, H. Mohd Tarmidzi, S. Mohan, K. Subramonian—UK

**Background:** Percutaneous Nephrostomy (PCN) is performed for patients with hydronephrosis and acute kidney injury (AKI) following urinary obstruction to provide temporary or permanent drainage of an obstructed urinary system. Malignancy of the Urinary tract or surrounding structures could present with urinary tract obstruction. We studied the various causes of malignant obstruction, their recovery of renal function and disease specific survival after treatment with PCN.

**Methods:** A retrospective study was undertaken of all patients who underwent PCN between April 2005 and December 2008. A total of 477 procedures were performed during this time period. After excluding failed PCN insertions, re-insertions and ureteric stent insertions, there were a total of 362 procedures. Patients presenting with malignant cause of obstruction were identified and data collected on the patient's baseline creatinine, recovery following PCN at day 1, day 2, day 3, day 4 and finally at plateau and disease specific survival.

**Results:** There were a total of 159 patients (52%) in the malignant group who had a total of 191 procedures. The top three indications for PCN were bladder (29.6%), prostate (26.4%) and gynaecological (11.3%) cancers. At presentation, the average decline in eGFR from baseline was 54.3%. Following PCN, the eGFR recovered to a plateau of 81.7% of the baseline and it took an average of 24.8 days. Patients were followed up over a range of 2.6 to 3.8 years and as of February 2009, there were 59 deaths (37%) during the follow up period. The disease specific mortality was 30% for Prostate, 22% for bladder and 35% for gynaecological cancers and these 3 cancers contributed to 59.3% of deaths. The average survival for patients who died during this period were 5.34 months for bladder cancer, 6.89 months for the gynaecological malignancies and 8.84 months for prostate cancer.

**Conclusion:** Amongst patients presenting with urinary tract obstruction, malignancy contributes a significant proportion with prostate, bladder and Gynaecological cancers forming the majority. Following treatment with PCN, the renal function returned almost to baseline levels within 4 weeks. However, the mortality rate in this cohort of patients is quite high and the average duration of survival in those patients who died during follow up is very short. It is important to counsel these patients about the poor prognosis.

## VP1: LAPAROSCOPY—KIDNEY 1

### VP1-01 LAPAROSCOPIC PARTIAL NEPHRECTOMY FOR RENAL TUMORS GREATER THAN 4CM: A COMPARATIVE STUDY

D. Lifshitz, S. Shikanov, T. Deklaj, M. Katz, K. Zorn, A. Shalhav

**Background:** The indications for Laparoscopic partial nephrectomy (LPN) continue to expand. We compared the outcomes of patients who had elective laparoscopic partial nephrectomy (LPN) for renal tumors >4 cm to those operated for renal tumors <4 cm

**Methods:** Data was retrieved from a prospective data base of 184 patients who underwent LPN for a renal tumor. Patients were stratified into two groups: 149 (81%) patients with tumors ≤4 cm (Group 1) and 35 patients (19%) with tumors >4 cm (Group 2). A comparison was made between all perioperative and postoperative outcomes.

**Results:** Groups 1 and 2 did not differ in WIT, estimated blood loss, operative time, conversion rate, intraoperative complications rate and hospital stay. The incidence of postoperative complications in Group 2 was higher (25.7% vs 12%) (p=0.04). Clinical staging correlated with the pathological staging in 96% of the patients in Group 1 and only in 71% in Group 2 (p<0.001). Upstaging to pT2 or pT3 occurred in 29% of the patients in Group 2. High-grade tumors were more prevalent in group 2 (36% vs 12%) (p=0.001). The proportion of positive margin was higher in Group 2. With a median follow up of 18 months no local or distant recurrences were noted. The mean decline in estimated creatinine clearance was significantly higher in Group 2.

**Conclusion:** LPN for tumors >4 cm, while safe and feasible in experienced hands, is associated with a higher postoperative complication rate, as well as a higher rate of pathologic upstaging. Longer followup is required to assess the oncologic outcome.

### VP1-02 LAPAROSCOPIC CRYOABLATION OF SMALL RENAL MASSES

K. Sahadevan, J. Dominguez, P. Mehrotra, R. Marsh, P. Johnson

**Background:** We report the functional and oncological outcomes of our initial experience on 22 consecutive renal LCA cases.

**Methods:** All procedures were performed by a single surgeon, under a strict departmental protocol. Our protocol includes 2 Freeze-Thaw cycles, extension of ice-ball at least 5 mm beyond the tumour under laparoscopic USS guidance. Patients were followed with serum creatinine and CT scans at 3, 6, 12, 18 and 24 months and yearly thereafter.

**Results:** There were 22 patients with mean (range) age of 69 (53–80) years. The average (range) tumour size was 2.9 (1.5–4.5) cm. Blood loss was minimal and the average (range) operating time was 166 (120–224) minutes. The median (range) number of cryoneedles used was 5 (range3–6). Histology demonstrated renal cell carcinoma in 17, oncocytoma in 2, urothelial carcinoma in 1, normal parenchyma in 3 and necrotic tissue only in one patient. Complications include a blood transfusion, embolisation of an arterio-venous fistula and pneumonia. The average hospital stay was 4 (2–14) days. No clinically significant difference in renal function was noted. There were 20 patients who have had CT follow-up at a mean (range) of 17 (3–37) months. There was no

enhancement noted in 16 tumours and 4 tumours showed enhancement.

**Conclusion:** Laparoscopic cryoablation is a safe treatment option for small renal masses in a selective group of patient. Furthermore, although the follow-up is limited, results from this cohort, supported by similar findings in larger published series with longer follow-up, demonstrate the oncological safety of this minimally invasive technique.

### VP1-03 TUMOR IN SOLITARY KIDNEY: LAPAROSCOPIC PARTIAL NEPHRECTOMY VERSUS LAPAROSCOPIC CRYOABLATION

G. Haber, S. Crouzet, M. Lee, K. Kamoi, J. Kaouk, G. Inderbir—USA

**Background:** We compare perioperative, functional and oncological outcomes of laparoscopic partial nephrectomy (LPN) versus laparoscopic cryoablation (LCA) for small renal tumor in patients with a solitary kidney.

**Methods:** Between 2/1998 and 9/2008, 48 patients underwent LPN and 30 patients underwent LCA for small renal tumor in a functionally solitary kidney. Baseline, perioperative and follow-up data were collected prospectively with retrospective data analysis.

**Results:** Comparisons between LPN and LCA groups are demonstrated. There were no significant differences between the LPN and LCA group with respect to mean patient age, BMI, and Charlson Comorbidity Index. LPN was associated with larger tumor size, greater estimated blood loss, and intraoperative and postoperative complications. Overall renal function represented by serum creatinine and estimated GFR was significantly more compromised in the LPN group (p=0.04 and 0.02 respectively). Overall survival was not significant (p=0.74) though cancer-specific and recurrence-free survival was significantly higher in the LPN group (p=0.03 and 0.05 respectively).

**Conclusion:** Both LPN and LCA are viable nephron-sparing options for patients with a solitary kidney. LCA is technically easier and has superior functional outcomes. However, LPN has superior oncological outcomes.

### VP1-04 PREDICTING FACTOR FOR RENAL FUNCTION DECREASE AFTER LAPAROSCOPIC PARTIAL NEPHRECTOMY

K. Kamoi, S. Crouzet, G. Haber, A. Kawauchi, T. Miki, I. Gill—Japan

**Background:** Renal function after laparoscopic partial nephrectomy (LPN) is a major concern. Herein, we studied the predictive factors of postoperative renal function after LPN.

**Methods:** A total of 953 patients underwent a LPN between September 1999 and September 2008. Demographic, operative indication, intra-operative, peri-operative, and renal functional follow-up data were collected prospectively. We used uni and multivariate analysis with logistic fit regression model for each data to identify predicting factors of post operative percent change in eGFR at the highest postoperative values between 1 to 24 months after surgery.

**Results:** The mean nadir eGFR was reached at postoperative day 1 and the plateau at 6 month. Three factors appear to be significant predictor for the post-operative percent eGFR decrease >20, >25 and >30 points: the imperative surgical indications, the warm ischemia time and a tumor size ( $p \leq 0.01$  for all). Sex, ASA score, Carlson Comorbidities Index, patient with a solitary kidney, coronary artery disease or hypertension also influence the post operative eGFR change in the univariate analysis but did not reach statistical significance on the multivariate analysis. With ROC curve analysis to predict >30% decrease in plateau eGFR, warm ischemia time >30 min and a tumor size >2.0 cm were the optimal threshold value.

**Conclusion:** Pre-operative imperative surgical indication, warm ischemia time and the tumor size are the most predictive factors of post-operative eGFR decrease after LPN.

### VP1-05 SEALED BLADDER CUFF TECHNIQUE DURING LAPAROSCOPIC NEPHROURETERECTOMY UTILIZING THE LIGASURE™ ELECTROSURGICAL DEVICE: LABORATORY AND CLINICAL EXPERIENCE

S. Herrell, E. Lambert, H. Altamar, L. Schacter, G. Moeckel, N. Miller

**Background:** Laparoscopic nephroureterectomy (LNU) is a safe, minimally invasive approach for management of upper tract urothelial tumors. Controversy exists over the optimal technique for the distal ureter and bladder cuff excision. We examined the novel technique of using the LigaSure™ bipolar electrosurgical device in laboratory investigations and during clinical LNU to manage the distal ureter and bladder cuff.

**Methods:** Initial investigations were undertaken in the porcine model. Areas of both normal porcine ureters and bladders, and ex vivo human ureters from radical nephrectomy specimens were sealed with the LigaSure™ and stained with NADH and Hematoxylin and Eosin to examine the length of treatment effect and the viability of the ablated tissue. Clinically, we performed 22 LNU for proximal urothelial tumors using the LigaSure™ for the management of the distal ureter and bladder cuff. Intraoperative cystoscopy assessed cuff resection and bladder leakage. On postoperative day 10, a cystogram was performed.

**Results:** In the porcine model, the technique sealed the bladder effectively with a mean burst pressure of 14 mmHg. Cellular staining revealed no viable urothelial tissue in the seal area and an additional 2 mm outside this area. 18 patients had a successful seal/ablation intraoperatively. Cystoscopy revealed cautery artifact and blanching over the former position of the ureteral orifice.

**Conclusion:** The LigaSure™ device ablates and seals urothelial tissue with no viable cells in the clamped and adjacent blanched tissue. Our technique is technically feasible, removes an adequate bladder cuff, typically maintains a closed urinary system, and adheres to sound oncological principles. This procedure could be performed in both laparoscopic and open NU for proximal upper tract transitional cell tumors.

### VP1-06 LAPAROSCOPIC PARTIAL NEPHRECTOMY AT BOSTON MEDICAL CENTER: A SINGLE SURGEON'S EXPERIENCE AND OUTCOMES

R. Dickstein, S. Ganick, M. Geltzeiler, R. Babayan, D. Wang—USA

**Background:** Nephron sparing surgery is now the standard of care for small renal masses suspicious for renal cell carcinoma (RCC). Since the first laparoscopic partial nephrectomy (LPN) was de-

scribed, utilization of this operation has expanded in only a limited way. We intend to describe our experience with LPN for patients at Boston Medical Center (BMC).

**Methods:** A retrospective chart review was performed on all LPN's performed at BMC by a single surgeon (DSW) from March 2004 to June 2008. Significant pre-operative patient characteristics, peri- and post-operative outcomes, and tumor characteristics were all recorded. A qualitative data analysis was performed.

**Results:** Eighty-four LPN's were performed, 35 utilizing a pure-laparoscopic technique and 49 a hand port. The average patient age was 55.4 years old (range 22–84). Sixty-nine (82.1%) of the excised masses were malignant (48 clear cell RCC, 15 papillary, and 6 chromophobe) and fifteen (17.9%) were benign (6 cysts, 4 angiolipomas, 3 oncocytomas, and 2 metanephric adenomas). The average tumor size radiographically was 2.8 cm (range 1.0–4.5) and pathologically was 2.6 cm (range 0.7–5.5). Sixty-three tumors were exophytic, nineteen endophytic, and two hilar. Ten of the tumors abutted collecting system. The surgical margins were clear of tumor in all but six cases. Median estimated blood loss was 257 mL's (range 50–3000) and the average warm ischemia time was 30.5 minutes (range 20–46). The average length of stay was 2.9 days (range 2–15). Two patients required blood transfusion and one had a delayed urine leak that healed spontaneously. There was one conversion to open surgery. Fourteen patients were readmitted after discharge: four with pseudoaneurysms, three with peri-renal hematoma, two with gross hematuria, one with a peri-renal abscess, one with a wound infection, and three for other causes (ileus, pneumonia, and pain).

**Conclusion:** We have demonstrated the feasibility of LPN at our institution, including tumors of larger size and difficult location. With further analyses we hope to demonstrate improved outcomes with operative experience over time.

### VP1-07 IS THERE A SELECTION BIAS BETWEEN SURGEONS IN CHOOSING LAPAROSCOPIC NEPHRON-SPARING SURGERIES FOR SMALL RENAL MASSES?

R. Bhavsar, N. Hamilton, T. Yoost, H. Clarke, J. Picard, S. Savage—United States

**Background:** Laparoscopic renal cryoablation (LRC) and laparoscopic partial nephrectomy (LPN) are viable therapeutic options for small renal tumors. We sought to determine if a surgeon selection bias exists in choosing the type of surgery.

**Methods:** We reviewed our cases from 3/03–5/09. We examined pre-operative, intraoperative and post-operative parameters between the two groups in order to detect significant differences. Additionally, we reviewed the operative surgeons and the urologists who had initially seen the patients.

**Results:** There were 97 patients for review treat by 3 surgeons. Sixty-eight underwent LRC and 29 underwent LPN. The average age and median ASA score for the LRC and LPN groups were 67 & 55 and 3 & 2, respectively ( $p < 0.0001$ ). Mean tumor size was 3.07 cm for LRC and 2.28 cm for LPN ( $p < 0.22$ ). There were no significant perioperative differences. Two patients after LPN and 9 after LRC failed initial treatment. Of the nephron-sparing surgeries done by surgeon 1, 28 (38%) were LPN and 46 (62%) were LPC. Surgeon 2 performed 1 (33%) LPN and 2 (67%) LPC. Surgeon 3 performed 19 (100%) LPC. Of patients seen first by surgeon 3 and 2 other surgeons, 100% went on to LPC. 41% seen by surgeon 1 had LPN, 59% had LPC. Of pt's seen by surgeon 2, 33% had LPN, 67% had LPC. A third referring urologist had 31% LPN and 69% LPC, mirroring the numbers for surgeon 1.

**Conclusion:** Despite excellent results in LPN, there appears to be a surgeon selection bias. Preoperative tumor board discussion was instituted to address this potential.

### VP1-08 LAPAROSCOPIC PARITAL NEPHRECTOMY WITH SEGMENTAL RENAL ARTERY CLAMPING

Y. Changjun

**Background:** Laparoscopic partial nephrectomy is indicated in T1a kidney tumor. The common procedure is performed through clamping the main renal artery with the warm ischemic time limited in 30 min. We study the feasibility of laparoscopic parital nephrectomy with segmental renal artery clamping for T1a–T1b kidney carcinoma and evaluate its outcomes.

**Methods:** A total of 7 cases (4 male and 3 female) of renal carcinoma were admitted to our department from January 2008 to May 2009. The mean age was 44.2 yrs (37~58 yrs). All the patients received examination of ultrasonography and contrasted CT scan before operation. Among the 7 cases of tumor, 5 cases were in left side and 2 cases in right with the mean diameter 4.3 cm (3.6–5.5 cm). The tumor located in apical pole in 2 cases and 5 cases in inferior pole. The patients were given general anesthesia and placed in flank position. Four ports were introduced in lumbar area and retroperitoneal approach was employed. The main renal artery was exposed and further dissection was performed to visualize the segmental artery. The tumor was fully exposed through isolating the kidney along of the renal capsule. The feeding branch could be determined by observation of bloodless field under laparoscopy after clamping one of the branch with the bulldog. The outline of incision was made using electrocautery before clamping the branch. The parenchyma was incised with cold scissor keeping 0.5–1 cm distance to the tumor capsule. The calices were closed with 3–0 Vicry suture and renal parenchymal was reconstructed by suturing with 2–0 Vicry in running manner. The tumor was retrieved through a small incision.

**Results:** 5 cases were performed successfully with no open conversion. 2 cases were converted to conventional method by clamping the renal artery laparoscopically because of undetermined of feeding branch. The mean operative time was 85 min (60–125 min). The ischemic time after clamping of the artery was 24 min (19~43 min) and the blood loss 150 ml (50–350 ml). The margins were negative in all cases and pathologic studies revealed 2 cases in T1a and 5 cases in T1b. Complications included 4 cases of mild hematuria postoperation. No bleeding and urine leakage occurred postoperative.

**Conclusion:** Laparoscopic parital nephrectomy with segmental renal artery clamping is feasible in selected cases with kidney tumor. The influence on renal function caused by warm ischemia damage is minimized significantly by the procedure comparing to conventional method. The procedure is technically challenging and the long term outcome is awaited.

### VP1-09 HEMOSTASIS BY USING THE ARGON BEAM COAGULATION (ABC) WITHOUT CLAMPING RENAL ARTERY IS SUFFICIENT IN SOLITARY PERIPHERAL T1A RENAL TUMORS TREATED WITH LAPAROSCOPIC NEPHRON SPARING SURGERY (NSS)

O. Sanli, T. Mut, T. Tefik, M. Ortac, F. Ozcan, & Nane—Turkey

**Background:** NSS is currently the mainstay treatment for small T1a peripheral renal tumors. However, either it's performed open or laparoscopic hemorrhage is the main problem for morbidity.

The aim of this preliminary report is to evaluate the role of argon beam hemostasis during laparoscopic NSS.

**Methods:** Between February 2008 and June 2009, 11 patients diagnosed with small peripheral tumors were treated with laparoscopic NSS by using ABC without clamping renal artery. The ABC was used at standard settings (130–140 W, and an argon gas flow rate between 4–10 L/min). Baseline patient characteristics, intraoperative and postoperative parameters were evaluated from a prospectively collected database.

**Results:** The mean age of the patients (6 female, 5 male) was  $47.3 \pm 13.6$  years. The mean tumor diameter was  $4.0 \pm 2.9$  cm. Overall, tumors were localized in upper pole, middle zone, and lower pole in 7, 2 and 2 patients, respectively. They were accessed transperitoneally or retroperitoneally in 5 and 6 cases, respectively. The mean operative time was  $135 \pm 54$  min, and mean intraoperative blood loss was  $189.0 \pm 127.7$  ml; whereas, the mean Hb drop was  $1.7 \pm 1$  mg/dl. Only in one of the procedures the renal artery was needed to be clamped and in the same case open hemostasis had to be performed (tumor diameter 5.5 cm) due to hemorrhage in the next day of the operation. In neither of cases, hemostatic agents or sutures needed to be used.

**Conclusion:** According to our preliminary report, hemostasis with ABC is a safe procedure for solitary, peripheral, small renal tumors. However, we do not advocate the use of ABC in tumors larger than T1a lesions.

### VP1-10 RUNNING SUTURE DURING LPN: WHICH ARE THE ADVANTAGES? RESULTS OF A COMPARATIVE STUDY

F. Porpiglia, C. Fiori, R. Bertolo, S. Grande, I. Morra, R. Scarpa

**Background:** To confront two techniques of renal parenchyma reconstruction during laparoscopic partial nephrectomy (LPN).

**Methods:** The retrospective study included consecutive patients who underwent LPN from 3/2005 to 5/2009 at our Institution. Patients were divided into two Groups: group A, including patients where an interrupted suture has been made and Group B, where a running one has been used. Demographic and perioperative data were collected and analyzed. Statistical analysis was made by a statistical software using Student t-test and Chi-square test (a p-value smaller than 0.05 was considered statistically significant).

**Results:** A total of 86 LPN procedures were included in this study: 43 patients in Group A and 43 patients in Group B. Patients in the Groups were comparable about age, sex, TC scan size, intraoperative complications rate, length of hospital stay and pathological size and weight of lesions. Mean warm ischemia time (24.84 in Group A vs. 20.39 in Group B), blood loss (232 vs. 160.33) and rate of post-operative complications (11/43, 25.6% vs. 3/43, 7.0%) were statistically significantly different between Groups. Finally, in elective procedures for malignant tumors, positive surgical margins rate was not significantly different ( $p > 0.05$ ).

**Conclusion:** Data of our study suggest that running suture plays a key role after renal tumor resection during LPN and in our opinion this is the best way to reconstruct the renal parenchyma.

### VP1-11 “NO CLAMP NO SUTURE” LAPAROSCOPIC PARTIAL NEPHRECTOMY FOR SMALL EXOPHYTIC RENAL TUMORS

G. Simone, M. Ferriero, R. Papalia, S. Guaglianone, E. Forastiere, M. Gallucci

**Background:** We report the mid-term oncologic and functional results of a series of 85 patients treated with “no clamp - no suture” laparoscopic partial nephrectomy (LPN).

**Methods:** Between August 2003 and January 2009, 85 patients with small exophytic renal tumor underwent LPN. Mean patients age was 58 years (range 45 to 70), mean tumor size was 2.6 cm (range 1.8 to 4.0 cm) and median intraparenchymal depth on preoperative CT was 0.8 cm (range 0.5 to 1.4 cm). Hilum vessels were not clamped and were not isolated. The renal parenchyma was incised with a monopolar scissor just some mm below the renal tumor and the dissection plane was found using the 10 mm Ligasure. Once identified the cleavage plane, the Ligasure allowed to minimize the intraoperative bleeding and to reduce the time for PN. The hemostasis of the surgical bed was completed with the Ligasure or with the monopolar coagulation and than using a bolster of Surgicel, Tachosil or Tabotamp alternatively. In most cases, the Gerota’s fascia was closed with a running suture and a drain was placed into the perinephric tissue close to renal bed. Renal function was evaluated by preoperative, 3 and 12 month postoperative 99mTc DTPA renal scans.

**Results:** Mean operative time was 62 minutes (range 45 to 160) and mean blood loss was 90 ml (range 20 to 240). No conversion to open surgery occurred, in four patients at the end of the procedure a suture was necessary to complete the hemostasis of the surgical bed. Mean hospital stay was 3.1 days (range 2 to 5). Pathologic analyses found benign tumors in 22 patients and renal cell carcinoma in 63 cases (61 pT1a, 2 pT1b). Surgical margins were negative in all patients. At a median follow-up of 45 months CT scan revealed 1 local recurrence in a patient with pT1b tumor who underwent subsequent radical nephrectomy. Three month and 1-yr postoperative median decreases of GFR in the treated kidney was 3% (range 0 to 9%) and 1% (range 0 to 5), respectively.

**Conclusion:** Avoiding hilar clamp and surgical bed suture is feasible in most cases of small peripheral renal tumors. The hemostasis of the surgical bed can be accomplished by combining the use of the 10 mm Ligasure, monopolar coagulation and haemostatic agents. LPN with “no clamp - no suture” technique guarantees optimal functional outcome without impairing oncologic result.

#### VP1-12 LAPAROSCOPIC RADICAL NEPHRECTOMY: SINGLE CENTRE EXPERIENCE IN 128 CASES

R. Regensburg, A. Kooistra, P. Dom

**Background:** Laparoscopic nephrectomy has become an established surgical procedure for renal tumors. We present our own experience performing transperitoneal laparoscopic radical nephrectomy.

**Methods:** We reviewed 128 consecutive patients who underwent transperitoneal laparoscopic radical nephrectomy (LRN) for solid lesions between January 2001 and December 2008.

**Results:** Mean age was 62 years (32–86), mean tumor size: 56 mm (15–130). Eighty patients were male (64%). LRN was successful in 125 patients (98%): 3 (2.4%) underwent conversion (bleeding). Major complications (2.4%): leakage from a malignant cyst (1), sepsis (1), bleeding after restart anticoagulation therapy (1). Minor complications occurred in 13 patients (10.1%). Mean blood loss was 148 ml (10–1700); operation time: 206 minutes (62–469); hospitalization time: 4.8 days (2–21). Pathology showed renal cell carcinoma (109): oncocytoma (13); angiomyolipoma (1); transitional cell carcinoma (1) and a hemorrhagic cyst (1). For statistical analysis we compared the first 63 patients with the second group of 62 patients.

There were no significant differences found between the two groups, except for operation time (241 minutes versus 173 minutes,  $p < 0.01$ ). Overall operation time correlated with blood loss ( $p < 0.01$ ) and was strongly dependent on tumor size ( $p < 0.01$ ).

**Conclusion:** Experienced laparoscopic surgeons can safely perform laparoscopic radical nephrectomy. The operation time is strongly dependent on tumor size. Considering the learning curve operation time declines, although the mean time for the transperitoneal radical nephrectomy is still about 3 hours even after more than 100 procedures.

#### VP1-13 LAPAROSCOPIC PARTIAL NEPHRECTOMY: A SINGLE CENTER EVOLVING EXPERIENCE

D. Lifshitz, S. Shikanov, T. Deklaj, M. Katz, K. Zorn, A. Shalhav

**Background:** The indications and surgical technique of laparoscopic partial nephrectomy (LPN) continuously evolve. We review our LPN experience, examine the evolution of technique, and compare the outcomes between the early and recent experience.

**Methods:** Data for 184 patients who underwent LPN for a renal tumor between 10/2002 and 8/2008 was retrieved from a prospective database. Surgical and functional outcomes for the entire cohort were analyzed and a comparison between the first (Group 1) and most recent (Group 2) 50 cases was preformed.

**Results:** The groups were similar in terms of baseline renal function, BMI and co-morbidities. The mean tumor size and the proportion of central tumors in Group 1 and 2 were 2.4 vs 3 cm and 12% vs 52%, respectively ( $p < 0.003$ ). In Group 2 we stopped the use of ureteral catheters and bolster renorrhaphy, and routinely clamped the renal hilum. Mean warm ischemia time in Group 1 and 2 (30 and 27 min, respectively  $p = 0.3$ ) and the complication rate were similar. Despite the inclusion of more challenging cases in Group 2, surgery time was similar and the EBL and hospital stay decreased (243 vs 140 ml,  $p = 0.01$ , 1.4 versus 2.5 days,  $p < 0.001$ ). Overall 78% of the tumors were malignant and the positive margin rate was 3%. With a median follow-up of 18 months, no local or distant tumor recurrences were observed.

**Conclusion:** With growing experience and technical modifications, LPN is now performed for patients with larger and more central tumors. Longer follow-up is necessary to evaluate oncologic outcomes.

#### VP1-14 OPEN VERSUS LAPAROSCOPIC PARTIAL NEPHRECTOMY FOR HILAR TUMORS

D. Snow, G. Haber, K. Kamoi, M. Lee, S. Crouzet, I. Gill—USA

**Background:** Hilar tumors are defined as those located in the renal hilum and demonstrated to be in actual physical contact with the renal artery and/or renal vein on preoperative 3D CT. Partial nephrectomy for hilar renal tumors remains a technical challenge for even experienced urologic surgeons. While open partial nephrectomy (OPN) has been the reference standard for nephron sparing surgery (NSS) for hilar tumors laparoscopic partial nephrectomy (LPN) is a more recent development. We compared perioperative outcomes of OPN and LPN for hilar tumors.

**Methods:** Between 01/2006 and 08/2008, 89 patients underwent OPN and 38 patients underwent LPN for hilar tumor. Baseline, perioperative, and follow-up data were collected prospectively. Data analysis was retrospective.

**Results:** OPN LPN P value % Male 66%63% 0.7 Average BMI (kg/m<sup>2</sup>) 30 28 0.09 ASA score 2.5 2.4 0.9 Average tumor size (cm) 4.33.7 0.06% with imperative indication for NSS 48% 29% 0.07 Average

operative time (hrs) 3.95 4.08 0.7 Average estimated blood loss (mL) 508 338 0.3% with intra-operative complications 5.6% 2.6% 0.4% with pleural injuries 17% 0% 0.01 Average warm ischemia time (min) 21 19 0.3 Average % of kidney spared 68% 76% 0.7 Average length of time to discharge (days) 6 5 0.3% re-visit to ER in 30 days 3% 3% 0.8% with urologic postoperative complications 6% 8% 0.7% non-urologic postoperative complications 15% 16% 0.7 Average baseline serum Cr (mg/dL) 1.2 1 0.04 Average baseline eGFR (mL/min/1.73 m<sup>2</sup>) 54 78 0.03 Average % change in GFR at last follow up 26% 6% 0.01 % with RCC on pathology 67% 71% 0.6 % with positive margins 3.4% 2.6% 0.51

**Conclusion:** Hilar tumors represent a higher level of technical challenge during partial nephrectomy. In experienced hands OPN and LPN deliver comparable outcomes in these settings. These data further advance the applicability of laparoscopic partial nephrectomy.

### VP1-15 LAPAROSCOPIC MANAGEMENT OF STAGE- T3B RENAL CELL CARCINOMA

M. Chiruvella

**Background:** Radical nephrectomy is the gold standard in management of renal cell carcinoma. Tumour thrombus in renal vein or inferior vena cava carries a similar prognosis as localised disease. This necessitates surgical removal in all these cases. Advent of laparoscopy in the recent years has revolutionised the management. Though laparoscopic radical/partial nephrectomies are frequently done, management of T3b disease laparoscopically has been a challenging task. We present our experience in the situation.

**Methods:** Seven patients aged between 39 to 62 yrs presented to us with T3b disease in the last 3 years. Male to Female ratio was 5:2. Two patients underwent open surgical intervention in view of large tumour bulk. Rest of the 5 underwent laparoscopic radical nephrectomy. Three of them had extension of tumour thrombus into renal vein (right-1, left-2) and two had into inferior vena cava (right-2). Feasibility of clamping IVC proximal to thrombus and distally was assessed by a preoperative CT and intra-operative findings. All of them underwent transperitoneal radical nephrectomy with 6–7 ports. IVC control was achieved by satinsky clamps placed proximally and distally through separate ports. Cavotomy was done, thrombus milked away and cava closed with 3–0 silk.

**Results:** Procedure took 180 to 200 minutes. Blood loss was around 500 ml. Loss was mostly from the parasitic veins all around the kidney. Post operative recovery was smooth in both the patients. Preoperative CT scan aids in assessing the feasibility of clamping the IVC proximally during laparoscopic surgery. Ability to the clamp is the key factor in the surgery.

**Conclusion:** Laparoscopic radical nephrectomy in T3b renal cell carcinoma is a feasible alternative. Proper selection of the case by preoperative CT scan and intra-operative findings is mandatory. Refined skills in laparoscopic surgery are essential for a successful outcome.

### VP1-16 LAPAROENDOSCOPIC SINGLE-SITE RADICAL NEPHRECTOMY FOR LOCALIZED RENAL CELL CARCINOMA: COMPARISON WITH CONVENTIONAL LAPAROSCOPIC SURGERY

Y. Park, S. Lee, J. Ku, H. Jeong, C. Kwak, H. Kim

**Background:** To compare the technical feasibility of laparoendoscopic single-site (LESS) and conventional laparoscopic radical nephrectomy for localized renal cell carcinoma (RCC).

**Methods:** This study was designed as a matched case-controlled study from a RCC database of our hospital. Nine consecutive pa-

tients undergoing LESS radical nephrectomy were compared with 18 patients undergoing conventional laparoscopic radical nephrectomy. Controls were matched for age, gender, side of operation, and mass size via a statistically generated selection of all laparoscopic radical nephrectomies.

**Results:** Mean operative time in the LESS group was 219 (160–335) min compared with 173 (125–205) min in the open group ( $p=0.028$ ). There were no significant differences in mean blood loss (158.9 min versus 161.1,  $p=0.794$ ), and complication rate (22.2 versus 11.1%,  $p=0.582$ ) between the LESS and conventional laparoscopic group. However, Postoperative hospital stay after LESS radical nephrectomy was 2.7 (2–4) days, compared with 3.9 (3–7) days in the open group ( $p=0.002$ ). Postoperative pain, as measured by visual analogue scale at postoperative day 1 (4.9 versus 5.8 points,  $p=0.026$ ), 2 (3.1 versus 4.7 points,  $p=0.001$ ), and 3 (2.8 versus 4.2 points,  $p=0.009$ ), was significantly lower in the LESS group.

**Conclusion:** LESS radical nephrectomy is a feasible and safe surgical option for localized RCC demonstrating additional benefits of decreased postoperative pain and decreased hospital stay.

### VP1-17 SURGICAL MARGINS AFTER LAPAROSCOPIC PARTIAL NEPHRECTOMY: EXPERIENCE OF A SINGLE SURGEON

F. Porpiglia, C. Fiori, R. Bertolo, I. Morra, S. Grande, R. Scarpa

**Background:** The aim of this study is to evaluate the status of surgical margins after laparoscopic partial nephrectomy (LPN) during the learning curve of a single surgeon.

**Methods:** One hundred thirty-four surgical specimen were reviewed three group were created: Group A surgical specimen from LPN #1 to #45, Group B from LPN #46 to #90 and group C from LPN #91 to #134. Groups were compared according the following variables: lesion size at CT scan, pathological size, staging according to TNM, minimum and maximum resection margins, difference between minimum and maximum resection margin, rate of positive surgical margins (SM+).

**Results:** Groups were comparable in terms of CT and pathological size, 89 lesions were malignant and 45 benign. We found statistically significant difference among the groups neither in rate of malignant lesions nor in distribution of TNM staging. Minimum and maximum resection, and average rim of healthy tissue excised were significantly lower in the group C with respect to groups A and B. On the contrary no differences were found as far as the difference between minimum and maximum resection margin is concerned. There was no statistically significant difference in terms of +SM rate among the Groups, with an overall rate of 2.2% (3/134) of positive. No +SM were recorded in the group C.

**Conclusion:** With the increase of surgeon experience, there is a significant decrease of the amount of healthy parenchyma excised during LPN but this does not compromise the oncological results of the procedure.

### VP1-18 LAPAROSCOPIC NEPHRONE-SPARING SURGERY: PERI-OPERATIVE RESULTS IN RELATION TO TUMOUR SIZE

F. Porpiglia, C. Fiori, R. Bertolo, R. Scarpa

**Background:** To analyse, through the experience of our laparoscopic centre, morbidity of laparoscopic nephron-sparing surgery (lap-NSS) in relation to tumour size.



**Methods:** The study included patients who underwent lap-NSS performed by the same surgeon (F.P.) since 2001. Patients were divided into two Groups, according to the size of the renal lesions at the pre-operative abdominal computed tomography (CT-scan size) (Group A when  $<4$  cm, Group B when  $>4$ ,  $<7$  cm,  $p < 0.0001$ ). Age, sex, pathological tumour size, rate of positive surgical margins (%SM+), were collected and analysed. Operative time, warm ischemia time, blood loss, medical and surgical complication rates and length of Hospital stay were specifically recorded for the purpose of this study. Groups were compared by using Student t test.

**Results:** 150 lap-NSS procedures were included in this study: 119 patients treated for lesions below 4 cm and 31 for larger lesions till 7 centimetres. Pathological diameter was significantly higher in Group B ( $p < 0.0001$ ) as CT-scan size. Mean operative time, intra-operative complications rate and length of hospital stay were comparable between the Groups; mean warm ischemia time was statistically shorter for smaller lesions ( $p = 0.047$ ), mean operative time ( $p = 0.034$ ) and blood loss ( $p = 0.018$ ) were significantly increased in Group B. Post-operative complications rate was lower in Group A (16.8% vs. 29.0%) but not statistically different. Finally, in elective procedures for malignant tumours, %SM+ was not significantly different between Groups. A death was registered in Group B, related to infectious pulmonary causes.

**Conclusion:** Good cancer control and outcomes can be achieved with lap-NSS in carefully selected patients with tumours  $>4$  cm. Expanding the indication for lap-NSS results in an increased but acceptable morbidity.

#### VP1-19 RETROSPECTIVE COMPARISON OF THE LONG-TERM RESULT OF RETROPERITONEOSCOPIC VERSUS OPEN NEPHROURETERECTOMY FOR UPPER URINARY TRACT TRANSITIONAL CELL CARCINOMA

W. Xiaoqing

**Background:** We compared the long-term clinical outcomes of retroperitoneoscopic and adical nephroureterectomy for upper urinary tract transitional cell carcinoma.

**Methods:** Clinical data on 48 patients who underwent retroperitoneoscopic nephroureterectomy were retrospectively compared with those on 54 who underwent open nephroureterectomy for upper urinary tract transitional cell carcinoma, including patient demographic data, perioperative indexes, intraoperative indexes and long-term clinical outcomes.

**Results:** There were no significant difference in age, sex, side and the tumor stage in the two groups. There is no significant difference in the operative time, but the intraoperative estimated blood loss and postoperative hospital stay in the retroperitoneoscopic group showed significant advantages. The median follow-up period was 26.4 months (range 15 to 48). The overall survival rate and disease special survival rate in the retroperitoneoscopic group was 79.17% and 91.67% respectively. In the open group, the overall survival

rate and disease special survival rate was 85.18% and 94.44%, there is no difference between the two groups. The recurrence free survival rate and the intravesical recurrence free survival rate in the retroperitoneoscopic group were the same at 79.17%, and in the open group was 72.22% and 79.63% respectively. The difference was not statistically significant between the two groups.

**Conclusion:** Comparison with open operation, retroperitoneoscopic nephroureterectomy for upper urinary tract transitional cell carcinoma is a safe, minimally invasive and effective procedure. The two modes of operation have the same long-term result.

#### VP1-20 EXPERIENCE WITH LAPAROSCOPIC PARTIAL NEPHRECTOMY WITHOUT VASCULAR CLAMPING

O. Stakhovskyi, N. Benoist, M. Galiano, X. Cathelineau, F. Rozet, G. Vallancien—France

**Background:** Loss of renal units due to warm ischemia is of great concern in laparoscopic partial nephrectomy (LPN). We present our experience with LPN without vascular control.

**Methods:** Between January 2000 and December 2007, 129 patients underwent LPN in our institution. Out of these, 30 patients median age 55 years (24–62) without significant comorbidities underwent LPN without vascular control and composed the population of the study. A surgical approach without hilar clamping and no suture of tumor bed was performed for these patients. Hemostasis of tumor bed was accomplished with either monopolar or bipolar energy and hemostasis adjuvant. We verified the medical files of these patients and end points assessed retrospectively were perioperative, pathological and complication outcomes among the series.

**Results:** Thirty-one LPN were performed in 30 patients. Median operative time was 128 min (75,240), Median tumor size was 25.3 mm (15,40), median blood loss was 353 cc (10–1000), no intraparenchymal tumors were resected and there was not involvement of the upper urinary tract when resecting the lesions. Tumor location were 10, 9 and 12 for upper pole, medial and lower pole. 9 lesions had posterior location. There were 2 (6.4%) complications: one patient with a urinary tract infection which received medical treatment and another patient with intrabdominal hemorrhage presenting in the perioperative period. This patient was managed with open surgery reoperation and evolved uneventfully. At a median follow-up of 5.8 years none of these patients have presented with recurrence. A creatinine increase of 0.3 mg/dl or greater was seen in 1 patient (3.2%) following surgery, due to underlying medical renal disease. In the remaining patients no creatinine augmentation was verified.

**Conclusion:** A tailored approach based on patients characteristics, tumor size and location allows to perform LPN without vascular clamping with optimal results and minimal blood loss in selected small and superficial renal masses without compromising morbidity and oncological outcomes.

## VP2: LAPAROSCOPY RECONSTRUCTION

### VP2-01 INTRA-OPERATIVE COMPLICATIONS OF LAPAROSCOPIC PYELOPLASTY AND TIPS AND TRICKS OF MANAGEMENT

A. Patel, V. Jain, A. Ganpule, R. Sabnis, V. Muthu, M. Desai—India

**Background:** Laparoscopic pyeloplasty is a meticulous surgical exercise and requires certain learning curve and expertise. Incidence of intra-operative complications like loss of needle, cutting of DJ-stent, bowel injury, anastomotic rupture etc range from 2.0 to 2.3% in large series, mostly without consequences for the patient. A few intra-operative complications of laparoscopic pyeloplasty are presented here with tips and tricks for adequate management. **Methods:** 133 patients with PUJO underwent laparoscopic pyeloplasty in our institute. This video will demonstrate identification and steps involved in the management of the following four intra-operative complications of this procedure: intra-operative loss of needle and its retrieval under IITV, bowel injury which was sutured, anastomotic rupture and upside down anastomosis requiring re-suturing.

**Results:** Incidence of intra-operative complications of this procedure in our series is 3.14%. All patients recovered without any consequences and showed significant improvement in function and drainage on follow-up.

**Conclusion:** Laparoscopic pyeloplasty has been proven safe and effective with comparable results to open surgery. The experience of pioneering centres with incidence and management of complications will be used by next generations of laparoscopic urologic surgeons to shorten their learning curve.

### VP2-02 FLEXIBLE PNEUMOCYSTOSCOPY FOR RETROGRADE DOUBLE J STENTING DURING LAPAROSCOPIC PYELOPLASTY

C. Fiori, F. Porpiglia, A. Distasio, S. Grande, R. Scarpa—Italy

**Background:** Laparoscopic pyeloplasty (LP) has gained more and more acceptance in the urological world. One of the most critical point is the stent positioning and two techniques are routinely employed: preoperative retrograde or intra-operative stenting. The aim of this study is to present our results in terms of feasibility, safety and efficacy of pneumocystoscopy during double J stenting in patients undergoing LP.

**Methods:** In this prospective study all patients with indication of LP were included. Operative technique: Patient is placed on the flanked at a 45° angle. Pneumocystoscopy is performed using a flexible cystoscope and a 6F ureteral catheter is positioned in the mid ureter. Laparoscopic dismembered pyeloplasty is then performed with a trans-peritoneal access, according to Anderson Hynes technique. After completing the running suture of posterior wall of the uretero-pyelic anastomosis, the urethral catheter is exchanged with a double J stent in a retrograde way. The distal end of the stent is controlled using pneumocystoscopy before completing the UP anastomosis. We evaluated: gender, age, operative time, time for stenting, intraoperative complications, ancillary maneuvers.

**Results:** Twenty-seven patients were treated with standard LP, 4 patients were treated with robot-assisted LP. 13 patients were male

and mean age was 39.7 years. Operative time was 124' while double J stenting time was 4.2 minutes (2–6). We observed 1 case of cranial migration of the stent, forcing us to repeat the procedure which was completed without complications. No ancillary procedures or Xray control were needed.

**Conclusion:** Retrograde double J stenting using flexible pneumocystoscopy during LP is feasible, easy, safe and effective, the procedure can be completed without change of patient position and without the use of Xray; moreover it can be easily utilized during robot assisted pyeloplasty

### VP2-03 LAPAROSCOPY ASSISTED AUGMENTATION CYTOPLASTY (FIRST EXPERIENCES)

F. Yalcinkaya, F. Demirel, U. Altug, M. Topcuoglu, C. Murat

**Background:** Augmentation cytoplasty is the most successful technique to increase the capacity and decrease the pressure of the neurogenic bladder. Although open surgery is performed routinely laparoscopy assisted augmentation cytoplasty has some advantages.

**Methods:** Distal ileal segment is pulled out from the 4 cm midline subumbilical incision as in open surgery. After isolation, detubularization and reconfiguration of the ileal patch and reestablishing of the bowel continuity, the patch is put into the abdominal cavity and the wound is closed. 5 ports are used laparoscopic procedure. The bladder is mobilized and opened with midline anteroposterior incision. The anastomosis between bladder and ileal patch was made fullthickness, single layer running sutures beginning from posterior wall.

**Results:** We performed 3 laparoscopy assisted augmentation cytoplasty using distal ileal patch in our clinic. Mean operation time was 270 minutes. Blood loss was minimal. Except temporary paralytic ileus in one case, no complication has seen. Mean hospital stay was 7 days. The mean increase in bladder capacity 6 months after the surgery was 200 cc.

**Conclusion:** Laparoscopy assisted augmentation cytoplasty may be an important alternative to open surgery.

### VP2-04 LAPAROSCOPIC TREATMENT OF URINARY LITHIASIS

M. Conradie—South Africa

**Background:** Although most urinary lithiasis can be treated today with endoluminal surgery, PCNL or ESWL as a preferred treatment, there are still certain conditions that mandate alternative surgery. The aim of this study is to define the role and efficacy of laparoscopic treatment of urinary lithiasis.

**Methods:** A retrospective chart review was performed on 102 patients who underwent laparoscopic surgery for urinary calculi. These procedures included 26 pyelolithotomies, 1 calyceal diverticular stone removal, 5 partial nephrectomies, 9 nephrectomies, 3 coagulum pyelolithotomies, 48 ureterolithotomies and 20 staghorn stones. Stone position, operating time, blood loss, complications, stone clearance rate, re-treatment rate, removal of abdominal drain/JJ stent and hospital stay were documented. The patients were followed up for stone clearance rate with a plain abdominal KUB x-ray.

**Results:** All but three patients were rendered stone free. The stone clearance rate and the re-treatment rate were 97% and 1.9% respectively. Only two patients required an additional ureteroscopy for removal of residual stone fragments. One patient passed the residual stone fragment spontaneously. In the case of the nephrolithotomy, conversion to open procedure was required.

**Conclusion:** Laparoscopic surgery is rarely needed in patients requiring stone surgery. However, it may be a safe and effective approach in the management of patients with more complex stone disease. This study provides evidence of high stone-clearance rates and low re-treatment rates. Correctly applied, laparoscopic stone removal procedures can be valuable extension of the current minimally invasive treatment modalities in calculus disease.

#### VP2-05 LONG TERM FOLLOW UP OF LAPAROSCOPIC PYELOPLASTY: A SINGLE CENTRE EXPERIENCE

R. Kapoor, R. Bansal, R. Maheshwari, A. Mandhani, A. Srivastava, M. Ansari—India

**Background:** To determine the safety, efficacy and long-term outcome of laparoscopic pyeloplasty

**Methods:** A retrospective analysis of 203 patients, who underwent laparoscopic pyeloplasty from January 2000 to May 2008 was done. Patients were evaluated with pertinent investigations including isotope renogram. Retrograde Pyelography was not done preoperatively. Tubeless pyeloplasty was done in 16 patients, retrograde stenting in 33 and antegrade stenting in 154 patients. Postoperatively patients were followed with renogram at 3, 6, 12 months and then annually. Success was defined as improvement in the symptoms/or better drainage on postoperative renogram.

**Results:** A total of 203 patients with mean age of 27.6 years (4 months to 67 years) underwent laparoscopic pyeloplasty. Dissected pyeloplasty was done in 176 patients, Foley Y-V plasty in 12 and ureterocalycostomy in 15 via transperitoneal approach. Mean operative time was 151 minutes (78–369); mean blood loss 68.3 ml (50–310) with a mean hospital stay of 5.63 days (2–14). Conversion to open was required in 12 (6.93%) patients, majority being in the initial phase. Follow up renograms were available in 189 patients which showed improvement in drainage in 172 patients and obstructed pattern in 17. Six patients among the obstructed group underwent redo open pyeloplasty while the rest eleven were lost to follow up. Failed patients presented within one year. At mean follow up of 53.58 months (12–113), our overall success rate was 91%.

**Conclusion:** Laparoscopic pyeloplasty gives excellent long-term results, which can be predicted by one year follow up renogram.

#### VP2-06 IS AN EXTERNAL DRAIN NECESSARY AFTER LAPAROSCOPIC PYELOPLASTY?

T. Schuster, E. Ohmann, K. Sternberg, K. Shahrou, T. Averch

**Background:** Urine leak is a known potential complication of pyeloplasty for ureteropelvic junction obstruction (UPJO). Although an external drain is typically placed, very little data supports this practice. We report our experience in laparoscopic pyeloplasty to examine the need for external drain placement.

**Methods:** A retrospective review of all adult patients who underwent a laparoscopic or robot-assisted procedure for UPJO at our institution was performed. Post-operative drain outputs and drain fluid creatinine levels were recorded to evaluate the presence of a urine leak.

**Results:** Forty-seven renal units were treated laparoscopically for UPJO between December 2000 and April 2008. Operative techniques included dismembered pyeloplasty (n = 29), Fengerplasty (n = 6), and Y-V plasty (n = 1); Eleven patients who underwent ureterolysis were excluded from analysis. Of the 36 pyeloplasties, 16 (44%) were performed laparoscopically and 20 (56%) were robot-assisted. Internal stents were placed in all patients. Jackson-Pratt drains connected to bulb suction were placed in all but one case. Mean drain output was  $96 \pm 66$  mL on post-operative day (POD) #1 and  $65 \pm 58$  mL on POD #2. Mean drain output in the eight hours prior to removal was  $29 \pm 26$  mL. Drain fluid creatinine levels were obtained in 21 patients (60%) and demonstrated no evidence of urine leak. All patients were discharged home without a drain or Foley catheter at a mean hospital length of stay of  $2.5 \pm 1.0$  days. None of the patients developed a delayed urine leak at a mean follow-up of  $25.1 \pm 21.2$  months.

**Conclusion:** An external drain is routinely placed at the time of pyeloplasty. However, our data reveal that the risk of urine leak after laparoscopic or robot-assisted pyeloplasty is extremely low, suggesting that placement of a drain may not be necessary. This may be further evidence that the technical principles of pyeloplasty, including careful handling and preservation of the ureteral blood supply and creation of a tension-free, watertight anastomosis, are successfully achieved using the laparoscopic or robot-assisted approach. Future prospective studies are needed to further define the role of external drains after pyeloplasty.

#### VP2-07 UPDATE REPORT OF LAPAROSCOPIC MODIFIED HELLSTROM TECHNIQUE FOR MANAGING URETEROPELVIC JUNCTION OBSTRUCTION DUE TO LOWER POLE CROSSING VESSELS

A. Nouralizadeh, N. Simforoosh, A. Basiri, A. Tabibi, M. Soltani, H. Kilani—Iran

**Background:** To demonstrate the update report of our experience with laparoscopic management of ureteropelvic junction (UPJ) obstruction by division of the aberrant crossing vein and cephalad relocation of crossing artery in a large group of patients with long term follow up.

**Methods:** From Jun 2001 to Jan 2009, 314 patients elected for transperitoneal laparoscopy for management of UPJ obstruction. Intraoperatively, we identified lower pole crossing vessels in 112 patients. After laparoscopic division of the aberrant crossing vein, the lower pole crossing artery was relocated cephalad and fixed to peripelvic tissue with interrupted absorbable sutures. Regarding to significant renal pelvic emptying with proper pyeloureteral peristalsis, dismembered pyeloplasty was not performed in 67 cases and no JJ stent was required in any of these patients. Postoperative outcomes were assessed with intravenous urography (IVU) and/or diuretic renography.

**Results:** The mean age of patients was 27.63 (7–69) years. The mean operative duration was 133.73 (55–185) minutes and blood loss was negligible. Mean hospital stay was 2.84 (1–7) days and mean follow up was 28.3 (3–72) months. Success rate was 97.1% and recurrence of obstruction was noted in two patients six months and five years later, respectively. No significant complications were happened.

**Conclusion:** Transposition of lower pole crossing artery after division of crossing vein in selected cases is an ideal alternative for

classic dismembered pyeloplasty with noticeable outcomes in long term follow up.

### VP2-08 LAPAROSCOPIC PYELOPLASTY USING HELLSTROM TECHNIQUE IN A 6-YEAR-OLD BOY WITH URETEROPELVIC JUNCTION OBSTRUCTION BY CROSSING VESSELS ASSOCIATED WITH HORSESHOE KIDNEY

N. Masumori, K. Nishinaka, Y. Kunishima, T. Tanaka, N. Itoh, T. Tsukamoto—Japan

**Background:** The Hellstrom technique, which allows lower-pole aberrant crossing vessels to be cranially translocated without incision or excision of the pelvic wall, is a minimally invasive method to treat ureteropelvic junction obstruction (UPJO). We performed the procedure under laparoscopy for a boy with UPJO caused by crossing vessels.

**Methods:** A 6-year-old boy (height 112 cm, weight 18.4 kg) who complained of intermittent abdominal pain was diagnosed with left hydronephrosis due to UPJO caused by lower-pole crossing vessels associated with horseshoe kidney. A preoperative renogram demonstrated the obstruction pattern of the left kidney. Since computed tomography and retrograde pyelography showed sufficient dilatation of the left extrarenal renal pelvis and no findings suspicious of intrinsic ureteral obstruction, laparoscopic pyeloplasty using the Hellstrom technique was planned.

**Results:** Using a 3-port transabdominal approach, anterior crossing vessels were identified and completely freed from the ureteropelvic junction. During this procedure, improvement of hydronephrosis was observed. The pelvic wall and the proximal ureter were exposed widely enough and two interrupted 4-0 vicryl sutures using were placed between the pelvic wall and proximal ureter to transpose the crossing vessels to the cranial position and reduce the volume of the extrarenal renal pelvis. Sufficient urinary drainage from the pelvis to the ureter through the original crossing site was confirmed under intravenous administration of furosemide. The operation time and blood loss were 167 minutes and 10 cc, respectively. No ureteral stent was placed. There were no complications observed postoperatively. His complaint disappeared and a postoperative renogram was planned.

**Conclusion:** Laparoscopic pyeloplasty using the Hellstrom technique is a minimally invasive and safe procedure to resolve UPJO due to anterior crossing vessels even in a child. However, careful inspection of whether urine is sufficiently drained from the pelvis to the proximal ureter passing through the original crossing site is mandatory.

### VP2-09 LAPAROSCOPIC EXTENDED PYELITHOTOMY WITH PYELOPLASTY

M. Ramalingam—India

**Background:** Management of staghorn calculi has always been complex. Partial staghorn calculi have been managed by multiple percutaneous nephrolithotomy with or without ESWL or open extended pyelolithotomy with nephrolithotomy. Laparoscopic extended pyelolithotomy 7 or anatomic nephrolithotomy 2 are less commonly done. The submitted video highlights the technique of laparoscopic extended pyelolithotomy with pyeloplasty.

**Methods:** Equipment: 45 year old male presented with a partial staghorn calculus involving the lower calyces (anterior and posterior) and pelvis. He also had a pelviureteric junction obstruction. As the patient had two pathologies, the options were open surgery

or laparoscopy. PCNL with endopyelotomy was not considered due to the need for multiple punctures for the stone and the unsatisfactory results of endopyelotomy. Using 5 ports the colon was mobilized and the ureter and pelvis were dissected. Pyelotomy was planned such that a nondismembered pyeloplasty (fengerplasty) could also be done. Extension into the lower calyx was done. The calculus was removed in toto. Secondary calculi were removed by irrigation during which a few calculi slipped into the perirenal area. A 20 mm port was used for removing the stag horn calculus intact. Nondismembered pyeloplasty (Fengerplasty) was done with 5-0 polyglactin sutures. Subsequently the calyceal incision was sutured. Stent was placed antegrade. Nephrostomy was placed in the middle calyx with an idea to consider second look nephroscopic retrieval of residual calculi. Drain was placed through the flank port.

**Results:** The operating time was 210 minutes. The blood loss was about 50 ml. Nephrostogram was done on the 5th postoperative day. A few secondary calculi were present outside the renal area. A few secondary calculi all less than 4 mm were in the lower minor calyx. These inaccessible calculi were left behind with an idea to manage later by RIRS or ESWL. There was no immediate or delayed surgery related morbidity. At 6 months of follow-up, patient remains asymptomatic, urine culture is sterile and renal function is good.

**Conclusion:** Thus laparoscopic pyelolithotomy with pyeloplasty is an option (even though technically demanding) with the benefits of minimally invasive surgery, minimal morbidity with correction of the pelviureteric junction obstruction.

### VP2-10 LAPAROSCOPIC UNDIVERSION FROM ILEAL CONDUIT TO ILEOCYSTOPLASTY

M. Ramalingam, K. Senthil, M. Ganapathy Pai—India

**Background:** Laparoscopic ileocystoplasty is a well documented procedure. But laparoscopic ileocystoplasty from an ileal conduit has not been described. Here we illustrate the technique of laparoscopic undiversion.

**Methods:** A 6 years old boy had sacral agenesis with neurogenic bladder and mild renal failure. To stabilize the renal function laparoscopic ileal conduit was done in 2008. One year later his renal function stabilized at Serum creatinine of 1.5 mg/dl. Patient's parents were counselled for undiversion and possible clean intermittent catheterisation and chemoprophylaxis. Using 4 ports the conduit was detubularised along its antimesenteric border using electrocautery. A transverse cystotomy was done to match the length of conduit (about 7 cm). Intracorporeal suturing of cystotomy edge to the conduit was started in the posterior layer using 3-0 Polyglactin sutures. An suprapubic cystostomy was done as a vent. Subsequently the anterior layer suturing is completed. Finally the urostoma is disconnected and extracorporeally closed with 3-0 Polyglactin suture. The stomal site is closed with 2-0 interrupted polyglactin sutures. A tube drain was introduced through one of the flank ports.

**Results:** The operative time was 190 min. Blood loss was about 75 ml. Patient made an uneventful recovery. The SPC was left to drain the mucus plugs as the 8Fr urethral catheter may get blocked with mucus. He was discharged on the 6th postoperative day. The renal function remains stable. Post operative cystogram at 3 months and urodynamic study at 6 months are presented.

**Conclusion:** Laparoscopic undiversion is safe feasible and less invasive method.

### VP2-11 MULTI-INSTITUTIONAL EXPERIENCE WITH LAPAROSCOPIC URETEROLYSIS IN THE TREATMENT OF URETEROPELVIC JUNCTION OBSTRUCTION

T. Schuster, K. Sternberg, K. Shahrouh, R. Munver, T. Averch

**Background:** To perform a multi-institutional review of laparoscopic ureterolysis in the treatment of ureteropelvic junction obstruction (UPJO) in adults.

**Methods:** We retrospectively reviewed 17 consecutive patients who underwent laparoscopic ureterolysis for UPJO at two institutions between December 2000 and June 2008. Patient characteristics, perioperative data, intraoperative findings and outcomes were recorded.

**Results:** Mean patient age was 39.8 years (range 19–71 years). The obstruction was right-sided in seven and left-sided in ten patients. Seven (41%) patients were previously treated; six with either balloon dilation or endopyelotomy, or both and one with open pyeloplasty. A crossing vessel was observed in nine patients (53%). Mean operative time, estimated blood loss, and length of stay were  $299 \pm 97$  minutes,  $20.9 \pm 24.8$  mL, and  $1.7 \pm 0.8$  days, respectively. At mean follow-up of  $23 \pm 15$  months, a 77% overall success rate was achieved. Ureterolysis was more successful in the patients without a crossing vessel (88%) compared with those with a crossing vessel (67%). Ureterolysis resulted in a 71% success rate in the subset of patients who had previously been treated for UPJO.

**Conclusion:** Although pyeloplasty remains the preferred treatment for UPJO, ureterolysis has been applied successfully in some circumstances. Further investigation is warranted to help define the specific clinical situations in which ureterolysis may be beneficial.

### VP2-12 LAPROSCOPIC SCARDINO-PRINCE PYELOPLASTY FOR LONG SEGMENT URETEROPELVIC JUNCTION OBSTRUCTION-SINGLE CENTER EXPERINCE

S. Bhat, G. Kumar—India

**Background:** Anderson-Hynes dismembered pyeloplasty is the standard treatment for Pelvi-ureteric junction obstruction. Non-dismembered pyeloplasties have a role in selected cases of long segment obstruction. We report a series laparoscopic Scardino-Prince vertical flap pyeloplasty for long segment PUJ obstruction.

**Methods:** Laparoscopic pyeloplasty was performed using either 3 or 4 ports. Length of the narrowed segment is assessed by pre operative ureterogram and per operatively to plan the type of repair. If a long length of narrowing was anticipated preliminary ureteric spatulation was performed and once it was confirmed that dismembered pyeloplasty would be difficult a vertical flap procedure was performed. An indwelling double “j” stent was placed for 4 weeks.

**Results:** A total of 8 patients, (Age: 4 months–46 years; 4 males and 4 females) underwent the procedure between Nov. 2007 and May. 2009. Approach was transperitoneal with no major intraoperative complications. Postoperative hospital stay was 4–10 days (mean 5.5 days), mean operative time was 151 min, blood loss 36.8 ml; and there were no conversions to open. Follow up ranged from 3 to 18 months (except one patient who is still on a stent) with all patients having improvement of symptoms, ultrasound appearance and renogram patterns when compared to preoperative status.

**Conclusion:** Long segment PUJ obstruction can be managed laparoscopically by the Scardino prince pyeloplasty with good outcomes.

### VP2-13 LAPAROSCOPIC PYELOPLASTY: ARE THERE PREDICTORS FOR FAILURE?

N. Hamilton, V. Trang, R. Jansen, S. Savage

**Background:** INTRODUCTION: Laparoscopic pyeloplasty (LP) is an accepted standard of care for ureteropelvic junction (UPJ) obstruction. Many factors have been considered in relation to success of treatment. We analyzed our experience to determine if there were specific factors predictive of failure.

**Methods:** We retrospectively reviewed all patients who underwent (LP) by a single surgeon at our institution from 2/05–2/09. Factors evaluated include age, body mass index (BMI), previous interventions, surgical operative approach, presence of crossing vessels, transposition, operative time, estimated blood loss (EBL), and duration of Jackson-Pratt (JP) drainage. Patients were characterized as successes, equivocal (symptoms without obstruction by functional study) or failures (symptoms with obstruction by functional study).

**Results:** Thirty-six patients were reviewed. Eight patients had a total of 10 previous interventions. Twenty-five patients underwent the transperitoneal approach while 11 had retroperitoneoscopy. There were 25 successes, 9 equivocal and 2 failures. Twenty-seven had crossing vessels ( $p = 0.251$ ) of which 8 were transposed ( $p = 0.202$ ). Failures had non-significantly increased operative times versus successes (252.5 min vs. 229,  $p = 0.139$ ). There was significantly more EBL in the failures vs. the successes (150 ml vs. 48.7,  $p = 0.0007$ ). Prolonged JP drainage was not predictive for failure ( $p = 0.29$ ).

**Conclusion:** Laparoscopic pyeloplasty when performed by an experienced surgeon has a low failure rate (5.5%). Surgical approach or transposition of vessels was not a prognostic variable. Operative time and EBL were increased in failures and may represent patients that require close follow-up.

### VP2-14 LAPAROSCOPIC URETEROLITHOTOMY: A MINIMALLY INVASIVE SECOND LINE TREATMENT

G. Simone, C. Leonardo, R. Papalia, S. Guaglianone, M. Ferriero, M. Gallucci

**Background:** We describe our experience of 33 laparoscopic ureterolithotomies for large ureteral stones after ureteroscopic and open ureterolithotomy failures.

**Methods:** Since February 2004 in our Department no open ureterolithotomy was performed and 33 patients had undergone transperitoneal laparoscopic ureterolithotomy. Inclusion criteria was failure of SWL and/or ureteroscopic treatment in 31 cases and failure of open ureterolithotomy in 2 cases. Mean patients age was 47 years (range 37 to 51). The mean stone size on preoperative IVP-CT scan was 34 mm (range 18–55). All stones were impacted from 4 to 36 months before procedure. Stones were located in the lower ureter in 9 patients, in the mid ureter in 16 patients and in the upper ureter in 8 patients.

**Results:** Successful rates was 100%. No conversion to open surgery occurred. No intraoperative and postoperative complication occurred. Mean operating time was 85 minutes (range 60 to 160). Mean intraoperative blood loss was 70 ml (range 30 to 120). Mean hospital stay was 3.4 days (range 2 to 7). At a mean follow-up of 24

months (range 6 to 44) no ureteral stricture was observed in any patient and all patients were stone-free.

**Conclusion:** In our hand first line treatment after failure of SWL and or ureteroscopy is laparoscopic ureterolithotomy. Large stone size and previous open surgery did not affect successful rates of laparoscopic ureterolithotomy.

### VP2-15 LAPAROSCOPIC URETEROLITHOTOMY FOR IMPACTED PROXIMAL URETERIC STONES

A. Abusamra, A. Al-sayad—Kingdom of Saudi Arabia

**Background:** Large impacted proximal ureteric stones constitute a management dilemma to the practicing urologist. We reviewed our experience of laparoscopic ureterolithotomy for management of this especial situation.

**Methods:** Retrospective chart review was carried out for all patients who underwent laparoscopic ureterolithotomy at our institution from January 2007 to June 2009. Exclusion criteria included: stones less than 2 cm in size, lower ureteric stones, and follow up duration less than 6 months.

**Results:** We identified 12 patients (9 men and 3 women). Mean age was 53 years (31–67). Mean stone largest dimension was 3.9 cm (2.1–6.2). Mean number of stones was 1.4 (1–3). Operative time ranged from 40–150 minutes with mean of 72 minutes. Hospital stay ranged from 1 to 5 days with a mean of 2.2 days. Mean duration of ureteric stenting was 4.5 weeks (4–12). We achieved 100% stone clearance rate. Mean Follow up duration was 14 months (6–30). Post operative complications included ureteric stricture development in 2 patients; it developed 6 month postoperatively in one patient and after 15 months in the other.

**Conclusion:** Laparoscopic ureterolithotomy is a safe and reliable procedure for this special group of patients with an excellent success rate. The need for long term follow up cannot be over-emphasized.

### VP2-16 LAPAROSCOPIC PYELOPLASTY LONG-TERM FUNCTIONAL OUTCOME: MINIMUM 10-YEAR FOLLOW-UP

M. Atalla, A. Herati, J. Cho, L. Kavoussi—USA

**Background:** Laparoscopic pyeloplasty (LP) has been shown to be as successful as open pyeloplasty in the treatment of ureteropelvic junction obstruction (UPJO). A paucity of long-term data exists, however. To determine if the success of LP stands the test of time, we sought out to assess the long-term functional outcome of our series.

**Methods:** We retrospectively reviewed our database of LP patients to identify patients who qualified for long-term outcome assessment. Only patients who were at least 10 years out from their surgery were included. Peri-operative data were compiled and each patient was contacted to answer a telephone questionnaire. Patients who did not have recent radiographic evaluation were prescribed a diuretic renogram.

**Results:** Eighty-one patients underwent LP for UPJO between 1993 and 1998. Twenty-three patients were available for long-term follow-up analysis. Mean follow-up was 11.52 years (10–14 years). Of the 23 patients, mean age at time of surgery was 40.3 (15–67 years). Thirteen patients were male (56.5%) and 13 procedures were right-sided (56.5%). Twenty of the procedures were performed as primary procedures (86.9%) and three procedures were salvage procedures. Thirteen patients presented with pain, six with recurrent urinary tract infections (UTIs), and four patients were asymptomatic with incidentally discovered UPJO. There were no intra-operative complications. Two patients had short-

term complications (8.7%): sepsis and a ureteral obstruction due to a blood clot. There were three long-term complications (13%): all were port-site hernias. One patient required subsequent procedures for UPJO (4.3%), requiring four retrograde balloon dilations with eventual resolution of the obstruction as documented by recent diuretic renography. Two of the thirteen patients who presented with pain had mild residual pain (rated 4 and 5 out of 10). One of the six patients with preoperative UTIs continues to have UTIs.

**Conclusion:** To our knowledge, this is the first study to report 10-year long-term outcome of LP in the treatment of UPJO. LP has been shown to be a safe and successful treatment option for UPJO in the short-term. Our analysis of the long-term clinical success and safety of LP shows that its short-term efficacy is durable. Ongoing objective assessment of functional outcome with diuretic renography would further corroborate these findings.

### VP2-17 LAPAROSCOPIC PYELOPLASTY FOR URETEROPELVIC JUNCTION OBSTRUCTION: KITASATO EXPERIENCE IN CONSECUTIVE 100 CASES

D. Ishii, M. Iwamura, H. Sasamoto, M. Nishi, S. Baba—Japan

**Background:** Laparoscopic pyeloplasty (LPP) is now widely accepted as a minimal invasive alternative for surgical management of ureteropelvic junction obstruction (UPJO). Since October 1998, LPP has been performed as a first line surgical treatment for UPJO at our institution. We now show the results of LPP in 100 consecutive cases.

**Methods:** Between October 1998 and June 2009 we performed laparoscopic pyeloplasty on 100 ureters in 95 patients presenting with symptomatic hydronephrosis secondary to a short stenosis of the UPJ or to ventrally crossing vessels. There were 52 males and 48 females with median age of 31 (range, 1–76) years old. We performed dismembered Anderson-Hynes pyeloplasty, Fenger plasty, Y-V plasty and ureteral incision in 82, 15, 2 and 1 ureters, respectively. All procedures except one were carried out transperitoneally.

**Results:** The procedure was completed successfully in all cases. Crossing vessels were noted in 50 ureters and 32 cases (32%) were considered as the principle cause of UPJO. Median operative time and blood loss were 205 (range, 80 to 775) minutes and 20 (range, 5 to 250) ml, respectively. Perioperative minor complications were noted in 12 procedures (12.0%). In 4 cases (4%), pelvic stones that required subsequent lithotripsy were formed. Ninety four of 100 ureters (94.0%) demonstrated a patent UPJ on excretory urography and/or improvement of renal function on diuretic renography at a median followup of 41 months.

**Conclusion:** Although the procedure requires advanced laparoscopic skills, it can be safely and successfully completed as frequently as can the conventional open procedure. Laparoscopic pyeloplasty seems to be a valuable alternative to open pyeloplasty for UPJO.

### VP2-18 REOPERATIVE LAPAROSCOPIC RECONSTRUCTION FOR RECURRENT URETEROPELVIC JUNCTION OBSTRUCTION AFTER OPEN PYELOPLASTY

S. Corvin, G. Bromberger, A. Nicklas, C. Antwerpen, H. Hammerl—Germany

**Background:** Meanwhile, laparoscopic pyeloplasty has been established as a highly effective alternative for primary ureteropelvic junction (UPJ) obstruction. However, only few reports are available about the use of laparoscopy in the management of the worst case scenario: recurrent UPJ obstruction after failed open pyeloplasty and subsequent salvage endoscopic treatment.

**Methods:** Between February 2006 and June 2008, four patients presented at our department for symptomatic recurrent UPJ obstruction after open pyeloplasty and subsequent retrograde endopyelotomy. All patients underwent laparoscopic transperitoneal repair of the UPJ. We performed dismembered Anderson-Hynes pyeloplasty, Fenger plasty and ureterolysis in one, one and two cases, respectively. The preoperatively placed double pigtail ureteral stents were removed 6 weeks postoperatively.

**Results:** All operations were performed successfully without complications or conversion to open surgery. Mean operative time, including preoperative transurethral ureteral stenting was  $160 \pm 30$  min. No urinary leakage was observed. Three patients experienced resolution of obstruction as shown by renal nuclear scan. The remaining patient, who had persistent obstruction after laparoscopic ureterolysis, underwent permanent ureteric Memokath stent insertion. All patients reported reduction or relief of pain. Durable clinical and radiographic success was observed during a followup of 5 to 31 months.

**Conclusion:** The present data demonstrate that laparoscopy is an applicable tool in the treatment of patients failing both an initial open pyeloplasty and subsequent endoscopic salvage procedures. In experienced hands, redo laparoscopic reconstruction can be performed safely with a success rate comparable to that of open surgery. However, utmost care has to be taken for preoperative patient selection and intraoperative decisionmaking.

#### VP2-19 URETEROENTERIC ANASTOMOTIC STRICTURE: NOVEL USE OF A CUTTING BALLOON DILATOR

U. Boylu, M. Oommen, M. Raynor, B. Lee, R. Thomas—USA

**Background:** The cutting balloon device features a 2 cm non-compliant balloon with 4 microsurgical blades mounted longitudinally on its outer surface and it is used for angioplasty. We evaluated the feasibility and outcome of the cutting balloon dilator in the treatment of ureteroenteric anastomotic strictures.

**Methods:** Three patients with approximately 1 cm ureteroenteric strictures underwent a transluminal dilation under fluoroscopic guidance. A guidewire was introduced into the renal pelvis and ureter in antegrade fashion and passed through the stricture. The cutting balloon dilation device (Boston Scientific, Natick, MA) was deployed over the guidewire and the balloon was inflated at the stricture site. The maximum diameter of the inflated balloon was 8 mm. Approximately 30 sec later, the balloon was deflated and the passage from the ureter to the ileal loop was verified under fluoroscopy. A pigtail stent was placed and removed 6 weeks after the procedure.

**Results:** Postoperative CT scans at 3 months revealed no hydronephrosis. All patients were asymptomatic postoperatively. One patient had a solitary kidney and creatinine level decreased significantly following the procedure.

**Conclusion:** Dilation with cutting balloon device is a novel approach for the treatment of the short ureteroenteric anastomotic strictures. Long-term data needs to be followed to establish the efficacy of this technique.

#### VP2-20 MICROLAPAROSCOPIC 2-MM HYBRID LAPAROSCOPIC PYELOPLASTY: A NEW COMPETITOR

D. Herrell, N. Miller, H. Altamar, E. Lambert—Tennessee USA

**Background:** Laparoscopic pyeloplasty (LPPL) is a well-established standard for UPJ obstruction. Recently described techniques are improving cosmesis and potentially reducing the morbidity of the operation including single-port laparoscopy, robotic surgery and NOTES. 3 mm instruments have been described for LPPL in children. We describe the initial clinical application of 2-mm microlaparoscopic working instruments and 2.5-mm ports for the performance of adult LPPL.

**Methods:** Two patients underwent microlaparoscopic pyeloplasty. Initially, a 5 mm optical trocar was inserted through a hidden umbilicus incision and 2 2.5-mm trocars were inserted through skin punctures. Freehand intracorporeal suturing was performed with intracorporeal tying. A standard postoperative care pathway with discharge on postop day one was followed.

**Results:** The procedures were technically successful with no extra-umbilical skin incisions. Patient #1 had significant crossing vessels which were preserved despite marked scarring from failed Acucise endopyelotomy. Patient #2 had a primary UPJ. The total operative time was 4 and 3 hours, respectively. Estimated blood loss <20 cc and hospital stay was one day. There were no complications. Pain scores were similar to standard LPPL. Cosmetic results were rated “outstanding” by the patients.

**Conclusion:** Microlaparoscopic instrumentation, including needle holders, has improved such that complex upper tract reconstruction such as pyeloplasty is both technically feasible and safe in selected patients. The only external incisional scar is concealed within the umbilicus. The 2-mm instruments through 2.5-mm trocar sites are virtually invisible after healing and most importantly allow for instrument triangulation facilitating proper tissue retraction, intracorporeal suturing and preventing crossing instruments, a commonly encountered problem in single-port laparoscopy. This extremely minimally invasive procedure an even less “incisional” option.

## VP3: URETEROSCOPY 1

#### VP3-01 THE ROLE OF URETEROSCOPY IN RETROPERITONEAL OR PELVIC NON UROLOGIC MALIGNANCIES

B. Petrut, F. Nechita, B. Tintila, S. Popescu, A. Irimie

**Background:** Our objective was to assess the place of the ureteral exploration in obstructive non urologic malignancies of the pelvis and the retroperitoneal organs.

**Methods:** We evaluated prospectively 16 patients during the last 8 month suffering from cervix, colon malignancies and one case of retroperitoneal fibrosis due to history of radiotherapy. During the ureteroscopy we followed the aspect of the bladder mucosa and ureteral ostiums, difficulty of the ureteral access, position and the aspect of the stenosis, mobility of the ureter. Biopsies have been performed from every stenosis during the ureteroscopy.

**Results:** We tried to establish correlations between the technical parameters determined during ureteroscopy and the outcome of the pathology exam. In 9 (56.25%) patients the stenosis was passed by guide wire under direct visual control. In 7 cases we performed percutaneous nephrostomy and antegrade pyelography that also stated the complete stenosis. These cases were approached by open surgery.

**Conclusion:** The ureteroscopic attempt in retroperitoneal non urologic malignancies succeeds retrograde catheterization in approximately half of the cases. Also provides tissue specimens avoiding the morbidities of open procedures.

### VP3-02 RETROGRADE CONSERVATIVE TREATMENT OF UPPER URINARY TRACT TRANSITIONAL CELL CARCINOMA: IS A 9.6 W MAXIMUM POWER HOLMIUM:YAG LASER SUFFICIENT TO OBTAIN A COMPLETE TUMOR ABLATION?

L. Ruggera, P. Beltrami, A. Aloisi, F. Zattoni—Italy

**Background:** aim of this prospective study was to evaluate the effectiveness of the transureteral endoscopic approach and the efficacy and safety of a 9.6 W maximum power Holmium:Yttrium–Aluminium–Garnet (Ho:YAG) laser in the treatment of the upper urinary tract (UUT) tumor.

**Methods:** from January 2006 to July 2008, 10 patients (7 males and 3 females), with an average age of 69.5 years ( $\pm 9.53$  SD), underwent multiple cysto-ureterorenoscopies and transureteral conservative laser treatments for superficial UUT transitional cell carcinomas (TCCs). The Calculase™ low-power Ho:YAG laser (Karl Storz Tuttlingen, Germany) was applied, being able to deliver an average power up to 9.6 W through 230, 365 or 600 micron Water-Free fibers. Analysis of treatment results, incidence of adverse events, recurrence rate and need of more invasive therapies were the primary outcomes of this study.

**Results:** all treatments were satisfactory, allowing an easy and complete tumor ablation with no significant bleeding. Adverse effects occurred in 5 out of 44 procedures (11.4%): a ureteral stricture, successfully treated with following laser incision, in one patient; a caliceal infundibular stenosis treated with balloon dilatation, in another one; fever,  $>38^\circ\text{C}$ , following 3 procedures. At a median follow-up of 17.5 months (interquartile range 8.5–23.5 months), the overall survival rate was 100%, with a recurrence rate of 50%. Nephroureterectomy was performed in one patient with a primary high-grade tumor (10%).

**Conclusion:** our results confirmed that conservative treatment, in case of UUT TCC, appeared to be useful for maintaining the renal function, particularly in selected patients. Likewise, the Calculase™ low-power Ho:YAG laser, that operates using low repetition frequencies and energy levels, proved to be safe and effective, allowing for a fine and complete tumor photoablation.

### VP3-03 LONG-TERM USE OF DOUBLE IPSILATERAL INTERNAL STENTS FOR THE TREATMENT OF EXTRINSIC MALIGNANT OBSTRUCTION OF THE URETER

M. Sofer, G. Lidawi, H. Matzkin, A. Greenstein

**Background:** Progresses in oncological therapies resulted in significant prolonged survival of patients with advanced malignancies. As such, patients with secondary extrinsic ureteral obstruction seek for durable, simple and low-cost solutions of drainage. We present our experience using 2 ipsilateral internal stents with a dwelling time of 1 year.

**Methods:** Double ipsilateral stenting of 17 extrinsic obstructed ureters of 14 patients was done after balloon dilation (15 FR) of the compressed segments. The procedures were performed under general anesthesia and advanced hydrophilic, low friction coefficient, 7 FR, double J, commercially available stents were used. The stents were replaced every 12 months and the patients were given the possibility to choose an other method of drainage, anytime. The urological follow-up consisted of periodic assessment of symptoms, creatinine level, urinary culture and ultrasound study.

**Results:** The study group comprised 7 females and 7 males aging an average age of 56 years (range 16–80). Half of the patients presented after being drained by nephrostomy tubes for an average period of 6 months (range 3–12), suffering of complications (e.g. infection, tube migration or obstruction, etc) necessitating hospitalization and/or intervention with an average occurrence of 6 weeks. The origin of the malignant obstruction was: ovary ( $n = 2$ ), cervix ( $n = 2$ ), breast ( $n = 1$ ), colon ( $n = 9$ ). The average length of the obstructed segment was 3 cm (range 2–5). Double stenting was feasible in all cases. After an average follow-up of 16 months (range 12–36) none of the patients needed replacement before the maximal dwelling time (1 year). Post-stenting urinary tract infection occurred in 2 (14%) patients and was antibioticly treated. One (7%) patient, with uretero-Hartmann's pouch fistula demanded substitution of internal drainage with nephrostomy tube due to severe irritative symptoms and continuous anal urinary discharge. Two patients died of their malignancy at 12 and 14 months, respectively. All the other patients were satisfied by the double stenting and those previously drained by nephrostomy tubes appreciated this solution as a significant improvement in their quality of life.

**Conclusion:** Double ipsilateral stenting using long-term dwelling stents is feasible and provides durable relief of extrinsic malignant ureteral obstruction. It represents a valuable alternative to other methods of urinary diversion, avoiding the need for external tubes and bags and contributing to improved patients quality of life and self esteem.

### VP3-04 MULTICENTER EXPERIENCE WITH METALLIC URETERAL STENTS FOR MALIGNANT AND BENIGN CHRONIC URETERAL OBSTRUCTION

B. Knudsen, A. Modi, C. Ritch, R. Walsh, J. Landman, M. Gupta

**Background:** A new coil-based metallic ureteral stent (Resonance, Cook Urological) and initial data demonstrated to offer greater radial strength with possible longer indwell time (up to 12 months), and possible decreased likelihood of obstruction secondary to encrustation compared to polyurethane stents. This multicenter retrospective study further evaluated this stent in patients with malignant or benign chronic ureteral obstruction.

**Methods:** Patients with malignant or benign chronic ureteral obstruction were stented in a retrograde fashion. We analyzed pre- and post-placement renal ultrasounds, intravenous urograms, or computerized tomography scans to determine degree of hydronephrosis. Stent encrustation was determined by either visual inspection at the time of stent change or plain abdominal radiographs. Pre-operative and follow-up serum creatinine values were compared for each patient. Complications were recorded.

**Results:** Metallic stents were placed in 58 renal units (39 patients, 19 bilateral). Median patient age was 63 years (range 28–93). Twenty-nine patients were obstructed due to malignancy and 10 due to benign disease. No intra-operative complications were



encountered. Median follow up was 6.6 months (range 0–14). Follow-up imaging was available for 45 units (30 patients): 21 (47%) were stable, 18 (40%) were improved and 6 (13%) had worsening hydronephrosis. In 30 patients with available creatinine values at last follow-up, 10 (33%) were improved, 8 (27%) were stable (<2 mg/dl change), and 12 (40%) had worsening values. Three patients developed significant stent encrustation on direct visualization but not on plain radiographs. Two of these patients required cystolitholapaxy and percutaneous nephrolithotomy for removal, respectively. Eighteen patients required early stent pull due to obstruction (5), voiding symptoms (9), stent migration (1) and UTI (3). Of 31 kidneys obstructing the conventional stent, thirteen (42%) ultimately obstructed the metallic stent.

**Conclusion:** Metallic stents are a viable alternative to nephrostomy tubes in patients who fail conventional stents due to obstruction, but need to be followed closely. Stent encrustation resulting in retained stents was poorly visualized on plain film. Patients remain at risk for obstruction, UTI and LUTS from the metallic stent.

### VP3-05 USE OF TANDEM DOUBLE J STENTS IN THE MANAGEMENT OF RECURRENT URETERAL STENOSIS AFTER KIDNEY TRANSPLANT

R. Miyaoka, O. Duran-castro, S. Alanee, M. Monga, D. Hunter

**Background:** To evaluate the use of tandem double J stents to treat recalcitrant ureteral stenosis after kidney transplant.

**Methods:** We retrospectively identified patients who underwent tandem double J stent placement following kidney transplant, assessing demographics (gender, age, cause of renal failure, recipient implantation site, blood pressure, donor status), renal function, biopsies, site of stenosis, dilations, time with tandem stents, complications and outcome. Success was defined as ureteral patency without need for reconstructive surgery. Student T test was used for creatinine levels. Multivariate survival analysis identified risk factors for failure.

**Results:** Nineteen patients (mean age 36.6 years) were included. The most common site of ureteral stenosis was distal (79%). Average number of biopsies before tandem stents was 1.8 (0–5) and pathology showed acute rejection in 16%. Percutaneous nephrostomy was performed after an average of  $66.8 \pm 140.8$  weeks from transplant date. Dilations averaged  $2 \pm 1.1$  (0–4) before tandem placement. Renal function improved after tandem stents ( $p < 0.01$ ) and remained stable throughout follow up ( $p = 0.147$ ). Patency success rate was 58% with a mean of  $48.7 \pm 48$  weeks with tandem in place. Failure rate was 26% with a mean of  $16 \pm 7$  weeks for tandem time. No perioperative complications were identified. Number of dilations before tandem was the only factor associated to failure (hazard ratio 2.61; CI 1.150–5.908,  $p < 0.03$ ). Proximal strictures ( $p = 0.072$ ) and renal function ( $p = 0.067$ ) were associated with a trend for tandem stent failure.

**Conclusion:** Tandem stents are an effective treatment of recurrent and recalcitrant ureteral stenosis after kidney transplant that failed previous balloon dilation or ureteral reconstruction.

### VP3-06 URETEROSCOPIC MANAGEMENT OF RENAL CALCULI IN SPECIAL SITUATIONS

A. Xavier, K. De Juan, R. Brites, F. Chagas dos santos, Á.M. Figueiredo f° facs, J. Travassos-São Paulo

**Background:** To review our experience in treating patients with renal calculi, in special anatomical situations, and to evaluate the efficacy of this approach.

**Methods:** 12 patients with renal calculous in anomalous kidneys were identified. Ureteroscope size, litotribe used, duration of surgery, complications and stenting were the parameters evaluated.

**Results:** Our cohort consisted of 1 patient with uretero-uretero anastomosis, 6 patients with horseshoe kidney, and 5 patients with pelvic kidneys, (8 males, 4 females, mean age 48.2 years). Nitinol baskets, ho-yag laser, and 7.5 flexible ureteroscope were used in all patients. 9 patients had complete clearance of the stones in post op imaging. 2 patients (1 horseshoe kidney and 1 pelvic kidney) required additional surgical intervention.

**Conclusion:** Flexible ureteroscopy is considered a reasonable procedure and an alternative to shockwave lithotripsy in the management of this particular cases, and can also be considered an excellent option for select patients with stones in horseshoe kidneys and pelvic kidneys, before a percutaneous procedure.

### VP3-07 URETEROSCOPIC MANAGEMENT FOR SYMPTOMATIC PARAPELVIC RENAL CYST

S. Hosseini, A. Basiri, V. Najjaran Tousi, M. Mohammadi Sichani—Iran

**Background:** Parapelvic cyst could be managed with various challenging techniques. Due to the proximity of parapelvic renal cyst and the renal pelvis, we used endourologic technique that is both effective and less invasive.

**Methods:** Two men (ages 56 and 53 years old) were referred to our clinic with the diagnosis of parapelvic cyst. In the first patient, IVU and CT scan revealed a polycystic kidney with a 6 by 5 cm parapelvic renal cyst that had compressed and displaced the upper major calyx, and the other patient showed one 6.5 by 7.5 cm parapelvic renal cyst which had compressed and displaced the upper and middle calyces with moderate to severe hydronephrosis. We decided to incise the cyst by a ureteroscope to make internal drainage of parapelvic renal cyst into the renal pelvis possible. Therefore, we started with a 8.5 Fr semi-rigid ureteroscope to inspect pelvicalyceal system at first. Lateral renal pelvis wall was bulged because of the cyst. By using tip of the ureteroscope, the urothelium was stripped away to identify the cyst wall. Then, the cyst wall was incised extensively by electrocautery hook in the first patient, and by holmium laser in the second one. At the end of the procedure, a ureteral catheter was inserted in the unroofed cyst to ensure a wide patency between the cyst and the renal pelvis in retrograde pyelography.

**Results:** Our patients discharged on the day of the operation. In two weeks time, postoperative symptoms and images showed significant improvements. There were no complications in these two cases.

**Conclusion:** Ureteroscopic management is a less invasive outpatient procedure in comparison with the other techniques in the selected patients with large parapelvic renal cysts.

### VP3-08 PRESTENTED VERSUS NON-PRESENTED URETERORENOSKOPIC STONE EXTRACTION: A RETROSPECTIVE STUDY

B. Goossens, L. Van wynsberge, S. Füller, A. Lampel—Deutschland

**Background:** Ureterorenoscopy (URS) is the standard operation for ureteral stones. After URS ureteral stents are placed in most

patients to avoid complications following mucosa lesions, obstructive ureteral oedema, postoperative spasms and even ureteral strictures. As an alternative, a ureteral stent can be placed in advance to achieve atonisation of the ureter before URS. We present our experience with pre-stented (secondary) and classic non-prestented (primary) ureterorenoscopic stone surgery.

**Methods:** In a single-centre retrospective study, between 2007 and 2008, 318 secondary URS were compared to 30 primary URS procedures. In these two groups stone-free rates, the need for intraoperative lithotripsy and postoperative ureter stenting, as well as the intra-operative complication rate (e.g. perforation) were analysed.

**Results:** Both groups were comparable for gender and age. A bias was observed since patients who became a primary URS over this period were more likely to have smaller stones in more distal stone positions. In the primary URS-group stone-free rates of 66.7% for ureter and kidney and 90.0% for ureter alone could be achieved, whereas this increased up to 75.8% and 96.0% respectively in the secondary URS-group. Postoperative stenting was needed less frequently after secondary URS (47.2% vs 63.3%). A tendency towards less lithotripsy in the secondary group was noted (16.4% vs 23.3%). Extravasation was not observed in primary URS, in secondary URS this rate was 4.4%, which is explained by the bias for stone size and position.

**Conclusion:** In our clinic, pre-ureterorenoscopy-stenting has become standard. It achieves high stone-free rates, few complications, is easy to perform and can be used as an early training procedure for young colleagues. Possibly, less lithotripsy is needed, and the extraction of bigger stones in an atone ureter is more atraumatic, which can reduce the need for postoperative stenting. Bladder spasms and reflux-caused flank pain are negative side-effects in up to 10% of preoperative stented patients.

### VP3-09 WHAT IS THE APPROPRIATE LENGTH OF URETERAL ACCESS SHEATH FOR FLEXIBLE URETEROSCOPY OF PROXIMAL URETERAL STONES?

J. Teichman, L. Chang Kit—Canada

**Background:** Ureteral access sheaths provide access to the kidney during flexible nephroureteroscopy. Sheaths are currently available from 20 to 55 cm in length. The appropriate length of access sheath should gain access to the ureter just distal to the ureteropelvic junction. We aimed to establish the length of access sheath most suitable for proximal ureteral stones.

**Methods:** Seventy-seven consecutive successful ureteroscopies (52 male, 22 female) were studied. Under cystoscopic and fluoroscopic guidance, the length between the urethral meatus and ureteral orifice and between the urethral meatus and ureter at the level of the iliac vessels were measured using a graduated 5Fr ureteral catheter.

**Results:** The distance from urethral meatus to ureteral orifice was  $25 \pm 2$  cm (max 27 cm) in males and  $8 \pm 1$  cm (max 9 cm) in females. The distance from urethral meatus to level of the iliac vessels was  $30 \pm 2$  cm (max 33 cm) in males and  $15 \pm 1$  cm (max 17 cm) in females.

**Conclusion:** The access sheath should approximate 32 cm in males and 16 cm in females for successful ureteroscopy of proximal ureteral stones.

### VP3-10 COST ANALYSIS OF FLEXIBLE URETERORENOSCOPY AFTER 630 INTERVENTIONS

P. Liske, P. Ober, Y. Aguilar, V. Zimmermanns, S. Lahme—Germany

**Background:** Flexible ureterorenoscopy plays an important role in the treatment of upper urinary tract diseases. Due to the use and technical wear of flexible scopes every procedure causes additional costs. Frequency and costs of repair were analysed.

**Methods:** 630 consecutive flexible ureterorenoscopic procedures were evaluated. In all cases an ureteral access sheath was used. In 514 cases renal pelvic or calyceal stones were treated. In 275 cases holmium laserlithotripsy (230 $\mu$ m fibre) was used. In total the procedures were performed by 12 flexible ureteroscopes (Viper, Richard Wolf Company, Knittlingen, Germany).

**Results:** In total 29 repairs were necessary in 12 instruments. Total costs of repair were Euro 96.037,51. The mean costs per procedure were Euro 152,44. The average durability of each instrument was 21.9 procedures. Repair of flexible scopes was necessary due to alteration of the working channel, the wires for deflection, alteration of the scope's surface and break of optical fibres. Damages were caused by use of holmium laser during operation, sterilisation process and transportation.

**Conclusion:** Flexible ureterorenoscopy is associated with additional costs due to the fragility of instruments. These costs of repair are acceptable as they only account for a minor part of the reimbursement. Because of the shorter treatment time, lower retreatment rate and higher stone free rate than shockwave lithotripsy it is cost-effective to use flexible ureterorenoscopy in endourological stone treatment.

### VP3-11 HOLMIUM:YAG LASER LITHOTRIPSY WITH SEMIRIGID URETERORENOSCOPE FOR TREATMENT OF URETERAL CALCULI (REPORT OF 1432 CASES)

Z. Wu, Q. Ding, H. Jiang, P. Gao, J. Geng, Y. Zhang—China

**Background:** To evaluate the efficacy and safety of holmium:YAG laser lithotripsy with semirigid ureterorenoscope for treatment of ureteral calculi.

**Methods:** A total of 1432 patients with ureteral calculi underwent holmium:YAG laser lithotripsy with a semirigid ureterorenoscope from September 2002 to May 2009. The stones were located in the upper ureter in 381 patients, the mid ureter in 339, and the distal ureter in 712.

**Results:** The overall successful fragmentation rate for all ureteral stones in a single session achieved 93.6% (1341/1432). The successful fragmentation rate stratified by stone location was 81.4% (310/381) in the upper ureter, 94.1% (319/339) in the mid ureter, and 100% (712/712) in the distal ureter. 6 intraoperative perforations (0.4%) were encountered during the procedures. Ureterorenoscopy access failure was happened in 5 patients, 4 of whom with sharply angulated ureters, and the other one with severe BPH. 36 patients complicated with urinary tract infection including 8 with infective shock postoperatively were successfully managed. 2 weeks, 6 months (with a mean of 3.5 months) follow up revealed that the overall stone-free rate for all ureteral stones achieved 95.0% (1244/1310). The stone-free rate stratified by stone location was 81.8% (248/303) in the upper ureter, 96.4% (298/309) in the mid ureter, and 100% (698/698) in the distal ureter. Postoperative ureteral stricture developed in 7 patients (0.5%).

**Conclusion:** Holmium:YAG laser lithotripsy with semirigid ureterorenoscope is a highly effective, minimally invasive and safe therapy for ureteral calculi. It should be indicated as a first choice

of treatment for patients with ureteral calculi, especially for the ones in midureter and distal ureter.

### VP3-12 HOLMIUM LASER LITHOTRIpsy WITH FLEXIBLE URETEROSCOPE FOR UPPER URINARY TRACT CALCULI (REPORT OF 36 CASES)

Z. Xiao-feng, Da-zhi, J. Bo—China

**Background:** To evaluate the Clinical value of Ho: YAG laser lithotripsy with flexible ureteroscope on the treatment of upper urinary tract calculi.

**Methods:** From June 2007 until now, a total of 36 cases of upper urinary tract calculi were treated with VersaPulse Select Ho:YAG laser lithotripter through flexible ureteroscope. They included 23 male and 13 female. Of these cases, 5 cases were proximal ureteral calculi, 24 were renal calculi, 7 were proximal ureteral with renal multiple calculi, associated ipsilateral light or middle degree of hydronephrosis. The calculi were located on the left side in 20 cases, on the right side in 16 cases. The size of the calculi ranged from 0.9 to 2.0 cm (mean 1.5 cm). Flexible ureteroscope can be introduced into the upper urinary tract without prior ureter dilation. If this procedure was proved difficult, ureteral access sheath were available. The laser was used at a maximum energy of 10~20 w with 200 $\mu$ m fiber.

**Results:** All the cases were successful. 36 cases had 53 stones. 7 stones in proximal ureter, 5 stones in renal pelvis and 26 stones in upper or middle calyx. The successful fragmentation rate in one single session was 100%. The stone access rate of the 15 stones in lower calyx was 86.6% (13/15), and the fragmentation rate in one single session was 80% (12/15). The operative time was 25~65 min (mean 50 min). The postoperative hospital stay was 2~7 days (mean 4.5 days). 9 cases received ESWL. The double-J tubes were removed in case of no larger than 3 mm residual fragments post-operatively 2~4 weeks. No major complications were found.

**Conclusion:** Holmium laser lithotripsy with flexible ureteroscope is an effective and safe method for upper urinary tract calculi, especially for those with diameter less than 2 cm and without significant hydronephrosis and those meeting the failure of ESWL and expectantly difficult MPCNL. The successful fragmentation rate for the lower calyceal calculi was lower than the upper or middle calyceal calculi.

### VP3-13 CLINICAL AUDIT OF FLEXIBLE URETEROSCOPY FOR LOWER POLE STONES IN A MAJOR UK STONE UNIT

S. Graham, C. Nathaniel, S. Longhorn, R. Smith, T. Philp, S. Choong

**Background:** We present an audit of one years experience in flexible ureterorenoscopy (FURS) for lower pole stones, in a major london teaching hospital. We perform almost 400 ureteroscopic cases per year and in the specimen year examined, 76 cases were identified for flexible removal of lower pole stones. We have a small local population, a seasonal visiting overseas population, and are the major tertiary referral centre for south east England, north of the River Thames. We demonstrate a 90% clearance rate for all commers of stone size up to 2.5 cm, with stone hardness, infundibulo-pelvic angle, total burden & stone composition not affecting results. Number of stones, did however did affect success. All but 3 patients had less than a 24 hour stay, with half going home the same day. there were no major complications and 3 minor ones.

2 patients were lost to follow up. we maintain that FURS is safe and efficacious in lower pole stones.

**Methods:** A clinical audit of a single year of data from April 2006 to April 2007, with data culled from our own personal database, our electronic patient record, clinical notes and our on line x ray system. Data recorded included stone size, position, composition, number, infundibulo pelvic angle, prior ESWL, prior stenting, complications and stone free rate.

**Results:** 76 patient episodes were indentified. Mean age of the patients treated was 56, and 2/3 were male. 50% had up to 3 stones, but patients had up to 10 stones. 20 patients had had ESWL, either by us or the referring unit. 13 had a stent, and 16 patients were having residual stones removed post PCNL. Stone hardness by houndsfield unit did not predict in this series, failure of ESWL. Success was reported in up to a 30 degree infundibulopelvic angle. only 3 patients required a prolonged stay, longer than 23 hours. 56% of stones removed were calcium oxalate, although, if post PCNL FURS is subdivided, 43% of residual stones are Struvite (20% of all PCNLs done at UCLH are staghorns). 91% of patients were stone free, with only number of stones a predictor of failure. One patient had a prolonged stay for clot retention, one developed a bulbar stricture and one Lower Urinary Tract Symptoms.

**Conclusion:** We conclude that FURS is safe, effective and a potential method of choice in lower pole stones up to 2 cm and should be considered along side ESWL as a treatment option. Care should be taken, however in patients with multiple stones.

### VP3-14 UPPER URETERAL CALCULUS: IS THERE A ROLE FOR SEMI RIGID URETEROSCOPY?

V. Ramakrishnan, J. Murugesan, A. Ganapathy, K. Kailasam, B. Bansal

**Background:** ESWL remains the mainstay of treating Upper Ureteral Calculi. Flexible Ureteroscopy and Lasertripsy has assumed an increasing role. We prospectively analysed the role of Semi Rigid Ureteroscopy (URS) for Proximal Ureteral stones between January 2007 to December 2008.

**Methods:** Patients were investigated with Ultrasound and Excretory Urography or CT (KUB). Solitary upper ureteral calculi (<10 mm) without severe obstruction were advised ESWL in Situ. Patients with larger stone (>10mm), severe obstruction were subjected to URS/JJ Stenting. Patients with very large (>20 mm) calculi, and/or urosepsis requiring PCN/PCNL were excluded. URS was performed after Ureteral dilation, with 7/8.5 FR. or 8/9.8Fr. Wolf Ureteroscope; stones were fragmented with Swiss Lithoclast or pushed back to kidney and stented for subsequent ESWL. The stents were removed following adequate stone fragmentation/clearance. Stone characteristics, treatment regimen, complications and clearance were analysed.

**Results:** 423 patients with solitary upper ureteral calculi were enrolled. 79 patients (18.6%) qualified for ESWL in situ and were excluded from the final analysis. 344 were treated by URS and Lithoclasty. The stone could not be accessed in 22 (6%) and a stent was placed for subsequent ESWL. Complete clearance with URS was achieved in 167 (48%). Partial fragmentation/push back and subsequent ESWL was done in 155 (45%) Residual Ureteric fragments required relook URS in 9 patients. Flexible URS+laser tripsy was done for salvage in 2 patients. Ureteral perforation with Urinoma once required Percutaneous Nephrostomy and stenting. **Conclusion:** ESWL or Flexible URS with Holmium Lasertripsy are the current favoured treatment options for upper ureteral stone

Semirigid URS and auxiliary ESWL offers an alternate affordable option.

### VP3-15 URETEROSCOPY DURING PREGNANCY WITH FOLLOW THE WIRE TECHNIQUE

E. Ehab Rifat Tawfik

**Background:** Purpose To present our experience with ureteroscopy during pregnancy using the technique of following the wire ureteroscopically with no need for fluoroscopy.

**Methods:** Patients and methods The study included 26 pregnant patients suffering from renal colic not responding to medications between March 2002 and January 2009. Most of the patients presented during the second trimester 15 patients, 3 patients during the first trimester and 8 during the last. A 7.5–8 F Semi-rigid ureteroscope was introduced without ureteral dilation by advancing the guide wire GW through the ureteroscope into the ureteric orifice and following it stepwise until the site of obstruction and the GW is advanced past the obstruction under vision to the kidney. The ureteroscope was removed and re-introduced. Lithoclast was used for disintegration and tipless dormia for stone extraction. Stent with string was placed for 5–7 days.

**Results:** Results Ureteroscopy was successfully performed in all patients without ureteral dilation, Stones were detected in 18 patients <6–9 mm. Eleven patients had distal stones while 7 had proximal stones. Fluoroscopy was not required. There were no complications related to the procedure. Requirement for analgesia was reduced due to placement of stents. Stent related complaints were tolerable. All patients completed full term.

**Conclusion:** Conclusion Ureteral obstruction during pregnancy can be safely handled ureteroscopically using the follow the wire technique. It obviates need for ionizing radiation. In experienced hands the technique is safe and reproducible. Application of this technique in non pregnant will reduce exposure to radiation.

### VP3-16 PULSE FREQUENCY, ENERGY AND LENGTH INFLUENCE THE EFFECTIVENESS OF HOLMIUM:YAG LASER LITHOTRIPSY

F. Wezel, C. Hammes, P. Krombach, A. Häcker, M. Michel, T. Bach—Germany

**Background:** We evaluated the influence of pulse frequency, power and length on the effectiveness of Holmium:YAG (Ho:Yag) laser lithotripsy using two different artificial stone compositions in-vitro.

**Methods:** Three different Ho:Yag laser devices (Sphinx, RevolixDuo (both LisaLaser, Germany) and Odyssey 30 (Cook, Ireland) were tested. The lasers were used at different pulse energy rates (1 and 2 Joule) and frequency settings (5 and 10 Hz) resulting in an output power of 10 W, respectively. Where possible (Sphinx, Odyssey 30), pulse length was modified (350 vs. 700 msec). The light was transmitted via flexible 365 $\mu$ m fibers. Experiments were performed in a water bath using artificial soft stone (plaster of paris) and hard stone (Fujirock stone type 4) composition. Lithotripsy was performed for 60 sec in contact mode. Fine granulated sand was used to measure the volume of the craters.

**Results:** In all of the tested groups, a slower pulse rate in combination with increased pulse energy (5 Hz/2 J vs. 10 Hz/1 J) resulted in a higher stone disintegration when applied on both hard and soft stone composition. Reduction of the pulse length from 700 to 350 msec resulted in a significantly higher stone disintegration in soft stone composition. In hard stone composition, reducing the

pulse length was associated with higher stone disintegration only in combination with slower pulse rates (5 Hz, 2 J) but not at higher pulse rates (10 Hz, 1 J).

**Conclusion:** Our results indicate that pulse frequency, energy and length are determinants of stone disintegration rates of Holmium:YAG laser lithotripsy, in some extend depending on the stone composition. This may help to improve effectiveness of Holmium:YAG laser lithotripsy in clinical application.

### VP3-17 URETEROSCOPIC LASER FRAGMENTATION IN THE FIRST LINE TREATMENT OF LARGE RENAL CALCULI

S. Patel, S. Kommu, A. Jain, T. Green, A. Blacker

**Background:** Percutaneous nephrolithotomy (PCNL) is commonly regarded as the treatment modality of choice for managing renal calculi greater than 2 cm. Ureteroscopy with laser fragmentation has been noted as a useful minimally invasive alternative. We aimed to identify the efficacy of ureteroscopy with laser fragmentation as a first line modality in the treatment of large renal calculi in selected cases.

**Methods:** We prospectively collected data pertaining to a total of 19 patients who were treated with ureteroscopic laser fragmentation for intrarenal calculi greater than 2.0 cm. The stone-free rate was defined as no visible stone on X-ray (kidney, ureter and bladder) KUB and 2 mm or less on ureteroscopy or CT. All patients underwent follow-up imaging with either an X-Ray and/or CT scan.

**Results:** The total number of renal calculi was 40 from 21 renal units with a mean number of stones per patient of 2.1. The mean stone burden was 41.3 mm (range: 21–80 mm). All patients underwent ureteroscopic laser fragmentation with an average of 2 procedures per renal unit. The Stone-free rate after a single treatment of ureteroscopic stone fragmentation was 47%. Overall stone-free rate after treatment with ureteroscopic laser fragmentation including other adjunctive treatment modalities (shock wave lithotripsy and repeat ureteroscopy) was 66%. The remaining 33% of patients are still undergoing follow up. There was one death within 30 days of surgery from unrelated causes in a patient with serious co-morbidities. Minor complications occurred in 7 of 21 patients (ureteroscopic complication rate of 29%) including steinstrasse and postoperative urosepsis, acute retention of urine, postoperative pain, haematuria and post op pyrexia. Only the patient with sepsis secondary to steinstrasse needed active intervention in the form of a stent change.

**Conclusion:** In appropriate cases, the management of large intrarenal calculi by ureteroscopic laser fragmentation is safe and efficacious. This is a useful alternate first line treatment mode to PCNL with low morbidity. The role of ureteroscopic laser fragmentation in large calculus treatment should be explored further.

### VP3-18 THE ROLE OF FLEXIBLE URETERORENOSCOPY IN THE TREATMENT OF LOWER POLE RENAL STONES

S. Willis, N. Smith, N. Hegarty, J. Glass, K. Thomas

**Background:** Due to poor drainage and difficult anatomy, treatment of lower pole renal stones is often unsuccessful. Optimal treatment is debated. Currently the main options are shock wave lithotripsy (SWL) and percutaneous nephrolithotomy (PCNL). However flexible ureterorenoscopy (fURS) with laser lithotripsy is emerging as an alternative.

**Methods:** We present prospective data from November 2007 to November 2008 to illustrate our experience with fURS for lower pole stones.

**Results:** 132 patients were treated. Median age: 51 years. Mean stone length: 9.8 mm (3–24.1 mm). Mean surface area: 71.6 mm<sup>2</sup>. 11 patients (8%) were anticoagulated (4 warfarin, 7 antiplatelet agents). 8 (6%) had solitary kidneys. 12 (9%) weighed more than 120 kg. 1 (1%) was hepatitis B positive. Stone clearance was 54%: 61% in stones smaller than 15 mm (113 patients); 32% in stones 15 mm or larger (19 patients). All residual stones were cleared with further URS or ESWL. Complication rate was 8% (4 fever, 3 pain, 1 urinary retention, 1 stent requiring GA removal, 1 sepsis). Median length of stay 3 days.

**Conclusion:** Modern flexible ureterorenoscopes in conjunction with holmium laser lithotripsy allow safe and effective treatment of lower pole stones. Results obtained in our unit compare favourably with those obtained by fURS and SWL in other published studies.

### VP3-19 BILATERAL URETEROSCOPY ASSESSMENT AND OUTCOME

E. Ehab Rifat Tawfik

**Background:** Our aim in this study is to evaluate the safety and efficacy of performing bilateral ureteroscopy for distal ureteral stones at the same session compared to staged procedure.

**Methods:** This study included 31 patients with bilateral distal ureteral calculi operated up on at same session in the period between March 2001 and May 2006. Small diameter ureteroscopes (6.9–8 F) were used and pneumatic lithotripsy was available when required. We used to start with the easier side first.

**Results:** Bilateral ureteroscopy was successfully performed in 24 out of 31 patients. It was some times technically difficult to go through the other side either due to disturbed field of vision, failure of access, anesthetic reasons or even elective when the duration of the first side is prolonged. Starting with the easier side definitely contributed to the success rate. Morbidity is relatively increased compared to staged procedure, mostly because of use of two stents. Also it was related to dealing with two renal units at the same time.

**Conclusion:** Bilateral ureteroscopy can be applied safely and effectively with the advantages of reduced cost and decrease the number of anesthesia required. Morbidity is relatively increased compared to staged procedure but mostly related to the use of bilateral stents and dealing with two renal units. Key words ureteroscopy stones distal ureter.

### VP3-20 FLEXIBLE URETERORENOSCOPY WITH HOLMIUM LASER (6 YEARS SINGLE CENTRE EXPERIENCE)

O. Traxer, S. Alqahtani, D. Legraverand, M. Ndoye, M. Demesmeaker—France

**Background:** We assessed the effectiveness and safety of flexible ureterorenoscopy with holmium:YAG laser for managing different pathological conditions of upper urinary tract in a reference centre.

**Methods:** From February 2003 to May 2009, 1206 ureterorenoscopic procedures were done in our institute for 822 patients. All the data had been collected retrospectively. Indication of treatment: stone disease, upper urinary tract malignancies, Ureteropelvic junction (UPJ) obstruction, diagnostic and other pathologies. Patients pain scale, rate of complications and the hospital stay had been recorded.

**Results:** Our data showed 453 procedures (36%) in female patients and 753 (64%) in male patients. 831 (69%) procedure for stone disease, 185(15.3%) upper tract tumors (UUT-TCC), stone and tumor in 5(0.4%), UPJ obstruction in 23(1.9%), 123(10.2%) for diagnostic purposes, ureteral strictures in 16 (1.3%) and 18(1.5%) for unknown microscopic hematuria. The ureteroscope was used in 35 calyceal diverticula, 23 horseshoe kidney and 33 solitary kidneys. For urolithiasis, 822 patients underwent 836 procedures, we found that 460, 102, 31, 14, 2 and 1 patient underwent 1, 2, 3, 4, 5 and 8 sessions of flexible ureterorenoscopic procedure respectively.

**Conclusion:** Holmium:YAG laser lithotripsy is a highly effective and safe treatment modality for managing of varieties pathological conditions of upper urinary tract with low rate of complications and brief hospital stay.

## VP4: PCNL-I

### VP4-01 PERCUTANEOUS NEPHROLITHOTOMY CAN BE PERFORMED SAFELY IN PATIENTS WHO HAVE PURULENT FLUID AT INITIAL PUNCTURE

A. Unsal, C. Kara, B. Resorlu, I. Cicekbilek

**Background:** Some patients undergoing percutaneous nephrolithotomy (PCNL) have purulent fluid during initial puncture although preoperative laboratory tests were normal. We report the management and outcome of PCNL in 15 patients who have purulent fluid during the initial puncture.

**Methods:** Among the 517 patients who underwent PCNL at our center from November 2006 to June 2009, 15 had purulent fluid in the kidney at initial puncture. These patients were asymptomatic, and the preoperative laboratory and clinical findings did not

suggest infection. We evaluated preoperative findings, operative details, stone-free rate, intraoperative and postoperative complications, and final outcome of these patients.

**Results:** Male to female ratio was 9:6 and mean age was 46.6 years (range 31–55). Ten patients (66.7%) required single tract, while 5 (33.3%) required multiple tracts (2 to 3). The calculi were fragmented successfully by pneumatic/ultrasonic lithotripter in all patients. Complete stone clearance was achieved in 13 (86.6%) patients after the first stage. Mean operative time was 70 minutes. Results of urine cultures showed E.coli in three patients and Klebsiella pneumoniae in two patients; results of urine cultures of 10 (66.7%) patients were negative. Four (26.6%) patients with positive urine culture experienced <38°C fever for 12 to 24 hours. They were treated with antibiotics successfully. None of the pa-

tients experienced any complications. The range of hospital stay was 2 to 3 days, and for patients with postoperative fever was 3 to 5 days. We had no cases of sepsis or sepsis syndrome.

**Conclusion:** In patients who undergone PCNL even with sterile urine culture, purulent fluid may be aspirated during the initial the puncture. PCNL can be performed safely with antibiotic coverage.

#### **VP4-02 SUPRA VS. INFRA-COSTAL PCNL IN THE MODERN ERA**

K. Pace, D. Ghiculete, S. Pace, A. Ray, R. Honey—Canada

**Background:** Percutaneous nephrolithotomy (PCNL) is the gold-standard therapy for large renal calculi. The site of puncture into the collecting system has been the subject of debate, with many suggesting that supracostal access tracts lead to greater morbidity. We report a retrospective review of 185 consecutive PCNL cases from Jan, 2005 to June, 2009.

**Methods:** Pre-, intra-, and post-operative data was collected on 185 PCNL cases performed from Jan, 2005 to June, 2009. Patients were followed post-operatively with KUB and CT scans. Stone free was defined as no stone visible on KUB and no stone or tiny papillary fragments <2 mm on CT scan.

**Results:** 185 cases (58.6% male) with mean BMI = 28.2 (SD 5.8). Stone trended to be larger for supra-costal vs. sub-costal access (543 vs. 426 mm<sup>2</sup>, p = 0.08); and 31 (16.8%) were staghorn calculi. 11 (5.9%) of the tracts were above the 11th rib, 80 (43.3%) above the 12th rib, and 94 (50.8%) below the 12th rib. A single tract was used in 181 (97.8%). There were no difference in stone free rates (87.9 vs. 94.6%, p NS) in supra- vs. sub-costal accesses. There were no blood transfusions. Chest complications were noted in 13.8% vs. 1.1% of the supra- vs. sub-costal accesses (p 0.001), however intervention (chest drainage) was required in only 6.6% (p = 0.047).

**Conclusion:** When indicated, supra-costal access can provide excellent outcomes, particular for patients with complex stone disease, and may obviate the need for multiple tracts. Chest complications can occur, but are uncommon and require intervention less commonly.

#### **VP4-03 SUPINE PERCUTANEOUS NEPHROLITHOTOMY WITH SUPRACOSTAL ACCESS: IS IT SAFE?**

F. Vicentini, E. Chedid Neto, E. Mazzucchi, A. Danilovic, G. Ebaid, M. Srougi

**Background:** Percutaneous nephrolithotomy in supine position is a very well accepted technique to treat large renal stones. The supracostal access in this position is poorly described and its safety is unknown. Our objective is to report our experience with supracostal access in supine percutaneous nephrolithotomy.

**Methods:** We review the records of patients that underwent to supine percutaneous nephrolithotomy with at least one supracostal access. We analyzed the age, sex, side, body mass index (BMI), stone size, type of stone, number of punctures, surgical time, bleeding, transfusion rate, surgical complications, and stone-free rate. All patients had chest radiography performed immediately after surgery and a nephrostogram or a CT scan to evaluate residual stones.

**Results:** Between June 2001 and June 2009, twelve patients (4 male) with mean age of 43.4 years (range of 19 to 71) underwent to twelve supine percutaneous nephrolithotomy with at least one supracostal tract. Right kidney was affected in 83.3% of patients. Mean BMI was 27 (19 to 39). Stone size range from 20 and 60 mm

(mean 34 mm). Fifty percent of the stones were staghorn, 25% were pyelic and 25% were multiples. Supracostal was the sole access in 66.6% of patients and all supracostal accesses were between 12th and 11th rib. Medium calix was punctured in 50% of the accesses, superior in 25% and inferior calix in 25%. Intraoperatively, bleeding occurred in one patient who had 2 blood units (8.3% of transfusion rate). The mean drop in hemoglobin level was 1.42 g/dL (0.2 to 4.0 g/dL). Our overall stone-free rate was 83.3% after mean of 1 percutaneous nephrolithotomy and 0.54 auxiliary procedures. No patient had sepsis or injury to the lung, liver, spleen or colon.

**Conclusion:** Supracostal access between 12th and 11th rib in supine percutaneous nephrolithotomy is possible to be made and in our series was safe and effective.

#### **VP4-04 MINI-PNL VS. CONVENTIONAL "TUBE" PNL: IS THERE ANY BENEFIT FOR THE PATIENT?**

T. Knoll, F. Wezel, M. Michel, G. Wendt—Nordahl

**Background:** Percutaneous nephrolithotomy (PNL) remains the standard therapy for renal calculi >20 mm. The introduction of so-called Mini-PNL with reduced sheath diameters led to use of percutaneous procedures even for smaller calculi, following the idea of a reduced morbidity. Thus, aim of this study was to compare outcome and complications of conventional and Mini-PNL.

**Methods:** In this prospective, non-randomized study 50 consecutive patients with solitary renal calculi located in the lower pole or renal pelvis were treated either by conventional PNL (26F sheath, Karl Storz Endoscopes) or Mini-PNL (MPNL; 18F sheath, Karl Storz Endoscopes). Ultrasound (Calcuson, Karl Storz Endoscopes) or Holmium laser probes (StarMedTech) were used for lithotripsy. Patients were treated tubeless after uncomplicated MPNL, with thrombin-matrix tract closure (FloSeal, Baxter) and antegrade DJ placement, while after PNL all patients received 22F nephrostomies. The following parameters were assessed: age, gender, BMI, stone size and location, OR time, intra- and postoperative complications, stone free rate at day 1, postoperative pain (visual analogue pain scale (VAS), use of analgesics), duration of hospital stay.

**Results:** Patients characteristics were comparable in both groups, except of stone size with 18 ± 8 mm (MPNL) and 23 ± 9 (PNL; p = 0.042). OR time was 48 ± 17 vs. 57 ± 22 min. (n.s.). After MPNL 96% were stone free at day 1 compared to 92% after PNL. (n.s.) Significant complications did not occur in both groups (transfusion rate 0%). Minor complications were: fever 12% (MPNL) vs. 20% (PNL; p = 0.000), bleeding 4% vs. 8%, perforations 0% vs. 4% (all n.s.). Overall outcome was not influenced by BMI. Patients required slightly less pain medication after tubeless MPNL (VAS: 3 ± 3 vs. 4 ± 3; p = 0.048, analgesics: 25 ± 12 mg/d vs. 37 ± 10 mg/d; n.s.). Hospital was slightly shorter after MPNL (3.8 vs. 4.9 d; n.s.).

**Conclusion:** Conventional and Mini-PNL are both safe and effective procedures for treatment of renal calculi. A slightly shorter hospital stay and less pain medication may support the use of Mini-PNL at least for intermediate sized stones. Further prospective studies are necessary to determine the value of Mini-PNL when compared to conventional tubeless procedures.

#### **VP4-05 MINIMALLY INVASIVE PERCUTANEOUS NEPHROLITHOTOMY FOR TREATMENT OF UPPER URINARY TRACT CALCULI IN OBESE PATIENTS**

Z. Xiao-feng, L. Min, X. Hui—China

**Background:** To evaluate the safety and efficacy of minimally invasive percutaneous nephrolithotomy for treatment of upper urinary tract calculi in obese patients.

**Methods:** We retrospectively analyzed 42 obese patients with upper urinary tract calculi registered in our hospital from January 2008 to May 2009, compared with 194 natural-weight patients with similar clinical characteristics. The two groups both underwent MPCNL during the same period. The parameters including BMI index, operating time, necessity for secondary procedures, postoperative hospital stay, stone-free rate, and intraoperative and postoperative complications were analyzed between the two groups.

**Results:** All the procedures were successful. A significant difference was found in the BMI index between the obese patients (mean, 38) and the natural-weight patients (mean, 21) ( $p < 0.05$ ). No difference was found in operative duration, postoperative hospital stay, stone-free rate, and perioperative complications between the two groups ( $p > 0.05$ ). No difference was also found among the various degrees of obese patients ( $p > 0.05$ ).

**Conclusion:** MPCNL is a safe and effective method for the treatment of the upper urinary tract calculi in obese patients.

#### VP4-06 THE CANADIAN STONEBREAKER TRIAL: A RANDOMIZED, MULTICENTRE TRIAL COMPARING THE LMA STONEBREAKER AND THE SWISS LITHOCLAST DURING PERCUTANEOUS NEPHROLITHOTOMY

B. Chew, R. Paterson, O. Arsovska, D. Lange, D. Beiko, R. Honey, K. Pace

**Background:** Percutaneous nephrolithotripsy (PNL) is the preferred treatment for renal stones greater than 2 cm. The StoneBreaker™, a hand-held pneumatic lithotripter, is powered by a compressed carbon dioxide cartridge. The purpose of this study is to compare the LMA StoneBreaker™ to the Swiss LithoClast R pneumatic lithotripter.

**Methods:** From January 2008 to June 2009, we prospectively randomized patients undergoing PNL to either the LMA StoneBreaker or the Swiss LithoClast. The primary outcomes were the time to 1) fragment the stone, 2) pluck the fragments and 3) remove debris using ultrasonic (US) lithotripsy. Secondary endpoints included stone free rate, time to setup each device, ease of use, endoscopic visualization, damage to mucosa, and device-related complications.

**Results:** Of the 63 patients, 37 were randomized to StoneBreaker and 26 to the Swiss LithoClast arm. The StoneBreaker ( $8.72 \pm 1.06$  mm<sup>2</sup>/s) was significantly faster at fragmenting stones ( $4.47 \pm 0.65$  mm<sup>2</sup>/s,  $p = 0.003$ ) and at total lithotripsy time ( $667.30 \pm 92.32$  mm<sup>2</sup>/s vs  $989.5 \pm 129.74$  mm<sup>2</sup>/s,  $p = 0.0415$ ) than the SwissLithoclast. The StoneBreaker was significantly faster to setup ( $p = 0.02$ ), was easier to use ( $p < 0.01$ ) and resulted in less operator fatigue ( $p < 0.05$ ). Visibility and epithelial damage were not significantly different. The stone free rates and stone composition was similar in both groups. There were no device-related complications in either group.

**Conclusion:** The StoneBreaker pneumatic lithotripter produces an equivalent stone free rate to the Swiss LithoClast with no complications and provides significantly faster setup, stone fragmentation and lithotripsy time.

#### VP4-07 KIDNEY-URETERAL-BLADDER CALCULUS—WHOLE URINARY TRACT STONE WITH 7 YRS RETAINED DJ STENT: MANAGED ENDOUROLOGICALLY

T. Hareh

**Background:** Ureteral stents are integral part of urological procedures but if not changed or removed at a given time it can lead to dangerous complications and legal dilemma. Stent encrustation is one of the most difficult complication to manage. Management of such complicated ureteral stent with calculus requires a multimodal therapeutic approach.

**Methods:** We present such a case of 42 yrs gentleman who underwent left ureterolithotomy in 2000 with stent and presented with urosepsis with left urinary tract calculus extending from calyx to bladder with broken stent. After stabilization, functional evaluation of urinary tract he underwent staged endourological procedures and successfully made stone and stent free.

**Results:** First of all patient was stabilized with good hydration and antibiotics. Then renal functional evaluation was done with IVU. Once good renal function was documented on the stent side then He underwent cystolithotripsy and ureteroscopy with intracorporeal lithotripsy and lower fragmented stent removal. Second stage was planned for upper stent removal and upper ureteric and renal calculus removal. He was made free of stone completely with multimodal endoscopic intervention and was discharged on 6th day. Stent was placed again with special consent for its removal taken. Follow up upto 10 months was done and he was asymptomatic.

**Conclusion:** Although successful management using endourological techniques rendered the patient stent–stone free and preservation of renal function, the complexity of the procedure emphasizes the need for prevention of such complication.

#### VP4-08 PERCUTANEOUS NEPHROLITHOTOMY: NEPHROSTOMY OR TUBELESS OR TOTALLY TUBELESS?

M. Istanbuluoglu, T. Cicek, B. Ozturk, M. Gonen, H. Ozkardes—Turkey

**Background:** To compare the feasibility and morbidity of tubeless, totally tubeless and standard PNL with nephrostomy tube in a single center with selected patient population.

**Methods:** Between July 2006 and February 2008, PNL was performed in 176 patients in this retrospective study. Patients with no serious bleeding or perforation in the collecting system during the operation, stone free or CIRF ( $< 4$  mm) at the end of the procedure and those with no more than one access were enrolled in the study. Patients were categorized into three groups. In group 1 ( $n = 43$ ) no nephrostomy or ureter catheters were placed after PNL (totally tubeless group); in group 2 ( $n = 41$ ), no nephrostomy catheter was placed but antegrade J-stent was used (tubeless group) while standard nephrostomy catheters were placed in 92 patients in group 3 (standard group). Three groups were compared with respect to age, stone volume, postoperative hemoglobin change, transfusion rate, operation time, analgesic requirement, hospitalization time and complication rates.

**Results:** No significant differences were found in mean stone volume, operation time, transfusion rates and hemoglobin level change between the groups. However, hospitalization time and the amount of narcotic analgesic required were significantly higher in group 3 compared to the other groups ( $p < 0.05$ ). Complications

were observed in 2 (4.6%), 3 (7.3%) and 7 (7.6%) patients in groups 1, 2, and 3 respectively ( $p = 0.738$ ).

**Conclusion:** In patients with no major intraoperative bleeding and calyceal perforation tubeless approach is safe with decreased analgesia requirement and hospital stay. However, totally tubeless procedure should be reserved for those without any residual stones, so the “totally tubeless” approach is not dangerous in highly selected patients.

#### VP4-09 PERCUTANEOUS NEPHROLITHOTOMY IN HORSE-SHOE KIDNEYS

I. Aridogan, V. Izol, Y. Bayazit, Z. Tansug, S. Zeren—Turkey

**Background:** Percutaneous nephrolithotomy (PNL) is a “Gold Standard” treatment modality in larger kidney stones. It is also a well accepted procedure for the stones in horseshoe kidneys. The results of PNL treatment in horseshoe kidneys are reviewed.

**Methods:** Between September 1998 and June 2009, 36 patients with “horseshoe kidney” underwent 41 PNL procedures on 40 renal units. The mean age of the patients were 34 years (3–72) and the average stone burden was  $497 \text{ mm}^2$  ( $100\text{--}2800 \text{ mm}^2$ ). In 34 procedures pneumatic lithotripter was used for the fragmentation of calculi and in 9 stones were extracted intact by forceps. Because of the deep localization of horseshoe kidneys flexible nephroscope and flexible zero-tip nitinol baskets were required to extract the fragmented stones.

**Results:** In 32 procedures (78%) single access and in 9 multiple accesses were used. Thirty-seven renal units (92%) were stone-free at the time of discharge. Two had clinically insignificant residual fragments and a shock wave (SWL) treatment was planned for the third patient. Because of intraoperative hemorrhage two units of blood transfusion were required in one patient (2.5%) and no other serious complication was seen. The mean hospital stay was 4.0 days (range 2–12).

**Conclusion:** Percutaneous surgery in horseshoe kidneys for the treatment of renal stone disease has some special features due to ectopia, malrotation and vascular alterations. These patients usually require upper pole access and flexible nephroscopy to enter the kidney and reach the stones easily. With meticulous and cautious surgery, it is possible to obtain high success rates as in normal kidneys.

#### VP4-10 ENDOUROLOGICAL TREATMENT OF CALYCEAL DIVERTICULUM STONES—INDICATIONS AND RESULTS

Y. Aguilar, P. Liske, V. Zimmermanns, S. Lahme

**Background:** Due to the anatomical conditions of calyceal diverticulum stones results of extracorporeal shockwave lithotripsy (SWL) are very poor. Even after successful desintegration, the stonefree rate is only about 50% because of diverticulum neck obstruction. Since introduction of new miniaturized endourological instruments the technical feasibility of these procedures has been significantly improved. The main advantage is to combine treatment of the morphological obstruction and the removal of the stone.

**Methods:** 37 patients were treated in total. 8 patients underwent ureterorenoscopy (URS) (A). 20 patients underwent minimal invasive percutaneous nephrolithotomie (MPCNL) (B) and 9 received a combination of both procedures (C).

**Results:** The overall stonefree-rate was 81.8%. In the patients who underwent URS a stone-free rate of 75% was achieved. The stone-

free rate with URS for the upper calyceal group was 84%, for the middle calyceal group 100% and for the lower calyceal group 50%. In group B, overall stone-free rate was 96%, 100% in the upper calyceal group, 100% in the middle calyceal group and 91% in the lower calyceal group. For group C, a stone-free rate of 78% was achieved. 50% in the upper calyceal group, 100% for the middle and the lower calyceal group. It was possible to treat the calyceal diverticulum neck every time.

**Conclusion:** In comparison with SWL a high stone-free rate can be achieved with new minimal-invasive endourological instruments. The advantage of this method is the additional treatment of the obstruction due to the calyceal diverticulum neck, which is necessary to prevent stone-recurrence. The complication-rate of endourological treatment was very low. In conclusion the endourological approach to calyceal diverticulum stones is superior to SWL. The decision whether to use MPCNL or URS should depend on the stone localization.

#### VP4-11 PERCUTANEOUS NEPHROLITHOTOMY FOR STONES IN PATIENTS WITH HORSESHOE KIDNEY: A SINGLE-CENTRE EXPERIENCE

A. Unsal, C. Kara, B. Resorlu, I. Cicekbilek—Turkey

**Background:** Horseshoe kidney is the most common fusion anomaly of the kidney. Percutaneous nephrolithotomy (PCNL) is a well accepted procedure for the large stones in horseshoe kidney. However, PCNL in horseshoe kidney may be difficult due to abnormal anatomic configuration and vascularization. In this study, the results of 14 PCNL cases with horseshoe kidney are presented.

**Methods:** A total of 517 PCNL operations were performed at our institution from November 2006 to June 2009. Fourteen patients (12 male, 2 female) had horseshoe kidney anomalies. The mean age was 35.4 years (range 28–52) and the average stone burden per kidney was 2.88 cm (range 2.5–5.5 cm). Renal access was made in upper pole of the kidney in 9 patients and in mid-pole in 5 patients. A 26F semirigid nephroscope (Olympus, Japan) was used for nephroscopy. The stones were disintegrated by ultrasonic and/or pneumatic lithotripter. Flexible nephroscopic control was performed on all patients at the end of the each operations to improve stone-free rates. Operation and fluoroscopy time, complication rate, tract number, use of auxiliary procedures, and length of hospital stay were recorded.

**Results:** Mean operative and fluoroscopic screening time were 65.3 (40–95), 2.9 (1.5–5) minutes respectively. The stones were cleared by a single tract in 10 cases (71.5%), and 4 cases (28.5%) required 2 tracts. Twelve patients (85.8%) were stone-free at the time of discharge. Auxiliary procedures were required in 2 renal units (14.8%) and included ureteroscopy in 1, and SWL to residual fragment in one patient. None of the patients in the present series developed visceral or vascular injury. One patients required a blood transfusion. The mean hospital stay was 3.2 days (range 3–5).

**Conclusion:** Despite the presence of anatomic abnormalities, PCNL is a safe and effective management option for calculi in the horseshoe kidney in the experienced hands.

#### VP4-12 FLOUROSCOPIC PCNL ACCESS BY A UROLOGIST, THROUGH A MENTORED TRAINING PROGRAMME. A SERVICE EVALUATION STUDY

A. Mangera, S. Mehta, F. Salim, J. Hall—England



**Background:** The place of gaining access at PCNL is shared between clinical Radiology and Urologists, depending upon local expertise. Historically, in our unit, radiologists have gained access. However, due to waiting list pressures and limited radiologist availability we identified the need to develop a urological access service. Therefore our aim was to develop a Urology access service using fluoroscopy alone, thereby negating ultrasound.

**Methods:** We identified suitable cases for more simple and potentially less morbid access at our Endo-urology MDT meeting based on; lower pole renal access, a planned single track, no complex renal / adjacent organ or bony anatomy to navigate and suitable body habitus. The urologist performed 10 cases under direct supervision and then further cases with a decreasing level of assistance. The mentoring programme of 15 cases took one year. A non-randomised control arm of comparative cases was taken from the radiologists series to identify any differences in outcomes. We collected data on stone size, demographics and clearance and also with regard to length of hospital stay and mean drop in haemoglobin. Morbidity data included the presence of fever, colic or tract site leak as well as the need for transfusion and embolisation.

**Results:** During mentored training, the urologist required radiological ultrasound support in three cases. One where bony anatomy prevented lower pole access and in two cases where there was concern over potential colonic injury. Since the end of the mentored training period, only one case required relisting for radiological ultrasound guided access. There were no comparative differences in stone clearance and complication rates between the two arms of the study. •

**Conclusion:** PCNL access by a mentored urologist is comparably safe, with no increase in complication rates or morbidity. In our unit we identified approximately one in four cases to be 'uncomplicated access' suitable for fluoroscopic guidance alone by the urologist. By developing this service we can obviate the need of the radiologist in selected cases, which has time, resource and cost benefit implications.

#### VP4-13 MINIMAL INVASIVE PCNL IN OLDER PATIENTS - ANALYSIS OF OUTCOME AND MORBIDITY IN 57 CONSECUTIVE PATIENTS AGED 70 AND ABOVE. DEPARTMENT OF UROLOGY, SILOAH ST. TRUDPERT HOSPITAL, PFORZHEIM, GERMANY

V. Zimmermanns, P. Liske, P. Ober, S. Lahme

**Background:** Minimal invasive PCNL (MPCNL) is used in the treatment of nephrolithiasis as an alternative treatment to shock wave lithotripsy or conventional PCNL in suitable cases. Previously published data demonstrated a high efficiency and low morbidity of the method. This study analyses the data of 57 consecutive patients aged 70 years (y) or above compared with 278 younger patients to evaluate the applicability of the method in aged patients.

**Methods:** 57 patients (range 70 to 92 y, mean age  $75.0 \pm 4.2$  y) were treated by a miniaturized PCNL (MPCNL) equipment, including a 12 F nephroscope and an 15 F Amplatz sheath. Data on the stone size and location, stone-free rate, blood transfusions, operating time and complications were recorded prospectively. Results were compared with the data of 278 consecutive younger patients. Student's t-test or Chi-square test were used for statistical testing.

**Results:** Average stone size was  $4.7 \text{ cm}^2$  on the plain x-ray film and did not differ from controls ( $4.2 \text{ cm}^2$ ). Furthermore no statistically significant differences could be detected for mean operating

time ( $62 \pm 28$  min. vs.  $68 \pm 30$  min.), stone-free rate (90% vs. 89%), and transfusion rate (1.8% vs. 1.8%). The necessity for re-treatment to achieve endoscopically and radiographically assured absence of residual fragments tended to be lower (21% vs. 32%) but did not reach statistical significance. A significant difference ( $p < 0.05$ ) however was revealed for postoperative febrile episodes. There was no relevant fever episode in older patients (0%) whereas fever was observed in 7.9% of controls.

**Conclusion:** MPCNL demonstrated to be well applicable in older patients. Results are independent of age in terms of stone-free rates and treatable stone burden. There was no higher morbidity in aged persons compared with younger individuals. Therefore, in aged patients MPCNL can be regarded a safe and reliable alternative treatment modality to SWL and PCNL in suitable cases, as well.

#### VP4-14 EFFECT OF THE STONE AND PATIENT RELATED PARAMETERS ON TIME DURATION OF PERCUTANEOUS NEPHROLITOTOMY OPERATION AND THE LENGTH OF HOSPITALIZATION: ANALYSIS OF 1466 PATIENTS

T. Akman, E. Sari, M. Binbay, K. Tepeler, A. Muslumanoglu, A. Tefekli—Turkey

**Background:** To evaluation effect of the stone and patient related parameters on the duration of PNL and length of hospitalization (LOH).

**Methods:** During 7 years period, the records of 1466 patients with renal calculi who underwent PNL were reviewed retrospectively. According to median, duration of operation time (median = 60 min) and LOH (median = 2 days) were categorized to two groups. Multivariate binary logistic regression analysis was used for detecting the effects of independent variables included patient age, sex, body mass index (BMI), history of SWL or open surgery, stone size and opacity, presence of hydronephrosis, localization and number of access, per-operative and post-operative findings and complications on the duration of PNL and LOH.

**Results:** The mean operation time and LOH were  $62.6 \pm 25.4$  (10–210) min and  $2.9 \pm 1.6$  (1–21) days respectively. Overall success was achieved in 84.7%. According to outcome of multivariate analysis, stone size ( $p < 0.0001$ , OR = 1.97), presence of hydronephrosis ( $p = 0.014$ , OR = 2.1), bleeding blurring the vision during operation ( $p < 0.0001$ , OR = 1.7) and number of access ( $p < 0.0001$ , OR = 1.4) are significant independent predictors on the duration of operation during PNL. On the other hand, BMI ( $p = 0.008$ , OR = 0.82), stone size ( $p = 0.01$ , OR = 1.2), number of access ( $p < 0.0001$ , OR = 1.7) and postoperative fever or sepsis ( $p = 0.001$ , OR = 4.5) are factors influencing LOH.

**Conclusion:** Stone size and access number significantly affect the both operation time and LOH. However, presence of hydronephrosis and bleeding blurring the vision influence the operation time. Present data demonstrated statistical relationship between BMI and LOH. Post-operative fever and sepsis after PNL significantly increase LOH.

#### VP4-15 MINIPERC EXPERIENCE IN PEDIATRIC STONE DISEASE

L. Günay, C. Bilen, B. Tan, K. Inci, E. Ozden, S. Elhaj—Turkey

**Background:** We have analysed the efficacy and morbidity of miniperc operations in pediatric stone disease.

**Methods:** Eighteen percutaneous nephrolithotomy operations were performed using minimal access (14 F) instruments in 17 (m: 13, f: 4) patients in urology clinics of centers. All operations were

applied under general anesthesia with parenteral antibiotic prophylaxis. After cystoscopy and retrograde placement of 4 F soft ureteral catheters the patients were brought to prone position. Percutaneous access was established via fluoroscopic guidance. A pediatric working cystoscope (9.5 F) was used through 14 F tract. Holmium laser and pneumatic lithotriptors were used for in situ lithotripsy. The ureteral catheters were left indwelling in all without bleeding otherwise a 14 F nephrostomy catheter was used for diversion.

**Results:** Mean patient age was 5.0 (2–8). One had open surgery previously. Sixteen were managed through a single access and two needed a second one. Mean operation time was 78.4 minutes (40–165) and mean stone size was 204 mm<sup>2</sup> (97–550). Two needed blood transfusion. Mean postoperative hospitalization time was 3.1 (2–5) days. In 13 of the 18 renal units complete stone clearance has been achieved. Four of the patients with the residual fragments have undergone ESWL and three of them have become stone free. One patient was left with clinically insignificant fragments.

**Conclusion:** The smaller instrument sizes in percutaneous nephrolithotomy can give good results in pediatric age group however transfusion rates are similar especially in cases with larger stones and longer operation times.

#### VP4-16 TITLE: USE OF ABSORBABLE GELATIN SPONGE AS AN ADJUNCT TO “TOTALLY TUBELESS PERCUTANEOUS NEPHROLITHOTOMY”

R. Kapoor, R. Maheshwari, A. Mandhani—India

**Background:** To study the efficacy and safety of totally tubeless percutaneous nephrolithotomy (PNL) using absorbable gelatin sponge as an adjunct.

**Methods:** From January 2004 to March 2009, 45 patients underwent totally tubeless PNL (no internal drainage either with double J stent or ureteric catheter). Inclusion criteria were insignificant bleeding from the nephrostomy track, no injury to the pelviccalyceal system (PCS), single nephrostomy tract, infra-costal puncture and complete clearance on fluoroscopy. Median stone size was 3 cm (longest diameter recorded). The PNL tract was plugged with absorbable gelatin sponge at the end of the procedure. Drop in hematocrit, hospital stay, pain score by visual analogue scale, urinary leak and peri-renal collection by ultrasonography was documented in all the patients.

**Results:** Median age was 32 years (range 18–57 yrs). Median size of the stone (largest dimension was taken into consideration) was 3 cm (1.8 to 4 cm). All patients had complete stone clearance on postoperative X-ray KUB. Drop in mean value of Hematocrit recorded was 2.4% and none of the patients required blood transfusion. Median pain score was 3. Median value for oral and intravenous Diclofenac sodium was 200 mg (150 mg–300 mg). Perinephric collection was recorded in 3 patients who were managed conservatively. Median hospital stay was 3 days (2–5 days).

**Conclusion:** Totally tubeless PNL using absorbable gelatin sponge as sealant of percutaneous nephrostomy tract appears to be safe and effective in select group of patients.

#### VP4-17 SURGICAL SKILLS LAB FOR PERCUTANEOUS RENAL ACCESS TRAINING: CONTENT VALIDATION COMPARISON BETWEEN LIVE PORCINE AND SIMULATION MODEL

S. Mishra, A. Kurien, A. Ganpule, V. Muthu, R. Sabnis, M. Desai—India

**Background:** We incorporated the use of live porcine model and high fidelity computer based surgical simulator (PERC Mentor, Symbionix; Lod, Israel) in our skills lab for trainees interested in percutaneous renal access training. Construct validity (realism and usefulness) of percutaneous renal access obtained on a live porcine model and PERC Mentor was compared to determine which of the two was a more appropriate and effective training model.

**Methods:** A total of 24 experts performed a task of percutaneous renal access consecutively in a live porcine model and a PERC mentor. The porcine model access required general anesthesia and preplacement of ureteric catheter. The access was done with C-Arm fluoroscopy guidance with a 22 gauge skinny needle (Cook Medical, Bloomington, IN, USA). Then a specific task of percutaneous renal puncture using the same case scenario was done on PERC Mentor. The experts rated a questionnaire based on a 5 points Likert's scale, consisting of 10 and 3 items of realism and usefulness, respectively.

**Results:** Out of the 10 items of realism, porcine model was rated superior to PERC Mentor in terms of overall realism (4.44 ± 0.7, 2.75 ± 0.8), movement of the kidney (4.96 ± 0.2, 3.15 ± 0.7), tactile feedback of perinephric space (3.64 ± 0.8, 1.4 ± 0.6), fluoroscopic realism (4.64 ± 0.5, 3.05 ± 0.7) and complications encountered (4.36 ± 0.5, 1.9 ± 0.8). It was inferior to PERC mentor in terms of orientation to the flank (2.36 ± 1.1, 4.3 ± 0.5), aspiration (3.2 ± 0.9, 4.2 ± 0.6), repetitive performance (3.52 ± 4.1, 4.85 ± 0.4) and organizational feasibility (3.04 ± 1.0, 4.85 ± 0.4), respectively. Tactile feedback of successful access (4.24 ± 0.7, 4.6 ± 0.5) was similar in both models. Out of the 3 items of usefulness, overall usefulness (4.6 ± 0.6, 4.65 ± 0.5) and use as a training tool (4.32 ± 0.5, 4.75 ± 0.4) was similar, however, porcine model was a much superior assessment tool (4.68 ± 0.5, 2.75 ± 0.9).

**Conclusion:** Both the models have relative advantages and disadvantages. The live porcine model is more realistic and assessment tool for percutaneous renal access. The specific advantage of PERC mentor is of repetitive tasking and easier set up feasibility. Overall usefulness is same for both the models.

#### VP4-18 PCNL VS. MINI-PCNL FOR RENAL STONES <4 CM

C. Hammes, F. Wezel, A. Haecker, M. Michel, T. Bach—Germany

**Background:** Percutaneous nephrolitholapaxy (PCNL) is a safe method in the treatment of nephrolithiasis. A less invasive approach mini-PCNL has been developed. The aim of this study was to evaluate safety and efficiency of mini-PCNL in comparison to conventional PCNL in a single center study.

**Methods:** We retrospectively compared two groups [PCNL (group 1); mini-PCNL (group 2)] each including 17 patients with comparable stone burden and morbidity. We compared operation time, stone free rates, admission time and complications rates were evaluated. Puncture of the kidney was performed in x-ray and real-time ultrasound control in both approaches. Ch26 (PCNL) vs. Ch11 or Ch18 (mini-PCNL) have been used in different groups.

**Results:** In a comparable collective of patients regarding, mean age 51 (24–73) vs. 53 (34–79) years, mean stone burden 15 (11–35) vs. 15 (9–35) and mean ASA-score 1.5 (1–3) vs. 1.3 (1–2), we observed similar stone-free rates (94%) in both groups. Operation time of the PCNL-device was slightly longer compared to mini-PCNL (115 min vs. 110 min; p = 0.8). Excepted one blood trans-

fusion in the mini-PCNL group complication rates differed not significantly. Mean hospitalisation was 5 days in both groups.

**Conclusion:** Our results indicate equivalent efficiency of mini-PCNL compared to conventional PCNL. Due to the less invasive character with equal stone-free rates, mini-PCNL seems to be a favourable tool in nephrolithiasis-treatment up to a stone burden of 35 mm.

#### VP4-19 THE MINI-PERCUTANEOUS NEPHROLITHOTOMY FOR THE TREATMENT OF UPPER URINARY TRACT CALCULI IN CHILDREN (REPORT OF 73 CASES)

Z. Xiao-feng, Y. Yuan-hu, Xiao-ning—China

**Background:** To investigate the clinical value of mini-percutaneous nephrolithotomy (MPCNL) for the treatment of upper urinary tract calculi in children.

**Methods:** A total of 73 cases with upper urinary tract calculi underwent MPCNLs (including 15 cases drinking highly melamine-tainted powdered formula). Of these cases, 40 were boys and 33 girls, aged from 1 year to 15 years (mean, 9.3 years). The calculi were found on left side in 36 cases, on right side in 30 and on both side in 7. The smallest size of the calculus was 0.6 cm×0.6 cm, the largest was 2.8 cm×1.3 cm (mean, 1.3 cm×0.9 cm). Fifty cases had renal calculi, of whom 15 cases also had calculi in the proximal or middle ureter (3 negative calculi, 2 multiple calculi), 5 also had distal ureter calculi and 4 also had vesical calculi. The ureter and vesical calculi were managed by ureterolithotripsy (URL) or percutaneous cystolithotomy (PCCL) at the beginning of the operations.

**Results:** All the procedures were successful. Of them, 67 were stone-free after a single MPCNL procedure and the other 6 had residual stones (not more than 3.0 mm in size) removed by MPCNL after a week. Seven patients simultaneously underwent bilateral MPCNLs and 8 underwent tubeless MPCNLs (a 27 month-old boy was performed using totally tubeless MPCNL). There was no major perioperative complication. No patient needs transfusion. Patients were followed up from 1 to 95 months, no stone recurred except 1 melamine-associated case with proximal

ureter calculus was found recurrence after 4 months and treated by URL. The kidney and ureter developed well by intravenous pyelography and no perinephric urinary cyst was found by B ultrasound.

**Conclusion:** MPCNL appears to be a safe, minimally invasive, and quick-recovery procedure for upper urinary tract calculi in children. In some selective patients we can perform tubeless-MPCNL and bilateral simultaneous MPCNL.

#### VP4-20 IN GOOD ALTERNATIVE FOR THE TREATMENT OF LARGE UPPER URETER STONES: PERCUTANEOUS NEPHROURETEROLITHOTOMY

M. Istanbuluoglu, T. Cicek, B. Ozturk, H. Ozkardes—Turkey

**Background:** The treatment of large proximal ureteral stones continues to be controversial. We evaluate antegrade percutaneous approaches for the proximal ureteral stones in our clinic.

**Methods:** In study included 42 percutaneous nephroureterolithotomy (PNUL) operations applied for proximal ureteral stones between February 2005 and January 2009. The stones were located between ureteropelvic junction and 4<sup>th</sup> lumbar vertebra. PNUL's were applied in appropriate calyx with the patients in prone position. During operations, amplatz dilators were used for dilatation and pneumatic lithotripter was used for stone fragmentation. Patients were evaluated according to their success rate, complications, hospitalization period and preference of drainage tube.

**Results:** Patients mean age was found to be 51 years, mean stone surface area 271 mm<sup>2</sup> and mean hospitalization time 1.78 days. Single access done in 41 patients and 2 accesses were needed in one patient. 39 (%92.8) patients became stone free. Nephrostomy tubes were placement 8 patients after operation while tubeless approach was preferred in 34 patients. Complications seen in 4 patients. No any complications reported during follow up period.

**Conclusion:** Percutaneous nephroureterolithotomy is an effective and safe treatment modality if appropriate calyx access is performed. The possibility of renal stone treatment in the same session is an important advantage of this modality.

## VP5: ROBOTICS KIDNEY

#### VP5-01 ROBOT-ASSISTED LAPAROSCOPIC PARTIAL NEPHRECTOMY: RESULTS OF FIRST 50 CASES WITH ANALYSIS OF LEARNING CURVE

G. De naeyer, M. Sangalli, P. Schatteman, P. Carpentier, E. Fonteyne, A. Mottrie

**Background:** Laparoscopic partial nephrectomy (LPN) has established a place as a minimal invasive, nephron sparing treatment for T1 renal tumours. Literature studies, however have shown that LPN has longer warm ischemia times and more peri-operative complications compared to the open approach. We evaluated the use of the da Vinci<sup>TM</sup> robotic system in LPN.

**Methods:** Between September 2006 and June 2009, 50 patients underwent a robot-assisted laparoscopic partial nephrectomy (RALPN) for treatment of small renal tumours.

**Results:** The mean tumor size was 25.6 mm (10 to 64 mm). Mean console time was 96.5 minutes (50 to 180 minutes). Mean warm ischemia time (WIT) was 21.2 minutes (10 to 40 minutes) and the mean estimated blood loss was 152 ml (20 ml to 900 ml). 50% of the patients had pyelocalical system repair. No major intra-operative complications were encountered. No significant changes in peri-operative creatinine-values were seen. Two patients had postoperative transfusions. One patient had a superselective embolisation for persistent hematuria. One patient had a positive surgical margin. A subset analysis of the first 20, compared to the last 20 patients, showed a mean WIT of 26.1 minutes versus 15.9 minutes respectively.

**Conclusion:** These results show that RALPN is feasible and a technically possible alternative for patients otherwise undergoing open partial nephrectomy or laparoscopic radical nephrectomy.

We believe that the da Vinci™ robotic system can facilitate the closure of the urinary collecting system and the re-approximation of the renal parenchyma resulting in acceptable ischemia times. In this presentation the technique, results and complications are discussed in detail.

### VP5-02 ROBOT ASSISTED PARTIAL NEPHRECTOMY: EARLY OUTCOMES IN 150 PATIENTS

E. Weise

**Background:** Laparoscopic partial nephrectomy has been shown to have oncological efficacy equivalent to open partial nephrectomy while improving recovery. The need for complex reconstruction under time pressure makes it a challenging procedure. Use of a computer assisted robotic surgical interface has been found to facilitate complex dissection and reconstruction in other laparoscopic procedures.

**Methods:** Between October 2005 and June 2009, 150 consecutive patients (median age 63 years old, range 24–85) underwent robot assisted partial nephrectomy (RAPN) for enhancing renal masses (76% cT1aN0M0, 20% cT1bN0M0 and 4% cT2N0M0). Median size on preoperative imaging was 2.6 cm (range 1.1–10.6). Surgical principals included placement of ureteral catheter in select cases, complete defatting of the renal capsule with the exception of the mass, intraoperative ultrasound assessment; hilar clamping; sharp excision on a bloodless field, immediate pathological evaluation; case adapted repair strategy; early unclamping; passive drain.

**Results:** Median operative time was 179 minutes (range 91–392). Median console time was 99 minutes (range 61–249). Median estimated blood loss was 150 cc (50–750). Median warm ischemia time was 21 minutes (range 6–47). All cases were completed laparoscopically. There was one conversion to radical nephrectomy due to a tumor thrombus extending to the confluence with the vena cava. 5% of patients received transfusion of blood products. Complications included three delayed acute hemorrhage and three urinoma. 79% of patients were discharged on postoperative day 1 (range 1–8 days). Intraoperative pathological assessment revealed negative surgical margins in all cases. In two cases the final report was changed: one to microscopic positive margin and one to indeterminate due to a small area of possible enucleation. Renal cell carcinoma was found in 78%, with stage pT1a in 60%, pT1b in 7%, pT2 in 2%, pT3a in 8% and pT3b in 1%. Other pathologic findings included oncocytoma. (10%), angiomyolipoma (8%) and complex cyst (4%).

**Conclusion:** RAPN is a safe and effective modality for treatment of renal masses. The robotic interface facilitates the technical challenges and may have the potential to expand indications, decrease warm ischemia time and improve precision of reconstruction.

### VP5-03 TRANSITION FROM LAPAROSCOPIC TO ROBOTIC PARTIAL NEPHRECTOMY: THE LEARNING CURVE FOR AN EXPERIENCED LAPAROSCOPIC SURGEON

H. Lavery, A. Small, R. Mark, D. Samadi, M. Palese—USA

**Background:** Many experienced laparoscopic surgeons are turning to robotic partial nephrectomy (RPNx) as an alternative to laparoscopic partial nephrectomy (LPNx) for the treatment of small renal masses. This analysis examined the learning curve for a single surgeon's transition to RPNx.

**Methods:** The perioperative outcomes of the first 10 patients undergoing RPNx were retrospectively compared to the last 10 pa-

tients who underwent LPNx by a single, experienced laparoscopic surgeon (MP). Surgical technique remained consistent across platforms. The renal artery was clamped with a laparoscopic bulldog, collecting system defects were closed with a running 2–0 vicryl suture, hemostasis was accomplished with oxidized cellulose and hemostatic matrix, and the renal capsular defect was re-approximated with a running vicryl suture and bolsters. Significance was calculated using student's t-test.

**Results:** Preoperative demographics and tumor characteristics were comparable between the two groups. Histopathologic tumor features were also similar, one microscopic positive margin occurred in a LPNx. Postoperatively, no significant differences were seen in regards to length of stay, complications, or change in renal function. The mean operative time (OT) and warm ischemia time (WIT) in the last 10 LPNx were 191 (range: 132 to 222 minutes) and 23 minutes, respectively. The mean OT and WIT in the first 10 RPNx were 206 (range: 122 to 294 minutes) and 26 minutes, respectively ( $p=NS$ ). There was a steady downward trend in both OT and WIT during the RPNx learning curve. After 7 cases, the OT and WIT were consistently at or below the LPNx average.

**Conclusion:** The transition from laparoscopic to robotic partial nephrectomy is rapid in an experienced laparoscopic surgeon. Similar OT and WIT to LPNx were consistently achieved after seven RPNx.

### VP5-04 ROBOT ASSISTANCE INCREASES THE UTILIZATION OF LAPAROSCOPIC NEPHRON SPARING SURGERY FOR TREATMENT OF RENAL MASSES

E. Weise

**Background:** Laparoscopic partial nephrectomy (LPN) is a proven modality for treatment of renal masses. It combines the benefits of nephron sparing surgery (NSS) with the improved recovery and morbidity of laparoscopy. LPN is considered a challenging procedure and its application is limited by technical considerations. This study was undertaken to determine the impact of robot assisted partial nephrectomy (RAPN) on the utilization of laparoscopic NSS (LNSS).

**Methods:** Prospectively gathered data on all patients undergoing treatment for renal masses in a recent 3 year period in a urologic oncology program lead by a urologist with fellowship training in urologic oncology as well as in endourology were reviewed. Utilization of LNSS was calculated as (number of LNSS procedures/number of all procedures) in a given time period. The initial 12 months (group 1) were used as baseline and compared to four subsequent 6 month periods (groups 2, 3, 4 and 5). Mass size as a surrogate for technical complexity was reviewed. Patients with metastatic renal cell cancer or end stage renal disease were excluded. No patient underwent probe ablation.

**Results:** 202 patients were treated for renal masses. LNSS was used in 96 patients, while laparoscopic radical nephrectomy (LRN) was used in 100, open partial nephrectomy in 4 and open radical nephrectomy in 2. Overall utilization of LNSS was 48%. No laparoscopic procedures were converted to open. 1 RAPN was converted to LRN due to a renal vein tumor thrombus. 2 LRN were aborted (1 lymphoma, 1 unresectable). All open procedures were completed as planned. Utilization of LNSS increased from 17% in group 1 to 39% in group 2, 49% in group 3, 68% in group 4 to 88.5% in group 5 ( $p < 0.05$ ). LNSS mass size was 1.9 cm (range 1.2–3.3) in group 1 and increased to 3 cm (1.9–5) in group 2, 2.9 cm (1.4–5.4) in group 3, 3.2 cm (1.1–7) in group 4 and 3.8 cm

(1.1–10.6) in group 5 ( $p < 0.05$ ). Size of all masses not treated with LNSS was 3.5 cm (range 2–15) in group 1 and increased to 6.5 cm (1.7–18.7) in group 2, 7.5 cm (3–20) in group 3, 8.75 cm (2.5–15.5) in group 4 and 8 cm (4.6–19) in group 5 ( $p < 0.05$ ).

**Conclusion:** In the practice of a urologist well trained in surgical modalities for management of renal masses, the introduction of a computer assisted robotic surgical interface increased the utilization of laparoscopic nephron sparing surgery by inclusion of masses of greater technical complexity.

### VP5-05 RISKY BUSINESS? DETERMINATION OF SATINSKY CLAMP SAFETY ZONE TO ROBOTIC ARM DURING ROBOTIC PARTIAL NEPHRECTOMY

A. Bowen, M. Raynor, U. Boylu, B. Lee

**Background:** Much ado has been made about the risk of using a Satinsky clamp in combination with the DaVinci robotic platform during partial nephrectomy. Opponents argue that having a fixed hilar clamp outside of the patient's body places the renal vessels at untoward risk, due to the possibility of arm-clamp collision with resultant potential intimal tear or arterial avulsion. However, advocates argue the Satinsky clamp has superior vascular-occlusive performance, requires less skeletonization and hilar dissection, and does not require an advanced-skilled assistant to place and remove compared to Bulldog clamps. This investigation seeks to determine how close the robotic arms approach the Satinsky clamp extracorporeally during the period of warm ischemia.

**Methods:** After port placement and renal hilar isolation and mobilization, a digital video recorder was used to film the relative position of the inferior robotic arm as well as the robotic camera arm relative to the Satinsky clamp. Using digital image analysis with After Effects CS3 software providing an image overlay ruler to scale, the distances between the hub of the Satinsky clamp were measured. Measurements between the camera and proximal robotic arm relative to the Satinsky clamp were recorded every ten seconds then analyzed for mean, range, as well as 10th and 90th percentiles.

**Results:** Number of Measurements: 104 Clamp time: 32 minutes Mean distance: Camera-Satinsky Clamp: 16.9 (range 2–21.4 cm) Mean distance: Robotic Arm-Satinsky Clamp: 20.9 cm (range 4–30 cm).

**Conclusion:** The risk of clamp-arm collision is minimal if fundamental laparoscopic principles are strictly maintained. Both surgeons should be cognizant of robotic arm location, and clamp-site selection should be performed after renal hilar dissection and exposure of the mass. Optimal distance to place Satinsky clamp during this video analysis was 8 cm from nearest robotic arm based on doubling the minimum distance which the robotic arm approached the Satinsky Clamp. A vigilant attention to instrument position and proximity is paramount. Further evaluation in the form of randomized trials between Bulldog and Satinsky clamping is needed, as well as comprehensive reporting of conversion and complication rates.

### VP5-06 MATCHED COMPARISON OF ROBOTIC PARTIAL NEPHRECTOMY AND LAPAROSCOPIC PARTIAL NEPHRECTOMY FOR COMPLEX RENAL MASSES

L. Dulabon, J. Finkelstein, M. Lipkin, M. Stifelman—USA

**Background:** It has been suggested that robotic-assisted laparoscopic partial nephrectomy (RAPN) may improve outcomes in patients with complex-hilar renal tumors. In order to evaluate this,

we compared our RAPN experience of complex renal tumors to a matched cohort of patients who underwent laparoscopic partial nephrectomy (LPN) by the same surgeon.

**Methods:** After IRB approval, we reviewed prospectively-collected data on our last 46 consecutive patients who underwent RAPN over a 12 month time period (April 2008 to April 2009) by a single surgeon (MS). Of these 46 patients, 14 had a “complex renal mass” defined as: tumor abutting the renal hilar vessels, tumor extending into the renal sinus or invading the collecting system, or multiple tumors within the same renal unit as seen on preoperative imaging with either CT or MRI. Results were compared retrospectively with 14 matched patients from a cohort of 55 patients who had LPN performed by the same surgeon over a 23 month time-period (from October 2006 to September 2008). The same surgical steps including the renorrhaphy technique were used in both groups, and intraoperative ultrasound was utilized in all cases. Patients were matched for gender, age, tumor location and tumor size. Outcomes measured included: warm ischemia time, estimated blood loss, length of hospital stay, change in serum creatinine/GFR, and margin status. Pathologic outcomes, intra-operative and post-operative complications were also noted.

**Results:** Data is summarized in the table below. There was a highly significant difference in warm-ischemia time (WIT), favoring the RAPN group (28.9 minutes for RAPN vs. 37.7 minutes for LPN,  $p = 0.002$ ). Overall, there were shorter operative times, hospital stays and less EBL in the RAPN group, although this is of unclear clinical significance. Change in serum creatinine/GFR were equivocal in both groups. One patient in the LNP required conversion to hand-assisted LNP for bleeding. One patient in the LPN and two patients in the RAPN group developed an intrarenal pseudoaneurysm requiring re-admission and angio-embolization. There were no urinomas or urinary fistulas. Final pathologic analysis proved renal cell carcinoma in all cases except for two AMLs in the RAPN group and 3 oncocytomas in the LPN group. \*  $p < 0.05$  n Age Gender BMI Max Tumor Size (cm) Operative Time (min) WIT (min) EBL (cc) LOS(days) Margins RAPN 14 59.6 (44–72) 6/8 (m/f) 29.8 (21–39.9) 3.66 (2.0–5.7) 199(121–244) 28.9\* (12–42) 221 (50–600) 2.75 (2–4) 1 (8%) LPN 14 61.4 (36–85) 6/8 (m/f) 26.0 (20–32.5) 3.29 (1.7–5.5) 208 (171–315) 37.7 (28–50) 279(100–500) 3.17 (2–5) 0 (0%)

**Conclusion:** Our data suggests that RAPN is a safe, effective, and feasible option for the minimally-invasive approach to complex renal tumors. In fact, there was a highly statistical advantage in the RAPN group regarding WIT. Although further experience and long-term data are needed to for full evaluation, initial results are encouraging.

### VP5-07 LAPAROSCOPIC VS. ROBOT-ASSISTED PARTIAL NEPHRECTOMY: A PROSPECTIVE HEAD-TO-HEAD COMPARISON OF TECHNIQUES

R. Munver, J. Uberoi, J. Yates—United States

**Background:** The transition from open to laparoscopic partial nephrectomy (LPN) for the management of small enhancing renal masses has been slow. Despite its growing acceptance, the optimal role for the da Vinci™ Surgical System in laparoscopic renal surgery has not been defined. We reviewed our experience with robot-assisted laparoscopic partial nephrectomy (RALPN) and compared results to pure LPN.

**Methods:** After overcoming the initial learning curve for robot-assisted renal surgery, a prospective review was conducted of the

most recent 15 cases of RALPN and 15 cases of LPN performed by a single surgical team. For RALPN, the da Vinci™ system was used for the entirety of the procedure, including hilar dissection, mass excision, and parenchymal reconstruction. Perioperative data were prospectively collected for all groups.

**Results:** The mean patient age was 55 (LPN) and 68 (RALPN). Mean operative time and warm ischemia time were 165 min/28 min (LPN) and 170 min/27 min (RALPN). Blood loss was 112 mL (LPN) and 202 mL (RALPN). Hospital stay was 2.2 days (LPN) and 2.0 days (RALPN). Mean tumor size was 1.9 cm (LPN) and 2.1 cm (RALPN). There was no statistical difference in operative time, warm ischemia time, or hospital stay. Pathology revealed 73% of the lesions were malignant. All surgical margins were negative and there were no major complications.

**Conclusion:** Robot-assisted laparoscopic partial nephrectomy can be successfully performed to achieve comparable oncologic results to a pure laparoscopic approach. Individual selection of the approach will likely be dependent on the preference and comfort level of the surgeon.

#### VP5-08 NEW TECHNOLOGY CHANGES PRACTICE PATTERNS: THE CASE OF ROBOTIC SURGERY AND MANAGEMENT OF RENAL MASSES

A. Weizer, J. Montgomery, W. Roberts, J. Wolf, Jr., D. Miller, K. Hafez

**Background:** Awareness of the benefits of laparoscopic and nephron sparing surgery have lead to increased adoption of technologies at tertiary medical centers to accomplish these goals. However, it is unclear how the introduction of new technologies impacts practice patterns. We reviewed our clinical experience with surgery for presumptive renal cell carcinoma before and after the introduction of robotic assisted partial nephrectomy.

**Methods:** We identified 394 total patients undergoing radical nephrectomy (open (n = 16) or laparoscopic (n = 101)) or partial nephrectomy (open (n = 82), laparoscopic (n = 149), or robotic (n = 31)) over a 30 month period including a 12 month period prior to the introduction of robotic assisted partial nephrectomy. Patients undergoing radical nephrectomy with vena cava tumor thrombectomy were excluded from this analysis because new technology was unlikely to change surgical approach. Patient, tumor, and perioperative information was abstracted from the institutional database. Analysis was performed using SAS version 9.1 (SAS Institute, Cary, NC).

**Results:** The introduction of robotic assisted partial nephrectomy reduced the number of radical nephrectomies performed compared to nephron sparing surgery. In addition, the introduction of robotic assisted partial nephrectomy has shifted nephron sparing surgery away from both laparoscopic and open partial nephrectomy. Patient characteristics were similar between the nephron sparing surgery groups; however, differences existed in terms of operative time, estimated blood loss, and mean tumor size, and ischemia time. Variable (mean,SD) Open (n = 15) Laparoscopic (n = 86) Robotic (n = 26) p Age (years) 52 (13) 57 (14) 58 (13) 0.36 Body mass index 27 (5) 30 (8) 32 (6) 0.13 Tumor size (cm) 3.9 (0.8) 3.1 (1.2) 3.8 (1.3) 0.01 Operative time (min) 159 (46) 189 (62) 212 (72) 0.04 Ischemia time (min) 38.6 (12.1) 31.0 (13.6) 35.9 (11.3) 0.05 Estimated blood loss (ml) 303 (231) 320 (292) 577 (625) 0.01 Length of stay (days) 4.0 (1.3) 2.9 (2.3) 3.1 (1.9) 0.21

**Conclusion:** Introduction of robotic assisted surgery appears to increase utilization of nephron sparing surgery for the management

of renal masses. While perioperative outcomes appear worse for early experience with robotic partial nephrectomy compared to a robust laparoscopic partial nephrectomy program, robotic assistance may lower the barrier for clinicians to offer minimally invasive nephron sparing surgery.

#### VP5-09 ROBOTIC PYELOPLASTY—INITIAL EXPERIENCE

C. Wagner, A. Schütte, J. Witt—Germany

**Background:** Concerning long-term functional outcomes as well as operative feasibility, laparoscopic pyeloplasty has become equal to open surgery. However, the operative technique is challenging and thus combined with a significant learning curve. As the da Vinci™-surgical system enhances standard-laparoscopic skills by far, it is a good system to easily conduct complex reconstructive procedures. Having started with robot-assisted prostatectomies, we have been applying the robot-assisted pyeloplasty since August 2006 and have performed 12 surgeries so far.

**Methods:** n = 12 patients, 7 female, 5 male, 7×left, 5×right side, mean age 43 years (range 23–77). Each with urodynamically relevant UPJ-obstruction. In addition: 1 staghorn calculus, 2 patients with nephrolithiasis Transperitoneal approach, flank position, capno-peritoneum 12–15 mmHG. Port-placement: 1 12 mm camera-trocar, 2 8 mm robot-trocars 8 mm, 1–2 5–12 mm assistant-trocars Technique analog Anderson-Hynes with pre- or intra-operative retrograde DJ-catheter-placement (Charrière 6). Anastomosis: Initial 3 cases single-stitch, Vicryl 4–0, the later 9 cases in running fashion Monosyn 4–0 on an RB-1 needle. In 2 cases simultaneous pyelo-lithotomy for renal calculus transposing lower pole artery found in 3 Cases.

**Results:** Mean follow Up: 14 months (2–29); mean skin-skin-time: 140 min. (90–170). mean EBL: 48 cc (30–200 cc), foley catheter removed after 2–3 days, mean pigtail-catheter removal after 24 (18–31) days. No conversions, no revisions. In one case prolonged wound pain. All patients asymptomatic, no evidence for re-strictures in IVP or ING.

**Conclusion:** Our initial experience with robot-assisted pyeloplasty show promising results concerning feasibility, complication rate & functional outcome. Regarding published series our data are comparable concerning OR-time, complications, blood loss and functional results. Robot-assisted pyeloplasty certainly can become the new standard therapy for treating UPJ-obstruction.

#### VP5-10 ROBOTIC ADRENALECTOMY: SURGICAL TECHNIQUE AND OUTCOMES

L. Yeung, H. Atalah, S. Parekattil, L. Su—USA

**Background:** Since 2000, robotic urologic surgery has rapidly expanded to include treatment of benign and malignant disease of both the lower as well as upper urinary tract. Robotic surgery for upper urinary tract pathology within the adrenal gland and kidney have especially become more common in the last few years. Herein, we present our institution's experience and outcomes of robotic adrenalectomy.

**Methods:** The patient is positioned in a modified lateral decubitus position on the operating room table. The robot is then docked at a 45 degree angle coming from the head of the table. A three armed robotic technique is used with a zero degree stereoscopic lens used throughout the case. One to two assistant ports are used as needed based on location and side of the lesion. The specimen is extracted intact through extension of the camera port.

**Results:** To date, we have performed 7 robotic adrenalectomies including two right sided and 5 left sided lesions, with the mean size being 4.3 cm (range 2–9.6cm). There were no complications in our series. All lesions were for benign pathology. Mean age was 55 years (range 22–80), operative time was 150 min, blood loss was 50 mL, and length of hospitalization was 1.4 days (range 1–2).

**Conclusion:** Robotic adrenalectomy offers the benefits of elimination of tremor and improved ergonomics with the wristed instrumentation, which is especially useful in addressing very large adrenal tumors or those located in deep and confined locations. The robotic approach may prove to be an alternative for surgeons with limited experience with conventional laparoscopic techniques.

### VP5-11 RADIOFREQUENCY ABLATION-ASSISTED ROBOTIC LAPAROSCOPIC PARTIAL NEPHRECTOMY WITHOUT RENAL HILAR VESSEL CLAMPING VERSUS LAPAROSCOPIC PARTIAL NEPHRECTOMY: A COMPARISON OF PERIOPERATIVE OUTCOMES

S. Wu, D. Viprakasit, N. Smith, P. Kent, D. Rebeck, R. Nadler—USA

**Background:** Radiofrequency ablation (RFA)-assisted laparoscopic partial nephrectomy may allow for improved hemostasis without need for renal hilar vessel clamping and elimination of warm ischemia to the kidney. We compare outcomes in patients undergoing RFA-assisted robotic clampless partial nephrectomy (RF-RCPN) and laparoscopic partial nephrectomy (LPN).

**Methods:** Thirty-six patients and 42 patients underwent LPN and RF-RCPN, respectively. In the RF-RCPN group, the Habib 4× RFA device was used to coagulate a margin of normal parenchyma around the renal mass to allow excision of the mass within a bloodless plane. Unlike in the LPN group, renal hilar vascular occlusion was not performed in the RF-RCPN group.

**Results:** Tumors treated in the RF-RCPN group tended to be larger (2.8 vs 2.0 cm) and more often endophytic (52.6% vs 16.1%). Collecting system reconstruction occurred more often in the RF-RCPN group (78.6% vs 30.6%). Operative duration was longer in the RF-RCPN group (373 vs 250 minutes) but this included time for cystoscopy, ureteral stenting and repositioning of the patient. Blood loss, transfusion rates, renal function, and complication rates did not differ between the two groups. No patients required renal hilar vessel clamping or nephrectomy to control bleeding in the RF-RCPN group.

**Conclusion:** The use of RFA-assistance during robotic partial nephrectomy allows excision of renal tumors without hilar vascular clamping, thus eliminating renal warm ischemia. Larger and more centrally located tumors were excised with RF-RCPN. No differences in blood loss, complication rate, post-operative bleeding, renal function, or recurrence rate were noted when compared to LPN.

### VP5-12 COMPARISON OF ROBOTIC ASSISTED AND PURE MICROSURGICAL VASOVASOSTOMY

S. Parekattil, H. Atalah, M. Cohen

**Background:** Our goal was to compare standard microsurgical vasovasostomy (MVV) to robotic assisted vasovasostomy (RAVV) in a preliminary human clinical series.

**Methods:** A review of all 30 bilateral vasovasostomy cases performed from Jul 2007 to June 2009 by a single fellowship trained microsurgeon. 22 cases were performed using RAVV, and 8 using MVV. Selection of approach (RAVV vs. MVV) was based on

patient choice after thorough discussion of options (the cost premium for RAVV was \$3,100 above MVV). The patients in each group were of similar age and duration since vasectomy. The same suture material and suturing technique (3 layer 10–0 and 9–0 nylon anastomosis) was used in both approaches. F/u was up to 22 months post-op (mean 3 months). Operative duration was measured for all cases (skin to skin). Semen analysis was performed at 2 months, 5 months and 11 months post-op.

**Results:** At 2 month follow up, 100% patency was achieved in all cases (>2 million sperm/high power field). Mean operative duration was significantly decreased in the RAVV series at 106 mins (70–180) compared to MVV at 126 mins (105–150),  $p=0.04$ . Mean sperm count at 2 months post-op was significantly better in RAVV compared to MVV (54 million vs. 11 million,  $p=0.04$ ). Sperm count and motility at 5 months was not significantly different between the two groups.

**Conclusion:** The use of robotic assistance in microsurgical vasovasostomy may have potential benefit over MVV with regards to decreasing operative duration and improving early sperm counts. Further evaluation and longer follow up is needed to assess its clinical potential.

### VP5-13 ROBOTIC ASSISTED MICROSURGICAL DENERVATION OF THE SPERMATIC CORD FOR CHRONIC TESTICULAR PAIN

S. Parekattil, H. Atalah, M. Cohen

**Background:** Our goal was to develop a robotic assisted microsurgical approach for the denervation of the spermatic cord (RMDSC) and present our initial results.

**Methods:** Prospective randomized control trial of microscopic denervation of the spermatic cord (MDSC) to RMDSC in a canine model and review of 24 human cases. Canine study: single microsurgeon performed cord dissection and ligation of 3 veins with 3–0 silk ties. 12 cases randomized into 2 arms of 6: MDSC vs. RMDSC. Procedure duration recorded. For the human study: 24 RMDSC cases from Oct'08–Jun'09 reviewed (mean follow up 2 months). Selection criteria: chronic testicular pain (>6 months), failed standard pain management treatments, negative neurologic and urologic workup, and complete temporary resolution of pain with local anesthetic spermatic cord block. A subinguinal, inguinal or intra-abdominal approach utilized based on location of pain. Robotic microsurgical platform utilized (DaVinci Sä with high magnification). Pain was assessed utilizing a standardized validated tool (PIQ-6).

**Results:** Canine study: RMDSC mean duration (9.5 min) was significantly less than MDSC (12 min),  $p=0.04$ . Human series: mean operative duration was 41 mins (19–80). Postoperatively, 75% (18) patients had complete resolution of pain and 17% (4) had a 50% decrease in pain. The 2 patients with continued pain had resolution of pain for only 1 month. The 4th robotic arm allowed the surgeon to control one additional instrument leading to less reliance on the microsurgical assistant.

**Conclusion:** Preliminary results from robotic assisted microsurgical denervation of the spermatic cord appear promising. Longer follow and further evaluation is needed.

### VP5-14 ROBOTIC ASSISTED MICROSURGICAL VARICOCELECTOMY

S. Parekattil, H. Atalah, M. Cohen

**Background:** Our goal was to compare standard microsurgical varicocelectomy (MVV) to robotic assisted varicocelectomy (RAVx) and present our initial human results.

**Methods:** Prospective randomized control trial of MVV to RAVx in a canine varicocele model by a fellowship trained microsurgeon and a review of our initial 25 human cases. For the canine study, surgeon performed cord dissection and ligation of 3 veins with 3–0 silk ties. 12 canine varicocelectomies were randomized into 2 arms of 6: MVV vs. RAVx. Procedure duration, vessel injury and knot failures recorded. 25 human RAVx cases from Jun'08–Jul'09 were reviewed (mean follow up 3 months).

**Results:** For the canine study, the RAVx mean duration (9.5 min) was significantly faster than MVV (12 min),  $p < 0.04$ . There were no vessel injuries or knot failures in either group. In the human series, mean duration per side was 41 mins (25–80). Indications for the procedures were: 3 azoospermia, 17 oligospermia and 5 testicular pain (failed all other treatment options). 3 month follow up available for 11 patients: 7 with oligospermia had significant improvement in sperm counts (two achieved pregnancy), and 2 with azoospermia remain unchanged. For testicular pain patients: all had complete resolution of pain. The 4th robotic arm allowed the surgeon to control one additional instrument during the cases decreasing reliance on the microsurgical assistant.

**Conclusion:** Robotic assisted microsurgical varicocelectomy appears to be safe. There are advantages in decreasing operative duration and improving surgeon efficiency. The preliminary human results appear promising. Further evaluation and follow up is needed.

#### VP5-15 ROBOTIC ASSISTED TRANSPERITONEAL DISMEMBERED PYELOPLASTY: OUR EXPERIENCE

F. Annino, A. Beato, C. De carne, S. De stefani, S. Micali, G. Bianchi

**Background:** Robot-Assisted pyeloplasty (RALP) is an actual approach to repair ureteropelvic junction obstruction (UPJO). We report our experience regarding perioperative and short term functional outcome of RALP.

**Methods:** Since 02/2008 to 04/2009 we performed 9 transperitoneal RALP for UPJO with da Vinci® System (6 right/3 left, 2 men/7 women, mean age 30 y.o). We performed a dismembered Anderson-Hynes pyeloplasty in all cases. The anastomosis is achieved with two running sutures (4/0 Monocryl); an ureteral DJ stent is placed antegradely during the surgery. Data have been collected prospectively. The patients were followed with clinical examination and ultrasonography 1 month after the DJ stent removed, IVU after 3 months and diuretic renography after 6 months.

**Results:** All procedures were completed in robotic fashion. Mean operative time has been 160 min (including antegrade JJ stent placement). An inferior aberrant crossing vasa was present in 1 case. Bladder catheter, drain and DJ were removed respectively 2, 3 and 30 days after surgery. The patient were discharged 4 days after surgery. No major or minor complications have been recorded. With a mean follow-up of 6.4 months (range 3–16) all the patients are asymptomatic and the diagnostic examinations show open UPJ.

**Conclusion:** Robotic assistance makes easier the reconstructive step of the surgery and it raise capabilities to work in a narrow space allowing the surgeon to perform meticulous endocorporeal sutures and fine and minimal dissection. Robotic assisted surgery

could become the gold standard procedure for UPJO reconstruction.

#### VP5-16 NOVEL MICRO DOPPLER PROBE FOR ROBOTIC MICROSURGICAL PROCEDURES

S. Parekattil, Sijo J., H. Atalah, M. Cohen

**Background:** The use of real time Doppler scanning for arterial localization during microsurgical procedures such as varicocelectomy is beneficial in preventing inadvertent arterial injuries. The use of the Da Vinci S HD robotic platform (Intuitive Surgical, CA) to perform microsurgical procedures is being explored. One of the caveats of this platform is the difficulty in manipulating standard microscopic Doppler probes with the robotic graspers during such procedures since these probes are designed to be held in the human hand. This study presents the initial evaluation of a novel micro Doppler probe (MDP) designed specifically for robotic microsurgical procedures.

**Methods:** The MDP (Vascular Technology Inc., NH) was evaluated in a human bilateral robotic assisted varicocelectomy case for efficacy in testicular artery localization and ease of robotic grasper maneuverability.

**Results:** The MDP was effective in identifying three testicular arteries within the spermatic cord on either side. Due to the compact size of the MDP and the presence of a small grasping handle for the robotic grasper, maneuverability using the robotic grasper was significantly improved over the standard handheld Doppler probe. MDP allowed for full range of motion of the robotic arms allowing the surgeon to easily scan vessels from a wide range of angles. The operative duration for the case was 70 minutes, 8 veins where ligated on the left, 6 on the right. No complications occurred.

**Conclusion:** The new micro Doppler probe for robotic microsurgical procedures appears to have performed effectively in this initial case. Further prospective testing and evaluation is necessary to confirm these findings.

#### VP5-17 ROBOTIC-ASSISTED SURGERY FOR INVASIVE BLADDER CANCER: CAN THE LYMPH NODE DISSECTION MATCH THE BENCHMARKS OF OPEN SURGEONS?

J. Davis, A. Kamat, B. Grossman, C. Dinney—USA

**Background:** The completeness of a pelvic lymph node dissection (PLND) during radical cystectomy is difficult to measure by node counts and template descriptions. Robot-assisted (RA) cystectomy/PLND is often completed with a small incision to extract the specimen and perform the urinary diversion. We therefore designed a prospective protocol to take advantage of this access to compare RA-PLND with a second-look open PLND.

**Methods:** RA-cystectomy/PLND was performed by a single surgeon (JWD) in 13 cases, followed by a second look open PLND. Patient selection excluded locally advanced stage and BMI >35. Lymph nodes were separated into 8 zones: 3 paired zones (obturator, external iliac, common iliac) and 2 mid-line zones (presacral, paracaval/aortic). Lymph node packets were loaded into 2 endocatch bags with surgical separating the specimens. Any nodes retrieved from the open dissection were separately submitted. Cases 1–4 were performed with a daVinci original (O) model and cases 5–13 with the S model (case 13 pathology is pending).

**Results:** For all 8 zones, the median RA-PLND node yield was 36 (range 19–63), and for open was 4 (range 0–8). The RA median node yield fraction was 93% (range 70–100). Only the S model



could adequately reach above the mid-common iliac region, and the yield in these cases was 94% (range 83–100). The RA obturator/internal iliac zones were the most reliable: dissected open in 5/24 sides with 100% yield. The least reliable were the RA peri-caval/aortic: dissected open in 6/12 cases with 33% yield. Of the 96 node zones (12 cases×8 zones):69/96 (72%) had no further tissue submitted from open, 10/96 (10%) had open tissue submitted showing no nodes, and 17/96 (18%) had open tissue submitted showing additional nodes. Operative median times included: total surgery 545 min. (range 459–736), RA-cystectomy 140 min. (range 90–200), RA-PLND 117 min (range 89–152), and open diversion 160 (range 75–381). All cystectomy specimens demonstrated negative surgical margins, 1 pT3a, and 1 N1 (captured with RA). **Conclusion:** RA-PLND and cystectomy can achieve acceptable oncologic results. The S model gives the surgeon greater access to the higher lymph node zones. The 2nd-look open dissection may be the safest model for negotiating the learning curve for this procedure for disease with high lethal potential.

#### **VP5-18 ROBOTIC-ASSISTED LAPAROSCOPIC RADICAL CYSTECTOMY WITH ORTHOTOPIC ILEAL NEOBLADDER: AN INITIAL SINGLE CENTER STUDY OF 18 PATIENTS**

L. Young Goo, S. Ha Jeong, C. Sang Hoon, L. Yong Seong

**Background:** Robotic-assisted laparoscopic radical cystectomy (RLRC) with orthotopic ileal neobladder in muscle-invasive bladder cancer patients was performed to improve quality of life after cystectomy.

**Methods:** 18 patients (13 male and 5 female, age 45–78 years old) underwent RLRC with orthotopic ileal neobladder from February 2008 to May 2009. First, Using a six-port (4 robot ports, 2 assistant ports) transperitoneal approach, cystectomy with retrovesical plane in male or rectovaginal plane in female and extended lymphadenectomy were completed. Second, in initial 13 patients (group 1, M/W: 10/3) specimen was extracted through a 4 cm infraumbilical midline incision. A 70 cm segment of ileum was used to construct orthotopic ileal neobladder (modified Hautmann pouch, W-pouch with double chymney) extracorporeally. Last, after wound closure robot was redocked and urethra-resorvior anastomosis were completed intracorporeally by robot assist continuously. But, lately 5 patients (group 2, M/W: 3/2), through a 4 cm suprapubic abdominal incision specimen was extracted. After orthotopic neobladder, urethra-resorvior anastomosis were completed by open technique.

**Results:** All procedures were completed with no intra-operative complications. The mean operation room time was 690 and 570 minutes in group 1 and 2, respectively. Console time was 510 and 380 minutes, respectively ( $p < 0.05$ ). Estimated blood loss was 458 and 420 ml, respectively. Soft diet was begun at postoperative day 4–5. Ureteral stent was removed at postoperative day 10–21.

**Conclusion:** Robotic-assisted laparoscopic radical cystectomy and orthotopic ileal neobladder in bladder cancer was safe and effective for initial experienced robot surgeon. It will be very helpful to improve quality of life after operation.

#### **VP5-19 ROBOT-ASSISTED LAPAROSCOPIC RADICAL CYSTECTOMY WITH ORTHOTOPIC BLADDER SUBSTITUTION: THE INITIAL KOREAN EXPERIENCE**

K. Young Hwii

**Background:** Purposes: To evaluate the feasibility and efficacy of the robot-assisted laparoscopic radical cystectomy (RARC) with

orthotopic neobladder in terms of operative, oncologic and functional outcome. To the best of our knowledge, this is the first report in Korea.

**Methods:** Materials and methods: From August 2007, patients with muscle invasive or recurrent high grade superficial bladder cancer had undergone RARC in our institution. All operation was performed by a single surgeon, who had no experienced in pure laparoscopic radical cystectomy. The formation of neobladder was done extracorporeally through 6 cm-long vertical low mid-line incision, then anastomosis was performed by robotic approach. The perioperative variables were surveyed prospectively.

**Results:** Among 24 cases of RARC, 10 patients had undergone orthotopic neobladder. All this 10 patients were male, with mean age of 57.6 years old. Among them, standard pelvic lymph node dissection (PLND) was performed in initial 5 patients, and extended PLND was performed in late 5 patients. The mean console time including PLND was 263.5 minutes. For neobladder formation and urethra-neovesical anastomosis, 153 minutes and 70 minutes was taken respectively. The blood loss was calculated as mean 390 ml. The operative time and blood loss decreased as accumulation of the cases, with statistic significance. One patient experienced mechanical ileus requiring surgical treatment, and the other minor complications were controlled with conservative management. The mean time for flatus was 3.1 days and hospital stay was 18.4 days. The surgical margins were negative in all patients, and the mean yield of lymph node was 16 versus 40 for standard and extended PLND. During 7.3 months of mean follow-up, no radiological evidence of recurrence was found. As short-term functional outcome, 8 patients regain continence within 6 weeks, and for 4 patients who had efficient preoperative sexual activity regained sufficient erection within 4 months after operation.

**Conclusion:** RARC with orthotopic neobladder is surgically feasible and safe procedure with acceptable oncologic and short-term functional results, from our initial experience.

#### **VP5-20 THE FEASIBILITY OF ROBOT-ASSISTED LAPAROSCOPIC RADICAL CYSTECTOMY WITH PELVIC LYMPHADENECTOMY: FROM THE VIEWPOINT OF EXTENDED PELVIC LYMPHADENECTOMY**

K. Seok Ho

**Background:** To evaluate the feasibility of robot-assisted laparoscopic radical cystectomy (RARC) with pelvic lymph node dissection (PLND), especially extended PLND (ePLND), during the initial experience.

**Methods:** From August 2007 to May 2009, prospective data obtained from the 24 consecutive patients who underwent robot-assisted laparoscopic radical cystectomy (RARC) with PLND at Korea University hospital. Data included baseline characteristics, perioperative, pathological outcomes, and complications. Evidence of the lymph node yield curve was examined using linear regression to compare the number of lymph nodes obtained.

**Results:** Among twenty one patients who underwent RARC, 14 had ileal conduit urinary diversion and 10 had orthotopic neobladder. Standard PLND (sPLND) were taken in early 16 patients, and ePLND were in recent 8 patients. The mean total operative time was  $558.9 \pm 136.8$  minutes and the mean estimated blood loss was  $373.5 \pm 202.9$  mL. The mean time for PLND was  $100.7 \pm 31.7$  minutes in patients with ePLND, and  $74.0 \pm 13.5$  minutes in patients with sPLND ( $p = 0.001$ ). All the patients had negative

surgical margins. The mean number of retrieved nodes was  $23.9 \pm 13.9$  (8–61) in all patients:  $41.9 \pm 11.0$  (29–61) in ePLND, and  $15.5 \pm 3.9$  (8–21) in sPLND.

**Conclusion:** The RARC with PLND is feasible for perioperative data and oncologic features. Robot-assistant laparoscopic surgery

is a safe and effective procedure with acceptable morbidity and good oncologic results from the viewpoint of PLND, especially ePLND.

## VP6: EDUCATION AND SIMULATORS

### VP6-01 OPTIMAL ROBOTIC UROLOGICAL TRAINING PROGRAMMES—TOP TEN INDICES

S. Kommu, T. Finnigan, D. Cartlidge, S. Hamid, Z. Hashim, S. (sarg)—United Kingdom

**Background:** Robotic Assisted Urologic Surgery (RAUS) is being initiated in an increasing number of units throughout the world. However, RAUS requires technical expertise and training in this approach has its own inherent challenges. These include ethical, medico legal, and health economic restrictions. The general consensus based on feedback via the Surgical Trainees Interested in Laparoscopic and Robotic Urological Surgery (STILUS) Website [www.stilus.co.uk], is that there is paucity of information regarding optimal robotic training programmes. Herein we aimed to establish a preliminary rank stratification of the top ten indices of the ideal Robotic Urological Training Programmes.

**Methods:** Trainees in the global network of the STILUS Group were asked to rank the top fifteen indices, which they felt represented the ideal Robotic Urological Training Programmes. We coded each response and filtered the top ten most common indices cited using standard software. Global mentors from the STILUS Group were asked to offer consensus opinions on the summary of the trainee responses.

**Results:** One hundred and eighty randomly chosen participants from a database pool of known trainees globally were sent a standard questionnaire by email. The response rate was 84%. The results when tallied in rank order of importance were as follows: [1] Funding and economic constraints, [2] Dry lab training facilities on site, [3] Courses and Meetings, [4] Wet/Animal lab training, [5] Balance and volume of cases, [5] Trainee activity restricted to RAUS only, [6] Mentor/Faculty Resources including feedback facilities, [7] High training time to service provision ratio, [8] Research activity, [9] Attendance by Global Faculty of experts, [10] Streamlining of post following training period.

**Conclusion:** The top ten indices for the ideal Robotic Urological Training Programmes are based on the themes of funding and ease of accessibility to training resources such as courses, hands on training and volume of cases. Knowledge of the identified indices could help training units to further tailor their programmes. It could act as a preliminary platform for initiation of subsequent benchmarks for optimal training.

### VP6-02 AN ASSESSMENT OF THE PHYSICAL IMPACT OF A COMPLEX SURGICAL TASK ON SURGEONS: COMPARISON BETWEEN OPEN, LAPAROSCOPIC AND ROBOTIC TECHNIQUES

O. Elhage, P. Dasgupta, A. Shortland

**Background:** Robotic surgery is widely used in Urology. It has been suggested it is associated with less surgical fatigue compared to laparoscopy. A comparison of open, laparoscopic and robotic techniques on the surgeon's ability to perform a realistic in-vitro simulation has been evaluated.

**Methods:** 6 urological surgeons performed simulated vesico-urethral anastomoses in dry lab settings, using open, laparoscopic and robotic techniques. Retroreflective markers were attached to anatomical landmarks on the performing surgeon's body during the task. Movement data was captured using a 3D system (Vicon; PlugInGait). Electromyography (EMG) probes placed on the upper limbs and back recorded muscle activities. Number of errors and level discomfort (Borg) were recorded.

**Results:** Movement analysis showed increased trunk flexion during RAS, increased neck flexion during open, and increased shoulder abduction during LAP. Mean EMG amplitude was maintained during all open and robotic sessions, however that of right deltoid muscle fell dramatically towards the end of laparoscopic sessions and correlated with increased number of errors and level of discomfort.

**Conclusion:** Laparoscopy is associated with increased fatigue and number of errors when performing simulated complex surgical tasks compared to Open and Robotic techniques.

### VP6-03 IS THERE A MODEL TO TEACH AND PRACTICE RETROPERITONEOSCOPIC NEPHRECTOMY?

M. Hisano, J. Colombo jr, R. Duarte, C. Passerotti, A. Brito, M. Srougi—Brazil

**Background:** Laparoscopy in urology had a rapid evolution since last decade. Kidney procedures can be performed by two main accesses: transperitoneal and retroperitoneal. Although retroperitoneal route had been classically utilized for open surgeries, the transperitoneal route is more used for laparoscopy. There is no retroperitoneal training model to teach this access. This study has the objective to develop and standardize a training model for retroperitoneoscopy, very important for residents and urologists in training.

**Methods:** For first pilot case, we inserted transperitoneal camera and created retroperitoneal space by this view. Fifteen piglets were operated to develop a retroperitoneoscopic nephrectomy (RN) training model, with no need of transperitoneal guidance. Retroperitoneal space was created by finger dissection, and a Hasson-type trocar was utilized in this access. All procedures were retroperitoneoscopically performed with 3 port access. Dissection always carried from arterial control to vein control and ureteral section. Kidney was left in place.

**Results:** We performed 8 right and 7 left procedures. Operative time varied from 15 to 50 minutes, with a median time of 30 minutes. Blood loss varied from 5 to 100 ml, with a median of 20 ml. Accidental peritoneal opening occurred in 5 of the first 6 cases. We had 2 surgical complications: renal vein lesion and slipped renal vein clip, both managed laparoscopically. After 7 cases, all these parameters had an important decrease to a constant result.

**Conclusion:** RN is feasible in a porcine model, and can be used to teach and train many aspects of the procedure: port placement, small working place, anatomic recognition, hilar dissection and avoidance of peritoneal cavity. With this standardization, this procedure can be readily available in training programs, making easy the transition to human procedures.

#### **VP6-04 THE MODIFIED TERMINOLOGIA ANATOMICA OF THE NERVE SPARING LAPAROSCOPIC RADICAL PROSTATECTOMY: IMPORTANT LANDMARKS OF THE PROCEDURE RELATED WITH FUNCTIONAL ANATOMY**

E. Huri, I. Tatar, M. Sargon, C. Germiyanoglu, R. Basar—Turkey

**Background:** The aim is to stress important anatomic landmarks, functional importance of these in a model of patient who had laparoscopic radical prostatectomy.

**Methods:** Extraperitoneal nerve-sparing radical prostatectomy might be summarized into seven steps. Terminologia Anatomica and its functional importance were based on this classification. Steps were; 1) Anterior abdominal wall, trocar positioning, 2) Incision of Fascia pelvis (endopelvic fascia) 3) Detachment of puboprostatic complex, 4) Urethral sphincteric complex 5) Apical dissection of prostate and urethra 6) Fascia rectoprostatica (Denonvillier fascia), 7) Neurovascular bundle, pedicle dissection, pelvic plexus related with erectile function.

**Results:** Important anatomic landmarks of steps: 1) linea alba, linea arcuata (arcuate line), umbilicus, spina iliaca anterior superior (anterior superior iliac spine), m. rectus abdominis (rectus abdominis muscle), a. and v. epigastrica superior–inferior (superior and inferior epigastric artery and vein) 2) fascia pelvis parietalis (endopelvic fascia), arcus tendineus, fascia obturatoria internus (internal obturator fascia) 3) ligamentum puboprostaticum (puboprostatic ligament), plexus venosus dorsalis (Santorini plexus), symphysis pubis (pubic symphysis), detrusor apron, vena dorsalis profunda penis (deep dorsal vein of penis), plexus venosus prostaticus, vesicalis 4) M. sphincter urethrae internus-externus (external-internal urethral sphincter) 5) plexus venosus dorsalis (avoid injury), M. levator ani, neurovascular bundle (avoid injury), smooth muscle of the urethra 6) fascia rectoprostatica, vesicula seminalis, perirectal fatty tissue 7) A.vesicalis inferior (inferior vesical artery), N. cavernosus penis (cavernous nerve of penis), a. and v. capsularis, pelvic plexus, lateral pelvic fascia, levator fascia (interfascial dissection), fascia periprostatica (periprostatic fascia) (intrafascial dissection), capsula prostatica

**Conclusion:** Focusing on anatomy of laparoscopic radical prostatectomy with suitable terminology might be the gold standard way of learning for this difficult surgical technique.

#### **VP6-05 HOW MANY CASES ARE REQUIRED TO DEVELOP COMPETENCE FOR LAPAROSCOPIC RADICAL NEPHRECTOMY PROCEDURES?**

K. Yoo, S. Jeon, K. Han, I. Seo, J. Lim, Y. Ono

**Background:** We evaluated the number of cases required to develop competence for performing laparoscopic radical nephrectomies (LRN) by chronologically analyzing the results of 150 cases.

**Methods:** 150 patients were included in this study, each of whom had had pure transperitoneal LRNs between March 2003 and February 2008 performed by three surgeons who were all novices in laparoscopic surgery. Each surgeon performed 50 cases of LRN. We identified the groups that demonstrated a statistically significant difference in operating time, compared to the most recent group. Based on this finding, we divided the cases into two groups: the novice group and the competent group. The complication rate, transfusion rate, and estimated blood loss were then compared between the two groups.

**Results:** The total average operating time was  $187.6 \pm 46.56$  min; from group 4 onward, there was no significant decrease in the operating time. Therefore, groups 1 to 3 were defined as the novice groups, and groups 4 to 10 as the competent groups. Incidence of intra-operative complications was 6 (13.3%) in the novice group and 9 (8.6%) in the competent group. There were 14 cases with post-operative complications, 4 (8.9%) in the novice group and 10 (9.5%) in the competent group. There were significant differences in the estimated blood loss and transfusion rate between the novice and competent groups ( $236.4 \pm 41.85$  ml vs.  $191.5 \pm 21.9$  ml, 17.8% vs. 4.8%, respectively).

**Conclusion:** Our results suggest that 15 cases are needed for a novice surgeon to achieve competence in LRN. Surgical outcomes and morbidity can be improved once this learning curve has been overcome.

#### **VP6-06 TRANSPERITONEAL VERSUS RETROPERITONEAL PARTIAL NEPHRECTOMY IN A PORCINE MODEL: DIFFERENT OUTCOMES FOR BEGINNERS**

M. Hisano, D. Ikejiri, L. Oliveira, R. Duarte, J. Colombo jr, M. Srougi—Brazil

**Background:** Laparoscopic procedures developed and gained more clinical application, making laparoscopic partial nephrectomy promising. Two accesses are proposed for this purpose: transperitoneal (TPN) and retroperitoneal (RPN). The objectives of this acute experimental study are to present a training model for TPN and RPN and compare their results.

**Methods:** Residents in training randomly performed 10 TPN and 10 RPN in a porcine model. For TPN we utilized four trocars and a 30-degree camera at umbilicus. For RPN we digitally created space 2 cm below last rib and we utilized three trocars with a 0-degree camera. We dissected only artery and temporarily clamped it, followed by a  $2 \times 2$  cm renal resection, 1 cm depth. A bolster of Surgicel<sup>®</sup> was placed at renal defect and parenchyma sutured with Vycril 2.0. Piglet was sacrificed at the end of procedure. Statistical analysis was performed with T Student test.

**Results:** We performed 7 lower, 2 middle and one upper pole TPN, 6 on the left and 4 on the right side. For RPN, we performed 7 left and 3 right procedures (9 lower pole and one middle partial nephrectomy). Medium time for TPN was 15 minutes (12–20), and 25.5 minutes (15–30) for RPN ( $p = 0.0004$ ). Medium blood loss was 10 ml (5–35) for TPN, and 5 ml (5–10) for RPN ( $p = 0.03$ ). Peritoneal opening occurred in six of seven first cases, all during space creation or trocars placement. We have no case of acute complication, major bleeding or conversion. There was no need to perform additional stitches.

**Conclusion:** TPN has a lower medium operative time; blood loss is lower in RPN, but is not clinically significant; besides this, we didn't find statistically significant difference in intraoperative complications rate. RPN is more technically demanding, but this model can facilitate acquisition of skills and training before human procedures.

#### VP6-07 LAPAROENDOSCOPIC SINGLE SITE (LESS) SURGICAL TOOLBOX: INSTRUMENTS, SCOPES, AND PORTS

G. Haber, W. White, S. Crouzet, J. Talarico, R. Goel, J. Kaouk—USA

**Background:** To offer a practical summary of the available tools used during LESS surgery.

**Methods:** With over 100 LESS urologic procedures completed at our institution, we provide an experience-based synopsis of the available LESS equipment.

**Results:** Ports Specifics Advantages Disadvantages R-Port Multi-channel valve (one 12 mm, two 5 mm) covered with an elastomer which maintains pneumoperitoneum.—Flexible-Adapts to size of incision-Fragile-Requires lubrication Uni-X Cone-shaped plastic outer unit converging on three separate 5 mm inlets. Venting-Curved instruments-Fascial sutures-5 mm ports only-RigidGelPort A wound protector, base plate and an external gel piece (unique soft gel-like material) that allows instrument passage.—Ease of instrument exchange-Hand access-Larger incision-Must use ports in addition to GelPort-Expense SILS The flexible port accepts (3) 5 mm cannulas or (2) 5 mm cannulas and a 5 mm-12 mm port.—Improved instrument spacing-Suture passage difficult during robotic LESS AirSeal Oval cannula with invisible pressure barrier—No valves-Stable CO2 pressures-Rigid-Air pump-Only 2 instruments Scopes Specifics Advantages Disadvantages EndoEYE HD Digital videoscope: 5 mm, 30° All-in-one construction CCD chip at the distal tip-Low profile-Image quality-Inadvertent activation of functions EndoEYE LTF Articulating Digital videoscope: 5 mm All-in-one construction CCD chip at the distal tip-Can position image off-axis-Unstable image-Requires skilled assistant Standard Scopes Conventional 5 mm, 30° scope-Ease of access-Cost-External bulk Instruments Specifics Advantages Disadvantages Roticulator Hand-held articulating operating instruments with 80 degrees of freedom- Not Tested-Not Tested-No hook cautery-Pnavel Hand-held fixed instrument with rotating tip -Stability-Rigidity-Lack of articulation-Poor tissue control RealHand Hand-held instruments with full range of motion mirroring hand movement-Low profile handle-Locking mechanism not intuitive Cambridge Hand-held articulating instruments with locking handle-Wide array of products-Bulky handles lead to external clashing.

**Conclusion:** Despite evolving and ever improving surgical equipment for use during LESS surgery, there exists a continued and pressing need for more ergonomic, adaptable, and reliable purpose-built instruments.

#### VP6-08 URETERAL STENTING FOR FELINE URETERAL OBSTRUCTIONS: A POTENTIAL MODEL FOR PEDIATRIC DISEASE

A. Berent, C. Weisse, D. Bagley—USA

**Background:** Ureteral stenting has been performed for a variety of benign and malignant disorders, bypassing an obstruction while directing urine from the renal pelvis to the urinary bladder. The most common ureteral dilemma in feline patients is ureterolith-induced obstruction due to their small ureteral diameter (0.3 mm),

of which traditional surgical therapy is associated with excessive morbidity/mortality. The authors' objective is to describe the technical and clinical outcome of ureteral stenting in feline patients with ureterolith induced obstructions and describe a novel stent prototype used for such small ureters.

**Methods:** Ureteral stents were placed in feline ureters for obstructions secondary to ureterolithiasis or ureteral strictures either endoscopically (retrograde); percutaneously (antegrade); or via a cystotomy (surgically). Both a traditional pediatric (3 french) double J stent as well as a novel stent (multifenestrated 2.5 french double J stent) was used. The smaller stent is not yet commercially available and the success is reported. The details of stent placement will be described.

**Results:** Thirty-two cats (35 ureters) had stent placement (3 or 2.5 french double pigtail) attempted for Ureterolithiasis (30) and ureteral strictures (5). Access was attempted endoscopically (14) and/or surgically (26). 22 female and 10 male cats, weighing 2.1–6.2 kg, were included. Surgical placement was possible in 23/26 (88%) and endoscopic in 5/14 (35%), with an overall success in 28/35 ureters (80%). The smaller 2.5 french stents were placed successfully in all cats attempted (6/6). 28/28 stents (100%) resulted in ureteral/pelvis decompression and azotemia stabilization. Procedure associated complications included: temporary stranguria (5), imperfect stent location (2) and a ureteral tear/trauma (1). One of two displaced stents required adjustment 3 days later. All other procedure associated complications resolved spontaneously without further intervention. Two cats had a stent reaction and required removal and placement of a subcutaneous ureteral bypass. Twenty-five of 28 stents remained in place and patent long-term (range: 10–>810 days). No encrustations were noted. 5/25 cats with stents developed urinary tract infections (4/5 while a nephrostomy tube was present). 3/4 were successfully cleared. One cat had evidence of intermittent hematuria without associated dysuria, infection, azotemia, or pyelectasia. Further investigation was declined.

**Conclusion:** Overall, ureteral stenting is possible, safe, and effective for the treatment of feline ureteral obstructions (stones or strictures), maintaining ureteral patency regardless of stone number or size. Newer small diameter, multi-fenestrated stents are in use and success in placement is excellent. This may be a natural model for pediatric ureteral disease.

#### VP6-09 ASSESSMENT OF FACE AND CONTENT VALIDITY OF A VIRTUAL REALITY LAPAROSCOPIC TRANSPERITONEAL NEPHRECTOMY TRAINER

S. Kolla, D. Pick, M. Louie, B. Argun, R. Sweet, E. McDougall

**Background:** Virtual reality (VR) trainers are being developed to teach and assess surgeons' operative skills. Validation of these simulators is necessary prior to implementing them in training programs. In order to steer continued development, we assessed the face and content validity aspects of the VR-LTN AUA/METI virtual reality laparoscopic transperitoneal nephrectomy (LTN) simulator.

**Methods:** During the 2009 American Urological Association meeting, participants were surveyed and asked to perform the "renal hilar dissection" task on the LTN simulator. A questionnaire evaluating face and content validity was then distributed to the participants. Participants rated the simulator with respect to specific characteristics on a 5-point Likert scale.

**Results:** 39 postgraduate urologists completed the study. The mean age of the participants was 39 years (range 28–61 years).

Eighty-two percent (32/39) had previous laparoscopic experience as a primary surgeon. Ninety percent were performing laparoscopic nephrectomy as the most common procedure in their practice. The average ratings of the trainer are shown in Table 1. Fifty-four percent felt that they would not recommend this simulator for a residency program in its current format. All the participants (100%) felt that the simulator needs further upgradation from the current format. Table 1: Average rating of the simulator by the participants Is LTN simulator a realistic practice platform? \*2.7/5 Is LTN useful for training residents? \*3.1/5 LTN simulator characteristics ^ Graphics/visual images- Educational feedback- Level of difficulty- 3.2/5 2.8/5 2.7/5 \* Likert scale 1-strongly disagree; 5-strongly agree ^ Likert scale 1=poor; 5-excellent

**Conclusion:** The VR-LTN simulator needs further improvement before it can be implemented into training programs. This study provided excellent feedback that will guide further development.

### VP6-10 USEFULNESS OF THE SWINE MODEL FOR TRAINING IN ENDOUROLOGICAL INTERVENTIONS

F. Soria, M. Delgado, M. Pamplona, J. Uson, F. Sanchez

**Background:** The aim of the present work was to evaluate the usefulness of the swine model for training in advanced retrograde endourological techniques.

**Methods:** Female swine were used in order to allow transurethral access. 35–40 Kg animals were selected, because these animals' kidneys are the same size as human kidneys from a 70 Kg. adult. Prior to their use in training, several endourological obstructive and lithiasic models were created, so that the trainees could then use them to increase their skills in endoscopy and fluoroscopically guided endourological techniques. The following procedures can be tested in this model: Ureterscopy, flexible ureterorenoscopy, Endopyelotomy, endoureterotomy, ureteral stricture balloon dilatation, Acucise<sup>®</sup>, endoscopic ureteral lithotripsy, double pigtail stent deployment, metallic stenting, guidewires and catheters manipulation, stent fragment retrieval and endoluminal ultrasound. 45 trainees received 16 hours training in this model. All trainees completed an anonymous survey after training, in order to subjectively evaluate their acquired skills, and the usefulness of this training model.

**Results:** 80% of the students consider that they have advanced “a lot” after receiving this training, whereas 16% referred “a little” improvement and the remaining 4% “very little”. Once the training activity was completed, 89% of the trainees considered themselves ready to include these techniques in their daily practice. 96% of them think this training is highly recommended.

**Conclusion:** Our results suggest that the use of an animal model (with previously induced disorders) is highly effective for training in this setting. Our trainees gained skills instrumental in including endoscopy and fluoroscopically guided approaches to the urinary system in their daily practice, through repeated manipulation under supervision. Animal models may be able to accurately represent the experience in human patients. In our opinion, this approach to training may decrease learning curve time and complications during the early stages of training.

### VP6-11 NATURAL ORIFICE TRANSLUMENAL ENDOSCOPIC SURGERY (NOTES) TOOLBOX: INSTRUMENTS, SCOPES, AND PORTS

G. Haber, S. Crouzet, W. White, J. Talarico, S. Brethauer, J. Kaouk—USA

**Background:** Natural orifice surgery currently involves gaining access to the peritoneum via natural body orifices (transgastric, transcolonic, transvaginal, and transvesicular). There are several major limits to NOTES; however, at our institution we have successfully performed several procedures. We offer a practical summary of the necessary tools used during NOTES.

**Methods:** Instruments used during access in transcolonic and transgastric cases include an over tube with dilator, Olympus dual (160/180) and single channel (T130) endoscopes, needle knife cautery, and an Olympus SWIFT balloon dilator. During the procedure, the previous instruments are used in addition to endoscopic graspers, Olympus Endojaw biopsy forceps, and Olympus surgical scissors. For closure we are using a t-tag based system available under approved protocols (Ethicon's Tissue Apposition System (TAS) or Bard's EndoStitch). Alternatively, there are several other closure devices available (PARE surgical based on endoluminal knot tying) or the H-type by USGI. For transvaginal procedures single port techniques were employed. This included extended length Novare RealHand as well as Cambridge Endo instruments (articulating graspers, Horgan dissectors, and hook cautery). Our visualization came via Olympus EndoEye flexible and traditional Olympus 0o and 30o laparoscopes.

**Results:** Transcolonic and transgastric access and closure is reliable in the canine model using this set of instruments. Procedures such as peritonoscopy, drainage of intrabdominal abscess, cholecystectomy, and appendectomy are feasible. Transvaginal experience is limited to nephrectomy using single port techniques and extended length instruments.

**Conclusion:** Industry support and physician acceptance are required to continue developing new dedicated NOTES instruments. Although there are ever expanding possibilities, there exists a continued and pressing need for an entirely new platform dedicated to NOTES. We continue to practice cautious optimism.

### VP6-12 NEW COMBINED APPROACH VERSUS STANDARD TECHNIQUE IN METALLIC URETERAL STENTING. EXPERIMENTAL STUDY IN SWINE

F. Soria, M. Delgado, L. Rioja, M. Blas, J. Uson, F. Sanchez—Spain

**Background:** The appearance of hyperplasia after metallic ureteral stenting has been suggested to be mainly due to the interaction between the ends of the stent and the healthy peristaltic ureter. The aim of this study was to assess the therapeutic value of a new treatment option for ureteral strictures that may avoid urothelial hyperplasia, which is the main cause of metallic stenting failure in the urinary system.

**Methods:** Twenty four Large white swine with a weight range of 30–35 Kg were used for this study. An experimental modelo of ureteral stricture was laparoscopically induced in all animals. Obstruction was confirmed using ultrasonography and retrograde ureteropyelography (RUP) 6 weeks after model creation. Animals were then randomly allocated to two experimental groups. Therapy involved stent graft (stent size 6 mm×30 mm) deployment in the ureter stricture (Group I) and the subsequent endoscopic ureterotomy at the ureteral segments adjacent to both ends of the stent using a 3 Fr Greenwald cutting electrode (Group II). A double pigtail stent was then deployed for three weeks. Completion studies performed at 6 months after therapy included RUP and ureteroscopy, assessing the formation of urothelial hyperplasia at the ends of the stent.

**Results:** Experimental ureteral stricture was created successfully in all animals. By the end of the study, no evidence of urothelial hyperplasia was seen in 50% in Group I and 71.4% in Group II. Four cases of cranial stent migration in Group I and two cases in Group II were seen at 6 months, with the stents located at the lower renal calyces. Mild stent encrustation was seen in a single animal (group II), and no cases of urinoma were evidenced during the study.

**Conclusion:** Hyperplasia was markedly reduced when ureteral peristalsis was inhibited by performing an endoureterotomy at the area of interaction between the stent and the ureter. This technique may avoid obstructions secondary to hyperplasia, thus increasing the potential indications of metallic ureteral stents.

### VP6-13 THE IMPACT OF LAPAROSCOPIC FELLOWSHIP PROGRAMME OVER A SIGNIFICANT LAPAROSCOPIC NEPHRECTOMY EXPERIENCE

O. Sanli, T. Tefik, T. Mut, H. Issever, D. Teber, J. Rassweiler—Turkey

**Background:** To evaluate the impact of 3-month laparoscopic fellowship programme (LFP, SLK Klinikum Heilbronn, Germany, August–October 2008) over a significant laparoscopy experience including mainly renal ablative surgeries.

**Methods:** Between September 2005 and June 2009, 131 patients underwent laparoscopic nephrectomies (LN). Group 1 (87 patients) and 2 (44 patients) was defined as patients who underwent laparoscopic operation before and after LFP. All data were prospectively recorded on a database system and then retrospectively reviewed.

**Results:** There was no statistically significant difference in age, BMI or ASA score between the two groups. Group 2 yielded a significantly shorter mean operative time ( $134.82 \pm 63.69$  vs  $110.75 \pm 36.68$  min.,  $p = 0.028$ ), lower estimated blood loss ( $283.56 \pm 412.97$  vs  $115.68 \pm 123.54$  mL,  $p < 0.005$ ), lower hematocrit drop ( $4.10 \pm 2.69$  vs  $2.59 \pm 3.28$ ,  $p = 0.006$ ) and shorter hospital stay ( $3.94 \pm 2.52$  vs  $3.11 \pm 2.67$ ,  $p < 0.002$ ). The retroperitoneal approach rate was higher in Group 2 compared to Group 1 (90.9% vs 29.9%,  $p < 0.005$ ). In addition, the rate of performing LN by attending surgeon to trainee's was significantly higher in Group 2 (3.4% vs 20.5%,  $p = 0.003$ ). However, there was no statistical significance between transfusion, complication and open conversion rates among groups. Overall easy, difficult and very difficult cases according to European Scoring System before and after LFP were 8.7% vs 13.3%, 77.1% vs 52.2% and 14.0% vs 34.4%, respectively.

**Conclusion:** To our opinion, it is worth receiving a LFP even if a surgeon has a significant laparoscopy experience. Because, transferring experience of a mentor improves perioperative outcomes. Moreover, LFP is an indispensable step initiating advanced laparoscopic cases.

### VP6-14 TRAINING OF UPPER URINARY TRACT ENDOSCOPY—EXPERIENCE WITH A NEW MODEL USING PORCINE URINARY TRACT

P. Liske, P. Ober, Y. Aguilar, V. Zimmermanns, S. Lahme—Germany

**Background:** Endourological procedures are of high significance in diagnosis and treatment of upper urinary tract diseases. In order to improve surgical skills it is advisable for the urological surgeon to perform in vitro exercises. So far just two-dimensional training

models were available. A new three-dimensional training model using a porcine urinary tract allows to learn and practice endourological techniques close to reality.

**Methods:** The transportable training model consists of a stainless steel torso covered with a neoprene cover. The relief of the retroperitoneum is imitated by a wire grating. The porcine urinary tracts are fixed by use of special granulate material. The urethra is fixed by suturing into a flexible silicone funnel to allow easy access to the urinary tract. All components are easy to clean and provide good hygienic conditions.

**Results:** The elastic fixation of the urinary tract allows the use of semirigid and flexible ureterorenoscopes in conditions close to reality. It is possible to prepare the urinary tract with artificial stones to practice the use of holmium laserlithotripsy. The training model was used successfully in many endourological workshops. So far more than 150 urologists have been trained successfully.

**Conclusion:** The newly developed training model allows to learn and practice endourological techniques close to reality because of its special three-dimensional configuration and the use of porcine urinary tract. It was successfully used in education of urologists.

### VP6-15 LAPAROSCOPIC RADICAL PROSTATECTOMY: IMPACT OF LEARNING CURVE ON OPERATIVE AND PATHOLOGIC OUTCOMES FOLLOWING LAPAROSCOPIC UROLOGY TRAINING

T. Erdogru, A. Ciftcioglu, M. Baykara—Turkey

**Background:** We assessed the operative and oncologic results in laparoscopic radical prostatectomy (LRP) performed by the fellowship-trained surgeon in his independent practice.

**Methods:** The prospectively created records of all consecutive LRPs were reviewed and 250 patients in whom the same surgeon performed the LRP were included. Patients were divided into three groups based on the time of surgery: group I included the first 70 cases; group II the second 70 cases; and group III the last 70 cases. We compared the rate of positive surgical margins, prostate-specific antigen level, Gleason score, stage and tumor volume were also evaluated.

**Results:** Patient demographics and preoperative staging variables were comparable with no statistically significant differences among the three groups. The positive surgical margin rates for pT2 disease were 11.1% (4/36), 7.3% (3/41) and 4.7% (2/42) for groups I, II and III, respectively. While the difference significant in pT2 disease, in overall positive margin rates in the three groups was statistically insignificant ( $p = 0.218$ ).

**Conclusion:** Operative safety can be achieved with laparoscopy training in independent practice. However, a reduction in positive surgical margin rates in pT2 disease demonstrates an independent confidence curve, of approximately 70 cases in LRP.

### VP6-16 HYBRID NATURAL ORIFICE TRANSLUMINAL ENDOSCOPIC SURGERY (NOTES) FOR NEPHRECTOMY WITH STANDARD LAPAROSCOPIC INSTRUMENTS. EXPERIENCE IN A CANINE MODEL

A. Aminsharifi, A. Taddayun, S. Shakeri, M. Hashemi, M. Abdi

**Background:** To demonstrate the feasibility of hybrid-NOTES nephrectomy with standard laparoscopic instruments through a modified vaginal trocar in a canine model.

**Methods:** Ten cross-bred adult female dogs were used for right ( $n = 4$ ) and left ( $n = 6$ ) transvaginal nephrectomy. After transumbilical peritoneoscopy, a laparoscopic transvaginal trocar was

introduced through the posterior vaginal fornix under direct vision. Using a 10-mm working laparoscope lens with a 3-mm working channel as endovision via the umbilical port and the transvaginal port, triangulation and dissection of the kidney and its hilum were possible. The renal artery and vein were closed with Hem-o-lok clips transvaginally. At the end of the procedure, after snaring the kidney in an endobag, the specimen was retrieved through a colpotomy incision by extending the vaginal port site.

**Results:** All procedures were completed successfully without need for conversion. Mean operative time was 101 min (75–135 min). Mean preoperative/postoperative hemoglobin was 12.01/11.7 g/dL. Intraoperative blood loss was minimal. Mean size of the removed kidneys was 9.1×5.1 cm, and mean weight was 98.5 g (90–115 g). One month- abdominal and vaginal exploration showed complete healing of the colpotomy incision with no visceral injury. There were no significant adhesions or fibrotic changes in the renal fossa.

**Conclusion:** Hybrid-NOTES nephrectomy is technically feasible in canine model with a standard laparoscopic setup and instruments. This study may remove barriers for further investigational work with NOTES technique, especially with a view to adapting it for use in low-resource centers, while offering a strategy to help surgeons train with this novel technology.

#### VP6-17 INTENSIVE TRAINING COURSE IN LAPAROSCOPIC RADICAL PROSTATECTOMY

A. Garcia Segui, E. Bercowsky u, C. Ballesteros, R. Valero, W. Husband, J. Moanack—Spain

**Background:** Laparoscopic Radical Prostatectomy (LRP) has emerged as an excellent treatment for prostate cancer; however, it requires a long and costly training. In Latin America the number of centers who perform LRP is few as well as the laparoscopic training institutes. Many urologists are better skilled to perform upper urinary tract laparoscopic procedures but have less experience with LRP or don't perform it at all, since they have not enough time to train. We developed an intensive training course in LRP aimed to improve the skills of urologists with previous experience in laparoscopy and intracorporeal suturing.

**Methods:** The course is performed in pelvic trainer with LRP simulators, and with experimental animals. It consists in 4 workstations mentor-assisted in ascending difficulty to make intracorporeal suturing and circular running suture anastomosis. The first task is performed in a homemade synthetic simulator of urethrovesical anastomosis (UVA), the second is in a chicken trachea like model of UVA, the third is the classic chicken model for LRP and the fourth is LRP in canine model. The trainees performed all stations during two days, and finally they assisted a LRP live-surgery like observer. The trainees answered a test one month after the course. Their ability to perform the surgical steps was evaluated by the mentors.

**Results:** Five of the 6 urologists who participated in this study, showed at the end point an enhanced ability to perform an accurate circular anastomosis. The 66% trainees believe that this program improved their surgical practice like to make their first LRP, 50% made the first LRP with a mentor one month after the program.

**Conclusion:** Our Intensive Training Course in LRP is an effective alternative to initial teaching in prostatic laparoscopy. The mentor is fundamental to start the learning curve in LRP. In the future,

Latin America must establish training programs in LRP in the majority centers with urological residence.

#### VP6-18 LEARNING CURVE OF LAPAROSCOPIC RADICAL PROSTATECTOMY IN A BRAZILIAN NON-UNIVERSITARY PUBLIC HOSPITAL: DIFFICULTIES AND POSSIBILITIES

L. Curcio, A. Cunha, J. Renteria, M. Marinho, R. Freire, G. Di biase—Brazil

**Background:** The first laparoscopic radical prostatectomy was done by SHUESLLER in 1992 and since that, it has spreading worldwide ( robot- assisted or pure laparoscopic) like a minimally invasive oncologic treatment. We began our cases in 2001, however only in 2007, at a second stage, we followed our program improving our skills in laparoscopic prostatectomy surgery. We present our difficulties and first results.

**Methods:** From 2001 to 2007 (phase I), we performed transperitoneal access following Moutsouris technique, with a previous conversion surgical time combined with anesthesiologist. At a second moment (Phase II), since 2007, finally, we evolved and finalized the most of cases, introducing techniques modifications.

**Results:** Initially, 8 patients were operated and all surgeries were converted to open procedure. However, at a second stage, after hands-on-training, in our Intitution, forty procedures were done, with only 6 conversions. Our main difficulties were: bleeding, seminal vesicles approach and a bad surgical exposure by a non-training surgical team. Our surgical time was 270 minutes and despite of a non-satisfactory potency, the continence tax was good.

**Conclusion:** Laparoscopic radical prostatectomy is feasible, at little resource hospitals, in developing countries. Surgical team must be exhaustedly trained and difficulties can be overwhelming after reach the top of this steep and achievable learning curve.

#### VP6-19 THE USE OF EX VIVO SIMULATORS AND AN ANIMAL MODEL FOR TRAINING IN PERCUTANEOUS NEPHROSTOMY

F. Soria, M. Delgado, M. Pamplona, V. Gonzalez, J. Uson, F. Sanchez

**Background:** The objective of this study is describe our teaching model for an antegrade approach to the urinary tract, using an ex vivo model and a porcine animal model.

**Methods:** We began our percutaneous nephrostomy training module with the basic manoeuvres, so that trainee get the chance to practice using ultrasound to guide the puncture needle towards the target, in this case the renal pelvis. For this we use an ex vivo model consisting of a porcine kidney in which the pyelocaliceal system has been dilated. The kidney is embedded in a solidified gel, in order to allow trainees to practice renal puncture using ultrasound as a guide. Once this initial phase is complete, we use a new ex vivo simulator to teach trainees about nephrostomy, using a porcine liver with a porcine kidney between its lobes, the kidney having been fitted with a system that dilates the pyelocaliceal system. This simulator allows transhepatic punctures of the kidney to be performed, as well as the introduction of guide catheters and dilators (Alken) and the Amplatz sheath, in order to practice percutaneous nephrostomy (and implanted stones in order to perform lithotripsy for kidney stones using a laser) Once trainees have finished practicing on ex vivo models, we move on to a porcine animal model. In preparation for this stage, 3 weeks previously, an

obstructive uropathy model is created by ureteral laparoscopic ligature, using material that is reabsorbed in the short-term, thereby dilating the urinary passage, permitting a percutaneous nephrostomy to be performed using ultrasound or fluoroscopy to guide the procedure. This porcine model allows trainees to practice percutaneous puncture, tract dilation of the nephrostomy, and the introduction of calculi into the kidney in order to practice lithotripsy for kidney stones. It also allows trainees to practice manoeuvring guide catheters using a fluoroscope, and to perform an antegrade endopyelotomy. The results are assessed through an anonymous survey of the 20 trainees involved in this basic training, in which they describe the dexterity they have acquired and comment on the merits of using an animal model for this activity.

**Results:** 80% of trainees completing the survey said that they had made a lot of progress through this training, whilst 15% thought that the progress made was normal, and 5% said that they hadn't advanced much. 85% believed that after completing this training exercise they would be ready to start using these techniques in their hospitals. 100% of the trainees said that they would recommend the activity to their colleagues.

**Conclusion:** This study confirms the suitability of combining an ex vivo simulator with an animal model in basic Endourological training, enabling trainees to acquire the basic skills required in order to practice the procedure, through repetition of the manoeuvres involved and ongoing training. We therefore believe that this model will allow the learning curve for an antegrade approach to be shortened, reducing iatrogeny in the initial phases of learning this advanced technique. It allows trainees to know the different instruments used, and to practice the procedure for the first time, gaining dexterity as they do, since the animal model is very similar to actual clinical situations, offering the same tactile sensations, bleeding and elasticity. Furthermore, by using a combination of ex vivo models and an animal model, the use of experimental animals is reduced, thereby complying with one of the

ethical goals set forth in the relevant European Directive (86/609), on the protection of animals used for experimental and other scientific purposes, including medical training.

### VP6-20 DEFINING A LEARNING CURVE IN LAPAROSCOPIC SIMPLE PROSTATECTOMY

F. Heldwein, R. Sanchez-salas, E. Barret, M. Galiano, X. Cathelineau, G. Vallancien—France

**Background:** To assess the process of obtaining proficiency in laparoscopic simple prostatectomy (LSP) by examining outcomes from our first 101 LSP cases.

**Methods:** 101 consecutive patients with symptomatic benign prostatic hyperplasia underwent LSP between January 2003 and January 2008. Prostate volume, IPSS, uroflowmetry, post void residual, mean operative time, estimated blood loss, duration of catheter use, length of hospital stay, and complication rates were analyzed in this patient subset by dividing patients into one of two groups: Group 1, cases 1–50; Group 2, cases 51–101.

**Results:** There was no difference between the groups in terms of age, prostate volume, uroflow, IPSS score or post void residual. There was a significant decrease in operative time between the two groups ( $107 \pm 28.6$  minutes vs  $84 \pm 33.1$  minutes;  $p < 0.001$ ). No significant difference was observed regarding mean blood loss (325 mL vs. 400 mL;  $p = 0.275$ ). Although minor complications were more numerous in the last 51 cases, major complications tended to decrease with time ( $p = 0.014$ ). The duration of bladder catheter tends to decrease after the 50th case ( $p < 0.001$ ).

**Conclusion:** Laparoscopic simple prostatectomy is safe with comparable outcomes to those published for open prostatectomy series. The operative time can be effectively reduced with practice and we estimate the learning curve for this procedure to be 50 cases.

## VP7: LAPAROSCOPY-KIDNEY 2

### VP7-01 EXPERIENCE WITH 830 CONSECUTIVE LAPAROSCOPIC DONOR NEPHRECTOMIES: A CALL FOR USING A STANDARDIZED CLASSIFICATION OF COMPLICATIONS

A. Breda, J. Harper, J. Leppert, J. Veale, A. Gritsch, P. Schulam

**Background:** Laparoscopic living donor nephrectomy (LLDN) offers patients the benefits of decreased morbidity and improved cosmesis. LLDN is associated with equivalent graft outcomes and similar complication rates, when compared with open donor surgery. Using a standardized complication schema would allow comparing and combining data so potential donors could be adequately counseled. Presented is the largest series of LLDN by a single surgeon.

**Methods:** Between March 2000 and May 2009, a single surgeon at our institution performed 830 initial and consecutive LLDNs. A retrospective and prospective chart and database analysis, approved by the IRB has been performed. A dedicated committee

composed of donor and recipient surgeons, transplant nephrologists, radiologists, psychiatrists and coordinators were in charge of donor selection.

**Results:** Mean donor age was 40.5 years and average BMI was 25.7. There were three open conversions (0.3%), one was elective due to failure to progress and two the result of major vascular complications (0.24%). 44 of 830 patients had a complication for an overall complication rate of 5.3%. Median hospital stay was one day and readmission rate 1.2%. There were five reoperations (0.6%), none for the control of bleeding. No patients required a blood transfusion and there were no mortalities. Using a modified Clavien classification of complications previously described for live donor nephrectomy, 68.1% were grade 1, 29.5% grade 2 (11.3% 2a, 13.6% 2b, 4.5% 2c), 2.2% grade 3, and there were no grade 4 complications.

**Conclusion:** With appropriate patient selection and operative experience, LLDN is a safe procedure associated with low morbidity.



The use of a standardized classification of complications specific for this procedure is encouraged. At our institution, LLDN is considered the standard of care.

### VP7-02 COMPARATIVE OUTCOMES OF THE OPEN, HAND ASSISTED AND FULL LAPAROSCOPIC LIVING DONOR NEPHRECTOMY

W. Kongchareonsombat—Thailand

**Background:** Kidney transplantation is the standard treatment for end stage renal disease which the patients can quit the dialysis. There are many methods of harvesting kidney from living donor. The minimal invasive surgery is tend to replace the open surgery. Such as hand assisted and full laparoscopic nephrectomy have been performed in many institutes. So we will showed the outcomes of these three procedures in Ramathibodi Hospital.

**Methods:** We recruited the data of living donor nephrectomy operation since January 2006 to March 2009. There are total 103 living donor which can be divided in 68 open procedure, 14 hand assisted and 21 full laparoscopic procedure. Operative time (hours), Warm ischemic time (min), Length of hospital stay (day), Estimated blood loss (cc), were compared among three groups and complications were reported.

**Results:** The operative time (min.), warm ischemic time (min.), length of hospital stay (days) and estimated blood loss (cc.) of Open:HAL:full LAP are 144:192:162; 2.0:2.5:2.9; 6.5:5.0:6.6; 336:142:209 ( $p < 0.05$ ) in orderly. And the complications we found five patients with bowel ileus, two in open procedure, one case in HAL and two in full laparoscopy. There are one patient with adrenal injury and two patients had chylous fluid from drain in open procedure group.

**Conclusion:** Laparoscopic living donor nephrectomy has been shown to be a safe procedure in experienced hands. The operative time and warm ischemic time were slightly longer in laparoscopic group. Blood loss, analgesic use and complications were fewer in laparoscopic groups. Length of hospital stay seem not different in the three groups. Nevertheless the laparoscopic procedure is need the long learning curve and experienced surgeon.

### VP7-03 LAPAROSCOPIC DONOR NEPHRECTOMY AT A SINGLE INSTITUTION; KITASATO EXPERIENCE IN CONSECUTIVE 45 CASES

D. Ishii, M. Iwamura, K. Tabata, K. Yoshida, S. Baba

**Background:** Laparoscopic donor nephrectomy (LDN) is now widely accepted as a minimal invasive procedure for living renal transplantation. Since September 2001, LDN has been performed as a standard procedure for donor of living donor nephrectomy at our institution. We compared our experience with laparoscopic and open donor nephrectomy in a single institution.

**Methods:** Between 1992 and 2009 we performed open donor nephrectomy and 45 pure laparoscopic donor nephrectomy. In LDN, there were 12 males and 33 females with median age of 57 (range, 33–68) years old.

**Results:** Mean BMI of donors was 23.4 (range 18–26). 38/45 (84.4%) patients were left LDN. Mean operative time was 291 (188–345), warm ischemic time was 417.9 seconds (240–710). Mean length of hospital stay was 7.3 (4–13) days. Only one patient was led to open conversion. There have been no cases of donor renal failure or procedure-related death. Donor nephrectomy was associated with less blood loss ( $p < 0.01$ ), a shorter hospital stay

( $p < 0.01$ ), less analgesic usage ( $p < 0.01$ ) compared to open donor nephrectomies.

**Conclusion:** Laparoscopic donor nephrectomy resulted in less blood loss and shorter hospital stay than open nephrectomy. LDN appears to provide advantages for the donor in comparison to open donor nephrectomy.

### VP7-04 TRANSPERITONEAL VERSUS RETROPERITONEAL LAPAROSCOPIC LIVING DONOR NEPHRECTOMY: COMPARISON OF TWO PROCEDURES REGARDING CLINICAL OUTCOME AND COMPLICATION RATE

M. Saito, N. Tsuchiya, S. Narita, Y. Horikawa, S. Satoh, T. Habuchi

**Background:** Recently, endoscopic donor nephrectomy has been widely accepted to many kidney transplant programs due to its minimally invasiveness and cosmetic perspective. In Akita University, retroperitoneoscopic living donor nephrectomy (RDN) was introduced since July 2001. However, retroperitoneal approach may be technically demanding because of its narrow working space and fewer anatomical landmarks. Furthermore, laparoscopic nephrectomy for renal cancer patient may be comparable to retroperitoneoscopic procedure regarding minimal-invasiveness and surgical risk. We shifted the surgical procedure from retroperitoneal to transperitoneal approach (transperitoneal laparoscopic living donor nephrectomy; LDN) in June 2005. Since there are few reports about the comparison of the clinical outcome between RDN and LDN, we compared the clinical outcome and complication rate between RDN and LDN (a single center analysis).

**Methods:** From July 2001 to April 2009, 146 pairs of living donor and recipient who underwent kidney transplantation in our institution were included in this study (RDN group; 84, and LDN group; 62 pairs). We compared following parameters between RDN and LDN; donor background, operating time, estimated blood loss, warm ischemic time, total ischemic time, time to oral intake, intra- and post-operative complication rate, serum creatinine level of recipients (1, 7, 30, 180, 365 days after the operation), and frequency of delayed graft function (DGF).

**Results:** There is no significant difference of donor background between the two groups. The warm ischemic time in LDN group was significantly longer than that in RDN group ( $342 \pm 163$  vs  $231 \pm 163$  sec,  $p < 0.001$ ), however, there were no significant differences of any clinical parameters including operating time, estimated blood loss, total ischemic time, time to oral intake, and graft function between RDN and LDN (frequency of DGF in RDN and LDN were 9.5% (8/84) and 9.7% (6/62), respectively). Intra-operative complications occurred in 2 patients (2.4%) with RDN and 1 (1.6%) in LDN. They were 2 cases with endoscopically uncontrollable bleeding from the lumbar vein in the RDN group and one case with pneumothorax in the LDN group. Minor post-operative complication of RDN and LDN occurred in 10 (11.9%) cases and 9 (14.5%) cases, respectively. No major complications including intestinal disorders were observed in both groups.

**Conclusion:** There is no difference in a safety, efficacy and the short-term graft function between LDN and RDN. The approach in endoscopic donor nephrectomy may be determined from the surgeons' preference and patient's history of abdominal surgery because of the comparable outcomes.

### VP7-05 RIGHT-SIDED LAPAROSCOPIC DONOR NEPHRECTOMY—INITIAL EXPERIENCE OF SINGLE CENTER

D. Perlin, I. Alexandrov, G. Zolotarev, K. Kargin—Russia

**Background:** It concerns that laparoscopic donor nephrectomy is more difficult on the right side than the left, because of the short right renal vein.

**Methods:** Since January 2009, three patients underwent right-sided transperitoneal live donor nephrectomy. The donor is positioned in a traditional left lateral decubitus position, five ports were used, including one to retract the liver. Renal arteries were clipped twice and divided. The right renal vein is gently stretched laterally. The vein is then stapled using the modified Endo-GIA 30 12 mm. stapler. We removed 2 row of staples and cutting blade from device, then divide the vein with scissors close and parallel to the staple line. The tension on the renal vein allows to place the row of staples on the wall of the vena cava, increasing the graft vein length. Kidney were retrieved in all cases through a short Pfannenstiel incision. The records of donors and recipients, including early graft outcomes were reviewed.

**Results:** Median total warm ischemic time was 5 minutes. The median operating time was 212 minutes. In one case we used PTFE vascular graft for anastomosis with renal graft vein. The serum creatinine of all recipients normalized within 96 hours.

**Conclusion:** Right-sided laparoscopic donor nephrectomy is feasible and safe. The modification of GIA helps to take a more longer renal vein.

### VP7-06 RETROSPECTIVE COMPARISON OF LAPAROSCOPIC PARTIAL NEPHRECTOMY AND LAPAROSCOPIC RENAL CRYOABLATION FOR SMALL

G. Haramis, J. Rosales, Z. Okhunov, K. Badani, M. Gupta, J. Landman—USA

**Background:** We compared perioperative and short-term outcomes of laparoscopic partial nephrectomy (LPN) and laparoscopic renal cryoablation (LCA) in patients with small (<3.5 cm) renal cortical neoplasms.

**Methods:** A retrospective analysis from our prospectively established institutional database was performed. We identified 86 patients (group 1) treated with LPN and 80 patients (group 2) treated with LCA.

**Results:** The two groups were comparable in mean tumor size (2.1 for LPN, 2.0 for LCA;  $p=0.24$ ), mean operative time (149.5 vs 132.1 min,  $p=0.06$ ), preoperative (0.9 vs 1.1 mg/dl,  $p=0.64$ ) and postoperative creatinine levels (1.16 vs 1.1,  $p=0.44$ ). Patients undergoing LPN characterized by younger age (mean age 58.9 vs 69.2;  $p<0.001$ ), greater intraoperative blood loss (169.3 vs 66.8 ml;  $p=0.007$ ) and prolonged length of hospitalization (2.4 vs 1.6 days;  $p<0.001$ ). LCA group had 4 complications (4.1%), 3 hemorrhages leading to transfusion (3.1%) and 1 conversion (2.5%); LPN group had 3 complications (3.4%): 2 transfusions (2.3%) and 1 conversion (1%). The mean follow-up time was 28.2 months for group 1 and 12.2 months for group 2. Two recurrences were detected in the LCA group (2.1%) at 4 and 18 months, respectively. Only 1 case had positive margins in LPN group, while no recurrences were reported.

**Conclusion:** In the treatment of small (<3.5 cm) renal cortical neoplasms, LPN and LCA seem to be equally effective. LCA offers decreased blood loss and shorter hospital stay and equal morbidity

(despite older patients with more co-morbidities). Longer follow-up is required to establish oncologic efficacy.

### VP7-07 RETROPERITONEOSCOPIC RADICAL NEPHRECTOMY VERSUS OPEN RADICAL NEPHRECTOMY: ONCOLOGIC LONG TERM RESULTS FOR LOCALIZED RENAL CELL CARCINOMA <7 CM

A. Feicke, R. Strebel, G. Müller, A. Bachmann, T. Sulser, T. Hermanns

**Background:** Videoendoscopic radical nephrectomy is an established surgical treatment modality for localized renal cell carcinoma (RCC). Long-term follow-up has shown comparable oncological outcome with the open technique. The retroperitoneoscopic approach is used in many centers for tumor nephrectomy. However, oncologic long-term results are still scarce.

**Methods:** Between 1998 and 2006 109 patients (pts) underwent retroperitoneoscopic nephrectomy (RN;  $n=64$ ) or open nephrectomy (ON;  $n=45$ ) for localized RCC <7 cm in two centers. Medical records of all pts were reviewed for retrospective data collection.

**Results:** Baseline patient characteristics were comparable between the two groups. No significant difference between the two groups could be detected regarding median tumor size (RN: 4.4 cm; ON: 5.0 cm), distribution of T-status (RN: pT1 84%, pT3 16%; ON: pT1 73%, pT3 27%) Fuhrman Grade and histological grading, respectively. Median Follow up was 54 months (RN) and 82 months (ON). In the RN group disease recurrence developed in 3 pts (4.6%) within one to 13 months. All of those patients died due to cancer metastasis. In the ON group, 5 pts (11%) were diagnosed with recurrent disease within 18 and 59 months. At last follow up, 2 of those patients were still alive while 3 had died from to disease progression. No difference was revealed between the two groups for recurrence free, tumor-specific and overall survival. Five-year recurrence-free survival rate was 95% and 84%, 5-year cancer-specific survival rate 94% and 97% and 5-year overall survival rate 87% and 82% for RN and ON, respectively.

**Conclusion:** Our data demonstrate an excellent oncological outcome for retroperitoneoscopic nephrectomy and comparable results to the open technique for localized RCC <7 cm.

### VP7-08 PROSPECTIVE MINIMALLY INVASIVE APPROACH TO MANAGEMENT OF SMALL RENAL MASSES: EVIDENCE OF SIGNIFICANT INTERVAL GROWTH OR SIZE GREATER THAN 3 CM PRIOR TO INTERVENTION

R. Carey, T. Hakky

**Background:** For management of renal malignancies, nephron-sparing surgery (NSS) and minimally invasive techniques (laparoscopy) are preferable to whole kidney removal or open surgery whenever possible. For solid, enhancing renal masses less than 3 cm, watchful waiting should be encouraged unless the mass has demonstrated interval growth.

**Methods:** Institutional Review Board Approval was obtained for this study. 183 patients with a renal mass presented to a single surgeon fellowship-trained in endourology over a 30 month period. Patients with a solid, enhancing cortical mass less than 3 cm were strongly encouraged to elect conservative management. Patients with larger tumors were offered partial nephrectomy, radical nephrectomy, or radiofrequency ablation. Patients with suspected upper tract urothelial carcinoma were stratified for endoscopic biopsy and diagnosis followed by appropriate treatment.

**Results:** Of 193 patients, 32 (16.6%) had renal masses less than 3 cm and elected watchful waiting. Those treated elected for laparoscopic radiofrequency ablation (47, 24.4%, avg tumor size 3.6 cm), laparoscopic partial nephrectomy (5, 2.6%, avg size 2.2 cm), laparoscopic radical nephrectomy (49, 25.4%, avg tumor size 8.2 cm), laparoscopic nephroureterectomy (30, 15.5%), endoscopic fulguration of urothelial carcinoma (5, 2.6%), open partial nephrectomy (2, 1.0%, avg tumor size 4.8 cm), open radical nephrectomy (10, 5.2%, avg tumor size of 15.2 cm) and 13 patients (6%) entered a separate ablation protocol outside this study. No patients with NSS progressed to metastatic disease. No transfusions or visceral injuries occurred in the NSS group. Only four patients in the WW group showed interval growth requiring treatment (avg follow-up 14 months). In the NSS group, 100% had a biopsy and all were diagnosed as either renal cell carcinoma, oncocytic tumor, or angiomyelolipoma (one small tumor). There were no intraoperative deaths and one perioperative death (at 2 months from DVT/embolism in a cytoreductive procedure for metastatic disease).

**Conclusion:** Judicious choice of which patients should undergo treatment for renal masses helps to prevent unnecessary intervention. Larger masses (>3 cm) that have shown interval growth are more likely to be correctly diagnosed at biopsy prior to ablation and are more likely to be a renal cell cancer or oncocytic tumor than those masses treated immediately upon presentation. Complications rates are kept low with no deaths and no transfusions by use of a thermal, coagulative necrosis-based ablation strategy for larger tumors in the NSS group. Open surgery was reserved for extremely large tumors. Only two patients (each with tumors less than 2 cm) were lost to intervention after second opinion at a separate institution.

#### VP7-09 PERIOPERATIVE OUTCOMES IN LAPAROSCOPIC PARTIAL NEPHRECTOMY FOR HILAR TUMORS: COMPARING OFF-CLAMP SURGERY TO COMPLETE HILAR CONTROL

A. Srinivasan, S. Saluja, L. Richstone, L. Kavoussi, A. George, H. Amin

**Background:** The objective of this study was to compare intraoperative and perioperative outcomes for patients undergoing laparoscopic partial nephrectomy (LPN) for hilar tumors and peripheral tumors. Excision was completed after control of the renal artery and vein OR off-clamp thus completely avoiding warm ischemia time.

**Methods:** A retrospective review of all patients undergoing LPN from January 2006-June 2009 was completed. Hilar tumors were defined as those abutting the renal artery and/or vein identified during surgery. Intraoperative parameters and perioperative outcomes were compared between hilar (n = 21) and peripheral tumors (n = 258) using Mann-Whitney U Test.

**Results:** Excision of hilar tumors was largely completed with control of the vessels (80.3%) compared to peripherally located lesions (57.9%),  $p < 0.05$ . The requirement of blood transfusion was significantly higher for hilar tumors (10.6% vs. 0.7%,  $p < 0.05$ ) though mean estimated blood loss was not significantly different between the groups (369 ml vs. 304 ml). Those with hilar tumors experienced more complications (6.1% vs. 0.7%,  $p < 0.05$ ) including postoperative renal failure with an mean increase of creatinine of 34.2% vs. 18.1% postoperatively,  $p < 0.05$ . Mean tumor volume was 58% greater in the hilar group (50.94 cm<sup>3</sup> vs. 30.05 cm<sup>3</sup>,  $p < 0.05$ ). ASA, medical comorbidities, operative time,

and length of hospital stay were not significantly different between the groups.

**Conclusion:** LPN for hilar lesions is a technically challenging surgery, but feasible in capable hands. Short-term outcomes for peripheral tumors are superior though additional data is needed to determine if these differences have long-term consequence.

#### VP7-10 PERIOPERATIVE OUTCOMES OF LAPAROSCOPIC PARTIAL NEPHRECTOMY STRATIFIED BY BODY MASS INDEX: DOES MINIMAL INVASIVE SURGERY MAKE A DIFFERENCE?

A. S. Herati, A. Srinivasan, A. George, S. Saluja, L. Richstone, L. Kavoussi

**Background:** Increased body mass index (BMI) has been shown to have inferior perioperative outcomes with open surgery. The aim of this study was to determine the differences in perioperative outcomes for patients undergoing Laparoscopic Partial Nephrectomy in normal, overweight, and obese individuals.

**Methods:** A retrospective review of 279 patients undergoing LPN from January of 2006-June 2009 was performed stratifying patients according to BMI of <25 (group 1, normal), 25–30 (group 2, overweight), and >30 (group 3, obese). ANOVA test was used to compare comorbidities, and perioperative outcomes among the groups.

**Results:** Of the obese patients undergoing LPN, 23% more presented with diabetes mellitus with end organ damage ( $p = 0.015$ ), 16.7% more with coronary artery disease ( $p = 0.006$ ), and 8.5% more with obstructive sleep apnea ( $p = 0.015$ ) at the time of surgery when compared with the other 2 groups. Despite 37% of obese patients having a greater ASA class ( $p = 0.02$ ), and average blood loss of 128 ml greater than groups 1 and 2, group 3 performed similarly postoperatively in terms of operative time (136.9 min, 139.4 min, 145.6 min), clamp time (18.9 min, 17.6 min, 14.6 min), requirement of transfusion, hospital stay (2.92 days, 2.35 days, 2.92 days), complications and postoperative renal function.

**Conclusion:** LPN demonstrates equivalent perioperative outcomes in non-obese and obese patients despite significant comorbidities in the latter group. Laparoscopic approach levels the playing field in patients undergoing major abdominal surgery and provides superior outcomes when compared with open surgery.

#### VP7-11 LAPAROSCOPIC UPPER POLE HEMINEPHROURETERECTOMY IN CHILDREN: THE HEILBRONN EXPERIENCE

A. Gözen, T. Kalogeropoulos, L. Tunc, F. Yencilek, J. Rassweiler, D. Teber—Germany

**Background:** We report our technique and outcomes with laparoscopic transperitoneal and retroperitoneal upper pole heminephroureterectomy (HNU) in children with renal duplex systems and impaired upper pole.

**Methods:** Laparoscopic HNU was performed in 13 children (8 girls, 5 boys) with a mean age of 5.21 years between 2002 and 2008. Four underwent retroperitoneal and nine transperitoneal HNU. Urinary tract infection was the first presenting symptom in all children. Voidingcystoureterography (VCU) and scintigraphic studies showed vesicoureteral reflux (VUR) and dual collecting systems in 7 cases on the right side but 6 on the left. The upper pole collecting system of kidney was affected in all cases. A month after the operation, VCU and USG and 3 months after the operation renal scintigraphic studies were performed to check the urinary system.

**Results:** Overall, the mean operation time was 165.38 ± 27.2 minutes (166.6 for retroperitoneal and 160.3 for transperitoneal HNU). Blood loss was low as 10–40 cc and there were no intra-operative complications. Mean hospitalization and postoperative follow-up were 5.0 ± 1.25 day and 22 ± 9.83 months respectively. Postoperative recovery was uneventful. At 3rd month evaluation after the surgery, renal scintigraphic studies revealed no parenchymal loss of the remaining renal moiety. None of the patients were admitted to the hospital with operation related complications after a mean follow-up of 19 months.

**Conclusion:** Laparoscopic HNU in children can be performed via transperitoneal or retroperitoneal approach, both with low morbidity and the typical benefits of laparoscopic surgery.

### VP7-12 LAPAROSCOPIC APPROACH IN DIFFICULT SECONDARY NEPHRECTOMY CASES

M. Arslan, T. Degirmenci, M. Yuksel, B. Gunlusoy, S. Minareci, A. Ayder—Turkey

**Background:** To report our experiences on cases who had non-functioning kidney after renal surgery, and undergone secondary nephrectomy performed with laparoscopic transperitoneal nephrectomy (LTPN).

**Methods:** Between September 2007 and March 2009 we performed 14 (9 female, 5 male) secondary laparoscopic nephrectomy. The mean age value was 39.5 (17–72) years. Preoperative abdominal computerised tomography and renal sintigraphy were ordered. In LTPN procedure 4-ports (2 ports 5 mm, 1 port 10 mm, 1 port 12 mm) were used. Harmonic scalpel and ligasure were used for dissection and the control of small vessels. Endogia stapler or polymer ligation clips were used for renal pedicle control. All of the specimens were taken out in endobags through port holes after morsalation.

**Results:** Of the 14 secondary nephrectomy patients 7 had kidney stone, 3 upper ureter stone, 4 ureteropelvic junction stenosis surgeries, and renal function was less than 20% on renal sintigraphy in all included cases. Mean operation duration was 148 minutes, mean blood loss was 275 ml, mean hospitalization duration was 3.25 days in LTPN patients. In 4 patients complications occurred, in 2 case we had to return to open surgery due to adhesions and the loss of surgical plane. Mean wound healing time was 16.4 days, and mean time to return to normal activities wa 22.8 days. Mean follow-up time was 9.8 (1–20) months.

**Conclusion:** Open surgery remains to be a safe and effective procedure in secondary nonfunctioning kidneys. By the help of increasing experience, we choose to perform LTPN which has better cosmetic results and faster recovery period, for secondary nonfunctioning kidneys.

### VP7-13 LAPAROSCOPIC TRANSPERITONEAL AND RETROPERITONEAL NEPHRECTOMY: THE LARGEST ONE CENTER STUDY FROM TURKEY

M. Arslan, T. Degirmenci, M. Yuksel, B. Gunlusoy, S. Minareci, A. Ayder—Turkey

**Background:** In this study we report our results of renal carcinoma, nonfunctioning kidney and atrophic kidney treated with transperitoneal laparoscopic nephrectomy (LTPN) versus retroperitoneal laparoscopic nephrectomy (LRPN) approach.

**Methods:** Between December 2004 and April 2009 we performed 177 laparoscopic nephrectomy. Of these 177 patients, 108 were women and 69 were male, and the mean age value was 42 years (16–79 years). Laparoscopic nephrectomy was with transperitoneal approach in 84 patients (42 radical, 42 simple), and retroperitoneal in 93 patients (18 radical, 75 simple). In transperitoneal approach 4-ports (2 ports 5 mm, 1 port 10 mm, 1 port 12 mm) and in retroperitoneal approach 3-ports (2 ports 10 mm, 1 port 5 mm) were used. All of the specimens were taken out in endobags or from gibson incision by hand.

**Results:** The mean operation times of our radical LTPN, simple LTPN, radical LRPN and simple LRPN patients were 128, 100, 114, 92 minutes, respectively. The loss of blood during operation were 180, 150, 125 and 90 ml, respectively. The average hospital stay durations were 3.5, 2.5, 3, 2.5 days, respectively. In 12 patients due to complications we had to change the procedure and return to open surgery. The avarage wound healing times of LTPN and LRPN were 12.6 and 9.4 days, respectively. The convalescent times of LTPN and LRPN were 22.5 and 18.4 days, respectively. The average follow-up time of the patients was 25.8 months (1–52).

**Conclusion:** Laparoscopic kidney procedures are minimally invasive methods that are commonly used in kidney pathologies. If we consider the postoperative convelescence time of the patients, retroperitoneal laparoscopic nephrectomy seems to be more effective than transperitoneal laparoscopic nephrectomy.

## VP8: LESS-I

### VP8-01 LAPAROENDOSCOPIC SINGLE SITE (LESS) SURGERY: INITIAL 100 PATIENTS

M. Desai, A. Berger, M. Aron, R. Brandina, R. Sotelo, I. Gill

**Background:** Laparo-endoscopic single site (LESS) surgery is a novel minimally invasive approach that has recently been used to perform various urologic procedures. To our knowledge, we report our experience with the initial 100 LESS procedures in urology.

**Methods:** Between October 2007 and December 2008, we performed LESS urologic procedures in 100 patients for various in-

dications. These included nephrectomy (N = 34; simple 14, radical 3, donor 17), nephroureterectomy (N = 2), partial nephrectomy (N = 6), pyeloplasty (N = 17), transvesical simple prostatectomy (N = 32) and others (N = 11). All procedures were performed using a novel single port device (r-Port) and a varying combination of standard and specialized bent/articulating laparoscopic instruments.

**Results:** In the study period, LESS procedures accounted for 15% of all laparoscopic cases by the authors for similar indications. Conversion to standard multi-port laparoscopy was necessary in 3

cases, addition of a single 5 mm port was necessary in 4 cases, and conversion to open surgery was necessary in 4 cases. There was a mortality following simple prostatectomy in a Jehovah's Witness due to patient refusal to accept transfusion following hemorrhage. Intra- and post-operative complications occurred in 5 and 9 cases, respectively. Mean operative time was 145, 236, 220, and 113 minutes and hospital stay was 2, 2.9, 2, and 3 days for simple nephrectomy, donor nephrectomy, pyeloplasty and simple prostatectomy, respectively.

**Conclusion:** Laparoendoscopic single site (LESS) surgery is technically feasible for a variety of ablative and reconstructive applications in urology. With proper patient selection, conversion and complications rates are low. Improvement in instrumentation and technology is likely to expand the role of LESS in minimally invasive urology.

### VP8-02 OPERATIVE EXPERIENCE AND SHORT-TERM OUTCOMES OF LAPAROENDOSCOPIC SINGLE-SITE SURGERY (LESS) PYELOPLASTY: A MULTI-INSTITUTIONAL STUDY

M. Schwartz, C. Tracy, S. Rais-bahrami, M. Desai, J. Cadeddu, L. Richstone—USA

**Background:** We report a multi-institutional experience with LESS pyeloplasty to examine operative feasibility, peri-operative complications, and short-term outcomes.

**Methods:** Between October, 2007 and April, 2009, peri-operative data from initial experience with LESS pyeloplasty was prospectively collected at 3 institutions. The modified Clavien criteria were used to classify complications. Pre- and post-operative renograms and glomerular filtration rate (GFR) calculation were used to gauge success of the procedure.

**Results:** 41 patients underwent LESS pyeloplasty on 43 obstructed ureteropelvic junctions. Mean patient age was 36.7 years (range 10–79) and mean follow-up was 11 months (range 2–20 months). Mean operative time was  $210 \pm 51$  minutes. Mean incision length was 26.8 mm. In 7 right-sided cases, an additional 3 mm port for liver retraction was required. Mean hospital stay was 2.5 days. Pre- and post-operative renal function, as assessed by both renogram and calculated GFR, were not statistically different. Major complications included one post-operative obstruction, and two post-operative urine leaks requiring percutaneous nephrostomy placement. The major complication rate (grades 3–5) was 9.3%. Five patients had not yet undergone post-operative renogram, but all other patients have demonstrated no clinical or radiographic evidence of ureteral obstruction.

**Conclusion:** Given the short-term follow-up data available, LESS is a safe minimally invasive approach to pyeloplasty with success and complication rates similar to those published using robotic or traditional laparoscopic techniques. A minimal scar/incision burden may be particularly advantageous in what is typically a young patient cohort more concerned with cosmesis. Long-term follow-up data is required to further gauge the durability of these outcomes.

### VP8-03 LAPAROENDOSCOPIC SINGLE SITE (LESS) DONOR NEPHRECTOMY: FEASIBILITY AND TECHNIQUE

M. Atalla, S. Andonian, A. Herati, S. Rais-bahrami, L. Richstone, L. Kavoussi—USA

**Background:** As laparoscopy becomes a standard approach in many urologic procedures, research strives to make minimally invasive surgery less invasive. This is particularly pertinent when live organ donation for transplantation is concerned. A primal goal for such procedures is to offer the least morbidity and time away from work while offer the best functional and cosmetic result for live organ donors. The widespread acceptance for laparoscopic donor nephrectomy could be at least partially attributed to these benefits. In an attempt at further improving these benefits, we developed a technique for and investigated the feasibility of true LaparoEndoscopic Single Site (LESS) donor nephrectomy.

**Methods:** Four healthy patients were electively scheduled for kidney donation. Preoperative screening and preparation was completed as per our Transplant Center protocol. The operative technique utilized a modified ipsilateral flank position. Pneumoinflation was obtained using a Veress needle. A single 5 cm transverse Pfannenstiel incision was made. Two 5 mm Anchorports (Surgique; Orange, CT) and one 12 mm trocar were placed through separate fascial punctures within the single incision site. A flexible-tip laparoscope (LTF Series, Olympus Surgical; Orangeburg, NY) and flexible instruments (Reahand, Novare; Cupertino, CA) were used in addition to standard laparoscopic instruments. Laparoscopic donor nephrectomy technique was duplicated via a single operative site. The fascial puncture sites were joined and the kidney was extracted in a large Endocatch bag through the same incision for immediate transplantation.

**Results:** The patients' mean age was 42. Mean operative time was 171 minutes. Mean warm ischemia time was 4.75 minutes. Estimated blood loss was 100 ml in each case and no transfusion were needed. Mean serum Creatinine was 1.025 preoperatively and 1.575 postoperatively. Mean hospital stay was 2.5 days (mode of 2 days). There were no intraoperative or postoperative complications.

**Conclusion:** LESS donor nephrectomy is feasible by replicating laparoscopic donor nephrectomy techniques with the advent of flexible-tip laparoscopes and flexible instruments. Our technique describes the exclusive use of a single site for introduction of the instruments and extraction of the harvested kidney, without the needed for any other ports. A prospective randomized trial is needed to evaluate if the technique offers equivalent functional results and superior recovery and cosmesis when compared to laparoscopic donor nephrectomy.

### VP8-04 INITIAL EXPERIENCE OF LESS IN THE TREATMENT OF BENIGN ADRENAL ADENOMA

B. Jeong, D. Han, S. Jeon, Y. Park, H. Kim

**Background:** To describe our initial clinical experience and assess the feasibility of LESS in the treatment of benign adrenal adenoma.

**Methods:** Nine consecutive patients undergoing LESS adrenalectomy for benign adrenal adenoma were compared with 26 patients undergoing conventional laparoscopic adrenalectomy. Controls were matched for age, gender, surgical indications, and tumor size via a statistically generated selection of all conventional laparoscopic adrenalectomies performed during the same period of time.

**Results:** There were no significant differences in mean operative time (169 min versus 144.5,  $p = 0.287$ ), blood loss (177.8 ml versus 204.7 ml,  $p = 0.792$ ), and postoperative hospital stay (3.2 days versus 3.5 days,  $p = 0.525$ ) between the LESS and conventional

laparoscopic group. However, postoperative pain, as measured by number of days of IV patient control anesthesia use, was significantly lower in the LESS group (0.9 days versus 1.9 days,  $p = 0.047$ ). Perioperative complications were similar between two groups. Table 1. Baseline characteristics of patients according to the surgery LESS adrenalectomy Conventional p-value No. of patients 917-Sex (%) 0.281 Male 4 (44.4) 11 (64.7) Female 5 (55.6) 6 (35.3) Age (years) 46.0 (26–64) 43.8 (19–72) 0.458 ASA score (%) 0.258 13 (33.3) 4 (23.5) 23 (33.3) 11 (64.7) 33 (33.3) 2 (11.8) Pre-operative diagnosis (%) 0.992 Nonfunctioning adenoma 3 (33.3) 6 (35.3) Cushing's syndrome 1 (11.1) 2 (11.8) Pheochromocytoma 5 (55.6) 9 (52.9) Laterality (%) 1.000 Right 3 (33.3) 7 (41.2) Left 6 (66.7) 10 (58.8) Table 2. Surgical outcomes according to the surgery LESS adrenalectomy Conventional p-value Conversion (%) 1 (11.1) 1 (5.9) 1.000 Mass size (cm) 2.8 (1–5.4) 4.3 (2.5–10.0) 0.011 Operative time (minutes) 169.2 (89–289) 144.5 (70–300) 0.287 Estimated blood loss (ml) 177.8 (50–400) 204.7 (10–900) 0.792 Transfusion (%) 0 (0) 1 (5.9) 1.000 PCA duration (days) 0.9 (0–2) 1.9 (0–4) 0.047 Hospital stay (days) 3.2 (2–4) 3.5 (2–4) 0.525 Complication (%) 1 (11.1) 1 (5.9) 1.000

**Conclusion:** LESS adrenalectomy for benign adrenal adenoma is comparable to the conventional laparoscopic approach with regard to operative time, blood loss, length of hospital stay, and complication, demonstrating excellent cosmetic outcomes.

#### VP8-05 STANDARD VERSUS SINGLE PORT LAPAROSCOPIC PARTIAL NEPHRECTOMY: COMPARATIVE OUTCOMES

W. White, G. Haber, R. Goel, S. Crouzet, M. White, J. Kaouk

**Background:** To evaluate perioperative outcomes among patients who underwent single port or conventional laparoscopic partial nephrectomy.

**Methods:** A prospective, observational study was performed to evaluate perioperative outcomes among patients who underwent single port laparoscopic partial nephrectomy (SPLPN). Salient demographic and operative data were obtained. These patients were next retrospectively compared to a contemporary, matched-cohort of patients who underwent conventional LPN (CLPN). End-points including age, BMI, operative time, estimated blood loss (EBL), complications, conversion, and post-operative Visual Analog Pain Scale (VAPS) scores were examined. Statistical analysis was performed.

**Results:** Fifteen SPLPN and 15 CLPN patients were evaluated. There was no significant difference between the SPLPN and CLPN cohorts with respect to mean age (66 vs. 59 years,  $p = 0.149$ ), mean BMI (26.7 vs. 28.0,  $p = 0.422$ ), mean operative time (196 vs. 245 minutes,  $p = 0.08$ ), mean EBL (422 vs. 337 mL,  $p = 0.67$ ), and mean length of hospitalization (4.5 vs. 3.5 days,  $p = 0.494$ ). Mean VAPS score at discharge was significantly less in the SPLPN cohort (0.67/10 vs. 3/10,  $p = 0.009$ ). One patient in the SPLPN cohort required conversion to standard laparoscopy. Four patients in the SPLPN cohort required post-operative blood transfusions, one of which required angioembolization. Three patients in the CLPN cohort received blood transfusions.

**Conclusion:** Based on our experience, single port LPN demonstrates equivalent comparative outcomes to conventional LPN with significantly less pain and superior cosmesis in the single port cohort. Prospective, randomized studies are needed to confirm these findings.

#### VP8-06 A COMPARISON OF PERIOPERATIVE OUTCOMES BETWEEN TRANSUMBILICAL SINGLE-PORT ACCESS AND CONVENTIONAL LAPAROSCOPIC RENAL CYST MASUPIALIZATION

J. Choi, D. Han, B. Jeong, S. Seo, S. Jeon, H. Lee

**Background:** We evaluated the perioperative outcomes of transumbilical single-port access (SPA) laparoscopic renal cyst masupialization compared with conventional laparoscopic surgery.

**Methods:** We retrospectively reviewed medical records of 28 patients who underwent laparoscopic renal cyst masupialization (29 cases, 1 patient of bilateral renal cysts, 27 of unilateral cysts). Fourteen patients (group I) were performed by conventional laparoscopic procedure using one 12 mm-camera port and two 5 mm-working port and fourteen patients (15 cases, group II) were performed by transumbilical SPA procedure. During transumbilical SPA surgery, we made a 2 cm single incision at umbilicus and used a home-made port made from surgical glove, wound retractor (Alexis®; Applied Medical, USA) and conventional trocars. Articulating and straight working instruments were used for transumbilical SPA laparoscopic surgery. After operation, intravenous patient controlled analgesia (PCA) was routinely applied to all patients and additional intravenous pethidine was applied on demand. We investigated perioperative outcomes including operation time, serum hemoglobin change, pain severity (VAS; visual analogue scales), and hospital stay and compared the parameters between the both groups.

**Results:** Mean age was 52 years in group I and 50 years in group II. Mean cyst size was 8.9 cm years in group I and 8.3 cm in group II. There was no difference in operation time (145 min vs. 119 min,  $p = 0.17$ ) and percent change of serum hemoglobin (8.4% vs. 9.7%,  $p = 0.64$ ) between two groups. Two patients in group I required additional intravenous pethidine and no patient required additional pain killer in group II. However, there was no difference of applied dose of pethidine between two groups (7.1 mg vs. 0 mg,  $p = 0.54$ ). Postoperative pain VAS of the operative day was lower in group II than I (3.9 vs. 2.9,  $p = 0.04$ ). However, VAS of 1st and 2nd postoperative day was not different. There was no difference of mean length of hospital stay. There were no complications related to the operations such as bleeding that require transfusion, infection and intraabdominal organ injury.

**Conclusion:** Transumbilical SPA renal cyst masupialization was technically feasible with good perioperative outcomes comparable to conventional laparoscopic surgery. Transumbilical SPA renal cyst masupialization can be performed safely with cosmetic benefits and could be considered as a primary treatment option.

#### VP8-07 LAPARO-ENDOSCOPIC SINGLE SITE (LESS) MANAGEMENT OF BENIGN UROLOGIC DISEASES

S. Permpongkosol, C. Leenanupunth

**Background:** To present our experience with Laparo-Endoscopic Single Site (LESS) management of benign urologic diseases.

**Methods:** From September 2008 to May 2009, 13 patients underwent single port transumbilical (SPA) laparoscopic surgery: nephrectomy (6 cases), cyst decortications (6 cases) and redopyeloplasty (1 case), respectively. All SPA nephrectomy confirmed with chronic pyelonephritis and non functional kidney. SPA decortications cysts of all patients enrolled in the study were

classified as simple cysts (Bosniak class 1–2). All surgical procedure, management, and complications were analyzed.

**Results:** LESS was possible and safe approach in 84.6% of patients underwent SPA. All 6 LESS decortications of symptomatic renal cysts and redo-pyeloplasty were completed without major complications or conversion to open surgery. However, there was 1 case of each SPA cyst decortication and pyeloplasty requiring an additional 3-mm port for suturing due to bleeding and error instrument, respectively. Patients who experienced a complete pain relief had significantly larger cyst sizes compared with patients with a partial pain decrease. Two (33.3%) SPA nephrectomies with higher waist circumference were converted to standard laparoscopic nephrectomy due to failure to progress. Histology of Xanthogranulomatous pyelonephritis was confirmed in one case. In an additional procedure during the operation, two cases were required pus aspiration to decrease the kidney size.

**Conclusion:** Transumbilical Single-Port laparoscopic transperitoneal surgery presented an effective and safe treatment option in the management of benign urologic diseases.

#### VP8-08 SINGLE PORT LAPAROSCOPIC SURGERY: CUMULATIVE OUTCOMES WITH OVER 100 CASES

W. White, R. Goel, G. Haber, S. Cruzet, M. White, J. Kaouk

**Background:** To present perioperative outcomes in an observational cohort of patients who underwent Laparo Endoscopic Single Site (LESS) surgery at a single academic center.

**Methods:** A prospective study was performed to evaluate patient outcomes following LESS urologic surgery. Demographic data including age, BMI, operative time, estimated blood loss (EBL), operative indications, complications, and post-operative Visual Analog Pain Scale (VAPS) scores were accrued. Patients were followed post-operatively for evidence of adverse events.

**Results:** Between September 2007 and June 2009, 105 patients underwent LESS urologic surgery. Specifically, 78 patients underwent LESS renal surgery (cryoablation -9, partial nephrectomy -15, metastectomy -1, renal biopsy -1, simple nephrectomy -7, radical nephrectomy -8, cyst decortication -2, nephroureterectomy -7, donor nephrectomy -20, and dismembered pyeloplasty -8) and 27 patients underwent LESS pelvic surgery (varicocelectomy -3, radical prostatectomy -7, radical cystectomy -3, sacral colpopexy -13, and ureteral reimplant -1). Mean patient age was 55 years. Mean BMI was 26.1 kg/m<sup>2</sup>. Mean operative time was 198 minutes. Mean EBL was 132 mL. No intraoperative complications occurred. Six patients required conversion to standard laparoscopy. One patient required open conversion. Mean length of hospitalization was 3 days. Mean VAPS score at discharge was 1.5/10. At a mean follow-up of 11 months, 10 Clavien Grade II (transfusion - 8, UTI - 1, DVT -1) and 2 Clavien Grade IIIb (recto-urethral fistula -1, angiobolization -1) surgical complications occurred.

**Conclusion:** Based on our experience, LESS urologic surgery is feasible, offers improved cosmesis, and may offer decreased pain. Its superiority compared to standard laparoscopy is currently speculative.

#### VP8-09 RETROPERITONEAL LAPAROENDOSCOPIC SINGLE-SITE SURGERY IN UROLOGY: INITIAL EXPERIENCE

T. Oh, D. Ryu, J. Kwon, H. Jung

**Background:** We present initial experience with laparoendoscopic single site surgery (LESS) via the retroperitoneal approach using

the homemade single-port device and articulating laparoscopic instruments.

**Methods:** Since December 2008, 21 patients have undergone LESS for various urological diseases, including renal cyst decortication in 6 patients, adrenalectomy in 3 patients, nephroureterectomy in 5 patients, radical nephrectomy in 5 patients, and ureterolithotomy in 2 patients. For the retroperitoneal LESS, the Alexis wound retractor and surgical glove as the homemade single-port device were used.

**Results:** All cases were completed successfully without conversion to standard laparoscopic or open surgery. The mean operative time and mean estimated blood loss (EBL) for decortication of the renal cysts was 56 minutes (range, 45–70 minutes) and 179 ml (range, 22–398 ml), respectively; the mean operative time and mean EBL for extirpative surgery was 160 minutes (range, 115–21 minutes) and 395 ml (range, 35–1324 ml), respectively. There were no major intra-operative complications. The mean hospital stay was 6.5 days (range, 4–14 days). Mean Visual Analogue Score for pain was 2.0 at discharge.

**Conclusion:** Retroperitoneal LESS is technically feasible and offers a safe, cosmetic alternative to traditional retroperitoneoscopy.

#### VP8-10 TRANSUMBILICAL LAPAROENDOSCOPIC SINGLE-SITE (U-LESS) NEPHRECTOMY: INITIAL EXPERIENCE

G. Wu, J. Marshall, D. Golijanin, E. Singer, H. Rashid—USA

**Background:** Laparoscopic nephrectomy requires 3 to 5 small incisions for port placement. Specimen extraction requires elongation of one of those small incisions. Transumbilical laparoendoscopic single-site (U-LESS) surgery employs only a small paraumbilical incision for multiple instrument entry and specimen extraction with advantages to further “minimize” minimally-invasive surgery. In this report, we present our initial experience of U-LESS nephrectomy.

**Methods:** Patients were positioned in a modified lateral decubitus position. A 2.5 to 5 cm skin incision (based on the size of the specimen) was made along the skin crease of the umbilicus. Pneumoperitoneum was created by inserting a Veress needle. A 12-mm port and two 5-mm ports were placed through separate fascial insertion along the incision. Standard laparoscopic instruments as well as a 10-mm flexible tip HD EndoEye and 5-mm 30 degree EndoEye laparoscope (Olympus), articulating Marilyn dissector (Novare), and 5-mm LigaSure (Valleylab) were used for these procedures. Renal arteries and veins were controlled with large Hem-o-lok clips or Endo GIA vascular staplers.

**Results:** From November 2008 to June 2009, a total of 12 cases (3 male and 9 female) with age ranging from 8 to 81 yrs were performed, including nonfunctioning atrophic kidney (4 cases) and kidney mass (8 cases). All cases were performed uneventfully without needs for additional port sites. Operative time ranged from 60–192 minutes. Estimate blood loss was 5 ml to 100 cc, with an average of 45 ml. Hospital stay ranged from 1–4 days (median 2 days).

**Conclusion:** LESS nephrectomy can be safely performed for selected patients with currently available laparoscopic instruments though with increased technical challenges. This technique provides improved cosmesis than conventional multiple-port laparoscopic nephrectomy.

### VP8-11 SINGLE PORT LAPAROSCOPIC SURGERY IN THE OBESE POPULATION: FEASIBILITY AND COMPARATIVE OUTCOMES

M. White, W. White, G. Haber, R. Goel, S. Crouzet, J. Kaouk

**Background:** To evaluate outcomes among obese patients who underwent LaparoEndoscopic Single Site (LESS) surgery at a single academic center.

**Methods:** A retrospective cohort study was performed to evaluate comparative outcomes between obese and non-obese patients undergoing LESS urologic surgery. Obesity was defined as a Body Mass Index (BMI)<sup>3</sup> 30 kg/m<sup>2</sup>. Demographic and perioperative data including age, BMI, operative time, estimated blood loss (EBL), operative indications, complications, conversion to standard laparoscopy, and post-operative Visual Analog Pain Scale (VAPS) scores were examined. Statistical analysis was performed.

**Results:** Between September 2007 and June 2009, 19 obese and 86 non-obese patients underwent LESS urologic surgery. Mean BMI of the obese and non-obese cohorts was 34 kg/m<sup>2</sup> and 24.6 kg/m<sup>2</sup>, respectively ( $p < 0.01$ ). There was no significant difference between the obese and non-obese cohorts with respect to age (60 years vs. 53.4 years,  $p = 0.16$ ), operative time (209 minutes vs. 196 minutes,  $p = 0.42$ ), EBL (252 ml vs. 175 mL,  $p = 0.33$ ), length of hospitalization (3.3 days vs. 2.9 days,  $p = 0.52$ ), or VAPS score (1.9/10 vs. 1.4/10,  $p = 0.20$ ). Conversion to standard laparoscopy was required in 2 obese patients and 5 non-obese patients. There was no significant difference in perioperative adverse events between the 2 groups ( $p = 0.89$ ).

**Conclusion:** Based on our experience, LESS surgery in obese patients is technically challenging but is not associated with a disproportionate risk of operative conversion or perioperative adverse events. Therefore, BMI should not be an explicit contraindication to LESS urologic surgery.

### VP8-12 LAPAROENDOSCOPIC SINGLE-SITE SIMPLE NEPHRECTOMY: INITIAL EXPERIENCE IN BRAZIL

E. Metrebian, F. Lima, T. Pinheiro, F. Beltrame, V. Ortiz, C. Andreoni—Brazil

**Background:** Laparoendoscopic single-site surgery (LESS) is an emerging technique in minimally invasive surgery and after the instruments became available in Brazil, we performed the first 2 cases at our institution.

**Methods:** Two patients underwent simple nephrectomy performed through a single umbilical multichannel laparoscopic port and standard straight or articulating laparoscopic instruments were used selectively. Both a 5 mm and a 10 mm laparoscope were used throughout the procedure. The surgical technique was the same as used for the conventional laparoscopic approach; briefly, the hilar blood vessels were dissected and ligated with clips. The kidneys were removed intact through the umbilical incision.

**Results:** The patients had 31 and 33 years old and they both presented with symptomatic hydronephrosis with minimal residual renal function. Both cases were finished without any complications. Surgical time was 155 and 180 minutes and blood loss was less than 100 cc in both cases. We placed an additional port in both cases; in the first case, the 5 mm scope did not allow for reliable image and we placed a 10 mm port to insert the clip applicator as the 10 mm port in the umbilicus had to be used for the 10 mm scope; in the second case, a 5 mm trocar was placed for colon mobilization

purpose. Umbilical incision length was 3.5 and 4 cm. Postoperative recovery was uneventful. Hospital stay was 1 and 2 days.

**Conclusion:** LESS simple nephrectomy is safe and feasible with all special instruments available offering cosmetic advantage. Further experience and evaluation of other possible advantages are still needed.

### VP8-13 PROSPECTIVE EVALUATION OF SINGLE SITE LAPAROSCOPIC RADICAL AND PARTIAL NEPHRECTOMY

I. Derweesh, J. Silberstein, W. Bazzi, M. Talamini, C. Kane, S. Horgan

**Background:** By consolidating working trocar and extraction incision sites, Single Site Laparoscopy (SSL) may represent a further decrease in morbidity compared to traditional laparoscopy. Herein we present our pilot study of SSL for Laparoscopic Radical Nephrectomy (SSLRN) and Laparoscopic Partial Nephrectomy (SSLPN).

**Methods:** As part of an ongoing IRB-approved prospective study, 7 patients underwent SSLRN and 4 pts underwent SSLPN from 2/2009 to 6/2009. For SSLRN and SSLPN, transperitoneal access was obtained through a peri-umbilical incision through which all working trocars were inserted. SSLRN and SSLPN recapitulated all the standard steps of the multi-site laparoscopic RN and PN. For SSLRN this included; renal dissection, sequential ureteral, renal arterial and venous staple ligation, and intact specimen extraction. For SSLPN this included: renal dissection, and hilar control; prior to specimen excision and renorrhaphy. In 3 SSLPN temporary hilar occlusion was utilized for specimen excision and renorrhaphy, in 1 case excision and hemostasis were achieved utilizing the Habib 4× laparoscopic radiofrequency resection device (Angiodynamics, Queensbury, NY). Demographic factors, tumor characteristics, peri-operative variables, outcomes and complications were prospectively recorded and analyzed.

**Results:** Eleven patients (4 Men/7 Women, mean age 59.6 years, Mean BMI, 28.24) underwent transperitoneal SSLRN and SSLPN. Ten of the 11 cases were successfully performed without conversion to multi-site laparoscopic or open surgery, one (9%) SSLPN was converted to open PN for non-progression. For SSLPN mean tumor size was 1.7 (range) (1.4–2) cm, mean incision size was 4.1 (3.8–4.3) cm, operative time was 177 (150–208) min, mean EBL was 113 (50–200) cc, mean hematocrit declined 10%, mean warm ischemia time was 26 min, mean overall change in creatinine was 0.13 mg/dl, and mean decline in Modification of Diet in Renal Disease (MDRD) was 13.5 mL/min/1.73 m<sup>2</sup>. For SSLRN mean tumor size was 5.1 cm with 2 tumors having renal vein thrombi (pT3b tumors), mean incision size was 4.7 (4–5.3) cm, operative time was 147 (112–190) min, mean EBL was 140 (50–250) cc. Ketorolac and tramadol were utilized for analgesia, with 6/11 (54.5%) not requiring any opioid supplementation. No patients in either group required blood transfusions, all patients had negative resection margins, and all are currently alive. In all cases completed by SSL, all patients were advanced to regular diet in under 24 hours, and were discharged from the hospital in under 72 hours (mean length of stay 51.8 hours). One patient (9%) had a complication, a pneumothorax which was treated with tube thoracostomy decompression with resolution and tube removal within 23 hours.

**Conclusion:** SSL is a safe and technically feasible method for performing complex renal surgery, with excellent and reproducible preliminary oncologic outcomes in this pilot series. Assessment of more patients and evaluation of longer term outcomes with comparison to standard multi-site laparoscopic surgery is requisite.



## VP9: URETEROSCOPY 2

### VP9-01 URETEROSCOPIC MANAGEMENT OF THE STONE IN CALYCEAL DIVERTICULUM

E. Bercowsky u, A. Garcia Segui, I. Gomez Fernandez, M. Gascon mir—Spain

**Background:** Calyceal Diverticulum (CD) is a congenital non-secretory cavity in the renal parenchyma lined with transitional cell epithelium. Stones are found concomitantly within the diverticulum in 9.5–39% of the cases. Percutaneous approach is the most established technique for this disorder. Retrograde management with the use of minimally invasive flexible devices has been used to treat this disorder in some selected cases. We present a case of CD harboring a stone (CDS) treated with flexible ureteroscope in combination with Holmium YAG laser.

**Methods:** A 32-year-old woman presented elsewhere with left flank pain treated with SWL 7 times without resolution of the symptoms. Ultrasound showed a 2 cm left renal stone. An IVP and CT scan revealed a middle calyceal diverticulum harboring the stone. A retrograde approach via flexible 7.5 ureteroscope was done, identifying a pinpoint diverticulum neck. The Holimun YAG laser was used to incise the stenotic infundibulum and to treat the stone. The residual stone fragments inside de CD were removed by tipless stone basket, and a pig-tail catheter was inserted with the proximal tip inside the diverticulum.

**Results:** The OR time was 90 minutes, the hospitalization stay was 2 days, two weeks post-operative plain abdominal x-ray showed less than 4 mm fragment stones, and the patient was without pain during two months follow-up.

**Conclusion:** Ureteroscopic management CDS with the use of flexible devices in combination with Holmium YAG laser is a feasible and effective therapy in selected cases and avoids the potential complications and discomfort of percutaneous approach.

### VP9-02 THE PRESENCE OF ISCHEMIA IN BENIGN URETERAL STRICTURES MAY AFFECT SUCCESS OF HOLMIUM LASER ENDOURETEROTOMY

E. Gnessin, O. Yossepowitch, R. Holland, P. Livne, D. Lifshitz—Israel

**Background:** Laser endoureterotomy has increasingly become the preferred option for treating short benign ureteral strictures but few studies addressed its outcome. We assessed the results of laser endoureterotomy and factors associated with successful outcome.

**Methods:** 35 patients with a benign ureteral stricture were treated from October 2001 to June 2007 by retrograde holmium laser endoureterotomy. The clinical outcomes and factors associated with success were investigated. Success was defined as symptomatic improvement and radiographic resolution of the obstruction. Ischemic stricture was defined as one following open surgery, radiation or previous stone impaction.

**Results:** Median follow-up was 27 months (range 10–72). All patients but one were followed for at least 16 months. All patients completed clinical follow up, and 33 completed the imaging studies. Twenty-nine of 35 patients (82%) were symptom-free during the follow-up period and 26 of 33 (78.7%) were free from radiographic evidence of obstruction. All failures but one occurred within less than 9 months postoperatively. Success rate was higher

for non-ischemic strictures (100% vs. 64.7%,  $p=0.027$ ) and tended to be higher for shorter strictures ( $\leq 1$  cm) (89.4% vs. 64.2%,  $p=0.109$ ).

**Conclusion:** Holmium laser endoureterotomy is an effective treatment for benign ureteral strictures in well-selected patients. Most failures will occur within less than 9 months after surgery, which may advocate for closer follow-up during the first post-operative year. Factors that might affect outcome are the presence of ischemia and stricture length.

### VP9-03 IS A SAFETY WIRE NECESSARY DURING ROUTINE FLEXIBLE URETEROSCOPY?

R. Dickstein, B. Harnisch, R. Babayan, D. Wang—USA

**Background:** The use of flexible ureteroscopy for nephrolithiasis has been rapidly expanding. Initially, safety wires were maintained alongside the ureteroscope during renal stone manipulation to prevent loss of access and ureteral avulsion. Recently, the safety and feasibility of ureteroscopy without a safety wire has been described. We intend to examine a large series of patients who underwent flexible ureteroscopy without a safety wire.

**Methods:** A retrospective chart review was performed on all flexible ureteroscopies performed at our institution by a single surgeon from August 2003 to May 2008. Pre-operative patient characteristics, radiographic stone sizes, operative findings, and post-operative outcomes were recorded. Patients with renal [ureteropelvic junction (UPJ), renal pelvis, calyceal] stones were isolated and a qualitative data analysis was performed.

**Results:** Two hundred forty-six consecutive patients underwent flexible ureteroscopy for nephrolithiasis, of which 59 were bilateral. Of 305 ureteroscopies analyzed, 270 were considered routine and performed without a safety wire. No intra-operative complications resulted from the lack of a safety wire during routine flexible ureteroscopy including no cases of lost access, ureteral perforation/avulsion, or need for a percutaneous nephrostomy tube. Thirty-five cases were considered complicated, necessitating a safety wire. Sixteen had concomitant impacted ureteral stones, five had associated encrusted ureteral stents, and fourteen had difficult access due to a large stone burden (steinstrasse, staghorn) or aberrant anatomy (pelvic kidney, urethral/ureteral stricture, neurogenic bladder, contractures).

**Conclusion:** This study demonstrates that, in a large series, a safety wire was not necessary for routine cases of flexible ureteroscopy with UPJ or renal stones. Particular cases with complicated anatomy, bulky stone burden, or impacted UPJ stones may still necessitate use of a safety wire.

### VP9-04 FLEXIBLE URETEROSCOPY WITH HOLMIUM: YAG LASER LITHOTRIPSY FOR TREATMENT OF RENAL STONES

Z. Wu, Q. Ding, H. Jiang, P. Gao, Y. Zhang—China

**Background:** To evaluate the efficacy and safety of flexible ureteroscopy with holmium: YAG laser lithotripsy for treatment of renal stones.

**Methods:** A total of 69 patients with renal stones ( $\leq 2.0$  cm) underwent flexible ureteroscopy with holmium: YAG laser litho-

tripsy from November 2007 to February 2009. Of the patients, 20 with original renal stones (had history of a prior treatment failure by SWL), 49 with renal stones from retrograde migration of the proximal ureteral stones during the holmium: YAG laser lithotripsy with a semirigid ureterorenoscopy.

**Results:** The success rate of the flexible ureteroscopic insertion in a single session was 89.9% (62/69). Flexible ureteroscopy access failure was happened in 7 patients. The calculi were detected in the kidney in 93.5% (58/62) of the patients. The overall successful fragmentation rate for all renal stones in a single session achieved 94.8% (55/58). No intraoperative perforations or bleeding were encountered during the procedures. 2 weeks–6 months (with a mean of 3.3 months) follow up revealed that the overall stone-free rate for all renal stones achieved 85.5% (47/55).

**Conclusion:** Flexible ureteroscopy with holmium: YAG laser lithotripsy is a highly effective, minimally invasive and safe therapy for some renal stones. It should be indicated as a treatment choice for patients with renal stones ( $\leq 2.0$  cm, with treatment failure by SWL or semirigid ureterorenoscopic lithotripsy).

#### VP9-05 URETERORENOSCOPIC INCISION WITH HOLMIUM:YAG LASER FOR TREATMENT OF URETERAL/URETEROPELVIC JUNCTION OBSTRUCTION

Z. Wu, Q. Ding, H. Jiang, P. Gao, Y. Zhang—China

**Background:** To investigate the efficacy and safety of retrograde ureterorenoscopic incision with holmium: YAG laser for treatment of ureteral/ureteropelvic junction obstruction.

**Methods:** 69 patients (58 with ureteral obstruction, and 11 with ureteropelvic junction obstruction) were treated with retrograde ureterorenoscopic incision using holmium:YAG laser from May 2003–May 2009. All procedures were performed using a 8 F/9.8 F semirigid ureterorenoscope with a 365  $\mu$ m holmium: YAG laser fiber. A ureteral stent was left in place for 1–3 months after the procedure. Follow-up was obtained with ultrasound, intravenous urography or scintigraphy. Success was defined as the patient being stent free, asymptomatic, and without evidence of passage disturbance on radiographic study.

**Results:** Successful laser incision in a single session was performed in 65 patients [54 with ureteral obstruction (UO), 11 with ureteropelvic junction obstruction (UPJO)]. No bleeding or other serious complications were encountered during the procedures. 4 patients with severe UO  $> 2.5$  cm were changed to open surgery. With a median follow-up of 6.1 months (range 1–12 months) in 65 patients, the success rate was 73.8% (48/65). Postoperative recurrences were developed in 17 patients (15 with UO, 2 with UPJO). 13 of whom (11 with UO, 2 with UPJO) needed a repeat laser incision, 2 of whom with UO  $> 2.5$  cm was changed to open surgery, and the other 2 were performed 3rd laser incision. Urinary tract infections were observed in 8 patients postoperatively and were managed with anti-infectious therapy.

**Conclusion:** Retrograde ureterorenoscopic incision with holmium: YAG laser is an effective, safe and minimally invasive therapy for patients with ureteral/ureteropelvic junction obstruction ( $\leq 2.5$  cm).

#### VP9-06 COMPARISONS OF MINIMAL INVASIVE SURGERIES FOR URETERAL OBSTRUCTIONS: ENDOURETEROPYELOTOMY, ACUCISE ENDOURETEROPYELOTOMY, AND LAPAROSCOPIC URETEROPYELOPLASTY

H. Dong Youp, K. Ill Sang, S. Ill Young, S. Ill Young, J. Hee Jong

**Background:** The aims of this study was to compared the efficacies and outcomes of endoureteropyelotomy, Acucise endoureteropyelotomy, and laparoscopic ureteropyeloplasty for patients with ureteral obstructions.

**Methods:** Seventy-three patients with ureteral obstructions, who underwent minimal invasive surgeries between January 2001 and December 2006, were included in this study. Patients were divided into three groups according to the operative procedures; group I of endoureteropyelotomy (n = 35), group II of Acucise endoureteropyelotomy (n = 16), and group III of laparoscopic ureteropyeloplasty (n = 22).

**Results:** The mean ages of three groups were  $45.2 \pm 16.5$  years,  $48.9 \pm 12.4$ ,  $47.1 \pm 15.0$  respectively. The mean lengths of strictures were  $0.86 \pm 0.34$  cm,  $0.89 \pm 0.17$ , and  $0.96 \pm 0.41$  which showed no significant difference ( $p > 0.05$ ). In the mean operating time, group II ( $55.0 \pm 23.3$  minutes) shows shorter time than group I ( $111.7 \pm 37.5$ ) and group III ( $158.2 \pm 29.9$ ) ( $p < 0.05$ ). Hospital stay of group II ( $4.5 \pm 1.5$  days) was shorter than group I ( $6.1 \pm 1.7$ ) and group III ( $7.3 \pm 0.8$ ) ( $p < 0.05$ ). Success rates of symptomatic improvements in group I, II, and III were 63%, 69% and 91%, respectively and radiologic improvements were 66%, 69%, and 91%, respectively. Stricture length and hydronephrosis degree showed no significant correlation with the success rate.

**Conclusion:** Laparoscopic ureteropyeloplasty has the highest success rate in minimal invasive surgeries for patients with ureteral obstructions. However, when the length of stricture is less than 1 cm Acucise endoureteropyelotomy could be considered as the first treatment through short operating time and hospital stay.

#### VP9-07 EXTRARENAL MANIPULATIONS FOR RETROGRADE INTRARENAL SURGERY(RIRS) USING SEMIRIGID URS AND PNEUMATIC LITHOTRIPSY: A NOVEL CONCEPT

T. Haresh

**Background:** RIRS is the mainstay for small burden renal stone management when ESWL doesn't work. But the drawbacks associated with RIRS are availability, high initial and maintenance cost especially in developing world. Here we present our experience of RIRS using semirigid URS with some extrarenal manipulations making it more effective safe and feasible with low cost.

**Methods:** We have performed 32 cases of RIRS with semirigid URS with help of some manipulations from Nov 2008 to June 2009. Extrarenal manipulations like lifting kidney up, doem, rotating it medially or laterally, movement of upper or lower pole, tilting table ipsilateral or contralateral side, making table head side up or down, tilting patient side by side, making respiration rate and depth controlled as per need, making irrigation slow or fast, use of suction, forced diuresis with diuretics etc. We studied various parameters.

**Results:** Out of 33 patients, 16 has pelvic stone with upper calyceal stones in 13, middle calyceal stones in 18 cases, lower calyceal stones in 8 cases with favourable anatomy. With manipulations described we could clear stones in 29 patients (87%). There was no major intraoperative complications except minor extravasation in one case. Operative time was  $46 + 9$  minutes. Four patients had post operative fever

**Conclusion:** Extrarenal manipulations for intrarenal surgery using semirigid URS and pneumatic lithotripsy is safe, effective strategy without compromising outcome with low cost.

### VP9-08 INCIDENTAL STONES IN LIVING KIDNEY DONORS: BENCH URETEROSCOPY MAXIMISING THE DONOR POOL

J. Olsburgh, K. Thomas, J. Smith, L. Burnapp, G. Koffman—UK

**Background:** An increasing renal failure population requires maximising the living-donor pool. In our growing living-donor programme we diagnose incidental stones in 5% donors and consider them extended criteria donors. We consider the role of (ex vivo) bench ureteroscopy immediately after living donor nephrectomy to permit use of these kidneys.

**Methods:** Analysis of potential donors with asymptomatic stones on non-contrast phase of CT angiogram. To continue donor evaluation, stones had to be unilateral,  $\leq 5$  mm and neither infection or cystine stones.

**Results:** 29 potential kidney donors had asymptomatic stones (size 1–8.5 mm) of whom 3 with bilateral, 1 with stones  $>5$  mm and 1 with possible medullary sponge kidney were excluded from donation. In 9 cases the donor was unsuitable for other reasons or another donor was available. 9 people are currently progressing through donor assessment. 6 people with small asymptomatic stones have donated a kidney. None underwent pre-donation stone treatment. 5 had right-sided calculi of whom 4 had right nephrectomy (1, 2, 3 and 4 mm respectively) and one (1 mm stone) had left nephrectomy. 1 patient with left-sided calculus had left nephrectomy. Bench (ex-vivo) ureteroscopy was attempted in 3 explanted living donor kidneys—1 unsuccessful, 1 negative ureteroscopy (no stone seen) and 1 successful Holmium laser fragmentation of kidney stone. Donor and recipient follow up (3 months–3 years)—no stone related complications or detrimental effect to graft outcome.

**Conclusion:** Incidental stones were common. Donors and recipients should be fully counselled of potential risks and attempts at bench ureteroscopy considered. Donation with a small ( $<4$  mm) stone in situ may be appropriate but needs a larger patient cohort and longer follow up for firm conclusions.

### VP9-09 MINIMALLY INVASIVE MANAGEMENT OF URETERAL INJURIES SECONDARY TO OBSTETRIC AND GYNAECOLOGIC SURGERY

M. Gargouri, M. Teyeb, S. Sallami, F. Turki, Y. Nouira, A. Horchani—Tunisia

**Background:** To evaluate the minimally invasive management of iatrogenic ureteral injuries recognized late after obstetrical and gynaecological surgery.

**Methods:** From 1993 to 2008, 36 women presented with ureteral obstruction or ligation secondary to obstetrical or gynaecological surgery. Patients that had per-operative reconstruction were not included in this study. Diagnosis was made during the first month after surgery in two third of cases and there after for the rest. Symptoms were mainly acute flank pain (73%) and urinary leakage (35%). A primary minimally invasive treatment was tried for 28 patients.

**Results:** A percutaneous nephrostomy drainage was realized as primary treatment for eleven patients. Two patients, among them (18%), had spontaneous recovery as showed in antegrade pyelography and/or excretory urography realized three months later. A retrograde ureteral stent placement using a rigid ureteroscope was tried for 19 patients. This procedure was successful in eight cases (42%). Stents were left for six months in all cases. Patients treated

successfully by minimally invasive procedures had good outcome with a mean follow-up of 26 months. Patients treated by open surgery repair (first treatment for 8 patients and after failure of minimally invasive treatment for 18 other patients) obtained uneventful healing.

**Conclusion:** Minimally invasive procedures of iatrogenic ureteral injuries can be tried as primary treatment, however success rate is low (42%). Open surgery repair remains the treatment of choice for these gynaecologic complications.

### VP9-10 URETEROSCOPIC MANAGEMENT OF LARGE INTRARENAL CALCULI—A COMPARISON OF TECHNIQUES

D. Bagley, N. Leone, S. Hubosky, A. Mariani—USA

**Background:** To compare ureteroscopic lithotripsy techniques for the treatment of large intrarenal calculi, including holmium laser and electrohydraulic lithotripsy.

**Methods:** 79 consecutive patients underwent ureteroscopic lithotripsy by one of three at surgeons at two separate institutions. Demographic data, intraoperative techniques, success rates and complications were compared. Successful clearance of stones was defined as an absence of residual fragments measuring larger than 2 mm on post-operative imaging or last ureteroscopy.

**Results:** Mean stone size for all patients was 29.6 mm. Mean operative time was 111.1 minutes. Successful stone clearance was achieved in 76 patients (96.2%), and required an average of 1.4 ureteroscopic lithotripsy treatment episodes per patient. Primary electrohydraulic lithotripsy resulted in shorter operative times ( $p=0.0000$ ) and required fewer treatment episodes ( $p=0.0024$ ) compared to primary laser lithotripsy. The final success rate was similar for each group ( $p=0.332$ ). There was no difference in the number of unplanned ancillary procedures performed for post-operative complications ( $p=0.4103$ ).

**Conclusion:** Retrograde ureteroscopic lithotripsy offers excellent success and retreatment rates for the treatment of large intrarenal calculi  $>2$  cm, similar to gold-standard percutaneous nephrostolithotomy. Significantly shorter operative times and higher initial success rates were obtained when electrohydraulic lithotripsy was the primary treatment modality, but overall success was not significantly different when compared to holmium laser lithotripsy. The routine use of ureteral access sheaths and stone baskets with longer stenting may contribute to a lower rate of post-operative complications requiring ancillary procedures. Complimentary use of both techniques can help to achieve optimal results.

### VP9-11 ENDOSCOPIC TREATMENT OF MULTIPLE URETERAL FIBROEPITHELIAL POLYPS BY HOLMIUM YAG LASER RESECTION

H. Zakoji, T. Mochiduki, S. Kira, T. Nomura, I. Araki, M. Takeda—Japan

**Background:** Fibroepithelial polyps of the ureter, usually of congenital or inflammatory origin, are rare benign tumors that have traditionally been treated by open exploration and resection. Endoscopic resection have been regarded as a gold standard for small polyps, while management modality for many or large polyps are still controversial. We report our experience on the endoscopic treatment of multiple ureteral polyps.

**Methods:** A 23-year-old woman who presented intermittent left flank pain underwent ureteroscopic treatment of ureteral multiple fibroepithelial polyps. Under general anesthesia, a 12/14 F ureteral access sheath was inserted to the left renal pelvis to accommodate

the passage of the 7.5F flexible ureteroscope. Ureteroscopic evaluation of left ureter showed the presence of over 10 separate polyps, and the stalk of each polyp was ablated with the holmium laser fiber at 10 W operating from the upper ureter to the middle. A 7F double-J ureteral stent was placed at the end of this procedure.

**Results:** The operative time was 74 minutes, and there were no complications resulted from this operation. No ureteral strictures have developed since the ureteral stent was removed. The patient has not complained of left flank pain after the treatment.

**Conclusion:** Fibroepithelial polyps of the ureter can be managed less invasively with endoscopic surgery, and judicious use of the apparatus. The key to ureteroscopic treatment is to find the base of the polyp, the proper use of flexible ureteroscope, access sheath, and holmium YAG laser. We have demonstrated a specific minimally invasive technique.

### VP9-12 LONG TERM EFFICACY OF HOLMIUM: YAG LASER ENDOURETEROTOMY FOR LONG URETERAL STRICTURES

N. Andriopoulos, N. Pardalidis, E. Kosmaoglou—Greece

**Background:** Endourology techniques such as laser endoureterotomy have been increasingly used in recent years especially for the treatment of long ureteral strictures (>2 cm). Holmium: YAG laser possesses cutting and coagulating properties contributing to less morbidity. We report our experience with the laser endoureterotomy and evaluate the long term clinical and radiographic success of the method.

**Methods:** 19 patients (14 men and 5 women) underwent holmium laser endoureterotomy for iatrogenic ureteral strictures (9 proximal, 4 mid and 6 distal). The stricture approach was made in a retrograde fashion using either semi-rigid or flexible ureteroscope and the energy source was a laser micro fiber set at 1 Joule and 10Hz. Successful cut was considered when intraoperative extravasation presented. Indwelling stents or endopyelotomy stents were left in place for 4–6 weeks postoperatively and follow up was obtained with radiographic imaging in 1, 3, 6, 12 months and thereafter every year following the procedure.

**Results:** Success was defined as both relief of symptoms and radiographic resolution of the obstruction on intravenous pyelography or diuretic renography or both. Median follow up was 3 years. 4 of the patients who developed recurrent strictures in less than six months were considered failure and were treated in an open technique. Overall, 15 out of 19 patients (78, 9%) are clinically well with no evidence of stricture recurrence on the radiographic imaging for long ureteral strictures.

**Conclusion:** Holmium laser endoureterotomy is associated with a long-term success rate, better than other available minimally invasive treatment options for long ureteral strictures. It is therefore an ideal tool for performing safe and effective endoureterotomy.

### VP9-13 URETEROSCOPY IN PROXIMAL URETERAL CALCULI: EXPERIENCE ON 1238 CASES

R. Multescu, D. Georgescu, B. Geavlete, P. Geavlete—Romania

**Background:** In the past 25 years, the treatment of proximal ureteral lithiasis evolved from ureterolithotomy to extracorporeal shockwave lithotripsy and/or ureteroscopy. Our objective was to analyse, in a significant series, the results of retrograde ureteroscopy in proximal ureteral lithiasis.

**Methods:** Between June 1994 and February 2009, in our clinical department 5102 patients underwent retrograde ureteroscopy (5534 ureteroscopic procedures). Upper urinary tract lithiasis was the main indication, which was used in 4562 cases. The proximal ureteral calculi were treated on 1238 cases, 442 and 796 being larger and respectively smaller than 1 cm.

**Results:** The stone-free rate after one procedure was 86.5%. According to stone size, the success rates were 81.9% for calculi over 1 cm and 88.9% for stones smaller than 1 cm. Treatment failures were related to ascending migration of stone fragments (7.2%), impossible approach of the calculus (5.2%) and aborting the procedure due to complications (1.1%). The intraoperative incidents occurred in 1.3% of the cases: fixed stone extractors (0.6%), equipment damages (0.4%) or JJ stent malpositioning (0.3%). The incidence of intraoperative complications was 3.4%: mucosal abrasion (1.4%), false passage (1%), ureteric perforation (0.5%), extra-ureteral stone migration (0.1%), bleeding (0.1%), ureteric avulsions (0.2%). Early complications were described in 10.2%. We also found late complications such as ureteral stenosis (2 cases) and persistent vesico-ureteral reflux (1 case).

**Conclusion:** According to our experience, ureteroscopy represents a valuable option in proximal ureteral lithiasis treatment with high stone-free rates and minimum morbidity.

### VP9-14 NEW LESS INVASIVE TECHNOLOGIES IN RENAL CALCULI MANAGEMENT. SCIENTIFIC RESEARCH INSTITUTE OF UROLOGY, MOSCOW

R. Fatikhov, D. Merinov, E. Borisenko

**Background:** Transurethral pyelocalcolithotripsy spreads more and more widely in clinical practice due to appearance of new technical possibilities including use of new rigid and flexible ureteroscopes and new contact lithotripsy options.

**Methods:** 20 patients with single stones less than 2 cm sized located in miniature renal calices-pelvis system, embarrassing percutaneous lithotripsy, took part in our research. Patients underwent standard clinical investigation for nephrolithiasis. 6 (30%) of them had clinically significant bacteriuria, treated conservatively. 8 (40%) had a stent placed because of acute pyelonephritis. 3 (15%) had unsuccessful shock-wave lithotripsy. Transurethral ureteropyeloscopy was performed by rigid instrument No 8 and No 10 Ch. Calculi fragmentation was made with a help of pneumatic and laser lithotriptors. In all cases operation was finished by ureteral stent insertion.

**Results:** In 18 (90%) cases renal stones were completely destroyed and removed. 2 patients underwent shock-wave lithotripsy because of clinically significant residual stones with positive results. 3 (15%) cases complicated by pyelonephritis attack.

**Conclusion:** Our experience evidences high efficiency of transurethral pyelocalcolithotripsy in nephrolithiasis management in patients with miniature renal calices-pelvis system and renal stones sized 2 cm and less.

### VP9-15 PRIMARY AND SECONDARY RETROGRADE INTRA-RENAL SURGERY (RIRS) FOR RENAL STONES IN PATIENTS WITH LARGE STONE BURDEN

W. Au, S. Chu, P. Tam—China

**Background:** We report our results of primary and secondary RIRS using flexible ureterorenoscope and Holmium laser in patients with large renal stone burden.

**Methods:** Patients with large renal stone burden (two or more stones/stones with maximum diameter >15 mm) who were treated with RIRS from September 2006 to March 2009 in our centre were included. Patient demographic data, indications, stone characteristics, operative data, treatment outcome and complications were entered into a prospective database. Successful treatment was defined as absence of target stone/presence of insignificant (size <2 mm) residual stone fragment(s) on KUB radiograph/imaging on follow-up visit.

**Results:** Thirteen patients (10 male and 3 female) with mean age 60 years (35–83 years) underwent 16 RIRS (13 primary and 3 secondary) during the study period. Mean stone size was 16 mm (4–30 mm) and mean number of stones was 4 (1 to >10). Indications included anatomical problem (3 patients), failed ESWL (2), radiolucent stones (5) and multiple stones (3). All RIRS were performed by the first-author under general anaesthesia with mean operative-time 159 min. (100–325 min.); a double-J ureteric catheter was inserted for all but one patient. Median hospital-stay was two days (1–7 days; Day-surgery in 6). Successful outcome was achieved in 12 patients (92.3%) with stone-cleared in 11 patients. Peri-operative and post-operative complications occurred in 6 RIRS (37.5%); all subsided with conservative management.

**Conclusion:** Primary and secondary RIRS for renal stones, as Day-surgery in selected patients, is an effective treatment option for patients with large stone burden.

#### VP9-16 DISTAL ENDOSCOPIC URETEROLITHOTOMY DURING PREGNANCY: EXPERIENCE IN 21 CASES

O. Castillo, I. Vidal-mora, G. Rubio, A. Foneron, R. Campos, M. Feria-flores

**Background:** The management of urolithiasis in pregnancy is complex, because there are two patients involved. For this reason, in most cases a conservative treatment is chosen trying to avoid the inherent risks of the surgical procedure. When this treatment fails, endoscopic ureterolithotomy is an option. This series illustrates our experience with endoscopic removal of a distal ureteral lithiasis in pregnant patients.

**Methods:** A retrospective analysis was performed of 21 pregnant patients treated our center with ureteral obstruction necessitating surgical intervention. The mean patient age was 24 years, and the mean gestation period was 22 weeks (range 14–32). Abdominal ultrasonography was the main diagnostic test used. All of them had distal ureteral lithiasis. The stones were fragmented using a pneumatic lithoclast through a 6.9 F/8 F semirigid ureteroscope, and extracted with dormia, with the patient under general anesthesia. Ureteral catheter was left connected to a Foley per one day. In no case was made dilatation of the intramural ureter or fluoroscopy.

**Results:** The procedure was successful in all cases. There were no obstetric or urologic complications.

**Conclusion:** Ureteroscopy during pregnancy is a feasible procedure to perform, safe for both mother and fetus, without radioscopic guide and without complication.

#### VP9-17 NO MATTER OF SIZE: URETEROSCOPIC STONE TREATMENT IN OBESE PATIENTS

K. Oberhagemann, C. Netsch, T. Bach, A. Gross—Germany

**Background:** Obesity is a growing problem in most countries, on the other hand, obesity is a risk factor for stone development. Morbid obesity might be a problem for ESWL or percutaneous lithotomie because of poor accessibility to the stone by body fat.

With this subgroup analysis we wanted to show, that there is no limit in patients obesity for ureteroscopic stone treatment.

**Methods:** All patients who underwent ureteroscopic stone treatment in our department between 2008 and 2009 were matched by their body-mass-index (bmi[kg/cm<sup>2</sup>]) into 3 subgroups, according to WHO-classification: 1. under- or normal weighted (bmi < 24.99; n = 164). 2. overweighted (bmi > 25 < 30; n = 203) 3. obese (bmi > 30; n = 107).

**Results:** Male gender was prominent in all groups (82%, 73%, 64%) with comparable mean age (48.9, 52.9, 50.3 years). There were no significant differences in mean stone size (7.6, 8.8, 7.9 mm; p 0.72) or number (2.0, 1.6, 1.5; p 0.19). Stone localizations were comparable in the 3 groups. There were slight but not significant differences (p 0.911) in the stone free rates (1: 91.5%, 2: 88.6%, 3: 87.9) between the 3 groups. Complications appeared in nearly equal frequency (1: 12.2%, 2: 10.8%, 3: 11.2%), p 0.79).

**Conclusion:** No significant influence on stone free rates by high bmi could be proven, also there is no higher risk for complications in URS for obese patients. Safety and efficiency is no matter of weight of the patient treated.

#### VP9-18 URETEROSCOPIC STONE TREATMENT OF LOWER POLE CALCULI

K. Oberhagemann, C. Netsch, T. Bach, A. Gross—Germany

**Background:** By improved technology stones in nearly every calix of the kidney are treatable by ureteroscopy. Still the indication for lower pole stones is discussed. In our department we perform URS for lower pole calculi on basis of the following algorithm: 1. Stone size <1.3 cm. 2. stone situation with poor prospect of success in ESWL. 3. after two or more unsuccessful treatments with ESWL. Aim of this study was to explore safety and efficiency of URS in lower pole calculi.

**Methods:** 172 patients were included in this retrospective study, who sustained URS in sole stone burden of the lower calix. Mean age was 50.5 y., with 62.2% (n = 107) male patients. Average stone size was 6.9 mm (1.5–23.2 mm) with a mean stone number of 1.6 (1–20).

**Results:** Flexible URS was performed in 99 cases (57.6 %), in 73 patients a combination of flexible and rigid URS. 67 (39%) of the patients had earlier stone treatments, in particular ESWL (n = 26), URS (n = 5) and PCNL (n = 14). 22 of the patients had multiple earlier treatments. Lithotripsy (Ho:YAG-Laser) was used in 43 patients (25%). Mean operation-time was 57.7 min (13–170 min). Stone-free rate after single-treatment was 91.1% (n = 139), including 10 cases of Randell-plaques (5.8%) and 6 cases of extra-pelvic stone location (3.5%). Complications appeared in 15 cases (8.7%) consisting of hematuria (n = 1), infection (n = 1), paravasation (n = 4), perforation (n = 4) and others (n = 5).

**Conclusion:** By ureteroscopy a high stone-free rate is possible with a low complication rate and a very low rate of severe complications. This assures safety and efficiency of renosopic stone treatment, also in lower pole calculi.

#### VP9-19 URS: WHERE IS THE STONE?

K. Oberhagemann, C. Netsch, T. Bach, A. Gross—Germany

**Background:** By better availability of IVU or CT renal stones can be more exactly localized. Still in URS some of those pre-assigned intra-pelvic stones show to be extra-pelvic or still coated with tissue (Randell-Plaques). Aim of this present study was to analyze frequency of those non-treatable stones in performed URS.

**Methods:** Between 2006 and 2008 1.120 patients required URS for stone treatment in our department. In 80 (7.1%) of those a non-treatable stone was described. All 80 patients got prior x-ray for stone diagnostic, in particular CT in 9 cases (11.3%), IVU in 23 cases (28.8%) and 76 cases of retrograde-urography (95.0%). Mean stone size was 8.0 mm (2–20 mm) with mean number of 2.3 stones (1–33). 26 of the patients (32.5%) had earlier stone treatments, in particular SWL in 5 (6.2%), URS in 2 (2.5%) and PNL in 11 (13.6%) cases. 8 patients (10%) had multiple earlier treatments because of large stone burden.

**Results:** In 20 cases (25%) the pre-assigned stones could not be located in the renal pelvis or calix. In 32 patients (40.0%) an extra-pelvic stone localization appeared, in 48 patients (60%) Randell-Plaques were visible with no intention to treat. Complications appeared in 4 cases (4.9%) with one case of gross-hematuria after lithotripsy. No complications appeared in cases of diagnostic URS only.

**Conclusion:** Non-treatable stones appear in over 7 percent of all performed URS. In uncertain stone situation with possibility of extra-pelvic stone localization or Randell-Plaque URS can serve as a safe and efficient diagnostic method to spare patient unnecessary treatments, such as ESWL.

#### VP9-20 ANTEGRADE URETEROSCOPY FOR MANAGING OF URETERAL STONES IN TRANSPLANTED KIDNEYS

S. Hosseini, A. Tabibi, A. Noor-alizadeh—Iran

**Background:** We report our experience with antegrade ureteroscopy for ureteral stone in transplanted kidneys.

**Methods:** Between July 2004 and March 2008, four men (mean age 50.7 years, range 38–65) were diagnosed with ureteral stones in their transplanted kidneys. The patients were underwent shock wave lithotripsy that failed. Therefore, they scheduled for antegrade ureteroscopy. We evaluated perioperative variables, including: transplant type (cadaveric vs live), interval between transplantation and percutaneous nephrolithotomy, stone size and location, serum creatinine and hemoglobin levels and how the patients' urolithiasis presented. We also collected intraoperative data, such as imaging modality used to gain access, puncture location, type of dilation system used, placement of double-J ureteral stent, estimated blood loss, and the need for a blood transfusion.

**Results:** All patients were stone-free after procedure, with no complications during or after surgery. The mean (range) operative duration was 45 (25–60) min, the mean hemoglobin decrease was 0.6 (0.2–1.2) g/dL and no blood transfusions were required. The serum creatinine level was decreased after surgery.

**Conclusion:** Antegrade ureteroscopy is a safe and effective procedure for managing ureteral stone in transplanted kidney. It could be considered as effective alternative method in treating these patients regarding shock wave lithotripsy and retrograde ureteroscopy limitations.

## VP10: LAPAROSCOPY PROSTATE-1

#### VP10-01 THE IMPACT OF PROSTATE SIZE ON LAPAROSCOPIC RADICAL PROSTATECTOMY

M. Baptistussi, M. Morihisa, E. Gewher, A. Martins—Brasil

**Background:** Removal of a large prostate can be challenging during open or laparoscopic radical prostatectomy (LRP). Although gland size has been shown not to influence functional outcome in open radical prostatectomy (ORP) (Foley 2003), longer operating times have been reported for transperitoneal LRP (El-Feel, 2003 & Rassweiler, 2001). The aim of this study was to investigate the influence of prostate size on LRP outcomes.

**Methods:** 200 cases of LRP were performed from March 2002 to December 2008, 39 LRP were performed using a transperitoneal approach and 161 using an extraperitoneal approach. 159 patients had a prostate weight  $\leq 80$  g (group I) and 41 patients had a prostate weight  $\geq 80$  g (group 2) on final histology.

**Results:** Patients age, weight, PSA, Gleason sum and clinical stage were all similar. The mean (group 1 versus group 2) gland weights were 46.8 g versus 97.8 ( $p < 0.0001$ ), mean operating times 192 versus 207 minutes ( $p < 0.03$ ), mean blood loss 259 versus 289 ml ( $p < 0.25$ ), mean inpatient stay 3.2 versus 2.9 days ( $p < 0.04$ ), mean complications 4.5 versus 10.5% ( $p < 0.07$ ) and mean positive margins 21.5 versus 9.3% ( $p < 0.03$ ). Independent samples test; Chi-square test.

**Conclusion:** Larger prostates were associated with a longer operating time (15 minutes) but shorter hospitalization and fewer positive surgical margins. Blood loss and complication rates were similar. Prostate size should not be a factor determining a patient's

suitability for LRP. Longer follow-up is needed to assess the affect of prostate size on functional and oncological results.

#### VP10-02 EXTRAPERITONEAL LAPAROSCOPIC RADICAL PROSTATECTOMY: ONCOLOGIC AND FUNCTIONAL RESULTS REGARDING 175 CASES

M. Baptistussi, M. Morihisa, E. Gewher, A. Martins—Brasil

**Background:** To evaluate operative, oncologic and functional results of extraperitoneal Laparoscopic radical prostatectomy.

**Methods:** From 2003, 175 patients underwent laparoscopic extraperitoneal radical Prostatectomy for clinically localized prostate cancer. Age at surgery, clinical stage, Preoperative PSA, and Gleason score of positive were noted. Postoperatively, the weight of the specimen, final Gleason score, lymph node status, occurrence of positive margins and the pathological stage were noted. Continence (defined by no pad) and erectile function (defined by erection allowing sexual intercourse without medication) were analysed Prostatectively by a self-administrated questionnaire.

**Results:** Mean age of patients was 57.9 years, mean PSA 7.9 ng/ml. Clinical stage of Patients was T1a-b in 3.0%, T1c in 64.2%, T2a in 30.3% and T2b in 2.4%. Mean Gleason Score of biopsies was  $6.2 \pm 1.0$ . Mean operating time was  $155 \pm 48$  min, transfusion rate 4%, bladder catheterization time  $6.6 \pm 7.5$  days, hospital stay  $2.3 \pm 0.2$  days, rate of medical and surgical complications 2.4% and 6.1%. Mean prostate weight was  $56.7 \pm 21$  g, mean Gleason score  $6.9 \pm 0.6$ . Pathological stage was pT2 in 45.5% tumors. Positive surgical margins were 15.4% for pT2 and 44.7% for pT3

tumors, and 26.7% overall. After 2 years of follow-up, continence rate increased to 91% and potency rate to 64% in Case of bilateral bundles preservation (87.5% for patients <60 years old).

**Conclusion:** Extraperitoneal approach offers satisfactory results to radical Prostatectomy with advantages of laparoscopic procedures. Functional results and Specially potency radical prostatectomy are equivalent to open surgery.

### VP10-03 THE ROLE OF LAPAROSCOPIC RADICAL PROSTATECTOMY (LRP) IN THE MULTIMODAL TREATMENT OF HIGH RISK PROSTATE CANCER (HRPCA): PRELIMINARY EXPERIENCE ON 25 CASES

U. Anceschi, C. Anceschi, M. Gaffi, F. D'amico, C. Molinari, M. Lentini—Italy

**Background:** To describe retrospectively the perioperative, oncologic and functional outcomes of LRP for HRPCa.

**Methods:** Between October 2007–March 2009 we performed 25 LRP for HRPCa. As an alternative to first-line radiotherapy (RT) laparoscopic treatment was offered to patients with the following eligibility criteria: PCa  $\geq$  T2b; PSA  $\geq$  15; Gleason Score  $\geq$  7; no comorbidity; life expectancy >10 years. All the procedures were performed by the same team with a transperitoneal approach and extrafascial technique. An extended lymphadenectomy was performed in all the procedures. Patients were informed about the loss of sexual function and the possibility of a further adjuvant treatment (RT/hormonal therapy (HT)). Primary endpoints to evaluate treatment efficacy were: positive surgical margins (PSM) rate; Mean lymphnode number; perioperative complication rate; median hospital stay; mean catheterization time; biochemical failure rate; local disease recurrence rate; mean disease free survival (DFS); mean disease specific mortality rate; urinary continence rate. Potency recovery rate was not assessed for the whole amount of extrafascial procedures. In case of PSM or lymphnode involvement patients were offered respectively adjuvant radiotherapy or hormone therapy.

**Results:** Median age of patients was 61 years. The definitive histological results were as following: 4 organ-confined disease (pT2c), 14 PCa with extra capsular extension (ECE) (pT3a) 7 with seminal vesicles involvement (pT3b). 3 patients had positive lymph nodes (pN+). Median lymphnode number removed for patient was 16. 11 patients had locally advanced disease (ECE with no PSM). PSM rate was 24% (6 pz). Median hospital stay was 7 days (range 5–12), median catheterization time was 9 days (9–21). Continence rate at 3 months follow-up was 80%. % of perioperative complications was 8%. At 14.5 median follow-up (range 12–17) 80% has an undetectable PSA value. In a range of 9 months from the procedure 13.3% developed metastatic disease. MTS was 6.6%.

**Conclusion:** The role of PRL for HRPCa treatment remains controversial. Patients should be exhaustively informed about the higher incidence of intraoperative and postoperative complications, inferior functional outcomes and the possibility of a further adjuvant treatment. PRL may be considered an alternative to first-line RT for HRPCa in patients with no comorbidity and life expectancy >10 years. However, further evidence is needed to understand whether LRP has a role in the multimodal treatment of HRPCa.

### VP10-04 A COMPARISON OF OUTCOMES FOR INTER-FASCIAL AND INTRAFASCIAL NERVE-SPARING RADICAL PROSTATECTOMY

J. Stolzenburg, P. Kallidonis, M. Do, A. Dietel, R. Rabenalt, E. Liatsikos

**Background:** To compare the efficacy and results of the intrafascial nerve-sparing Endoscopic Extraperitoneal radical prostatectomy (nsEERPE) with the interfascial (standard) nsEERPE in an attempt to elucidate which technique provides the better outcome.

**Methods:** 400 patients underwent nsEERPE between June 2004 and June 2008. 200 patients underwent bilateral intrafascial nsEERPE (Group A) and 200 bilateral standard nsEERPE (Group B). All patients had at least 12 months follow up. Patient demographics, mean blood loss, mean catheterisation time, complications, functional and oncological outcome were reviewed.

**Results:** Patient demographics, mean blood loss and mean catheterisation time were similar between the groups. At three months, 74% of Group A and 66.5% of Group B were continent. At 6 months the respective figures 84.2% and 82.7%. At 12 months, 93.2% of Group A and 90.8% of Group B were continent. Potency rates of Group A were 93.5% (<55 years), 83.3% (55–65 years) and 60% (>65 years) at 12 months. The respective figures for Group B were 77.1%, 63.2% and 40% at 12 months. Positive surgical margins (PSMs) were detected in 6.2% of pT2 and 31.8% of pT3 patients of Group A. PSMs in Group B were observed in 5.6% of pT2 and 26.3% of pT3 patients.

**Conclusion:** Intrafascial nsEERPE provides significantly better potency in patients 55–65 years of age at 6 and 12 months without compromising the oncological outcome. The overall potency was significantly improved in the case of intrafascial technique at 6 and 12 months. Current data supports the claim that the additional nerve preservation in the radical prostatectomy procedures may improve the functional outcomes.

### VP10-05 LONGER PRESERVATION OF MEMBRANOUS URETHRA IMPROVED URINARY CONTINENCE IN LAPAROSCOPIC RADICAL PROSTATECTOMY: THE INITIAL RESULTS

X. Gao, X. Pu

**Background:** Several modifications in technique have been suggested to improve postoperative incontinence, including bladder neck preservation and various methods of apical dissection. We performed an initial study to determine whether the technique of a longer preservation of membranous urethra improved urinary continence after laparoscopic radical prostatectomy (LRP).

**Methods:** A total of 20 men with clinically localized prostate cancer underwent LRP (standard apical dissection in 10, longer preservation of membranous urethra technique in 10). In longer preservation of membranous urethra group, variable division of the membranous urethra at least 5 mm distal to the prostatic urethral junction. Patients were evaluated by independent observer questionnaire to determine their continence status. The overall continence rate and time to achieve continence was compared between the two surgical groups.

**Results:** Mean patient age and serum prostate-specific antigen values were not significantly different between the two groups. Clinical and pathologic stages were also similar. The mean follow-up period for the longer preservation of membranous urethra group

was 35 weeks compared with 36 weeks for the standard group ( $P > 0.05$ ). The median time until continence was achieved after surgery was significantly shorter ( $P < 0.01$ ) for the longer preservation of membranous urethra group than for the standard method (6.0 and 12 weeks, respectively). However, the overall continence rate at 1-year follow-up for the two groups was similar (100% and 96%, respectively).

**Conclusion:** The longer preservation of membranous urethra technique improves the rapidity of return of urinary continence after LRP without significantly enhancing overall continence.

#### **VP10-06 LAPAROSCOPIC RADICAL PROSTATECTOMY FOR PATIENTS WITH GLEASONS 8–10 ± PSA > 20**

A. Arora, C. Eden

**Background:** High-risk prostate cancer (HiRPC) (PSA > 20 ng/ml ± Gleason 8–10) is characterised by its higher rate of metastasis and cancer-related death and responds poorly to treatment monotherapy with 10-year survival rates for G8-10 of 45–67% (Lu-Yao, 1997). As a result, interest continues to grow in multi-modality approaches to HiRPC.

**Methods:** Of a total of 1159 patients who were accepted for laparoscopic radical prostatectomy (LRP) 71 had HiRPC. All patients were treated by extended pelvic lymphadenectomy and LRP with wide-excision of both neurovascular bundles.

**Results:** Mean operating time = 208 minutes; blood loss = 233 ml; post-op. hospital stay = 2.9 nights; complication rate = 2.8%; node count = 11.2; lymph node positivity = 7.1%; margin positivity = 21%; up-grading = 11.3%; down-grading = 46.5%; up-staging = 28.2%; down-staging = 1.4%. At a mean follow-up of 30.0 months 95.8% of patients were free of biochemical recurrence and 95.8% were continent.

**Conclusion:** The significant proportion of patients (46.5%) who had their tumour down-graded on final histology, the 95.8% BDFS and the 95.8% continence rates at 30 months should serve to encourage suitably experienced urologists to offer radical prostatectomy to patients with HiRPC and negative staging.

#### **VP10-07 FEASIBILITY OF LAPAROSCOPIC RADICAL PROSTATECTOMY FOLLOWING TOTAL EXTRAPERITONEAL (TEP) MESH INGUINAL HERNIA REPAIR**

A. Arora, C. Eden

**Background:** Open radical prostatectomy following total extraperitoneal (TEP) mesh inguinal hernia repair has a reputation for being technically challenging (Liedberg et al., 2002) due to the intense fibrosis and fusion of tissue planes elicited by the mesh, and can result in the abandonment of surgery (Foley et al., 2003).

**Methods:** Sixteen patients with a history of TEP (unilateral = 3, bilateral = 13) underwent laparoscopic radical prostatectomy (LRP) using an extraperitoneal (92%) or transperitoneal (8%) approach. This group was compared to the 1143 patients operated on in the same period who did not.

**Results:** Peri-operative parameters in TEP and non-TEP patients were: operating time = 193 & 181 minutes ( $p = 0.39$ ); blood loss = 279 & 263 ml ( $p = 0.79$ ); post-op. hospital stay = 2.7 & 2.9 nights ( $p = 0.50$ ); complication rate = 0% & 4.8% ( $p = 1.00$ ); +ve margin rate = 23.18% & 13.5% ( $p = 0.65$ ) There was one conversion and five blood transfusions, all in non-TEP patients.

**Conclusion:** LRP following TEP mesh inguinal hernia repair is feasible and safe, with no discernable difference in patients with

and without a prior history of this. However, the authors would still advise surgeons inexperienced in RP to exercise caution when selecting these patients for surgery.

#### **VP10-08 COMPARATIVE EVALUATION OF ULTRASONIC SCISSORS VERSUS ENERGY-FREE DISSECTION DURING NERVE-SPARING ENDOSCOPIC EXTRAPERITONEAL RADICAL PROSTATECTOMY**

E. Liatsikos, P. Kallidonis, A. Dietel, M. Do, T. Haefner, J. Stolzenburg—Greece

**Background:** To elucidate the impact of dissection technique on the functional and oncological outcome in nerve-sparing Extra-peritoneal Endoscopic Radical Prostatectomy (nsEERPE).

**Methods:** 520 consecutive patients underwent bilateral intrafascial or standard nsEERPE. In 260 patients, the dissection was performed by ultrasonic scissors (Group A) while in another 260 patients the dissection took place with a combination of clips and scissors (Group B). The intraoperative and postoperative parameters were recorded.

**Results:** Patients of Group A reported to be continent in 67.7% while 24.1% reported minimal stress incontinence and 8.2% required >2 pads/d at 6 months. At 12 months, 92.8%, 6.3% and 0.9% of the Group A patients were continent, required 2–3 pads/day and >3 pads/day, respectively. The respective figures for Group B were 84.7%, 12.6% and 2.7% at 6 months as well as 92.7%, 6.3% and 1.0% at 12 months. Erectile function sufficient for intercourse with or without the help of PDE5 inhibitors was reported by 48.8% of Group A patients and 64.6% of the Group B patients at 6 months. At 12 months, 65.9% and 80.3% of Group A and B patients were potent, respectively. Overall potency was significantly better when using the Clips method, when measured both in 6 months and 12 months periods.

**Conclusion:** The performance of cautery-free nsEERPE proved to provide better functional results in terms of potency and seems to provide additional documentation to the existing debate regarding the avoidance of energy producing instruments during the dissection of neural containing structures.

#### **VP10-09 EXPERIENCES OF CONTINENCE-PRESERVING IN LAPAROSCOPIC RADICAL PROSTATECTOMY**

L. Ma, Y. Huang, G. Wang, C. Xiao, X. Hou, K. Hong

**Background:** To summarize our experiences of continence-preserving in 106 cases of Laparoscopic radical prostatectomy.

**Methods:** We Retrospective summarized 106 of Laparoscopic radical prostatectomy which during Feb. 2004 to Jun. 2009. The patients' age were 57–82 years with a mean of 70 years. The max of the diameter of their prostate ranged from 2.8–7.5 cm with a mean of 4.6 cm. We selected 4–5 points to puncture prostate, and all the patients were diagnosed of prostate cancer by biopsy before operation. The key points of continence-preserving were Listed in the following: 1. Removing the surrounding fat of prostate to see straight the anatomical structure. 2. When we separate and cut the apex of prostate, using scissors is better than ultracision and bipolar coagulation. 3. Close to the Seminal Vesicle to separate Ventral prostate can reduce the injury of inferior hypogastric nerve. 4. Close to the Seminal Vesicle and Outer membrane of prostate to cut off the posterior ligament.



**Results:** The procedure was successfully completed in all the cases without converting to open surgery, The operation time ranged from 1 h 50 min to 11 h.

**Conclusion:** The key points of continence-preserving are using scissors to dissociate and cut the apex of prostate, and less using ultracision and bipolar coagulation. Distinguish the neurovascular bundle and avoid to injury it is the most importance to prevent incontinence.

### VP10-10 SUTURELESS DORSAL VEIN LIGATION DURING LAPAROSCOPIC RADICAL PROSTATECTOMY

M. Kilciler, L. Tahmaz, S. Bedir, H. Guler, M. Dayanc

**Background:** Our aim was to evaluate the efficiency of sutureless dorsal vein ligation during laparoscopic radical prostatectomy.

**Methods:** We did not use any suture for dorsal vein ligation in last 12 patients performed laparoscopic radical prostatectomy at our clinic. We performed 11 retroperitoneal and 1 transperitoneal laparoscopic radical prostatectomy. We used 5 mm LigaSure for dorsal vein ligation. While LigaSure was closed, we performed three times coagulation. Then dorsal vein was cut with LigaSure's knife. LigaSure was more effective when thin tissue was clamped. In this way, the procedure was continued until all dorsal vein complex finished. When bleeding occurred during procedure there was enough tissue to put metal clips close to symphysis pubis. This was another important subject in our study.

**Results:** Mean age was 63, mean operation time was 210 minute and mean blood loss was 350 ml. In our 3 patients, bleeding was occurred during dorsal vein dissection but the bleeding was stopped with metal clips easily. Drains and urethral catheters were removed at 3rd and 5th day, respectively.

**Conclusion:** No suture using during dorsal vein ligation reduces the operation time. LigaSure is a proper tool for dorsal vein ligation during laparoscopic radical prostatectomy.

### VP10-11 OBESE AFRICAN AMERICANS WITH DIAGNOSTIC PSA

D. Albala, M. Lipkin, A. Caire, L. Sun, T. Polascik, J. Moul—USA

**Background:** We sought to analyze the relationship between African American (AA) race and obesity in early detected prostate cancer.

**Methods:** A cohort of 4196 patients who underwent radical prostatectomy (RP) from 1988 to 2008 was retrieved from the Duke Prostate Center database. A subset of 389 (AA = 20.9% and non-AA = 79.1%) patients with a body mass index (BMI)  $\geq 30$ , T1c, and PSA  $< 10$  ng/ml were stratified by race and analyzed. Age at surgery, race, surgical margin status, pathological tumor stage (pT2, pT3/4), pathological Gleason sum ( $< 7$ , 3 + 4, 4 + 3,  $> 7$ ), extracapsular extension, seminal vesicle invasion, and tumor percent underwent univariate analysis followed by Cox regression analysis.

**Results:** Approximately 38.1% (143) of AA were obese compared to 25.0% (509) of the non-AA when examining the entire cohort. AA race had significantly higher tumor percent (15.0 vs. 10.0%,  $p = 0.002$ ), as well as a greater proportion of pT3/4 disease (45.1 vs. 26.2%,  $p = 0.039$ ), pathological Gleason sum  $\geq 7$  (70.7 vs. 50.5%,  $p = 0.003$ ), extracapsular extension (37.8 vs. 23.1%,  $p = 0.007$ ), and positive surgical margin (52.4 vs. 36.8%,  $p = 0.010$ ), compared to non-AA. AA race had a greater risk of

PSA recurrence (PSAR) in Kaplan Meier ( $p = 0.004$ ) and Cox regression analysis ( $p = 0.040$ , HR = 1.72).

**Conclusion:** A greater proportion of AA's were obese. Obese AA's with non-palpable cancer and PSA  $< 10$  ng/ml have higher risk pathological features than obese non-AA as well as higher risk of PSAR. Obesity may be partly responsible for the racial disparity seen in prostate cancer.

### VP10-12 MODIFIED APICAL DISSECTION OF THE PROSTATE IMPROVES EARLY CONTINENCE IN LAPAROSCOPIC RADICAL PROSTATECTOMY: TECHNIQUE AND INITIAL RESULTS

X. Gao, X. Pu, J. Qiu

**Background:** Incontinence after radical retropubic prostatectomy (RRP) is one of the greatest worries for all patients. One of the possible reasons for this urinary incontinence is a postoperative deficiency of the external striated urethral sphincter (EUS) complex and continence nerves. This study evaluated the application of a modified simple technique to dissection of the apical prostate in laparoscopic radical prostatectomy (LRP) and assessed the rate of urinary continence.

**Methods:** 104 patients were randomized selected using envelopes enrolled this study. A standard LRP was performed in 52 patients (standard LRP group) and a modified technique for simple dissection of the apical prostate in LRP was also performed in other 52 patients (modified LRP group). The urethra is dissected and transected at the apex of the prostate proximal to nerve-distributing rhabdosphincter using sharp scissors for avoiding to damage the EUS complex and continence nerves. In all patients, a pad test were performed in 3, 30, and 90 d postoperatively and correlated with urinary continence.

**Results:** After catheter removal, the continence rates were regained in 56%, 82% and 92% of patients in modified LRP group compared with 28%, 56%, 72% of patients in standard LRP group at 3, 30 and 90 days, respectively. A statistically significant difference was present at 3 and 30 d ( $p < 0.01$ , respectively). At 90 d the difference, although still present, was not statistically significant ( $p > 0.05$ ).

**Conclusion:** In this preliminary study, the technique of simplified apical dissection of the prostate in LRP appears to be an easy and feasible technique in early recovering the urinary continence.

### VP10-13 ENDOSCOPIC EXTRAPERITONEAL RADICAL PROSTATECTOMY AFTER PREVIOUS TURP: ONCOLOGICAL AND FUNCTIONAL OUTCOMES OF 100 CASES

E. Liatsikos, M. Do, P. Kallidonis, A. Dietel, A. Al aown, J. Stolzenburg—Greece

**Background:** Radical prostatectomy has been reported to be more challenging and associated with complications in patients with history of transurethral resection of prostate (TURP).

**Methods:** In our series of 2300 patients, 100 patients had undergone endoscopic extraperitoneal radical prostatectomy (EERPE) after previous TURP. All patients included in the study had at least 1 year follow up. Patient demographics, mean blood loss, mean catheterisation time, complications, functional and oncological outcome were reviewed.

**Results:** 26 patients underwent nerve-sparing EERPE. Lymphadenectomy was performed in 45 patients. Operative time and mean blood loss were similar to previous EERPE series. The transfusion rate and mean time of catheterisation were slightly higher than

general EERPE population. Positive surgical margin rates were 7% for pT2 and 36% for pT3/4. At 12 months follow-up, 94% of the patients did not experience PSA level  $\geq 0.1$  ng/ml. The overall complication rate was 14%. At 12 months, 93% of patients were continent, 4% using 1–2 pads/day and 3% needing  $>2$  pads/day. The potency rates for the 26 patients who underwent nsEERPE were 52.6% and 66.7% at 6 and 12 months, respectively.

**Conclusion:** Patients who had previously undergone TURP should be considered for radical treatment with EERPE. The procedure is safe even though technically more demanding. Peri-operative, functional and short-term oncological outcome is promising and directly comparable to existing EERPE experience. Transfusion rate and catheterisation time are slightly higher but still remained low in comparison to open radical prostatectomy series. Potency results were lower in comparison to existing EERPE series.

#### VP10-14 LAPAROSCOPIC RADICAL PROSTATECTOMY: MINIMUM 5 YEAR FOLLOWUP OF THE FIRST UK CASES

A. Arora, C. Eden

**Background:** Laparoscopic radical prostatectomy (LRP) continues to develop as a minimally invasive alternative to open radical prostatectomy. We present the results of the first cases performed in the UK with a minimum of five years follow-up.

**Methods:** Mean age = 62 years (range 45–73). Most (85%) patients had a PSA between 4–10, clinical stage T1 disease (55%), and Gleason 6 on biopsy (59%). Forty-six percent of patients underwent unilateral or bilateral nerve preservation and 18% had pelvic lymphadenectomy performed.

**Results:** Mean operating time = 208 minutes, with a 0.4% conversion rate. 1.6% of patients received a blood transfusion and 2.8% had major complications, including 3 rectal injuries. The positive margin rate = 11.6%. At a minimum of 5 years follow-up (mean = 5.4 years) overall survival = 99.2% and biochemical progression-free survival = 92% in all patients: 92.8% for pT2, and 86% for pT3. Ninety-four percent of patients were pad-free and 60% of patients undergoing nerve preservation retained erectile function.

**Conclusion:** This series updates the 5-year minimum follow-up results for LRP performed in the UK, with morbidity and functional and oncological results which are comparable to previously published open radical prostatectomy (ORP) series.

#### VP10-15 THE EFFECT ON CONTINENCE OF PRESERVING THE BLADDER NECK IN ENDOSCOPIC EXTRA-PERITONEAL RADICAL PROSTATECTOMY

E. Liatsikos, P. Kallidonis, M. Do, A. Dietel, T. Haefner, J. Stolzenburg—Greece

**Background:** Bladder neck (BN) preservation during radical prostatectomy has been reported to improve post-operative continence. The current study investigates the impact of BN preservation on the early and late postoperative continence and the influence of BN approach on the Positive surgical margins.

**Methods:** 150 patients (Group 1) who underwent BN sparing endoscopic extraperitoneal radical prostatectomy (EERPE) and 90 patients with BN resection (Group 2) were retrospectively evaluated.

**Results:** Both groups were similar regarding age, PSA and size of prostate. There was no significant difference in operative times, mean blood loss or transfusion rates. Mean catheterisation time was similar. The overall positive surgical margin rates (+SMR)

were very similar at 10.7% for Group 1 and 10.0% for Group 2. (Group 1, pT2 = 5.1%, pT3 = 30.3%, Group 2, pT2 = 2.9%, pT3 = 33.3%). 1/16 patients in Group 1 and 1/9 in Group 2 had a + SM at the bladder neck. Statistically significant differences in continence were observed between the two groups at 24 hours after catheter removal and at 3 months postoperatively.

**Conclusion:** BN preservation proved to have an impact in the early postoperative continence of patients undergoing EERPE. The positive surgical margins were not influenced by the performance of BN preservation.

#### VP10-16 EXPERIENCES OF CONTINENCE-PRESERVING IN LAPAROSCOPIC RADICAL PROSTATECTOMY

L. Ma, Y. Huang, G. Wang, X. Hou, K. Hong, J. Lu—China

**Background:** To summarize our experiences of continence-preserving in 106 cases of Laparoscopic radical prostatectomy.

**Methods:** We Retrospective summarized 106 of Laparoscopic radical prostatectomy which during Feb. 2004 to Jun. 2009. The patients' age were 57–82 years with a mean of 70 years. The max of the diameter of their prostate ranged from 2.8–7.5 cm with a mean of 4.6 cm. We selected 4–5 points to puncture prostate, and all the patients were diagnosed of prostate cancer by biopsy before operation. The key points of continence-preserving were Listed in the following: 1. Removing the surrounding fat of prostate to see straight the anatomical structure. 2. When we separate and cut the apex of prostate, using scissors is better than ultracision and bipolar coagulation. 3. Close to the Seminal Vesicle to separate Ventral prostate can reduce the injury of inferior hypogastric nerve. 4. Close to the Seminal Vesicle and Outer membrane of prostate to cut off the posterior ligament.

**Results:** The procedure was successfully completed in all the cases without converting to open surgery, The operation time ranged from 1 h 50 min to 11 h.

**Conclusion:** The key points of continence-preserving are using scissors to dissociate and cut the apex of prostate, and less using ultracision and bipolar coagulation. Distinguish the neurovascular bundle and avoid to injury it is the most importance to prevent incontinence.

#### VP10-17 MINIMALLY INVASIVE MANAGEMENT OF POSTOPERATIVE BLEEDING AFTER RADICAL PROSTATECTOMY: TRANSARTERIAL EMBOLIZATION

C. Jeong, Y. Park, C. Kwak, J. Ku, H. Jeong, H. Kim

**Background:** Severe postoperative bleeding after radical prostatectomy is a rare but one of the most serious complications. Massive postoperative bleeding causing hemodynamic instability necessitates open surgical exploration associated with considerable morbidity. Minimally invasive management such as transarterial embolization (TAE) could be alternative option, thus we report on our successful experience related this.

**Methods:** From July 2006 to June 2009, men with a severe immediate postoperative bleeding causing hemodynamic instability after radical prostatectomy were enrolled. We performed emergency angiography and superselective TAE instead of surgical exploration as the initial management. TAE was performed using an embucilate (Histoacryl<sup>®</sup>; Braun, Melsungen, Germany): ethiodized poppy seed oil (Lipiodol; Guerbet, Paris, France) 1:3 mixture. We determined treatment success rate, efficacy and safety.

**Results:** A total of 4 among 628 patients (0.6%) had postoperative bleeding fit to inclusion criteria in this period. CT angiography

revealed active bleeding in all cases. Table 1 shows clinicopathologic characteristics and treatment results of these 4 patients. All cases were successfully treated with TAE without any additional treatment such as surgical exploration and there was no treatment related adverse event. Table 1. Clinicopathologic characteristics and treatment results. Case 1234 Age (years) 54696973 Type of surgery LRPRALPRALPRRP Neurovascular bundle saving Bilateral Left Bilateral Bilateral Bleeding focus A branch of the left internal iliac artery A branch of the left internal iliac artery A distal branch of the right internal pudendal artery A branch of the left internal iliac artery Preoperative hematocrit (%) 36.041.540.643.6 Lowest hematocrit before TAE (%) 26.927.527.223.4 Total amount of postoperative transfusion (units) 57109 Duration of TAE (hours) 914184 Success Yes Yes Yes Adverse event NoNoNoNo Hematocrit at discharge (%) 3735.943.439.2 Pathologic T stage-T3aT3aT2aT2a Gleason score 6(3+3) 7(3+4) 7(4+3) G(3+3) Comment Hemophilia A LRP=laparoscopic radical prostatectomy, RALP=robot-assisted laparoscopic radical prostatectomy, RRP=radical retropubic prostatectomy.

**Conclusion:** We successfully treated all patients who had severe immediate postoperative bleeding after radical prostatectomy with TAE for last 3 years. We concluded that rapid diagnosis by CT angiography and early TAE could replace surgical exploration in this situation. And this could minimize the morbidity associated with severe bleeding, transfusion, and open surgical exploration.

#### VP10-18 EVALUATION OF A NEW VALVE-LESS TROCAR FOR UROLOGIC LAPAROSCOPY

M. Atalla, A. Herati, S. Andonian, S. Rais-bahrami, L. Kavoussi—USA

**Background:** Laparoscopic trocars typically maintain pneumoperitoneum using trap door valves and silicone seals. However, valves and seals hinder passage of instruments, cause lens smudging, trap specimens and needles being removed from the abdominal cavity, and lose their seal with repeated instrument exchange. The aim of the present study was to evaluate the feasibility of a newly designed valve-less trocar.

**Methods:** The valve-less trocar system creates a curtain of forced gas to maintain pneumoperitoneum. A separate unit filters smoke and recirculates captured escaping gas. The valve-less trocar was trialed in consecutive laparoscopic renal procedures of a single surgeon. Perioperative parameters and outcomes were collected and analyzed. The system's safety, advantages, and disadvantages were evaluated. Insufflation gas usage, elimination, and absorption were also measured.

**Results:** Twenty-five patients underwent laparoscopic renal procedures using the valve-less trocar system. The procedures included laparoscopic partial, radical, and donor nephrectomy. The mean patient age was 58.26 years. The mean operative time was 125 minutes and the mean drop in Hb for the cohort was 2.34 g/dL (range 0.4–5.4). Two patients developed subcutaneous emphysema and of the two patients, one developed clinically insignificant pneumomediastinum postoperatively. There were no postoperative complications. The surgeon noted that the use of a valve-less trocar decreased smudging of laparoscopes, expeditiously evacuated smoke during cauterization leading to improved visualization, maintained pneumoperitoneum even while suctioning, and resulted in easy extraction of specimens and needles. It was noted that insufflation gas consumption was low and CO<sub>2</sub> elimination was not impaired.

**Conclusion:** Use of a valve-less trocar is safe. Decreased laparoscope smudging may translate into decreased operative times and reduced gas consumption may equate to cost savings. Additionally, its use brings several advantages and convenience to the operating surgeon. However, the system should be compared with conventional trocars prospectively to demonstrate clinical and economic benefit.

#### VP10-19 EARLY EXPERIENCE WITH EXTRAPERITONEAL TRANSVESICAL ADENOMECTIONY FOR BENIGN PROSTATIC HYPERPLASIA

M. Hisano, F. Vicentini, M. Chaib, M. Pinheiro, M. Gotto, R. Shin—Brazil

**Background:** Benign prostatic hyperplasia (BPH) is a common disease that affects men over 50 years-old. It's treatment could be medical or surgical. Traditionally, surgical options are transurethral resection (TURP) and open surgery. Besides TURP been an optimal endoscopic treatment, it's limited by time and surgeon experience because of dilutional hyponatremia, restricting indication for large prostates. We describe our early experience with extraperitoneal transvesical adenomectiony (ETA) for these cases.

**Methods:** Between November 2008 and May 2009 we performed 11 consecutives ETA's for BPH. We started with a 2 cm transverse incision for skin and aponeurosis, 2 cm below umbilicus. Preperitoneal space was digitally developed. A 10 mm trocar is inserted and insufflation begun at 15 mm Hg. Others 3 ports were inserted by extraperitoneal view (2 of 10 mm at bilateral mid-clavicular line, and one of 5 mm, 2 centimeters medial to right iliac spine). Surgery started with bladder incision and recognition of trigone and bladder neck, which is circular incised, giving access to the plane of adenoma. Bluntly dissection of adenoma was performed until urethra, which is sectioned. Hemostasia of prostatic fossa was achieved with mono or bipolar. Bladder was closed in one total plane with Vycril 2.0 running suture. Three-way catheter and bladder irrigation was left. Adenoma was retrieved in a sac. An aspirative drain was left at extraperitoneal space.

**Results:** Median age was 70 years-old, varying from 65 to 83. Median prostate weight by ultrasound was 87 g (range from 69 to 170 g). Total operative time varied from 150 to 300 minutes, with a median time of 240 minutes. Intraoperative blood loss varied from 50 to 1000 ml, with a median of 400 ml. Median time for bladder irrigation was 36 hours, varying from 36 to 144 hours. One case needed conversion because of difficult dissection (9%) and another needed transfusion during post-operative time because of prolonged hematuria (9%). Hospitalization varied from 48 to 168 hours, with a median time of 72 hours. One case had orchitis; we didn't experience any other clinical or surgical complication. Final pathology showed BPH in all cases except one, with a median weight of 60 g.

**Conclusion:** ETA can be an option in the treatment of BPH. This series is associated with a low rate of transfusion, conversion and complications. Hospitalization time is also acceptable. More cases and randomized studies are needed to define its role.

#### VP10-20 THE IMPACT OF TIME-LAG IN THE LEARNING CURVE FOR EX VIVO SKILL ACQUISITION FOR LAPAROENDOSCOPIC SINGLE SITE SURGERY (LESS) VESICOURTHRAL ANASTOMOSIS

S. Kommu, D. Cartlidge, A. Chakravarti, A. Golash, C. Luscombe, S. (sarg)—United Kingdom

**Background:** We previously described a camera-monitor system that allowed for a delay in hand movement relative to movement perceived on the monitor i.e. "Time-Lag" and showed that this concept could alleviate intention anxiety for task completion (Kommu et al. J Endourol 2006, Vol. 20, No. supplement 1). We then successfully tested the impact of this tool on the learning curve for completion of a complex laparoscopic urological procedure i.e. the vesicourethral anastomosis. Herein we apply this platform and test its impact on ex vivo skill acquisition for Laparoendoscopic Single Site Surgery (LESS) vesicourethral anastomosis (VUA).

**Methods:** The Vesicourethral model was based on Kommu Level-4 model (Kommu et al. Levels of models. BAUS section of En-

dourology 2007. Edinburgh). The software for the Time-Lag Mode permitted a 2.0 second delay in movement on screen relative to real-time hand movement. Six novice trainees were enrolled (3 in Time-Lag versus 3 in conventional mode). Tasks were recorded and subsequently analysed.

**Results:** Novices who practiced initially with the Time-Lag mode were on average 1.8 times quicker at reaching the target skill set for LESS VUA compared with those who used real-time movement.

**Conclusion:** The concept of Time-Lag appears to significantly shorten the learning curve for target skill acquisition for VUA. Time-lag may have a potential application in acquiring the necessary skills for LESS prior to undertaking the live human LESS Urological case.

## VP11: IMAGING AND NEW TECHNIQUE

### VP11-01 EVALUATION OF ACUTE RENAL COLIC: A COMPARISON OF NONCONTRAST CT VERSUS 3 TESLA NON-CONTRAST HASTE MR UROGRAPHY

M. Semins, M. Bohlman, W. Hosek, J. Berkowitz, B. Matlaga—USA

**Background:** With the introduction of a 3 Tesla scanner, magnetic resonance urography (MRU), may be an alternative imaging modality for evaluation of acute renal colic. We performed a prospective study to compare the performance of CT with MRU in the evaluation of patients with suspected renal colic.

**Methods:** Patients presenting to the Emergency Department with acute renal colic were eligible for inclusion. Following a standard CT stone evaluation, patients underwent a noncontrast HASTE MRU study with a 3 Tesla scanner. The presence of peri-nephric fluid, hydronephrosis, ureteral obstruction, and calculus was assessed.

**Results:** A total of 22 patients completed the study. Twenty (91%) were diagnosed with an upper tract stone by radiographic findings. MRU detected a discrete stone in 50% of patients with stones seen by CT. Perinephric fluid was noted in 12 MRUs, compared to 7 CTs. Using CT as the reference standard, the combination of stone, perinephric fluid, and ureteral dilation gave MRU a sensitivity of 89%, specificity of 100%, and accuracy of 94%.

**Conclusion:** HASTE MRU with a 3 Tesla MR scanner can reliably detect the presence of upper urinary tract obstruction. Although CT imaging remains the superior modality with which to detect calculi, MRU detects a greater number of secondary signs of upper tract obstruction. For situations in which the use of ionizing radiation is undesirable, MRU is a reasonable imaging alternative.

### VP11-02 IDENTIFYING URIC ACID STONES USING DUAL-ENERGY COMPUTED TOMOGRAPHY: FIRST DIAGNOSTIC PERFORMANCE EVALUATION IN PATIENTS

M. Kozomara, P. Stolzmann, H. Scheffel, S. Leschaka, M. Müntener

**Background:** To investigate prospectively in patients with the suspicion of urinary stone disease the diagnostic performance of dual-energy (DE) computed tomography (CT) for the differentia-

tion between UA-containing and non-UA-containing urinary stones.

**Methods:** Data was acquired in 180 patients who were referred with the suspicion of urinary stone disease. DE CT scans were performed using dual-source CT in a DE mode (tube voltages, 80 kV and 140 kV; reference tube current time products 390 mAs/rot and 95 mAs/rot). The stones were classified as UA-containing or non-UA-containing. Sensitivity, specificity, positive predictive and negative predictive values were calculated using the crystallographic stone analysis as the reference standard.

**Results:** Of the 180 patients, DE CT depicted 101 patients (56%) with urinary stone disease. In 53 patients, stones were sampled. Forty-four out of 53 stones (83%) were non-UA-containing; and nine stones (17%) were UA-containing. The software automatically mapped 52/53 (95%) stones. One non-UA-containing stone (UA, 2 mm) was missed, one UA-containing stone was misclassified by software analyses. The sensitivity for the detection of UA-containing stones (8/9) was 89% (95% CI:52–100%), the specificity (43/44) was 98% (95% CI:88–100%), the positive predictive value (8/9) was 89% (95% CI:52–100%), and the negative predictive value (43/44) was 98% (95% CI:88–100%).

**Conclusion:** Our in-vivo results indicate that the differentiation between UA-containing and non-UA-containing stones can accurately be performed using dual-source dual-energy CT. Clinical implications: Dual-source DE CT accurately differentiates between UA-containing and non-UA-containing uroliths in patients and thereby may impact therapeutic decision making.

### VP11-03 INTRA-OPERATIVE SELECTIVE RENAL ARTERY BALLOON OCCLUSION DURING LAPAROSCOPIC RADICAL NEPHRECTOMY—DEMONSTRATION OF THE TECHNIQUE

S. Kommu, M. Nayeemuddin, C. Luscombe, A. Golash, J. Asquith, D. West—United Kingdom

**Background:** Laparoscopic radical nephrectomy (LRN) for renal tumors is a technically challenging operation with the potential for complications including significant blood loss. Temporary Intra-operative Selective Renal Artery Balloon Occlusion is an effective

adjunct that can be done prior to undertaking LRN. Herein, we demonstrate the technique.

**Methods:** A percutaneous transfemoral approach is used to perform arterial catheterisation and temporary balloon occlusion of the renal artery with the aid of a 5Fr double lumen occlusion catheter. The procedure is performed after intubation and ventilation immediately prior to nephrectomy. The main objective of this technique is to reduce renal blood perfusion and to aid with the nephrectomy. The balloon was deployed under image guidance by either of two experienced interventional radiologists prior to the laparoscopic surgeons' surgical extirpation. The technique was successfully used to permit LRN in fifteen cases.

**Results:** There were 15 cases (7 males & 8 females) with average age of 61 yrs (range 39–82 yrs). Average operative time was 185 mins (range 90–250 mins). The urological surgeons found that balloon assisted occlusion of the renal artery allowed tumour dissection and pedicle control to be achieved comfortably in kidneys with large renal tumours.

**Conclusion:** Intra-operative Selective Renal Artery Balloon Occlusion is a safe, reliable and effective adjunct in performing LRN with reduced blood loss. We demonstrate the technique.

#### VP11-04 CLINICAL OBSERVATION OF MALE VOIDING USING DYNAMIC MAGNETIC RESONANCE IMAGING: A PRELIMINARY STUDY OF BLADDER OUTLET OBSTRUCTION

Y. Siang Lin, H. Chin Tiong, L. Heow Pueh—Singapore

**Background:** Various methods in assessing bladder outlet obstruction have been demonstrated using imaging and non-imaging techniques. Images using ultrasound scanners are low in quality images and lack of three dimensional reconstruction capabilities. A study utilizing dynamic magnetic resonance imaging (MRI) that captures the dynamic changes of lower urinary tract has been conducted. This study aims to understand the morphological changes during voiding in real time.

**Methods:** A healthy 50 year old male with mild lower urinary tract symptoms was asked to void with a full bladder while lying supine in a 1.5 Tesla MRI machine. Single shot dynamic MRI images were obtained with a narrow field of view of 15 mm thickness. Sequential images were obtained and subject further analysis.

**Results:** The morphological changes of lower urinary tract of a male patient were successfully captured in sagittal view using dynamic MRI. Measurement parameters include bladder neck diameter, prostatic urethral angle, prostatic urethral diameter and urethra diameter. From the measurements, the bladder neck expands almost twice the size during voiding. The prostatic urethra was observed to bend at an angle of 34.2° at the proximal part of the verumontanum. Furthermore, the prostatic urethral diameter dilates almost 5 times, forming a spindle-shape. On the other hand, the urethra diameter was at 1.9 mm during initial voiding and expands to 6.72 mm at maximum voiding.

**Conclusion:** This study showed that MRI can be used to understand the dynamic behavior of lower urinary tract. Morphological changes can be measured and observed during voiding. These parameters maybe correlated to the degree of bladder outlet obstruction as a dynamic non-invasive assessment.

#### VP11-05 DIGITAL VIDEO FLEXIBLE URETEROSCOPY: GYRUSACMI/OLYMPUS INVISIO®DUR®-D TWELVE MONTH FAILURE AND REPAIR EXPERIENCE

B. Knudsen, M. Ferraro, K. Shah

**Background:** The GyrusACMI/Olympus Invisio®DUR®-D is a CMOS based digital flexible video ureteroscope that promises improved visualization and better ergonomics as compared to traditional fiber optic flexible ureteroscopes. While the failure modalities of fiber optic scopes are well established, little is known regarding the failure rate and modality of this new digital flexible ureteroscope. We report our 12 month experience with this endoscope specifically in terms of scope failure and repair.

**Methods:** We reviewed the 12 month repair record for four newly purchased DUR-D digital flexible ureteroscopes. Endoscopes that were deemed to need repair were returned to the manufacturer and the repair report was reviewed. We audited whether the repair was covered under warranty and, if not, what the cost of the repair was.

**Results:** A total of 9 failures requiring scope repair occurred. Seven of nine failures were not covered under warranty. Each repair was \$6600 and the total cost of the repairs was \$46,200. The causes of the failures was multifactorial, but 5/7 non-warranty repairs had a damaged distal lens which resulted in the scope flooding. This failure pattern was seen clinically as an abrupt onset of a very hazy and unclear image. The damage did not appear to occur as a result of inadvertent laser energy damage.

**Conclusion:** The primary failure modality for the DUR-D digital flexible ureteroscopes was different than what has been previously reported for fiber optic ureteroscopes. The distal lens appears to be extremely fragile and prone to breakdown. Further refinement of this video ureteroscope design is needed to improve reliability and cost effectiveness.

#### VP11-06 A PROSPECTIVE RANDOMIZED EVALUATION OF LAPAROSCOPIC DOPPLER TECHNOLOGY FOR HILAR DISSECTION DURING MINIMALLY INVASIVE PARTIAL NEPHRECTOMY

E. Hyams, P. Mufarrij, M. Perlmutter, M. Stifelman—USA

**Background:** We evaluated the utility of laparoscopic Doppler ultrasound (LDU) for facilitating hilar dissection during minimally invasive partial nephrectomy (MIPN).

**Methods:** An IRB-approved, prospective randomized protocol was developed to compare hilar dissection time with and without use of LDU during MIPN. Primary endpoints included hilar dissection time, estimated blood loss (EBL), subjective grading of bleeding, and complications. Also recorded were accessory vessels detected on Doppler survey compared with preoperative imaging (CT or MR angiography), and whether LDU findings changed operative management.

**Results:** 53 consecutive patients underwent MIPN during the study period (27 +LDU, 26 –LDU). There were no significant differences in disease or perioperative factors. Total time for hilar dissection in +LDU (time for Doppler evaluation + dissection) was significantly less than time for hilar dissection in –LDU (time for dissection only) (7.2 vs. 11.0 min,  $p < 0.05$ ). There were no intraoperative complications. Seven patients (26%) in the +LDU arm had accessory vessels discovered by LDU that were not seen on preoperative imaging; one patient had an accessory renal artery found on dissection that was seen on neither preoperative imaging nor LDU examination. Doppler revealed persistent parenchymal flow after arterial clamping in 3 additional cases, allowing for successful re-clamping.

**Conclusion:** LDU objectively improved time for hilar dissection in this prospective randomized comparison. Improved sensitivity for hilar vessel detection compared with preoperative imaging as well

as change in operative management based on findings were demonstrated. This is evidence of the objective benefit of LDU for hilar dissection during MIPN.

#### **VP11-07 EARLY DETECTION OF LOCAL AND NODAL RECURRENCES FOLLOWING RADICAL PROSTATECTOMY BY USING THE INTEGRATED 18 F-CHOLINE PET-CT**

G. Simone, R. Papalia, S. Guaglianone, M. Ferriero, E. Forastiere, M. Gallucci

**Background:** To evaluate the accuracy of integrated 18 F-Choline PET-CT in detecting recurrences following radical prostatectomy.

**Methods:** Ninety-six consecutive patients previously undergone radical prostatectomy were enrolled. Twenty-two patients were treated with androgen deprivation therapy (ADT) (LH-RH analogue + antiandrogen) at the time of the PET-CT. Positive exams were confirmed by biopsy, by lymphadenectomy or by the decrease of PSA levels following radiation therapy. Median PSA value in the whole cohort was 1.3 ng/mL (range 0.005–9.36). The sensitivity was evaluated in the two cohort of patients (treated with ADT or not treated) and for each cohort a subanalysis was performed after stratifying patients on PSA levels (PSA <1, PSA between 1 and 2 ng/mL, PSA between 2 and 5 ng/mL and PSA >5 ng/mL).

**Results:** PET-CT findings were positive in 65 patients (67.7%). Median PSA level in the 65 patients with positive PET-CT was 1.43 ng/mL (range 0.1–9.36). The sensitivity in the whole cohort was 84.5%, the specificity was 69.2%, the positive predictive value was 92.3% and the negative predictive value was 47.6%. The sensitivity in the subgroup of patients without androgen deprivation therapy was 81.8%, and when stratified for PSA levels it was 57.8% for PSA ≤ 1 ng/ml (Range: 0.005–0.99; Median: 0.44), 88.8% for PSA between 1 and 2 ng/ml (Range: 1–1.93; Median: 1.35), 100% for PSA between 2 and 5 ng/ml (Range: 2.4–4.24, Median: 2.8) and 100% for PSA > 5 (Range: 6–8.27; Median: 6.65). In the subgroup of patients receiving ADT at the time of PET-CT the sensitivity was 93.8%. When analyzed for different PSA levels the sensitivity was 75% for PSA ≤ 1 (Range PSA: 0.24–0.96; Median: 0.445), 100% for PSA levels between 1 and 2 ng/ml (Range PSA: 1.3–1.8; Median: 1.54), 83% for PSA levels between 2 and 5 ng/ml (Range PSA: 2.36–4.76; Median: 3.095) and 100% for PSA > 5 ng/ml (Range PSA: 6.89–9.36; Median: 8.68).

**Conclusion:** The integrated 18 F-Choline PET-CT significantly improves the detection of local and distant recurrences in patients with PSA increasing levels following radical prostatectomy. The promising results of the integrated 18 F-Choline PET-CT could play a role in a new definition of “biochemical recurrences” and could be helpful in guiding treatment of recurrences and delaying ADT.

#### **VP11-08 UPDATE ON PSA-NADIR PREDICTING TREATMENT FAILURE AFTER HIGH-INTENSITY FOCUSED ULTRASOUND (HIFU) OF LOCALIZED PROSTATE CANCER—APPLICATION OF THE STUTTGART FAILURE CRITERIA**

R. Ganzer, H. Fritsche, W. Wieland, A. Blana

**Background:** The PSA-nadir was shown to be an independent predictor of treatment failure and disease-free survival rates (DFSR) after HIFU therapy for localized prostate cancer (PC) as defined by the Phoenix ASTRO criteria. We present an updated analysis after application of the recently published HIFU failure “Stuttgart criteria” (PSA-nadir + 1.2 ng/ml).

**Methods:** 159 patients after HIFU treatment (Ablatherm, EDAP TMS, France) for localised PC with the following inclusion criteria

were evaluated retrospectively: cT1/ T2, PSA ≤ 20 ng/ml, Gleason score ≤ 7, no previous hormonal therapy, regular follow-up visits every 3 months. Treatment failure was defined by the Stuttgart criteria. Three PSA-nadir groups were defined: group 1: ≤ 0.2 ng/ml, group 2: 0.21–1 ng/ml, group 3: > 1 ng/ml. DFSR were calculated using life table methods. The log rank test was used to compare the curves based on Kaplan–Meier models.

**Results:** The median follow-up was 6.1 (3–11.5) years. Mean time to PSA-nadir was 5.1 ± 2.8 months. A PSA-nadir of ≤ 0.2 ng/ml, 0.21–1 ng/ml and > 1 ng/ml was reached by 67.3%, 23.3% and 9.4% of patients, respectively. Treatment failure rates during follow-up were 8.7%, 45.9% and 71.4%, respectively for the 3 groups (p < 0.001). The actuarial DFSR at 5 years were 94%, 57% and 16% for the 3 groups (p < 0.001).

**Conclusion:** The PSA-nadir after HIFU correlates highly significantly with treatment failure and DFSR. Excellent oncological outcome is obtained if a PSA-nadir of ≤ 0.2 ng/ml is reached. The analysis is based on the HIFU-specific “Stuttgart failure criteria” which have been recently published.

#### **VP11-09 COMBINED USING OF LAPAROSCOPIC AND FLOROSCOPING IMAGING TO PERFORM NEPHROLITHOTOMY IN A PATIENT WHO HAS RETRORENAL COLON; A NEW TECHNIC**

F. Demirel, F. Yalcinkaya, M. Cakam, B. Kara, U. Altug

**Background:** Percutan nephrolithotomy carries risk of colon perforation in the presence of retrorenal colon. Although ultrasonography or computerised tomography guided first puncture in a separate stage is widely used to decrease this risk, colon perforation rates never reaches zero. In this video, percutaneous puncture of the appropriate calices under direct vision of retroperitonscopic guidance and percutaneous nephrolithotomy in one stage operation is presented.

**Methods:** 33 year old female patient, with primary right upper and lower pole calices stones (total stone volume 3.07 cm<sup>3</sup>). Her body mass index was 25.6. Spiral computerised tomography showed retrorenal colon. In the beginning of the operation, abdominal organs were freed from the renal area with retroperitonscopic procedure in flank position.

**Results:** Retroperitonscopic stage was performed in 15 minutes. After that, in prone position, percutaneous puncture to the appropriate calices group was performed safely under retroperitonscopic and floroscopic guidance simultaneously. Following this puncture, standart nephrolithotomy procedure was performed. In the post-operative period there was no complication.

**Conclusion:** In this case report, in one patient with retrorenal colon, percutaneous access under retroperitonscopic and floroscopic guidance, and nephrolithotomy in one stage operation is presented. There were no complication due to retroperitonscopic or nephrolithotomy procedures. Retroperitonscopic stage took only 15 minutes and whole operation finished in one stage and it seemed an advantage. We think, such combined procedures can be performed safely in selected cases.

#### **VP11-10 RISK OF TRACT RECURRENCES FOLLOWING PERCUTANEOUS RESECTION FOR UPPER TRACT UROTHELIAL CARCINOMA: CLINICAL, PATHOLOGIC AND RADIOLOGIC EVALUATION**

B. Irwin, A. Berger, R. Brandina, R. Stein, S. Shah, M. Desai—USA

**Background:** Historically, urothelial carcinoma (UC) has been associated with wound and port-site recurrences following open and laparoscopic surgical interventions. The risk of percutaneous tract seeding after resection, though a theoretic possibility, is largely unquantified. We report data on pathologic examination of excised percutaneous tracts in patients undergoing nephroureterectomy as well as clinical and radiographic evaluation following prior percutaneous intervention.

**Methods:** All charts were reviewed from 421 patients undergoing nephroureterectomy for upper tract UC at a single institution since 1992. Four patients who had nephrostomy tubes placed prior to nephroureterectomy for either obstruction or following percutaneous resection were identified. Pathologic examination of the excised tracts was performed by the department of pathology looking for evidence of tumor. Radiographic follow-up with CT scan imaging was available in 22 of 39 patients undergoing percutaneous resections for upper tract UC. All were reviewed for evidence of tract recurrences. Evidence of clinical tract recurrences was also recorded.

**Results:** The nephrostomy tubes in the tract excision group were in place for a median of 6.5 months prior to nephroureterectomy. All patients had grade 3 lesions and ranged in pathologic stage from pT1 to pT3. All excised tracts showed evidence of fibrosis and chronic inflammation with one also showing focal giant cell reaction to foreign material. No evidence of tumor was seen in any of the tract specimens. While no patient showed clinical evidence of tract recurrence, radiographic review revealed one patient who almost certainly had tract seeding with mass formation in the perinephric tissue in the region of the tract. This patient was found to have node positive disease at the time of planned nephroureterectomy and tract excision. A second patient was identified with local recurrence in the area of a prior tract following subsequent ipsilateral nephroureterectomy; he ultimately succumbed to the disease.

**Conclusion:** The number of patients who undergo percutaneous resection and subsequent nephroureterectomy with nephrostomy tube site excision is low, even at large volume centers. There does not appear to be routine pathologic evidence of tumor cells within these tracts which might represent a source for tract site recurrences. Given the lack of presence of tumor cells in these tracts, as well as the paucity of reports in the literature, percutaneous resection for upper tract UC appears to be associated with a low, but not insignificant, risk of tract seeding. When present, axial imaging can help to identify potential recurrences.

#### VP11-11 INITIAL EXPERIENCE WITH THE FREEHAND TM ROBOTIC CAMERA HOLDER IN LAPAROSCOPIC UROLOGY

D. Sharma, C. Brown, C. Kouriefs, H. Sood, P. Grange, H. Patel—UK

**Background:** Freehand TM is a second generation robotic camera holder which has recently become available to laparoscopic surgeons. We report our experience following 24 consecutive cases.

**Methods:** From April 2009 to June 2009, Freehand TM was used to perform 12 radical prostatectomies, 10 laparoscopic renal operations—nephrectomy—partial and radical, and renal cryotherapy and 2 laparoscopic radical cystectomies. 5 surgeons were involved in the study. The time to set-up, ergonomics, image quality, user-friendliness and cost were assessed.

**Results:** Mean set-up time was 4 minutes (2–10). All surgeons found that a rock steady clear image was achieved. Freehand TM was easy to use, made for more comfortable operating, and avoided regular clashes with assistants. 8 out of 10 renal operations have been performed as a solo surgeon and in the others the active role of a trained assistant is significantly reduced.

**Conclusion:** The Freehand TM robotic camera holder has proved itself to be a very welcome addition to our laparoscopic armamentarium. It is easy to set up, user friendly, and has so far proved to be durable.

#### VP11-12 STANDARDIZED LINEAR PORT PLACEMENT FOR LAPAROSCOPIC UROLOGIC SURGERY: EXPERIENCE WITH 1264 CASES

J. Harper, J. Leppert, A. Breda, P. Schulam

**Background:** Traditional laparoscopic port placement for renal and adrenal surgery involves camera access via the umbilicus with working ports placed on either side of the camera at various locations for different surgeries. This diamond port configuration requires the camera operator to cross hands with the primary surgeon. A standardized linear port configuration has been used for nearly all transperitoneal urologic retroperitoneal surgery at our institution since 2000. The objective of this paper is to describe our experience with this simplified approach and its advantages.

**Methods:** A retrospective review was conducted of all laparoscopic cases conducted by a single surgeon between 2000 and mid-2009. The linear port configuration includes three ports placed along the ipsilateral pararectal line with the most superior port one fingerbreadth below the inferior costal margin and the inferior port at the level of the umbilicus. A 5 mm camera is utilized exclusively through the most superior port. An additional port is placed off the 11th or 12th rib for lateral retraction. Typically four 5 mm ports are used with modification if needed. If an extraction site is needed, a low transverse incision is typically used through which a 15 mm port for a stapling device or endoscopic bag can be placed.

**Results:** 1264 laparoscopic cases were performed using the linear port configuration. Of these, there were 186 radical and simple nephrectomies, 852 donor nephrectomies, 60 partial nephrectomies, 35 nephroureterectomies, 49 adrenalectomies, 50 pyeloplasties, 20 renal cryoablations, and 12 miscellaneous renal procedures. 98.4% were performed successfully via this port configuration. There were 20 (1.6%) open conversions: 16 were elective and four secondary to complications.

**Conclusion:** Standardization of port placement via a linear configuration for both right and left renal and adrenal surgery is feasible, easy to learn, simplifies strategic planning preoperatively and provides excellent exposure. Utilizing camera access through the superior port allows for direct visualization and minimizes interaction between the camera holder and the surgeon's working envelope.

#### VP11-13 RADIOFREQUENCY ASSISTED LAPAROSCOPIC PARTIAL NEPHRECTOMY: A NOVEL ALTERNATIVE IN TREATMENT OF SMALL RENAL MASSES

J. Diaz, I. Pinto, A. Hornig, C. Sandoval—Chile

**Background:** Actually, radical nephrectomy is the gold standard therapy for renal tumors. Technical advances and accumulated experience have done laparoscopic partial nephrectomy a viable option in the treatment of small renal masses (<4 cm), because of

its oncologic effectiveness and the association between radical nephrectomy and chronic renal failure and cardiovascular morbidity associated. Ablative therapies arise like a valid alternative in the treatment of small renal masses, between these radiofrequency. Recent reports suggest that ablative therapies do not offer an adequate oncological control and that current imagenology can't carry out follow-ups of sure form.

**Methods:** We present a case series of 13 patients diagnosed of 16 small renal masses, treated by laparoscopic partial nephrectomy with radiofrequency assistance between April 2008 and June 2009. Procedure was realized by a transperitoneal approach in eleven patients and by retroperitoneal approach in two. Radiofrequency was administrated by percutaneous way under visual laparoscopic control and partial nephrectomy realized without needing of renal vascular clamping.

**Results:** Average surgical time was 93 minutes (45–135). There was no important bleeding during surgery and no surgical complications associated. Thirteen of total sixteen tumors corresponded to renal cell carcinomas, one to angiomyolipoma and the last one to oncocytoma. All surgical margins were informed as negatives and at present, all the patients have no evidence of disease with a follow-up average time of 8 months (1–15 months).

**Conclusion:** Radiofrequency can be an excellent tool assisting laparoscopic partial nephrectomy. It allows surgery without need of clamping renal vein and artery avoiding warm ischemia and with no bleeding.

#### VP11-14 EVALUATION OF A NOVEL DISSECTING SUCTION IRRIGATOR INSTRUMENT

D. Pick, J. Lee, M. Louie, E. Mcdougall, R. Clayman, J. Landman—CA

**Background:** The laparoscopic suction irrigator is used by many surgeons as a blunt dissection or retraction tool. Laparoscopic Kittners are preferred by many surgeons for blunt dissection, as the gauze tip provides effective dissection, and is relatively atraumatic. We present a novel combination suction irrigator/kittner (Dissector) and compare it to a standard suction irrigator.

**Methods:** Seven surgeons evaluated three suction irrigators. One was a standard Stryker laparoscopic suction irrigator. The other two were modified Stryker irrigators with Kittner ends (one with and one without a small hole in the tip). One of these still had the standard side holes in the irrigator intact. Flow rates were determined using saline, and the three devices were evaluated for aspiration, dissection, hemostasis, and device properties, using a 10 point analog scale.

**Results:** Flow for the standard, modified and modified with side holes suction irrigator was 13.5, 4.4 and 6.0 ml/sec. Both modified suction irrigators were evaluated as slightly better than the standard suction irrigator in hilar dissection and hemostasis. The modified instruments were not as effective at aspirating blood clots and clogged more easily. The suction kittner without side holes received the highest evaluation point total. Table 1 presents the evaluation data. Device Aspiration Dissection Hemostasis Irrigation Ease of clogging/cleaning Total Standard Suction Irrigator 7.86 ± 0.736.90 ± 0.977.47 ± 1.818.20 ± 1.118.35 ± 2.877.76 ± 1.68 Suction Kittner 8.24 ± 1.819.05 ± 1.158.89 ± 0.667.40 ± 1.907.29 ± 2.658.18 ± 1.91 Suction Kittner with side holes 8.00 ± 1.389.05 ± 1.158.89 ± 0.665.15 ± 1.637.29 ± 3.037.68 ± 2.27

**Conclusion:** The combination suction irrigator kittners performed well during laboratory testing. Further clinical evaluation is warranted.

#### VP11-15 APPLICATION OF RADIOFREQUENCY INTERSTITIAL TUMOR ABLATION(RITA) IN “NO CLAMP—NO SUTURE” LAPAROSCOPIC PARTIAL NEPHRECTOMY

R. Papalia, G. Simone, M. Ferriero, S. Guaglianone, E. Forastiere, M. Gallucci

**Background:** Technical challenges of laparoscopic partial nephrectomy (LPN) are bleeding control and warm ischemia time threshold. We report a first experience with the use of RITA as hemostatic device in LPN as alternative to vessels clamp and to parenchymal suture.

**Methods:** One patient, with exophytic renal lesions (2.5 cm), underwent LPN without hilar clamping. The RITA device was used to obtain hemostasis of tumor burdens before performing tumor excision. Taking into account the intraparenchymal depth of tumor the Habib 4× laparoscopic radiofrequency ablation device was applied all around the tumor in order to have a complete hemostatic control of tumor burdens. Thus an avascular cleavage plane was created before performing tumor excision. The renal tumor was then sharply excised using monopolar scissors and the hemostasis of renal stump was completed with the use of a Tachosil.

**Results:** Operative time was 45 minutes, blood loss was 90 cc, and no blood transfusion was necessary. Pathologic analysis of specimen found a clear cell renal carcinoma. Intraoperative evaluation of tumor margins on the specimen was negative. The use of the Habib 4× RITA device did not interfere with margins evaluation.

**Conclusion:** The use of RITA provides effective hemostasis and allows to perform LPN without performing hilar clamp and thus without the risks of warm ischemia. Laparoscopic Habib 4× RITA simplifies technical challenges of LPN and can be used at the beginning of learning curve.

#### VP11-16 A NOVEL TECHNIQUE FOR LARGE, MULTIPLE URETERIC STONE: ANTEGRADE FLUSH & RETROGRADE URS

T. Haresh

**Background:** Large and multiple ureteric stone is still management dilemma especially in upper ureter and impacted. Due to stone belt region with poor socioeconomic condition we get so many large burden ureteric stone with renal insufficiency making its management tough. So using various techniques we developed our new technique for such type of urolithiasis management. Here we present our novel technique for management of upper ureteric stone.

**Methods:** We present this technique for endourological management for large burden ureteric stone in 12 cases. We do Percutaneous nephrostomy preplanned and through we do antegrade irrigation while doing retrograde URS and fragmenting stone with lithoclast. Advantage of antegrade irrigation is stone fragments do not migrate.

**Results:** We performed this technique in 12 patients who had large, multiple ureteric stone of 1.3 cm to 3 cm and one stone to more than 30 stones. All stones could be cleared completely except one who required auxiliary procedure. Four patients required two staged procedure. Three patients had postoperative fever. Non had any major complications. Out of 12 patients 8 had renal insufficiency so PCN could help in improving Renal function.



**Conclusion:** This Novel technique—Antegrade flush-Retrograde URS is effective, safe, cost effective modality for management for large burden ureteric stone.

### VP11-17 LAPAROSCOPIC COLD KNIFE: A NEW INSTRUMENT FOR URETERAL INCISION

S. Guven, M. Kilinc, D. Yuksel, L. Tunc, S. Basal, Y. Ozgok

**Background:** During the interventions for laparoscopic pyeloplasty and ureterolithotomy laparoscopic scissors or blades are used; however, the incisions made using these tools may sometimes lead to difficulties for the surgeons. We developed an efficient, safe, reusable, and inexpensive instrument to cut the urethra and pelvis during laparoscopic ureterolithotomy and pyeloplasty.

**Methods:** The internal urethrotomy is a classic with a cold knife, transformed into an endoscopic instrument that can be inserted easily through a 5 mm diameter trocar. The cold knife has a manual retraction system enabling a stand by position during the times when no incisions are made and thus ensures security.

**Results:** We used this cold knife in laparoscopic pyeloplasty and ureterolithotomy. Using a 3-port retroperitoneal access, cutting the ureteropelvic junction and ureter were easy. There were no complications during the procedures.

**Conclusion:** The use of the laparoscopic cold knife, during laparoscopic pyeloplasty and ureterolithotomy interventions requiring ureteral incision, is a simple, safe, reusable, and inexpensive instrument with a low maintenance cost.

### VP11-18 REPEATED TRANSURETHRAL RESECTION AND INTRAVESICAL BCG FOR EXTENSIVE SUPERFICIAL TRANSITIONAL CELL CARCINOMA OF THE BLADDER: A REPORT OF 106 CASES

S. Sallami, S. Ben rhouma, H. Mohamed, Y. Nouria, A. Horchani

**Background:** We assessed the outcomes of repeated transurethral resection plus intravesical BCG in patients with diagnosed pT1 transitional cell carcinoma of the bladder larger than 5 cm in terms of recurrence, progression and overall survival.

**Methods:** 268 patients with Ta-T1 bladder cancer larger than 5 cm were diagnosed between January 1995 and December 2004. A total of 106 patients underwent at least multiple TURB and received adjuvant BCG intravesically. Patients with incomplete resection, muscle invasive disease were excluded from this study. They were 89 men and 17 women with a mean age of 57.3 years (37–81).

**Results:** The mean follow-up was 61.53 months (range 13 to 168). The recurrence rate was 60.3%, 51.8% at 1, 5 year respectively. The progression rate was 10.3%, 14.1% 1, 5 year respectively. Recurrence/Progression was observed in 56%/11, 33%; 60.4%/8.33% and 71.4%/14.2% of patients with G1, G2 and G3 tumors respectively at 1 year. Recurrence/Progression was observed in 15.9%/50%; 14.5%/54.1% and 7%/50% of patients with G1, G2 and G3 tumors respectively at 5 years. The Recurrence Free Survival rate was significantly worse in the high grade group (G2 and G3). The rate of recurrence-free survival was 98.5%, 89.67% for the first and fifth year.

**Conclusion:** TUR with intravesical maintenance BCG therapy provides a significantly better good result in reducing the incidence of recurrence and progression. Urologists can discuss this therapeutic option with patients in an effort to preserve the bladder.

### VP11-19 CRITERIA TO PREDICT SUCCESSFUL STONE TREATMENT UTILIZING A DISPOSABLE FLEXIBLE URETEROSCOPE

P. Lowry—Texas

**Background:** The expensive cost of maintenance for flexible ureteroscopes leads to strategies which will decrease damage to flexible ureteroscopes. We have previously examined shown the effectiveness of a novel disposable flexible ureteroscope in certain situations. The goal of this study was develop criteria which would result in successful surgery using only the disposable flexible ureteroscope. By avoiding usage of traditional flexible ureteroscopes, we hope to prevent the resultant deterioration of the effective, yet expensive and fragile traditional flexible ureteroscopes.

**Methods:** Seven patients were screened for surgery by the following criteria: 1) Solitary renal stone less than or equal to 7 mm in the upper or mid pole. 2) Solitary ureteral stone less than or equal to 7 mm in the upper or mid ureter, only if a rigid ureteroscope was unable to access the stone. 3) Less than 5 small renal stones (less than or equal to 5 mm) in the upper or mid pole. 4) Lower pole stones were excluded. 5) Anatomic variations that may cause prevent successful surgery were excluded, such as significant hydronephrosis, calyceal diverticulum, etc. All surgery were performed with the Semiflex ureteroscope made by Maxiflex LLC.

**Results:** One patient had a previously unknown pinpoint ureteral stricture, preventing ureteroscopy. The remaining 6 patients were successfully treated using only the disposable flexible ureteroscope and either laser lithotripsy and/or basket extraction. In 2 cases with 6–7 mm stones requiring laser lithotripsy, traditional flexible ureteroscopy was utilized to confirm that all stone fragments had been removed.

**Conclusion:** Using these criteria, patients may be successfully treated using only the disposable flexible ureteroscope. We believe that judicious usage of this ureteroscope may help decrease damage and deterioration of traditional flexible ureteroscopes, which may be reserved for more complex ureteroscopic cases. As our experience and comfort with the disposable flexible ureteroscope increases, inclusion criteria for usage of this scope may expand.

### VP11-20 COMPUTATIONAL FLUID DYNAMICS MODELS OF URINE FLOW THROUGH URETEROPELVIC JUNCTION (UPJ) OBSTRUCTIONS

J. Sumfest

**Background:** UPJO is the most common cause of newborn urinart tract obstruction. Despite this, very little study has been done of the mechanics of the obstruction. We studied ureteral flow dynamics using a computational fluid model developed with COMSOL<sup>®</sup>, a commercial software package. Fluid dynamics of a normal ureter were compared to those associated with a ureteropelvic junction (UPJO) obstruction. Our model evaluates urodynamics flow across the UPJ through several simple, idealized geometries and through more realistic geometries reconstructed from clinical images of UPJ obstructions. In principle, the flow of urine in the ureter is a straightforward engineering problem—flow of water through a tube. Urine has fluid properties that differ from those of water by only a few percent with an even smaller variability between individuals. Our initial representation of the ureter is as a straight, rigid cylindrical tube with uniform diameter. The next level of model considers an idealized geometry in which the diameter is constricted for a short interval representing a UPJ obstruction. The last

of model was when the geometry of the ureter and UPJ obstruction are extracted from clinical images.

**Methods:** The simplest geometry under consideration is a straight cylinder of constant diameter (Figure 1). The only parameters needed to define this geometry are the diameter  $D$  and length  $L$ . Since there is no angular variation in the resulting flow, the model is implemented as a 2-dimensional, axisymmetrical case where the velocity and pressure are found as functions of radial position  $r$  and axial position  $z$ . Next models of an idealized constriction were based on this cylindrical model. To create more anatomically-realistic models, three medical images of UPJOs as well as normal ureter were obtained. These images were converted into grayscale 'tiff' files. The geometrical data was then used in COMSOL to create axisymmetrical, two-dimensional and fully three-dimensional models. Flow in the ureter is assumed to be steady with respect to time. Actual flows may be transient due to peristalsis, but the present model is suitable for determining the time averaged flow. The pressure drop along the length of the ureter was readily calculated from Poiseuille's Law.

**Results:** The minimum diameter is clearly the controlling factor in the pressure drop. The fourth power dependence of the pressure drop on the diameter as demonstrated in Poiseuille's law explains these results. A short narrow section of ureter will produce more pressure drop than much longer sections of intermediate diameter. In anatomic studies, as with the idealized constrictions, the areas with the smallest diameter in the model have the highest velocities. In addition, in the model of an obstructed ureter shows regions of nearly stagnant or recirculating flow under high flow conditions.

The image-based models show pressure drop characteristics similar to those seen for the idealized geometries. The pressure drop in the ureter is dominated by the narrowest sections rather than the average or maximum diameters. Each of these models confirms that the pressure drops rapidly in the narrowest sections of the ureter, but remains nearly constant in the larger sections.

**Conclusion:** Our results demonstrate several common features of urinary flow in obstructed ureters. In all cases the flow must accelerate to pass through the constriction. In doing so the shear rate in the fluid increases dramatically leading to rapid pressure drop through the constriction. The pressure drop in the ureter as a whole is dominated by the narrowest segments, even if these segments represent only a small fraction of the total length of the ureter. Since the flow in the ureter is laminar, Poiseuille's is useful for relating the pressure drop, flowrate, length, and diameter of the ureter. Since the change in pressure across the obstruction is inversely proportional to the diameter of the narrowed area to the fourth power, it is the point of maximal anatomic obstruction of the ureter that becomes the primary factor in determining fluid dynamics of all ureteral obstructions. The image-based models included in the study demonstrate that the fine details of the geometry in the ureter do not seem to make much difference in the flow patterns or pressure drop. Only the narrowest segment influences the pressure drop and only the most rapid expansions seem to induce recirculation. This lends validity to the use of idealized models that capture the essential features of the anatomical geometry.

## VP12: LAPAROSCOPY PROSTATE-2

### VP12-01 A PROSPECTIVE, NON-RANDOMIZED SINGLE-SURGEON STUDY TRIAL COMPARING EXTRAPERITONEAL LAPAROSCOPIC INTRAFASCIAL NERVE-SPARING VERSUS OPEN RETROPUBIC INTRAFASCIAL NERVE-SPARING RADICAL PROSTATECTOMY: SURGICAL TRAUMA AND FUNCTIONAL OUTCOMES

F. Greco, S. Wagner, O. Reichelt, M. Hoda, A. Hamza, P. Fornara

**Background:** We report our experience with 300 consecutive patients who underwent a radical bilateral nerve sparing prostatectomy (nsRP) with intrafascial technique for clinically localized prostate cancer.

**Methods:** Between January 2005 and November 2007, 150 ns laparoscopic (nsLRP) and 150 ns retropubic prostatectomy (nsRRP) were performed at our clinic. Oncologic and functional outcomes were compared. In addition, systemic response to surgical trauma was measured in all patients by assessing the levels of acute-phase markers: C-reactive protein, serum amyloid A, interleukin-6, and interleukin-10 in different operative times.

**Results:** There were no statistically significant differences between the groups in mean Gleason score after radical nerve-sparing prostatectomy (5.7 and 6.4 for nsLRP and nsRRP, respectively) and similar distribution of pathological stages (pT2a). Although the laparoscopic group had a lower frequency of positive margins, the difference was not statistically significant. Twelve months

postoperatively, complete continence was reported in 97% of patients who underwent an nsLRP and in 91% of patients in the nsRRP group ( $P < 0.05$ ). At that time, 63% of patients in the nsLRP group, and 52% in the nsRRP group reported the ability to engage in sexual intercourse ( $P < 0.05$ ). No statistical differences were registered concerning the surgical trauma in both groups.

**Conclusion:** Laparoscopic nerve-sparing technique performed by expert surgeons results in functional outcomes of continence and potency superior to those of open nerve-sparing retropubic surgery. Concerning the surgical trauma, there is no significant difference between the two surgical techniques in the treatment of clinically localized prostate cancer.

### VP12-02 HIGH RISK PROSTATE CANCER IN LAPAROSCOPICALLY TREATED LOCALIZED PROSTATE CARCINOMA

R. Sanchez-salas, F. Bianco Jr, X. Cathelineau, F. Rozet, E. Barret, G. Vallancien—France

**Background:** Preoperative presence of high risk disease characteristics has an impact in cancer outcomes for radical prostatectomy. Standardized criteria might define high risk in clinically localized prostate cancer before definitive treatment. Of patients undergoing laparoscopic radical prostatectomy we identified those

at high risk and examined pathological characteristics and outcomes.

**Methods:** The analysis included 3260 men treated with laparoscopic radical prostatectomy alone between January 1998 and June 2008 with either trans- or extraperitoneal approach. Out of these, patients harbored high risk disease defined as: T3 tumor (71), Gleason score  $\geq 8$  (147), Preoperative PSA  $> 20$  ng/ml (147) and D'Amico high risk definition (354). Estimates of prostate specific antigen relapse for patients at high risk were generated with the Kaplan-Meier method. High risk group was defined Cox proportional hazards regression was used to estimate the HR for recurrence in high risk vs nonhigh risk cohorts.

**Results:** Depending on the definition used patients at high risk composed 2% to 11% of the study population. Sixty eight percent of T3 tumors were pathologically confirmed. The pathological stage was verified as T3 tumors in 41% and 55% of patients with PSA  $\geq 20$  and Gleason score  $\geq 8$ , respectively. When considering D'Amico definition, 48% of patients were confirmed pathologically as T3 tumors. Surgical margins were positive ranged from 23% to 31% for all high risk tumors definitions. Nerve sparing was performed in 54% to 65% of identified high risk patients. Survival at five years was verified as 55%, 51%, 44% and 30% for patients with clinical stage T3, PSA  $\geq 20$ , D'Amico definition and Gleason  $\geq 8$ .

**Conclusion:** Accurate selection of high risk patients has an impact in cancer outcomes for radical prostatectomy. Although definitions are not uniform in predicting prognosis, the presence of a high Gleason score might be associated with poor outcomes.

### VP12-03 INTRAFASCIAL NERVE SPARING ROBOT-ASSISTED LAPAROSCOPIC RADICAL PROSTATECTOMY: OUR INITIAL EXPERIENCE

F. Porpiglia, C. Fiori, M. Lucci Chiarissi, M. Manfredi, S. Grande, R. Scarpa

**Background:** The aim of this study is to report our experience with robot-assisted laparoscopic radical prostatectomy (RALP) with intrafascial nerve sparing technique (INS).

**Methods:** From July 2008 to March 2009 we performed the first 29 RALP with INS, doubling the technique achieved after more than 70 laparoscopic radical prostatectomy with INS. Mean age of the patients was 64.1 (53–73) years with a mean body mass index of 25.72 (20.7–31) kg/m<sup>2</sup>. Mean preoperative PSA and IIEF-5 were respectively 7.29 (1.8–13.3) ng/ml and 24.45 (23–25).

**Results:** Mean operation time was 141.31 (90–230) minutes, mean blood losses were 346.55 (100–1500) ml and complications (Dindo Grade I or II) occurred in 3 patients (10.34%). Positive surgical margins were found in 2 patients with pT2 stage (22.22%) and in 6 patients with pT3 stage (66.66%). No patients underwent lymph-node dissection. Mean post operative hospital stay was 6.72 (10–3) days with a mean catheterism time of 7.48 (7–17) days. Mean follow up was 6.35 (3–11) months. At three months the potency rate with or without administration of PDE 5 inhibitors was 65.52% and the mean IIEF-5 score was 18.8 (9–24). As regards continence, 55.17% of patients was continent immediately after catheter removal, 79.31% after a month and 86.21% after 3 months.

**Conclusion:** RALP with INS technique is an effective procedure leading promising and encouraging functional and oncologic results.

### VP12-04 EXTRAPERITONEOSCOPIC INTRAFASCIAL NERVE SPARING PROSTATECTOMY: ONCOLOGIC AND FUNCTIONAL OUTCOMES

F. Porpiglia, C. Fiori, M. Manfredi, M. Lucci Chiarissi, S. Grande, R. Scarpa

**Background:** The aim of this study is to present our experience with extraperitoneoscopic radical intrafascial prostatectomy (ERIP).

**Methods:** From October 2006 to February 2009, 70 patients with clinically localized prostate cancer (PC) underwent ERIP. After catheter removal an oral therapy was administered with 5PDE inhibitors (5PDE-I) 2 times per week for one month. Follow up visits are scheduled at 1, 3, 6 and 12 months. Continence, potency and disease free survival were evaluated with validated questionnaires (IIEF5 and ICS) and PSA.

**Results:** Mean patient age was 64 years, BMI was 26.6, PSA was 6.59 ng/ml and IIEF5 score 23. Gleason Score (GS) and number of positive cores at biopsies with a 12 cores scheme were respectively 6, 1 and 2, 14. We recorded 21 (30%) cases of focal positive surgical margins, one patient underwent radiotherapy on the basis of pathological analyses. Positive surgical margins rate was higher in patients with  $> 2$  positive cores at biopsies. After a mean follow up of 18.2 months (3–31), one patient with biochemical relapse was recorded. Patients reported spontaneous or 5PDE-I assisted sexual intercourses in 75.7%. Mean IIEF5 value was 16.9 score (0–23). Moreover the rate of patients dry (0 pad or 1 pad/die for safety) was 28.6% after the catheter removal, 77.4% within 3 months and 84% within 6 months.

**Conclusion:** In our experience ERIP is a challenge but safe and effective procedure and it allows good functional results. Surgeon must be careful in patient selection in order to reduce oncological failure.

### VP12-05 LAPAROSCOPIC RADICAL PROSTATECTOMY (REPORTED OF 110 CASES)

Y. Changjun

**Background:** We present our experience of 110 cases of laparoscopic prostatectomy including 85 cases through extraperitoneal approach and 25 cases through transperitoneal approach. We study the technique and evaluate its efficiency.

**Methods:** A total of 110 patients diagnosed with localized prostate carcinoma were admitted from February 2003 to May 2009. The level of serum PSA range from 7.5–47 ng/ml (mean 14 ng/ml). The volume of the prostate range from 35–75 ml (mean 52 ml). Biopsy was performed before the operation and the pathological results revealed prostate carcinoma with Gleason score no more than 8. CT, MR and ECT revealed no lymph node involved or bone metastasis. All the patients were given general anesthesia and 5 ports in low abdomen were applied for the operation. The procedures were performed with antegrade techniques and pelvic lymphadenectomy was performed in 32 cases and nerve-sparing techniques was performed in 11 cases.

**Results:** The operation duration range from 105–270 minutes (mean 173 minutes). Intraoperative blood loss was 110–1200 ml (mean 315 ml). Incontinence occurred in 19 cases in early stage and 18 cases recovery to normal within 3 months. Positive margin occurred in 28 cases. There were no complication of urethra stricture duration 3–30 months of follow-up. No lymph nodes were involved in 32 cases with pelvic lymphadenectomy. 5 in 11 cases

received nerve-sparing prostatectomy had normal erectile function during follow-up.

**Conclusion:** Laparoscopic radical prostatectomy was a safe, effective and efficient surgical procedure the minimal invasion, less morbidity and rapid recovery. Laparoscopic radical prostatectomy is emerging as an alternative to open radical prostatectomy.

### VP12-06 ANATOMICAL RECONSTRUCTION OF THE CONTINENCE MECHANISM FOLLOWING LAPAROSCOPIC RADICAL PROSTATECTOMY

A. Ghazi, R. Zimmermann, A. Schfler, G. Janetschek—Austria

**Background:** The incidence rates of urinary incontinence following radical prostatectomy (RP) are still a matter of concern. Urinary incontinence has a major impact on the quality of following surgical treatment of prostate cancer. Various surgical techniques and modifications have been put forward to minimize the incidence of urinary incontinence following radical prostatectomy; however published data is variable. We introduce our new technique as well as early results of an anatomical reconstruction of the continence mechanism following laparoscopic RP that has shown to achieve early continence.

**Methods:** Anatomical reconstruction of the continence mechanism consists of; Posterior reconstruction by restoring the continuity of the severed Denonvillier's fascia between the bladder neck and the urethral stump using a single interrupted suture, the vesico-urethral anastomosis which is easily accomplished in a tension free manner following the posterior reconstruction and finally the anterior reconstruction by approximation of the cut surface of the puboprostate-vesical ligament & dorsal vein complex to the anterior bladder neck using a ventral single interrupted suture. 30 patients who underwent laparoscopic RP for low-risk prostate cancer are currently enrolled in the study. A questionnaire regarding number of pads used per day (range >3/day to no pads) was prospectively administered to patients preoperatively and postoperatively at 1 day, 1 month, 3 months and 6 months. Average patient age was 62 years (44–73 years).

**Results:** Average operative time for anatomical reconstruction was 34.9 minutes (25–45 minutes). All 30 patients were followed up till first day postoperative (PO), 26 to 1 month PO, 22 to 3 months PO & 15 to 6 months PO. According to the follow-up schedule; 9 (30%) & 2 (6.6%) patients used 1 & no pads /day consecutively at day 1 PO, 11 (42.3%) & 8 (30.7.9%) patients used 1 & no pads/day at PO 1 month, 14 (63.6%) & 6 (27.2%) patients used 1 & no pads/day at PO 3 months and 5 (33.3%) & 10 (66.6%) patients used 1 & no pads/day at PO 6 months.

**Conclusion:** Removal of the prostate as well as division of the structures which provide dorsal & ventral fixation of the bladder to the pelvic floor following RP has a grave impact on the continence mechanism. Our reconstruction approximates these structures, thereby partially restoring anatomy as it was before. In addition to improving early continence, the anastomosis is tension free and reinforced.

### VP12-07 EVALUATION OF EARLY CONTINENCE AFTER ENDOSCOPIC EXTRAPERITONEAL RADICAL PROSTATECTOMY

J. Stolzenburg, M. Nicolaus, M. Do, A. Dietel, E. Liatsikos

**Background:** The aim of this prospective trial is to evaluate exactly as possible the difference in early continence after “wide

excision” endoscopic extraperitoneal radical prostatectomy (EERPE) and intrafascial nerve-sparing EERPE (nsEERPE).

**Methods:** To date a total of 190 consecutive patients with localized prostate cancer were included in this study. In 100 patients (mean age: 66.3 years) the “wide excision” EERPE (group A) was performed, the other 90 patients (mean age: 66.3 years) had nsEERPE (group B). The continence status was evaluated by a pad test on the seventh postoperative day and a standardized questionnaire three months postoperatively.

**Results:** The mean operative time was 144 min (group A) versus 133 min (group B). The pad test shows an average daily urine loss of 294.5 g in group A versus 88.7 g in group B ( $P < 0.00001$ ). Mean pad usage was 6.0 pads (group A) and 3.7 pads (group B) per 24 hours. Three months postoperatively the mean number of needed pads per day was 1.1 in group A and 2.3 in group B.

**Conclusion:** Using the pad test this study has demonstrated a highly significant difference in terms of early continence between the “wide excision” EERPE and the intrafascial nerve-sparing EERPE. We propose to apply the intrafascial nerve-sparing EERPE whenever it's possible to minimise the postoperative incontinence and improve the life quality after radical prostatectomy.

### VP12-08 LAPAROSCOPIC RADICAL PROSTATECTOMY IS FEASIBLE AND EFFECTIVE IN FIT SENIOR ADULTS WITH HIGH RISK LOCALIZED PROSTATE CANCER

R. Sanchez-salas, X. Cathelineau, F. Rozet, E. Barret, M. Galiano, G. Vallancien—France

**Background:** We assessed the impact of age and comorbidity on short-term complications, continence and long-term oncologic outcome following laparoscopic radical prostatectomy.

**Methods:** 2048 consecutive men underwent laparoscopic radical prostatectomy for clinically localized prostate cancer in a single center between January 2002 and April 2006. Comorbidity was assessed using the Charlson index. Short-term post-operative complications, transfusion rate, length of hospital stay, continence and oncologic outcome were analysed by age and Charlson index classes.

**Results:** Of the 2048 men, 297 were aged  $\geq 70$  years and 281 had a charlson index  $> 0$  (diabetes 31%, chronic pulmonary disease 26%, prior other non metastatic cancer 16%, prior myocardial infarction 12%, gastric ulcerative disease 8%). Compared to younger men, senior adults showed a significantly higher pathological stage (30% pT3-4 for  $\geq 70$  years vs 21% for  $< 60$  years) and higher grade tumors (48% Gleason 7–10 for  $\geq 70$  years vs 27% for  $< 60$  years). Over a mean follow-up of 4.4 years, overall survival was excellent ( $n = 2,017/2,048$ , 98.5%). Of the 297 men aged  $\geq 70$  years, none died of prostate cancer and 5 (1.7%) died due to another cause. Short-term post-operative complications were more related to comorbidity than chronological age. Multivariate analysis with stepwise regression confirmed that the most important predictors of short-term post-operative complications were a Charlson  $\geq 2$ , a prostate weight  $> 80$  g, a body mass index (BMI)  $> 30$  kg/m<sup>2</sup> and age  $\geq 70$  yrs. Postoperative continence significantly declined with age ( $< 60$  years, 87%; 60–69 years, 78%;  $\geq 70$  years, 67.5%). Predictors of long-term incontinence were age  $\geq 70$  yrs, a BMI  $> 30$  kg/m<sup>2</sup> and need for per-operative transfusion.

**Conclusion:** Laparoscopic radical prostatectomy is feasible in fit senior adults ( $\geq 70$  years) with high risk localized prostate cancer.

### VP12-09 LAST 50 LAPAROSCOPIC RADICAL PROSTATECTOMY (OF A SERIES OF MORE THAN 400 PATIENTS) VS FIRST 50 ROBOT-ASSISTED LAPAROSCOPIC RADICAL PROSTATECTOMY: OUR RESULTS

F. Porpiglia, C. Fiori, M. Lucci Chiarissi, M. Manfredi, S. Grande, R. Scarpa

**Background:** The aim of the study is to compare perioperative and functional result of laparoscopic radical prostatectomy (LRP) and robot-assisted laparoscopic radical prostatectomy (RALP) performed by a skilled laparoscopist that starts the experience with robotic system.

**Methods:** We extracted the data from our data base of the last 50 patients of a series of 400 pts undergone LRP (Group A) from 1/2007 to 6/2008 and the first 50 patients undergone RALP (Group B) from 7/2008 to 3/2009. We considered demographic and preoperative data: age, PSA, bioptic Gleason Score (GS), ASA score, BMI. Perioperative data were: operative time, blood loss, transfusions, post operative hospital stay, time of catheterization, complications, state of surgical margins, TNM staging, GS, prostatic and tumor volume, recovery of potency and continence rate.

**Results:** As regards preoperative data the only significant difference was recorded in terms of ASA score: (2,08 in Group A vs 1,78 in Group B). Operative time was higher in group B (137 min vs 159 respectively). No differences were recorded in perioperative results but the post operative stay which was significantly shorter in group B (9,22 vs 7,12 days respectively). Continence at catheter removal was higher in group B (21.43% vs 47.92% respectively). There was a trend in faster recovery of potency in the group.

**Conclusion:** When a skilled laparoscopist starts the experience with RALP perioperative results are not impaired whilst early functional results (continence and recovery of potency) are improved.

### VP12-10 RETROGRADE NERVE-SPARING LAPAROSCOPIC RADICAL PROSTATECTOMY. TECHNIQUE THAT MIMICS OPEN SURGERY AND ITS ONCOLOGICAL RESULTS

A. Garcia Segui, E. Bercowsky u, R. Matheus, H. Yaime, R. Valero, A. Lopez—Spain

**Background:** The Nerve-sparing Laparoscopic Radical Prostatectomy (NSLRP) showed comparable oncological results with the open technique. Nevertheless, the surgical margins during the learning curve are questionable. Furthermore, the majority of the series report an anterograde approach technique. In this prospective nonrandomized study we present our first serie in NSLRP performing a retrograde technique with the similar steps done during open surgery.

**Methods:** 75 patients with prostatic adenocarcinoma T1-T2 were underwent retrograde Laparoscopic Radical Prostatectomy. The average age was 62 years (range 40–82, SD ± 8.34), median PSA 8.83 ng/dl (range 0.9–27.3). The Clinical stages were: T1c in 64%, T2a in 21%, T2b in 12%, T2 c in 1%, and one case no specified. The Gleason combined were 7 in 60%, 6 in 20%, 5 or less in 16%, 8 in 4%. Our transperitoneal 5-port technique included similar steps done during open surgery emphasizing in two areas: First, in an exhaustive dissection of the apical zone in order to get a long urethral stump and clear identification the distal segment of Neuro-Vascular Bundles (NVB) in both lateral sides of the urethra to create adequate dissection plane, and second in a high peri-prostatic fascia dissection to perform an extended nerve-sparing tech-

nique. Demographic data, perioperative information and pathological results were reported. The pathological results were analyzed in two groups divided in the first 38 cases and the rest in other group.

**Results:** The median OR time was 221 minutes (range 150–360, SD ± 68.19). The pathological stages were: pT2a in 52%, pT2b in 16%, pT2c in 8%, pT3a in 17%, pT3b in 1%, one case the cancer not found. The Gleason combined score were: 7 in 57%, 6 in 25%, 5 in 11%, and 8 in 7%. The overall positive surgical margin (+SM) was 14.66% (64% pT3b, 9% pT3b, 9% pT2b, 9% pT2c). Respectively, 23.62% of the + SM were found in the first group and 5.45% in the second group.

**Conclusion:** Retrograde NSLRP is a feasible and secure surgical approach. It is oncologically safe with comparable surgical margins. The status of surgical margins is improving with the acquisition of experience. Furthermore, the retrograde extended nerve-sparing technique not affects oncologicals results comparing with other series. Finally, we believe like this technique repeats the steps done during open surgery, could be most easy to teach and learn it, because the majority of urologists are familiarized with conventional radical prostatectomy.

### VP12-11 LAPAROSCOPIC “SINGLE KNOT—SINGLE RUNNING SUTURE” VESICO-URETHRAL ANASTOMOSIS WITH RESTORATION OF POSTERIOR RABDOSPHYNCTER

G. Simone, S. Guaglianone, R. Papalia, A. Bove, E. Forastiere, M. Gallucci

**Background:** We present results of a simplified technique to restore posterior rhabdosphyncter and to configure the vesico-urethral anastomosis during laparoscopic radical prostatectomy (LRP) with a “single knot - single running suture”, comparing continence rates and mean time to continence of this series with those of a previous series of patients who underwent LRP with conventional Van Velthoven anastomosis without restoration of posterior rhabdosphyncter.

**Methods:** Between December 2007 and April 2008 68 LRP with a Van Velthoven anastomosis were performed. Between May 2008 and December 2008 132 LRPs were performed and the novel anastomosis were applied in all patients. All procedures were performed by a single surgeon who had already completed the learning curve before the study beginning. Patients who previously underwent TURP or simple prostatectomy were excluded. The modified anastomosis was performed as follows: once passed the sutures outside-in on the bladder neck a first suture was passed transversally through the rhabdosphyncter from right to left without including the urethral mucosa and then outside-in at 6:30 o'clock position on the bladder neck as well as the other suture passed from left to right through the rhabdosphyncter was subsequently passed outside-in at 5:30 o'clock position on the bladder neck. Following steps of the anastomosis were the same of conventional Van-Velthoven technique. Mean operative time of LRP and mean time to configure the anastomosis were recorded and compared between two groups. The catheter was removed in all patients on 10th postoperative day. Continence was defined as the proportion of patients using 0–1 pad per day. One month, 3 month and 6 month continence rates and mean time to continence of two groups were analyzed and compared.

**Results:** There were significant differences neither in mean operative times nor in mean time to configure the anastomosis between two groups. Continence rates at 6 month evaluation was 93.5% in

the group of patients with Van Velthoven anastomosis and 100% in the group of patients with the modified anastomosis technique. Mean time to continence was 74 days in the first group and 63.5 days in the second one, respectively.

**Conclusion:** Although differences in time to continence recovery have not a clinical relevance, the 6 month continence rate of patients treated with LRP and “single knot—single running suture” with restoration of the posterior rhabdosphincter was 100%. The excellent outcome together with the easiness of performing this kind of anastomosis compared to the traditional Van Velthoven makes it widely reproducible.

### VP12-12 KNOTLESS ANASTOMOSIS DURING LAPAROSCOPIC RADICAL PROSTATECTOMY

M. Kilciler, L. Tahmaz, S. Bedir, H. Guler, M. Dayanc

**Background:** Vesicourethral anastomosis in laparoscopic prostatectomy is a very difficult and time-consuming procedure. We report a technique during the running suture at the vesicourethral anastomosis step.

**Methods:** At Gulhane Military Medical Academy Department of Urology, in 11 patients who underwent laparoscopic radical prostatectomy (LRP) we did not use knot at the end of the continuing anastomosis during LRP. In these cases at the end of the running suture during vesicourethral anastomosis, we saw that both side sutures were very short for knot-tying. Instead of knotting at the end of the anastomosis, two sides of the sutures were being pulled and two Weck clip were placed at the both side of the anastomotic sutures. And the needles were cut and removed the outside of the body. Then the bladder was filled with 200 ml saline and we saw that there was no leakage from the anastomosis.

**Results:** When we compare the drain removing time in the knotless and knot groups, we determined approximately one and three day, respectively. Only one patient we noted a migration of Weck clip into the bladder at the bladder neck level. On the cystoscopic examination of the patient, this Weck clip was removed to the outside of the body. LRP was made retroperitoneally in ten patients, and intraperitoneally in one patient. Mean age of the patients was 63, mean operation time was 210 minute, and mean blood loss was 350 ml.

**Conclusion:** After the resection of prostate and seminal vesicles, reconstruction of the bladder and urethra is difficult and laparoscopist needs to have more experience to make anastomosis. Sometimes at the end of the continuing anastomosis both suture sides are insufficient to make knot and finish the anastomosis. In these situations at the both side of the continuing anastomotic sutures, Weck clip can be use instead of a knot. But routinely use of the Weck clip for this aim is not recommended because sometimes migration into the bladder can be seen as a postoperative problem.

### VP12-13 LIMITED AND EXTENDED PELVIC LYMPHADENECTOMY IN ROBOTIC RADICAL PROSTATECTOMY: CONCLUSIONS FROM 195 CASES

H. John, N. Engel, D. Bergstein, B. Fischer, J. Fehr

**Background:** Robot-assisted laparoscopic prostatectomy (RALP) is the preferred operative method today for localized prostate cancer. Optimal oncologic results, minimal morbidity and best functional outcomes of urinary continence and erection are claimed. However, only few centers report their policy and results concerning pelvic lymphadenectomy. This retrospective study

analyses systematically the results of limited and extended lymphadenectomy in a standardized robotic program.

**Methods:** 291 patients with localized prostate cancer and a mean age of 64 (41–80) years underwent RALP, whereof 193/291 (67%) had a pelvic lymph node removal. Routinely and in patients with limited lymphadenectomy (173/195, 89%), an extraperitoneal access was chosen, while patients with extended lymphadenectomy (22/195, 11%) underwent a transperitoneal approach. The limited lymphadenectomy was performed within the obturator fossa, while extended lymph node dissection included the external and iliac internal template up to the ureter.

**Results:** Patients with limited versus extended lymphadenectomy had a Gleason Score of 6.7 (3–9) versus 7 (5–10) and a PSA of 10 (4–44) ng/ml versus 22 (8–78) ng/ml,  $p < 0.002$ . Blood loss (300 ml) and hospital stay (7 days) was equal in both groups. Extended lymphadenectomies had a longer total operative time 220 (150–320) minutes versus 190 (110–600),  $p = 0.035$ . Extended lymphadenectomy revealed a removal of 24 (11–44) nodes versus 9 (1–33),  $p < 0.001$ . Positive lymph nodes were observed in 2.3% in limited and 46% in extended technique ( $p < 0.001$ ). pT2 stages were significantly increased in the limited dissection group ( $p < 0.001$ ), while pT3 stages were predominant in the extended group ( $p < 0.001$ ). In 14/195 (7%) patients, a symptomatic lymphocele developed and in 2/195 (1%) a femoral vein thrombosis. No iliac vessel injury occurred.

**Conclusion:** Limited and extended pelvic lymphadenectomies are technically well feasible during robotic prostatectomy. In patients with limited lymphadenectomies and extraperitoneal approach, a primary peritoneal fenestration may be efficient to avoid symptomatic lymphoceles. In patients with extended pelvic lymph node dissection, a transperitoneal access is recommended. No conclusion for the oncological relevance of limited or extended lymphadenectomy in patients undergoing radical prostatectomy can be drawn from this data.

### VP12-14 URINARY CONTINENCE AFTER VIDEOLAPAROSCOPIC RADICAL PROSTATECTOMY BASED ON ANATOMICAL LANDMARKS

J. Travassos, A. Xavier, Á. M. Figueiredo, K. De Juan—Brazil

**Background:** Videolaparoscopy provides magnification of the surgical field. Therefore, allowing better identification of the anatomical structures responsible for the mechanism of urinary continence.

**Methods:** 170 patients underwent VLAP extraperitoneal radical prostatectomy. The relevant anatomical landmarks: preservation of the circular fibers of the bladder neck; bilateral preservation of the neurovascular bundles; transection and reconstruction of the puboprostatic ligaments close to the apex of the prostate; selective ligation of the dorsal vein complex; dissection of the distal tip of the urethra until the longitudinal fibers and vesicourethral anastomosis, using minimum amount of urethral tissue. Patients continence were evaluated using the International Society of Urinary Continence concept.

**Results:** All patients were continent before surgery. In the 3 month post-operative, 145 (85.3%) patients were continent, 23 (13.6%) incontinent by effort and 2 (1.1%) incontinent. 6 months after surgery the data remain virtually unaltered 87% patients continent and 11.8% incontinent by effort. 9 months post-operative important changes happened 94.7% continent, 4.1% incontinent by effort

and 1.2% incontinent. Achieving 1 year after surgery 165 (97%) don't have any kind of urinary loss, 4 (2.4%) reported incontinence by effort and only 1 (0.6) stayed totally incontinent.

**Conclusion:** A better identification of the anatomical structures lead to an excellent result in urinary continence. It is fundamental to have a careful dissection of the prostate apex, with a maximum preservation of the circumferential musculature of the rhabdosphincter and bladder neck, and a minimum damage to these structures. In our understanding, the preservation of vasculo-nervous bundles also contributes positively for the recovery of urinary continence.

### VP12-15 NO-SUTURE X SUTURE IN LAPAROSCOPIC RADICAL PROSTATECTOMY

J. Travassos, A. Xavier, Á.M. Figueiredo, F. Chagas dos santos, R. Brites, K. De Juan—Brazil

**Background:** The vesical-urethral anastomosis has always been an important discussion in radical prostatectomy. The purpose was to compare a no-suture technique with suture. In both cases the bladder neck was preserved.

**Methods:** 80 consecutive patients underwent radical prostatectomy with bladder neck preservation and an anastomosis achieved by applying a gentle traction to a Foley catheter for 24 hours and vesical catheter for 18 days. The other group has 80 consecutive patients too. Their surgery had the suture, they stayed with vesical catheter for 10 days. The matters of concern were leakage, continence and anastomotic strictures.

**Results:** The group with no suture presented a continence rate of 97%. Firstly, no strictures were found although more cases of stricture were found after 12 to 18 months. No fistula were observed. In the group with suture the continence rate was the same (97%) but we found 4 cases of stricture.

**Conclusion:** The no-suture technique could be an alternative in front of challenging cases, when the suture is practically impossible. It can be also an advantage in patients with a short urethra.

### VP12-16 EXTRAPERITONEAL LAPAROSCOPIC RADICAL PROSTATECTOMY: CLINICAL EXPERIENCE AND LEARNING CURVE OF 103 CASES

S. Jung, H. Chung, J. Park, E. Hwang, C. Im, D. Kwon—South Korea

**Background:** To estimate the early operative results and learning curve of extraperitoneal laparoscopic radical prostatectomy in 103 patients.

**Methods:** Between March 2006 and January 2009, 103 patients with clinically organ-confined prostate cancer who underwent laparoscopic radical prostatectomy were enrolled in this study. Surgical morbidity, oncologic and functional results of groups were compared for evaluation of the learning curve.

**Results:** The patients' age was  $63.3 \pm 8.1$ , and serum PSA was  $14.1 \pm 7.6$  ng/ml. The mean operating time and hospital stay was  $265 \pm 83$  minutes and  $10.6 \pm 3.6$  days, respectively. The mean postoperative period of an indwelling Foley catheter was  $13.8 \pm 2.7$  days. A positive surgical margin rate was 26.2%. After a mean follow-up of  $15.5 \pm 9.4$  months, a PSA relapse was observed in 3 (8.6%) patients in the first period. The continence and sufficient erection rates were about 80%, 45% after 6 months, respectively. Analysis of the learning curve revealed differences in the operating time, estimated blood loss, complication rate but showed

no influence in their hospital days, indwelling Foley catheter days, positive surgical margin rate.

**Conclusion:** Although laparoscopic radical prostatectomy requires significant expertise with a learning curve, the morbidity is low and the oncologic continence result was promising. In patients with clinically organ-confined prostate cancer, extraperitoneal laparoscopic radical prostatectomy could be considered as the first safe treatment for patients with organ-confined prostate cancer. The learning curve of extraperitoneal laparoscopic radical prostatectomy seems to show no complete plateau in this study. It depends on the self perceived definition, not only the technical skills. Therefore the standardized expectations and operative outcomes could help to define the true learning curve for extraperitoneal laparoscopic radical prostatectomy.

### VP12-17 EXTRAPERITONEAL APPROACH FOLLOWING TRANSPERITONEAL SEMINAL VESICLE DISSECTION IN LAPAROSCOPIC RADICAL PROSTATECTOMY

M. Kawakita, G. Kawa, H. Kinoshita, T. Matsuda—Japan

**Background:** We present a modified Montsouris technique with the extraperitoneal dissection of the Retzius cavity during laparoscopic radical prostatectomy.

**Methods:** After the transperitoneal dissection of the seminal vesicles, the Retzius cavity is dissected with a dissection balloon. The trocars are reinserted into the Retzius cavity with using the same skin and muscle penetrations, and the following antegrade prostatectomy is completed extraperitoneally. This technique was applied to 45 patients with clinically localized prostate cancer.

**Results:** The dissection of the Retzius cavity with a dissection balloon and the reinsertion of trocars were easily performed in all patients. The vesicourethral anastomosis was performed without tension just as the original Montsouris technique. There were no major intraoperative or postoperative complications.

**Conclusion:** The modified Montsouris technique with the extraperitoneal dissection of the Retzius cavity following transperitoneal seminal vesicle dissection is easily and successfully performed for laparoscopic radical prostatectomy. This technique will reduce complications associated with fully transperitoneal approach by the original Montsouris technique.

### VP12-18 LAPAROSCOPIC SIMPLE PROSTATECTOMY: LONG TERM RESULTS

F. Porpiglia, C. Fiori, B. Cavallone, S. Grande, R. Scarpa

**Background:** We report the long term results of laparoscopic simple prostatectomy, according to Millin technique (LSPM).

**Methods:** From 1/2006 to 5/2009 75 patients underwent LSPM, 41 of these had at least 1 year of follow-up, so this last group was the population of the study. For each patient we considered age, BMI, Prostate Volume (TRUS), maximum urinary flow (Qmax), and PSA before LSPM and after a follow up of at least 12 months. Complications were recorded too. Moreover all patients filled out the EPIC and IPSS questionnaires before LSPM and during the follow-up visit.

**Results:** Mean age was 70.4 years, BMI was 24.6. Mean prostate volume was 90.02, mean follow-up was 22 months. Pre and post operative PSA was respectively 7.5 ng/ml and 1.13 ng/ml ( $p < 0.05$ ) pre and post operative Qmax was respectively 9.34 and 24.6 ml/s ( $p < 0.05$ ). We recorded early complications in 2 cases (4.8%), 1 case of urethral stenosis whilst 1 patient referred mild

incontinence, no late complications were recorded. IPSS score after surgery was significantly lower than before LSPM (24.3 and 5.3 respectively). Also the EPIC questionnaire showed an increase of the urinary function (from 88.6 to 94.14, range EPIC scale 0–100) and a decrease of the patients concerns about their urinary problems (from 39.65 to 14.54; EPIC scale 0–100); the overall satisfaction after LSPM was 80.87 (EPIC scale 0 to 100).

**Conclusion:** LSPM is an effective technique for the treatment of large prostatic adenomas and its results are stable during follow up.

### VP12-19 INTERFASCIAL MICROPNEUMATIC BALLOON AIDED TISSUE PLANAR FLUID DISSECTION DURING LAPAROSCOPIC RADICAL PROSTATECTOMY—PRELIMINARY CONCEPT

S. Kommu, C. Eden, F. Mumtaz, A. Golash, C. Luscombe, J. Emtage—United Kingdom

**Background:** Laparoscopic and robotic radical prostatectomy are included as standard options for the treatment of organ confined prostate cancer and the approach is believed by many to be the gold standard. Optimal surgical outcomes are seen by many to be incorporated in the trifecta of oncological control, continence preservation and maintenance of potency. With respect to the latter periprostatic tissue and its relationship to the prostate has been an area of great interest. Athermia and tension free dissection with minimal disruption of the neurovascular bundle is cited by many as a key facet in potency maintenance. In a previous study it was shown that in the cadaver, planar dissection of periprostatic tissue using microballoon pneumatic dissection and instillation of fluid could act as a useful means of performing a radical prostatectomy with the potential for preservation of the neurovascular bundle with minimal trauma (Kommu et al. Journal of Endourology. October 2007: A1-A292). Herein, we demonstrate the use of the technique during laparoscopic radical prostatectomy.

**Methods:** Periprostatic dissection was carried out via conventional laparoscopic ports and real-time dissection was achieved by serial pneumatic dilation of tissue planes with simultaneous instillation of water. The neurovascular bundles were then examined for breach.

**Results:** The technique permitted ease of dissection within tissue planes permitting interfascial dissection in an athermal environment and with minimal tension to the periprostatic nerves. The

technique was a useful supplementary tool for successful resection of the prostate with preservation of the neurovascular bundle.

**Conclusion:** Interfascial micropneumatic balloon aided tissue planar fluid dissection could be a useful tool for preservation of the neurovascular bundle during laparoscopic and robotic radical prostatectomy. The technique should be tested further.

### VP12-20 POSITIVE MARGINS AFTER LAPAROSCOPIC RADICAL PROSTATECTOMY (LRP): WHAT ARE THE INFLUENCING FACTORS?

M. Baptistussi, M. Morihisa, E. Gewher, A. Martins—Brasil

**Background:** To evaluate factors that influence positive surgical margin status (+sm) and biochemical prostatic specific antigen (PSA) recurrence status after LRP.

**Methods:** From April 2003 to March 2009 175 patients with localized prostate cancer underwent LRP. The Following factors were included into a regression analysis model in order to evaluate the factors associated with + sm status after LRP: patients age, preoperative prostate volume, body mass index, operating time, experience of the surgeon (ES, 100 procedures), preoperative tumor stage (T1, T2, T3), pathological tumor stage (pT2, pT3), preoperative Gleason-score, preoperative prostatic specific antigen (PSA), number of performed preoperative prostate core biopsies, number of positive core biopsies, and intraoperative preservation of vascular-nerve bundle (PVNB). Variables identified as significant ( $p < 0.05$ ) or approaching significance ( $p < 0.1$ ) were analysed using stepwise multiple logistic regression analysis.

**Results:** When all above listed factors were added to the logistic stepwise backward regression model, the pathological tumor stage was the most important factor (end model) for + sm status after LRP ( $p < 0.01$ ); odds ratio 11.1 (95% CI 3.4–36.9). The preoperative PSA value reached no significant levels ( $p = 0.128$ ). Worth mentioning, neither PVNB, preoperative supposed preoperative Gleason-score, ES, number of positive core biopsies nor the prostate size influence the + sm status of LRP.

**Conclusion:** In patients with locally advanced prostate cancer (pT3) the odds of having a positive surgical margin status after LRP is increased by a factor of 11.1, when compared to patients with pT2 tumor stage.

## VP13: FEMALE UROLOGY

### VP13-01 GENTIOURINARY TRACT EROSION OF MINIMALLY INVASIVE TECHNIQUES COMPARED TO OPEN ANTI-INCONTINENCE SURGICAL APPROACHES AND THEIR MANAGEMENT

F. Sharifiaghdas, N. Mortazavi

**Background:** Genitourinary tract invasion of synthetic non-absorbable tapes for the treatment of stress urinary incontinence is a known complication. In this retrospective study we report our data and management of this complication and compare it with the open surgical approaches.

**Methods:** Medical records of patients, who were surgically managed during six years (2002–2008) with the diagnosis of genitourinary tract erosion secondary to previous Anti-incontinence surgeries, were reviewed. Demographic data including age, parity, type of anti incontinence surgery, chief complaint, duration of symptoms, imaging, urodynamic study, rigid cystourethroscopy and surgical management recorded.

**Results:** Nineteen patients were enrolled in group I (T.OT, T.V.T, I.V.S) and 14 in group II (Burch colposuspension, Marshall–Marketti-Krantz). Mean age for group I and II was 48.1 and 52.5 years. Mean duration of symptoms for group I and II was 12.5 and



18.2 months. Imaging (ultrasound, K.U.B) was diagnostic in 42.2% cystourethroscopy and vaginal exam were diagnostic in 76% (25 out of 33) and 24% (8 out of 33) of patients. Endoscopic removal of foreign body was successful in all group II patients with mean surgical attempts of 1.6 times. Vaginal removal of tape was successful in all cases with mean surgical attempts of 1.5 times. Effective Endoscopic removal of intravesical foreign body was unsuccessful in group I and all underwent open surgical approach with partial or total removal of tape.

**Conclusion:** Endoscopic removal of intravesical tape was unsuccessful in our patients in contrast to open surgical Anti-incontinence approaches.

### VP13-02 EFFECT OF REPEATED BOTULINUMTOXIN-A INJECTIONS IN A PATIENT WITH LUMBOSACRAL SPINA BIFIDA AND SEVERE NEUROGENIC BLADDER DYSFUNCTION—A CASE REPORT

R. Steiner, P. Honeck, G. Wendt–Nordahl, T. Knoll—Germany

**Background:** Spina bifida and other congenital abnormalities of the spinal cord are relatively common (1 per 1000 births). After early urologic evaluation to determine the extent of neurologic involvement of the lower urinary tract timely medical and surgical treatment is essential. However, intermittent self-catheterization (ISC) and antimuscarinic agents (AM) do regularly fail in preventing the development of severe high-pressure, neurogenic bladder dysfunction. Intradetrusitorial Botulinumtoxin-A (Botox) injection offers a local minimal-invasive alternative to daily drug intake. However, the efficacy of Botox after long-term neurogenic bladder dysfunction is yet to be determined. We report a spina bifida patient with unsatisfying medical control of neurogenic bladder dysfunction and intractable incontinence, who was treated by repeated Botox injections.

**Methods:** The female patient, currently 23 yrs. of age, was born with lumbosacral spina bifida. Since early childhood, clean ISC was performed, accompanied by oral, later also intravesical AM drug application. Regular follow-up examinations, including video-urodynamics, were performed at our department, starting from 1995. Even substance change and dose modifications did not sufficiently prevent urine loss. Urodynamic evaluation demonstrated persistent low-compliance, high-pressure bladder dysfunction with typical morphology on cystography. Regular intradetrusitorial botulinumtoxin-A injection (Allergan, USA) was therefore initiated 4 years ago.

**Results:** Botox injection was safe, intra- or postoperative complications did not occur. Botox dose started with 200 i.E. and was increased to 300 i.E. from the 2nd application. Time interval between injections was 8–12 months. The effect of Botox was clearly superior compared to oral and intravesical AMs. Complete urinary continence was achieved with regular ISC. Oral AM treatment is continued on a low-dose protocol, intravesical AM application was stopped. Video-urodynamic follow-up demonstrated significant reduction of intravesical pressure and regression of morphologic changes.

**Conclusion:** Our case demonstrates that intradetrusitorial botulinumtoxin-A offers a highly-effective and safe treatment modality in neurogenic bladder disorders, that has a significant effect both on life quality and bladder function. The effect is superior compared to oral or intravesical therapy. Bladder morphology, even with severe manifest changes, regresses with therapy.

### VP13-03 LAPAROSCOPIC SACROCOLPOPEXY USING TITANIZED POLYPROPYLENE MESH—INITIAL EXPERIENCES WITH THE FIRST 10 PATIENTS—M. HATZINGER, D. VÖGE, M. LÖHR, M. SOHN DEPARTMENT OF UROLOGY, MARKUSHOSPITAL, FRANKFURT, GERMANY

H. Martin, D. Vöge, M. Löhr, M. Sohn

**Background:** Evaluation of the effects of a titanized soft tissue mesh in patients with vaginal vault prolapse during the laparoscopic sacrocolpopexy.

**Methods:** Between December 2008 and June 2009 we performed a laparoscopic sacrocolpopexy in 10 patients with vaginal vault prolapse. Instead of the standardized polypropylene mesh we used a titanized soft tissue mesh (Tilloop®). We fixed the mesh in the so called “duck-beak technique” at the promontory and the anterior and posterior vaginal wall.

**Results:** No major or minor complications were seen. Intraoperative handling problems or postoperative mesh erosion did not occur. No bladder or bowel perforation or infection. In all cases we found a perfect postoperative cystocele repair. Because the mesh is titanized it's possible to control the postoperative mesh position with the MRI. These controls showed a perfect elevation and correction of the prolapse.

**Conclusion:** To our knowledge this is the first series on the use of a very soft titanized polypropylene mesh in patients with vaginal vault prolapse and laparoscopic repair. Therefore we are convinced that these preliminary results justify the start of a prospective randomized controlled trial to evaluate the long term effects of Tilloop® in the management of laparoscopic pelvic floor reconstruction.

### VP13-04 TRANSVESICOSCOPIC REPAIR OF VESICOVAGINAL FISTULA

S. Devaraju, A. Guntaka, R. Nerli, M. Reddy—India

**Background:** Vesicovaginal fistula has been a social and surgical problem for centuries. Many surgical techniques have been developed to correct this abnormality, including transabdominal, transvaginal, and endoscopic approaches. The best approach is probably the one with which the surgeon feels most experienced and comfortable. Laparoscopy has become increasingly popular in urology, reducing the invasiveness of treatment and shortening the period of convalescence. We report our results of transvesicoscopic approach for VVF repair.

**Methods:** Patients with VVF were offered repair using the transvesicoscopic route. With the patient under general anaesthesia and in modified lithotomy position cystoscopy was performed with gas insufflation. Under cystoscopic guidance the bladder was fixed to anterior abdominal wall and ports inserted into the bladder. The fistula was repaired under endoscopic vision.

**Results:** Three women who had VVF following abdominal hysterectomy, underwent this procedure. The operating time ranged from 220 to 335 mins. There was minimal bleeding. Post operative complications included ileus in one and fever in another. No recurrence of VVF was noted in any patient.

**Conclusion:** Transvesicoscopic repair of VVF is feasible, safe, results in lower morbidity and quicker recovery time.

### VP13-05 SINGLE PORT LAPAROSCOPIC SACRAL COLPOPEXY: INITIAL OPERATIVE EXPERIENCE AND COMPARATIVE OUTCOMES

W. White, R. Goel, G. Haber, M. Swartz, R. Rackley, J. Kaouk

**Background:** To determine the efficacy and safety of single port laparoscopic abdominal sacral colpopexy (ASC) for the treatment of female pelvic organ prolapse (POP).

**Methods:** A retrospective cohort study was performed to assess perioperative outcomes among women who underwent treatment of symptomatic pelvic organ prolapse with laparoscopic, robotic, or single port laparoscopic ASC. All patients underwent preoperative history and physical examination including pelvic organ prolapse quantification (POP-Q) staging and urodynamics. ASC with or without anti-incontinence surgery was performed via the aforementioned approaches. Demographic and peri-operative data were obtained. Patients were followed postoperatively for a minimum of 12 months with POP-Q evaluation. Statistical analysis was performed.

**Results:** From October 2005 to July 2008, 30 females with symptomatic Stage II (6 patients), Stage III (23 patients), or Stage IV (1 patient) POP were treated with laparoscopic (10), robotic (10), or single port laparoscopic (10) ASC. Mean age of the entire cohort was 61.1 years. Mean BMI was 26.7 kg/m<sup>2</sup>. Seventeen patients demonstrated stress urinary incontinence and underwent concomitant sling placement. No intraoperative complications were encountered. There was no significant difference in the 3 cohorts with respect to operative time, blood loss, mean visual analog pain score at discharge, or duration of hospitalization. At 12 months following surgery, 27 patients underwent follow-up POP-Q with all patients demonstrating excellent apical support and prolapse reduction.

**Conclusion:** Single port laparoscopic ASC offers comparable efficacy, decreased pain, and superior cosmesis compared to alternative approaches. Long-term follow-up is needed to confirm durability of repair.

### VP13-06 LAPAROSCOPIC TRANSURETEROURETEROSTOMY WITH ILEAL CONDUIT IN RADIATION INDUCED VESICOVAGINAL FISTULA

M. Ramalingam, K. Senthil, M. Pai

**Background:** Management of radiation induced VVF can be very frustrating to the patient and the physician. We describe a case of cancer cervix with post radiotherapy VVF. This patient already had rectovaginal fistula for which loop colostomy was done.

**Methods:** Background –55 year old female presented with locally advanced carcinoma cervix for which she underwent radiotherapy in 2006. She was on regular follow up. She developed rectovaginal fistula in September 2007 and had a sigmoid loop colostomy. Unfortunately she developed a vesicovaginal fistula. Clinically and on imaging, the whole pelvis was found to be frozen and there was a large communication from the bladder to the vagina and rectum and she had bilateral hydronephrosis. Repair of VVF was not technically feasible and the option of diversion by an ileal conduit was discussed. During mobilization the left lower ureter was found to be stuck. As it was an irradiated pelvis and as the patient had renal impairment, it was not possible to take a long loop of ileum to reach the left ureter. Hence a left to right ureterour-

terostomy was done laparoscopically and ileal conduit was fashioned transportally.

**Results:** The operative time was 4 hours. The blood loss was about 150 ml. There was no complication during the post operative period. Even though the patient has two stoma bags she is comfortable, ambulant and happy at 15 months follow-up. CT scan done at 3 months, showed normal kidneys.

**Conclusion:** Ileal conduit is a worthy palliation in radiation induced VVF. Laparoscopic transureteroureterostomy is technically feasible.

### VP13-07 MINIMALLY INVASIVE APPROACH TO UROGYNECOLOGIC FISTULA: OUR EXPERIENCE

A. Guntaka, S. Devaraju, R. Nerli, M. Reddy—India

**Background:** Most urogynecologic fistulas in the industrialized world are iatrogenic, Though they may also result from congenital anomalies, malignant disease, inflammation and infection, radiation therapy, iatrogenic (surgical) or external tissue trauma, ischemia, parturition and a variety of other processes. Vesicovaginal fistulas represent, by far, the most common type of acquired fistula of the urinary tract. The goal of treatment of these fistulas is the rapid cessation of urine leakage with return of normal and complete urinary and genital function.

**Methods:** Female patients presenting with iatrogenic urogynecologic fistula formed the study group. A detailed history and physical examination was carried out. Imaging included intravenous urogram, cystogram, computerised tomography, MR imaging and retrograde ureterogram as felt necessary. Surgical repair of ureterovaginal, Vesicovaginal and Vesicouterine fistula was carried out through a laparoscopic approach.

**Results:** 14 women presented with VVF, Of these 10 underwent laparoscopic transperitoneal repair, whereas 4 underwent laparoscopic transvesicoscopic repair. 7 patients presented with ureterovaginal fistula. Three of these underwent successful endoscopic DJ stenting and four others underwent laparoscopic extravesical ureteroneocystostomy. 6 women presented with vesicouterine fistula following caesarean section and all underwent successful laparoscopic repair of the same. The intraoperative blood loss was minimal (<100ml) no major perioperative complications were noted.

**Conclusion:** Minimally invasive approaches to repair urogynecologic fistulas are feasible, safe and associated with minimal blood loss, hospital stay and morbidity.

### VP13-08 LAPAROSCOPIC SACROCOLPOPEXY: INITIAL EXPERIENCE IN 10 CASES

O. Castillo, F. Sepulveda, I. Vidal-mora, A. Foneron, G. Rubio, R. Campos

**Background:** Abdominal Sacrocolpopexy is the gold standard for vaginal vault prolapse (VVP) showing lower rates of recurrence and less dyspareunia than vaginal sacrocolpopexy. Our aim is to present our experience in laparoscopic sacrocolpopexy assessing its feasibility and reproducibility.

**Methods:** We performed a prospective analysis of laparoscopic sacrocolpopexy realized between april 2004 and may 2009. For each case we review the surgical history and the presence of urinary incontinence, surgical technique and associated surgery, operative time, length of hospital stay and perioperative complications.

**Results:** During this period 10 laparoscopic sacrocolpopexy were performed. Average age was 50.6 years (41–62). Four patients had a history of prior hysterectomy and one patient had a history of surgery for VVP. Six patients were managed with a mesh to the vaginal vault and 4 with an anteroposterior mesh. In 4 patients we also realized a subtotal hysterectomy and in 1 patient a total hysterectomy. 5 patients had a history of urinary incontinence being managed 4 of them with a transobturator tape (TOT) and 1 with a transvaginal tape (TVT). Average operative time was 103.7 minutes (45–130) and mean length of hospital stay was 2.7 days (2–3). All patients evolved without complications.

**Conclusion:** Laparoscopic sacrocolpopexy is a feasible technique that can safely achieve the concepts of open sacrocolpopexy.

### VP13-09 LAPAROSCOPIC COLPOSACROPEXY WITH BIOMESH (PELVISOFT®) IN THE TREATMENT OF PELVIC ORGAN PROLAPSE

S. Corvin, C. Antwerpen, G. Bromberger, H. Hammerl, M. Ulbrich—Germany

**Background:** In the present study, our first experiences with laparoscopic colposacropexy in the treatment of pelvic organ prolapse (POP) using a biomesh are reported.

**Methods:** We retrospectively studied 30 laparoscopic colposacropexies performed from January 2007 to June 2009. All patients presented with symptomatic POP with concomitant urinary incontinence or bladder outlet obstruction. 14 individuals had undergone previous pelvic surgery, i.e. hysterectomy and vaginal prolapse repair. Through a laparoscopic transperitoneal approach, anterior and posterior vaginal wall were prepared and fixed to the right sacrum using a biomesh (Pelvisoft®).

**Results:** All operations were performed successfully with a mean operative time of  $145 \pm 35$  min with minimal blood loss. Two cases required conversion to open surgery due to massive adhesions or a previously unknown pelvic tumor. POP symptoms and bladder outlet obstruction were cured in all patients. During a maximum follow up of 30 months, no recurrence was observed. Concomitant urinary incontinence was treated successfully by means of a simultaneous or delayed transobturator tape procedure.

**Conclusion:** Laparoscopic colposacropexy with Pelvisoft® is an applicable minimally invasive tool in the treatment of POP. Excellent results comparable to the open approach can be achieved especially in recurrent cases.

### VP13-10 LAPAROSCOPIC VESICOVAGINAL FISTULA REPAIR: 9 CASES

I. Vidal-mora, O. Castillo, F. Sepúlveda, G. Rubio, A. Foneron, R. Campos

**Background:** Objectives: Most vesicovaginal fistulas (VVF) develop after an urogynaecologic surgery. Transabdominal transvesical repair has been the standard treatment for this condition. However in times of minimally invasive surgery laparoscopic repair of VVF may be an alternative approach to treat this condition. Our aim is to present our experience in laparoscopic transvesical transabdominal repair of VVF.

**Methods:** We performed a prospective analysis of laparoscopic transvesical repair of VVF realized between the years 1996–2009 in our institution. For each case we analyzed the etiology of the VVF, evolution time, surgical technique, operative time, length of hospital stay and perioperative complications.

**Results:** During this period 9 laparoscopic repair of VVF were performed. All patients were operated by the same surgical team. The average age was 45 years (38–54). All patients had a past history of a hysterectomy and a posterior history of urine escape through the vagina with a mean evolution time of 59 months (0.5–180). The average operative time was 127.7 minutes (75–180) and the mean hospital stay was 4.7 days (3–10). All patients evolved with no complications except one that present an urinary tract infection (*Pseudomona aeruginosa*) being treated with antibiotics.

**Conclusion:** In experienced hands transvesical transabdominal laparoscopic repair of vesicovaginal fistula is feasible and safe preserving all the advantages of minimally invasive surgery.

### VP13-11 LAPAROSCOPIC VESICOVAGINAL FISTULA REPAIR

J. Diaz, R. Riffo, A. Pabon, I. Pinto, C. Sandoval, A. Hornig—Chile

**Background:** The genitourinary tract fistulas commonly occur as a complication of pelvic surgery, especially gynecologic procedures. Repair is a challenge for urologists. The aim of this presentation is to describe the technique for laparoscopic repair of vesicovaginal fistula, presenting the experience and results with these techniques.

**Methods:** Since august 2008 4 patients undergoing gynecological surgery had supratriangular vesicovaginal fistula as a complication. All of them were repaired by laparoscopic surgery.

**Results:** The laparoscopic repair was performed without complications in all cases. The mean operative time of surgery was 161.3 min (range: 135–180 min), the length of hospital stay was 4 days (range: 3–5 days). The mean follow up was 8 months. All patients evolved with complete remission of the VVF.

**Conclusion:** The management of genitourinary fistula secondary to gynecological surgery is possible to perform laparoscopic respecting the classical concepts of surgery.

### VP13-12 TECHNICAL NUANCES IN THE LAPAROSCOPIC REPAIR OF VESICOVAGINAL AND UTEROVAGINAL FISTULAE

M. Agarwal, S. Singh, R. Mavuduru, A. Mandal—India

**Background:** Laparoscopic repair of genitourinary fistula is considered technically demanding and has not attained status of 'standard of care'.

**Methods:** Two women with vesicouterine fistulae (age 35 & 32 years) and one with vesicovaginal fistula (41 years) underwent laparoscopic repair. With patient in Trendelenburg position transperitoneal access was made under vision and 3ports were placed (camera port–umbilicus; left and right working ports–intersection of midclavicular plane and spino-umbilical line). Vaginal leak of pneumoperitoneum was prevented by packing and plugging introitus with Foley balloon. Cystotomy was made starting 3 cm above level of cul-de-sac and continued till level of fistula. The edges were retracted using 2/0 polyglactin-910 suture fixed to peritoneum of lateral abdominal wall on either side. Fistula was dissected and closed without excising the fibrous tract. Bladder was closed in single layer. Knotting was replaced with hem-o-lok plastic clips. Local peritoneal flap or omentum was used for interposition.

**Results:** Median operative time was 150 min and blood loss <100 ml. Patients were ambulated on day 1, drain removed on day 3 and discharged on day 5. Urethral catheter was removed on

day 14. All patients are doing well at median follow up of 6 months.

**Conclusion:** Cystotomy retraction using sutures obviates need of extra ports and minimizes trauma to bladder wall due to instrumentation. Measures like use of clips instead of knots, avoidance of fistula-tract excision and single-layer closure of bladder save operative time. Technical nuances described would help simplify the procedure and decrease operative time.

### **VP13-13 EFFECT OF LAPAROSCOPIC REPAIR OF VESICOVAGINAL FISTULA**

W. Dongwen, C. Xiaoming, G. Jinxi, X. Yunfa, X. Yunfa, L. Xuezhi

**Background:** To explore the clinical value of laparoscopic repair of vesicovaginal fistula.

**Methods:** From Dec 2001 to Dec 2007, 5 patients of vesicovaginal fistula underwent laparoscopic repair operation. Record the operating time, the intraoperative blood loss, the time of postoperative recovery of intestinal function and the postoperative hospitalization.

**Results:** All operations were successfully completed. The postoperative period of the patient was uneventful and after a follow up of 12 months no recurrence was found.

**Conclusion:** We believe that laparoscopic repair of vesicovaginal fistula is a feasible and efficacious minimally invasive approach for the management of this entity.

### **VP13-14 COMPARISON OF OPEN, LOCAL AND LAPAROSCOPIC VARICOCELECTOMY ACCORDING TO OPERATION TIME, COST, SPERMIOGRAM AND COMPLICATIONS**

A. Shamsa, L. Mohamadi, M. Abolbashari, M. Shakeri, S. Shamsa

**Background:** Varicocele is one of the commonest etiologies of infertility. This study evaluated and compared the operation time, cost, spermogram and complications in three different methods of varicocelectomy.

**Methods:** 90 Bilateral varicoceles were selected and then allocated 30 cases for following groups randomly: Group 1- laparoscopic varicocelectomy. Group 2- open subinguinal varicocelectomy through G.A Group 3- open subinguinal varicocelectomy through L.A.

**Results:** operation time was  $30 \pm 5.5$ ,  $27 \pm 3.5$ , and  $38 \pm 1.85$  min. in laparoscopic, open and local varicocelectomy groups respectively. Intraoperative complications occurred in only one in laparoscopic group, postoperative complications were 20.7%, 25%, and 4.2% in group 1, 2, and 3 respectively. Spermogram didn't change significantly after varicocelectomy except sperm morphology in local varicocelectomy group.

**Conclusion:** Subinguinal varicocelectomy under L.A. is better than laparoscopic method according to cost, recurrence, hydrocele formation, and operation time. Subinguinal method under G.A. has intermediate efficacy (i.e. less complications and cost than laparoscopic method and better results in operation time than two other groups ( $p < 0.05$ )).

### **VP13-15 EXPERIENCE WITH LAPAROSCOPIC "CLIPLESS" BILATERAL VARICOCELECTOMY WITH MASS LIGATION-DIVISION OF SPERMATIC VESSELS USING SILK 1-0**

E. Arada III, P. Fausto—Philippines

**Background:** Titanium or polyethylene clips used in laparoscopic varicocelectomy are expensive and not affordable to many patients from developing countries compared to cheaper and widely available Silk. We present our experience with "clipless" technique of mass ligating bilaterally dilated spermatic vessels using Silk 1-0 ligatures without the use of clips.

**Methods:** After Veress needle pneumoperitoneum, ports inserted were 12 mm umbilical trocar for laparoscope, 10 mm right lower abdomen trocar for scissors or needle holder and 5 mm left lower abdomen trocar for dissector. Left spermatic vessels were identified, exposed through small, posterior peritoneal window at iliac fossa, isolated, grasped with right-angle dissector and mass ligated using Silk 1-0 intracorporeal knots tied with "flamingo-jaw" needle holder. Two Silk 1-0 ligatures were placed proximally and one ligature distally on vessels before division using scissors between ligatures. Same procedure was then performed on right spermatic vessels and trocars removed.

**Results:** Eight male patients, ages 23–44 years (mean = 35.25 years) with left-sided Grade III varicoceles and right-sided Grade I or II varicoceles underwent Silk 1-0 "clipless" ligation. The average operative time was 138.75 minutes (range = 120–173 minutes) or 13.75 minutes more than average of 125 minutes (range = 115–135 minutes) in our other patients undergoing clip ligation. No recurrences of varicoceles or significant complications were noted up to ten months of follow-up.

**Conclusion:** We presented our experience with technique of Laparoscopic "clipless" bilateral varicocelectomy with Silk 1-0 mass ligation-division of spermatic vessels. Silk ligation is as effective and safe as clip ligation. Silk 1-0 ligatures are cheap and widely available especially for patients in developing countries.

### **VP13-16 LAPAROSCOPIC CONTROLLED AND ASSISTED PERCUTANEOUS TRANSPERITONEAL ENDOSCOPIC EXTRACTION OF RENAL COLLECTING SYSTEM STONE CALCULI**

M. Baptistussi, M. Morihisa, E. Gewher, A. Martins

**Background:** The role of laparoscopy in urology is continuing to expand. Indications for laparoscopic stone surgery are limited, but are gaining appeal in certain circumstances. Patients undergoing dismembered laparoscopic pyeloplasty who also have stones in their renal collecting system or ureter are ideal candidates for laparoscopic transperitoneal endoscopic stone extraction.

**Methods:** 15 Patients undergoing dismembered laparoscopic pyeloplasty who also had stones in their renal collecting system had them extracted using a flexible cystoscope. The use of both the laparoscopic and cystoscopic cameras are critical to guide the cystoscope into the collecting system and that intraoperative fluoroscopy is used to aid exploration of the whole collecting system and locating of calculi. The operating time was 93 min (70–183).

**Results:** Stone extraction was successful in all patients as assessed at intraoperative endoscopic examination, intraoperative fluoroscopy and post-operative roentography.

**Conclusion:** Laparoscopic controlled and assisted percutaneous transperitoneal endoscopic extraction of renal collecting system stone calculi is a valuable tool for the endourologist and is likely to gain further appeal in the future as laparoscopy expands.

### **VP13-17 RETROPERITONEOSCOPIC PYELOPLASTY: OUR EXPERIENCE: ABOUT 28 CASES**

Y. Noura, Y. Kallel, A. Dahmani, S. Sallami, Z. Fitouri, A. Horchani

**Background:** Retroperitoneoscopy is minimally invasive and an established procedure for renal surgery. We evaluated our results with retroperitoneoscopic pyeloplasty for ureteropelvic junction (UPJ) obstruction.

**Methods:** In 17 female and 11 male patients, a retroperitoneoscopic pyeloplasty was performed (13 right /15 left). The UPJ was resected in all patients in an Anderson-Hynes pyeloplasty. In all patients a double-J stent was placed.

**Results:** The mean operative time was 228 minutes (range 190–280 minutes), and the average blood loss was 50 mL. There were no intraoperative complications. Eleven of these patients had a crossing vessel which was respected. The postoperative complications was a urinoma in 2 cases, which was punctured and 1 case of an acute pyelonephritis managed with antibiotics. The mean hospitalization time was 4.2 days. The double-J catheter was removed after an average of 4 weeks. The mean follow-up time was 25 months (range 5–67 months). Intravenous urography between 3 and 6 months later showed a permeable junction, an early uréteral passage and a reduction of dilation in all the cases

**Conclusion:** Retroperitoneoscopic pyeloplasty for UPJ obstruction is a safe and effective procedure. Our short-term results are similar to those of open pyeloplasty with the advantage of a minimally invasive approach.

### VP13-18 UPPER URINARY TRACT LAPAROSCOPY IN OBESE PATIENT

R. Maghsoudi, P. Shadpour, K. Mehravaran

**Background:** Morbid obesity is considered to be a relative limitation to laparoscopic surgery and make the procedure with problem to surgeon and the patient. This study reports our experience on massively obese patients undergoing upper tract urologic laparoscopic surgery.

**Methods:** we used the Body mass index (BMI) as an objective index to indicate massive obesity. Retrospective data on 9 patients having a BMI greater than 30 were evaluated. Procedures include 4 nephrectomies, 1 radical nephrectomy, 1 ureteropelvic junction obstruction and 3 ureterolithotomies

**Results:** In this study, the mean BMI was 33.2 (range 30.3 to 48.26). Mean operative time was 195 minutes (range 145 to 250). There was no conversion to open surgery and we didn't had any transfusion, lateralization of the procedure was 3 in right and 6 in left side, we used 4 trocars in left and 5 trocars in 2 right procedures, because of the limitation of the length of the instruments we insert our trocars more higher than usual location of trocar site. We didn't have any significant major or minor complication during the pre and post operative period. Mean post operative hospitalization of the patient was 2.5 days (2 to 4 days).

**Conclusion:** In this study, complication rates for urologic laparoscopic surgery on obese patients weren't significantly higher than in the general population undergoing laparoscopic surgery. It seems that using the one more trocar and choosing the proper location of trocar insertion may be facilitate the procedure.

### VP13-19 COMPARING RENAL CELL CARCINOMA TUMOR SIZE WITH PATHOLOGICAL GRADE: A CONTEMPORARY 10 YEAR EXPERIENCE

J. Jamal, E. Kwon, J. Fracchia, R. Sosa—USA

**Background:** Renal tumor size is known to correlate with Fuhrman grade in renal cell carcinoma (RCC). With the rise in incidental tumors encountered, and the minimally invasive and nephron sparing options available, more can be done to treat these tumors. The question of whether or not to treat these small tumors then arises. We endeavored to characterize the relationship between tumor size and pathologic grade to determine the need to treat small renal tumors.

**Methods:** We queried our institutional renal tumor database to identify nephrectomies performed for clear cell RCC from 1998 and 2008. We reviewed the pathological features of stage, histology, grade, and greatest diameter. We then subdivided our tumors according to size based on current staging: less than 4 cm, between 4 and 7 cm, and greater than 7 cm.

**Results:** A total 190 nephrectomy specimens were available for analysis. Of these, 29 were grade 1 (15%), 88 were grade 2 (46.3%), 49 were grade 3 (25.8%), 24 were grade 4 (12.6%). The median pathological diameter of each grade was 3.0 cm (range 1–8.5), 4.5 cm (1.4–12), 5.0 cm (1.6–14.5) and 6.5 cm (2.7–14), respectively. High grade tumors, defined as grade 3 or grade 4, were found in 29.5% of tumors < 4 cm, 42.2% of tumors 4–7 cm, and 52.6% of tumors greater than 7 cm.

**Conclusion:** Almost 30% of pT1a tumors and 42.2% of pT1b tumors harbored high grade disease. Our findings lead us to believe that small, incidentally found tumors still require the oncologically effective control, regardless of their size.

### VP13-20 LAPAROSCOPIC DISMEMBERED PYELOPLASTY FOR TREATMENT OF RETROCAVAL URETER: 2 YEARS FOLLOWUP IN 12 PATIENTS

X. Gao, J. Qiu, X. Pu

**Background:** The retrocaval ureter is a rare congenital malformation. The surgical management of this disease consists in various procedures such as pyelopyelostomy, ureteroureteroanastomosis or dismembered pyeloplasty. We report our experience in laparoscopic dismembered pyeloplasty for treatment of retrocaval ureter.

**Methods:** All of 12 patients underwent transperitoneal laparoscopic dismembered pyeloplasty because of retrocaval ureter. The preoperative evaluation included intravenous urography (IVU), retrograde pyelography, renal ultrasound, renal scan and sometimes CT angiography to evaluate for crossing vessels. All patients were followed up at least 2 years. The operative data, complications and followup functional data were analysed.

**Results:** All patients had successful operations without conversion. The mean operative time was 65 minutes (62–90 min). Mean blood loss was 50 ml (40 ~ 80 ml). The mean postoperative hospital stay was 4 nights (3 ~ 7 nights). The complication rate was 16.7%. In 2 patients, coexisting renal calculi were successfully removed. At a median follow-up of 30 months, no patients developed persistent loin pain, renal function deteriorated and recurrent stenosis.

**Conclusion:** Laparoscopic dismembered pyeloplasty for treatment of retrocaval ureter is a safe, effective, relative technical ease and well tolerated procedure. Larger series are needed to confirm the advantages before the surgical technique can be advocated.

## VP14: BPH 1

### VP14-01 BIPOLAR VERSUS MONOPOLAR TRANSURETHRAL RESECTION OF THE PROSTATE: A META-ANALYSIS OF RANDOMIZED CLINICAL TRIALS

C. Mamoulakis, D. Ubbink, M. Laguna, J. de la Rosette—Netherlands

**Background:** Incorporation of bipolar technology in TURP (B-TURP) potentially offers advantages over monopolar TURP (M-TURP). To evaluate the evidence, a meta-analysis was performed for the first time. Primary endpoints were efficacy (Qmax, I-PSS) and safety. Secondary endpoints included operation, irrigation, catheterization and hospitalization times.

**Methods:** Based on an unrestricted strategy, the literature was searched up to February 19, 2009 using MEDLINE, EMBASE, SCI and the Cochrane Library to detect all randomized clinical trials (RCTs). Methodological quality assessment was based on the Cochrane Collaboration checklist. Meta-analysis was performed on Review Manager 5.0.

**Results:** Sixteen RCTs (n = 1406 patients) were included. Overall trial quality was low. No differences in short-term efficacy were detected. Data on follow-up >12 months are scarce for B-TURP precluding long-term evaluation. Treating 50 (95% CI: 33–111) and 20 (95% CI: 10–100) patients with B-TURP results in one less TUR-syndrome (RD = 2.0%, 95% CI: 0.9–3.0%; p = 0.01) and clot retention (RD = 5.0%, 95% CI: 1.0–10%; p = 0.03), respectively. Operation times, transfusion rates, retention rates (after catheter removal) or urethral complications did not differ significantly. Irrigation/catheterization duration was significantly longer (p < 0.00001) with M-TURP (WMD = 8.75 hours, 95% CI: 6.8–10.7/WMD = 21.77 hours, 95% CI: 19.22–24.32). Inferences for hospitalization duration could not be made. Plasmakinetic TURP showed an improved safety profile. Data on TUR in saline are not yet mature to permit safe conclusions.

**Conclusion:** B-TURP is preferable due to a more favourable safety profile and shorter irrigation/ catheterization duration. Well-designed multicentre RCTs with long-term follow-up and a cost-analysis are still needed.

### VP14-02 FACE AND CONTENT VALIDATION FOR TRANSURETHRAL RESECTION OF PROSTATE ON URO TRAINER: IS IT WORTHWHILE?

S. Mishra, A. Kurien, A. Ganpule, R. Patel, R. Sabnis, M. Desai—India

**Background:** The only published paper on the validation of the Uro Trainer (Karl Storz GmbH, Tuttlingen, Germany) found unsatisfactory face and content validity. To ascertain, the utility of such a trainer, we performed a similar study. Here in, novice group was redefined as persons having done less than 3 as compared to the 50 TURPs in the published study.

**Methods:** 10 experts and 9 novices (done more than 50 and less than 3 TURP's, respectively) performed a TURP on Uro Trainer, and rated simulator usefulness (7 items), realism (5 items) and overall score (1 item) on a 10 point scale. Statistical analysis was done by students t test (p < 0.05\* significant) using SPSS 15 software.

**Results:** Mean ± S.D of general usefulness, realism and overall score for the experts and novice were 6.4 ± 0.52 vs. 8.44 ± 0.88, 6.3 ± 0.48 vs. 6.89 ± 0.93, and 6.5 ± 0.53 vs. 7.44 ± 0.53, respectively. Novices contemplated Uro Trainer as more helpful than experts in the following aspects of face and content validity; usefulness general (p = 0.0001\*), hand eye coordination (p = 0.04\*), material knowledge and skills (p = 0.02\*), spatial skills (p = 0.003\*), cystoscopy (p = 0.002\*), TURP (0.002\*), visual aspects (p = 0.003\* and overall score (p = 0.007\*). 1 item of usefulness (coagulation) and 3 items of realism (tissue feel, depth feel and capsule identification failed to impress both novice and experts.

**Conclusion:** Novice group (less than 3 TURPS done) found Uro Trainer more useful than the experts group. Further modification is advisable to increase the realism of the virtual training.

### VP14-03 VAPOENUCLEATION OF THE PROSTATE. EFFICACY AND COMPLICATIONS DURING AN INTERMEDIATE FOLLOW-UP INTERVAL LONGER THAN 12 MONTHS

T. Bach, C. Netsch, A. Haecker, T. Herrmann, M. Michel, A. Gross

**Background:** Thulium:YAG (Tm:YAG) VapoEnucleation has been introduced and relief of obstruction was demonstrated. Aim of this study was to proof durability of the outcomes in patients with an postoperative follow-up >12 month.

**Methods:** VapoEnucleation was performed using a 70 Watt continuous-wave-laser. After enucleation tissue was morcellated within the bladder. Patients were followed in terms of improvement of uroflow, intra- and postoperative course and for occurring complications.

**Results:** 88 consecutive patients with prostatic enlargement underwent our initial series of VapoEnucleation. Prostatic volume was 61.3 cc (30–160 cc). OR-time was 72 minutes ± 26.6 and laser-time 32.4 ± 10.1 minutes. Applied laser energy was 123.7 ± 40.6 kJ. Foley catheter-time was 2.1 days on average. In 79/88 patients the postoperative period extended 12 month. 2 patients deceased during the follow-up, 15 patients did not respond. Flow-rate and post-voiding residual urine improved significantly (3.5 vs. 23.3 ml/s; 121.3 vs. 33.4 ml). IPSS decreased from 18.4 to 6.8, QoL dropped from 4.6 to 1.4. Complications were urinary tract infection (n:6), bleeding (n:5), immediate re-treatment (n:2) and urethral stricture (n:1). Short term dysuria (<4 weeks) was recorded in 27% of the patients. 95% of the patients would re-choose VapoEnucleation.

**Conclusion:** VapoEnucleation is a safe and effective minimal invasive treatment modality for BPO. The improvement in voiding and bother is durable in patients with a postoperative period extending 12 month.

### VP14-04 OPTIMAL TREATMENT OF BPH (BENIGN PROSTATE HYPERPLASIA) USING A MULTI-DISCIPLINARY DIOLAS LFD 3000 LASER FOR PHOTOSELECTIVE VAPORIZATION OF THE PROSTATE

J. Neymeyer, T. Wülfing, W. Abdul-wahab Al-ansari, A. Apostolidis, M. Beer

**Background:** Current laser devices used in the treatment of BPH face several limitations, in particular regarding selection of appropriate patients, conditions during treatment and outcome. Our aim was to show that the newly developed, multi-disciplinary laser DIOLAS LFD 3000 using the Leveled Field Density (LFD) 3000 treatment mode is an effective mean of improving all mentioned aspects of the photoselective treatment of BPH.

**Methods:** This study included a total of 50 patients (n = 25 with LFD 3000; n = 25 with PVP Greenlight) who suffered from BPH, where 42 patients took blood thinning drugs. Various important indicators of the pre-, intra- and postoperative settings were evaluated during and after treatment for comparison with the 80 W PVP GreenLight laser system. Consequently, all patients were evaluated regarding IPSS, QoL, PSA, maximal flow rate (Qmax) and post-voiding residual volume (Vres).

**Results:** While complying with all typical advantages of the laser treatment of BPH, the group of patients treated with LFD 3000 showed less typical complications during the first week after treatment such as residual urine, inflammations and pain than the group of PVP patients. Further positive aspects of the DIOLAS LFD 3000 are installation requirements (no high voltage, no external water supply), conditions during treatment (vaporization efficacy, free sight, coagulation effect, etc.) and general comfort for the surgeon (no optical filters needed, handling).

**Conclusion:** The DIOLAS laser using the newly developed LFD 3000 mode for reaching a minimum penetration depth at excellent coagulation has shown significant improvements in comparison to established systems such as the 80 W PVP. The outcome of the treatments has shown convincing results that are supported by mid- and long-term indicators. To conclude, it can be said that the DIOLAS LFD 3000 has proven effective in daily clinical use and implies better handling at lower costs.

#### VP14-05 HIGH POWER 120 W THULIUM LASER FOR VAPO-RESECTION AND VAPO-ENUCLEATION OF PROSTATE OUR EXPERIENCE

S. Mattioli, A. Picinotti, M. Sbragi, M. Sabatino

**Background:** The Revolix laser has been specifically designed to vaporize and incise soft vascular and non vascular tissue with good hemostasis and without damage to surrounding structures. The target chromophore is water. Since the Thullium wavelength vaporize rather than coagulate tissue, the technique offers significant advantages over transurethral resection of prostate (TURP), Holmium procedure (HOLEP), and KTP laser-photoselective vaporization of prostate (PVP). The aim of this study is to evaluate the safety and true efficacy of a new high power 120 W Thulium laser (Thulium/2.013 nm<sup>2</sup>) for transurethral Vapo-resection (VRP) and Vapo-Enucleation (VEP) of benign obstructive prostate tissue (BPH).

**Methods:** From May 2008 to February 2009 a total of 65 patients underwent prostate Vapo-Resection (VRP) and Vapo-Enucleation (VEP) using Thulium laser in our Institution. In details: 50 pts with Vapo-Resection and 15 pts with Vapo-Enucleation (VEP). Patients' age ranged from 51 to 85 yrs. 12 pts presented urinary retention. 10 pts were on anticoagulant therapy. PSA I/f, transrectal ultrasound, biopsies if necessary, AUA-6 Symptom Score (AUA-SS), maximum urinary flow rate (Q-max) and post-void residual (PVR) urine volume, were performed in pre operative period. The Thullium laser was used in conjunction with an frontal and side fiber

engineered to precisely focus laser energy 120 W in order to minimize the risk of incomplete ablation of the prostatic tissue. VapoResection is a protocol whereby the laser is used to vaporize tissue and resect small pieces of prostate—similar to TURP—protocol. The size of the prostate ranged from 30 gr–80 gr in the group. The Vapo-Enucleation (VEP) was performed for large prostate (>80 gr), like Holep procedure. At the end of the procedure a new Wolf morcellator was employed for treat large pieces of residual prostatic tissue. A three way catheter is placed and removed 12 hours later. Patients are release catheter-free. Discharge after 30 hour post operative.

**Results:** The mean operative time for VRP ranged was 40 min and for VEP was 60 min. None patients presented a major complications. At a mean follow up of three months a AUA Symptom Score evaluation, uroflometry, a transrectal ultrasound were performed. At Fischer test we can note a statistically significant difference between pre- operative (mean AUA-SS 21.8, Q Max 0–7.1 ml/sec, PVR 125.6 ml) and post operative (mean AUA-SS 7.1, Q Max 23.1 ml/sec, PVR 18.5 ml/sec) parameters.

**Conclusion:** The high power 120 W Thulium laser Vapo-Resection and Vapo-Enucleation of prostate offer a bloodless procedure, and very little perioperative morbidity. The 120 W Thulium Laser provides immediate reduction of prostatic tissue and consistent TURP-like results, including istological examination. To date the results have been extremely encouraging especially comparing with the 70 W Thulium laser, providing more rapid procedure with less post-operative discomfort and voiding symptomatology.

#### VP14-06 ENERGY DELIVERY REGARDING PROSTATE VOLUME IN GREEN LIGHT LASER (KTP, 120-W) VAPORISATION OF THE PROSTATE

C. Yee, A. Wong, M. Ng, S. Mak, H. Cheung, S. Hou—China

**Background:** Photoselective laser vaporization prostatectomy using 120-W potassium-titanyl-phosphate (KTP) laser is an effective way to remove obstructive prostatic tissue in a haemostatic fashion. We evaluated the impact of the amount of energy delivered with respect to prostate volume on the clinical outcome after laser prostatectomy.

**Methods:** We assessed 72 consecutive patients undergoing green light laser vaporization of the prostate from February 2008 to May 2009. Patients were followed up 8 weeks, 3 months, 6 months and 1 year after their initial laser prostatectomy. Data concerning patients' demographics, prostate volume on transrectal ultrasound (TRUS), International Prostate Symptoms Score (IPSS), quality of life (QOL) score, uroflometry characteristics, and peri-operative course were prospectively collected.

**Results:** The mean age of the patients was 73 yrs (56–94 yrs). 17 patients were on urethral catheter pre-operatively and the mean pre-operative TRUS prostate volume was 56 ml (SD 26.4 ml). The mean pre-operative IPSS, QOL, maximum flow rate (Qmax), postvoid residual (PVR) was 20.3, 4.3, 7.12 ml/s and 120.2 ml respectively. All patients managed to void without catheter after laser prostatectomy. After testing the association between different parameters and energy consumption per prostate volume on pre-operative TRUS, only the difference between pre-operative and 3-month post-operative Qmax was found to be positively correlating with energy consumption. (Spearman's rho coefficient 0.68, p = 0.021).

**Conclusion:** A higher energy delivered correlates a better maximum flow rate in patients after green laser prostatectomy 3 months post-operatively.

#### VP14-07 HOLMIUM LASER ENUCLEATION OF THE PROSTAE: NON-MENTOR-AIDED LEARNING CURVE

C. Jeong, M. Cho, J. Bae, S. Oh

**Background:** Recently, Holmium laser enucleation of prostate (HoLEP) for benign prostatic hyperplasia (BPH) has been introduced in Korea. HoLEP is known to have steep learning curve and, therefore, making the clinical usage limited. The purpose of this study was to analyze the learning curve and early complications following HoLEP procedure.

**Methods:** A retrospective analysis was performed in consecutive 53 patients who underwent HoLEP for lower urinary tract symptom suggestive of BPH from July 2008 to June 2009, by single surgeon (SJO). Perioperative clinical variables including enucleation time, morcellation time, enucleation ratio (enucleation weight/transitional zone volume), enucleation efficacy (enucleated weight/enucleation time) and early complication were analyzed.

**Results:** Mean age of the patients was 68.2 (range 57–77) and prostate volume was 56.9 (21–162)gm, IPSS was 19.5 (6–32), mean enucleation time and morcellation time were 56.4 ± 34.2 min and 13.2 ± 8.5 min, respectively. Enucleation ratio and enucleation efficacy were 0.53 ± 0.24 gm/ml and 0.37 ± 0.28 gm/min. Post-operatively catheter was kept for 2.2 ± 2.4 days and hospital stay was 3.1 ± 1.8 days. There was a total 9 cases (17.0%) of surgery-related complications, including transient urinary retention (3 cases, 5.7%), urethral stricture (3 cases, 5.7%), postoperative bleeding (2 cases, 3.8%) and capsular perforation (1 case, 1.9%). There was no case of transfusion or bladder mucosal injury. There was significant increase between initial 20 cases and the later 34 cases in terms of enucleation efficacy (0.24 ± 0.23 vs. 0.50 ± 0.26,  $p=0.001$ ). However, there was no significant difference in enucleation ratio between them (0.48 ± 0.27 vs. 0.57 ± 0.19,  $p=0.146$ ). Furthermore there was no significant difference in complication rate between them (18.5% vs. 15.4%,  $p=1.00$ ) and it was tolerable level in virtue of proper case selection.

**Conclusion:** Our study showed that HoLEP is safe and it can be overcome gradually although learning curve is steep. To our opinion case selection is necessary to avoid the morbidity associated with the early stage of the learning curve. And further study is awaited in respect to the long-term postoperative follow-up.

#### VP14-08 THE LEARNING CURVE OF 120-W PHOTO-SELECTIVE VAPORIZATION OF THE PROSTATE FOR BENIGN PROSTATIC HYPERPLASIA

Y. Zang, Y. Shan, B. Xue, D. Yang

**Background:** To evaluate the learning curve of 120-W photo-selective vaporization of the prostate (PVP) as an treatment for Benign Prostatic Hyperplasia (BPH).

**Methods:** A total of 30 consecutive patients treated with 120-W PVP were included in this evaluation to study the learning curve of an endourologist with experience at performing 80-W PVP more than 400 cases. To assess the impact of the learning curve on postoperative outcome, 30 patients were divided into three groups: Group 1—patient 1 to 10, Group 2—patient 11 to 20, Group 3—patient

21 to 30. The preoperative and postoperative prostate volume, laser energy, laser time, operative time, laser efficiency were analyzed.

**Results:** The data of the three groups were showed in the table.

peroperative prostate volume (ml)	Postoperative prostate volume (ml)	energeusage (kJ)	Lasingtime (min)	operative time (min)	Laserefficiency (ml/kJ)
Group 1	73.2 ± 14.4	23.4 ± 6.4	89.2 ± 14.5	23.5 ± 3.8	0.57 ± 0.08
Group 2	58.1 ± 10.5	68.4 ± 16.7	52.3 ± 5.9	82.8 ± 23.3	0.54 ± 0.04
Group 3	24.8 ± 8.4	49.8 ± 10.5	98.1 ± 17.7	22.5 ± 4.9	0.53 ± 0.04

The six parameters were compared, and there were no significant differences among the three groups ( $P > 0.05$ ).

**Conclusion:** This study suggests that the learning curve of 120-W PVP is very flat for an endourologist experienced excellently with 80-W PVP.

#### VP14-09 EXPERIENCE IN HOLEP (HOLMIUM LASER ENUCLEATION OF PROSTATE) IN A SMALL UROLOGICAL INPATIENT WARD (BELEGABTEILUNG) WITH AURIGA XL

J. Bubeck—Deutschland

**Background:** Report is given about the learning curve in HoLEP from November 2007 up to May 2009 using a holmium laser system AURIGA XL. It is used also in the treatment of stones in bladder, ureter and kidney with semirigid and flexible instruments. Incisions of bladder neck, urethral strictures and ureterstenosis are also practised.

**Methods:** 75 patients with benign prostate hyperplasia with a prostate volume 30–120 ml were treated with HoLEP (AURIGA XL Fa.: StarMedTec / Endoscopic equipment and morcellator Fa.: Richard Wolf). Outcome of the patients were monitored during the hospital stay and in our outpatient practice usually 4 weeks and three months (if possible) after hospital discharge.

**Results:** On 19 of the first 20 patients the procedure was started as HoLEP and converted to a normal TUR procedure and the operation ended as a TUR resection of the prostate/ TUR-P. In the next 20 patients a conversion to TUR-P was done in the half of the cases. Later on no conversion due to operative conditions was done. The duration of catheter was 1 or 2 days, the hospital stay 5 or 6 days. Because of a defect of the morcellator, one patient got a second anesthesia to complete the morcellation of the enucleates in the bladder. No relevant postoperative bleeding occurred, one blood transfusion was done in a patient with preoperative anemia. Urge incontinence in 9 of the patients was treated successfully with anticholinergic drugs. 4 of the 5 patients with a mild postoperative stress incontinence (grade I) recovered completely under physiotherapy and medication with duloxetine (off label), one patient improved and continues therapy (4 week after discharge). In two cases an urinary retention, about 4 weeks after discharge occurred, one patient needs another indwelling catheter for 3 days, the other patient was treated with TUR-P.

**Conclusion:** The benefit of the better postoperative comfort of the patients compared to TUR-P, the shorter hospital stay and the acceptable learning curve to master the HoLEP procedure, justifies the purchase of such a laser system. If the operator is firm with the alternative methods as TUR-P and open adenomenucleation, it needs about 30–40 cases to establish the new method in the clinic (although it was no supervisor available). It is undisputed that the treatment of stones and stenoses in all localisations of the urinary tract is the domaine of a holmium laser. A holmium laser system



(e.g. AURIGA XL) is the first choice for a small urological department, because of its multipurpose use.

### VP14-10 BIPOLAR ENDOSCOPIC ENUCLEATION IN THE MANAGEMENT OF PATIENTS WITH BIG BENIGN PROSTATIC ENLARGEMENT

S. Chan, Y. Chiu, M. Yiu

**Background:** Surgical management for big benign prostatic enlargement (BPE) is problematic for urologists. Standard recommendation is still open enucleation but is well known to have the problems of hemorrhage, prolonged catheterization and hospital stay. We investigated the use of bipolar endoscopic enucleation (BEE) in managing this group of patients.

**Methods:** From the period December 2008 to May 2009, 18 consecutive patients with the diagnosis of BPE whose prostate volume was estimated to be above 80 ml on transrectal ultrasound (TRUS) measurement were recruited. The preoperative, perioperative and postoperative data were recorded and reported.

**Results:** 18 patients of mean age 73.2 years old were recruited 14 of them were in retention of urine. The mean prostate size was 110.6 (80–192)ml. Average operating time was 141.5 (range 75–199) min. 4 patients required transfusion. Concerning morbidities, one patient had fever and urinary tract infection after surgery and one had secondary hemorrhage 10 days after surgery. There was no 30-day mortality. The average catheterization time was 2.6 days and hospital stay was 3 days. 10 patients were followed up 3 months after surgery. Average prostate volume as 27.8 ml, PSA 1.85 and the average Qmax improved from 5.5 ml/s preoperatively to 19.1 ml/s, residual volume from 695.8 ml to 65.8 ml. IPSS from 16.2 to 8.4 and QOL from 3.6 to 1.7.

**Conclusion:** This represents the initial experience of bipolar endoscopic enucleation for patients with big BPE. The results were satisfactory in terms of speedy post-operative recovery and good symptomatic and functional outcome on early follow up. The transfusion rate was found to be significant in the series, though the complication rate was low. We expect the transfusion rate to decrease with improvement in experience.

### VP14-11 TM:YAG LASER PROSTATECTOMY. INTERMEDIATE-TERM RESULTS IN SUBGROUPS $\geq 75$ YEARS AND $\geq$ ASA 3

T. Bach, C. Netsch, A. Haecker, M. Michel, T. Herrmann, A. Gross—Germany

**Background:** Aim of this study was to evaluate intermediate-term efficacy of transurethral prostatectomy in older or multimorbid patients. Outcomes and complications of patients after a postoperative follow-up period of 12 month were analysed and compared to patients younger than 75 years and ASA status below 3 respectively.

**Methods:** Laser prostatectomy was performed using a 70 Watt Thulium:YAG 2 micron continuous-wave-laser in combination with continuous-flow laser resectoscope and mechanical tissue morcellator. Patients were followed in terms of improvement of uroflow and post-voiding residual urine, intra- and postoperative course and for occurring complications.

**Results:** 80 consecutive patients were included in this prospective trial. 33 patients with ASA  $\geq 3$  (group I) were compared to 47 patients with ASA status 1 and 2 (group II). Mean ASA score was 3.1 in group I and 1.8 in group II. Both groups were equal in terms of preoperative TRUS volume, Qmax, QoL, IPSS and PVR.

Postoperative outcome was comparable in both groups, with significantly higher improvement in IPSS in group II. In a second subgroup analysis patients were stratified according to age. Group III included patients with an age  $\geq 75$  years, group IV patients  $\leq 75$  years. Mean age was 80.1 year in group III and 66.6 in group IV. Preoperative data was comparable in both groups, as well as improvement in postoperative voiding and QoL.

**Conclusion:** Transurethral Tm:YAG laser prostatectomy is a safe and effective in all patients. Age and co-morbidity does not influence operative outcome.

### VP14-12 GREENLIGHT HPS™ LASER PHOTOSELECTIVE VAPORIZATION PROSTATECTOMY FOR BPH—2 YEAR FOLLOW UP

E. Heinrich, T. Meyer, G. Wendt—Nordahl, T. Bach, M. Michel, A. Haecker—Germany

**Background:** We evaluated our initial experience on Photo-selective Vaporization of the Prostate (PVP) with the GreenLight HPS™ laser of 139 men with benign prostatic hyperplasia (BPH) to investigate its safety and efficacy.

**Methods:** Transurethral PVP was performed using a GreenLight HPS™ side-firing laser system. International Prostate Symptom Score (IPSS), Quality of Life (QoL) score, serum prostate specific antigen (PSA), maximum flow rate (Qmax), post void residual (PVR) and transrectal ultrasonography (TRUS) were determined preoperatively and in the follow up examination. Operations times, energy usage, catheter time and complication were recorded. Up to date 21 of 139 had follow up examination further 50 patients are already scheduled for the next months.

**Results:** 139 consecutive patients with a median age of 73 (49–87) years underwent GreenLight HPS™ laser PVP from January 2007 through December 2008. Treated patients had oral anticoagulant therapy in 68 cases (49%) which was stopped before surgery. Median prostate volume was 56 (20–120) mL with a median PSA of 4.5 (0.1–35) ng/mL. Mean operative times and energy use were 60 (20–190) min and 244 (16–550) kJ, respectively. Two procedures have been converted to bipolar TURP due to technical problems. Mean catheter time was 1.15 (1–4) days. Perioperative two patients developed fever, one got a pyelostomy due to dilatation of the renal pelvis and three developed acute urinary retention. Follow up examination showed mean reduction of prostate volume of 47% (46 to 21.9 ml), reduction of mean IPSS score from 17.8 to 7.3. Mean PVR decreased about 47% (107 to 50.7 ml). QoL improved from 3.8 to 1.5.

**Conclusion:** Our two year experience of GreenLight HPS™ laser PVP suggests effective BPH treatment with low complication rates. Since the follow up evaluation is going on, we hopefully will be able to show more detailed results.

### VP14-13 HOLEP: TECHNIQUE IS MORE IMPORTANT THAN POWER

R. Reuther, P. Gilling, M. Fraundorfer, D. Bell

**Background:** Unlike prostatic ablation, excisional techniques such as HoLEP rely on anatomical dissection rather than 'raw power' to remove tissue. To determine whether patient outcome is compromised by lower power approaches (<60 watts), a comparative study in urodynamically obstructed patients comparing 50 W and 100 W devices in small prostates (<100 g) was undertaken.

**Methods:** 10 patients undergoing low power HoLEP were compared to matched 10 patients who underwent the usual high-power (100 W) procedure both utilising soft-tissue morcellation. Inclusion criteria were: Prostate volume by TRUS <100 ml, PSA, IPSS > 10, Qmax <15 ml/s, Schaffer Grade > 2, Residual volume <400 ml. Post-operative variables including Qmax, IPSS score, TRUS volume, PSA and adverse events were assessed at 1,3,6 and 12 months.

**Results:** The mean age was 68.9 years in the low power group and 70.0 years in the High power group. Patients were well matched for other pre-operative variables. The path weight was 20.3 g and 24.9 g respectively, the mean total operating time was 46.1 mins (low power) and 46.3 (high power) and the energy used was 53 and 103 kJ respectively ( $p < 0.01$ ). 20% patients required post-op irrigation (low power) compared to 6% (high power). Catheter times and hospital times were 21 vs 17 hrs and 34 vs 31 hrs respectively. Symptom scores and flow rates were similar at 1 month. There were no moderate or severe adverse events in either group.

**Conclusion:** There were no major differences between the 2 groups suggesting that, for experienced operators, power is less relevant than technique.

#### **VP14-14 LITHIUM TRIBORATE-LASER VAPORISATION OF THE PROSTATE USING THE 120 W HIGH PERFORMANCE SYSTEM (HPS) LASER: HIGH PERFORMANCE ALL THE WAY?** L. Hefermehl, D. Strebels, O. Gross, T. Sulser, H. Seifert, T. Hermanns

**Background:** It has recently been shown that laser fibre deterioration leads to a significant decrease of power output during 80 W KTP laser vaporisation (LV) of the prostate. This decrease results in ineffective vaporisation especially towards the end of the procedure. For the new 120 W lithium triborate (LBO) HPS laser not only higher power but also changes in beam characteristics and improved fibre quality have been advertised. However, high laser power has been identified as a risk factor for laser fibre degradation. The objective of our study was to investigate changes of the laser fibre and of power output during 120 W LBO-LV.

**Methods:** Between July 2008 and May 2009 46 laser fibres were investigated during routine 120 W LBO-LV in 35 consecutive patients. Laser beam power was measured at baseline and after the application of every 25 kJ during the LV procedure. Postoperatively, the surgeon subjectively rated the performance of the respective fibre on a scale from 1 to 4 (1 indicating perfect and 4 insufficient performance). The surgeons were blinded to the results of the previously performed measurements. Additionally, microscopic examination of the fibre tip was performed after the procedure.

**Results:** Median energy applied was 218 kJ (range 100–275 kJ). Changes of power output were similar for all fibres. Typically, a steep decrease of power output within the first 50 kJ was followed by a continuous mild decrease until the end of the procedure. After the application of 50 kJ the median power output was 58% (35–88%) of the baseline value. The median power output at the end of the 275 kJ-lifespan of the fibres was 48% (23–62%). The median surgeons rating of the overall performance of the laser fibres was 2 and the median estimated final decrease of power output 50%. Some degree of degradation at the emission window was microscopically detectable in all cases after the procedure. However, even after the application of 275 kJ, these structural changes were only mild.

**Conclusion:** Minor degradation of the laser fibre was associated with a significant decrease of power output during 120 W LBO-

LV. However, following an early, steep decrease, power output remained relatively constant on a medium level for the rest of the fibres' lifespan. The subjective rating by the surgeons is in accordance with these findings. Improved properties of the LBO laser and better fibre quality resulted in an only moderate decrease of power output which allowed for a consistently effective performance.

#### **VP14-15 TRANSURETHRAL BIPOLAR PROSTATE BENIGN HYPERPLASIA RESECTION: LONG-TERM RESULTS. SCIENTIFIC RESEARCH INSTITUTE OF UROLOGY, MOSCOW, RUSSIAN FEDERATION**

E. Borisenko, D. Merinov, R. Fatikhov

**Background:** Transurethral bipolar resection is a contemporary minimal invasive BPH treatment option, free of such side effects of traditional monopolar surgery like urethral and soft tissues burns, erectile dysfunction, TUR-syndrome. This research for long-term results is based on the experience of 153 patients treatment during 2 years.

**Methods:** Transurethral bipolar resection was used in treatment of 153 patients with BPH in the period from 2006 till 2008. In 27 cases the follow up period was 3 years. Preoperational complex urologic research included standard clinical analysis, IPSS score, QoL score, digital rectal investigation, transabdominal ultrasound prostate investigation, residual urine volume and PSA serum concentration determination. Test surveys were held before the patient's discharge from the hospital, 1, 3, 6, 12, 24 months after the procedure.

**Results:** Long-term outcomes in observed group showed the 79% decrease of IPSS score meanly from 20.7 to 4.4, QoL decreased from 5.2 to 1.5 (71%), Qmax meanly increased from 7.7 to 21.3 ml/s, average prostate volume reduced from 66.3 to 18.5 cm<sup>3</sup>, residual urine volume decreased meanly from 122.5 to 24.2 ml (80%). No cases of erectile dysfunction complication.

**Conclusion:** This data shows high efficiency and safety of bipolar transurethral resection in long-term outcomes. The concerned treatment option does not cause an erectile dysfunction, and that is very important in quality of life care. Thus we can say that it's possible that transurethral bipolar resection can be considered as "gold standard" to replace a traditional monopolar electrosurgery.

#### **VP14-16 COMBINATION OF TRANSURETHRAL RESECTION AND PHOTOSELECTIVE VAPORIZATION FOR THE TREATMENT OF HIGH VOLUME PROSTATE**

F. Aksit, A. Kural, H. Akpinar, I. Tufek, F. Atug

**Background:** We evaluated early follow-up and perioperative morbidity of transurethral resection of the prostate (TURP) followed by photoselective vaporization of the prostate (PVP) as a combination therapy in patients with benign prostatic hyperplasia (BPH) larger than 80 gr.

**Methods:** 80 patients with bladder outlet obstruction due to benign prostatic hyperplasia (>80 gr) underwent TURP alone (n = 45) and TURP + PVP (n = 75) in a prospective, non-randomized trial. Endpoints of the study were maximum urinary flow rate (Qmax), post-void residual volume (Vres) and International Prostate Symptom Score (IPSS). Additionally operative time, decrease of serum PSA level in follow-up, length of catheterization and length of hospital stay were also evaluated. Standard TURP was performed for the first group. In TURP + PVP group transurethral resection was performed initially to ease the work of PVP by

making a fine channel through the prostatic urethra mainly targeting the resection of median lobe.

**Results:** Preoperative evaluation of the baseline characteristics was similar for both groups. There were no significant differences between the groups in regard to operative time, and outcome of Qmax, Vres, and IPSS. Early decrease of serum PSA level with combination therapy is remarkable. Significant statistical difference was observed in length of catheterization ( $p < 0.001$ ), and length of hospital stay ( $p < .001$ ) time in the favor of TURP + PVP group.

**Conclusion:** TURP + PVP combination therapy is an effective alternative for large prostates providing both, excellent intra and post operative safety of PVP and proven long term benefits of TURP.

#### **VP14-17 BIPOLAR TURP- DOES IT SCORE OVER MONOPOLAR TURP? DR. ULHAS SATHAYE SAHAYOG SPECIALITY HOSPITAL, JAMNAGAR, INDIA**

U. Sathaye

**Background:** The 2 technologies were compared to judge the efficacy and supremacy of one over the other. The variables studied were: catheter time, Bleeding, Patient subjective comfort, Surgeons' feeling, immediate surgical outcome (Uroflow), complications.

**Methods:** 50 cases were included in each group viz. Group 1 (Bipolar) and Group 2 (Monopolar). They were matched regarding prostate volume (35 to 85 grams) and patient age. Water was used for monopolar and saline in the bipolar group. Regional anaesthesia, antibiotics, post-procedure inj frusemide, 20Fr 2 way catheter, gentle traction for 2 hours was common for all. Catheter time ranged from 24 to 48 hours.

**Results:** In group 1 40/50 got their catheter out at 24–30 hrs, the average blood loss was about 2 ml/gm. (colorimetric method), the flow rates improved, the subjective comfort was 2 for the majority on a scale of 0 to 5 (where 0 was no discomfort and 5 was severe symptoms), surgeons' comfort was excellent with this technology and 2 cases had reactionary bleed which required bedside bladder wash. In group 2 catheter time was 48 hrs in the majority, the blood loss was 3 ml/gm, subjective comfort was 3, flow rates improved, no patient had bleeding and surgeons' comfort was inferior to Bipolar technology.

**Conclusion:** Bipolar scores over Monopolar technology in subjective patient comfort, catheter time which is shorter and surgeons' comfort in the ease of resection. The other variables are the same in both the technologies.

#### **VP14-18 INCIDENTAL PROSTATE CANCER REVISITED: EARLY OUTCOMES OF PT1A AND PT1B AFTER HOLEP**

M. Humphreys, R. Nunez, P. Andrews

**Background:** Incidental prostate cancer (CaP) after treatment of benign prostate hyperplasia (BPH) is becoming less common due to the emergence of ablative therapies. The purpose of this research is to re-examine the clinical outcomes and importance of pT1a and pT1b prostate cancer in a contemporary cohort of patients after holmium laser enucleation of the prostate (HoLEP).

**Methods:** We retrospectively analyzed our IRB approved HoLEP database. We identified all patients with the diagnosis of prostate cancer prior to and after their HoLEP. We examined pre-operative PSA, prostate biopsy history, pathologic features, post-operative

change in PSA, and progression of disease. Patients were matched to a control group with benign pathology for outcome comparisons.

**Results:** The database consisted of 150 consecutive patients ages 54–89 years and prostate sizes from 25–243 cm<sup>3</sup>. Fifteen patients were identified with prostate cancer, 12 with pT1a or pT1b disease. All patients had at least one biopsy performed prior to HoLEP. The hospitalization, catheterization times, complications, and functional outcomes were similar among all groups. Two patients with pT1a disease required additional treatment due to a rising PSA: 1 patient underwent radiation and hormone therapy and 1 patient underwent RARP. All other cancers are being closely followed.

**Conclusion:** The functional benefits of HoLEP are well established. The incidental prostate cancer detection rate of 10% shows the benefit of pathologic analysis. While only 13% of these patients required additional treatment, the relevance is significant because these patients would otherwise go untreated or have delayed therapy. The impact on survival requires additional study.

#### **VP14-19 PRELIMINARY OUTCOMES OF SHORT-TERM INDWELLING URETHRAL CATHETER AFTER TRANSURETHRAL RESECTION OF THE PROSTATE**

Y. Ozgok, M. Ates, E. Kaya, M. Hoscan, S. Basal, M. Dayanc—Turkey

**Background:** To investigate the effect and safety of short-term indwelling urethral catheter after transurethral resection of the prostate (TURP).

**Methods:** The evaluation before treatment included, serum PSA level, International Prostate Symptom Score (IPSS), peak urinary flow rate (Qmax), transabdominal ultrasonography to estimate prostate size and postvoid urine residue (PVR). The operative duration, complications were noted postoperatively. The bladder catheter was removed at twelfth hour for prostates <80 gr in 37 patients and at twenty-fourth hour for prostates ≥80 gr or for patients followed by mild hematuria in 10 patients. After surgery patients were reassessed for the IPSS, Qmax, Qave and PVR at first and third month.

**Results:** The results of 47 patients, who underwent TURP with short short-term indwelling urethral catheter, and followed-up for three months, were enrolled in the study. The mean age of the patients, volume of prostates, operative time and hospital stay were 66.2 (44–86) years, 58 (27–190) gr, 60 (20–140) minutes and 21 (18–30) hours respectively. Postoperatively, there was moderate dysuria in 5 (9%) and hematuria in 10 (18%) patients with a mean duration of 4 and 2 weeks respectively. Three patients required recatheterisation following removal of indwelling urethral catheter. Compared with the preoperative period, postoperative mean Qmax increased from 11.3 to 25.7 and PVR decreased from 139 to 48 cc significantly ( $p < 0.001$ ). There were also improvements in postoperative IPSS values ( $p < 0.01$ ).

**Conclusion:** Short-term indwelling urethral catheter provides short hospitalization time, less dysuria and seems to be comparable with standard TURP and green-light laser vaporization of the prostate.

#### **VP14-20 GREENLIGHT HPS LASER PHOTOSELECTIVE VAPORIZATION PROSTATECTOMY (PVP) FOR SYMPTOMATIC BENIGN PROSTATIC HYPERPLASIA (BPH): INTERMEDIATE OUTCOMES**

K. Strom, M. Spaliviero, C. Wong—USA

**Background:** Greenlight HPSä laser PVP is a relatively new technology for the treatment of lower urinary tract symptoms

(LUTS) secondary to BPH. We review our intermediate clinical outcomes.

**Methods:** We prospectively evaluated our experience with Greenlight HPSä laser PVP. Patients underwent Greenlight HPSä laser PVP by a single surgeon (CW). All had American Urological Association Symptom Score (AUASS), maximum flow rate (Qmax) and post void residual (PVR) determinations and volumetric measurements with transrectal ultrasonography (TRUS). Under general anesthesia, transurethral PVP was performed using a Greenlight HPSä side-firing laser system through a 23 Fr continuous-flow cystoscope with normal saline irrigant. Laser and operative times and energy usage were recorded. AUASS, Qmax and PVR were evaluated 1, 4, 12, 24 and 52 weeks and 18 and 24 months post-surgery.

**Results:** 132 consecutive patients were identified, having a mean age of  $69 \pm 9$  years. The mean prostate volume was  $71 \pm 40 \text{ cm}^3$ . Mean laser time and usage were  $14 \pm 8$  minutes and  $91 \pm 54 \text{ kJ}$ , respectively. All were outpatient procedures with 74 (56%) patients catheter-free at discharge. Seven patients developed a urinary tract infection. Eleven patients had persistent hematuria for over a week. Seven patients had persistent catheter dependent urinary retention. No urethral strictures or urinary incontinence were noted. Mean AUASS decreased significantly from 22 to 8, 7, 5, 5, 4, 3 and 3 ( $p < 0.05$ ) during the follow-up interval.

**Conclusion:** Our intermediate results demonstrate that Greenlight HPSä laser PVP is safe and effective for the treatment of LUTS secondary to BPH.

## VP15: PCNL-2

### VP15-01 PERCUTANEOUS NEPHROLITHOTOMY IN MALFORMED KIDNEYS: SINGLE-CENTER EXPERIENCE

L. Tahmaz, M. Zor, Y. Ozgok, S. Bedir, S. Basal, M. Dayanc

**Background:** Percutaneous nephrolithotomy (PCNL) for complex calculi within malformed kidneys can be challenging because of the abnormal anatomy. We present our 3-year experience with PCNL in such patients.

**Methods:** We performed PCNL on 9 patients with complex calculi and anomalous kidneys, including 4 with horseshoe kidneys, 2 with ectopic kidneys, 1 with a ptotic kidney, 1 with a hypermobile kidney and one with osteogenesis imperfecta which is not an actually renal malformation but included the study due to difficult patient positioning for PCNL. The procedure was performed by choosing either anterior or posterior approaches depending on the kidney anomaly. In the patient with osteogenesis imperfecta and in ectopic kidneys laparoscopy was used.

**Results:** A single-stage PCNL resulted in complete clearance in 7 patients (77%). A second-look procedure was not performed to any of the cases. Shockwave lithotripsy was performed in one patient with horseshoe kidney and complete stone clearance was achieved. Subcostal renal accesses were performed in all patients except one with ptotic kidney. In this patient a suprailiac access was performed. Second tract was not needed. The procedure was guided by laparoscopy in two patients with calculi in ectopic kidneys and a patient with osteogenesis imperfecta. Percutaneous access with the guidance of laparoscopy could not be achieved in one patient with ectopic kidney and he was treated with open surgery. Serious complications were not encountered.

**Conclusion:** Patients with malformed kidneys can be managed safely and effectively with PCNL when they are properly selected and appropriately assessed before operation.

**Background:** To evaluate retrospectively the results of MN and to analyze the role of the Perc'N'Circle device in stone retrieval (for MIP). The analysis endpoints were assessed by mean operative time (MOT); % blood transfusion (BT); stone free rate (SFR); MIP time (MIPT) and % device failure for Perc'N'Circle stone extractor.

**Methods:** Between January 2007-February 2009 52 patients underwent MN. Median age of the patients was 48 (range 6–61 years). (18 males; 32 females). Mean Stone size was 2.8 cm (2.2–3.8 cm) A miniaturized 18-Fr Amplatz sheath was adopted in 39 cases; a 22Fr one in 13 cases. Median nephrosopes calibre was 10.8 Fr (range 17–19 Fr). We used a fluoroscopic-guided puncture of the kidney and a single step dilatation of the access tract in all the cases. A ballistic nephrolithotripsy with the patient in a prone position was performed in all the procedures. For stone retrieval (MIP) we used the Perc'N'Circle atraumatic basket.

**Results:** Median operative was 33 min. Stone free rate at 6 months was 92.3%. Median MIP time was 12 min (range 8–24) We report no device failure in every procedure. Severe complications, such as sepsis or bleeding requiring blood transfusion, did not occur in any of the procedure.

**Conclusion:** Morbidity rate associated with MN and MIP are comparable to the standard PCNL technique. The use of a smaller calibre tract may preserve renal parenchyma and increase post-operative patient comfort. MN may be considered a complementary or alternative technique to the standard PCNL. Main advantage of Perc'N'Circle is the easy expansion, which offers both complete caliceal opening and distension with minimal trauma and blood loss. Device flexibility offers an easy positioning over both ampullar and caliceal mucosa and it allows an easy retrieval and release of stone fragments. Perc'N'Circle is a safe device which reduces the MIP operative time.

### VP15-02 MINIPERCUTANEOUS NEPHROLITHOTRIPSY (MPCNL) AND MINIPERCUTANEOUS NEPHROLITHOLAPAXY (MIP) USING THE PERC'N'CIRCLE ATRAUMATIC BASKET: A RETROSPECTIVE ANALYSIS OVER 2-YEARS EXPERIENCE

U. Anceschi, C. Molinari, C. Anceschi, M. Gallucci

### VP15-03 CURABLE DISEASE IN THE INCURABLE

M. Nuttall, N. Smith, R. Dasgupta, K. Thomas, J. Glass

**Background:** Abnormal anatomy and associated co-morbidities, especially respiratory compromise, make managing stones in neurological patients challenging.

**Methods:** We reviewed our experience of stone surgery on severely neurologically disabled patients over a one year period.

**Results:** 16 patients were identified; 4 with spina bifida, 3 with spinal injury, 3 with multiple sclerosis, 3 with muscular dystrophy and 3 had cerebral palsy. 3 had long-term respiratory support; 2 had solitary kidneys; 1 stone was in a transplanted kidney. The mean age was 43.7 years. They underwent 25 procedures: 6 percutaneous nephrolithotomies, 13 ureteroscopies, 2 cystolithotomies, 2 stent removals, 1 suprapubic catheterisation and 1 open pyelolithotomy. Patients had high stone burdens (4 had bilateral disease with 3 staghorns). The mean stone burden was 257 mm<sup>2</sup>. Optimising patients for surgery was challenging—infections postponed 6 procedures. Median length of stay was 5 days. Postoperatively 3 patients had transiently increased creatinine (mean 79%); 7 had a decrease in haemoglobin (mean 1.6 g/dL); 5 suffered major complications (all sepsis). There were no deaths. One patient remains unfit for surgery. Another with permanent respiratory support is being managed conservatively due to risks.

**Conclusion:** These patients represent an endourological challenge. Limiting risk with minimally invasive approaches and close support from anaesthetists and respiratory physicians makes safe surgery possible.

#### VP15-04 COMPARISONS OF PERCUTANEOUS NEPHROLITHOTOMY WITH MINIPERC AND ADULT-TYPE NEPHROSCOPE IN PEDIATRIC KIDNEY STONES

O. Tanriverdi, M. Kendirci, M. Kadihasanoglu, M. Sýlay, M. Aydin, C. Miroglu

**Background:** To compare the outcomes of percutaneous nephrolithotomy (PCNL) with mini-nephroscope (miniperc) and adult-type nephroscope in pediatric stone disease.

**Methods:** During a 3-year-period, 28 children (<16 years of age; 14 male and 14 female) who had undergone PCNL due to kidney stones were included into this analysis and divided into two groups; Group-1: Miniperc (n=17, 17 Ch nephroscope) and group-2: adult-type nephroscope (n=11, 24 Ch nephroscope). The former underwent ordinal dilation and the latter underwent balloon dilation for renal access under fluoroscopic guidance. Both groups were statistically compared for age, gender, body mass index (BMI), stone burden and localization, operation and fluoroscopy time, stone clearance and complication rates, blood transfusion, and hospital stay. Chi-square and t tests were used for comparison between the groups and p < 0.05 was considered as significant.

**Results:** Mean age in the miniperc group was significantly younger than the adult-type-nephroscope group (8.74 ± 3.62 vs 12.36 ± 3.23, p < 0.05). However, no statistically significant difference was found between the two PCNL groups regarding BMI, stone burden and localization, stone clearance and complication rates, fluoroscopy times, blood transfusion rate, and hospital stay (p > 0.05). No major complication was recorded for the procedures.

**Conclusion:** Due to comparable stone clearance and complication rate with adult-type nephroscope, miniperc should be considered an option in pediatric stone disease in order to protect the developing kidneys.

#### VP15-05 LOW-RISK FOR COLONIC INJURIES DURING SUPINE VERSUS PRONE PERCUTANEOUS NEPHROLITHOTOMY: WHICH IS THE RATIONALE?

L. Ruggera, P. Beltrami, F. Zattoni—Italy

**Background:** Iatrogenic lesion of colon represents a rare major complication of percutaneous nephrolithotomy (PNL). Several studies have underlined that colonic injuries rate is lower during supine rather than prone PNL, as resulting by the medical records on adverse events. Is there a rationale explaining this assessment? Aim of this prospective study was to analyze the displacements of the ascending/descending colon and the omolateral kidney in supine and prone position, by means of preoperative abdominal computed tomography (CT).

**Methods:** 17 stone patients candidate to PNL preoperatively underwent abdominal CT scan, with and without contrast, in prone and supine position. Exclusion criteria were: congenital anatomical anomalies of the kidney or of the upper urinary tract; skeletal or abdominal abnormalities; previous upper urinary tract surgical treatments or infections and previous abdominal surgery. Supine position was obtained placing a roll, 10 cm in diameter, under the abdominal flank omolateral to renal stone. We identified two anatomical parameters, the colon-axial angle and the reno-colic angle, directly measured using the CT scan, in order to analyse the abdominal topography in prone and supine positions.

**Results:** Supine position was characterized by a median oblique inclination of 30° (interquartile range 25°–35°). CT scan in supine position evidenced a more medial displacement of colon respect the same in prone position, withdrawing that from the puncture area. Statistical analyses of the considered angles evidenced a significant difference between their values in prone and supine position, confirming a medial colon displacement in the latter case. Stratifying our patient group for gender, as far as for body mass index (< and >25 kg/m<sup>2</sup>) and umbilical waist circumference (< and >100 cm), it has been confirmed the presence of a similar statistically significant difference.

**Conclusion:** Our study supports the clinical observations that percutaneous approach to the lower renal pole in supine position is characterized by a lower risk of colonic injury than in the prone. The rationale is that, rolling from prone to supine position, there is a medial displacement of the colon far from the site of ideal percutaneous puncture of the kidney, independently of gender, build and central body fat release.

#### VP15-06 PERCUTANEOUS NEPHROLITHOTRISPY IN HORSESHOE KIDNEYS: THE AEGEAN EXPERIENCE

A. Skolarikos, A. Tefekli, B. Apostolis, M. Binbay, A. Muslu-manoglu, D. Charalambas—Turkey

**Background:** To evaluate the outcome of percutaneous nephrolithotomy (PCNL) in horseshoe kidneys performed at two neighbour countries.

**Methods:** We retrospectively reviewed all patients presenting to our centres with a horseshoe kidney and urolithiasis treated by PCNL. The indications for PCNL, the stone burden, surgical details, incidence of intraoperative and postoperative complications and use of auxiliary procedures (second-look PCNL, ureteroscopy, and ESWL), hospital stay, transfusion requirements, and stone-free rates at discharge were recorded.

**Results:** A total of 58 patients with horseshoe kidneys were offered PCNL at our departments from January 1997 to December 2008. All PCNL procedures were performed in a one-session technique with fluoroscopic guidance in a prone position. The mean patient age was 39.9 years (range 16–65). The mean stone size was 7.6 cm<sup>2</sup> (range 1–45 cm<sup>2</sup>). Access to the horseshoe kidneys was supracostal in 11 (19%) and subcostal in 47 kidneys (81%). A single tract was

used in 45 (77.6%), two tracts were created in 12 kidneys (20.7%) and three tracts in the remaining one kidney (1.7%). Significant hematuria requiring blood transfusion occurred in 8 patients (13.8). Postoperative complications were seen in nine procedures (15%) and included fever in 6 (10%), septicemia in two (3.3%) and prolonged ureteral leak in two (3.3%). All complications were successfully treated. Auxiliary procedures were required in 16 patients (27.6%) and included second-look PCNL in 2 (3.4%), ESWL to fragment residual stones in 11 patients (19%) and combination of ESWL and ureteral stent insertion in one patient (1.7%). The mean hospital stay was 70.20 hours (range 40 to 384 hours). The stone-free rate was 65.5% at discharge and 93.1% at 3 months. Stone analysis showed calcium oxalate composition in 86.2% calculi.

**Conclusion:** Although being technically demanding, PCNL is a safe and effective procedure in the treatment of large stones within horseshoe kidneys.

**VP15-07 TUBELESS PERCUTANEOUS NEPHROLITHOTOMY TECHNICAL ASPECTS AND FUNCTIONAL OUTCOME. ABOUT 39 CASES**

K. Yousri, N. Yassine, B. Ms, F. Zouhair, H. Mohamed, H. Ali

**Background:** Since the first description of the percutaneous nephrolithotomy (PCNL), the placement of a nephrostomy tube at the end of procedure was regarded as essential. Recently, the need for the external drainage was questioned and the concept of the PCNL with an internal drainage only “tubeless” was born. Through a series of 39 patients, we evaluated the feasibility, the effectiveness and the morbidity of this technique.

**Methods:** From June 2007 to March 2009, 39 patients underwent tubeless PCNL in ventral position and with only one lower caliceal way. The intervention was ended by draining the urinary tract by an internal double J stent in an antegrade manner. The patients were followed up at our outpatient clinic.

**Results:** They were 21 men and 18 women. The average patient age was 49, 7 years (19–75 years). The stone was left in 22 cases, Staghorn partial in 11 cases and pyelic and/or pyelocaliceal in 28 cases. The average stone size was 31 mm (20–65 mm). The average volume of irrigation used was of 24 liters (12.3 with 50.61). The average operational duration was 142 minutes (85 to 260 min). A bleeding occurred during the intervention was noted in two patients and required a blood transfusion in a third case. The plain radiography, made at the next day after surgery, had shown a stone free status in 22 cases and one or more fragments lower than 5 mm in 9 cases and a residual stone higher than 5 mm in 8 cases. This last group performed a secondary extracorporeal lithotripsy. The average pain value, evaluated 2 hours after surgery by the analogical visual scale, was of 2.2. Post operative fever was noted in 2 cases. The mean hospital stay was 2 days (range 1–5).

**Conclusion:** The PCNL “tubeless” without insertion of nephrostomy tube is an effective and safe method and reduced hospital stay and post operative pain without serious complications.

**VP15-08 FLEXIBLE CYSTOSCOPE ASSISTED PCNL IN TREATING COMPLICATED RENAL CALCULI**

G. Wang

**Background:** To investigate the role of flexible cystoscope in treating complicated renal calculi during PCNL.

**Methods:** Between July 2006 and June 2009, 215 patients with complicated renal stones were treated through PCNL. Flexible

cystoscope was utilized in 32 cases whose clinical data were analyzed.

**Results:** 19 were male and 13 were female. The mean age was 51 ys (24~71) and the mean stone maximum length was 52 mm (6~95). Flexible cystoscope was used in first session in 11 cases and in second session in 21 cases. In case of no additional tract all the 32 cases would remain residue stones without the aid of flexible cystoscope, thus the stone free rate was 74.5% among the 215 patients. With the combination of flexible systoscope 22 more patients were rendered stone free and the stone free rate was raised up to 85.1%. The utilization of flexible systoscope in PCNL is suitable for smaller residue calyceal stones, “staghorns”, multiple site residue stones that cannot be treated through nephroscope, especially those shaded by the liver, spleen, lung, colon. The size of the operating tract need to be F18–F22. The angle between the aimed stones and the operating tract is not too sharp, thus ease the manipulation of the flexible scope. The residue stones can be fragmented in situ by holmium laser or be moved to renal pelvic by a basket then cleared through a nephroscope.

**Conclusion:** Flexible systoscope assisted PCNL may raise the stone free rate without additional tracts in treating complicated renal calculi.

**VP15-09 A TECHNIQUE FOR PERCUTANEOUS ACCESS TO NON-DILATED PELVICALICEAL SYSTEM: ARTIFICIAL URETERAL OCCLUSION**

B. Seckin, E. Aydur, M. Kilciler, I. Yildirim, H. Irkilata

**Background:** Percutaneous placement of nephrostomy catheters in patients with non-dilated pelvicaliceal systems remains problematic. We described a technique for percutaneous access to the non-dilated upper urinary tract in patients urinoma or ureterocutaneous fistula developed secondary to open surgery.

**Methods:** Ureterocutaneous fistula in 2 patients and urinoma in the other one developed subsequently after open surgery. All of patients were initially managed by retrograde ureteral stenting. However, ureteral stents were ineffective due to high output of fistulas r urinoma. Thereafter, we attempted percutaneous nephrostomy placement under fluoroscopic control in 2 patients, but these attempts were unsuccessful because their pelvicaliceal systems were non-dilated. The patient was placed in the lithotomy position under general anesthesia, a 6F ureteral balloon catheter was passed up into ureteropelvic junction to cause a temporarily obstruction under fluoroscopic control, by guidance of previously inserted ureteral stent. The guide wire of balloon catheter was removed and 10cc contrast agent diluted by saline was injected through the space of guide wire into the affected pelvicaliceal system to opacify.

**Results:** Artificial ureteral occlusion resulted in pelvicaliceal dilatation observed fluoroscopically in all patients and this facilitated the fluoroscopy-guided percutaneous nephrostomies performed by using the Seldinger technique. No complications were encountered.

**Conclusion:** Temporary ureteral occlusion with retrograde ureteral balloon catheter appears to be safe and effective in patients with non-dilated upper urinary tract, who required urinary diversion and also this technique may be used for percutaneous stone removal in non-dilated pelvicaliceal system because it facilitated puncture to all calyx.

### VP15-10 DOES TAMBUSOLIN CHANGE THE MANAGEMENT OF PROXIMALLY LOCATED URETERAL STONES? A COMPREHENSIVE STUDY

F. Yencilek, S. Erturhan, H. Koyuncu, O. Canguven, C. Goktas, K. Sarýca

**Background:** To assess the efficacy tamsulosin on proximal ureteral calculi <10 mm.

**Methods:** Retrospectively, the patients having single radio-opaque upper ureteral stone sizing <10 mm were included into the study. Patients receiving Hyoscine-N-butylbromide and those taking Hyoscine-N-butylbromide + Tamsulosin were classified as Group 1 and 2, respectively. The results were compared on the basis of stone passage rate, mean stone expulsion time, change in colic attacks, the mean VAS score, and hospital readmission rates. Also, the stones in the groups were categorized according to stone size, with the stones <5 mm separated from those 5–10 mm.

**Results:** There were 50 patients in group 1 and 42 in group 2 and the mean age was  $34.2 \pm 12.6$  years. Stone expulsion rates and time to expulsion of the stone were statistically different between two groups ( $p = 0.02$  and  $p = 0.015$ , respectively). Also, the incidence of renal colic episodes in tamsulosin group was diminished ( $p < 0.001$ ). The hospital readmission rates ( $52\%$  vs.  $33.3\%$ ,  $p < 0.001$ ) and the mean VAS score of the groups ( $8.8 \pm 2.9$  vs  $4.5 \pm 2.3$ ,  $p < 0.01$ ) differed significantly. Higher stone free rates and distal relocation of the stones were seen in the stones <5 mm and 5–10 mm, respectively. The prominent effect of tamsulosin in patients having stones <5 mm and were higher spontaneous passage rate and, respectively.

**Conclusion:** Tamsulosin leads to facilitate the spontaneous passage of stones <5 mm. However, the prominent effect on larger stone was the distal relocation of the calculi enabling the urologist to manage the calculi more safely and easily.

### VP15-11 DAYCASE AND 23-HOUR STAY URETEROSCOPIC LASER FRAGMENTATION FOR LARGE RENAL CALCULI

S. Patel, S. Kommu, A. Jain, T. Green, A. Blacker

**Background:** Percutaneous nephrolithotomy is currently regarded by many as the treatment of choice for large intrarenal calculi. In selected cases, large renal calculi have been shown to be successfully tackled with ureteroscopic laser fragmentation. However, there is a paucity of information regarding the feasibility of the latter to be performed on a short stay basis (daycase and 23-hour stay). We aim to analyse the safety, efficacy and suitability of daycase and 23-hour stay following ureteroscopy and laser fragmentation for intrarenal calculi  $\geq 20$  mm in our series.

**Methods:** Prospectively collected data of 23 consecutive patients treated between 03/2007 and 12/2008 was analysed. All patients underwent postoperative X-ray or CT KUB. Stone free status was defined as no visible stone on X-ray or  $\leq 2$  mm on CT. All patients who had a low ASA grade, good home support and well motivated were primed for short stay and streamlined into a protocol that would permit direct contact of the middle or consultant grade surgeon in the event that any concerns rise following discharge. The patients would then be admitted directly to the urology ward and reviewed.

**Results:** A total of 47 calculi were treated in 23 patients with an average stone burden of 41.3 mm (range 21–80 mm). 13 (57%) patients had >1 stone. BMI was >30 in 12 (52%) and ASA grade 3

in 8 (35%). Within this series 70% were successfully treated as 23 hour stay patients with 13% of patients treated as true day cases. The median post-operative stay was 1 day. Stone free rate after single treatment was 44%. Overall stone free rate after any adjunctive treatment was 66% after a median follow up of 7 months and median of 1 treatment. There was one postoperative death from unrelated cause and other complications including steinstrasse, pyrexia and pain occurred in 7 (30%) cases but only one patient with sepsis required surgical intervention.

**Conclusion:** Ureteroscopy and laser fragmentation of large intrarenal calculi is safe and effective in selected patients on a daycase or 23-hour stay basis. There is a need for stratification systems to predict which patients are suitable for consideration for short stay surgery.

### VP15-12 RENAL STONES TREATMENT BY PERCUTANEOUS NEPHROLITHOTOMY (PCNL)

M. Baptistussi, M. Morihisa, E. Gewher, A. Martins—Brasil

**Background:** According of renal calculi treatment, among advanced and noninvasive techniques, the PCNL has a special place near the urologist and patients. In this prospectively study, we will discuss the success role, advantages and disadvantages as well.

**Methods:** From October of 2000 to March 2009 (91 months), 350 cases of renal stones in 350 patients treated by PCNL procedure in our department. The patients ages were varied between 5 to 65 years old (mean 41 years old). There were 230 cases of left and 120 cases of right renal stones recorded. Bilateral renal stones calculated 10 and 10 cases showed UPJO abnormalities. In 280 patients only the stones were multiple in number. Recurrent stones were 79 and staghorn 110 cases has seen in our study. 30 patients showed radiolucent stones. 20 patients had a solitary kidney but in 32 cases the renal and ureteral stone were found. 70 patients had underwent a failed open surgery or ESWL for their stones.

**Results:** In this study 78.7% of patients were stones free, 42 patients with residual stone, 12 underwent a flexible ureteroscopy, that 6 cases got stone free, therefore 36 patients referred for ESWL procedure.

**Conclusion:** To define of success rate of PCNL, in treatment of renal calculi, we showed the short hospitalization and low cost treatment with this technique, in compare with open surgery, the PCNL has showed better advantages and less complications. In our 91 months study of urology advanced center we found that, PCNL is one of the best procedures for renal calculi treatment.

### VP15-13 THE FACTORS ASSOCIATED WITH FEVER FOLLOWING PERCUTANEOUS NEPHROLITHOTOMY: PRELIMINARY RESULTS OF A PROSPECTIVE CLINICAL STUDY

T. Akman, M. Binbay, R. Aslan, E. Sari, A. Muslumanoglu, A. Tefekli—Turkey

**Background:** To evaluate correlation among preoperative urine culture (PUC), intrapelvic culture (IPC) and stone culture (SC) in order to predict factors on fever after percutaneous nephrolithotomy (PNL).

**Methods:** PUC, IPC and SC were prospectively obtained in consecutive 121 patients who underwent PNL. Patients with positive PUC were treated according to the antibiotic sensitivity tests preoperatively. Patients characteristics such as age, side, body mass index, previous percutaneous or open surgery and stone size, presence of hydronephrosis, localization and number of access, presence of rest calculi or CIRF, per-operative complications in-

cluding hemorrhage, pelviciceal system perforation, duration of operation and insertion of double J catheter were analyzed and their relation with postoperative fever (38°C) were investigated. Statistical analysis was performed with SPSS 16 Windows software (SPSS Inc, Chicago, Illinois, USA).

**Results:** PUC, IPC and SC were positive in 21 (17.3%), 20 (16.5%) and 18 (14.9%) patients, respectively. Fever following PNL was encountered in 10.7% (13) of patients. PUC was colonized in 53.8% of patients with postoperative fever, while this rate was 61.5% for both IPC and SC. Factors affecting fever were PUC

( $p = 0.02$ , OR = 1.86) IPC ( $p < 0.0001$ , OR = 2.31), SC ( $p < 0.0001$ , OR = 2.36) and perioperative complications ( $p = 0.03$  OR = 1.60). SC was more correlated with postoperative fever than PUC ( $r = 0.45$ ,  $p < 0.0001$ ;  $r = 0.32$ ,  $p = 0.0001$ ).

**Conclusion:** Postoperative fever was detected in about one-tenth of patients after PNL. Positive IPC and SC were more relevant with postoperative fever. SC or IPC may be useful in terms of changing antibiotic regimen in patients with fever despite using prophylactic antibiotics.

## VP16: BPH-2

### VP16-01 PHOTO-SELECTIVE 532 NANOMETER GREEN-LIGHT™ LASER VAPORIZATION IS A SAFE AND EFFICACIOUS ENDOSCOPIC TREATMENT OPTION FOR LARGE (GREATER THAN 90 CC) OBSTRUCTING PROSTATES

S. Psutka, M. Siddiqui, S. Tabatabaei

**Background:** Photoselective vaporization of the prostate (PVP) is less invasive than open simple prostatectomy and does not involve the same risks as transurethral resection of the prostate (TURP) of hyponatremia after prolonged procedures. The aim of this study was to evaluate the safety and efficacy of PVP for treatment of BPH in men with prostate volumes greater than 90 cc.

**Methods:** Between 2007 and 2009, 44 men with 90 cc or greater prostate volume underwent 532 nm laser Greenlight™ PVP. Pre-operative evaluations included post-void residual volume (PVR), prostate volume, and AUA symptom score (AUA SS). Operative time, length of stay (LOS), length of catheterization, transfusions, combination of PVP with TURP, and early postoperative complications were recorded. At each postoperative visit, the AUA SS and PVR were measured. Average follow-up was 11 months (range 1–26).

**Results:** Average preoperative prostate volume was 131.8 cc (max. 214 cc). 29 (66%) of patients were in urinary retention preoperatively. 18 (41%) patients continued antiplatelet therapy through their surgery. Both PVP and TURP were used in 11 patients (25%). Catheters were removed 4.3 days postoperatively (range 1–12). Overall, 91% passed the voiding trial on the first attempt. The average AUA SS decreased from 21.3 preoperatively to 5 at 24 months. No patients required transfusions. The primary postoperative complaint was irritative symptoms (15%). Two patients were readmitted for gross hematuria. Two patients required re-operation from postoperative complications.

**Conclusion:** Here we demonstrate the use of PVP for patients with large >90 cc prostates. The patients had 91% successful void trial rate and improved AUA SS on follow-up. This procedure was safely done even in patients requiring antiplatelet therapy through surgery.

### VP16-02 BIPOLAR ELECTROSURGICAL ENUCLEATION OF THE PROSTATE: TECHNICAL PROGRESS AND EARLY CLINICAL EXPERIENCE OF A NOVEL TECHNIQUE

J. Mandeville, R. Roth, A. Mourtzinou—USA

**Background:** Bipolar transurethral resection of the prostate (TURP) and holmium laser enucleation of the prostate (HoLEP) have an urodynamically proven efficacy to relieve bladder outlet obstruction, which seems to be durable in time with low long-term complication rates. Both techniques have minimized bleeding risk and eliminated transurethral resection syndrome. We present our early clinical experience with bipolar enucleation of the prostate (BEP), a novel technique using the plasma-cise generator electrode as an alternative to transurethral resection of the prostate and HoLEP in patients with lower urinary tract symptoms secondary to bladder outlet obstruction from benign prostatic hypertrophy.

**Methods:** We prospectively analyzed our first 20 consecutive patients who underwent BEP between December 2007 and October 2008 with a minimum of 6 month follow-up. All patients were evaluated at baseline and follow-up by medical history, International Prostate Symptom Score, inclusive of the question on quality of life, physical examination, and bladder postvoid residual.

**Results:** Improvements in flow rate, International Prostate Symptom Score, quality-of-life score, and bladder outlet obstruction grade were comparable to results reported in the literature for both bipolar TURP and HoLEP. One patient had previously undergone a minimally invasive procedure for bladder outlet obstruction. One patient developed a fossa navicularis stricture that was managed conservatively.

**Conclusion:** Our initial data suggest that BEP using the plasma-cise generator electrode is safe and effective. It may represent a valid alternative to bipolar TURP and serve as a bridge to learning the necessary skill set for HoLEP. Long term studies will help to substantiate our short term results.

### VP16-03 HOW TO DEAL WITH BLADDER OUTLET OBSTRUCTION (BOO) AND LOWER URINARY TRACT SYMPTOMS (LUTS) CAUSED BY BENIGN PROSTATIC HYPERPLASIA (BPH) OF RELATIVE SMALL VOLUME?

C. Xiaoming, W. Dongwen

**Background:** To explore an ideal method of treatment for bladder outlet obstruction (BOO) and lower urinary tract symptoms (LUTS) caused by benign prostatic hyperplasia (BPH) of relative small volume.

**Methods:** Since Jan 2004 to Dec 2008, 210 cases with BPH of small volume were treated with transurethral technique. Which in



Jan 2004 to Dec 2005, 82 cases were treated by a single transurethral resection of prostate (TURP); in Jan 2006 to Jun 2007, 68 cases were treated with TURP plus transurethral incision of bladder neck (TUIBN), and in Jul 2007 to Dec 2008, 60 cases were treated with TURP plus TUIBN, and oral administration of Doxazosin-GITS afteroperation. There were no statistically significant differences between the three groups in age, course of disease, preoperative prostate volume and resected prostate volume. The efficacy of treatment was evaluated by comparison of IPSS score, Qmax and PVR before and after surgery. Post-operative, the follow-up period was three to six months.

**Results:** Before operation, the mean IPSS score was  $23.4 \pm 3.2$ ,  $24.1 \pm 2.6$  and  $22.8 \pm 4.6$ , and the mean Qmax was  $(4.8 \pm 2.6)$  ml/s,  $(5.8 \pm 1.6)$  ml/s and  $(4.6 \pm 3.2)$  ml/s, and the mean PVR was  $(62 \pm 6.6)$  ml,  $(58 \pm 8.4)$  ml and  $(63 \pm 5.7)$  ml for TURP group, TURP + TUIBN group and TURP + TUIBN + Doxazosin-GITS group respectively. There were no statistically significant differences in all of the indicators between the three groups before operation ( $P > 0.05$ ). After operation, the mean IPSS score was  $13.6 \pm 2.5$ ,  $7.1 \pm 3.2$  and  $2.1 \pm 1.6$ , and the mean Qmax was  $(9.3 \pm 3.2)$  ml/s,  $(18.3 \pm 3.6)$  ml/s and  $(23.3 \pm 3.6)$  ml/s, and the mean PVR was  $(25 \pm 6)$  ml,  $(15 \pm 4)$  ml and  $(6 \pm 2)$  ml for TURP group, TURP + TUIBN group and TURP + TUIBN + Doxazosin-GITS group respectively. There were statistically significant difference in all of the three indicators between the three groups after operation ( $P < 0.01$ ).

**Conclusion:** The therapic effect of TURP plus TUIBN, and oral administration of Doxazosin-GITS afteroperation was satisfactory, which proved to be an ideal method for management of patients with BOO and LUTS caused by BPH of relative small volume.

#### VP16-04 POST-HOLMIUM LASER ENUCLEATION OF THE PROSTATE (HOLEP): AN MRI ANATOMICAL STUDY

M. Humphreys, R. Nunez, W. Eversman

**Background:** Holmium laser enucleation of the prostate (HoLEP) is one of the most scrutinized procedures for the treatment of benign prostate hyperplasia (BPH). Different lasers are available, but the unique properties of the 2140 nm wavelength in a post-enucleation setting has not been well described. The purpose of this research is to demonstrate the radiographic consequences of the HoLEP utilizing MRI.

**Methods:** We retrospectively analyzed our IRB approved database to identify patients that have undergone an MRI after HoLEP. MRIs are ordered for high risk incidentally detected pT1a and pT1b prostate cancer. MRIs were performed with an endorectal coil using axial, coronal, and sagittal T1 and T2 weighted imaging. All studies were reviewed by a single radiologist.

**Results:** Five patients were identified: ages 68–83, average tissue enucleated 46 g (30–69 g), with mean Gleason scores of 7. All MRIs were obtained within 3 weeks after HoLEP. Common radiographic findings: total absence of the central zone, minimal periprostatic stranding or changes, no discernable periprostatic edema. In none of the cases was there evidence of extraprostatic extension of their prostate cancer.

**Conclusion:** HoLEP is a well accepted procedure for BPH. The ability to scrutinize the pathologic characteristics allows us to identify incidental prostate cancer. These MRI findings are the first glimpse of the periprostatic tissue effects to be expected using the 2140 nm holmium wavelength. Currently, there is not enough ev-

idence to determine if this is better or worse than other BPH therapies.

#### VP16-05 THE LATEST TRANSURETHRAL OPERATION, TUEB (TRANSURETHRAL ENUCLEATION WITH BIPOLAR), IN THE TREATMENT OF PROSTATES LARGER THAN 50 ML

K. Nakagawa, H. Kono, E. Kikuchi, H. Nagata, A. Miyajima, M. Oya—Japan

**Background:** There is an increasing demand for safer and more reliable treatment due to the growing prostatic hyperplasia enlargement which surgical operation is needed amid the progress of alpha-blocker and aging population. We assessed clinical results of TUEB (Transurethral enucleation with bipolar) in the treatment of benign prostatic hyperplasia (BPH) larger than 50 ml.

**Methods:** From July 2006 to June 2009 forty-one BPH patients (mean estimated volume:  $77.3 \pm 23.8$  ml, range: 55.1–150.0 ml) were treated by TUEB. Adenomas were enucleated with TUEB electrode (Olympus Japan) after dividing three blocks. And the enucleated tissues were removed with a morcelator. The clinical results were evaluated.

**Results:** All operations were completed without any severe complications. The mean enucleating time was  $65.6 \pm 25.2$  minutes and the total operating time was  $119.8 \pm 27.5$  minutes. Mean hemoglobin levels before, immediate after and 1 day after the operation were  $14.0 \pm 1.3$  g/dl,  $12.2 \pm 1.4$  g/dl and  $12.3 \pm 1.3$  g/dl. Mean peak flow rate at 4 months after the operation was improved to  $21.7 \pm 6.7$  ml/sec from  $7.0 \pm 3.4$  ml/sec. Residual urine volume was improved to  $42 \pm 27$  ml from  $132 \pm 109$  ml. IPSS and QOL score were  $5.4 \pm 3.8$  from  $20.3 \pm 6.8$  and  $1.3 \pm 1.1$  from  $4.9 \pm 1.1$ , respectively. The PSA reduction rate was 92.2% (from  $11.5 \pm 11.5$  ng/ml to  $0.9 \pm 0.7$  ng/ml). The treatment effect has been kept over 1 year.

**Conclusion:** TUEB was effective and safe as a surgical treatment for over 50 ml BPH. TUEB should be considered as one of the most useful and reasonable options because the present surgical treatment of BPH must target the huge one.

#### VP16-06 PHOTOSELECTIVE VAPORIZATION OF THE PROSTATE (PVP) USING THE GREENLIGHT LASER VERSUS TRANSURETHRAL PROSTATECTOMY (TURP): A COMPARING COST ANALYSIS

E. Liatsikos, P. Kallidonis, I. Kyriazis, A. Alaoun, N. Maniada-kis—Greece

**Background:** An economic evaluation was undertaken to compare the two techniques in terms of their cost to the National Health Service (NHS) or to the Public Insurance Sickness Funds (PISF) and also to compare them in terms of the productivity loss imposed upon patients.

**Methods:** From the NHS hospital perspective the analysis accounted for the cost of infrastructure, consumables, hospitalization and side effects per intervention undertaken with any of the two techniques under evaluation. From the PISF perspective the analysis accounted for the reimbursement provided to the NHS for each patient undergoing the one or the other intervention and the average sickness disability allowance provided to patient. Finally, to estimate patient and economy productivity losses the number of days lost due to care and recovery were multiplied with the gross average daily salary taken from the National Statistics Office.

**Results:** From the NHS hospital perspective the true cost was €1782 in TURP and €1572 in PVP. Despite the fact that the PVP

approach is associated with higher cost of equipment and consumables, it reduces hospitalizations and complications drastically and thus it is on average the least costly option from the hospital perspective. From the PISF perspective the reimbursed cost for the treatment of patients was €554 in TURP and €1311 in PVP, due to the fact that sickness funds reimburse only a portion of the true hospital daily cost. However, if the sickness disability allowance is added, then the cost of TURP raises to €2471 whilst the cost of PVP to €1790, as patients are discharged much faster. Hence overall the PVP approach is preferable. From the perspective of patient there is a productivity loss of €1917 for the first approach and €671 with the alternative. Hence, the laser is preferable.

**Conclusion:** The present analysis indicated that the PVP technique is preferable from the perspective of the National Health Service, Public Insurance Sickness Funds and patients themselves and thus society overall. Given the number of cases per annum the use of PVP can result in significant saving and since it is less invasive to gain in quality of life, which make it a dominant treatment option.

### VP16-07 VAPOENUCLEATION OF THE PROSTATE WITH THE 70 WATT AND 120 WATT 2-M CONTINUOUS WAVE THULIUM LASER IN LARGE GLANDS

C. Netsch, K. Oberhagemann, T. Bach, H. Ho, A. Gross—Germany

**Background:** The 70 watt Thulium:YAG (Tm:YAG) VapoEnucleation of the prostate has been recently introduced demonstrating its effectiveness even in patients with larger glands. The latest evolution was the introduction of the 120 watt Tm:YAG laser in 2008. We therefore analyzed our 70 watt Tm:YAG VapoEnucleation series in comparison with the 120 watt VapoEnucleation series.

**Methods:** Tm:YAG VapoEnucleation was conducted with the 2  $\mu$ m continuous wave Tm:YAG laser (RevoLix<sup>®</sup>). 70 watt VapoEnucleation (A) was performed in 44 patients and followed up at least 1 year, 120 watt VapoEnucleation (B) in 40 patients with ongoing follow up. Prostate volume was  $\geq 60$  ml in each series. Patient data were analyzed and compared.

**Results:** Mean prostate volume was  $79.9 \pm 27.49$  cc in A and lower than in B ( $88.53 \pm 25.09$ ;  $p = 0.033$ ). There were no differences between both series regarding catheter time, age, PSA, total OP time and enucleation efficiency. Mean resection weight ( $38.34 \pm 25.48$  gm vs.  $58.9 \pm 22.55$ ;  $p = 0.000$ ), OP efficiency (weight/total OP time,  $0.42 \pm 0.27$  vs.  $0.76 \pm 0.35$ ;  $p = 0.000$ ) and percentage of resected tissue ( $45.41 \pm 23.33$  vs.  $66.93 \pm 22.79$ ;  $p = 0.000$ ) was significantly different between A and B.

**Conclusion:** The 120 watt Tm:YAG laser enhances the effectiveness of Tm:YAG VapoEnucleation with respect to percentage of resected tissue and OP efficiency. However, the effect of the learning curve of the procedure, with more tissue vaporization than enucleation in the beginning, should taken into account. 1 year follow up of the 70 watt VapoEnucleation therefore indicates significant reduction of prostate volume (72% volume reduction) and symptoms. Long term results of 120 watt Tm:YAG VapoEnucleation are awaited immediately.

### VP16-08 LOW POWER (25-40W) TRANSURETHRAL LASERNUCLEATION OF THE PROSTATE (TULP) VERSUS MONOPOLAR TURP: A MATCHED PAIR ANALYSIS

M. Roder, M. Schulze, A. Sclarikos, J. Rassweiler

**Background:** After a phase of introduction low power TULP with maximal output of 40 W and mechanical morcellator is now available. This study compares the results of TULP to the standard procedure of monopolar TURP.

**Methods:** From December 2003 until June 2009 75 patients were treated with TULP. Based on the weight of the resected tissue a matched pair analysis (criteria: resection weight and preoperative trans rectal ultrasound) was conducted to compare these patients to 75 patients treated with monopolar TURP. The TULP was performed with the Aurigal XL Laserdevice (Star-MedTec) with 2.2 J and 12–18 Hz (25–40 W). The Morcellation was done with a modified endoscopic shaver (Richard Wolf), via nephroscope with right angle optic. The TURP was performed with a 24 ch resectoscope (Karl Storz) using 230 W/80 W current (HF Generator Erbstrom, Erbe). Analysed parameter were or- time, transfusion rate, pre- and postoperative Hb value, reintervention rate (bleeding), catheter time, hospitalstay, continence, complications and functional results (IIEF, QoL, IPSS).

**Results:** The average age (72 vs 75 a. of the TULP group) of the patients was 74. The average prostateresection weight of the TULP group was 76 gr. (50–195 gr.) and 74 gr. (54–145 gr.) for the TURP group. The total average or- time of the TULP was 97 min. (enucleation: 73 min., Morcellation: 24 min.) versus 95 min. of the TURP. Transfusionrate (6% vs. 10 %), reintervention rate (4% vs 7%) and Hb-decline (3.0 mg/dl vs. 3.6 mg/dl) were lower following the TULP. The catheter time in both groups was 4 days. The hospital stay of the TULP patients was shorter (5 vs. 7 days). After 12 months there was no significant difference in continence- (95% vs. 94%) and urethral stricture rates. (2% vs. 4%). Also the functional results were similar.

**Conclusion:** After passing through the learning curve there was no significant difference regarding peri-operative parameters between TULP and TURP, where there are key benefits regarding the operative bleeding risks for the TULP also for the application of low power use.

### VP16-09 ENCRUSTED, FORGOTTEN URETERAL STENTS: REVIEW OF APPROACH, COMPLICATIONS AND MANAGEMENT

A. Colon-herdman, D. Bagley

**Background:** Retained, encrusted ureteral stents are a challenging surgical problem. We analyzed the published data and some proposed management options for treating this complication.

**Methods:** A systematic review of the literature was performed by searching Pubmed and Medline from January 1989 to April 2009. Electronic search was limited to the english language using key words “ureteral stent”, “forgotten”, “encrusted”, “calcified”, “overlooked” and “retained”. Relevant articles were reviewed and management approaches evaluated. When available, indwelling time, stent material, complications and stone former data was obtained.

**Results:** 38 relevant articles were reviewed. Available data from 343 calcified stents in 291 patients were pooled from the articles. Mean indwelling time was 23.26 months (Range 3 months–18 years). A mean of 2.1 procedures are required for complete stent extraction. 211 patients had reported history of lithiasis vs 52 with no reported history. Potential complications from retained stents include pyelonephritis, diminished renal function, sepsis and chronic renal failure. Mortality directly related to the calcified stent was demonstrated in 5 cases from pooled data (0.01%). Treatment

decision algorithms proposed have involved imaging evaluation, stone burden classification and grading of stent calcification. Laparoscopy, shockwave lithotripsy, ureteroscopy and multimodal approaches have been described for definitive management.

**Conclusion:** Retained, encrusted ureteral stent cause significant morbidity to the patient, are potentially lethal and, at times, are very difficult to manage requiring multiple procedures. The management of retained, encrusted ureteral stents generally requires a multimodal approach that must be individualized for each patient.

### VP16-10 URETERORENOSCOPY WITH A DOUBLE CHANNEL URETERORENOSCOPE: FIRST RESULTS

T. Horn, C. Lux, J. Gschwend, M. Straub

**Background:** The instruments of ureterorenoscopy have gone through an enormous process of improvements since the first description of the technique more than 40 years ago. The spectrum of indications has become wider in the last years due to technical progress and the greater experience of the surgeons.

**Methods:** We report about 30 patients being operated on with a new double channel flexible ureterorenoscope (COBRA, Wolf, Germany). These endoscopes allow the simultaneous insertion of two instruments, for example a laser probe and a basket for stone extraction. Usage of only one channel permits a higher flow of irrigation fluid through the second channel.

**Results:** Most of the 30 patients suffered from urolithiasis, one had a papillary transitional cell carcinoma of the renal pelvis. We evaluated the patients in terms of their stone free rate and the occurrence of intra- and postoperative complications. All the patients treated for urolithiasis have been free of residual stones after the procedure and we did not observe a single serious complication so far. In addition there was a huge time saving and improvement in sight and overview in the impression of the treating surgeon and in comparison with conventional single channel ureterorenoscopy. This was due to the abandoned need for repeated changing of the instruments which may also help to increase the life expectancy of the endoscopes because of less mechanical irritation.

**Conclusion:** The development of a double channel endoscope is a big improvement in the technique of ureterorenoscopy. The expectancies are to give more safety to the patient from improved sight and reduced operation time. Also, with ongoing technical improvements, there may be an indication shift in the treatment of large stones of the renal pelvis and the proximal ureter in favour of ureterorenoscopy. A possible downside of the new endoscopes is the heightened requirement for the manual coordination skills of the surgeon.

### VP16-11 PERCUTANEOUS MANAGEMENT OF UPPER-TRACT TRANSITIONAL CELL CARCINOMA

J. Diaz, I. Pinto, A. Hornig, C. Sandoval—Chile

**Background:** Transitional cell carcinoma of the upper urinary tract is an uncommon disease. They have a high percentage of recurrences and the therapeutic approaches are numerous. The treatment gold standard is radical nephrourethectomy. This is associated with a higher incidence of chronic renal failure and death from associated conditions. Actually, various nephron sparing therapies are in development. The main techniques are the percutaneous resection and the ureteroscopic resection.

**Methods:** We present a case series of four patients diagnosed with transitional cell carcinoma of the upper urinary tract treated by a percutaneous approach.

**Results:** Mean tumor size was 14.5 mm (8–20 mm), three of them had superficial tumors and one of them invasive ones. There was no major complications, average bleeding was 225 cc, no patient needed blood transfusions and mean hospitalization time was 3,75 días. Only one patient required complementary treatment (patient with invasive tumor), being treated with laparoscopic radical nephrourethectomy. Actually all patients are at complete response to treatment, with an average followup time of 50,25 months (34–61).

**Conclusion:** Percutaneous approach for transitional cell carcinoma of the upper urinary tract is a valid treatment option, associated with a low complications rate and safe form an oncological view.

### VP16-12 COMBINED WATER-JET DISSECTOR AND NEEDLE-KNIFE FOR EN-BLOC-RESECTION OF UROTHELIAL CARCINOMA OF THE BLADDER? AN EX-VIVO STUDY IN PIG BLADDERS

H. Fritsche, F. Eder, R. Ganzer, W. Wieland, S. Denzinger, M. Burger

**Background:** Conventional wire-loop transurethral resection (TURB) of bladder tumours contradicts the basic oncologic principle, to resect the tumor en-bloc by dissecting through normal tissue. We present the first study of a combined water jet dissector and needle-knife for mucosal elevation in the bladder.

**Methods:** Aim of the present study was the evaluation of applicability and safety of the Hybrid Knife® (ERBE Germany) in the resection of bladder mucosa of ex-vivo pig bladders. The micro-capillary wire was placed directly on the bladder wall and the optimal pressure for mucosal elevation was evaluated (30bar, water-jet-dissector ERBEJet2, ERBE Germany). 13 different mucosal areas with a mean diameter of 2 cm were elevated by a fluid cushion and resected by the Hybrid Knife®. The bladders were dissected and examined macroscopically by the surgeon; the specimens were assessed by a pathologist.

**Results:** The targeted high-pressure water jet of 30bar reliably penetrates the mucosa and upper muscular layers. It selectively creates a fluid cushion facilitating resection. Time for application of the Hybrid Knife® seems to be comparable to common wire-loop TURB with a steep learning curve. Macroscopic examination showed no perforation. Histological assessment showed an edema in the submucosa and to a small extent in the upper layers of the muscularis. The resected specimens all contained sufficient muscle for valid histopathologic evaluation.

**Conclusion:** The application of the Hybrid Knife® in pig bladders is safe and reliable. This new method could ameliorate the transurethral resection of urothelial carcinoma of the bladder and especially could provide the possibility for an elegant en-bloc resection according to oncologic principles.

### VP16-13 STONE DISEASE AND STRESS

R. Miyaoka, O. Ortiz-alvarado, C. Kriedberg, S. Alanee, M. Monga

**Background:** To characterize the presence of stress in stone disease patients through a validated questionnaire and identify other factors influencing their score.

**Methods:** We prospectively assessed 184 patients from our stone clinic. All provided information on demographics, stress risk factors in general (work activity, financial status as family provider, status as a caregiver for children), stressful events (family death, serious illness, change in marital status/ close relationship, other

traumatic events) and regarding stone disease (presence of symptoms at time of questionnaire, numbers of stone passed in the past, need for surgical treatment). Patients under treatment for clinical depression were excluded. They also responded to a self-applied 10-item validated questionnaire (Perceived Stress Scale-10) in order to quantify their "stress status". Each question yields a value from 0 to 4 (for a total of 0–40). Higher values imply more stressed status. Student's T test was used to identify relevant factors.

**Results:** 184 patients were enrolled. Average total score was  $15.2 \pm 7.9$ . Risk factors for stress were identified: female gender ( $17.1 \pm 8.1$  vs.  $12.9 \pm 6.9$ ,  $p = 0.0002$ ); unemployment ( $17.6 \pm 8.1$

vs.  $14.0 \pm 7.5$ ,  $p = 0.005$ ); occurrence of death or serious illness within the past 6 months ( $17.1 \pm 8.4$  vs.  $14.1 \pm 7.4$ ,  $p = 0.02$ ); presence of symptoms at the moment ( $15.7 \pm 6.7$  vs.  $12.8 \pm 8.1$ ,  $p = 0.006$ ); occurrence of other traumatic events ( $17.5 \pm 10.4$  vs.  $12.7 \pm 8.4$ ,  $p = 0.0001$ ); passage of 2 or more stones per year ( $15.7 \pm 7.9$  vs.  $12.4 \pm 7.0$ ,  $p = 0.02$ ).

**Conclusion:** Recurrent stone disease can be related to a significant amount of stress in patients who are suffering from acute symptoms and those who experience more than 2 passage events per year. Other factors may influence its occurrence.

## VP17: LAPAROSCOPY-KIDNEY 3

### VP17-01 A NOVEL BRIDGING TECHNIQUE TO FACILITATE DEVELOPMENT OF LAPAROENDOSCOPIC SINGLE SITE SURGICAL SKILLS

D. Baldwin, K. Ebrahimi, P. Mahdavi, R. Bowman, F. Jellison, L. Nicolay

**Background:** Laparoendoscopic single-site surgery (LESS) has recently been successfully applied to donor nephrectomy. In an attempt to reduce the learning curve for this complicated technique we have developed a bridging LESS technique (BLESS) designed to decrease surgical complexity and increase safety. The purpose of this study is to compare this novel technique to conventional hand-assisted laparoscopic donor nephrectomy (HALDN).

**Methods:** A retrospective comparison of four patients undergoing BLESS to 15 consecutive HALDN patients was performed. Similar to LESS, this bridging technique employs a single periumbilical incision with three ports placed into a Gelport. Slight enlargement of the abdominal fascial incision allows easy transition between LESS and hand-assisted laparoscopy with only the addition of a single 5 mm port. Statistical analysis on preoperative, perioperative and postoperative variables was performed using a Mann-Whitney test with significance  $p < 0.05$ .

**Results:** BLESS patients had significantly shorter warm ischemia time (median = 136 vs. 180 s;  $p = 0.04$ ), shorter incision length (median = 7.25 vs. 8.00 cm;  $p = 0.014$ ) and post-operative hospital stay (median = 1.5 vs. 3.0 days;  $p = 0.02$ ) compared to HALDN. BLESS patients had lower BMI (median = 21.3 vs. 25.6;  $p = 0.004$ ). Median recipient creatinine was excellent in the BLESS and HAL groups at 0.9 and 1.3 mg/dl, respectively.

**Conclusion:** This novel approach (BLESS) allows the surgeon to develop experience with single incision surgery while increasing the margin of safety for donors. It resulted in better cosmesis, shorter warm ischemia times and decreased hospital stays compared with HALDN.

### VP17-02 WIDENING THE PLANE OF DISSECTION IN LAPAROSCOPIC SIMPLE NEPHRECTOMY FOR SYMPTOMATIC NON-FUNCTIONING KIDNEYS KEEPING IN MIND THE HIDDEN UPPER TRACK UROTHELIAL MALIGNANCY

A. Kurien, A. Mathew, S. Mishra, A. Ganpule, R. Sabnis, M. Desai

**Background:** In our experience it is sometimes difficult to exclude a diagnosis of urothelial malignancy in patients with symptomatic non-functioning kidneys.

**Methods:** We did a retrospective analysis of our patient records for the last fifteen years. We identified 802 patients who had undergone nephrectomy for an indication of symptomatic non functioning kidney. Symptoms included pain, fever, hematuria and pyuria. Twenty-eight (3.5%) patients were suspected to have urothelial malignancy preoperatively by cytology or imaging and were consequently proved to be malignant by histopathology. In fourteen patients (1.7%) with non-functioning kidneys urothelial malignancy was incidentally detected after surgery.

**Results:** Fourteen patients following nephrectomy were found to have urothelial malignancy in whom pre-operative evaluation did not suggest a malignant pathology. The pre-operative diagnosis included chronic calculous pyelonephritis/pyonephrosis in 11 patients. Tuberculous pyelonephritis, xanthogranulomatous pyelonephritis and non functioning kidney with UPJO were the pre-operative diagnosis in one patient each. Squamous cell carcinoma, transitional cell carcinoma and adenocarcinoma of the urothelium were seen in 6, 5 and 3 patients respectively with a T stage of T4, T3 and T1 in 7, 5 and 2 patients respectively. Histopathology revealed microscopic nodal disease and lymphovascular invasion in 5 and eleven patients respectively.

**Conclusion:** CT scan images of these non-functioning kidneys should be thoroughly scrutinised for the presence of neoplasm. All patients may be counselled pre-operatively on the possibility of 'hidden' malignant tumours. Laparoscopic simple nephrectomies should be done with the plane of dissection outside the Gerota's fascia. Any enlarged lymph nodes should be excised along with the specimen.

### VP17-03 NOTES AND LESS LAPAROSCOPIC SIMPLE NEPHRECTOMY WITH THE USE OF STANDARD LAPAROSCOPIC INSTRUMENTS. INITIAL EXPERIENCE IN 4 CASES

I. Vidal-mora, O. Castillo, A. Foneron, R. Campos, G. Rubio, M. Feria—Flores

**Background:** Natural orifice transluminal endoscopic surgery (NOTES) and Laparoendoscopic single site surgery (LESS) are emerging technologies, which allows to performed surgical

procedures avoiding any surgical scars. However there are some problems due to the lack of equipment available for these procedures. The aim of these study is to present our initial experience with the transvaginal nephrectomy NOTES and LESS using standard laparoscopic instruments.

**Methods:** Four patients, 3 females and 1 male, with an average age of 26 years (15–40) and diagnosis of recurrent urinary tract infection and renal atrophy. In all females patients a laparoscopic simple nephrectomy with transvaginal NOTES assistance was performed, using a transvaginal access port for the camera and two abdominal work ports of 10 and 3 mm. In the male patient a transumbilical LESS nephrectomy was performed with the use of standard laparoscopic instruments.

**Results:** Average operative time for both technique was 110 minutes (40–200), with an estimated blood loss of 200 cc. There were no perioperative complications and all patients were discharged 36 hours after surgery.

**Conclusion:** Laparoscopic simple nephrectomy with transvaginal NOTES assistance and LESS are technically feasible with the use of standard laparoscopic instruments. Special access trocars and instruments development for this procedure will allow to performed a pure technique without the use of abdominal incisions.

#### VP17-04 800 LAPAROSCOPIC PARTIAL NEPHRECTOMIES: A SINGLE-SURGEON SERIES

I. Gill, K. Kamoi, M. Aron, R. Brandina, A. Berger, M. Desai

**Background:** We hypothesized that over a 9 year period (1999–2008) single-surgeon experience involving 800 laparoscopic partial nephrectomy (LPN) cases, the patient/tumor selection criteria, peri-operative outcomes, complications and renal functional outcomes of LPN may have evolved significantly.

**Methods:** 800 patients undergoing LPN for tumor by a single surgeon (ISG) were retrospectively divided into 3 chronologic eras: Era I: 09/1999–12/2003 (n = 276), Era II: 01/2004–12/2006 (n = 289), and Era III: 01/2007–11/2008 (n = 235). Data, collected prospectively, were evaluated for tumor characteristics, peri-operative outcomes and renal function outcomes.

**Results:** On comparing eras I, II and III, tumors in the most recent era were larger, more commonly >4 cm and central, and less often peripheral <4 cm (p-value significant for all). Despite increasing tumor complexity, warm ischemia times were shorter (31.9, 31.6 and 14.4 min, p < 0.0001), and overall, post-operative and urologic complications significantly lower in the most recent era. Positive parenchymal margin rates for cancer were 1%, 1%, and 0.6%, respectively. Renal functional outcomes were superior in era III, reflected by lesser percent decrease in estimated glomerular filtration rate (18%, 20% and 11%, respectively). In patients with pathologically-confirmed malignancy (n = 744), 5-year overall, cancer-specific, and recurrence-free survival was 90%, 98.5%, and 96.9%, respectively.

**Conclusion:** Over our 9-year experience with 800 consecutive LPNs, tumor characteristics and LPN outcomes have evolved. Despite increasing tumor complexity in contemporary practice, three key outcomes of LPN (ischemia time, complications, renal function) have improved significantly. We now routinely offer LPN for the majority of tumors hitherto reserved for open nephron-sparing surgery. Note: The authors, currently at the University of Southern California, performed the surgical procedures reported herein at the Cleveland Clinic.

#### VP17-05 APPLICATION OF SUTURELESS LAPAROSCOPIC PARTIAL NEPHRECTOMY TECHNIQUE BASED ON PREOPERATIVE AND INTRAOPERATIVE PARAMETERS

S. Stroup, J. L'esperance, B. Auge, C. Choe, A. L'esperance, I. Derweesh—USA

**Background:** A number of renorrhaphy techniques have been described to close cortical defects after laparoscopic partial nephrectomy (LPN). Standard closures require a combination of bolsters and sutures to achieve adequate hemostasis, however no one technique has proven superior. We sought to evaluate preoperative and intraoperative parameters from a multi-institutional experience to compare outcomes for LPN using a sutureless approach vs. standard sutured techniques.

**Methods:** A retrospective review of all LPN performed at either Naval Medical Center San Diego (NMCS D) or University of Tennessee, Knoxville (UT) was performed. Operative reports were then reviewed and cases were separated into three categories. In Group A, there was no sutured reconstruction performed whatsoever. In Group B, a bolstered repair at the level of the renal capsule was performed, over a Surgicel® (Ethicon, Somerville, NJ) bolster and a hemostatic agent (FloSeal™ Hemostatic Matrix, Baxter Healthcare, Fremont, CA) was applied underneath the bolster. There were no sutures used to ligate vessels at the base of the parenchymal defect. In Group C, all steps of the described open reconstruction were followed, including suturing of the base of the defect (incorporating medullary blood vessels and collecting system), FloSeal application, and repair of the cortical defect over a Surgicel bolster.

**Results:** A total of 95 laparoscopic partial nephrectomies were performed with a mean follow-up of 16.8 months. The groups were similar with respect to age, laterality of the lesion, and calyceal involvement on preoperative imaging. Significant differences between groups were found for tumor size and location, with Group 3 trending towards larger, more centrally located lesions. Collecting system entry was higher in Group 3. Blood loss, warm ischemia time, and post-operative renal function at 6 and 12 months significantly favored the sutureless technique over the sutured approach. The complication rate was 17.9 overall, and was similar between groups. Two patients were converted to radical nephrectomy intraoperatively. Disease free survival was 98.8% and negative margins were achieved in 96.6%.

**Conclusion:** A sutureless technique can be employed for repair of defects following LPN. This is true, even in the setting of small to moderate collecting system injury or significant hemorrhage. The potential effectiveness of a suture-less approach can be predicted based upon preoperative imaging and intraoperative findings, prior to tumor excision. In addition, when sutured repair is needed, a bolstered repair with a hemostatic agent is often sufficient, without any specific suture ligation of bleeders, or sutured repair of the collecting system.

#### VP17-06 RETROPERITONOSCOPIC NEPHRECTOMY IN NON-FUNCTIONED ATROPHIC KIDNEY: PRELIMINARY RESULTS OF 10 CASES

E. Huri, T. Akgöl, T. Karakan, C. Germiyanoglu—Turkey

**Background:** Laparoscopic surgery has been gaining more popularity in the world. Atrophic kidney could be congenitally or acquired. In this preliminary datas, we evaluated the efficacy of

retroperitoneal laparoscopic approach in non-functioned atrophic kidney treated with nephrectomy

**Methods:** Ten patients, diagnosed as atrophic non-functioned kidney which was found incidentally, underwent to retroperitoneoscopic nephrectomy procedure. History, physical examination, urinary ultrasound, abdominopelvic computed tomography (CT), urine analysis, complete blood count, creatinin were evaluated. The parameters of age, gender, laterality, previous surgical history, renal size, loin pain were included. Retroperitoneoscopic nephrectomy was performed. The surgical difficulty was evaluated related with surgeon views.

**Results:** Mean age was 52 years old. Five right, five left sided surgery was performed. Mean renal size was 5×3 cm. In one patient, previous ESWL, in one, ureteroscopy was observed. All patients were identified incidentally. Three trocars (10–10.5 mm) were used. Retroperitoneal access was provided by Hasson technique before insufflations for each patient. Each surgery was performed by two surgeons. During operation, the main problem was detected to dissect the kidney from the peritoneal side and identify the ureter. The anatomic landmarks for the operation could not seen due to the atrophic shape of kidney and related organs. Each session was achieved without complication, in only one, peritoneum was opened, not converted to open surgery. Mean operation time was 118 minutes.

**Conclusion:** Laparoscopic approach to atrophic kidneys is a feasible, effective and less invasive method of treatment choice although technically more difficult due to finding atrophic type of kidney, vessels, ureter step by step.

#### VP17-07 HEM-O-LOK CLIPS: A RELIABLE AND COST-EFFECTIVE METHOD OF VASCULAR CONTROL DURING LAPAROSCOPIC NEPHRECTOMY

R. Kapoor, R. Maheshwari, S. R. A. Srivastava, M. Ansari, A. Mandhani—India

**Background:** To evaluate safety, reliability and cost-effectiveness of Hem-o-lok clips for vascular control in laparoscopic nephrectomies.

**Methods:** From January 2001 to April 2009, 1194 laparoscopic nephrectomies (353 simple, 143 radical and 608 live related donor nephrectomies) were performed at our institute. One thousand one hundred and eleven patients underwent standard transperitoneal and 83 underwent retroperitoneal nephrectomy. Vascular control was taken using a pair of Hem-o-lok clips. Renal artery was kept tension free to avoid tenting effect and clip application on the aorta. Both the vessels were cut leaving a minimum 2–3 mm of free stump distally.

**Results:** Conversion to an open procedure was required in 36 patients (28 in the transperitoneal group and 8 in the retroperitoneal group). In all successful cases, arterial and venous control was achieved by application of two Hem-o-lok clips on the patient side after adequate circumferential dissection. The Hem-o-lok clips were applied under vision. These guidelines were formulated following clip dislodgement in a donor with fatal consequence in the initial part of the series. On an average, each patient required 5.2 clips, average cost to patient was US\$ 32.15. The mean postoperative hospital stay was 3.4 days.

**Conclusion:** Hem-o-lok clips are a reliable and cost-effective means of achieving vascular control during laparoscopic nephrectomy.

#### VP17-08 BILATERAL SYNCHRONOUS RENAL MASSES: 21 YEAR EXPERIENCE IN 260 PATIENTS

R. Brandina, M. Simmons, A. Berger, M. Desai, M. Aron, I. Gill

**Background:** Bilateral renal cell carcinoma (RCC) are rare (<5% of RCCs). We present clinico-pathological data to facilitate planning of management strategies in this challenging cohort.

**Methods:** Over a 21 year period (1988–2009), 260 patients underwent surgical treatment for synchronous bilateral enhancing renal tumors. Demographic, clinical and pathological parameters were analyzed from a prospectively maintained, IRB-approved electronic database.

**Results:** Mean tumor size was 3.7 cm and 3.6 cm for right and left side, respectively. Bilateral tumors were malignant in 197 (77%), benign in 32 (13%), and discordant in (10%). Of the bilaterally benign tumors, 28 (11%) were oncocytoma. A strong association between presence of cancer in the first and second procedure was noted. Of 44 patients with oncocytoma on one side, 15 (34%) had cancer contra-laterally. On histo-pathology, of 33 patients with oncocytoma diagnosed in the first surgery, 21% had cancer in the second kidney. Multi-focality was present in 41% of bilateral RCCs. Although not statistically significant, patients with multifocal disease tended to have smaller tumors. Note: The authors, currently at the University of Southern California, performed the surgical procedures reported herein at the Cleveland Clinic.

**Conclusion:** Amongst bilateral tumors, 10% discordant histology. When oncocytoma is diagnosed on one side, 34% have cancer on the opposite side. These data should be considered during clinical decision-making in these challenging cases.

#### VP17-09 IMPLEMENTATION EVOLUTION OF TRANS-PERITONEAL LAPAROSCOPIC PARTIAL NEPHRECTOMY IN SUTURE/BOLSTER TECHNIQUE. INITIAL RESULTS

T. Herrmann, M. Burchardt, S. Kruck, M. Kuczyk, U. Nagele—Germany

**Background:** Laparoscopic partial nephrectomy is increasingly a definitive therapeutic option in patients with a small renal mass. Intermediate term oncological outcomes after laparoscopic partial nephrectomy are excellent up to a mean follow-up up to 5 years. We present the surgical and oncological outcome of the first 40 consecutive patients after implementation of the technique.

**Methods:** From March 2007 until May 2009 laparoscopic partial nephrectomies were performed at our institutions in 40 patients. Transperitoneal technique was performed. Hilar clamp technique for the renal vein was used for warm ischemia. Interstitial tissue and collecting system was closed using a running suture secured by two resorbable clips where necessary. The surgical excision site was closed using single layer sutures over a haemostatic bolster. From April 2008 on a double layer suture parenchymal/bolster was performed. The threads were secured by non-resorbable clips. Clinical, surgical and oncological data were obtained prospectively. Follow-up data were kept from radiographic reports and office urologist contact.

**Results:** Average patient age was 61 years [39; 80]. Average tumor size was 2.5 cm [1–10]. Histopathological examination renal cell carcinoma was confirmed in 35 patients (87.5%). Pathological tumor stage was pT1a in 33/40 and pT1b 1/40 and pT2a 1/40. No positive surgical margin was noted. Median serum creatinine preoperatively and postoperatively was 0.9 and 1.0 mg/dl, respectively. Hb concentration preoperatively and postoperatively

was 14.2 and 11.9 mg/dl. Mean Hb drop was 2.5 mg/dl [0.9; 5.8]. Two patients received blood transfusion intraoperatively. At a median follow-up of 1.4 years no distant recurrence or single local recurrence was detected except in one case of primarily metastasized cancer. Operation time did not increase performing the double layer technique.

**Conclusion:** Laparoscopic partial nephrectomy is a feasible and safe procedure in the hands of experienced laparoscopic surgeons. Oncological results seem excellent, but further follow-up is needed for accurate long-term assessment of this surgical approach.

### VP17-10 LAPAROSCOPIC PARTIAL NEPHRECTOMY: A NEW ERA?

F. Porpiglia, C. Fiori, R. Bertolo, I. Morra, R. Scarpa

**Background:** The aim of this study is to review our experience with laparoscopic partial nephrectomy (LPN) to define the dealing of results with the increase of surgeon experience and the technical improvement.

**Methods:** Patients undergone LPN at our Institution were divided into three Groups: A pts no 1–50, B pts #51–#100, C #101–#150; 1 to 50. We considered the following pre-operative variables: age, distribution of the side of lesions and CT size of lesions, operative time, warm ischemia time (WIT), blood loss, intra-operative complications rate, medical and surgical complication rates, length of Hospital stay, pathological tumour size and weight and surgical margins were specifically recorded for the purpose of the study.

**Results:** Groups were comparable about preoperative data. In Group C, blood loss (134.34 cc) and WIT (18.98') were significantly lower with respect to the other groups. Overall intra-operative complications rate was 0.6%, while overall post-operative complications rate was 19.3%; in the Group C there was a significant reduction of the complications rate (6%). In particular no post operative bleeding, which is the most frequent complication of LPN, were recorded. Finally, in elective procedures for malignant tumours, overall positive surgical margins rate was 2.6% (4/150) without a statistically significant difference among Groups (4%, 4% and 0%, respectively).

**Conclusion:** The data of the last series of patients, similar to those of Open PN, suggest us that a new era of LPN is started.

### VP17-11 LAPAROSCOPIC RADICAL NEPHRECTOMY FOR RENAL CELL CARCINOMA: ONCOLOGIC OUTCOMES AT 10 YEARS OR MORE

A. Berger, R. Brandina, M. Aron, M. Desai, L. Kavoussi, I. Gill

**Background:** Purpose: To present oncological outcomes at a follow-up of 10 years or greater following laparoscopic radical nephrectomy for cancer.

**Methods:** Between February 1994 and March 1999, 73 laparoscopic radical nephrectomies were performed by 2 surgeons for pathologically-confirmed renal cell carcinoma (RCC). Data were obtained from patient charts, radiographic reports, telephone follow-up and a check of the Social Security Death Index.

**Results:** Mean follow-up was 11.2 years (range, 10–15 years). Each patient has completed a minimum of 10 year follow-up. Mean patient age at surgery was 60 years. Mean tumor size on CT scan was 5 cm (range, 1.7 to 13). Pathological staging was pT1a 41%, pT1b 30%, pT2 15%, pT3a 10%, pT3b 3% and pT4 1%. High grade tumors (Fuhrman  $\geq$  3) were present in 28% of cases (n = 18). Positive surgical margin occurred in 1 case. Actual 12-year overall, cancer-specific and recurrence-free survival rates were 65%, 92%,

86%, respectively. Twelve-year overall, cancer-specific and recurrence-free survival rates were 35%, 78%, 77%, respectively. At a mean 67 months, 10 patients (14%) developed metastatic disease; 8 out of these 10 patients (11%) died.

**Conclusion:** Long-term oncological outcomes after laparoscopic radical nephrectomy for RCC are excellent and appear comparable to open surgery.

### VP17-12 LAPAROSCOPIC Nephroureterectomy FOR UPPER TRACT TRANSITIONAL CELL CARCINOMA: RESULTS OF A SINGLE CENTER EXPERIENCE

O. Castillo, A. Foneron, I. Vidal-mora, R. Campos, G. Rubio, G. Rubio—Chile

**Background:** To determine the surgical outcomes in patients who underwent laparoscopic nephroureterectomy (LNU) for upper urinary tract transitional cell carcinoma (TCC).

**Methods:** From 1995 to 2008, we performed 49 LNU for upper tract TCC. 4 patients were excluded because the histological diagnosis was not confirmed. Data included sex, age, surgery, management of distal ureter, operative time, blood loss, hospital stay, complications and tumor histology.

**Results:** There were 35 males and 14 females. Mean age was 64 years. Mean operative time was 142 min. Twenty-three procedures were on the right and 26 on the left side. Mean blood loss was 104 ml and conversion rate was 0%. Complication rate was 5%. Median hospital stay was 4 days. Management of distal ureter was through an open approach in 16 cases, and through an endourological approach in 32 patients. Cistectomy was performed in 1 patient. Tumor location was: pelvicalyceal in 26, ureteral in 17 and multifocal in 6 patients. Pathologic staging shows: 35 pT1, 10 pT2 and 4 pT3 specimens. Pathological grade analysis shows: 2 grade I, 27 grade II, 12 grade III and 6 grade IV specimens.

**Conclusion:** LNU reduces morbidity of surgical management for upper tract TCC, with the advantages of minimal invasive surgery. These data supported the continued development of laparoscopic technique in management of upper tract TCC.

### VP17-13 INFLUENCE OF OBESITY UPON LAPAROSCOPIC RADICAL NEPHRECTOMY

H. Dong Youp, K. Ill Sang, S. Ill Young, J. Hee Jong

**Background:** We intended to identify the influence of obesity on the laparoscopic renal surgery as operative results. Our study was performed on the basis of body mass index (BMI).

**Methods:** Between March 2003 and December 2006, patients with localized renal cell cancer underwent laparoscopic radical nephrectomy were included in the study. We divided the patients into 3 groups according to BMI: group I (BMI < 23 kg/m<sup>2</sup>), group II (BMI 23.1–24.9), group III (BMI > 25). Patients with abdominal operation or radiation exposure histories were excluded from the study. The study has been started at the time of operator's overcoming of the learning curve for laparoscopic radical nephrectomy. Operative data were reviewed retrospectively.

**Results:** Forty-one patients were included in the study. Mean age of three groups were respectively 61.2  $\pm$  6.7 years, 58.2  $\pm$  6.1 years, 59.2  $\pm$  5.7 years and mean BMI was 20.3  $\pm$  2.6 in group I (n = 15), 24.1  $\pm$  0.8 in group II (n = 12) and 27.9  $\pm$  2.2 in group III (n = 14). According to the obesity degree, operation time have meaningfully increased group III (group I: 162.1  $\pm$  39.4, group II: 147.5  $\pm$  17.5, group III: 199.4  $\pm$  2.2 minutes). Complications of

laparoscopic radical nephrectomy including transfusion rate have no relation with obesity degree.

**Conclusion:** For laparoscopic renal surgery, obesity could influence on operative time but complications.

#### **VP17-14 OFF-CLAMP LAPAROSCOPIC PARTIAL NEPHRECTOMY: THE ULTIMATE STRATEGY FOR RENAL PROTECTION**

A. Herati, A. K. Srinivasan, A. K. George, S. S. Saluja, L. Richstone, L. R. Kavoussi—United States

**Background:** Recent focus in laparoscopic nephron sparing surgery has been to identify techniques to decrease warm ischemia time. We felt that laparoscopic partial nephrectomy could be safely performed in select patients without clamping the hilar vessels and thus avoid warm ischemia altogether. In this study we compare the perioperative outcomes of laparoscopic partial nephrectomies performed on-clamp and off-clamp.

**Methods:** A total of 273 patients underwent laparoscopic partial nephrectomy from June 2006 to May 2009 by a single surgeon (LRK). Of these 273, 189 cases were performed on-clamp and 84 were performed off-clamp. The decision to perform off-clamp surgery was based on tumor size and position and surgeon preference. The two groups were compared using Mann-Whitney U Test and  $p < 0.05$  was considered significant.

**Results:** Both groups were comparable for patient demographics, ASA score, operative blood loss, transfusion rate, postoperative complications, and length of hospital stay. Off clamp group had more patients with exophytic tumors (50.6% vs. 28.4%,  $p < 0.05$ ), less hilar tumors (15 vs. 29,  $p < 0.05$ ) and the overall tumor burden was lower (25.73 vs. 40.83 cm<sup>3</sup>,  $p < 0.05$ ). Comparing operative outcomes, operative time was significantly lower in the off-clamp arm (131.88 vs 145.75 min,  $p < 0.05$ ). Additionally, the patients in the off-clamp group had a significantly a smaller increase of creatinine from baseline compared to patients in the clamped group (5.67% vs 28.91%,  $p < 0.05$ ).

**Conclusion:** Off clamp laparoscopic partial nephrectomy is an excellent option for selected patients with no added adverse effects when compared to clamped laparoscopic partial nephrectomy. But it provides the additional benefits of minimal change in renal function from baseline and shorter operative time compared to the clamp group.

#### **VP17-15 CONTEMPORARY OUTCOMES OF OPEN VERSUS LAPAROSCOPIC PARTIAL NEPHRECTOMY: IMPACT OF THE 'EARLY UNCLAMPING' TECHNIQUE**

K. Kamoi, M. Aron, M. Desai, R. Brandina, A. Berger, I. Gill

**Background:** Initial laparoscopic partial nephrectomy (LPN) data indicated somewhat greater ischemia time and postoperative hemorrhage rate vis-à-vis open partial nephrectomy (OPN). To address these 2 remaining issues, a novel 'early-unclamping' LPN technique was developed. To evaluate the impact of this technique, we retrospectively compare 450 patients undergoing contemporary OPN, contemporary 'early-unclamping' LPN, and previous conventional LPN.

**Methods:** 450 consecutive non-randomized patients with a single, clinical stage T1 tumor <7 cm underwent OPN-contemporary (05/2006–08/2008; n = 150), LPN-contemporary (01/2007–09/2008; n = 150) and LPN-previous (04/2005–12/2006; n = 150). All OPNs were performed by one surgeon (ACN), and all LPNs by one

surgeon (ISG). Data, collected prospectively, were analyzed retrospectively.

**Results:** OPN-contemporary patients had larger tumors (3.7 vs 3.1 cm) and higher surgical risk, while LPN-contemporary patients had shorter ischemia time ( $p < 0.0001$ ) and lesser urological complications ( $p = 0.02$ ). To adjust for demographic differences, OPN- and LPN-contemporary patients with 2 kidneys (n = 252; 84%) were stratified for tumor size ( $\leq 4$  cm and  $> 4$ –7 cm) and operative indication (elective and imperative). Even after stratification, LPN-contemporary patients had shorter ischemia time and similar peri-operative outcomes as OPN-contemporary patients. Renal function outcomes in the LPN-contemporary cohort were superior after imperative PN (n = 107), and similar after elective PN (n = 145) compared to OPN-contemporary cohort. Compared to LPN-previous, the LPN-contemporary cohort had shorter ischemia time and superior renal functional outcomes ( $p < 0.0001$ ).

**Conclusion:** In this retrospective 2-surgeon study, contemporary 'early-unclamping' LPN provided shorter ischemia times and equivalent complications and renal functional outcomes as contemporary OPN, albeit with decreased patient morbidity. A prospective randomized study is warranted to substantiate these findings.

#### **VP17-16 RETROPERITONEAL LAPAROSCOPIC PARTIAL NEPHRECTOMY: THE LEARNING CURVE OF SINGLE SURGEON**

O. Kyung-jin, K. Young-jung, N. Deok-hyun, P. Kwangsung, R. Soo-bang, K. Dong-deuk—Korea

**Background:** Retroperitoneal laparoscopy may have some merits over transperitoneal laparoscopy in organ confined renal tumor undergoing partial nephrectomy. We present outcomes in 60 consecutive patients performed by a single surgeon (DK).

**Methods:** Between November 2004 and December 2008, 60 consecutive patients with organ confined renal tumor underwent retroperitoneal laparoscopic partial nephrectomy by a single surgeon. The 60 patients were divided into 3 groups (early, intermediate and late group) according to the time of operation, consecutively. The perioperative result, complication and oncologic outcome were investigated to analyze the single surgeon's learning curve.

**Results:** At early group, 2 patients were converted to open surgery and 1 patients were converted to laparoscopic radical nephrectomy. But, laparoscopic partial nephrectomy of intermediate and late groups were successfully completed. Mean operative time (194.4 vs 163.3 minutes,  $p = 0.000$ ), blood loss (417.5 vs 131.2 ml,  $p = 0.004$ ) and warm ischemia time (45.7 vs 29.9 minutes,  $p = 0.000$ ) were significantly reduction in late group compared with early group. Renal mass size, hospital stay, time to diet, time to ambulation and perioperative complication rate were not significantly different. During the follow up evaluation, no recurrence was presented.

**Conclusion:** Our results showed that retroperitoneal partial nephrectomy can be performed in a safe and timely manner with good oncologic results. Although it is technically challenging, it could overcome with surgeon's experience.

#### **VP17-17 COOLING AND MAINTENANCE OF LOW TEMPERATURE IN RETROPERITONEOSCOPIC PARTIAL NEPHRECTOMY USING ICE STICKS**

N. Ioritani, M. Aizawa, S. Matsuura, A. Takeuchi, T. Kudo



**Background:** In retroperitoneoscopic partial nephrectomy, various methods for cooling the renal parenchyma have been reported for cold ischemia. However, these methods, such as ice slush immersion, transureteral irrigation with cold water, are complicated and take time to start resection, because clear view can not be obtained until the cold water is aspirated. More over, additional cooling by these methods for low temperature maintenance is not practical for the limited ischemic time. We have been using ice sticks which enable quick start of parenchymal resection and additional cooling.

**Methods:** Ice sticks were prepared in stainless pipes (11 mm in diameter and 220 mm long) and saline. One set of sticks were made from eight pipes and about 200 ml saline. The operation was done retroperitoneally. After arterial clamping, two sets of ice sticks (400 ml) were applied through a 12 mm port. The parenchymal temperature was measured by thermocouples. An additional set of ice sticks was applied every 20–30 minutes for low temperature maintenance. This method was done on 36 cases.

**Results:** It took about three minutes for application of two sets. Parenchymal temperature decreased to 20°C at three minutes and reached to 10°C at six minutes. Then it turned to increase gradually to 20 to 25 degrees at 20 minutes. Additional one set could maintain 20–28 degrees in another twenty minutes.

**Conclusion:** Ice stick cooling was easy and repeatable method for renal cooling, by which low temperature could be maintained. It did not disturb the laparoscopic sight and enabled quick start after arterial clamping. Approximate temperature could also be assumed by the presence of solid ice without measuring the temperature.

#### VP17-18 LAPAROSCOPIC PARTIAL NEPHRECTOMY: IMPACT OF RESECTED VOLUME ON RENAL FUNCTION OUTCOME

F. Bagheri, C. Pusztai, J. Székely, Z. Szabó, I. Buzogány, L. Farkas

**Background:** After partial nephrectomy surgeries, renal function deterioration is expected due to the ischemia-reperfusion injury and the volume loss in the operated kidney. The preferred method for evaluation of renal functional loss is differential isotope examination; although, the extent of functional loss followed by parenchymal resection or by ischemic injury is not defined by this assessment. To evaluate the impact of volume loss on renal function, we have designed a prospective study.

**Methods:** From June 2005, we have performed 53 laparoscopic partial nephrectomies for treatment of small renal masses. All cases were approached transperitoneally, and en bloc hilar control was applied using Rummel tourniquet. The last 40 patients were evaluated prospectively. In these patients, total differential renal function using <sup>99m</sup>Tc-DMSA was evaluated preoperatively and postoperatively. In these examinations, special region of interest (ROI) was also applied to compare the intact half of the operated kidney with the same part on the other kidney. This measurement was used as the definitive renal functional loss resulted from ischemic-reperfusion injury.

**Results:** The mean warm ischemia time in our last 40 patients was 23 minutes (12–32). The mean weight of the resected specimen was 16 grams. Considering the total differential renal function, even though our warm ischemia time was below 32 minutes in all patients, we found an average of 6% decrease in renal function of the operated kidney 3 months after operation. However, the intact half of the operated kidney had only an average of 2% decrease in

the renal function. On the other hand, we didn't find any significant correlation between warm ischemia time and kidney function loss. We noted that the more kidney parenchyma resected, the more functional loss were detected.

**Conclusion:** In partial nephrectomy operations, due to the volume loss of normal parenchyma of the kidney caused by resection and parenchymal suturing, a decrease in kidney function is expected. This decline should be distinguished from the functional loss caused by warm ischemia time.

#### VP17-19 LAPAROSCOPIC NEPHRECTOMY FOR XANTHOGRANULOMATOUS PYELONEPHRITIS

M. Lopes de lima, J. Moro, R. Bertti, N. Rodrigues Netto Jr., P. César Rodrigues Palma

**Background:** This type of surgery is currently associated with great operative difficulty and surgical complications. We describe the results of laparoscopic nephrectomy for xantho-granulomatous pyelonephritis complicated with calculus and previous pyonephrosis.

**Methods:** Between March 1998 and April 2006, 42 patients (18 men and 24 women) with a mean age of 46.4 years were submitted to a laparoscopic nephrectomy for a unilateral nonfunctioning kidney with previous diagnosis of renal chronic inflammation complicated with calculus and previous pyonephrosis. All the nephrectomies were performed using transperitoneal approach, a similar technique used for radical nephrectomy. All the patients were previously evaluated with abdominal CT and nuclear medicine.

**Results:** Laparoscopic nephrectomy for renal chronic inflammation was successful in 34 of the 42 cases. Eight cases were converted to the open technique because of the difficulty in progression—dense adhesions in the pediculous or perirenal region. The mean operative time was 184 minutes. One major (colon lesion) and two minor (wound infection) complications occurred. The number of days to first postoperative oral feeding and first ambulation (first day), time of hospitalization (2.8 days), and number of patients requiring parenteral analgesics were similar to other laparoscopic nephrectomies. Diagnosis of xantho-granulomatous pyelonephritis was confirmed pathologically in all the specimens. There was increase in conversion to open surgery when the renal size was greater than 12 cm, or when the renal vessels were not isolated in the first 90 minutes of operation time.

**Conclusion:** Laparoscopic nephrectomy does not increase the specific risks associated with surgery for these renal pathologies.

#### VP17-20 CONTEMPORARY OUTCOMES OF OPEN VERSUS LAPAROSCOPIC NEPHROURETERECTOMY: CASE-MATCHING ANALYSIS

J. Soh, A. Kawauchi, K. Kamoi, N. Hirahara, Y. Naitoh, T. Miki—Japan

**Background:** We compared a contemporary, consecutive cohort of patients with upper tract urothelial tumor undergoing laparoscopic nephroureterectomy (LNU) with the most recent patients undergoing open nephroureterectomy (ONU).

**Methods:** Consecutive, non-randomized patients undergoing LNU (May 1999 to March 2009; n = 181) and ONU (January 1999 to April 2009; n = 115) were compared. All data (baseline, peri-operative, oncological outcomes) were collected prospectively. A propensity score for selection of surgery (LNU or ONU) was constructed using multivariable logistic regression. Case-matching

and multivariable regression modeling techniques were used to estimate the association of specific outcomes after adjusting for treatment selection using the propensity score.

**Results:** Case-matching patients undergoing LNU (n = 83) and ONU (n = 83) were comparable as regards mean age, BMI, ASA score, co-morbidities, clinical T stage, existence of ureteral tumor, existence of multiple tumor and surgery year (p > 0.05 for all). LNU patients had longer OR time (263 vs 229 min, p = 0.023), lesser estimated blood loss (281 vs 550 ml; p = 0.0003) and lesser blood transfusion rate (6% vs 22%, p = 0.006). Complication rate

was comparable for both surgeries. Disease-specific survival rate was significantly better in LNU comparing with ONU (p = 0.0363) while pathological T stage, grade and positive surgical margin rate were similar between surgeries.

**Conclusion:** Contemporary patients undergoing LNU had longer OR time, lesser blood loss and better disease-specific survival rate compared to ONU at our hospital group. As such, LNU is now a viable alternative to ONU for most patients with upper tract urothelial tumor.

## VP18: ESWL

### VP18-01 HISTOTRIPSY EROSION OF URINARY STONES W. Roberts, A. Duryea, A. Maxwell, J. Wheat, Z. Xu, C. Cain—USA

**Background:** Shock wave lithotripsy (SWL), though effective, can produce residual stone fragments of significant size, which may lead to incomplete clearance and ureteral obstruction. Previous work has shown that cavitational-based pulsed ultrasound therapy (histotripsy) can finely fractionate tissues. We hypothesize that application of histotripsy for treatment of urinary stones will minimize stone fragment size.

**Methods:** Ultracal-30 gypsum-based cement was used as a model stone in a comparative study between histotripsy and shock wave lithotripsy. For histotripsy pulsed ultrasound energy was generated from a spherically-focused 1-MHz transducer, generating 5 microsecond pulses delivered at a 1 KHz rate with 14 MPa peak negative pressure. SWL was performed with a Wolf Piezolith 3000, using a 2 Hz pulse rate and 14 MPa/76 MPa peak negative/positive pressures. Stones were treated for 5 minutes. Fragments were collected and sieved using filter sizes of 100 micron, 1 mm, and 2 mm.

**Results:** Eight stones were treated with each modality. Histotripsy produced very finely fragmented debris with no particles greater than 100 microns in diameter, while a mean of 24% of fragments produced by SWL exceeded 2 mm. On average 14% of the 0.8 ml model stones were eroded by histotripsy compared to 76% with SWL.

**Conclusion:** Preliminary results demonstrate that histotripsy can erode model kidney stones without generation of fragments greater than 100 micrometers. Although the histotripsy disintegration rate is currently below that of SWL, it should be noted that parameters have not yet been optimized. Further investigation and refinement of histotripsy for treatment of urinary stones may lead to alternative approaches to augment traditional SWL protocols.

### VP18-02 COMPARISON OF THE ANALGESIC EFFECTS OF DEXKETOPROFEN AND DICLOFENAC DURING SHOCK-WAVE LITHOTRIPSY: A RANDOMIZED, DOUBLE-BLIND CLINICAL TRIAL

H. Tokgoz, S. Yurtlu, V. Hanci, O. Turksoy, B. Erol, B. Akduman

**Background:** This prospective, randomized and double-blind clinical study aimed to assess the analgesic efficacy of single dose

intramuscular (i.m.) injection of dexketoprofen (Group DE) compared with single dose i.m. injection of diclofenac (Group DI) in patients undergoing shockwave lithotripsy (SWL) procedure.

**Methods:** A total of 70 males with single renal or ureteric stones were randomly separated into two groups. The 40 males in Group DI received 75 mg i.m. diclofenac sodium and 30 males in Group DE received 50 mg i.m. dexketoprofen trometamol 30 minutes before SWL. A 10-point visual analog scale was used to evaluate pain.

**Results:** The age, body mass index and mean stone burden were comparable between two groups (p > 0.05). Mean visual analog scale score for Group DE was statistically lower compared with the score for Group DI (p = 0.02). In 34 (85%) of the 40 males in Group DI, the SWL procedure was performed with no, minor or tolerable pain. But, in Group DE, 28 (93.3%) out of 30 cases evaluated the pain severity as no, minor or tolerable (p = 0.01). No major/minor adverse effects were observed in Group DI, whereas in 1 patient in Group DE, dyspepsia after injection was noticed (p = 0.423).

**Conclusion:** The severity of SWL related pain was significantly better tolerated with dexketoprofen trometamol. During a SWL procedure, analgesic efficacy of dexketoprofen was greater than that of diclofenac sodium. Although statistically insignificant, a little increased risk for gastric irritation was noticed with dexketoprofen.

### VP18-03 THE EVALUATION OF THE EFFICACY OF EXTRACORPORAL LITHOTRIPSY IN PATIENTS REFERRED TO LITHOTRIPSY CENTERS IN MASHHAD

R. Taghavi, M. Darabi Mahboub, R. Mahdavi Zafarghandi, K. Tavakkoli Tabassi—Iran

**Background:** Efficacy of extra corporal shock wave lithotripsy (ESWL) in patients with renal stones referred to lithotripsy centers in Mashhad for one and half year.

**Methods:** In a cross sectional study, by a simple randomized sampling, 71 patients suffering renal stone entered to this study. The site and size of stones and the, rate of shock waves recorded. And patients were followed (Two and four weeks later) finally the success rate of this procedure and quality of stones were considered.

**Results:** 1. The rate of success rate of extra corporal shock wave lithotripsy in our study was 74.6% 2. From 56 completely delivered stones, 87.6% were Mixed, 10.7% were Uric Acid, 7.1% were Calcium Oxalate, 3.6% were Calcium Phosphate. It is remarkable that all of the Uric Acid stones, Calcium Oxalate Stones and Calcium Phosphate stones in our samples were completely delivered. 3. In our study, 65% of caliceal stones, 78% of pelvic stones and 100% of proximal ureteral stone were delivered which this difference is significant. ( $P < 0.05$ ) 4. 89% of stone smaller than 10 mm and 51.7% of stones bigger than 10 mm were completely delivered which this difference is significant. ( $P = 0.000287$ ) 5. 99% of stones were fragmented by using 2500–3000 shocks.

**Conclusion:** Extra corporal shock wave lithotripsy is more successful in treatment of stone smaller than 10 mm. The highest stone free rate belongs to proximal ureteral stones, more than pelvic stones and more than caliceal stones. We found that 2500–3000 shocks is adequate for fragmentation of stone with any size, location and quality.

#### VP18-04 PANCREATIC SWL: DOES IT PROVIDE SUBJECTIVE RELIEF OF SYMPTOMS AND PREVENT MAJOR SURGERY?

N. Hamilton, M. McIntyre, S. Savage, C. Lawrence, T. Keane

**Background:** Pancreatic Shockwave Lithotripsy (PSWL) is an innovative procedure for patients with pancreatic ductal stones resistant to endoscopic retrograde cholangiopancreatography (ERCP). We examined this treatment to amenable patients who have failed ERCP as an alternative to major surgery

**Methods:** We retrospectively reviewed all patients who underwent PSWL from 12/04–3/09. Body Mass Index (BMI), number of shocks, and the impression of fragmentation were recorded. Immediate complications and subsequent ERCPs were reviewed. Phone interview was undertaken for Patients Global Impression of Change index (PGIC), subsequent surgical procedures, and narcotic use.

**Results:** Average follow-up was 26.3 months. Thirty-two patients underwent 43 procedures. Two additional attempts were aborted due to inadequate visualization. Average age, BMI and number of shocks were 58.5, 24.5, and 4863 respectively with male: female (2.2:1). Fragmentation was good in 30/42 (71.4%), partial in 9/42 (21.4%), none in 3/42 (7.1%), 1 unknown. Two patients had post-SWL complications. One was hospitalized for pain and another hepatic abscesses. 28/32 patients were available for phone follow-up. Average number of post-SWL ERCPs was  $< 1$ . 19/28 patients (67%) were successful based on PGIC scores. 6/28 (21.4%) went on to surgery. Only 4/22 (18%) of the non-surgery group used narcotics and 3/4 reported less than pre-procedure.

**Conclusion:** Pancreatic SWL provided safe, subjective relief in 67% of patients. This prevented major surgery in 78% and decreased narcotic use to 18% in non-surgical patients.

#### VP18-05 THE USE OF ETHYL CHLORIDE FOR PAIN CONTROL DURING EXTRACORPOREAL SHOCK WAVE LITHOTRIPSY

J. Heretis, V. Adamopoulos, U. Vergetaki, T. Karagounis, M. Venieri, F. Sofras—Greece

**Background:** To evaluate the efficacy of spray ethyl chloride compared with nonsteroidal anti-inflammatory drug during extra-

corporeal shock wave lithotripsy (ESWL) in a prospective randomized study.

**Methods:** Of 120 patients, 60 received 15 mg meloxicam 40 minutes before the ESWL session and 60 received ethyl chloride, applied to the skin of the flank at the area of entry of the shock wave marked by the urologist. The electromagnetic lithotripter 220f-xp (Dornier) was used. The degree of pain was rated by the patients using a 10-point visual analog scale.

**Results:** In 58 patients in the ethyl chloride group (96%) the entire procedure was performed with no, minor or tolerable pain after the application of ethylene chloride spray (mean pain score 3, 5). In 2 patients (4%), ESWL was interrupted because of intolerable pain. Of the 60 meloxicam group patients, 50 (83%) underwent the entire procedure with no, minor or tolerable pain after the i.m. injection of meloxicam (mean pain score 5, 2). In 10 patients from meloxicam group (17%) ESWL was interrupted because of intolerable pain.

**Conclusion:** Our findings have indicated that the pain scores were significantly lower for the ethyl chloride group than for the meloxicam group. In addition to the local anesthetic effect of ethyl chloride there were not any side effects in this group. Ethyl chloride spray seems to be a very promising agent for pain control during ESWL.

#### VP18-06 EXTRACORPOREAL SHOCK WAVE LITHOTRIPSY IN PEDIATRIC PATIENTS: OUR EXPERIENCE USING THE EMSE 220 F-XP LITHOTRIPTER

J. Heretis, D. Glaritis, G. Daskalopoulos, K. Makatounaki, M. Metaxari, F. Sofras—Greece

**Background:** We report our 6-year experience in the management of pediatric urinary lithiasis with extracorporeal shock wave lithotripsy (ESWL) using the EMSE 220F-XP (Dornier) lithotripter.

**Methods:** Between 2003 and 2008, 30 children (age range 10 months–14 years; mean 8.5 years) were treated with the EMSE 220F-XP for urinary lithiasis. In 16 children younger than 8 years of age the ESWL procedure was performed under general anesthesia, while for the rest of the children, older than 8 years, we used cream lidocaine 1% locally plus supp. Paracetamol one hour before the SWL procedure. Stones were located in the kidney in 8 children, the renal pelvis in 5, the upper ureter in 7, the middle ureter in 4, and the lower ureter in 6. Their size ranged from 5 mm to 25 mm (mean 11.4 mm). Double-j stent was placed in two patients before the ESWL procedure. An average of 2300 shock waves per procedure was performed. Stone clearance was assessed at 1 and 3 months. Clinical success was defined as no radiological evidence of stone or residual fragments 3 mm or less.

**Results:** Total 34 stones were treated. The stone free rates for renal and ureteral stones were 84.6% (11 patients) and 82.3% (14 patients) respectively. The overall clinical success was 90%. In 4 children multiple ESWL sessions were necessary. Intraprocedural pain for the children without general anesthesia was tolerable. Complications were infrequent and generally minor for all patients.

**Conclusion:** The use of EMSE 220F-XP lithotripter for urinary stones in pediatric patients is safe and offers high stone free rates and minor complications. Older children can tolerate the ESWL procedure without general anesthesia or intravenous analgesia. We strongly believe that ESWL is the primary treatment of choice for urinary stones less than 20 mm.

### VP18-07 INITIAL EXPERIENCE WITH A NEW DUAL-SHOCKWAVE LITHOTRIPTER IN THE MANAGEMENT OF UPPER URINARY TRACT CALCULI

J. Abbaraju, A. Sahai, F. Anjum, S. Madaan, H. Marsh, S. Sriprasad—United Kingdom

**Background:** The majority of lithotripters utilised for ESWL have a single source generator of shockwaves. We report our preliminary results with a new dual-shockwave lithotripter (Duet, Direx) in managing upper urinary tract calculi.

**Methods:** Patient demographic, procedure & stone data was collected prospectively from 144 consecutive patients attending for ESWL from August 2007 to June 2009 treated with Analgesia at 240 shocks/min. All patients were reviewed in the clinic at 4–6 weeks post ESWL with a plain X-ray. Success was defined as stone free or stone fragment <3 mm.

**Results:** Of the 144 patients, 7 were excluded (3 did not tolerate the analgesia and 4 had intraparenchymal stone) and the rest 137 were included in the study. The male: female ratio was 103:34. One hundred and eighteen patients had a single procedure, 18 had two procedures and 1 patient had 3 procedures. The mean stone size was 8.86 mm (range 4–19 mm). Seventeen patients had a ureteric stent in situ. The distribution included upper (12%), mid (9%), lower (56%) calyceal stones as well as pelvic (15%) and proximal ureteric (8%) calculi. The dual-shockwave asynchronous mode was utilised in 88% of patients with a mean shockwave time of 13 minutes. Nine patients (6%) did not tolerate the procedure well and one patient was admitted overnight for analgesia. The overall stone free rate was 78.11%.

**Conclusion:** Dual-shockwave lithotripsy is safe, quick and effective in treating upper urinary tract calculi. Stone free rates may improve with the use of sedation for big or hard stones.

### VP18-08 URETERAL STENT DURING EXTRACORPOREAL SHOCK WAVE LITHOTRIPSY: WHICH ROLE?

M. Sighinolfi, S. Micali, A. Beato, S. De stefani, G. Pini, G. Bianchi

**Background:** Even if routine ureteral stenting has not been recommended as a part of extracorporeal shock wave lithotripsy (SWL), urgent occurrences bring up the need for stent positioning. The actual role of those devices on SWL outcomes still remains controversial. The aim of this study is to evaluate SWL with and without ureteral stent.

**Methods:** 40 pts (Group A) with ureteral stent have been prospectively considered: stent was previously positioned for urosepsis (30), as preSWL auxiliary procedure (4), after endoscopic lithotripsy of ureteral stone with untreated renal stone (6). Stone location was: 12 pelvic, 13 ureteral, 15 calyceal stones. Mean stone size was 9.7 mm. A total of 44 pts (Group B) complaining of acute renal colic due to reno-ureteral stones were considered as control group. Mean age, stone size, location and composition were similar among the 2 groups. All subjects were submitted to SWL with Dornier LithotripterS XXP. Stone free rate, time to stone free condition, number of sessions were compared with non parametric tests.

**Results:** Stone free rate was 72.5% with ureteral stent and 81.8% in the control group ( $p = 0.224$ ). Unless post-SWL renal colic was more frequent without ureteral stent, no auxiliary procedures were requested. Mean number of session was similar among groups (1.58 in GroupA, 1.3 in GroupB,  $p = 0.233$ ). Opposite, time to

stone free condition was significantly shorter in the control group (Group A: 90; Group B: 45days,  $p = 0.03$ ).

**Conclusion:** SWL treatment with ureteral stent still remains a matter of argue. This brief analysis shows similar outcomes of SWL regardless ureteral stent, in terms of stone free rate and mean number of session. However, despite renal colic occurrence, fragment expulsion seems to be faster in patients without ureteral stent.

### VP18-09 CLEARANCE OF LOWER POLE KIDNEY STONES USING FOCUSED ULTRASOUND TECHNOLOGY

A. Shah, B. Cunitz, W. Lu, M. Sorensen, L. Crum, M. Bailey

**Background:** Lower pole kidney stones have lower rates of stone clearance after extracorporeal shock wave lithotripsy treatment compared to other stone locations because of dependant positioning. We describe the use of acoustic radiation force and streaming created by transcutaneous focused ultrasound to manipulate the location of stone fragments within the collecting system in order to facilitate passage of residual stone fragments.

**Methods:** Artificial and human stones were placed in the lower pole of transparent kidney phantoms and cadaveric porcine kidneys. The focused ultrasound therapy probe consists of an 8-element annular array with a nominal frequency of 2.0 MHz, acoustic power output of 15–20 W at a 50% duty cycle, and programmable focal depth of 4.5–8.5 cm. There is an opening in the center of the therapy probe for an HDI P4-2 imaging probe to provide ultrasound image guidance in a 2D plane. Stone motion was observed visually in the kidney phantom and using both diagnostic ultrasound and fluoroscopy in the porcine kidneys.

**Results:** All stones placed in the kidney phantoms and cadaveric kidneys were seen to move. Stone velocities were on the order of 1 cm/s. Stone displacement distance was up to 3 cm and operators could generally control the direction of stone movement. No evidence of thermal necrosis of renal tissue was observed on gross examination.

**Conclusion:** Focused ultrasound can be used to move stones within the collecting system and may be able to improve rates of lower pole stone fragment clearance. Further studies are required to assess minimum ultrasound exposures necessary to move stones and the bio-effects caused by focused ultrasound devices. Work supported by NIH DK43881 and NSBRI SMST001601.

### VP18-10 HOLMIUM LASERLITHOTRIPSY FOR URETERIC CALCULI: PREDICTIVE FACTORS FOR COMPLICATIONS

M. Baptistussi, M. Morihisa, E. Gewher, A. Martins—Brasil

**Background:** To define possible predictives factors for complications in laserlithotripsy-procedures we performed a retrospective analysis. **Methods:** We analysed all laserlithotripsy-procedures performed in an private center from 2007 until 2009 ( $n = 105$ ). Data included sex, age, stone size, stone location, complications and operator experience. Complications were divided into three groups: infectious, iatrogenic and other. Operator experience was divided into four groups: staff >20 procedures, staff between 10 and 20 procedures, staff <10 procedures and residents (supervised). Mean stone size was 10 mm (3–21 mm). Mean age was 50 years (19–81 years). 66% was male. Multivariate analysis was used to define possible predictive factors for complications.

**Methods:** No methods.

**Results:** The total success-percentage (stone free-rate after 3 months) of 105 procedures was 84.8%. Complications were present in 13 cases (12.4%); 5 iatrogenic, 5 infectious and 3 other. Iatrogenic complications were 4 minor perforations (treated with JJ-catheter) and 1 major perforation leading to distal ureteral necrosis. Infectious complications were short septic periods, treated with antibiotics. Other complications were post-procedural slow start of micturation, a short ileus and technical problems. Complications rate varied significantly ( $p = 0.03$ ) with operator experience: from 4.2% in the most experienced operator group (staff), to 41.7% in the least experienced group (staff). Complication rate in the resident group was 8.3%. Procedures in females tend to have more complications ( $p = 0.09$ ). Stone location, size and age did not influence complication rate.

**Conclusion:** Operator experience is a predictive factor for complications. Experienced operators have less complications. In women more complications tend to occur. Stone location, size and age did not influence complication rate.

### VP18-11 THE ADVANTAGES OF NEW TURKISH MADE COMBINED LITHOTRIPTOR, WITH INTEGRATED, ADJUSTABLE ASPIRATOR FOR PERCUTANEOUS LITHOTRIPSY

R. Saglam, Z. Tokatli, M. Safak, A. Kabakci—Turkey

**Background:** In this study we aimed to study the safety and effectivity of a new Turkish made combined lithotripter with integrated adjustable aspirator.

**Methods:** Between September 2006 and October 2008 we performed PCNL to the 157 patients, diagnosed as kidney stones. We used “Vibrolith PLUS” ELMED Co. Ankara, Türkiye, as a combined ultrasonic and pneumatic lithotripter. The sizes of the stones, fragmentation and evacuation times and mucosal appearance recorded. We started to lithotripsy in all patients with ultrasonic lithotripter. If the stone hard we moved to combined lithotripsy. To provide better vision we adjusted the flow rate of the aspirator. We noted the heating of the hand piece during lithotripsy.

**Results:** Mean stone diameter was 3.7 cm (2.3–6.2 cm), mean fragmentation and evacuation time was 22 minutes (10 – 55 min). In 108 renal unit (67%), ultrasonic lithotripsy was sufficient, in 53 (33%) we used combined lithotripter. Fragmentation rate was 100%. Adjustable aspiration provide better vision, aspirate the small fragments. There was no severe bleeding and no mucosal damage.

**Conclusion:** The new Turkish Lithotripter Vibrolit PLUS was effective. The new hand-piece is light, easy to handle and does not get hot even during prolonged action. The combined energy of the ultrasonic and pneumatic lithotripters results easy and rapid initial cracking of the stone and further fragmentation. Lithotripsy time was shorter. It also does not cause any harmful effect on the urothelium or renal parenchyma. We could not see any damage, perforation, burning or tearing caused by the probes of the lithotripters. Integrated adjustable aspirator was very helpful to provide better vision and aspiration.

### VP18-12 STONE CONE VERSUS NITINOL TIPLESS DORMIA BASKET TO AVOID PROXIMAL STONE MIGRATION

E. Ehab Rifat Tawfik

**Background:** Stone migration is always a challenge during ureteroscopy. In this study we compare the efficacy and safety of stone cone versus nitinol tipless dormia to avoid proximal stone migration during ureteroscopy using the lithoclast.

**Methods:** This study included 133 patients with ureteral stones treated ureteroscopically (73 distal, 25 middle and 35 proximal) using semirigid ureteroscope and lithoclast. Stone cone was used in 64 cases and nitinol tipless dormia basket in 69 cases to avoid stone migration.

**Results:** Ureteroscopy was successful in all except 2 cases due to marked oedema and angulation below the stone. Both the stone cone and nitinol tipless dormia basket were effective in preventing stone migration and no significant gravels were left. In 16 patients with very hard stones we had to switch from stone cone to nitinol tipless dormia to avoid migration. Entrapment of the stone with dormia allowed successful fragmentation of hard stones.

**Conclusion:** Both the stone cone and nitinol tipless dormia basket are effective in preventing stone migration. Nitinol tipless dormia is superior for harder stones using the lithoclast but it needs more experience.

**Key words:** Stone cone ureteroscopy Dormia basket

### VP18-13 RENAL FUNCTION RECOVERY FOLLOWING PERCUTANEOUS NEPHROSTOMY

S. Mohan, R. Jordan, H. Mohd Tarmidzi, K. Subramonian—UK

**Background:** Percutaneous Nephrostomy (PCN) is performed for patients with hydronephrosis and acute kidney injury (AKI) following urinary obstruction to provide temporary or permanent drainage of an obstructed urinary system. Following nephrostomy, the degree of renal function recovery can be monitored using serum creatinine levels. Currently, there are no studies that have quantified the degree and time scale for renal function recovery following PCN.

**Methods:** A retrospective study was undertaken of all patients who underwent PCN between April 2005 and December 2008. A total of 477 procedures were performed during this time period. After excluding failed PCN insertions, re-insertions and ureteric stent insertions, there were a total of 362 procedures. Patients were assigned into benign or malignant groups depending on the cause of obstruction. Data were collected on the patient's baseline creatinine, which on average was 8.7 months prior to presentation. Creatinine levels were recorded at presentation and following PCN at day 1, day 2, day 3, day 4 and finally at plateau. Each creatinine measurement was formulated into an estimated glomerular filtration rate (eGFR) using the MDRD calculator.

**Results:** At presentation 44.8% of patients fulfilled the criteria for AKI according to the Acute Kidney Injury Network classification. The proportion of patients with AKI was higher in the malignant group (55.8%) compared to the benign group (32.9%). The vast majority (95.3%) of patients presented with hydronephrosis. Mild, moderate and severe hydronephrosis was present in 10.2%, 34.5% and 34% of patients respectively. At presentation, the average decline in eGFR from baseline was higher in the malignant group at 54.3% compared to the benign group at 36.2%. Following PCN, the benign group's plateau eGFR recovered to 97.7% of the baseline eGFR and took 21.5 days to do so. In the malignant group, the plateau eGFR recovered to 81.7% of the baseline eGFR and on average was 24.8 days post-PCN.

**Conclusion:** This study shows that PCN is an effective intervention for post-obstructive renal failure and patients are able to recover most of their lost renal function in less than a month. Patients presenting with benign conditions regained their renal function completely within three weeks. Although patients with malignant

conditions had significant improvement, renal function did not recover back to baseline levels.

#### VP18-14 TELESCOPIC VERSUS ONE -SHOT DILATION TECHNIQUE FOR TRACT CREATION IN PERCUTANEOUS NEPHROLITHOTOMY

A. Jitendra, R. Dipak

**Background:** The aim of this study to assess the feasibility and morbidity of metal telescopic dilation technique versus metal single shot dilation technique

**Methods:** 110 patients who underwent PCNL for stone disease from Jan 2008 to Jun 2009, were included in the study. All cases were randomly divided in two groups according to type of technique used for dilation of tract. In group 1-Alken telescopic dilation & group-2 metal one shot dilation technique used. Access tract dilation time, x-ray, exposure time, success rate, & bloodloss & other complication were evaluated

**Results:** One shot metal dilation technique was compared with routine Alken telescopic dilation technique. There was no difference in morbidity. There was no any significant difference in complication. There was definite difference in x-ray exposure & access time

**Conclusion:** One-stage tract dilation for PCNL is safe & effective method in almost in all adult patient.

#### VP18-15 HIGH POWER HOLMIUM LASER IN PERCUTANEOUS NEPHROLITHOTOMY FOR IMPACTED PROXIMAL URETERAL STONES

T. Zhou, X. Gao, Y. Sun—China

**Background:** High power holmium laser has been used in percutaneous nephrolithotomy (PCNL) at our department. In this study we further investigated high power holmium laser in PCNL for impacted proximal ureteral stones.

**Methods:** From January 2006 to June 2007, 58 consecutive patients with an age range from 35 to 67 years (average 52 years), underwent PCNL for impacted proximal ureteral stones. High power holmium laser (70W) was used to fragment the ureteral stones into bigger parts which were subsequently extracted by forceps. The operation time was recorded and the patients were followed up at least two years.

**Results:** All the impacted stones were completely removed with PCNL. The average stone size was  $1.5 \pm 0.5$  cm. The mean operation time was  $60 \pm 15$  min. No severe complications occurred and no transfusion was administered. For at least two years follow-up, no patients had ureteral stricture.

**Conclusion:** Ureteral stricture is one of the most common complications for ureteroscopy with holmium laser in treating impacted proximal ureteral stones. Stone fragmentation with high power holmium laser and extraction with forceps in PCNL can prevent ureteral mucosa damage and avoid future ureteral stricture.

#### VP18-16 TREATMENT OF LARGE UPPER URETER STONE: ANALYSIS OF 97 PATIENTS IN SINGLE HOSPITAL

S. Yoon, K. Lee, T. Kim, K. Kim, H. Jung—South Korea

**Background:** The optimal treatment of upper ureter stone continues to be a point of discussion, as there are different treatment modalities such as Extracorporeal shock wave lithotripsy (ESWL), ureteroscopy (URS), percutaneous nephrolithotomy (PNL), and retroperitoneoscopic ureterolithotomy. An analysis of large upper

ureter stone treated in our institution was made and these results were analyzed.

**Methods:** During the period from January 2008 to March 2009, 97 patients were treated in our institution for upper ureter stone larger than 1 cm. They were treated with 3 methods; ESWL (25 cases), PNL (18 cases) and retroperitoneoscopic ureterolithotomy (54 cases). Retroperitoneoscopic ureterolithotomy was performed with retroperitoneal approach.

**Results:** ESWL group had smaller ureter stones than surgery groups respectively (1.14 cm: 1.54 cm: 1.50 cm). Average follow-up period of ESWL group was 47.4 day and average number of ESWL times were 3.68 times. Compared with PNL and retroperitoneoscopic ureterolithotomy, ESWL group had no difference in success rate (ESWL group: PNL group: retroperitoneoscopic ureterolithotomy group = 92.0%: 96.2%: 94.5%) and complication rate (0%: 11.1%: 14.9%). In two patients who failed with ESWL, PNL was performed. Between PNL group and retroperitoneoscopic ureterolithotomy group, there was no difference in operation time (194 minute: 190 minute), transfusion rate (11%: 6%), post operation hospital day (6.61 day: 6.74 day) and Hemoglobin decrement (1.2 g/dl: 1.3 g/dl).

**Conclusion:** In case of upper ureter stone larger than 1.5 cm, surgical treatment tended to be performed more than non-invasive treatment like ESWL. For upper ureter stone that measures 1–1.5 cm, ESWL as initial therapy may be preferable to surgery.

#### VP18-17 FLEXIBLE URETEROSCOPY FOR A LARGER AND MORE COMPLEX STONE BURDEN: AN ANALYSIS OF THE COST OF EQUIPMENT MAINTENANCE

P. Lowry, T. Ruddell, K. Sam—Texas

**Background:** Technologic progress has allowed development of flexible ureteroscopes which are smaller and have greater dexterity. This allows Urologists to treat a larger, more complex stone burden in a minimally invasive manner. However, treatment of a larger and more complex stone burden requires more operative time, resulting in more strain on the ureteroscope. We present data analyzing the cost of maintaining flexible ureteroscopes.

**Methods:** In a retrospective manner, we obtained the costs for our flexible ureteroscope repair for 6 months October 2008–March 2009). Our institution uses Storz equipment, and contracts with Integrated Medical Systems (IMS) for minor repairs. Major damage is sent to Storz for repair. For the same 6 month period, we reviewed 201 ureteroscopic procedure performed by 8 different surgeons by searching the CPT codes for ureteroscopy with laser lithotripsy, ureteroscopy with basket manipulation, and diagnostic ureteroscopy.

**Results:** Of the 201 Ureteroscopic procedures in this 6 month period, 157 were performed with flexible ureteroscopes. Minor repair costs performed by IMS totaled \$61,107. Major repair costs completed by Storz totaled \$105,548. The total maintenance cost per ureteroscopic procedure was \$1,061.

**Conclusion:** As flexible ureteroscopy is employed to treat a larger and more complex stone burden, maintenance becomes more costly. We must identify factors that place more wear and tear on the scopes, so that we perform surgery in a manner that will preserve function and decrease repair cost. We are actively collecting data on these procedures to further this analysis. Clearly, more study must be performed to examine and subsequently control cost, and a multi institutional study would be of benefit as well to decrease bias.

### VP18-18 STEINSTRASSE AFTER ESWL: THERAPEUTIC RECOMMENDATIONS ABOUT 157 CASES

S. Sallami, S. Ben Rhouma, D. Nizar, M. Weld Sidi Mohamed, Y. Nourira, A. Horchani

**Background:** Steinstrasse (SS) is defined as an aggregation of stones revealed by a plain film; generally due to extracorporeal shock wave lithotripsy (ESWL). This complication became rare, but need a fast and efficient management. Objectives: To focus on the risk factor of SS happening and suggest recommendations for treatment

**Methods:** Between January 1999 and March 2008, 4747 patients were treated for urinary stones by ESWL. This procedure was complicated by SS in 157 patient (incidence = 3%). They were 94 men and 63 women with a median age of 54 years (22–74). The parameters studied were: Initial stone size, location, side of SS, location of SS, length of the SS column, type of SS according to Coptcoat classification and size of the leading stone of the SS. Medical treatment was administrated to all patients for 1 month and endo-urological procedure was proposed if failure of medical treatment.

**Results:** The stone treated by ESWL was renal in 82% of cases and lumbar ureteral in 18%. Age, sex and initial stone location were not found as a risk factor for SS. A stone size superior to 20 mm increase the risk of SS four times. SS column length varied from 1 to 8.4 cm and it was classified in type 1 in 77 cases (49%), type 2 in 47 case (30%) and type 3 in 33 cases. Medical treatment was significantly successful for distal SS ( $p=0.02$ ), in type 1 SS ( $p=0.015$ ) and when the leading stone size was inferior to 6 mm ( $p=0.008$ ). Type 2 or 3 SS and leading stone of SS superior to 6 mm need an endo-urological treatment initially.

**Conclusion:** SS is rare but serious complication of ESWL treatment. Early diagnosis and management is recommended. Medical treatment is efficacious for distal type 1 SS and when the leading stone is inferior to 6 mm in size.

### VP18-19 THE DEVELOPMENT OF STEINSTRASSE AFTER EXTRACORPOREAL SHOCKWAVE LITHOTRIPSY (ESWL): IS IT A PREDICTABLE COMPLICATION?

B. Sami, S. Sallami, B. Mohamed, Y. Nourira, A. Horchani, B. Nawfel

**Background:** ESWL is actually a safe and effective therapeutic tool in the treatment of upper urinary tract stones. The pilling of stone fragments in the ureter, define as steinstrasse, is a serious complication that may require further surgical treatment. We evaluated the patients in whom steinstrasse developed after ESWL treatment to determine clinical course and predictive factors of steinstrasse.

**Methods:** Between October 2007 and June 2009, 922 patients, who were treated by ESWL for upper urinary tract stones, were retrospectively reviewed. They were 584 males and 338 females with a mean age of 52.7 years (18–73). 54 patients (5.8%) were previously treated for upper urinary stones: ESWL ( $n=11$ ), PCNL ( $n=19$ ) and surgery ( $n=24$ ). Double J stenting was performed in 53 cases before and during ESWL. Steinstrasse was developed in 47 patients (5.1%). The stone characteristics (stone size, stone location, number of stones, stone shape and stone burden) were studied on KUB plain film and IVP.

**Results:** Our patients were divided in two groups:ü Group “steinstrasse (+) >> that accounts 47 patients.ü Group “steinstrasse (-) >> that accounts 875 patients. There were no significant difference between the two groups concerning age and sex. According to pre-ESWL evaluation, stones of which steinstrasse developed, in patients who were previously treated for renal stones and who were treated for large stones ( $>2\text{ cm}^2$ ), located in renal pelvis in 68,1% of patients, more than two stones in about half of case. The table emphasizes all data according to the studied parameters. Steinstrasse (+) Steinstrasse (-) P value Previous renal stone surgery/ PCNL 16 (34%) 38 (4,3%) 0.0001 Location of stones:- Renal pelvis- Upper calyx- Mid calyx- Low calyx- Proximal ureter 32 (68,1%)7 (14,9%)1 (2,1%)4 (8,5%)3 (6,4%) 787 (90%)26 (3%)11 (1,2%)32 (3,6%)19 (2,1%) 0.00010.00010.600.190.17 Average stone burden  $2.4\text{ cm}^2$  (1,8– 3,1)  $1.7\text{ cm}^2$  (0,7– 2)  $<0.05$  Stone number  $\geq 2$  ( $n=142$ ) 22 (46,8%) 120 (13,7%) 0.0001 Ureteral J stent previous ESWL 7 (15%) 46 (5,2%) 0.014 **Conclusion:** According to our data, stone size, stone location, stone number, JJ stenting before treatment and previous history of renal surgery are the most significant predictive factors for development of steinstrasse after ESWL.

### VP18-20 THE RELEVANCE OF COUPLING GEL VISCOSITY FOR EFFICIENT ENERGY COUPLING IN SWL

T. Bergsdorf, C. Chaussy, S. Thueroff—Germany

**Background:** Energy transfer in SWL is mostly performed with a coupling bellows and ultrasound gel. Air bubbles in this acoustic interface between shock wave system and patient will be a relevant factor for the reduction of treatment efficacy. In an in vitro setup, coupling gels with different characteristics were investigated regarding coupling quality and quantitative impact on disintegration efficacy.

**Methods:** All experiments were performed in a transparent test tank with integrated membrane for coupling with the shock wave source, installed on a clinical lithotripter (SIEMENS Lithoskop®). To judge the coupling quality, the coupling process was filmed with the use of different ultrasound gels (low, medium and high viscosity, gel disc). In a second setup, artificial stones (AST 0118) placed in a mesh with 2 mm were fragmented (60 SW/min.  $E+12\text{ mm}$ : 31 mJ), to assess the quantitative influence of different coupling gels. The number of shock waves, needed for total fragmentation with different gels was the criterion for efficacy.

**Results:** The quality of coupling (amount of air bubbles in the coupling area) was varying over a wide range, whereas the gel disc and gel of low viscosity yielded the best results. Quantitative impact of different gels SW-number SW-energygel disc 1474.5 Jgel with low viscosity (8780m Pas) 1685.2 Jgel with medium viscosity (24584 mPas) without manual removal of air bubbles 42413 J with manual removal of air bubbles 1685.2 Jgel with high viscosity (40244 m Pas) without manual removal of air bubbles 2648.1 J with manual removal of air bubbles 1875.8 J

**Conclusion:** Our in vitro findings indicate, that the selection of a proper coupling medium (gel disc or gel with low viscosity) or the accurate removal of air bubbles plays a key role for efficient SWL therapy.

## VP19: NEW TECHNOLOGY

### VP19-01 FOUNTAIN TECHNIQUE FOR FRAGMENT EVACUATION AFTER PULVERISATION OF LARGE BLADDER CALCULI

A. Ashish Patil—India

**Background:** To present a novel technique of evacuating fragments after endoscopic pulverisation of large vesical calculi

**Methods:** A technique was developed for evacuation of the large stone fragment bulk resulting after a suprapubic percutaneous pulverization of bladder stones more than 4 cms. Percutaneous suprapubic 30F access sheath was introduced under cystoscopic guidance. The per urethral cystoscope sheath was left in situ. Pulverisation of the calculus was performed by suprapubic route. Post pulverization urethral sheath was used for forceful irrigation which helped flush out the calculi through the suprapubic sheath (The Fountain technique). Suprapubic and transurethral catheters were placed postoperatively.

**Results:** Seven patients with a median age of 45 years (range 30 to 66) were treated using this technique. 3 underwent transurethral resection of the prostate at the completion of stone clearance. The median stone size was 46 mm (range 40 to 55 mm), and the median lithotripsy time was 36 minutes (range 25 to 50). The median postoperative hospitalization was 3 days (range 2 to 5), and complete stone clearance was achieved in all cases. No complications were observed intraoperatively or postoperatively. The median follow-up was 10 months (range 3 to 15).

**Conclusion:** The Fountain technique is a safe, fast and effective for the evacuation of stone bulk after pulverisation of large bladder calculi. It augments the advantage of suprapubic endoscopic approach for stone treatment. It can be used for evacuation of TURP specimen when the same is combined with stone surgery. It does not alter the intraoperative or post operative morbidity.

### VP19-02 A SAFE AND EFFICIENT TECHNIQUE FOR INITIAL ACCESS TO INTRAPERITONEAL LAPAROSCOPY

A. Ghazi a., R. Zimmermann, A. Schfler, G. Janetschek

**Background:** One of the fundamental and critical steps in intraperitoneal laparoscopy is the initial access and creation of pneumoperitoneum, although complications associated with port-site placement are uncommon, the potential for associated morbidity is high. Veress needle and direct trocar insertion are blind techniques used to create pneumoperitoneum and are usually accomplished without incident. However, on rare occasions it can lead to major vascular, bowel or abdominal wall injuries. We herein present our experience with a safe and efficient technique to initiate intraperitoneal laparoscopy.

**Methods:** This technique involves; a skin incision is at the site of Veress needle application. The anterior sheath overlying the muscle of the abdominal wall is adequately exposed. Two hook retractors (Fistula hook retractor; single prong, Aesculap AG) are used to fix the sheath on opposite sides, gentle traction of the hooks causes elevation & stabilization of the abdominal wall during application of the Veress needle & creation of pneumoperitoneum. The trocar harboring the telescope is then placed using the same technique of stabilization, thereby avoiding injury to the underlying intra-abdominal structures by the tip of the trocar due to

downward displacement of the abdominal wall during application of this trocar blindly. The remaining trocars can then be applied under vision.

**Results:** This technique has been routinely applied by one of the authors since 1993 & at our institution since 2000 and by which over 1900 cases have undergone intraperitoneal access without any reported complications during initial access.

**Conclusion:** This technique although simple is very efficient & economical method of providing a safe access to intraperitoneal laparoscopy.

### VP19-03 THE APPLICATION OF “ENDO-LAP” APPROACH IN UROLOGY DISEASES

S. Chan, Y. Chiu, S. Lam

**Background:** Laproscopic approach is widely used in urology. However, its lack of 3 dimensional view and genuine touch from surgeon's hands have rendered laparoscopic dissection, sometimes, more difficult than open approach. Endoscopic assisted laparoscopic approach helps in improving the pitfalls in dissection by early identification of the structure. It also helps in marking the margin of the tumour to be resected, which is difficult to be identified extramurally at early stage of the tumour or if the tumour is benign. 3 patients with 3 different ureteric pathologies had endoscopy (ureteroscopy/cystoscopy) assisted laparoscopic ureteric surgery from January to June 2009 in Caritas Medical Center, HKSAR. This study retrospectively looks at these 3 cases and reports the indication, procedure and complication arising from this surgical approach.

**Methods:** Case 1: a 77 year-old male patient with retroperitoneal fibrosis complicated with acute renal failure has ureteroscopy-assisted laparoscopic left ureterolysis in Caritas Medical Centre in February 2009 (right kidney is non-functioning). Operation was carried out in a transperitoneal four-ports approach, both dissection of ureter and subsequent successful mobilization were assisted and confirmed by ureteroscopy. Case 2: a 73 year-old female patient with an obstructing distal ureteric transitional cell carcinoma had cystoscopy-assisted laparoscopic left partial ureterectomy and partial cystectomy in May 2009. Operation was carried out in a transperitoneal four-ports approach, cystoscopy assisted the identification of the tumour and the margin of dissection. Collin's knife was used cystoscopically to mark the margin of partial cystectomy and helped in dissecting out the cuff from the rest of the bladder. Case 3: a 25 year-old male patient with a benign polyp over left PUJ, which failed laser ablation had ureteroscopy-assisted laparoscopic left segmental ureteric resection in June 2009. Operation was carried out in a transperitoneal four-ports approach, ureteroscopy assisted both dissection of ureter and identifying the polyp endoscopically, which marked the margin of resection.

**Results:** Case 1: Pre-operative Whitaker test was positive for obstruction. Intra-operative blood loss was 100 mL. Post-operative course was uneventful, no blood transfusion was required and the post-operative haemoglobin drop was 0. The patient was discharged on day 6. Follow-up nuclear scan showed no obstruction. Case 2: Pre-operative RP showed complete obstruction and ureteroscopy failed to advance through the tumour. Intraoperative blood loss was 200 mL. Post-operative course of uneventful, no



blood transfusion was required and the post-operative haemoglobin drop was 2.3 g/dL. The patient was discharged on day 7. Follow-up ureteroscopy will be done in 6 months' time. Case 3: Pre-operative IVU after laser ablation was positive for obstruction. Intra-operative blood loss was 30 mL. Post-operative course was uneventful, no blood transfusion was required and the post-operative haemoglobin drop was 0.2 g/dL. The patient was discharged on day 6. Follow-up nuclear scan and IVU will be done in three-months' time.

**Conclusion:** This represents the initial experience of ENDO-LAP approach for laproscopic ureteric surgery. Case 1: This case illustrates how endoscopy aids dissection, especially there is dense adhesion over retroperitoneum on reteroperitoneal fibrosis. Case 2: This case illustrates how Ureteroscopy and cystoscopy helped in identifying the VUJ which is deep down in the pelvis, and marking the ureteric cuff margin in the bladder. Case 3: This case illustrates how ureteroscopy helped in identifying the margin of the polyp, as this is a benign pathology, we would like to save as many ureteric tissue as possible. The results were satisfactory in terms of speedy post-operative recovery and good symptomatic and functional outcome. We expect this approach to be adopted widely in other laparoscopic ureteric surgery to improve the efficiency and also safety.

#### VP19-04 NOTES TRANSVAGINAL NEPHRECTOMY: INITIAL CLINICAL EXPERIENCE

W. White, G. Haber, R. Goel, S. Crouzet, S. Brethauer, J. Kaouk

**Background:** To present the first clinical experience of Natural Orifice Transluminal Endoscopic Surgery (NOTES) transvaginal nephrectomy.

**Methods:** A prospective, IRB-approved study was performed to evaluate the feasibility and safety of NOTES transvaginal nephrectomy. Operative candidates included females with a non-functioning kidney and a compelling indication for removal. All patients underwent complete history/physical examination, serologic testing, and appropriate imaging studies. Following consent, a 3 cm posterior colpotomy was made to access the peritoneal cavity. Standard and articulating instruments were employed to perform pelvic adhesiolysis, reflect the colon, and expose the renal hilum. An endovascular stapler was deployed transvaginally to divide the renal hilum. Upper pole attachments were divided using a 65 cm articulating monopolar hook. The kidney was entrapped in a laparoscopic retrieval bag and removed.

**Results:** NOTES transvaginal nephrectomy was successfully completed in 2 patients. Mean patient age was 57.5 years. Mean BMI was 30.57 kg/m<sup>2</sup>. Mean operative time was 405 minutes. Mean EBL was 75 mL. Mean length of hospitalization was 18.5 hours. Mean visual analog pain scale score at discharge was 1/10. No perioperative complications occurred. A 5 mm umbilical port was placed in one patient who had undergone prior pelvic surgery to direct safe vaginal entry. The second case was completed transvaginally without any abdominal instruments or ports.

**Conclusion:** NOTES transvaginal nephrectomy is safe and technically feasible. In patients with prior pelvic surgery, access to the peritoneal cavity should be performed under visual guidance. Future study is needed to better define patient selection criteria and indications for NOTES transvaginal urologic surgery.

#### VP19-05 LAPAROSCOPIC PARTIAL NEPHRECTOMY VS LAPAROSCOPIC ABLATIVE THERAPY: A COMPARISON OF SURGICAL AND FUNCTIONAL OUTCOMES IN A MATCHED COHORT

K. Kiriluk, S. Shikanov, K. Zorn, G. Steinberg, A. Shalhav, D. Lifshitz—USA

**Background:** Patients undergoing laparoscopic ablative therapy (LAT) are often older with more co-morbidities in comparison to patients undergoing laparoscopic partial nephrectomy (LPN). A matched cohort study was performed to compare the surgical and functional outcomes of LPN and LAT.

**Methods:** A prospectively maintained data base of 250 patients who underwent nephron sparing surgery was explored. 51 LAT patients (21 laparoscopic radiofrequency ablation, 30 laparoscopic cryoablation) (Group1) were matched with 51 LPN patients (Group2). A comparison of pre-operative, operative and post-operative outcomes was performed.

**Results:** The 2 groups were similar in age, gender, BMI, preoperative estimated glomerular filtration rate (eGFR), number of co-morbidities and tumor size. Group1 had a lower incidence of endophytic tumor and higher incidence of upper and middle pole tumors. Hilar-vessels clamping was performed only in group2 (47/51 patients). Mean estimated blood loss and operative time were higher in Group2 ( $p < 0.001$ ). Group2 had more operative and less postoperative complications ( $p = 0.18$ ). However, there was no significant difference in transfusion rate and hospital stay. Mean follow-up was 27 and 18 months in groups 1 and 2, respectively ( $p < 0.01$ ). The mean percent change decline of eGFR at the last follow-up was 10 (95%CI: 4–15) and 7.5 (95%CI: 4–11), respectively. In comparison to baseline, eGFR declined significantly ( $P < 0.0001$ ) but there was no difference between the groups.

**Conclusion:** Despite renal ischemia, longer operative time and higher blood loss associated with LPN, the hospital stay and long-term functional outcomes are similar to LAT in a matched cohort study.

#### VP19-06 LAPAROSCOPIC PORTSITE ASSISTED (TRANSPORTAL) ILEAL URETER

M. Ramalingam, K. Senthil, M. Pai

**Background:** We describe the technique of laparoscopic port site assisted (transportal) ileal ureter reconstruction in a tuberculous ureteric stricture.

**Methods:** A 40 year old female patient presented with recurrent UTI and evaluation revealed multiple strictures in the left upper and mid ureter. Right kidney was poorly functioning. Serum creatinine was raised (2.3 mg/dl). Patient had undergone ureteric re-implantation on the right side for lower ureteric stricture 5 years ago. Patient was placed in 45° left loin position. Using 5 ports, the left colon was mobilized and the strictured upper 2/3rds of ureter excised. The 10 mm port in the left iliac fossa was enlarged to 20 mm port and the distal ileum was delivered through this port. This ileal segment (about 20 cm) was isolated and the ileal continuity was restored. The intestine was returned to the peritoneal cavity. The port site was narrowed so as to admit a 12 mm port. Upper end of the isolated ileum was anastomosed to pelvis of the left kidney using 3-0 vicryl over a stent. The lower end of the ileal ureter was anastomosed to the bladder.

**Results:** The operative time was 7 hours and the blood loss was about 100 ml. The recovery was uneventful. The patient was discharged on the 9th post operative day. The serum creatinine settled to 1.5 mg. The nephrostogram done on 14th post operative day showed good drainage. At 15 months followup the serum creatinine is normal and there is no dilatation of the collecting system on the left side.

**Conclusion:** Port site assisted (transportal) laparoscopic ileal ureter is less morbid. The procedure is less time consuming compared to pure laparoscopic ileal ureter.

### VP19-07 8-YEAR OUTCOMES OF RENAL CRYOTHERAPY

M. Aron, K. Kamoi, R. Brandina, A. Berger, I. Gill, M. Desai

**Background:** We present 5–11 year oncologic outcomes after laparoscopic renal cryoablation (LRC).

**Methods:** Between 09/1997 and 10/2008, we performed renal cryoablation in 340 patients. Of these, 80 patients treated by a single surgeon prior to 10/2003 (all laparoscopic) have minimum 5-year follow-up. Follow-up involved MRI imaging on postoperative day 1, 3 months, 6 months, 12 months, and then annually. Cryolesion biopsy was performed at 6-months. All data were prospectively accrued.

**Results:** In the 80 patients with minimum 5-year follow-up, mean age was 66 years. Mean tumor size was 2.3 cm (0.9–5.0 cm). Median ASA score was 3, while mean BMI was 28. Five patients developed local recurrence, 2 had locoregional recurrence with metastases, and 4 had distant metastases without locoregional recurrence. Overall, there were 6 cancer deaths. In the 55 patients with biopsy-proven renal cell cancer (median follow-up 93 mos; range 60–132 mos), 5-year overall, disease-specific, and disease-free survival was 84%, 92%, and 81%, respectively, while 10-year overall, disease-specific, and disease-free survival was 51%, 83%, and 78%, respectively. On multivariate analysis, previous radical nephrectomy for RCC was the only significant predictor for both disease-free survival and disease-specific survival ( $p=0.023$  and  $0.030$ , respectively).

**Conclusion:** Laparoscopic renal cryoablation is effective oncologic treatment for renal mass in select patients. Disease-specific survival of 92% at 5-years and 83% at 10-years is possible. Preceding radical nephrectomy for RCC treatment was the only independent predicting factor for both disease-free and disease-specific survival.

### VP19-08 SCARLESS MICROPORT AUGMENTED RESTORATION OF TRIANGULATION (SMART) SURGERY: A NEW SURGICAL PARADIGM

D. Baldwin, D. Greene, N. Krupp, P. Mahdavi, J. Chamberlin, K. Ebrahimi

**Background:** Laparo-endoscopic single-site surgery (LESS) and natural orifice transluminal endoscopic surgery (NOTES) produce excellent cosmetic outcomes, but are technically challenging with steep learning curves. These challenges have limited their application in urologic surgery. The objective of this study was to test the feasibility of a novel surgical paradigm for minimally invasive surgery that produces a scarless outcome and restores the fundamental principles of triangulation.

**Methods:** Two SMART nephrectomies (Scarless Microport Augmented Restoration of Triangulation) were performed in the

porcine model. A single 2.5 cm umbilical incision was placed and three additional 2 mm ports were placed in a diamond configuration. Specialized instruments were developed which were passed intra-abdominally and assembled at the umbilicus; thereby providing the functionality of a 5 mm or 10 mm instrument with only a 2 mm skin incision. A pinhole camera was brought in through the umbilical incision but suspended and directed with a 2 mm shaft thereby allowing optimal camera positioning. Only hilar ligation and renal entrapment required use of the umbilical port. All other portions of the case including camera visualization, dissection, cauterization, retraction and suction were able to be performed through 2 mm ports using SMART technology.

**Results:** Two porcine SMART nephrectomies were completed with no complications and minimal blood loss. Mean operative time was 99 minutes (82, 115 minutes). The restoration of triangulation made this technique easy to learn and subjectively improved surgeon comfort compared to LESS.

**Conclusion:** SMART represents a new paradigm for scarless minimally invasive surgery. Application of SMART technology could simplify and improve the acceptance for LESS and NOTES.

### VP19-09 PERCUTANEOUS CYSTOLITHOTOMY BY-RETROGARDE APPROACH

S. Sakhal, B. Samadzade, A. Bardide, M. Moradi, M. Omidvar, H. Karami

**Background:** report a safer, easier and more effective method of percutaneous cystolithotomy (PCCL)

**Methods:** This study is a clinical trial in which 10 patients with bladder stone sized 20–100 mm are enrolled. the patients were placed in lithotomy and telenderenburge position, through the urethra a metallic sound (benike) was conducted into the bladder. An incision was made over the tip of the sound while it was palpated in supra pubic region. The incision was deepened till the rip of the sound appeared. Then with the guide of the sound an amplatz sheath was placed over the sound tip and was pushed into the bladder. Finally through the amplatz sheath, with nephroscop, lithotripsy was performed in a method the same as the classic PCCL.

**Results:** All patients achieve stone free statue without early and late complications. Duration of the procedure was much shorter in comparison With classic PCCL. (antegrade approach).

**Conclusion:** PCCL With retrograde approach is safer, easier and more effective technique in comparison with classic PCCL. This approach can be done by general urologist while the ante grade approach needs to be an endourologist. This method is performed without the need for fluoroscope and dilator, and is prevented of over advancement of the amplatz sheath and those less probability of injury to bladder and bowls wall.

### VP19-10 TRANSMESOCOLIC APPROACH TO LAPAROSCOPIC PYEOLITHOTOMY

M. Ramalingam, K. Senthil, M. Pai

**Background:** We describe the technique of transmesocolic approach to laparoscopic pyelolithotomy. Large renal pelvic stones can be managed by multiple puncture PCNL or sandwich therapy (PCNL + ESWL). Laparoscopic pyelolithotomy by a transmesocolic approach is a alternative nephron sparing technique.

**Methods:** A 35 year old man presented with left loin pain of short duration. IVU showed large left renal pelvic stone. The patient was

placed in the 70° lateral position. Using 4 ports without mobilizing the colon, the left renal pelvis and upper ureter were approached by incising the mesocolon. A stay was taken from the cephalic segment of pelvis. A linear pyelotomy was made and large pelvic stone extracted in toto. A double pigtail stent (6Fr) was introduced antegrade through a Veress needle cannula. Pyelotomy was closed using 4-0 interrupted vicryl sutures. A tube drain was left in. Mesocolic rent was closed using 3-0 vicryl. This method gives good illumination as the colon is not mobilized.

**Results:** The operative time was 150 minutes, post operative period was uneventful. The tube drain was removed on day 5. IVU done 3 months post operatively showed good functioning left kidney.

**Conclusion:** Laparoscopic transmesocolic pyelolithotomy is safe and effective alternate method to treat the large pelvic stones. The calculus can be usually removed intoto. This also gives good illumination as the colon is not mobilized.

### VP19-11 PURE NOTES NEPHRECTOMY: FROM THE CADAVER MODEL TO THE FIRST SUCCESSFUL CLINICAL CASE

M. Aron, A. Berger, M. Desai, R. Brandina, I. Gill, R. Sotelo

**Background:** Objective: To present our stepwise technique development from cadaver to the first successful clinical case of NOTES transvaginal radical nephrectomy for tumor.

**Methods:** We performed in 4 fresh female cadavers, 3 nephrectomies (2 right, 1 left side). The four clinical cases were performed at two institutions. Using one multichannel access port in the vagina and only one in the umbilicus, laparoscopic visualization, intraoperative tissue dissection, and hilar control were performed transvaginally and transumbilically. The intact specimen was extracted transvaginally.

**Results:** In the cadaver, one procedure was not completed because of intra-abdominal adhesions. Additional dissection through the umbilical port was necessary in less than 5% of the first 2 procedures to free the upper pole. Last procedure was performed without any additional dissection through the umbilical port. The first three NOTES clinical cases were electively converted to standard laparoscopy because of rectal injury during vaginal entry, of failure to progress, and of gradual bleeding during upper-pole dissection after transvaginal hilar control, respectively. The fourth case was successfully completed via transvaginal and umbilical access. Operative time was 3.7 h, estimated blood loss was 150 cm, and hospital stay was 1 d. Final pathology confirmed a 220-g, pT1b, 7-cm, grade 2, clear-cell renal cell carcinoma with negative margins. The patient was readmitted for an intraabdominal collection that responded to drainage and antibiotics.

**Conclusion:** Although transvaginal nephrectomy is feasible in the highly selected patient with favorable intraoperative circumstances, considerable refinements in technique and technology are necessary if this approach is to advance beyond mere anecdote.

### VP19-12 INTRA-OPERATIVE SELECTIVE RENAL ARTERY BALLOON OCCLUSION DURING LAPAROSCOPIC RADICAL NEPHRECTOMY

S. Kommu, M. Nayeemuddin, A. Golash, C. Luscombe, J. Asquith, D. West—United Kingdom

**Background:** Laparoscopic Radical Nephrectomy (LRN) can be technically challenging with potential for complications including significant blood loss. Selective renal arterial embolisation prior to undertaking these procedures has been purported to be a useful

adjunct. Herein, we present our experience with temporary Intra-operative Selective Renal Artery Balloon Occlusion immediately prior to LRN.

**Methods:** A percutaneous transfemoral approach was used to perform arterial catheterisation and temporary balloon occlusion of the renal artery with the aid of a 5Fr double lumen occlusion catheter. Indications for selection for this procedure included renal tumours greater than 7 cm and/or those with venous involvement. The procedure was performed after intubation and ventilation immediately prior LRN. Data was collected prospectively. Information was compared with matched patients who had open radical nephrectomy (ORN) with balloon occlusion and LRN without balloon occlusion.

**Results:** There were 15 cases (7 males & 8 females) with average age of 61 yrs (range 39–82 yrs). Average operative time was 185 mins (range 90–250 mins). The mean balloon deployment time for balloon rendered occlusion of the main renal artery was 22 mins (range 14–27 mins). Mean estimated blood loss in LRN with balloon occlusion was 120 mls compared to 450 mls for ORN with balloon occlusion and 250 mls for LRN without balloon occlusion. There were no major complications. One patient had a small haematoma at the femoral entry point that was controlled by pressure.

**Conclusion:** Intra-operative Selective Renal Artery Balloon Occlusion is a safe, reliable and effective adjunct in performing LRN in selected cases. The technique should be explored further as a useful adjunct during surgical extirpation of the kidney for large renal tumours.

### VP19-13 AN ENDOSCOPIC TRANSVESICAL ANASTOMOSIS: REALIZATION OF NATURAL ORIFICE SUTURING TECHNIQUES

M. Humphreys, J. Sauer, P. Andrews

**Background:** Natural Orifice Translumaenal Endoscopic Surgery (NOTES™) is rapidly evolving. One area of difficulty is the unique challenges of using natural orifices (transgastric, transanal, transvaginal and transvesical) and achieving a hermetic closure of the portal. The purpose of this research is to describe a novel method of endoscopic natural orifice suturing.

**Methods:** Porcine surrogate bladders and fresh frozen human cadavers were used. Transvesical circumferential incisions separated the bladder from the urethra. Early attempts used commercially available SR-5 LS suture devices (LSI Solutions, Victor, NY), 3-0 monofilament suture with extracorporeal knots. Subsequent attempts used a modified Running Device and adapted Ti-Knot replacement device (LSI Solutions, Victor, NY) through a prototype offset endoscope and cannula to achieve water tight anastomoses. The anastomosis in the last two cadavers was achieved with customized versions of the previously described equipment.

**Results:** The transvesical incision was closed in all cases, using 4–8 simple interrupted sutures. The early SR-5 LS device worked well in the animal model but was not ideal in the human cadaver. The second generation devices allowed excellent water tight closure without the need for knot tying. The latest generation of devices used fixed instrumentation and a novel 60° scope to visualize the tissue closure.

**Conclusion:** NOTES™ applications may not be relevant for every surgical procedure, but this project demonstrates how ingenuity and a pioneering spirit may eventually allow conceptual translation. This equipment and techniques require further investigation

and experience before being added to the NOTES™ surgical armamentarium.

#### **VP19-14 RENAL VESSEL SHIELDING IN LAPAROSCOPIC RENAL MASS CRYOTHERAPY (VIDEO ABSTRACT)**

A. Benson, B. Schwartz—United States

**Background:** With the widespread use of advanced cross-sectional abdominal imaging, incidentally found renal masses are increasing in number. These incidentally found renal masses often are in elderly patients with many medical co-morbidities. Minimally invasive surgical techniques, including laparoscopic partial nephrectomy and laparoscopic renal cryotherapy, are becoming standard treatment for these small masses in the elderly population to avoid present or future complications related to co-morbidities. Similar to other minimally invasive techniques, laparoscopic renal mass cryoablation may be complicated by pathology-to-anatomy relationship and require a novel approach for success.

**Methods:** Using video presentation, we demonstrate a novel approach in laparoscopic cryotherapy for an upper pole renal mass in a 73-year-old woman. The renal mass was seen to be in direct contact with the main renal vessels and a segmental renal artery. Two sterile foam pledgets were used to shield the main renal and superior segmental arteries along with a wide vessel loop to displace the main renal vein away from the sub-zero temperatures generated by the cryoablation probes.

**Results:** Displacement of the renal vein with gentle traction and shielding of the main and superior segmental renal arteries with foam pledgets were successful in preserving these vessels, and ultimately, the kidney's blood supply. Cryoablation of the right upper pole renal mass was completed as planned.

**Conclusion:** Aborting the cryotherapy due to important vessels in close proximity to the renal mass was avoided through a novel technique. The foam pledgets were effective insulating shields for the renal vessels against the therapeutic cold of renal mass cryoablation.

#### **VP19-15 INTERMEDIATE FOLLOW-UP OF RENAL MASSES TREATED BY LAPAROSCOPIC CRYOABLATION**

C. Mamoulakis, P. Beemster, S. Mehmedovic, H. Wijkstra, J. de la Rosette, M. Laguna

**Background:** To assess oncological outcomes in our series of Laparoscopic Renal Cryoablation (LRC).

**Methods:** Data on LRC is prospectively collected in our department since September 2003. Follow-up and diagnostic of recurrence are based on cross-sectional radiological follow-up (CT/MRI). The first 100 tumours treated in our Department by LRC were assessed in terms of overall and cancer specific survival (OS, CSS) and recurrence free survival. Tumour persistence was defined as evident persistent enhancement in the treated mass at first evaluation, three months after treatment. Local tumour recurrence was defined as contrast enhancement other than tenuous ring enhancement, at the level of the cryolesion after a transient period of absence of contrast enhancement.

**Results:** A total of 100 tumours were treated in 92 patients (58 males/34 females). Median age was 67.1 years (38.8–91.3). Median follow up in this population is 27 months (6–60). There were 3 persistent tumours, for an immediate cryoablation success rate of 97%. Those three patients received local kidney sparing treatment and are free of recurrence or metastases. During follow up there were 4 radiological local recurrences at 6, 22, 24 and 37

months. All persistent or recurrent tumours but one, presented in patients with documented RCC at biopsy. All patients were re-treated (1 by Radiofrequency, 1 Nephrectomy and 2 Partial Nephrectomies) and are free of disease at follow-up. Six patients died during follow up by other causes. Recurrence / persistence free survival is 93%, OS and CSS 93% and 100% respectively.

**Conclusion:** Based on cross sectional imaging, the two years tumour recurrence and/or persistence rate after LRC is 7%. Local treatment after persistence or recurrence is still feasible and CSS is 100%.

#### **VP19-16 RENAL LAPAROENDOSCOPIC SINGLE-SITE SURGERY (LESS) WITHOUT ACCESSORY TROCARS: A SINGLE INSTITUTION EXPERIENCE**

S. Rais-bahrami, A. Herati, S. Montag, M. Atalla, L. Kavoussi, L. Richstone

**Background:** Ongoing attempts are underway to minimize incisions used for laparoscopic access. LaparoEndoscopic Single-Site Surgery (LESS) was developed and has been increasingly attempted as an extension of classic laparoscopy. Investigators hypothesize that LESS offers a superior cosmetic result, faster recovery, and equivalent efficacy as laparoscopic surgery. Our aim is to present our experience with renal LESS without accessory trocars.

**Methods:** Prospective data collection was performed on patients undergoing urologic LESS at our institution yielding a total of 26 LESS cases between July 2008 and June 2009: ten LESS donor nephrectomies, one LESS nephroureterectomy, three LESS radical nephrectomies, seven LESS partial nephrectomies (in six patients), and five LESS pyeloplasties. All LESS procedures replicated conventional laparoscopic techniques via a single operative incision, using a 5 mm flexible-tip laparoscope, and combining flexible with conventional working instruments.

**Results:** The mean ASA score was  $1.76 \pm 0.66$ . The mean operative time was  $157.4 \pm 38.5$  minutes. The mean estimated blood loss was  $154.4 \pm 243.7$  ml, with a mean length of hospitalization of  $2.5 \pm 1.3$  days. One pyeloplasty patient was readmitted for prolonged ileus, one partial nephrectomy patient was readmitted for angioembolization of a bleeding pseudoaneurysm, and one patient required postoperative transfusion. Postoperative pain requirements were tabulated and revealed a mean in-hospital requirement of  $33.9 \pm 34.6$  mg (range 7–158) of morphine equivalents. Three patients in the series received intravenous ketorolac (maximum 120 mg).

**Conclusion:** Renal LESS is feasible as flexible laparoscopes and instruments continue to develop. In our series, expert laparoscopists are able to perform LESS with equivalent efficacy without compromising perioperative measures including operative time, blood loss, complication rate, and hospital stay compared to large published series of conventional laparoscopy. Randomized studies are necessary to elucidate differences, if any, in postoperative analgesic requirements and patient satisfaction with postoperative cosmesis.

#### **VP19-18 TUMOR SIZE AND ENDOPHYTIC GROWTH PATTERN AFFECT RECURRENCE RATES AFTER LAPAROSCOPIC RENAL CRYOABLATION**

M. Tsivian, C. Lyne, V. Mouraviev, J. Mayes, M. Kimura, T. Polascik

**Background:** Laparoscopic cryoablation (LCA) has gained popularity in the treatment of small renal tumors but local tumor control remains a concern. In this study we analyze factors that may contribute to local relapse after LCA of renal tumors.

**Methods:** We analyzed 165 patients who underwent LCA between October 2001 and June 2008 at either Allegheny General Hospital or Duke University Medical Center with at least 6 months of post-surgical follow-up. Demographics, perioperative variables, tumor characteristics (size, pattern of growth, biopsy results) and follow-up were recorded. Growth pattern was categorized as exophytic, mesophytic or endophytic. Regression analyses were performed to evaluate risk factors for local relapse after LCA.

**Results:** Median patient age was 66 (range: 33–90) with males comprising 60.6% of the cohort. Median tumor size was 2.3 cm (range: 0.5–5.0). Pathology was distributed as follows: renal cell carcinoma in 118 (71.5%), oncocytoma in 13 (7.9%), angiomyolipoma in 8 (4.8%) and other in 26 (15.8%) patients. Patients were treated for a single lesion in 94.5% of cases and multiple tumors in 5.5%. Endophytic growth pattern was present in 22.4%. We observed 7 (4.2%) local recurrences over a median follow up of 60 (range: 6–79) months. Median time to recurrence was 15 (range: 6–48) months. On proportional hazards regression, tumor size and endophytic growth pattern were significantly associated with local recurrence ( $p=0.008$  and  $p=0.001$ , OR = 4.1 and OR = 1.15, respectively).

**Conclusion:** LCA demonstrated good short-term tumor control with an acceptable recurrence rate. Larger tumors and those with endophytic growth pattern may be at increased risk of relapse after LCA.

#### VP19-19 LAPAROSCOPIC AND PERCUTANEOUS RENAL CRYOABLATION HAVE COMPARABLE MID-TERM ONCOLOGIC OUTCOMES

M. Tsivian, V. Chen, M. Ferrandino, R. Nelson, D. Albala, T. Polascik

**Background:** Laparoscopic (LCA) and percutaneous cryoablation (PCA) of small renal masses have gained popularity but only limited reports have been published comparing the two approaches. In this study we present on the oncologic outcomes of LCA and PCA in a single tertiary center experience.

**Methods:** Retrospective review of electronic medical records was carried out for patients undergoing LCA or PCA between 2005–2009 at our institution with at least one postoperative imaging study available. Demographics, comorbidities, radiographic variables and rates of post-treatment persistent or de novo enhancement were compared.

**Results:** Of a total of 152 patients, 61 underwent LCA and 91 PCA with an average follow-up of 25 (2–77) and 13 (1–41) months, respectively. Caucasians accounted for 69% of LCA and 71% of PCA groups. Mean age was 65.2 and 62.0 years, respectively ( $p=0.154$ ). Preoperative serum creatinine was 1.11 and 1.44 mg/dL ( $p=0.074$ ) and mean body mass index was 29.0 and 31.3

( $p=.046$ ) in LCA and PCA groups, respectively. Median tumor size on preoperative imaging was 2.0 (1.0–5.7) cm for both groups. We observed radiographic enhancement on follow-up imaging in 7 (11.5%) LCA and 6 PCA (6.6%) patients ( $p=.377$ ) after a mean of 13.2 (3–50) and 10.2 (1–40) months, respectively. Three LCA and 5 PCA patients required retreatment. The remaining patients were followed with serial imaging with stable or regressed enhancing foci. On multivariate regression analysis, no factor was significantly associated with persistent or de novo radiographic enhancement.

**Conclusion:** LCA and PCA offer comparable mid-term oncologic control although longer follow-up is needed to safely establish the role of these innovative techniques and reliably define treatment failure.

#### VP19-20 OUTCOMES OF HIGH INTENSITY FOCUSED ULTRASOUND (HIFU) IN THE TREATMENT OF LOCALIZED PROSTATE CANCER

R. Sanseverino, O. Intilla, G. Napodano, A. Campitelli, U. di mauro, R. Angrisani—Italy

**Background:** HIFU technology is a valid alternative for the treatment of localized prostate cancer in patients unsuitable for radical prostatectomy. The combination of transurethral resection of the prostate (TURP) and HIFU limits the risk of postoperative urinary retention. We report our experience with HIFU treatment of prostate cancer.

**Methods:** From November 2004 to January 2009 83 patients affected by localized prostate cancer underwent HIFU following TURP. In 44 patients both procedures were performed in the same session (Group A); in 39 patients HIFU was delayed (Group B). Follow up included serial PSA measurements and prostate biopsies 6 months after the treatment in all patients. Biochemical recurrence was defined as PSA nadir + 2 ng/ml (ASTRO 2005 criteria).

**Results:** The mean age and mean follow up were 73.7 ( $\pm 4.8$ ) years and 23.5 ( $\pm 8.9$ ) months, respectively. Mean preoperative PSA was 13.6 ng/ml. The treatment was performed under locoregional anaesthesia in all patients; mean procedure time was 128 minutes and mean hospitalization was 3.4 days. Complications rate was lower when HIFU has been delayed after TURP (Group B) [see table]. Mean PSA nadir was 0.37 ng/ml. Six months prostate biopsy was negative in 85.3% of patients. Overall and cancer related survival were 92.7% and 98.8%, respectively. % UTIMILDINCONTINENCEI - IISEVEREINCONTINENCEIII URETHRAL STENOSISBLADDER NECK STRICTURES AURRECTO URINARY FISTULAOVERALL PTS 13.2 21.7 2.4 4.8 10.8 4.81.2 GROUP A 20.4 38.64.59.1 18.29.12.3 GROUP B 5.12.6 002.6 00

**Conclusion:** HIFU is an effective option to treat patients with localized prostate cancer who are unsuitable for radical surgery. Splitting TURP and HIFU in two different sessions seems to reduce postoperative complications and improve patient tolerance of the procedure. Longer follow up and larger patient population are needed to obtain more robust evidence.

## VP20: ROBOTICS-PROSTATE

### VP20-01 PERIURETHRAL SUSPENSION STITCH DURING ROBOTIC-ASSISTED LAPAROSCOPIC RADICAL PROSTATECTOMY: DESCRIPTION OF THE TECHNIQUE AND CONTINENCE OUTCOMES

R. Ferreira Coelho, K. J Palmer, S. Chauhan, B. Rocco, M. B Patel, V. Patel—US

**Background:** Several studies have shown that RALP is feasible, with favorable complication rates and short hospital times. However, the early recovery of urinary continence remains a challenge to be overcome. We described our technique of periurethral retropubic suspension stitch during RALP and report its impact on early recovery of urinary continence.

**Methods:** We analyze prospectively 331 consecutive patients who underwent RALP. Ninety four patients underwent RALP without the placement of suspension stitch (Group 1) and 237 patients with the application of the suspension stitch (Group 2). The periurethral retropubic stitch was placed using a 12-in monofilament polyglytone suture on a CT-1 needle. The stitch was passed from right to left between the urethra and DVC and then through the peristomium on the pubic bone. The stitch was passed again through the DVC and then through the pubic bone, in a figure of eight, and then tied. Continence rates were assessed with a self administered validated questionnaire (EPIC-Expanded Prostate Cancer Index Composite) at 1, 3, 6 and 12 months after the procedure. Continence was defined as the use of “no absorbent pads” or “no leakage of urine”.

**Results:** In the group 1 the continence rate at <1 month, 3, 6 and 12 months postoperatively was 33% and 83%, 94.7% and 95.7%, respectively, and in the group 2 the continence rate was 40% and 92.8%, 97.9% and 97.9%, respectively. The suspension technique resulted in significantly greater continence rates at 3 months after RALP ( $p = 0.013$ ).

**Conclusion:** The periurethral suspension stitch during RALP also resulted in a statistically significant higher continence rate at 3 months after the procedure, without affecting the frequency of PSM in the prostatic apex. The continence rates at 6 and 12 months were not significantly affected.

### VP20-02 SALVAGE ROBOTIC-ASSISTED LAPAROSCOPIC PROSTATECTOMY (SRALP) FOR RADIORECURRENT PROSTATE CANCER: MULTI-INSTITUTIONAL OUTCOMES

M. B Patel, R. Ferreira Coelho, R. Ferrigni, E. Castle, T. Ahlering, V. Patel

**Background:** There is a paucity of literature regarding feasibility of RALP as a salvage option for local recurrences in men who failed definitive radiation therapy (RT) for prostate cancer (PCa). Majority of reported radical prostatectomies (RP) were associated with major complications, such as rectal injury. We report, a multi-institutional experience w/performing sRALP after definitive RT.

**Methods:** Patients w/ biopsy proven PCa after RT who underwent sRALP were identified retrospectively (over 15.9 mos) by multiple, high volume robotic performing institutions. All men exhibited a negative metastatic w/up at time of surgery & life expectancy >10 years. We assessed the morbidity associated w/

this procedure & compared results to those in contemporary literature of open cases.

**Results:** Twelve patients of mean age 63 years underwent sRALP. Mean lag-time between diagnosing radiorecurrent PCa and sRALP was 7.2 months. Our series showed a mean estimated blood loss (EBL) of 70.8 cc, operative time (OR) of 125.8 min and length of hospital stay (LOS) of 1.3 days. At mean follow-up of 7.23 mos, 3 patients (25%) presented with biochemical progression (PSA > 0.2); all had negative surgical margins. When stratified by age, at mean follow-up of 7.1mos, all pts <64 years (6) were continent (pad free); 50% of patients aged 64–70 (2/4) were continent; no patients >70 years were continent. There were no rectal injuries, blood transfusions, or conversion to open surgery.

**Conclusion:** sRALP is safe and feasible option for treatment of local recurrence after RT for PCa. In comparison to contemporary open series, sRALP appears to have similar continent rates with a trend towards less blood loss, lower operative time and shorter hospital stay.

### VP20-03 HYPOTHERMIC ROBOTIC RADICAL PROSTATECTOMY: IMPACT ON CONTINENCE

T. Ahlering, D. Finley, K. Osann, A. Chang, R. Santos, D. Skarekcy—USA

**Background:** Radical prostatectomy undoubtedly causes inflammatory damage to surrounding neuromuscular tissue (i.e. bladder, urethra, nerves) which may contribute to urinary incontinence. We report the use of local hypothermia during Robot-assisted Laparoscopic Prostatectomy (hRLP) to attenuate this injury.

**Methods:** Regional pelvic cooling was achieved utilizing cold intracorporeal irrigation and an endo-rectal cooling balloon (ECB). 115 men undergoing hRLP (case #668–782) was prospectively compared to a historical cohort (case #1–667). Intracorporeal rectal and neurovascular bundle temperatures (T) and intra-rectal temperatures were measured. Continence was defined as zero urinary pads. Kaplan-Meier analysis of time to zero pads and multivariate Cox Proportional Hazards Regression was used.

**Results:** Hypothermia was achieved in 112/115 patients; 6 were excluded (3 ECB malfunction, 2 prior radiation, 1 completion prostatectomy). Median endorectal T = 18.7 C. (range 9.1–29.5 C.) Mean intra-corporeal T = 25.6 C. (ECB + irrigation, range 19.4–34.0 C.) Three and 12 month hRLP zero pad rates were 81–89% and 100% for initial and extended cooling groups vs. 65% and 89% for controls. Return to continence was significantly faster for hRLP vs. controls: median time to zero pad use was 39 days for hRLP vs 62 days for controls. Multivariate analysis adjusting for AUA symptom score, nerve sparing surgery, learning curve, IIEF-5, age, and prostate weight, demonstrated a significantly faster return to continence (HR = 1.53, 95% CI: 1.1–2.1). Trends towards improved continence was observed with colder temperatures and older patients.

**Conclusion:** Local hypothermia during prostatectomy resulted in a significant improvement in early post-operative zero-pad continence rates. Longer and deeper cooling appears to be associated with improved continence, particularly among older men.

#### VP20-04 RECTOURINARY FISTULA AFTER PRIMARY AND REPEATED HIFU FOR PROSTATE CANCER. PREVALENCE AND SURGICAL MANAGEMENT

C. Cellarius, D. Pfeiffer, C. Netsch, H. Boehme, E. Gross, A. Gross

**Background:** High-intensity focused ultrasound (HIFU) allows primary or salvage treatment of prostate cancer (CaP). Rectourinary fistula (RUF) is a severe complication after HIFU. We assessed retrospectively the prevalence, time to diagnosis and the surgical approach for this problem.

**Methods:** Over a period of 5 years, 280 patients with CaP underwent 295 HIFU treatment sessions. The outcome of the following 3 treatment groups were analysed: A. primary HIFU (260 sessions), B. repeated HIFU (n = 15) and C. salvage HIFU (S-HIFU) after radical prostatectomy and/or EBRT (n = 20).

**Results:** RUF occurred after 8 treatments. A: RUF 3-4 weeks after primary HIFU (4/260 = 1.5%). B: RUF 1 week after the repeated HIFU (2/15 = 13%). C: RUF 2 and 21 days after S-HIFU (2/20 = 10%). After diagnosis of RUF all patients received initially transurethral catheterization and antibiotic therapy. A spontaneous closure of the RUF was never noted. Repair was accomplished in group A either by transanal rectal advanced flap (fistula size <10 Charr.; n = 1), perineal approach with interposition gracilis muscle (n = 1) or by retropubic prostatectomy with transperitoneal omentum flap (n = 2). Prostatectomy was also performed in group B. Treatment in group C was abdominal rectum resection with colonic J-pouch reconstruction.

**Conclusion:** After primary HIFU, RUF is a rare complication which develops with delay. Transanal repair is preferential in small rectal lesions. Retropubic prostatectomy as a part of surgery for RUF is feasible even after two HIFU sessions. RUF after S-HIFU requires major abdominal surgery.

#### VP20-05 ROBOT-ASSISTED LAPAROSCOPIC RADICAL PROSTATECTOMY. RESULT OF OUR FIRST 100 CASES

B. Alessandra, F. Annino, C. De carne, S. Micali, S. De stefani, G. Bianchi

**Background:** We report our series of 100 Robot-Assisted Laparoscopic Radical Prostatectomy (RALRP) in term of functional and oncologic results with a mean follow-up 9 months (0–21).

**Methods:** Between 10/2007 and 06/2009 we performed 100 RALRP with a tension-energy-free intrafascial (endo/inter-fascial) aim. The patients were selected by Gleason score  $\leq 7$  (3 + 4), PSA  $\leq 15$  ng/ml, clinical stage  $\leq T2$ . Functional and oncologic outcome have been respectively evaluated at 1, 4, 6 and 12 months.

**Results:** Every operation were completed by robotic fashion except for one conversion to open surgery due to robot failure. Nerve sparing was achieved in 98% of cases (80% bilateral, 17% monolateral). Mean operative and console times were respectively 268 min (165–455), 199 min (140–360). Dissection and anastomosis times were respectively 160 min (115–260); and 39 min (15–120). We haven't had major intraoperative complications except one re-operation due to immediate postoperative venous bleeding. Functional outcome: continence (0 pad) at 10 days from catheter removal was 46%. At 1,4,6 and 12 mo it was respectively 51%, 64%, 73%, 77%. Of the preoperative potent patients (IIEF 1–5:15 >16), the patients who referred sexual intercourse recovery at 1,4,6 and 12 months have been respectively 25%, 49%, 48%,

80% including patients using 5-PDEi. Positive surgical margin have been 18% (12% for pT2, 53% for pT3).

**Conclusion:** Our series is comparable to others reported in literature and confirm that RALP is an effective and safe procedure that can provide excellent short term functional and oncologic result with minimal morbidity for the patients.

#### VP20-06 QUALITY IMPROVEMENTS IN ROBOTIC PROSTATECTOMY: THE EFFECT OF TECHNICAL CHANGES ON ONCOLOGIC AND FUNCTIONAL OUTCOMES

H. Lavery, F. Nabizada-pace, J. Carlucci, D. Samadi—USA

**Background:** The technique of the robotic-assisted laparoscopic prostatectomy (RALP) continues to evolve. We evaluate the effect of two discrete changes in our technique on functional and oncologic outcomes.

**Methods:** An institutional database of 1310 RALP was divided into 3 historical cohorts based on surgical technique changes. The “original” technique included incision of the lateral endopelvic fascia and suture ligation of the dorsal vein complex (DVC). The first modification, to be called the “intermediate” technique, was to abandon the lateral opening of the endopelvic fascia. In June 2008, the “current” technique began without using the DVC stitch, cutting the DVC with cold scissors and oversewing it after removing the specimen. Biochemical recurrence (BCR) was defined as a PSA > 0.2 ng/ml, continence was defined as the use of zero or one pad daily.

**Results:** The original, intermediate and current techniques were performed on 770, 169 and 331 patients, respectively. Bilateral nerve-sparing was performed at the same rate in each group, approximately 87%. Each technical change resulted in progressive improvements in both oncologic and functional outcomes. The rate of extensive positive surgical margins fell from 12.5 to 8.3 to 4.6% in the three groups (p < 0.001), while the rate of BCR trended down from 6.0 to 4.8 to 4.5% (p = NS). Continence rates at 6 months improved from 81 to 86 to 89% (p = 0.05). Potency rates and longer-term continence rates were similar between the groups.

**Conclusion:** Discrete technical modifications, combined with improvements associated with greater experience, have improved the oncologic and functional outcomes of RALP.

#### VP20-07 HIGH VOLUME, FELLOWSHIP-TRAINED SINGLE SURGEON ROBOTIC-ASSISTED LAPAROSCOPIC RADICAL PROSTATECTOMY EXPERIENCE: 350 CASES IN 30 MONTHS

R. Carey, T. Hakky

**Background:** Robotic-assisted laparoscopic radical prostatectomy (RALRP) is a complex, technically demanding operation where surgical outcomes are likely to depend upon the experience of surgeon and hospital. We report the high volume experience of a single surgeon fellowship-trained in endourology and robotic surgery leading a hospital through the RALRP learning curve.

**Methods:** A total of 350 patients underwent RALRP over a period of 30 months. Prospective data collection included Expanded Prostate Cancer Index Composite (EPIC), PSA, Gleason grade, and clinical stage. Operative parameters were estimated blood loss, length of surgery, and complications. Post-operative parameters included length of hospital stay, pathology, return to continence, catheter time and PSA.

**Results:** The mean patient age was 63.7 years (46–79), mean BMI 28.7 (20.9–43.8), mean prostate size 54.7 (22.0–131), mean pre-

operative PSA 6.0. The mean follow-up is 16.0 months. Pathology stages were T2a–T2b (19%), T2c (64.5%), T3a (10.5%), T3b (4.2%), and T4 (1.8%). Gleason scores were 5 (1%), 6 (48.5%), 7 (43.6%), 8 (3.8%), 9 (3.1%). Bilateral pelvic lymph node dissections were performed in (72.1%) of patients with positivity identified in 7 (2.0%) patients. The length of surgery improved from 213 min for cases 1–50 to 119 min for cases 150–305. 97% of patients went home by post-operative day 2. The estimated blood loss for cases 1–50 was 170 mL, and for cases 150–350 was <100 mL. The overall positive margin rates for this study were 13.2%, although this fell to 5.7% for cases 150–350. No positive margins were obtained for T2b or lower disease. Early continence rates (no pads within 3 months) was 95% with only 2% have significant continence issues (>1 pad per day) at 12 months. No artificial urinary sphincters have been indicated. There were no (0%) intra-operative transfusions and only (1.7%) post-operative transfusions. Adjuvant radiation therapy for biochemical recurrence occurred has been undertaken in 2.9% (n = 10) patients. No (0%) bladder neck contractures have occurred and no (0%) artificial urinary sphincters have been indicated.

**Conclusion:** Although low blood loss and low patient pain scores were achieved early, operative times and positive margins improved markedly between the first fifty cases and cases 150–350. Athermal techniques of dissection, maximized urethral length, posterior reconstruction, urethral suspension stitch, and bladder neck reconstruction/tubularization (for large bladder necks) were employed routinely. Although long-term follow up for 5 year biochemical recurrence is needed, these results contradict reports of higher complication rates for RALRP compared to open surgery.

#### VP20-08 IMPACT OF ROBOTIC TRAINING ON SURGICAL AND PATHOLOGIC OUTCOMES DURING ROBOT-ASSISTED LAPAROSCOPIC RADICAL PROSTATECTOMY

E. Kwon, H. Jung, T. Bautista, S. Williams, G. Chien—USA

**Background:** To prospectively compare surgical and pathologic outcomes during robotic prostatectomy between surgeons with formal training in robotic prostatectomy (RALP) se with formal training in laparoscopic prostatectomy (LRP).

**Methods:** A total of 286 robotic prostatectomies were performed by 12 urologists between August 2008 and March 2009 as part of a new robotic surgery program at one of the largest health maintenance organizations in the United States. Four surgeons had formal training in RALP and 8 had formal training in LRP. We prospectively compared surgical and pathologic outcomes between these two groups of surgeons.

**Results:** The 4 RALP surgeons performed 121 RALPs and the 8 LRP surgeons performed 165 RALPs. Patient demographics were similar between groups. The robot-naïve group had significantly more clinical stage T1c than the robot-trained group (87.9% vs. 74.4%,  $p = 0.003$ ). Prostatectomy parameters were similar between the two groups of surgeons in terms of prostate size, Gleason score, pathologic Stage and estimated blood loss. The robot-trained surgeons had significantly lower overall positive margin rates (24% vs. 34.6%,  $p = 0.05$ ) and lower margin rates in T3 tumors (38.5% vs. 61.8%,  $p = 0.07$ ) which approached statistical significance. There was no difference in margin rates in T2 tumors. The robot-trained surgeons had significantly lower apical margin rates (8.3% vs. 21.2%,  $p = 0.003$ ) and lateral margin rates (1.7% vs. 7.3%,  $p = 0.05$ ).

The robot-trained surgeons had 10–15% shorter procedure times. There was no difference in complication rates.

**Conclusion:** Formal RALP training may be beneficial for surgical and pathologic outcomes of RALP compared to formal LRP training during the initial implementation of a new robotics program.

#### VP20-09 OCCURRENCE OF BLADDER OUTLET OBSTRUCTION (BOO) AFTER SINGLE HIFU TREATMENT OF THE PROSTATE

C. Netsch, D. Pfeiffer, C. Cellarius, A. Gross—Germany

**Background:** HIFU provides a successful treatment of prostate cancer. Prostate tissue is destroyed by heat and cavitation. Ideally, micturition should normalize spontaneously after elimination of necrotic debris. We investigated the need of secondary transurethral interventions (TI) for BOO.

**Methods:** 226 consecutive patients, treated between 12/02 and 09/07, were examined and followed at least 1 year. The Ablatherm Maxis<sup>®</sup> and the Integrated Imaging<sup>®</sup> device (EDAP, Lyon, France) were in use, the latter providing a realtime visualization of the ongoing treatment from the apex to bladder neck. The sites of BOO were recorded.

**Results:** 57 (25.2%) patients developed BOO. Repeated TI were performed in 24 patients (10.6%), 3 to 7 TI in 13 patients (5.75%). Patients with repeated TI were older than patients with singular BOO ( $71.75 \pm 4.97$  vs.  $68.18 \pm 5.03$ ;  $p = 0.024$ ). In primary BOO, multiple sites were more often involved than in repeated BOO (25/57 vs. 7/24), whereas bladder neck stenosis was predominately found in patients with  $\geq 2$  episodes of BOO. Regarding the HIFU device, no difference in the manifestation of primary BOO was noted. The rate of repeated BOO however dropped from 17/135 (12.6%) to 7/91 (7.7%) with the application of the Integrated Imaging device.

**Conclusion:** BOO after HIFU is common, particularly affecting the bladder neck. Therefore, the need for a singular consecutive TI appears to be rather an integral part of the HIFU procedure than a complication. The risk of repeated BOO is associated with age. The better control of the bladder neck by improved treatment monitoring has reduced this risk.

#### VP20-10 POSITIVE SURGICAL MARGINS DURING ROBOT-ASSISTED LAPAROSCOPIC PROSTATECTOMY: THE EFFECT OF LOCATION UPON EXTENT

H. Lavery, F. Nabizada-pace, J. Carlucci, D. Samadi—USA

**Background:** Recent reports have suggested that the location and length of positive surgical margins (PSM) at the time of radical prostatectomy are predictive of biochemical recurrence.

**Methods:** An institutional database was reviewed for 1,305 consecutive RALP performed by a single surgeon. PSM was defined as the presence of cancer cells at the inked margin. PSM were further subclassified into “focal” and “extensive” if the PSM length was less than or greater than 2 mm, respectively. Biochemical recurrence was defined as a PSA > 0.2 ng/mL.

**Results:** Positive surgical margins were present in 245 of the 1305 patients, for an overall rate of 18.6%, focal in 9% and extensive in 9.6%. Multifocal positive margins occurred in 37 (3%). Margins were positive in 12% of 1057 pT2 tumors, 7% focal and 5% extensive. Of the 248 pT3/pT4 patients, 45% had PSM: 17% focal and 28% extensive. Bilateral nerve-sparing was performed in 88% of patients. The most common location of PSM was posterior in 47%, followed by posterolateral in 19% and apical in 11%. PSMs



posteriorly, when compared to those posterolaterally, were significantly more likely to be extensive (55% vs. 22%,  $p = 0.0001$ ). Controlling for nerve-sparing status and extracapsular extension did not significantly affect these findings. At a median follow-up of 12 months, biochemical failure occurred in 3.6%, 7% and 19% of those with negative, focal and extensive PSM, respectively. Differences were significant between extensive PSMs and focal or negative ( $p < 0.01$ ), but not between focal and negative ( $p = 0.18$ ). **Conclusion:** The location of PSM at RALP is correlated with the extensiveness of the PSM. Extensive PSMs were significantly more likely to experience biochemical failure than focal or negative margins, but focal PSMs were not statistically different than negative margins at a median follow-up of 12 months.

### VP20-11 TUMOR PERCENTAGE INVOLVEMENT PREDICTS PROSTATE SPECIFIC ANTIGEN RECURRENCE AFTER RADICAL PROSTATECTOMY ONLY IN MEN WITH SMALL PROSTATES

D. Albala, M. Lipkin, M. Uhlman, T. Polascik, L. Sun, J. Moul—USA

**Background:** This study sought to determine the predictive power of tumor percentage involvement (TPI) on PSA recurrence (PSAR) in patients when stratified by prostate weight.

**Methods:** A cohort of 3057 patients receiving radical prostatectomy (RRP, RPP and RALP) between 1988 and 2008 was retrieved from the Duke Prostate Cancer database. Patients with TPI, prostate volume and PSAR data were included in the analysis. Patients were divided into three groups based on prostate volume (PV) (<35 cc, 35–45 cc and >45 cc). The variables TPI, age at surgery, race, PSA, pathological Gleason, positive surgical margins (PSM), extra capsular extension (ECE), seminal vesicle invasion (SVI), and year of surgery were analyzed using Chi-squared and Mann-Whitney tests to determine individual effects on PSAR. TPI and PSA were evaluated as continuous variables. Significant variables from univariate analysis were included in multivariate Cox regression analysis to compare their effects on PSAR.

**Results:** TPI significantly predicts PSAR in men with small prostates ( $p = 0.006$ ), but was not predictive in prostates >35 ccs. AA race was found to be a marginally significant predictor ( $p = 0.055$ ) of PSAR in men with medium sized prostates and age at surgery was found to be a predictor of PSAR ( $p = 0.003$ ) in men with larger prostates. Additionally, PSA, PSM, SVI and pathological Gleason  $\geq 7$  predicted PSAR in men of all prostate sizes.

**Conclusion:** For men with prostates less than 35 ccs, TPI is an important variable when assessing risk for PSAR. TPI and PV should be considered when counseling patients and determining which patients may benefit from heightened surveillance following RP.

### VP20-12 SINGLE PORT ROBOTIC RADICAL PROSTATECTOMY

R. Goel, W. White, G. Haber, S. Crouzet, J. Kaouk

**Background:** Single port laparoscopy has gained momentum in achieving a virtually scarless minimally invasive approach. Technical hindrances currently prevent the widespread adoption of this evolving technique. Recent application of the robotic platform to radical prostatectomy has demonstrated excellent results. Herein, we evaluate our experience with single port robotic surgery during radical prostatectomy.

**Methods:** A retrospective analysis of single port robotic (SPR) radical prostatectomies performed at a single institution was re-

viewed. Patients eligible for the SPR approach included patients with low risk, organ confined disease, baseline impotency and the absence of previous abdominal or pelvic surgery. The daVinci-S system was positioned through a commercially available single port. Perioperative variables including operative time, blood loss and surgical technique were assessed. Post operative visual analog pain scores (VAPS); oncological and functional outcomes were also evaluated.

**Results:** Three single port robotic radical prostatectomies were performed without use of additional laparoscopic ports. Mean operative time was 217 minutes with estimated blood loss of 133 ml. All patients were discharged on postoperative day two. Standard robotic dissection was performed throughout the case with note of a continuous urethral-vesical anastomotic suture in all three cases. Mean VAPS at discharge was  $1.3 \pm 0.8$ . Pathology revealed T2b disease with Gleason 7 (2) and Gleason 6 (1) disease. One patient demonstrated margin positivity however no evidence of biochemical relapse has been detected. Given the brevity of followup, evaluation of continence is premature.

**Conclusion:** Robotic application to single port laparoscopic surgery has the potential to further evolve this technique. Improved imaging, range of motion and robotic ergonomics assist the surgeon during complex reconstructive procedures. Further evaluation of the single port robotic technique requires extended evaluation, however, early functional outcomes show promise.

### VP20-13 ROBOTIC-ASSISTED SALVAGE RADICAL PROSTATECTOMY AFTER FAILED HIFU AND IMRT

R. Carey, T. Hakky—USA

**Background:** Alternative therapies to radical prostatectomy for prostate cancer treatment such as high intensity focused ultrasound (HIFU) and Intensity Modulated Radiation Therapy (IMRT) do not actually remove prostate cancer tissue, but rather effect cancer cell kill by delivery of thermal energy or radiation to the prostate. Patients who have subtotal cell kill leaving residual cancer present in the prostate may be considered for salvage therapy for removal of their prostates if their disease remains localized.

**Methods:** Institutional Review Board Approval was obtained for this study. We retrospectively reviewed the charts of 347 patients who underwent robotic-assisted laparoscopic radical prostatectomy, RALRP, over a period of 30 months by a single surgeon fellowship trained in robotic surgery. Four patients who underwent salvage RALRP after failed primary alternative therapy, one HIFU and three IMRT, were identified. Each patient had residual cancer on biopsy and rising PSA. Their charts were reviewed for pre- and post-operative pathologic findings, intra-operative parameters, and post-operative continence.

**Results:** The length of surgery for RALRP and bilateral pelvic lymph node dissection was 158 minutes (salvage HIFU) and 162 minutes (salvage IMRT) compared to 119 minutes for comparable non-salvage RALRPs. Three patients were completely continent, using no pads, within three months after surgery. One was wearing two pads per day. Urinary retention in two IMRT patients resolved. Initial PSA values at 3 months were undetectable at less than 0.01 ng/mL. All surgical margins were negative for malignancy.

**Conclusion:** Salvage robotic-assisted laparoscopic radical prostatectomy is a viable procedure after failed high intensity focused ultrasound therapy and intensity modulated radiation therapy. The salvage procedures take longer and are significantly more technically difficult for the surgeon, but the outcomes in this study are

promising. Patients seeking salvage therapy for prostate cancer after failed primary treatment with HIFU or IMRT may be directed to surgeons who are willing to perform salvage RALRP.

#### **VP20-14 SHORT-TERM ASSESSMENT OF THE ONCOLOGIC SAFETY OF ROBOTIC PROSTATECTOMY IN PRE-OPERATIVELY HIGH-RISK PATIENTS**

H. Lavery, F. Nabizada-pace, J. Carlucci, D. Samadi—USA

**Background:** The lack of haptic feedback at the robotic console has raised concerns regarding the oncologic safety of the robotic prostatectomy in high-risk patients, as tumor cannot be palpated. We analyzed our outcomes in patients with high-risk prostate cancer according to the D'Amico risk group classification.

**Methods:** An institutional database of 1418 robotic-assisted laparoscopic prostatectomies (RALP) was queried for patients presenting with PSA > 20 ng/ml, Gleason 8 or higher on biopsy, or clinical stage T2c or higher. Continence was defined as the use of zero or one pad daily. Potency was defined as erections sufficient for vaginal penetration in men who were potent preoperatively. Biochemical recurrence was defined as PSA > 0.2 ng/ml.

**Results:** High-risk features were found in 136 patients. Mean serum PSA was 10.7 (range 1.7 to 53). Biopsy Gleason scores in 11%, 15% and 74% were 6, 7 and 8 or higher, respectively. Bilateral, unilateral and non-nerve sparing was performed on 58%, 16% and 27%, respectively. On final histopathology, 47% were organ confined; 58 patients had extracapsular extension and 38 had seminal vesical invasion. Pathologic Gleason scores were downgraded, as 4%, 47% and 49% were Gleason 6, 7 and 8–10, respectively. Lymph nodes were positive in 3%. Positive surgical margins occurred in 31%: 13% focal and 18% extensive. At a median follow-up of 15 months, 78% were continent and 54% were potent. Biochemical recurrence occurred in 23%. The “trifecta” of continence, potency and freedom from recurrence was achieved in 29 patients (21%).

**Conclusion:** At 15 month follow-up, robotic prostatectomy can safely be performed in high-risk patients without routinely sacrificing the neurovascular bundles. Good postoperative functional and oncologic outcomes can be expected.

#### **VP20-15 OBSTACLES IN THE INITIAL PHASE OF ROBOT ASSISTED RADICAL PROSTATECTOMY (RARP)—A PROSPECTIVE ANALYSIS OF THE FIRST 75 CASES. DEPARTMENT OF UROLOGY, SILOAH ST.TRUDPERT HOSPITAL, PFORZHEIM, GERMANY**

V. Zimmermanns, P. Ober, J. Sommer, S. Lahme

**Background:** Robot assisted radical prostatectomy (RARP) is a highly standardized procedure. In general the learning curve is regarded to be steep, nevertheless existing. To evaluate the objective and subjective obstacles of the procedure we prospectively gathered data about technical and surgical difficulties. The aim was the identification of critical points in order to improve solution and prevention strategies.

**Methods:** 75 consecutive, initial patients (mean age 65 y) underwent transperitoneal RARP. A DaVinci® four arm system (Intuitive Surgical) was employed. Data about tumor status, complications, blood transfusion and conversion were gathered prospectively. Moreover objective and subjective deviations from the ideal procedure course were recorded immediately after the operation. We distinguished between technical problems related to the equipment and surgical difficulties.

**Results:** 50 patients had pT2 and 25 pT3 tumors, positive margins were present in 2% (pT2) and 44% (pT3). There was no Clavien III or higher complication, no blood transfusion, no conversion. Mean operating time dropped from 386 minutes for the first 10 cases to 234 minutes for the last ten cases. The number of identified difficulties per five procedures ranged between two and ten with an average of 1.2 difficulties per procedure. There was no clear drop in the number of difficulties for more recent procedures. Pure technical problems made up for only 10% of all severities. All of them could be solved without conversion. 90% were procedure related. Seven frequent obstacles could be identified. Inadequate range of instruments (21%), intraperitoneal adhesions after previous surgery (20%) and periprostatic adhesions (19%) being most common.

**Conclusion:** RARP could be safely established without severe complications. Technical problems of the equipment could be solved and did not induce conversion to open surgery. Evaluation of surgical difficulties identified only a quite limited number of typical obstacles. All of them could be handled adequately and caused no obvious intra- or postoperative complication. Knowledge of typical severities is helpful for training purposes on the one hand and patient selection for initial surgery on the other hand.

#### **VP20-16 ROBOTIC SINGLE PORT SUPRAPUBIC TRANS-VEISCAL ENUCLEATION OF THE PROSTATE (R-STEP): INITIAL EXPERIENCE**

K. Fareed, W. White, G. Haber, R. Goel, S. Crouzet, J. Kaouk—USA

**Background:** We present perioperative outcomes in an observational cohort of patients who underwent Robotic Single Port Suprapubic Transvesical Enucleation of the Prostate (R-STEP).

**Methods:** A prospective study was performed to evaluate operative outcomes following R-STEP for symptomatic benign prostatic hyperplasia (BPH). All patients underwent preoperative transrectal ultrasound (TRUS) of the prostate and urodynamics prior to intervention. Appropriate candidates underwent transurethral incision of the prostate apex, were repositioned in the supine position, and an approximate 3 cm lower midline incision made. A cystotomy was created and a GelPort® laparoscopic system positioned in the bladder. The da Vinci S robotic operating system was docked through the GelPort® platform and prostate enucleation performed in a standard fashion. Perioperative outcomes were obtained for all patients.

**Results:** Between March 2009 and June 2009, 3 patients underwent R-STEP. Mean preoperative prostate volume by TRUS was 131 grams. Preoperatively, 2 patients were in urinary retention and one patient had bladder stones and a Qmax = 5.2 mL/second. Mean operative time was 3.8 hours. Mean EBL was 233 mL. No intraoperative complications occurred. Post-operatively, one patient developed clot retention and required evacuation and fulguration. The same patient required a blood transfusion. No other postoperative complications occurred. Cystogram was negative in all patients. Mean volume of resected tissue was 42 grams. Post-operative mean Qmax = 26.8 mL/second.

**Conclusion:** R-STEP is a technically challenging procedure with a brief yet pronounced learning curve. Use of the robot during STEP procedures may ultimately offer improved outcomes as compared to standard laparoscopic STEP.

### VP20-17 USE OF ENSEAL® DURING ROBOTIC PROSTATECTOMY PEDICLE CONTROL: COLD IRRIGATION TO MINIMIZE LATERAL THERMAL INJURY

K. Zorn, M. Katz, A. Razmaria, G. Zagaja, A. Shalhav, H. Alhamadie—USA

**Background:** Thermal-based hemostasis at the prostatic pedicles during robotic prostatectomy (RP) may cause collateral injury to adjacent neural tissue and has been demonstrated to negatively impact sexual function. The engineering design of the Enseal® (SurgRx, Redwood City, CA) theoretically limits collateral thermal damage to 0.5–1.0 mm. Use of tissue cooling during instrument activation may also minimize thermal spread. We evaluated the collateral tissue effects of Enseal®, with or without cold-saline irrigation (CSI), during prostate pedicle control.

**Methods:** The Enseal® Trio device was used for pedicle control in 20 consecutive patients undergoing bilateral, non-nerve-sparing RP. Ipsilateral pedicles were randomly selected to Enseal® alone or Enseal® + CSI (<4°C) application to the tissue before and during device activation. The primary endpoint was the distance of thermal injury from the inked margin margin using both hematoxylin and TUNEL-apoptosis staining. A mean of 3 measurements were taken for each pedicle. Pathological analysis was performed by a single, blinded uro-pathologist.

**Results:** Mean distance of thermal injury from the inked margin was 0.31 mm (range 0.15–0.40) and 0.97 mm (range 0.8–1.1) for the Enseal® + CSI and Enseal® alone, respectively ( $p < 0.0001$ ). TUNEL staining also demonstrated lateral tissue damage of 0.39 mm (range 0.2–0.5) and 1.12 mm (range 0.9–1.3), respectively ( $p < 0.0001$ ). No problems with hemostasis or post-operative bleeding were observed in the study.

**Conclusion:** The hemostatic properties of Enseal® work effectively when immersed in CSI. Adjacent thermal tissue damage is significantly minimized with the addition of CSI. This may have a beneficial impact for nerve preservation and sexual function outcomes after RP.

### VP20-18 LAPAROSCOPIC AND ROBOTIC UROLOGICAL SURGERY—EVOLVING ANATOMICAL KNOWLEDGE OF THE PROSTATE

S. Kommu, Z. Hashim, A. Golash, C. Luscombe, C. Eden, S. (sarg)—United Kingdom

**Background:** The coupling of anatomical radical prostatectomy done via the open approach together with cumulative surgical experience gained by experts, led to improved knowledge of the anatomy of the prostate gland and its surrounding structures (e.g. dorsal vein complex and the neurovascular bundles). With the introduction of laparoscopic and robotic urological surgery, there has been a further increase in the knowledge of the anatomy of the prostate. We studied the impact of laparoscopic and robotic urological surgery on the anatomical knowledge of the prostate.

**Methods:** A literature search was performed using relevant texts, Medline and PubMed. A tally from consensus meetings and lectures from experts in the minimally invasive approach to radical prostatectomy (i.e. laparoscopic and robotic radical prostatectomy) was made.

**Results:** In 1991, the first laparoscopic radical prostatectomy (LRP) was successfully completed. The introduction of the Laparoscope permitted the scrutiny of the prostate gland from a different perspective due to the visual angles and magnifications

enabling prostatic relations to be assessed with detail not previously appreciated. Equipped with new anatomical perspectives about the prostate the approach was modified to include continent and potency conscious procedures. With the introduction of the da Vinci® robot, further anatomical appreciations were made with the addition of 3-Dimensional views with greater degrees of magnification. In 2002, it was noted that important relationships existed between pelvic plexus ganglions and seminal vesicles. Further fine neural plexuses along the posterior and antero-lateral surface of the prostate were described based on cadaveric studies and laparoscopic and robotic views. Later on, the technique of nerve preservation in which a plane (deep to the Santorinis plexus) between the prostatic capsule and inner prostatic fascial layer is developed at its cranial extent was described (i.e. the Veil of Aphrodite). Shortly following this, ‘Cupid’s Bow’ was described. In 2003–2004, Lunacek et al. noted that the cavernosal nerves running along the prostate become displaced further anteriorly and spread, thus forming a concave shape (like a ‘curtain’) of the neurovascular bundles. This led to the description of the modified ‘curtain dissection’ in 2005. Recently interfascial dissection of the neurovascular bundles that is tension and cautery free was described. Several aspects of the anatomy of the prostate remain controversial among experts. Some argue that the prostatic ‘capsule’ is not really a true capsule but instead consists of a partially formed fibromuscular tissue that is an extension of the glandular structures. A separate periprostatic fascia that is distinct from this fibromuscular extension of the gland is noted to exist by some. Some propose that longitudinal smooth muscle fibres located under the posterior bladder neck correspond to the posterior longitudinal fascia of the detrusor muscle. As laparoscopic and robotic surgery evolves, our anatomical knowledge continues to be redefined.

**Conclusion:** Laparoscopic and robotic urological surgery has made significant contributions to our understanding of the anatomy of the prostate. This understanding continues to redefine surgical approaches towards the quest for achieving optimal results with the trifecta of oncological control, potency preservation and maintenance of continence during radical prostatectomy.

### VP20-19 FEASIBILITY OF ROBOT-ASSISTED INTRACORPOREAL LAPAROSCOPIC ILEAL CONDUIT URINARY DIVERSION

M. Sangalli, G. De naeyer, P. Schatteman, P. Carpentier, E. Fonteyne, A. Mottrie—Belgium

**Background:** Several reports have recently demonstrated that robot-assisted cystectomy with total intracorporeal ileal conduit (RACIC) is a feasible challenge. We report our experience with functional outcomes of a series of patients undergone to RACIC.

**Methods:** Between February 2008 and March 2009, 8 patients underwent RACIC; indications for cystectomy was invasive TCC; in all patients, the ileal conduit was performed totally intracorporeally.

**Results:** The RACIC was technically successful in all 8 pts. (2 females and 6 males. mean age 75.4; 57 to 87) without open conversion; the mean operative time including lymphadenectomy and urinary diversion was 346.2 min (210 to 480), the mean estimated blood loss and the median hospital stay were 258 ml (200 to 500) and 20.3 days (10 to 58) respectively. Where a pelvic lymphadenectomy was performed, a mean of 19 lymphnodes were taken. In the 2 female pts. the specimen was extracted through the vagina. There were no intraoperative complications and only 1

major postoperative complication: one postoperative necrosis of ileal conduit without clear cause, as the ileal conduit was well vascularised at the end of the operation (arteric embolus or closure of the vascularisation due to an high grade atherosclerosis). At the final pathological report, 3 pts. were pT0, 2 pts. pT1, 2 pts pT2, 1 had a pT3 TCC; no pts had positive lymphnodes; in 2 pts. incidental prostate cancer was found. At a median follow-up of 9.5 months, no evidence of local recurrence or distal metastasis were seen.

**Conclusion:** RACIC is technically feasible and safe without increased complications. A longer follow-up is required to confirm our results.

### VP20-20 ROBOTIC-ASSISTED LAPAROSCOPIC INGUINAL HERNIA REPAIR WITH DUAL-LAYER POLYPROPYLENE MESH DURING ROBOTIC-ASSISTED LAPAROSCOPIC CYSTECTOMY

J. Marshall, J. Gordetsky, E. Singer, D. Golijanin, H. Rashid, G. Wu—USA

**Background:** Inguinal hernias are frequently identified during robotic-assisted cystectomy. Pneumoperitoneal pressure and pelvic dissection may aggravate a preexisting inguinal hernia leading to enlargement and/or incarceration postoperatively, requiring additional surgery. Laparoscopic hernia repair requires use of mesh, which is directly exposed to abdominal contents after cystectomy. We present our short-term observation of patients who had concurrent laparoscopic inguinal hernia repair with a dual-layer

polypropylene mesh during robotic-assisted laparoscopic cystectomy.

**Methods:** Nonabsorbable dual-layer polypropylene surgical meshes (ETHICON) were used for all inguinal hernia repairs. All repairs were done with a robot-assisted approach at the end of the laparoscopic portion of the surgery. Hernia contents were reduced and the sac removed. The oval layer of the mesh was inserted into the hernia defect with the round layer facing inside. The mesh was attached to the abdominal wall with a 5-mm ProTack or AbsorbaTack Device (Covidien).

**Results:** From Jan 2007 to June 2009, 70 robotic-assisted laparoscopic cystectomies were performed with 12 inguinal herniorrhaphies (3 bilateral and 6 unilateral). Two inguinal hernias were identified preoperatively and the rest incidentally found intraoperatively, all in men. All hernias were asymptomatic preoperatively. Seven patients underwent total intracorporeal laparoscopic ileal conduit diversion. One patient was anephric, excluding the need for urinary diversion and one patient underwent a left cutaneous ureterostomy due to past bowel surgery and nephroureterectomy. Operative time for a unilateral hernia repair was approximately 10 minutes. One patient developed swelling and pain at the inguinal area postoperatively, which resolved spontaneously. No patient to date has developed any herniorrhaphy-related complication.

**Conclusion:** Robotic-assisted laparoscopic inguinal hernia repair with dual-layer polypropylene mesh during robotic cystectomy is safe in the short-term. However, long-term follow-up is necessary to determine the safety of this approach.

## VP21: LESS-II

### VP21-01 PAIRED CONVENTIONAL-ARTICULATING VERSUS DUAL ARTICULATING AND DUAL CONVENTIONAL INSTRUMENTS IN EX VIVO SUTURING IN LAPAROENDOSCOPIC SINGLE SITE SURGERY (LESS)

S. Kommu, D. Cartlidge, T. Finnigan, A. Chakravarti, C. Luscombe, A. Golash—United Kingdom

**Background:** Laparoendoscopic Single-Site Surgery (LESS) has been successfully utilised in performance of several urological procedures. However, proponents of this approach indicate that LESS requires technical expertise with a steep learning curve and a narrower margin for error when compared to conventional laparoscopic surgery. One of the reasons for this is the difficulty in achieving triangulation while at the same time avoiding instrument collision. The articulating instruments, which are introduced into the multichannel port in LESS often, need to be manipulated in a targeted fashion with precision. In a bid to find the optimal mode for suturing in LESS, we compared the impact of paired conventional-articulating versus dual articulating and dual conventional instruments in ex vivo suturing in Laparoendoscopic Single Site Surgery (LESS).

**Methods:** There were two target tasks for assessment in this study. One involved suturing a standard longitudinal defect in a cut glove. The other involved performing five interrupted stitches in a pre-

marked rubber glove. Assessment of trainees was done on two parameters. One was the time taken to achieve the skills necessary to perform the initial target task. The other parameter involved the actual time it took for individual task completion from start to finish. Nine surgical trainees who were naïve to laparoscopy were placed into 3 groups of three. GpA trainees were required to complete the task using paired instruments one of which was a conventional straight needle holder and the other was an articulating needle holder (Autonomy™ Laparo-Angle™, Cambridge Endo, Framingham, MA, USA). GpB trainees used two articulating instruments and GpC used two straight instruments. The instruments were deployed in a purpose built LESS platform consisting of a box model (DIY-LTK™) which was fitted with an R-Port™ as previously described (Kommu et al. Journal of Endourology. November 2008: 1–340).

**Results:** For both the tasks of learning to suture a standard longitudinal defect in a cut glove and performing five interrupted stitches in a premarked rubber glove, GpA took the least time followed by GpC and then GpB. In a separate arm of the study looking at direct timing of individual task completion from start to finish, suturing of a standard longitudinal defect in a cut glove was quickest in GpA followed by GpC and then GpB. Similarly, for the task of putting five interrupted stitches in a premarked rubber glove, the quickest time was by GpA followed by GpC and then GpB.

**Conclusion:** Conventional straight needle holder coupled with an articulating needle holder offers the best overall performance using the LESS approach to suturing. The initial learning curve and later time to task completion were consistently better in this group. GpB trainees who used two articulating instruments were slower at initial uptake and also in the individual task completion times when compared to the other two pairs of instruments. Task performance and learning curve in the LESS platform appears to be optimal when a conventional straight needle holder is coupled with an articulating instrument. Triangulation is achievable with relative ease compared to the other two modes.

### VP21-02 ACCESS AND UTILITY OF A LAPAROENDOSCOPIC SINGLE-SITE SURGERY (LESS) TRAINING PLATFORM AMONG TRAINEES INTERESTED IN LAPAROSCOPIC UROLOGICAL SURGERY

S. Kommu, A. Chakravarti, A. Golash, C. Luscombe, A. Rane, S. (sarg)—United Kingdom

**Background:** Recent developments in minimal access minimally invasive urological surgery such as Laparoendoscopic Single-Site Surgery (LESS) for urology trainees have led to its uptake in several centers of excellence. Surgical trainees who are being groomed for the uptake of these new approaches, and indeed their mentors, are under increasing pressure to acquire, maintain and transfer optimal skills. This has led to current demands for the exploration of novel ways of helping the trainee to achieve the necessary skill set. In a previous study (proceedings of WCE 2006; Journal of Endourology. 2006: A97–A298) we initiated four designated mini-training units for laparoscopic training [called ‘Hot-spots’]. We analyzed the utility of these units in acquiring a target level of skill using two complex laparoscopic radical prostatectomy steps i.e. the dorsal vein complex ligation (DVCL) and the vesicourethral anastomosis (VUA). Herein we share our experience with the utility of a solitary training Hotspot for skill acquisition in Laparoendoscopic Single-Site Surgery (LESS) for urology trainees.

**Methods:** A solitary training Hotspot (a designated room with a box kit and necessary instruments and training tools within a training facility) for skill acquisition in Laparoendoscopic Single-Site Surgery (LESS) was built as previously described (Journal of Endourology. November 2008: 1–340). The Hotspot consisted of a box training kit equipped with articulating instruments on a platform using a multichannel port. The target tasks were based on the basic, intermediate and advanced models in the ex vivo setting. Two trainees, T1 & T2 with basic laparoscopic skills, were given access to the training tool and their utility of the was tool assessed over a six-month period. The time spent, diurnal patterns and learning curves for specific tasks were analyzed. A urological surgeon proficient in LESS Urological procedures analyzed target tasks at the end of the six-month period.

**Results:** Both trainees utilized the LESS Training Hotspot in the following way temporally: [T1 in first month (M1) = 15 hrs, M2 = 17.8 hrs, M3 = 18.2 hrs, M4 = 19.8 hrs, M5 = 22 hrs, M6 = 22.6 hrs] and [T2 in first month (M1) = 18.2 hrs, M2 = 20.1 hrs, M3 = 22.3 hrs, M4 = 28.5 hrs, M5 = 30.2 hrs, M6 = 38.2 hrs]. Target tasks for basic skill, intermediate and advanced procedures were successfully achieved in both trainees at the end of the six months. T1 took longer than T2 to complete LESS vesicourethral anastomosis and dorsal vein complex ligation in the ex vivo models. There was a clear relationship between mean

time spent training and time for task completion at the end of the six months. There was a linear increase in utility of the instruments among both trainees. Consensus of trainees was that with increased utility and confidence with instrument use, there was a further increased drive towards practicing. Both trainees found the initial hurdle of camera-instrument clash with narrow axis of triangulation difficult and took on average 40 Hrs of practice before being “comfortable” with the LESS platform.

**Conclusion:** Purpose built training hotspots in LESS for urological trainees can lead to satisfactory utility with acquisition of the basic skill sets prior to undertaking advanced procedures in the porcine model and the live human case. Designated LESS Training Hotspots in training units/programmes could act as useful supplementary tools with satisfactory outcomes with a minimum of six months of utility. These tools should be studied further.

### VP21-03 INTACT SUTURING USING SONOSCOPIC INSTRUMENT MANIPULATION IN LAPAROENDOSCOPIC SINGLE-SITE SURGERY (LESS)

S. Kommu, I. Persad, I. Lewis, A. Forde, C. Ramjit, S. (sarg)—United Kingdom

**Background:** Laparoendoscopic Single-Site Surgery (LESS) has recently been successfully utilised in the performance of several urological procedures. The preliminary consensus, however, is that it requires technical expertise with a narrow margin for error than for conventional laparoscopic urological surgery (LUS). The challenges of LESS in urology include the narrow focus for target tasking, the difficulty of achieving triangulation and real-time avoidance of instrument collision while maintaining a satisfactory view. Herein we describe the concept of using audio cues by means of sonoscopic aided instrument manipulation. We describe its use in ex vivo suturing using LESS instrumentation without vision but with the sole aid of audio cues i.e. sonoscopy.

**Methods:** A LESS platform consisting of a box model (DIY-LTK™) was fitted with an R-Port™ and flexible cystoscope was developed as previously described (Kommu et al. Journal of Endourology. November 2008: 1–340). Autonomy™ Laparo-Angle™ Instruments from Cambridge Endo were used for this module. The target task was ex vivo knot tying without vision but with the sole use of audio cues in a closed space. The articulating instruments were inserted into a tennis ball and a hook attached at its centre. Probes capable of generating sound were coupled to probes attached to the flexible instruments. Audio feedback was relayed to the operating candidate.

**Results:** Following conventional practice with full visual aid to render familiarity with the instruments and the sound cues, the trainee was blindfolded. The sequence of audio cues required to perform an intact three-prong knot was learnt by the trainee over a period of 520 minutes of practice. Following this initial learning curve the trainee was asked to perform the task in tandem with removal of visual feedback. The task was achieved with the sole aid of sonoscopy.

**Conclusion:** This is the first report of total intact suturing without visual feedback. Whereas, we do not advocate this as a means of performing surgery, we propose that the coupling of visual and audio feedback could aid in optimal task completion in environments that are challenging, as occurs in LESS and NOTES. This approach could act as a useful supplementary tool for optimal task completion in conjunction with visual and tactile feedback in technically challenging approaches.

### VP21-04 INTERNET BASED INFORMATION FOR LAPAROENDOSCOPIC SINGLE-SITE SURGERY (LESS) AND NOTES IN UROLOGY

V. Koo, S. Kommu, A. Chakravarti, A. Golash, C. Luscombe, S. (sarg)—United Kingdom

**Background:** Laparoscopic and robot assisted urological surgery has recently entered a new paradigm leading to an exponential increase in techniques of minimal access minimally invasive surgery. Urology is one of the surgical specialities in which techniques involving Natural Orifice Translumenal Endoscopic Surgery (NOTES) and Laparoendoscopic Single-Site Surgery (LESS) have been successfully applied to the live human case. As these approaches increase in their use, there is a parallel demand by trainees for knowledge and skill acquisition. Some centres are endowed with academic units that have optimal resources to achieve knowledge and skill. However, pilot feedback from trainees seems to suggest that there is a paucity of resources. With the increasing use of the Internet as a resource for information, we assessed the accessibility and utility of the information on the worldwide web regarding resources associated with these procedures.

**Methods:** Using the internet search engine “Google”, and the keywords “LESS”, “E-NOTES”, “SAS”, “SSA”, “SPA”, “NOTUS”, “NOTES”, “SILS”, “TULA”, “U-LESS”, “TUES”, “OPUS” and “urology”, we identified the resources available and knowledge quotient available on the internet.

**Results:** A total of 426 websites were found. There were 185 on SILS, 71 on NOTES, 48 on E-NOTES, 34 on OPUS, 30 on NOTES, 21 on SPA, 15 on LESS, 6 on TUES, 5 on SAS, 5 on TULA, 4 on U-LESS, and 2 on SSA. Geographically, there are 88% from USA, 4.7% from Europe, 1.6% from India, 2.5% from China, 1.2% from Canada, 0.5% from Brazil, 0.5% from Egypt, 0.7% from Korea and 0.3% from South Africa. Several sites are suboptimal with misleading nomenclature. There were very few courses noted. Most courses that were found had already been completed at the time of search. Only six courses were clear in their content and found with relative ease. Most of these were linked to the Endourological Society and The American Urological Association Site.

**Conclusion:** There is geographical variation of Internet information availability, with predominance in the USA and paucity in Asian countries. There is still a wide variation of terms used to describe Laparoendoscopic Single-Site Surgery, and this highlights the need for standardised nomenclature. There was no clear guidance on nomenclature. Studies are currently under way to develop a robust resource website in LESS and NOTES for surgical trainees interested in laparoscopic and robotic urological surgery.

### VP21-05 LAPAROENDOSCOPIC SINGLE-SITE SURGERY (LESS) HOTSPOT TRAINING MODULE IN UROLOGY—A LOW COST APPROACH

S. Kommu, A. Chakravarti, A. Rane, T. Finnigan, A. Golash, C. Luscombe—United Kingdom

**Background:** Demands for skill acquisition and delivery in laparoscopic urological surgery (LUS) coupled with the present global economic constraints led to exploration of novel ways of helping the trainee to achieve skills with low cost training platforms. Laparoendoscopic Single-Site Surgery (LESS) has recently been

applied successfully in performance of a host of urological procedures. Preliminary consensus from the experts is that this mode of surgery is technically challenging and requires expertise. The transition from trainee to practicing surgeon, especially in complex procedures with challenging learning curves, takes time and mentor guided nurturing. However, the trainee needs to use platforms of training to gain the necessary skills that are deemed necessary for undertaking the live human case. The introduction and current uptake of LESS in urology has made skill acquisition more challenging with the inherent technical challenges of single port surgery using articulating instruments. Herein, we developed a low cost model for LESS training in the ex-vivo setting and describe the construction of this device using materials available to most urological units currently practicing laparoscopic or robotic urological surgery.

**Methods:** The raw materials required included a longitudinal cardboard box, a Gel Port™ i.e. that used in hand assisted laparoscopic surgery, a multi channel port e.g. R-Port™, flexible cystoscope or other camera device, rolled cloth×2 and masking tape. The R-Port™ is a multi-instrument access port. It has 3 channels to permit a maximum of 3 instruments to be used simultaneously. Currently, commercially available instruments can be broadly divided into articulating laparoscopic graspers and shears (Real Hand™, Novare Surgical Systems, Cupertino, CA and Autonomy Laparo-angle™, Cambridge Endo, Framingham, MA), endoshears (Cambridge Endo), and laparoscopic needle drivers (Cambridge Endo). Autonomy™ Laparo-Angle™ Instruments from Cambridge Endo represent another means of flexible instrumentation. Having acquired the necessary raw materials, we built a platform to practice the steeplechase exercises. A longitudinal box is cut at the top such that the trainee can look directly into it to allow for direct three-dimensional view of the target task. The use of articulated instruments as dictated by LESS requires familiarisation, which is best done by direct visualisation prior to viewing on the monitor with its restricted two-dimensional view. Two pieces of cloth are rolled to act as a buttress for the Gel Port™. The Gel Port™ is stretched out over the rolled pieces of cloth and the entire system is secured with heavy-duty tape. The Gel Port™ will then be an ex vivo template that acts a portal for a further multichannel port and could be seen as replicating an umbilicus at its centre. The multichannel R-Port™ is then inserted into the centre of the Gel Port™ and secured. The platform for skill acquisition is now complete. The next step is to introduce the instruments and to set the target tasks. Articulating instruments are placed into the appropriate channels. Camera(s) can be set up just above the box to permit viewing via a monitor. A flexible cystoscope can be placed via the camera port and linked to a monitor. We found in this model that direct vision over the box should be undertaken first to allow for instrument familiarisation prior to undertaking the more challenging two-dimensional view via a camera. The target task is set up and the trainee can progress under mentor guidance. Following basic skill acquisition such as loop stacking and pattern cutting, the trainee can practice suturing and more advanced tasks including LESS vesicourethral anastomosis, dorsal vein complex ligation, pyeloplasty and partial nephrectomy. The continuum based approach as previous described (e.g. Kommu et al. Journal of Endourology. October 2007: A1-A292.) was utilised in the training hotspots.

**Results:** A low cost training platform for Laparoendoscopic Single-Site Surgery was successfully developed and utilised for basic and advanced urological skill acquisition in the ex-vivo

setting. The skills acquired by two trainees using the platform were analysed in a structured format by a surgeon proficient in LESS Urological procedures in the live human case. The analysis which included Directly Observed 'Procedural Skills' and time to task completion analysis deemed the trainees competent for mentored progress to the live human case.

**Conclusion:** The readily reproducible Laparoendoscopic Single-Site Surgery (LESS) Hotspot Training Module in Urology can be used by trainees in a structured format to achieve targeted skills in a continuum from basic through to advanced procedures in the ex-vivo setting prior to undertaking mentored live human cases. The LESS Training Hotspots are now being piloted in 4 major teaching hospitals in the U.K. setting. Furthermore the relative low cost of this model makes skill the platform economically feasible.

### VP21-06 LAPAROENDOSCOPIC SINGLE SITE SURGERY (LESS): INITIAL EXPERIENCE USING CONVENTIONAL DEVICES

J. Diaz, R. Riffo, A. Pabon, I. Pinto, C. Sandoval, A. Hornig—Chile

**Background:** Laparoscopic urologic surgery has revolutionized care of the urologic patient, reducing trauma to the abdominal wall. Laparoscopic surgery is generally performed using three to six ports by transperitoneal or retroperitoneal access. The introduction of single port laparoscopy and natural orifice surgery represent the latest evolution in endourology. We present our initial experience in LESS, using conventional instruments and ports.

**Methods:** Since June 2009, four LESS procedure were performed in our center. The Veress needle was placed through the abdominal wall which allowed the carbon dioxide inflow. A 10 mm trocar was placed in the periumbilical site for the laparoscope, followed by placement of two additional 5 or 10 mm periumbilical trocars. The entire procedure was performed using conventional instruments and ports. In the end of surgery the specimen retrieval was removed through the periumbilical skin incisions.

**Results:** Four procedure were performed following this technique: two renal cyst decortication for unrelenting pain, and two nephrectomies. The mean operative time were 91.25 minutes and blood loss were less than 50 cc. No intraoperative complications occurred and no patients needed blood transfusion. Analgesia was performed using ketoprofen (100 mg iv q12h). Mean hospital stay was 19.75 hours.

**Conclusion:** LESS procedure seems to be feasible and safe using conventional laparoscopic instruments.

### VP21-07 LAPARO-ENDOSCOPIC SINGLE-SITE SURGERY (LESS): INITIAL EXPERIENCE IN RENAL SURGERY

H. Kübler, M. Autenrieth, T. Maurer, J. Gschwend

**Background:** The advent of laparoscopic and robotic surgery has revolutionized care of urologic patients. The introduction of laparo-endoscopic single-site surgery (LESS) and natural orifice surgery (NOTES) represent the latest evolution in urology, focused on esthetics and decreased postoperative pain. We present our institution's initial operative experience using LESS in renal surgery.

**Methods:** We performed LESS for renal cyst decortications in a 19 year old, female professional athlete with unspecific flank pain. SILSTM port was used through a transumbilical incision. A flexible grasper and a 5-mm 30-degree camera were used in addition to standard laparoscopic equipment.

**Results:** LESS renal cyst deroofing was successfully accomplished without the need to convert to conventional laparoscopy. The operation time was 64 minutes, and the blood loss was 50 ml. Histopathology confirmed a benign renal cyst. No intraoperative or postoperative complications occurred. Postoperative pain management required only the use of NSAR.

**Conclusion:** LESS is a feasible and safe approach for renal cyst decortications with improved cosmetics and pain control. With further technical development of surgical instrumentation it is inevitable that LESS will be extended to more complex and technically demanding procedures in urologic surgery.

### VP21-08 LAPAROENDOSCOPIC SINGLE SITE (LESS) DONOR NEPHRECTOMY: MULTI-INSTITUTIONAL EXPERIENCE OF 42 CASES

M. Desai, A. Ganpule, S. Adonian, I. Gill, L. R, L. Richestone

**Background:** Mihir M. Desai, Sero Andonian, Arvind Ganpule, Andre Berger, Ricardo Brandina, Amin Herati, David Canes, Monish Aron, Brian Irwin, Mahesh Desai, Louis Kavoussi, Inderbir S. Gill, Lee Richestone. To present a multi-center experience with laparo-endoscopic single site (LESS) donor nephrectomy in 42 patients with specific emphasis on peri-operative donor outcomes and recipient renal allograft function.

**Methods:** Data from 42 patients undergoing LESS donor nephrectomy at 3 institutions (CC, MPUH, NS-LIJ) were accrued in a prospectively managed database. LESS donor nephrectomy was performed transumbilically at CC and MPUH using a novel multi-channel port (N=36) or through a single Pfannenstiel incision using three 5 mm Anchorport trocars at NS-LIJ (N=6). Allograft extraction was performed through the LESS access site in all 42 cases. Mean donor age was 43 years, and BMI was 25. Complex vascular anatomy was present in 8 (16%) cases (two renal arteries 7, retroaortic renal vein 1) and there were 3 right sided (9%) procedures. Peri-operative donor and recipient renal allograft function data were collected and analyzed.

**Results:** LESS donor nephrectomy was technically successful in all 42 patients without need for conversion to conventional laparoscopy or open surgery. Mean operative time was 215 minutes, estimated blood loss was 123 cc, and hospital stay was 2.8 days. Mean warm ischemia time was 6 minutes (3–10 minutes). A renal allograft was lost on post-op day 1 from intra-renal clotting (warm ischemia time 3.8 minutes) and one patient had delayed graft function (warm ischemia time 4 minutes). There were 7 recipient and 3 donor complications. Mean post-transplant recipient serum creatinine was 2 mg/dl, 1.3 mg/dl and 2 mg/dl at day 1, 1 week and 1 month, respectively.

**Conclusion:** LESS donor nephrectomy is technically feasible and reproducible. Early data suggest acceptable donor outcomes and recipient allograft function using the LESS approach. Future research should identify any additional benefit beyond cosmesis and focus on further reducing ischemia time.

### VP21-09 TRANSUMBILICAL LAPAROENDOSCOPIC SINGLE SITE (LESS) SURGERY IN UROLOGY: INITIAL EXPERIENCE

Y. Bayazit, I. Aridogan, D. Abat, O. Karsli, N. Satar, S. Doran

**Background:** It has been aimed to present our initial experience with transumbilical laparoendoscopic single site surgery (LESS).

**Methods:** Since December 2008, LESS has been performed on nine patients including nephrectomy (five), nephroureterectomy

(one), bilateral varicocelectomy (one), bilateral orchiectomy with inguinal hernia repair in a patient with testicular feminization and diagnostic laparoscopy with bilateral excision of the distal tip of the vas deferens due to vanishing testis syndrome. All of the procedures were performed transperitoneally, through a 2 cm semicircular incision in the inner curve of the umbilicus by using three 5 mm trocars. Flexible and straight laparoscopic instruments were used and operations were performed duplicating standard laparoscopic steps.

**Results:** Out of nine patients, five were male and four were female. Mean age was  $27 \pm 11.7$  (10–40) years, and mean BMI was  $23 \pm 0.22$  (15–28)  $\text{kg}/\text{cm}^2$ . There were two pediatric patients. Mean operation time was  $150 \pm 84.2$  (40–270) minutes and in none of the procedures conversion to a traditional laparoscopic or open surgery was needed. No blood transfusion was needed except a pediatric patient who underwent LESS nephrectomy for calculus pyonephrosis. There was no postoperative complication and a drain was inserted in only 2 cases. A single injection of an analgesic agent was used except in three patients who had not required. The mean hospital stay was  $22 \pm 14.5$  (5–46) hours. Postoperative cosmetic results were very satisfying.

**Conclusion:** In conclusion, LESS is feasible in appropriately selected cases and may have some advantages like improved cosmesis, shortened convalescence and less pain. The encouraging initial results and the low incidence of major complications are important factors for LESS to be continued to perform in appropriately selected cases in experienced centers.

#### VP21-10 EMBRYONIC NATURAL ORIFICE TRANSMU- BLICAL ENDOSCOPIC SURGERY (ENOTES) IN UROLOGY USING SILS PORT: INITIAL EXPERIENCE

M. Arslan, T. Degirmenci, M. Yuksel, B. Gunlusoy, S. Minareci, A. Ayder—Turkey

**Background:** In this study, we report our initial results of hidronephrotic and atrophic nonfunctioning kidneys treated with Embryonic Natural Orifice Transumbilical Endoscopic Surgery (ENOTES) approach using SILS Port.

**Methods:** Between March to June 2009, we performed 12 ENOTES nephrectomy. Of these 12 patients, 8 were women and 4 were male and the mean age value was 29 years (16–54). Nine nephrectomies were performed from left and 3 from right side. The patient were prepared in the supine position, and the multichannel port (SILS Port) was inserted into the peritoneum through a 2-cm semicircular incision at the inner edge of the umbilicus. A 4-channel (2 ports 5 mm, 1 port 12 mm, 1 gas port) SILS port and bent or rigid laparoscopic instruments were used. The specimens were taken out from umbilicus after morcellation in endobags.

**Results:** The mean operation time was 125 (62–260) minutes. The loss of blood during operation were 125 (20–375) ml. In 2 patients due to complications we had to change the procedure and return to open surgery and in 1 patient we had to change the procedure to 4 port conventional laparoscopic surgery. The average hospital stay durations were 2 (1–3) days. The average wound healing time was 9.4 (5–12) days and wound infection was seen in 2 patients. The convalescent time was 16.2 (10–21) days. The average follow-up time of the patients was 2.8 (1–4) months.

**Conclusion:** By the help of increasing skills and instruments ENOTES—which has better cosmetic results and faster recovery period—can be performed for hidronephrotic and atrophic non-

functioning kidneys using SILS Port. Prospective comparison is needed to more clearly define its role.

#### VP21-11 ROBOTIC ASSISTED RADICAL CYSTECTOMY: ONCOLOGIC AND FUNCTIONAL OUTCOMES AT UP TO 5 YEARS

O. Elhage, B. Challacombe, F. Ismail, P. Rimington, S. Khan, P. Dasgupta

**Background:** We report the outcomes of the robotic-assisted radical cystectomy (RARC) at up to 5 years. Medium or long term follow-up of this procedure is limited.

**Methods:** We report the oncologic and functional outcomes in the first 60 patients, between 2004–9. Maximum follow-up extends to 5 years. Urinary diversion, ileal conduit (n = 55) or Studer pouch (n = 5) were performed extracorporeally.

**Results:** Of 53 men and 7 women, mean age  $\pm$  SD:  $68 \pm 9$  years, mean operating time  $\pm$  SD  $361 \pm 73$  minutes and blood loss  $\pm$  SD:  $341 \pm 216$  ml. Mean hospital stay  $\pm$  SD:  $9.8 \pm 4$  days. Surgical margins were all clear except for one. Fifty-seven had TCC on final histology (CIS = 5, T0 = 7, G3Ta = 7, G3T1 = 10, G3T2 = 11, G3T3 = 12, G3T4 = 3, G2T1 + CIS = 2), one adenocarcinoma, one squamous cell carcinoma and one sarcomatoid. Mean  $\pm$  SD lymph nodes yield:  $14 \pm 5$  with 6 microscopic nodal metastases. Six patients died of distant metastasis. Overall survival is 90% and disease free survival is 83% at up to 5 years.

**Conclusion:** At medium term follow-up of up to 5 years, RARC appears to be as effective as open and laparoscopic radical cystectomy.

#### VP21-12 SINGLE-INCISION UMBILICAL LAPARO- SCOPIC NEPHRECTOMY: EARLY EXPERIENCE AT THE UNI- VERSITY OF ILLINOIS AT CHICAGO

L. Jones, L. Deane

**Background:** Single-incision laparoscopic nephrectomy has been shown to be technically feasible and represents near scar-free surgery. We review the experience with single-incision laparoscopic nephrectomy at our institution with regard to patient characteristics, technical feasibility and perioperative outcomes.

**Methods:** Three patients underwent single-incision laparoscopic nephrectomy by a single surgeon at our institution utilizing the Covidien Single-Incision Laparoscopic Surgery (SILS) port<sup>TM</sup>. Two patients underwent SILS nephrectomy for renal tumor and one for benign disease. Patient demographics, operative data and outcomes were collected retrospectively.

**Results:** The mean age was 45 (range 20–59) and the mean body mass index was 25.5 (range 21–28). All operations were completed as planned without need for conversion to standard laparoscopic nephrectomy or open radical nephrectomy with a mean operative time of 250 minutes (range 210–270). Blood loss was minimal in all cases (median: 100 cc). Pathologic evaluation revealed advanced (pT3b) tumor stage in one patient and low (T1a) tumor stage in one patient and benign disease in the third patient. Mean tumor size was 4.0 cm. No operative complications were noted. Post-operatively, all patients did well and were discharged from the hospital in 3 or 4 days.

**Conclusion:** Single-incision laparoscopic nephrectomy was technically feasible in a small group of patients for both advanced and localized renal tumor and for benign disease.



### VP21-13 SINGLE PORT TRANSUMBILICAL DISMEMBERED PYELOPLASTY

A. Mikhail, A. Figueroa, L. Bryant, K. Tamaddon, J. Yew, G. Chien

**Background:** With the advent of newer technology and instrumentation, single incision surgery has become increasingly apparent. We therefore present our experience with single port transumbilical endoscopic surgery for dismembered pyeloplasty.

**Methods:** Six patients with clinically symptomatic left ureteropelvic junction obstruction underwent a dismembered pyeloplasty. During this procedure a single Triport system (Advanced Surgical Concepts, Dublin Ireland) was used in 5 cases. Ureter was dissected up to the renal hilum revealing crossing lower pole vessels in two patients. The ureteropelvic junction was dismembered. While suturing the anastomosis, an additional 5 mm port was placed at the future drain site to facilitate this portion of the procedure on the first case. In the remaining 5 cases this 5 mm port was placed at the start of the case.

**Results:** Six patients (3 female and 3 male) with an average age of  $33.0 + 15.5$  (16–54) years underwent a left dismembered pyeloplasty via single incision technique. Average BMI was  $27.8 + 3.9$  (22.9–33.7) kg/m<sup>2</sup>. Average operative time was  $222.3 + 41.1$  (182–285) minutes with an average blood loss of  $66.7 + 49.2$  (25–150) ml. Mean length of hospitalization was  $1.5 + 0.84$  (1–3) days. Average follow up was  $6.5 + 3.5$  (2–11) months. One patient required conversion to standard laparoscopic technique; however, no postoperative complications occurred and no treatment failures to date.

**Conclusion:** Single incision surgery offers patients an aesthetic improvement to standard laparoscopic incisions with potentially less post operative analgesic requirements. Its learning curve may prevent its wide spread use, however, early use of an additional port at the future drain site may facilitate suturing as well as dissection. Longer follow-up with a larger cohort of patients will be required to verify the durability of this procedure with regards to pain control and overall feasibility.

### VP21-14 SINGLE-INCISION LAPAROSCOPIC SURGERY IN UROLOGY: RETROPERITONEAL APPROACH

M. Arslan, T. Degirmenci, M. Yuksel, S. Minareci, A. Ayder—Turkey

**Background:** In this study, we report our initial results of hydronephrotic and atrophic nonfunctioning kidneys treated with Retroperitoneal Single-Incision Laparoscopic Surgery (SILS).

**Methods:** Between March to June 2009, we performed 3 SILS nephrectomies. Of these 3 patients, 2 were women and 1 was male and the mean age value was 37 years (28–64 years). Two nephrectomies were performed from left and 1 from right side. The patients were prepared in the 90 degree flank position and 3 cm incision was vertically performed over the same place which was used for camera trocar in conventional retroperitoneal laparoscopic surgery. Subsequently, surgeon entered into the retroperitoneal space with the index finger and then retroperitoneal space was dissected and extended by using balloon dissection. After the occurrence of enough place for retroperitoneal surgery a 3 mini ports (2 ports 5 mm, 1 port 10 mm) were inserted through the same incision into the retroperitoneal space and bent or rigid laparoscopic instruments were used. The specimens were taken out from the 3 cm incision after morcellation in endobags.

**Results:** The mean operation time was 105 (65–190) minutes. The loss of blood during operation were 80 (20–200) ml. No complication was occurred perioperatively. The average hospital stay durations were 2 (1–3) days. The average wound healing time was 8 (6–10) days and no wound infection was seen. The convalescent time was 14 (12–16) days. The average follow-up time of the patients was 2 (1–3) months.

**Conclusion:** Currently, careful case selection is paramount so that these procedures can be explored safely, with a low threshold to convert to standard laparoscopy as indicated for safety and quality of care. Less hospital stay, better cosmetic results are the advantages of the SILS approach. We think that continuing advances in SILS technology will improve in the near-term.

### VP21-15 PROSPECTIVE COMPARISON OF SINGLE SITE AND TRADITIONAL LAPAROSCOPY FOR UPPER URINARY TRACT SURGERY: INITIAL OUTCOMES

I. Derweesh, W. Bazzi, E. Godebu, J. Silberstein, R. Im, K. Sakamoto

**Background:** Single Site Laparoscopy (SSL) is an emerging platform which, which by consolidating working trocar and extraction incision sites, may represent a further decrease in morbidity compared to multi-trocar site traditional laparoscopy (TL). Herein we present a prospective comparison of transperitoneal TL and SSL approaches for laparoscopic Radical Nephrectomy (RN) and Partial Nephrectomy (PN).

**Methods:** Nonrandomized prospective comparison of TL- and SSL-RN and PN. 11 patients underwent SSL (7 SSL-RN/4 SSL-PN) and 15 patients underwent TL (11 TL-RN/4 TL-PN) from 2/2009 to 6/2009. All cases were performed with via a transperitoneal approach. TL-LRN and TL-LPN were performed with a 4 trocar approach. For SS-LRN and SS-LPN, transperitoneal access was obtained through a peri-umbilical incision through which all working trocars were inserted. SSL-RN and SSL-PN recapitulated all the standard steps of TL-RN and TL-PN. For TL- and SSL-RN this included: Renal dissection, sequential ureteral, renal arterial and venous staple ligation, and intact specimen extraction. For TL-SSL-PN this included: Renal dissection, and hilar control; prior to specimen excision and renorrhaphy. In 3 TL-PN and 3 SSL-PN and temporary hilar occlusion was utilized for specimen excision and renorrhaphy, in 2 cases (1 TL-PN/1 SSL-PN) excision and hemostasis were achieved utilizing the Habib 4x laparoscopic radiofrequency resection device (Angiodynamics, Queensbury, NY). Demographic factors, tumor characteristics, peri-operative variables, outcomes and complications were prospectively recorded and analyzed. Students t-test was utilized for statistical analysis.

**Results:** All 15 TL cases were successfully completed laparoscopically. 10/11 SSL cases were successfully performed without conversion to TL or open surgery, one SSL-PN was converted to open PN for non-progression. There were no significant differences with respect to demographic factors (Mean age, sex, ethnicity, BMI, ASA Class) between the two groups. For TL- and SSL-PN: Mean tumor diameter (cm) was 1.7 and 1.8, respectively ( $p=0.88$ ); mean Ischemia time (min) was 23 and 20, respectively ( $p=0.81$ ); operative time was 138 and 177, respectively ( $p=0.17$ ). There were no significant differences with respect to preoperative/postoperative serum creatinine ( $p=0.88$ ) and estimated Glomerular Filtration Rate ( $p=0.97$ ). For TL- and SSL-RN: Mean tumor diameter (cm) was 5.0 and 5.3, respectively

( $p=0.81$ ); mean operative time (min) was 178 and 151, respectively ( $p=0.27$ ); mean estimated blood loss (mL) was 186 and 133, respectively ( $p=0.33$ ). For the SSL group, mean incision size was 4.7 (4–5.3). For the TL and SSL groups: mean hospital stay (days) was 4.8 and 3.4, respectively ( $p=0.10$ ); percent requiring postoperative opiate supplementation was 86.7% and 45.5% ( $p=0.02$ ). No patients in either group required blood transfusions, all patients had negative resection margins, and all are currently alive and there were no significant differences in complication rates between the two groups ( $p=0.66$ ).

**Conclusion:** In this well matched prospective comparison, SSL appears to be comparable to TL in terms of preoperative parameters and confers a benefit with respect to opiate supplementation requirement. Evaluation of more patients and longer-term assessment and follow up are requisite.

### VP21-16 THE TECHNIQUE AND SKILL IMPROVEMENT OF LAPAROSCOPIC LIVE DONOR NEPHRECTOMY VIA RETROPERITONEAL APPROACH (WITH 150 CASES REPORT)

L. Ma, L. Zhao, X. Hou, G. Wang, K. Hong, Y. Liu

**Background:** To summarize the technique and skill improvement of laparoscopic live donor nephrectomy via retroperitoneal approach in our hospital.

**Methods:** 150 patients underwent laparoscopic live donor nephrectomy via retroperitoneal approach at our institution from December 2003 to June 2009. Under general anesthesia, all donors were placed in lateral decubitus. We used three transretroperitoneal trocars whose diameter was 12 mm, 10 mm and 5 mm through different ports of the waist. The skill of the dissociation of donor kidney and vessel of kidney: a. Clean up the extroperitoneal fatty tissue of the hyperpimelic patients. Cut off the Geort fascia for 3–4 cm in front of the major psoas muscle. The incision couldn't be too large! Dissociate the donor kidney completely inside the adipose capsule. It would not influence our operation if the adipose capsule was adhered to the tissue around. b. Remove the fatty tissue between the major psoas muscle and the kidney. It would be very easy to reveal and liberate the renal vessel. c. Separate and deligate the genital vein and the lumbar vein between the major psoas muscle and the kidney. d. Liberating the ureter for about 7–8 cm away from the anus perineum of donor kidney in advance would make it much easier to separate the renal pedicle. Skill improvement: A. Genital vein, lumbar vein and adrenal veins were cut with ultrasound knife. It would be much expensive to cut these veins with endoscopic articulating linear stapler. Beside, cutting with Ti-clip would influence the occlusion of renal arteries and veins with hem-o-lok. B. The dissected donor kidney and ureter were taken out through an incision about 6 cm extended from the first trocar port. The incision should be suitable to the muscle fiber in order to reduce muscle fiber and nerve injury. C. In order to decrease the warm ischemia time, we usually cut open skin and subcutaneous tissue prior to the disconnect of renal arteries and veins.

**Results:** All the 150 nephrectomy operations were successfully performed, mean operative time was 80 min (50–180 min), and mean blood loss during operation was 70 ml (10–200 ml), none of the donors needed blood transfusion. Warm ischemia time was 3–5 min, postoperative length of stay averaged 5.5d (3–9d). At the mean follow-up, all the donors were healthy and no complication occurred. All the renal transplantations were successfully performed.

**Conclusion:** Mastered the skills of laparoscopic live donor nephrectomy via retroperitoneal approach and combined with technical improvement, we have made the operation safe and effective.

### VP21-17 RETROPERITONEAL LAPAROSCOPIC NEPHRON-SPARING SURGERY FOR RENAL TUMOR (REPORT OF 50 CASES)

L. Ma, Y. Huang, J. Lu, K. Hong, G. Wang, L. Zhao

**Background:** To summarize the experience of retroperitoneal laparoscopic nephron-sparing surgery in our hospital.

**Methods:** A total of 50 patients with renal tumors underwent retroperitoneal laparoscopic nephron-sparing surgery from January 2006 to June 2009. The retroperitoneal approach was used in these 50 patients with 3 trocars through different ports of the waist. Liberate the kidney and perirenal fat. Afterwards, fatty cysts surrounding or on the surface of the tumor were resected about 2 cm around the tumor. During the operation, the renal artery was exposed and was then clamped. Tumor excision was then performed using shears. An incision was made at the point 0.2 cm ~ 0.5 cm away from the margin of the tumor, and was extended deeply to completely cut the tumor. 70 percent pelvis was cut off and was interrupted sutured or continuous sutured with 3-0 absorbable sutures. After the procedure, the renal incision was interrupted sutured with 1-0 or 2-0 absorbable sutures, and covered with fibrin sealant. One more stitch was sutured when bleeding happened after unclamping the renal artery.

**Results:** All procedures were successfully completed without open conversion. Mean surgical time was min (55 min ~ 150 min) and mean blood loss was 80 ml.

**Conclusion:** With good laparoscopic surgery technique, retroperitoneal laparoscopic nephron-sparing surgery is feasible and safe.

### VP21-18 LAPAROSCOPIC PARTIAL VS. RADICAL NEPHRECTOMY: COMPARISON OF LONG-TERM FUNCTIONAL OUTCOMES

B. Benway, J. Cabello, S. Bhayani—USA

**Background:** Nephron-sparing surgery (NSS) has demonstrated improved functional outcomes over radical nephrectomy in the open setting. However, limited comparative data exists for minimally-invasive approaches, during which the kidney is exposed to warm ischemia. We sought to evaluate functional outcomes associated with laparoscopic radical (LRN) and partial (LPN) nephrectomy in patients with T1a lesions.

**Methods:** From August 2004 to December 2008, 262 patients underwent laparoscopic or robot-assisted surgery for T1a tumors. Patients with pre-existing renal insufficiency, an impaired or absent contralateral kidney, and those with follow-up <30 days were excluded. Glomerular filtration rate was estimated (eGFR) using the MDRD equation. Results were evaluated with a Mann-Whitney U test.

**Results:** 42 LRN and 67 LPN patients met inclusion criteria. Preoperative serum creatinine (sCreat) and eGFR were equivalent (0.91 and 0.92 mg/dL,  $p=0.8$ ; 84 and 86 ml/min/1.73 m<sup>2</sup>,  $p=0.5$ ). At a mean follow-up of 662.6 and 455.5 days, sCreat was significantly higher (1.52 vs. 1.04 mg/dL,  $p<0.0001$ ) and eGFR was significantly lower (49 vs. 75 ml/min/1.73 m<sup>2</sup>,  $p<0.0001$ ) for patients undergoing LRN, compared to LPN, respectively. Postoperative chronic renal insufficiency was observed in 17% of LRN and none of the LPN patients. Consistently, LRN was associated with higher incidence of new onset of stage 3 or higher chronic

kidney disease (eGFR < 60 ml/min/1.73 m<sup>2</sup>), with 29 (69.0%) vs. 11 (16.4%) patients observed in the LPN group.

**Conclusion:** LPN is associated with improved preservation of renal function and a decreased incidence of chronic renal insufficiency compared to LRN, despite the potential insult of warm ischemia during partial nephrectomy.

### VP21-19 RETROPERITONEOSCOPIC DONOR NEPHRECTOMY: OUTCOME OF 500 CASES

P. Modi, J. Rizvi, B. Pal

**Background:** Introduction: Transperitoneal laparoscopic donor nephrectomy is standard of care at many centers. We present outcome of retroperitoneal laparoscopic donor nephrectomy. The principles of open donor nephrectomy were followed.

**Methods:** 500 retroperitoneoscopic donor nephrectomy (RDN) were performed between September 2004 and June 2009 by a single surgeon. 347 were on left side and 88 donors were Africans and all others were Indians. For right RDN four and for left RDN three ports were used. Endo TA 30 mm stapler was used for control of right renal vein and, hem o lok clips were for renal arteries and left renal veins. Kidney was procured from suprainguinal muscle splitting incision.

**Results:** Three left RDN required conversion to open surgery; two due to haemorrhage and one due to nonprogress. Mean warm ischemia time, operation time and blood loss were 225 seconds, 138 minutes and 84 ml respectively. 64 cases had two or more arteries and, 23 cases on right side had multiple renal veins. Major complications (Clavien classification) were present in 4 cases and minor in 35 cases. Recipient mean serum creatinine value at one month was 1.23 mg%. Delayed graft function was present in 5 patients. 33 grafts were lost at one year follow up; two each due to renal artery thrombosis and mycotic aneurysms and all others due

to rejections. 19 patients were lost; 12 due to infection related complications.

**Conclusion:** Both right and left sided retroperitoneoscopic donor nephrectomy is donor and recipient friendly.

### VP21-20 INICIAL EXPERIENCE IN UROLOGICAL LAPAROENDOSCOPIC SINGLE-SITE SURGERY (LESS)

Hugo Bermudez, Rodrigo Ledesma, Oscar Storme, Conrado Stein, Mr. Raul Valdevenitol, Pablo Bernier—Chile

**Introduction:** Laparoendoscopic Single-Site Surgery (LESS) is becoming a feasible surgical alternative for improving post-operative care by reducing stress on the abdominal wall through a single access mainly made over the umbilicus. Herein we describe our initial experience.

**Methods:** From March to June 2009, Ten patients underwent LESS. Five pielloplasties, three bilateral varicocelectomies and two simple nephrectomy were performed. Procedures were conducted by using flexible instruments and optic that were inserted on a working channel made by a low-profile port passed through the umbilicus. An accessory 3 mm port was used for suturing on pielloplasty procedure.

**Results:** The average age was 23 years old (18–29), with a operative time of 140 minutes (pielloplasty), 23 minutes (bilateral varicocelectomy) and 89 min (nephrectomy) respectively. Average blood loss was estimated in 40cc (pielloplasty), 0cc (bilateral varicocelectomy) and 50 cc (nephrectomy). Patients were discharged mainly at the second day (1–5). For pielloplasty, an indwelling catheter was used for 7 days and a double J catheter was left for 3 weeks.

**Conclusions:** LESS is arising as a safe, effective and reproducible technique. More studies are needed for determining whether this surgical approach will be able to stand out as a new standard of care.

## VP22: LAPAROSCOPY—ADRENAL AND KIDNEY

### VP22-01 LAPAROSCOPIC ADRENALECTOMY FOR ADRENAL TUMORS LARGER THAN 5 CM: AN OUTCOME ANALYSIS

G. Arvind, R. Sharma, R. Sabnis, V. Muthu, A. Kurien, M. Desai

**Background:** We examined the outcome and complications of laparoscopic adrenalectomy for lesions larger than 5 cm.

**Methods:** A total of 26 patients underwent Laparoscopic Adrenalectomy from March 2003 till date of whom 18 patients had tumour >5 cm in size. Their mean age was 41.4 years (range 10–66 years), and the mean tumor size was 7.1 cm (range 5.3–9.5 cm). They were compared with patients whose adrenal tumors were <5 cm.

**Results:** The tumor group of >5 cm size had a mean operating time of 144.7 ± 51.6 minutes (range 60–240 minutes) and a mean hemoglobin drop of 1.47 gm% (range 0.3–4.0 gm%) and required a mean of 25 hours before starting oral intake and requirement of analgesia was 191 mg of Tramadol (range 50–550 mg). Except for operative time which is significantly higher in the large tumour

group (106 min of average OR time in smaller tumour group), none of these values is significantly different from the results in the control group (P > 0.05). There were no major complications seen in any of the patients and no open conversions. Histopathology revealed 15 benign tumors (7 pheochromocytomas, 4 non functioning adenomas, 2 ganglioneuroma, 1 pseudocyst and 1 myelolipoma). There were only 3 malignancies encountered in the >5 cm group (16.6%), one was primary adrenocortical carcinoma and 2 metastases.

**Conclusion:** Laparoscopic adrenalectomy is feasible for tumours large than 5 cm. Surgeon should be ready to convert to open adrenalectomy if there is local invasion, capsular disruption, or technical difficulties.

### VP22-02 SURGICAL OUTCOME OF SIMULTANEOUS LAPAROSCOPIC BILATERAL ADRENALECTOMY IN A SINGLE INSTITUTE

Y. Kawasaki, S. Ishidoya, A. Ito, Y. Arai—Japan

**Background:** Laparoscopic surgery is established as golden standard for surgical treatment of adrenal diseases and a large number of laparoscopic adrenalectomy is widely performed. In this study we analyzed surgical outcomes especially about safety and efficacy for simultaneous bilateral laparoscopic adrenalectomy in a single institute.

**Methods:** A Total of 45 patients received bilateral laparoscopic adrenalectomy, in which 34 patients underwent simultaneous bilateral surgery while 6 patients underwent two-step bilateral adrenalectomy and other patients underwent open surgery between 1998 and 2009. After endocrinological examinations, all patients received multi-detector CT (MDCT) and adrenal venous sampling (AVS) carried out by radiologists. According to the results of MDCT and AVS, laparoscopic adrenalectomy was performed by staff urologists.

**Results:** We performed simultaneous laparoscopic bilateral adrenalectomy for 19 patients with bilateral aldosterone-producing adenoma (APA), 4 with bilateral Cushing's syndrome (CS) and unilateral APA with contralateral nonfunctioning adenoma (NFA), 3 with bilateral APA associated with subclinical CS, 2 with bilateral pheochromocytoma, and one patients with bilateral metastatic tumor or bilateral subclinical CS respectively. The mean operative time (including repositioning time) was 334.6 min (range, 211–572 min) and the mean estimated blood loss was small (range, 0–850 ml). Any patients did not experience major complications including open conversion nor postoperative Addisonian crisis.

**Conclusion:** Simultaneous laparoscopic bilateral adrenalectomy is safe and effective surgical procedure for patients with bilateral adrenal disease.

### VP22-03 LAPAROSCOPIC ADRENALECTOMY FOR PHEOCHROMOCYTOMA IN THE PRESENCE OF A HORSESHOE KIDNEY

J. Yates, N. Patel, J. Uberoi, R. Munver—United States

**Background:** Adrenal pheochromocytoma is associated with various genetic syndromes including multiple endocrine neoplasia and neurofibromatosis type 1 (NF-1). This report illustrates the excision of a right adrenal pheochromocytoma in a patient with neurofibromatosis and a horseshoe kidney.

**Methods:** A 62 year old female with NF-1 was found to have a right adrenal mass associated with a horseshoe kidney. Radiologic characteristics and endocrinologic evaluation revealed the mass to be a pheochromocytoma. The patient was symptomatic and elected for surgical management via a laparoscopic approach.

**Results:** A transperitoneal approach was employed with the use of 4 trocars. An upper pole renal artery and vein were noted to be in close proximity to the inferior border of the adrenal gland. Meticulous dissection resulted in identification of the inferior vena cava and a large hepatic vein. Further dissection revealed an anomalous main adrenal vein that entered into the hepatic vein. The adrenal vein was dissected, ligated, and transected. The upper, lateral, and inferior attachments of the adrenal were divided and the adrenal gland was placed in a laparoscopic bag and extracted. The operative time was 104 minutes and blood loss was 5 milliliters. The patient was discharged home on the first postoperative day without complication. Final pathology revealed a 3.5 cm pheochromocytoma.

**Conclusion:** Laparoscopic adrenalectomy in the setting of a horseshoe kidney may be complicated by anomalous anatomy. In

particular, anomalies or multiplicity of the adrenal vessels or renal hilar vessels must be suspected. Cautious dissection and recognition of potential abnormalities can result in successful and uneventful removal of the adrenal gland.

### VP22-04 ROBOTIC-ASSISTED LAPAROSCOPIC PARTIAL ADRENALECTOMY FOR ADRENAL ADENOMAS

J. Yates, J. Uberoi, R. Munver—United States

**Background:** Partial adrenalectomy has been described as a procedure focused on the preservation of normal adrenal tissue. Although questions remain about the risks and benefits of routine application of adrenal-sparing surgery, selective use of laparoscopic partial adrenalectomy has been described. This report illustrates the technique of robotic-assisted laparoscopic partial adrenalectomy for benign adrenal adenomas.

**Methods:** A 47 year old male presented with a hormonally active left adrenal mass that demonstrated growth on serial imaging. The mass was consistent with an adenoma on radiologic imaging studies. The patient elected for minimally invasive surgery for management of the adrenal mass.

**Results:** A transperitoneal approach was utilized with 4 trocars. Robotic assistance was employed for the entirety of the procedure starting with mobilization of the colon and spleen. The adrenal vein was identified, ligated, and transected. The improved visualization and dexterity provided by the robotic instruments assisted with dissection of the adenoma from uninvolved adrenal tissue. The adenoma was separated from the remnant adrenal gland with a bipolar vessel sealing device. The patient was discharged home on the first postoperative day without complication. The operative time was 165 minutes and blood loss was 35 ml. Pathology revealed a 3.5 cm × 2.5 cm × 2.0 cm adenoma.

**Conclusion:** Adrenal-sparing surgery offers the advantage of treating benign adrenal tumors while sparing patients from the potential need for lifelong hormonal supplementation. Robotic-assisted partial adrenalectomy is a safe and feasible technique that offers improved visualization, dexterity, and precision compared to standard laparoscopy. Partial adrenalectomy via this minimally invasive approach may be suitable for select patients in which adrenal preservation is desired.

### VP22-05 LAPAROSCOPIC ADRENALECTOMY—THE INDIAN EXPERIENCE

G. Kumar, S. Bhat—India

**Background:** In developed nations, there are numerous large single center series for Laparoscopic Adrenalectomy (LA). We present the first large single center experience from India. The demographics, indications and other details are discussed.

**Methods:** We retrospectively analyzed the charts of all LA done in our institution between May 2002–May 2009 with respect to the demographics (age, sex, size of the lesion) operative parameters, postoperative course and complications.

**Results:** 116 Laparoscopic adrenalectomies were done in 97 patients. Nineteen were bilateral and majority were females (59:38). The mean (95% confidence interval) size, operating time, blood loss and hospital stay were 5.27 (4.8, 5.7) cm, 133.5 (119.8, 147.2) minutes, 89.0 (61.9, 116.2) ml and 4.5 (4.0, 5.0) days. Majority (n = 33) were phaeochromocytomas. Subset analysis showed increased blood loss (p < 0.05) for phaeochromocytomas (126.9 vs. 68.65 ml) and large masses more than 6 cm (146 vs 55 ml), although operating times were comparable with non-phaeochromocytomas

(127.7 vs 136.6 min) and small masses (145 min vs 126.5 min). Seven of the Thirty-six adrenal masses more than six cm in size, where malignant (pheochromocytoma-5, adrenocortical carcinoma-2). Five large masses (>8 cm) required a terminal hand assist and one needed open conversion. The overall complication rate was 12.9% with one mortality.

**Conclusion:** LA is the “gold standard”. Our large series by Indian standards has revealed that sustained contact with practicing physician and surgeons of the state of Kerala has resulted in strong referral base. This has indeed improved the standards of care in adrenal disease to levels that are internationally acceptable.

#### VP22-06 COMPARISON ADRENALECTOMY TECHNIQUES: LATERAL TRANSPERITONEAL AND PRONE RETROPERITONEAL APPROACHES

Z. Okhunov, A. De la Torre, D. Lee, J. Lee, J. Landman—United States

**Background:** Laparoscopic adrenalectomy has supplanted the conventional open adrenalectomy approach for the vast majority of cases. Recently, a novel retroperitoneal lateral approach performed in the prone position has been introduced. In this study we compare the transperitoneal and the lateral retroperitoneal approaches as defined by intraoperative parameters and outcomes.

**Methods:** A retrospective chart review was performed for patients who underwent either transperitoneal adrenalectomy (TA) or retroperitoneal lateral adrenalectomy (RLA). Patient demographics, comorbidities, perioperative and postoperative data were collected and analyzed.

**Results:** Between July 2006 and August 2008 total of 25 patients underwent laparoscopic adrenalectomy, of these, 13 TLA and 12 RLA. There were no major intraoperative or postoperative complications. Patient demographics and comorbidities were identical in both groups. Mean adrenal mass size was 4.2 ( $\pm 2.02$ ) cm for the TA group and 2.1 ( $\pm 0.65$ ) cm for the RLA group ( $p = 0.007$ ). TA was comparable to RLA in terms of operative time 121 ( $\pm 36$ ) versus 81 ( $\pm 31$ ) minutes; ( $p = 0.09$ ). The mean positioning time for TA and RLA was 28.6 ( $\pm 13.3$ ) and 24 ( $\pm 13.9$ ), respectively; ( $p = 0.60$ ). The hospital stay for TA and RLA averaged at 2.1 days ( $\pm 0.75$ ) versus 1.5 days ( $\pm 0.5$ ), respectively; ( $p = 0.03$ ). Intraoperative blood loss for TA and RLA was 98.5 ( $\pm 117$ ) and 4.5 ( $\pm 7.9$ ) mL, respectively; ( $p < 0.02$ ). In addition, mean follow up time was significantly longer in the TA group than in the RLA group 18.5 versus 11.7 mos, respectively; ( $p = 0.02$ ). Table 1. Patient demographics, comorbidities, and pathological data

Characteristic	TA (n=13)	RLA (n=12)
Male (%)	6 (46%)	7 (58%)
Female (%)	7 (54%)	5 (42%)
Mean age (years)	56.8	43.8
Mean BMI	24.7	24.5
No. right side	7 (54%)	5 (42%)
No. left side	6 (46%)	7 (58%)
Patients comorbidities		
Prior abdominal surgery	3 (23.1%)	2 (16.7%)
Diabetes	3 (23.1%)	3 (25%)
CVA	2 (15.4%)	0
HTN	9 (69.2%)	8 (66.7%)
Pathology		
Aldosteronoma	9 (75%)	6 (50%)
Cushing syndrome	1 (8.3%)	0
Pheochromocytoma	1 (8.3%)	4 (33.3%)
Other not specified	2 (16%)	2 (16.6%)

**Conclusion:** Both transperitoneal lateral and retroperitoneal lateral approaches for laparoscopic adrenalectomy are safe and effective approaches. The retroperitoneal technique may be a more cost effective and time efficient approach than the transperitoneal approach for small adrenal tumors (less than 5 cm). However, further study is necessary with larger patient population to support these findings.

#### VP22-07 LAPAROSCOPIC ADRENALECTOMY WITH 10MM LIGASURE

G. Simone, S. Guaglianone, R. Papalia, M. Ferriero, E. Forastiere, M. Gallucci

**Background:** We describe the feasibility and perioperative efficacy of laparoscopic adrenalectomy using the 10 mm Ligasure sealing system.

**Methods:** Between January 2002 to March 2009, 105 patients underwent laparoscopic adrenalectomy, using Ligasure sealing system. Preoperative data and perioperative results were collected in a prospectively maintained data base. Twelve patients underwent simultaneous bilateral laparoscopic adrenalectomy. Surgical procedure was performed with a three/four trocar technique and with patients in extended flank position. No clip and no ligature was applied to adrenal vessels, tumor dissection and vessels sealing was performed with the only use of a 10 mm Ligasure. Specimens were removed in endobag through the 12 mm port. A drain was left into the adrenal fossa.

**Results:** No conversion to open surgery occurred. The mean size of the removed adrenal gland was 5.1 cm (range 2.7 to 10 cm). The mean operative time was 42 minutes (range 30–58) for unilateral procedure and 90 minutes (range 60 to 160) for single setting bilateral procedures. The median blood loss was 50 ml (range 30–600 ml) for unilateral adrenalectomies and 80 ml (30–300 ml) for bilateral ones. No major complication occurred but in one patient a postoperative bleeding required reintervention and in this patient two transfusions were necessary postoperatively. The median time to discharge was 2.7 days (range 2 to 13).

**Conclusion:** The Ligasure vessels sealing system can be used for hemostasis of vessels and tissue bundles in laparoscopic adrenalectomy. The time spared thanks to this device significantly reduce morbidity without affecting hemostasis effectiveness.

#### VP22-08 LAPAROSCOPIC ADRENALECTOMY FOR ADRENOCORTICAL CARCINOMA IN 12 CASES

O. Castillo, I. Vidal-mora, F. Sepulveda, R. Campos, A. Foneron, G. Rubio

**Background:** The role of laparoscopic adrenalectomy (LA) for adrenocortical carcinoma is a controversial issue due to the low incidence of this disease and the lack of oncological followup. Our aim is to present our experience in adrenocortical carcinoma managed by LA.

**Methods:** We performed a prospective analysis of LA performed between 1996 and 2008. Only those patients with histologic diagnosis of adrenal carcinoma were included. For each case we analyzed the preoperative characteristics of patients, surgical results and follow up.

**Results:** During this period 315 LA were performed showing only 12 of them the histological diagnosis of adrenal carcinoma. The average age was 38 years with a male: female ratio of 1:1. The average tumor size was 8.6 cm (5.516 cm), margins were negative on 11 cases, and only one presented an incomplete resection. All procedures were completed by laparoscopic surgery without complications. The average follow up time was 41 months during which 5 patients had disease progression and 2 presented local recurrence.

**Conclusion:** In experienced hands the LA for adrenocortical carcinoma can be used safely in large tumors without increasing

morbidity for the patient. Long term follow up is still needed to validate the oncologic results of this technique.

### VP22-09 LAPAROSCOPIC TRANSPERITONEAL ADRENALECTOMY: EXPERIENCE IN 308 CASES

O. Castillo, I. Vidal-mora, R. Campos, G. Rubio, A. Foneron, F. Sepulveda

**Background:** Laparoscopic adrenalectomy has become the procedure of choice for all adrenal masses, regardless of their functionality or even his tumor character. We describe the indications and results of our series.

**Methods:** Between September 1996 and February 2009 308 laparoscopic adrenalectomys have been performed. The main indications in this series were: incidentaloma (120/38%); Hyperaldosteronism (42/12, 8%); Cushing (23/7.7%) and pheochromocytoma (35/11.4%). The average age of patients was 41.1 years and the average tumor size was 5.5 cm. (2–11).

**Results:** The pathological diagnosis in order of frequency was, pheochromocytoma, Cushing's disease, metastasis, hiperaldosteronism, congenital adrenal hyperplasia, myelolipoma and adenoma. We performed a total adrenalectomy in 279 patients (90.2%) and partial in 29 (9.7%). The mean operative time was 78.6 minutes (25–210) and mean blood loss was 63 ml (0–500). Transfusion was required in eight patients. There were 17 major complications (5.7%) most of them resolved laparoscopically and only one required conversion. One patient died of a myocardial infarction (AMI) in the post-operative and we described only two incisional hernias as late complications. The mean hospital stay was 3.2 days. (2–5).

**Conclusion:** We believe that laparoscopic adrenalectomy is a viable, safe, and reproducible and should be the technique of choice in the management of adrenal tumors.

### VP22-10 LAPAROSCOPIC SYNCHRONOUS BILATERAL ADRENALECTOMY

A. Foneron, O. Castillo, G. Rubio, I. Vidal-mora, R. Campos, M. Feria-flores—Chile

**Background:** To report our experience in a series of bilateral synchronous laparoscopic adrenalectomies detailing technique and results.

**Methods:** A total of 242 laparoscopic adrenalectomies were performed in an 8 year period at our institution. Out of these, 24 were bilateral. Of the 24 patients, 22 (92%) were bilateral and synchronous. Mean patient age was 41.4 years (range 17 to 72 years) and male to female ratio was 1:2.1.

**Results:** Mean adrenal size was 5.5 cm (range 2 to 11 cm). In order of frequency, pathological finding was: Pheochromocytoma, Cushing disease, Metastatic lesions, Hyperaldosteronism, Congenital Adrenal Hyperplasia, Myelolipoma and Adrenal Adenoma. Complete adrenalectomy was performed in 36 cases (82%) while in 8 cases (18%) partial adrenalectomy was preferred. Mean operative time was 78.6 minutes (range 25 to 210 min) being 79.5 min and 77 min for right and left adrenalectomies respectively. Mean operative bleeding was 63 ml (range 0 to 500 ml). Only one patient received a transfusion. An intraoperative complication occurred in only one patient (2%), a small tear in the renal vein that was successfully controlled by means of intracorporeal suturing. Mean hospital stay was 3.2 days (range 2–5 days).

**Conclusion:** We believe that laparoscopic synchronous bilateral adrenalectomy is a feasible, safe and reproducible technique that

should be considered of choice for the management of benign bilateral adrenal pathology.

### VP22-11 BILATERAL PHEOCHROMOCITOMA: BILATERAL SYNCHRONIC LAPAROSCOPIC ADRENALECTOMY IN 9 CASES

O. Castillo, G. Rubio, I. Vidal-mora, A. Foneron, R. Campos, M. Feria-flores

**Background:** Laparoscopic surgery for the management of pheochromocytoma is a validated technique. We report our experience in 9 cases with bilateral pheochromocytoma, who underwent laparoscopic simultaneous bilateral adrenalectomy.

**Methods:** A prospective analysis of 296 laparoscopic transperitoneal adrenalectomy was performed. From May 1999 to June 2008, 9 patients were diagnosed with bilateral pheochromocytoma, after serological and radiological examinations.

**Results:** Nine transperitoneal laparoscopic simultaneous bilateral adrenalectomy procedures were performed. There was no conversion. The average time of surgery was 180 minutes (range 95–300). The intra-hospital stay averaged 3.8 days (range 3–5). The mean bleeding was 92 ml. (range 0–500 ml.). The histopathologic diagnosis was pheochromocytoma in all samples, with one case reported as malignant pheochromocytoma.

**Conclusion:** With an adequate preparation, and a refined surgical technique, the laparoscopic simultaneous bilateral adrenalectomy is a safe procedure, and adds all the advantages of minimally invasive surgery with better convalescence and cosmetic results.

### VP22-12 LAPAROSCOPIC ADRENALECTOMY FOR SUSPECTED METASTASIS OF THE ADRENAL GLANDS: OUR EXPERIENCE

A. Foneron, O. Castillo, I. Vidal-mora, R. Campos, G. Rubio, M. Feria-flores—Chile

**Background:** We present our experience in laparoscopic adrenalectomy for isolated adrenal metastasis.

**Methods:** A total of 34 adrenalectomies were performed in 32 patients for incidental adrenal masses discovered at the time of primary tumor diagnosis or during follow-up. Primary tumors were: 13 lung carcinoma, 9 renal cell carcinoma, 2 colorectal carcinoma, 2 bladder carcinoma and 1 ovarian carcinoma, breast cancer, gastric cancer and melanoma respectively. Two patients had no history of a primary tumor. Mean patients age was 59 years (range 26–75). Male to female ratio was 1.9:1.

**Results:** Mean operative time was 87 minutes (range 40–240). Average blood loss was 89 ml (range 0–1000). There was no need for conversion to open surgery. Mean hospital stay was 3 days (range 1–5). There was 1 intraoperative diaphragmatic lesion repaired laparoscopically and 1 patient had a pancreatic fistula which was managed by percutaneous drainage. Mean tumor size was 4.3 cm (range 1.5–9). Microscopic analysis showed 22 malign lesions (64.7%) and 12 cases of benign pathology (35.3%). Mean survival time was 26 months (range 4–64) for the 22 patients with malign lesions. In 2 patients (9.1%) surgical margins were positive.

**Conclusion:** Laparoscopic adrenalectomy for small isolated metastases is feasible. However, due to a high risk of positive margins this procedure should only be done by an expert laparoscopist. We haven't found correlation between mass size and malignancy. Nevertheless, we believe that longer follow-up is mandatory before definitive conclusions are drawn.

### VP22-13 IS RETROPERITONEAL LAPAROSCOPIC ADRENALECTOMY SAFE AND EFFECTIVE IN OBESE PATIENTS?

Y. Hou, C. Wang—China

**Background:** Recently laparoscopic surgery has been described as the “gold standard” for the management of many kinds of adrenal diseases. Obesity is an obstacle for this procedure and was initially considered as relative contraindication for laparoscopy. This study attempts to identify if retroperitoneal approach was safe and effective for such patients and try to define some technical tips for retroperitoneal laparoscopic approach adrenalectomy.

**Methods:** Between June 2003 and May 2009, 13 consecutive patients underwent retroperitoneal laparoscopic adrenalectomy (RLA) in one center by one surgeon. All the patients were obese (body mass index greater than 30). Peri-operative data were collected prospectively. Of all the patients, 4 cases were male and 9 cases female. The ages ranged from 14 to 46. All cases had received CT scan and the related laboratory examination before operation. 2 cases were diagnosed as primary aldosteronism, 3 cases pheochromocytoma, 6 cases cushing disease, 2 cases adenoma without function. The tumor sizes ranged from 1.0 cm to 6.5 cm in diameter. The duration of the procedure, intraoperative and postoperative complications, and length of stay were also collected. Three ports approaches were adopted. Tracheal cannula and general anaesthesia were performed in all patients and uninjured lateral decubitus position was adopted. The ports sites were described as follow: □ 2 cm under the inferior border of 12th rib along the posterior axillary line; □ 2 cm above the crest of ilium along the midaxillary line; □ 2 cm under the costal arch along the anterior axillary line. Retroperitoneal laparoscopic dissection and exposure was facilitated by a simple balloon-expanding device made of a rubber glove tied around a catheter. The specimen was placed into homemade specimen bag and removed through the extended incision along the posterior axillary line.

**Results:** The mean body mass index (BMI) was 32.6. All patients strictly met the criteria for surgery. The mean overall operative time was 48 minutes. The mean hospital stay was 44 hours. Peritoneum injury occurred in 2 patients. No other severe intraoperative or postoperative complications occurred.

**Conclusion:** RLA had many advantages such as little injury, little bleeding and short hospitalization. Although obesity might cause some difficulty, RLA was still a safe and effective method for many kind of adrenal diseases. These data and our experience support RLA as the technique of choice for adrenal diseases in the obese patients.

### VP22-14 THE LARGEST ONE CENTER LAPAROSCOPIC ADRENALECTOMY STUDY FROM TURKEY: TRANSPERITONEAL AND RETROPERITONEAL APPROACHES

M. Arslan, T. Degirmenci, B. Gunlusoy, S. Minareci, A. Ayder—Turkey

**Background:** In this study we report results of the transperitoneal and retroperitoneal laparoscopic adrenalectomy performed for adrenal mass.

**Methods:** We performed 32 laparoscopic adrenalectomy between March 2005 and April 2009. Of the 32 patients 15 were female and 17 were male. The mean age value was 52 (39–74) years. Eighteen patients had right and 14 had left adrenal masses. The mass size was an average of 5.8 cm (3–12). In transperitoneal approach 4-

ports (2 ports 5 mm, 1 port 10 mm, 1 port 12 mm) and in retroperitoneal approach 3-ports (2 ports 10 mm, 1 port 5 mm) were used. All of the specimens were taken out as a whole in endobags.

**Results:** The mean operation time of the transperitoneal and retroperitoneal adrenalectomy were 112 and 98 minutes, respectively. The mean blood loss in transperitoneal approach was 125 ml, and 90 ml for the retroperitoneal approach. Median hospital stay of transperitoneal and retroperitoneal adrenalectomy patients were 2.5 and 2 days, respectively. Only 4 patients were complicated (in 2 the avulsion of the adrenal vein from the vena cava, in 1 iatrogenic vena cava injury and in 1 splenic injury) and was laparoscopically mended. The average wound healing time was 8.4 days and wound infection was seen in 4 patients. The convalescent time was 16.8 days. The mean follow-up of the patients was 24.6 months (1–48).

**Conclusion:** When compared laparoscopic adrenalectomy approach has similar success rates with open surgery. Less hospital stay, better cosmetic results are the advantages of the laparoscopic approach. In our clinic, we prefer to remove masses bigger than 6 cm by tranperitoneal approach. By the help of increasing skills laparoscopic adrenalectomy is about to be the golden standart.

### VP22-15 THE FEASIBILITY OF LAPAROENDOSCOPIC SINGLE-SITE NEPHRECTOMY: INITIAL EXPERIENCE USING HOME-MADE SINGLE-PORT DEVICE

Y. Park, H. Jeon, W. Han, S. Yang, H. Jeong, H. Kim

**Background:** To report our early experience with laparoendoscopic single-site (LESS) nephrectomy using home-made single-port device for benign nonfunctioning kidney.

**Methods:** Fourteen patients with benign nonfunctioning kidney underwent transperitoneal LESS nephrectomy by two experienced laparoscopic surgeons. The indications for nephrectomy were nonfunctioning kidney associated with ectopic kidney (n = 2), UPJ obstruction (n = 5), genitourinary tuberculosis (n = 4), ureter stone (n = 2), and ureter stricture (n = 1).

**Results:** All procedures were completed successfully. The mean operative time was 151 (85–230) minutes, estimated blood loss 108 (negligible–500) ml, and postoperative hospital stay 3.1 (2–6) days. There were no major complications.

**Conclusion:** LESS nephrectomy is a feasible and safe surgical option for benign nonfunctioning kidney.

### VP22-16 URETERAL COMPLICATIONS IN RECIPIENTS FOLLOWING LIVING LAPAROSCOPIC DONOR NEPHRECTOMY: A FOCUS ON SURGICAL TECHNIQUE

J. Harper, A. Breda, A. Gritsch, J. Veale, J. Singer, P. Schulam

**Background:** Ureteral complications may cause significant patient morbidity. There has been previous debate whether preserving the gonadal vein with the specimen aids in prevention of ureteral strictures. The purpose of this study was to review all recipient ureteral complications in our series of living laparoscopic donor nephrectomies (LLDN) and focus on laparoscopic surgical technique.

**Methods:** A detailed prospective database documenting all complications, diagnoses, readmissions, procedures, and reoperations of renal transplant patients was reviewed. All living LLDN patients and their recipients from January 2000 through October 2008 were included. During laparoscopic dissection, the gonadal vein is divided near the renal vein junction and then rolled medial to the ureter. Ureteral dissection is performed sharply between the go-

nadal vein and ureter, leaving the vein in situ and then transecting the ureter at the level of the iliac vessels. Both the Lich-Gregoir and single-stitch (Shanfield) technique were employed for reimplantation during parts of this timeframe.

**Results:** There were 942 living donor nephrectomies: 757 laparoscopic and 185 open. There were thirteen ureteral complications (1.7%) in recipients from laparoscopic donors. Five patients developed a ureteral stricture (0.67%): four distal and one proximal, all less than 2 cm in length. Other complications included seven urine leaks, five of which occurred within the first week in patients without a stent. Finally, there was one ureteral iatrogenic injury during exploration for incarcerated bowel 2 years postoperatively. All underwent ureteral reimplantation.

**Conclusion:** Meticulous technique during procurement as well as reimplantation is essential to minimize complications. Preservation of the proximal ureteral tissue, periureteral blood supply, and avoidance of stripping the ureter is essential to avoid ureteral stricture formation. Removal of the gonadal vein does not result in ischemia of the ureter.

### VP22-17 CONTEMPORARY EXPERIENCE WITH LAPAROSCOPIC RADICAL NEPHRECTOMY FOR RENAL CORTICAL NEOPLASMS

M. Rothberg, K. Badani, M. Gupta, J. Mckiernan, J. Landman

**Background:** Previous reports have definitively established the capability of laparoscopic radical nephrectomy (LRN) to provide equivalent oncologic control to open radical nephrectomy (ORN). As technologies and technique continue to improve and laparoscopic single site surgical approaches emerge, it becomes increasingly important to establish a standard by which all radical renal extirpative procedures should be judged. As such, we evaluated our contemporary experience with LRN.

**Methods:** Between June 2005 and July 2009, 66 patients underwent LRN. Cytoreductive procedures were excluded from this analysis. Patient demographics, tumor characteristics, operative and recovery data were collected from a prospectively established, IRB approved database.

**Results:** The mean operative time was 138 minutes (range 77–240), mean estimated blood loss was 94 cc (range 5–600), and mean specimen size was 6.0 cm (range 1.6–18.0). The mean length of stay was 2.2 days (range 0.7–8.0), mean times to oral intake and ambulation were 19.7 hours (range 3–64) and 23 hours (range 8–64), respectively, and mean analgesic requirement was 35 mgSO<sub>4</sub> (range 6.7–92.5). Pathologic staging revealed 13 (21%) pT1a, 26 (42%) pT1b, seven (11%) pT2, nine (15%) pT3a, and seven (11%) pT3b renal cell tumors. Four (6%) intra-operative complications occurred in three patients, one (1.5%) conversion was performed, and four (6%) post-operative complications occurred.

**Conclusion:** Compared to published data, a vast majority of LRN outcomes metrics are consistent with or have been improved upon from previous reports. Novel access techniques for LRN must be compared to contemporary outcomes as the reference standard for minimally invasive radical extirpative treatment of renal cortical neoplasms.

### VP22-18 IS XL NONABSORBABLE POLYMER LIGATION CLIP FOR LAPAROSCOPIC RENAL VEIN CONTROL THE SAFER?

M. Arslan, E. Aksoy, S. Minareci, A. Ayder—Turkey

**Background:** In this study we evaluated XL polymer ligation clip (PLC) use for renal vein control in laparoscopic nephrectomy (LN). **Methods:** In between July 2007 and April 2009 we performed 110 LN. The arteries and veins were dissected and controlled one by one with nonabsorbable PLC (L/XL) or renal pedicle was controlled as a whole with endoGIA (30/45 mm) stapler.

**Results:** In 28 of 110 cases renal pedicle was controlled as a whole with endoGIA stapler. Of the remaining 82 cases, renal vein was controlled discrete from renal artery in 38 with PLC-L, and 44 with PLC-XL. Mean renal vein control time was 10 (3–24) minutes with PLC-L, and 6 (2–12) with PLC-XL. Control difficulty in 8 cases due to large renal vein, hemorrhage in 4 cases due to clip nail injury were evident in PLC-L controlled cases. Hemorrhage was controlled laparoscopically. Mean follow-up time of the patients was 8.2 (2–20) months, and no postoperative complication (arteriovenous fistula, visceral injury, hemorrhage) secondary to renal vein control was observed.

**Conclusion:** Renal vein control, particularly on the right side, is one of the most difficult steps in laparoscopic nephrectomy. Renal vein control with PLC-XL seems easier, more effective, faster and safer than with PLC-L.

### VP22-19 REGISTRATIONS FOR IMAGE-GUIDED MINIMALLY INVASIVE KIDNEY SURGERY

H. Altamar, R. Galloway, R. Ong, C. Glisson, S. Herrell—USA

**Background:** We examined the effects of the limited laparoscopic view of the kidney surface on registration. We determined the effect of perfusion and incision on kidney surface registrations in an animal model.

**Methods:** Point-based registrations, using either rigidly attached markers or anatomical landmarks as fiducials, served as initial alignments for surface-based registrations. Laser range scanner (LRS) obtained surfaces were registered to the phantom's image surface using a rigid iterative closest point algorithm. Subsets of each orientation's LRS surface were used to determine which parts of the surface yield the most accurate registrations. LRS surfaces were obtained on perfused and unperfused as well as incisional effect.

**Results:** 28% of the surface was needed for an accurate registration. Surface subsets that contain information from opposite sides of the kidney yield RMS errors below 1 mm while only containing 15% of the image surface. The mean, standard deviation, and maximum closest point distances between unperfused (5 mm Hg) and perfused (99 mm Hg) LRS surfaces were 2.6 mm, 0.54 mm, and 8.0 mm, respectively. Incision caused minimal change in surface registration except in the immediate area.

**Conclusion:** Our results suggest that obtaining accurate registrations is a function of the percentage of the total surface and of geometric surface properties, such as curvature. 28% is required. However, that percentage decreases using information from opposite ends and/or unique anatomical features, such as the ureter, renal artery and vein. Kidney perfusion significantly impacts surface registration accuracy, while incision by itself causes minimal change if overall position does not change.

### VP22-20 MULTICENTER COMPARISON OF INTERMEDIATE ONCOLOGIC OUTCOMES OF LAPAROSCOPIC PARTIAL NEPHRECTOMY AND RENAL CRYOABLATION

S. Stroup, J. Malcolm, J. L'esperance, R. Wake, M. Fabrizio, I. Derweesh



**Background:** The surgical paradigm for small renal masses has evolved towards less invasive nephron sparing intervention. While partial nephrectomy remains the gold standard for the management of most small renal masses, increasing experience with renal cryoablation has suggested a viable alternative with a favorable morbidity profile and good efficacy. We compare intermediate-term oncologic outcomes following laparoscopic partial nephrectomy (LPN) and renal cryoablation (RC) from a multi-center experience.

**Methods:** We performed a retrospective review of our LPN and RC experience between 9/1998 and 3/2008. Patients with at least 6 months follow-up were included in the analysis. LPN was performed via a transperitoneal approach. RC was performed via a percutaneous or transperitoneal laparoscopic approach. Follow-up consisted of imaging and laboratory studies at regular intervals. Persistent mass enhancement or interval tumor growth was considered a treatment failure following RC, and repeat biopsy and retreatment were recommended. Residual enhancing tumor was evidence of treatment failure following LPN.

**Results:** 119 patients (60% male, 39% black, mean BMI: 29.3) underwent RC with a mean follow-up of 29.5 months (range: 7–120). 123 patients (41% male, 34% black, mean BMI: 27.5) un-

derwent LPN with a mean follow-up of 23.8 months (range: 7.7–74.6). Average patient age was 58 for LPN and 68 for RC ( $p < 0.001$ ). Overall, co-morbid conditions were prevalent with 20% DM, 61% HTN, and 68% smoking history in the LPN cohort and 24% DM ( $p = 0.40$ ), 78% HTN ( $p < 0.05$ ), and 53% smoking history ( $p < 0.05$ ) in the RC cohort. Mean tumor size was 2.7 cm for LPN and 2.6 cm for RC ( $p = 0.84$ ). 70% of LPN specimens were RCC while 48% of RC were biopsy-confirmed RCC ( $p = 0.001$ ). 5 positive margins were reported in the LPN cohort. Local failures after primary RC were successfully salvaged with repeat RC in 8 patients. Disease free survival was 99% in the LPN cohort with only 1 local recurrence and no metastatic recurrences. Disease free survival in the RC cohort was 97% with 4 patients having evidence of disease at last follow-up ( $p = 0.19$ ). Overall survival was 96% and 97% in the LPN and RC cohorts, respectively ( $p = 0.71$ ).

**Conclusion:** Intermediate oncologic outcomes appear to be nearly equivalent in this multi-center study of well-matched LPN and RC cohorts. RC had higher primary treatment failure rates than LPN, but salvage retreatment afforded statistically equivalent overall cancer-free survival.

## VP23: ENDOSCOPY

### VP23-01 BIPOLAR TRANSURETHRAL RESECTION IN SALINE OF BLADDER CANCER: OUTCOME AND COMPLICATION RATES AFTER THE FIRST 480 CASES

P. Puppo, C. Introini, F. Germinale, F. Bertolotto, A. Naselli—Italy

**Background:** Bipolar TURB in physiological solution is an emerging technique which shows the same efficacy of monopolar resection. However there is currently little available data on the safety of bipolar devices. We assessed outcome and safety of bipolar TURB on a large cohort of patients with at least 6 months follow up.

**Methods:** Between January 2006 and October 2007, 480 consecutive TURB were performed. All procedures were carried out with a bipolar device in physiological saline (TURis®). The resectoscope used was an Olympus 26F in continuous flow type Iglesias with continuous aspiration. The loops were all disposable, single use. The incidence of unwanted stimulation of the obturator reflex, TUR syndrome, thermal skin lesion, blood transfusion, urethral strictures were recorded.

**Results:** None of the patients operated experienced a TUR syndrome or a thermal skin lesion. The median follow up of the entire cohort was 10 months, range 6 to 20 months. The median resection time was 27 min. A median of 3 mL of tissue was resected. The median drop in haemoglobin was 0.7 g/dL. The involuntary stimulation of the obturator nerve occurred overall in 6 patients out of 301 with a neoplastic lesion of the lateral wall (2%). Urethral strictures occurred in 12 patients (2.5%). 10 patients (2%) experienced postoperative clot retention. 4 patients (0.8%) required blood transfusions of up to two units of erythrocyte concentrate.

**Conclusion:** Bipolar TURB in saline solution offers the patient the same results as monopolar technology guaranteeing maximum safety without increasing the incidence of urethral strictures.

### VP23-02 THE EFFICACY OF PLASMAKINETIC ENERGY IN TRANSURETHRAL RESECTION OF BLADDER TUMOUR: THE MIDTERM REPORT OF SERIES

E. Huri, T. Akgül, S. Özcan, C. Germiyanoglu—Turkey

**Background:** Transurethral resection of bladder tumor is primary therapy of bladder tumor. We investigated efficacy of plasmakinetic energy during resection.

**Methods:** Thirty-one patients were included. Plasmakinetic GyruS® bipolar resection of bladder tumor was performed to each patient. Age, previous operation number, tumor number, size, shape, localization, grade, stage of tumor, pathologic artefact, operation time (min), hospitalization time (day), intra-postoperative complication, adductor contraction, converting to conventional method were recorded. Urethral stricture and persistent hematuria were evaluated.

**Results:** Mean age was 63.9. Mean previous operation and tumor numbers were 1.8, 1.9. Mean tumor size was 2.1 cm. Tumor shape was papillary in 20, solid in 10 and solid-papillary in 1 patients. Localizations were generally around left or right sided of bladder wall. Grade was in 18 low, 7 high while in 1 papilloma, 3 cystitis, 1 cystitis cystica, 1 adenocancer. Stage was in 13 patients Ta, 9 T1, 3 T2. Pathologic artefact was found in only 1 patient. Mean operation time was 38.3 min. Hospitalization time was 3.4 days. Adductor contraction was observed in 7 (22.5%), tumor located at left bladder wall in all, while in 2, technique converted to conventional method. Complication, blood transfusion, urethral stricture and persistent hematuria were not confirmed.

**Conclusion:** Plasmakinetic resection of bladder tumor provides comfort during operation with short operation time, hospital stay, no pathologic destruction and minimal bleeding. Although significant adductor contraction has been demonstrated, it should not

be a reason to convert the surgery to conventional monopolar resection technique.

### VP23-03 ENDOSCOPIC MANAGEMENT OF UPPER-TRACT TRANSITIONAL-CELL CARCINOMA

S. Martin Martin, J. Torrecilla Garcia-ripoll, F. Trueba Arguiñarena, R. Calvo Gonzalez, E. Valsero Herguedas, E. Fernandez del busto

**Background:** We report an evaluation of the outcome of endoscopic management of upper-tract transitional-cell carcinoma (TCC), its effectiveness and complications.

**Methods:** From 1994 to 2009, 12 patients (mean age 72 years; range 57–82; males 10; females 2) with upper-tract TCC were treated by endoscopic approach as primary management: 9 (75%) by percutaneous techniques with intravesical instillation after Double-J stent and 3 (25%) by ureteroscopy. All of them were treated with electrocautery fulguration and they had Double-J stent for 2 months. Follow-up was between 23 and 146 months (mean 68 months). Most of the patients, 10 (83.4%), had a normal contralateral kidney, and the indication for conservative management was low tumor size (<2 cm) and patient commitment to a rigorous follow-up protocol.

**Results:** The majority of tumors were of pathologic low grade 75%, 2 were high grade and there were insufficient pathological specimen in 2 cases. Of the 12 patients, 2 (16.6%) had local recurrence, both high grade. A nephroureterectomy was realized in a patient with local recurrence and it was not possible on the other one consequent upon significant medical comorbidities. Both patients developed lung metastasis 3 and 4 years later. 2 patients developed recurrence in the bladder and 1 had synchronous affectation. The median time from diagnosis to the first bladder recurrence was 20 months. There were 2 complications: a ureteric stricture treated with a self-expanding nitinol stent covered with expanded polytetrafluoroethylene and a nephrocolic fistula managed by withdrawing the nephrostomy tube from the renal pelvis, bowel rest, total parenteral nutrition and antibiotic coverage. At last follow-up 6 patients had died, including 2 (16.6%) of transitional cell carcinoma of transitional cell carcinoma.

**Conclusion:** Tumor grade appeared to be the most important prognostic indicator in patients with renal TCC regardless of the surgical approach. Conservative treatment is preferred in patients with bilateral disease, a solitary kidney, or co-morbidities that contraindicate major surgery. Patients with low-grade, low-stage disease and normal contralateral kidneys also benefit.

### VP23-04 TIPS FOR INTRACORPOREAL PLACEMENT OF URETERAL STENTS

J. Marshall, A. Cardin, H. Rashid, G. Wu

**Background:** Placement of ureteral stents is common practice during urologic ureteral procedures. With minimally invasive surgeries, this can be difficult depending on the type of case and when the stent is placed. Here we present some simple and reliable to aid in expeditious deployment of ureteral stents during robotic ureteral surgery.

**Methods:** Surgeries were divided into three general areas of ureteral surgery: anastomosis of a tube to a hollow structure (pyeloplasty and ureteral reimplant), anastomosis of a tube to another tube (uretero-ureterostomy), and ureteral-ileal anastomoses.

**Results:** For pyeloplasty or reimplant, double J ureteral stents were used. A glide wire was placed through the stent with 4 cm of wire coming out the end of the stent. And fed through a 5 mm or 12 mm port using a laparoscopic instrument. The wire is guided into the ureter (after completing the posterior anastomosis) and passed down to the bladder (pyeloplasty) or up to the kidney (ureteral reimplant). The wire is removed and the proximal curl is fed into the hollow organ under vision before the anastomosis is completed. For anastomosis of two tubes the stent is prepared and passed up to the kidney as above. The wire is then fed through the pusher into a side-hole of the stent and passed down to the bladder end of the stent. The stent is then passed down the ureter to the bladder. When the stent is entirely in place the wire is carefully removed leaving the ureter stented. The anastomosis is then completed. For ureteral-ileal anastomoses we disconnect the metal laparoscopic suction tip and advance the suction tip into the ileal segment. The suction is passed through the enterotomy and the single-J stent (wire in place) is passed through the suction. The metal sucker is removed and the stent is then passed up to the kidney. The anastomosis is completed.

**Conclusion:** We present our tips on deployment of ureteral stents for 3 general areas of ureteral surgery. We have found these techniques to be quick and relatively simple for the assistant to learn while providing an efficient way to reliably place ureteral stents.

### VP23-05 ENDOPYELOTOMY: A PROSPECTIVE ANALYSIS OF LONG TERM EFFICACY

V. Ramakrishnan, J. Murugesan, S. Rammamurthy, A. Ganapathy, K. Kailasam

**Background:** Role of Endopyelotomy has been redefined in recent years. We prospectively analysed the long term efficacy (>3 years) of providing drainage to the obstructed Ureteropelvic Junction (UPJ).

**Methods:** From January 2001 to December 2005, 33 patients with UPJ obstruction underwent Antegrade Endopyelotomy. They were prospectively followed till May 2009. Patients were selected for Endopyelotomy after Ultrasound, Excretory Urography and TcDTPA scan with Diuretic Renogram. There were 23 males and 10 females; all patients underwent Percutaneous Antegrade Endopyelotomy. The strictured UPJ was incised with semi circular cold knife (twin rail technique) and stented with Internal Endopyelotomy stent (14/7 Fr or 12/6 Fr). Stents were removed after 4 weeks. Follow up was done with Diuretic Renography at 6 months and yearly thereafter.

**Results:** All patients were adults (18 to 60 Years) Concomitant PCNL was done in 18 for stone disease (54.5%). 4 patients had previous pyeloplasty; one had a solitary kidney. Post-up complications were fever (6), bleeding (3). The follow up ranged from 39 months to 101 months. (average 72.4 months). Immediate failure was noted in 2 patients—1 was restented; the other required Nephrectomy for Pyonephrosis. The restented patient who underwent Pyeloplasty had crossing vessels. Endopyelotomy was repeated in 1 patient after 3½ years. Overall 6/33 (18%) had poor drainage during followup—3 were reoperated and 3 are on followup with reduced function.

**Conclusion:** This prospective study indicates that Antegrade Endopyelotomy has a successful outcome with optimum pre-operative selection. Cosmesis, reduced analgesia and quick return to normal routine are obvious advantages.

### VP23-06 BALLOON DILATATION OF URETHRAL STRICTURES VIA FLEXIBLE CYSTOSCOPES

G. Watson, R. Ali—UK

**Background:** 20 patients with bulbar strictures were managed by balloon dilatation of the stricture followed by intermittent self-dilatation using disposable hydrogel-coated catheters.

**Methods:** The balloon dilatation was performed under vision using a flexible cystoscope with intraurethral lignocaine anaesthesia only. The balloon was a 6F Stirling coronary artery balloon. The balloon dilatation itself was not painful but patients did react as usual to guidewires being passed or the cystoscope being passed through into the bladder. It was therefore equivalent to a flexible cystoscopy.

**Results:** In all 20 cases the flow rate improved dramatically. It was not necessary to pass a urethral catheter following the procedure. Patients were encouraged to self catheterise 24 hours later in order to keep the stricture patent.

**Conclusion:** The procedure does not disrupt the urethra and therefore does not seem to lengthen the stricture in contrast to optical urethrotomy. Unlike dilatation with bougies there is no tendency to create false passages. It is truly “office based” and can be performed under local anaesthesia.

### VP23-07 LOCALIZED PRIMARY AMYLOIDOSIS OF THE LOWER URINARY TRACT

A. Mathew, A. Kurien, R. Sabnis, M. Desai

**Background:** Amyloidosis is a heterogeneous group of diseases characterized by the deposition of amyloid protein in various organs. Several types of amyloidosis exist and are classified on the basis of the protein deposited. Amyloidosis can also be classified as localized when only one organ is involved or systemic when it involves multiple sites. Kidneys are frequently involved in all forms of systemic amyloidosis. However, primary localized amyloidosis of the lower urinary tract is a rare condition.

**Methods:** We evaluated a 60 years old man with right flank pain and lower urinary tract symptoms. Radiological evaluation revealed right hydronephrosis with the ureter dilated upto the ureterovesical junction. The patient underwent cystoscopy with punch biopsies taken from yellowish plaque like lesions in the urethra and right ureteric orifice.

**Results:** Both biopsies showed a normal urothelium with acellular eosinophilic amorphous material in the sub mucosa which gave an apple green birefringence under polarized light on Congo Red stain. It maintained staining characteristics even after Potassium-permanganate pretreatment, suggesting a primary amyloidosis. In view of proteinuria, renal biopsy was performed which revealed diabetic nephropathy. Serum and urinary electrophoresis showed non specific changes. A diagnosis of primary localized amyloidosis of the lower urinary tract was made.

**Conclusion:** Primary localized amyloidosis of the urinary tract is a rare condition. It may be confused with a malignancy in its presentation as well as cystoscopic appearance. A histopathological evaluation is required for a definitive diagnosis.

### VP23-08 ANTEGRAD BALLOON DILATATION IN THE TREATMENT OF URETEROVESICAL STENOSIS IN PATIENT WITH PREVIOUSLY UNDERGONE URETEROCUTANEOSTOMY AND URETERAL STENOSIS DUE TO UNSPECIFIED ETIOLOGIES

L. Tahmaz, M. Zor, S. Bedir, S. Basal, I. Karabuga, M. Dayanc

**Background:** To assess the usefulness of antegrad balloon dilatation as a starting treatment technique of ureteral and ureterovesical stenosis.

**Methods:** 2 patients with ureteral stenosis, one patient with ureterovesical stenosis and 2 patients with ureterocutaneous stoma strictures were treated with antegrad balloon dilatation between January 2007 and June 2009.

**Results:** Except the one patient with ureterovesical stenosis all cases were adult and the mean patient age was 48 years old. The patient with ureterovesical stenosis was an 8 years old boy. He was underwent augmentation cystoplasty and ureteroneocystostomy for the treatment of decreased bladder capacity. He presented with ureterohydronephrosis in the 6 month of the treatment. We performed antegrad balloon dilatation and ureteral stent implantation. In two patients with ureteral strictures antegrade balloon dilation and ureteral stenting was achieved in one patient. In the remaining patient, the procedure was aborted due to the failure in passing a guidewire through the stenotic lesion. In the last two patients with ureterocutaneous stoma stenosis, balloon dilatation of the stomal stricture and ureteral stent implantation was successfully performed. In the follow-up one patient with ureterocutaneous stricture required open ureterocutaneous revision. The remaining 4 patients showed improvements both in contrast media excretion and in prestenotic dilatation in their 3—16 months follow-up period.

**Conclusion:** Antegrade balloon dilation of the urinary tract combined with ureteral stenting is a minimal invasive and effective technique for the management of urinary stenosis. It can be considered used as a first line treatment in such conditions.

### VP23-09 SAFE RESECTION OF BLADDER TUMORS WITH PLASMA KINETIC ENERGY

I. Yildirim, S. Basal, H. Irkilata, M. Zor, S. Goktas, M. Dayanc

**Background:** Obturator nerve reflex (ONR) is a frequent complication of the transurethral resection of bladder tumors (TURBT), especially those localized at the lateral walls of bladder. The transurethral operation is often interrupted, or changed into a transabdominal one, because of the risk of bladder perforation or severe bleeding. The purpose of this study was to compare the bipolar Plasma Kinetic (PK) energy and conventional monopolar energy in the terms of ONR and bladder perforation, in-transurethral bladder tumor resections.

**Methods:** Thirty patients who undergone TURBT for bladder lateral wall tumor, between September 2005 and December 2007, were included in the study. TURBT was performed with monopolar energy and bipolar PK energy in the first and second groups (each were 15 cases), respectively. Maximum tumor size and number, active ONR, number of minor and major (needs open bladder repair) bladder perforations and hospitalization periods were noted.

**Results:** The mean age was 60 (48–72) years in the first group, and 62 (45–73) years in the second group. In the first group, 6 minor and 1 major ONR related bladder perforations were seen. No complications occurred in the second group. No infection occurred and no blood transfusion was required in any of the groups. The number of minor perforations and hospitalization periods were also compared between the groups and statistically significant differences were noticed.

**Conclusion:** Bipolar resection of bladder tumors located on lateral walls using Plasma Kinetic energy system is safer than conven-

tional monopolar energy in preventing ONR related bladder perforations.

### VP23-10 THE EFFICACY AND SAFETY OF THE BART'S MODIFIED VALDIVIA POSITION FOR SIMULTANEOUS ANTEROGRADE AND RETROGRADE URINARY TRACT ACCESS

K. Moraitis, Z. Maan, T. El-husseiny, A. Papatsoris, J. Masood, N. Buchholz

**Background:** We present the results of our experience with the Bart's modified valdivia position for achieving simultaneous anterograde and retrograde access in complex upper urinary tract pathology.

**Methods:** 22 patients were placed in the lithotomy with the pelvis tilted at 45° supported by a foam wedge, while the torso was twisted to the contra-lateral side with the shoulders perpendicular to the operating table. The leg of the operated side is flexed and adducted following the lateral rotation of the trunk, the contra-lateral leg remains fully abducted. 12 patients had PUJ obstruction with impacted stones. 3 patients had upper ureteric strictures and three had impacted upper ureteric stones with stricture below. 1 patient had an upper ureteric stone, 2 patients had encrusted JJ stents and one patient with a solitary kidney had a distal stone in a ureter re-implanted into a neobladder.

**Results:** All patients undergoing endopyelotomy and stone extraction were rendered stone-free with relief of obstruction in 83% of cases. We achieved successful recanalisation of all ureteric strictures. The ureteric stone clearance rate has been 100%. One of two patients (the other requiring adjuvant ESWL) with heavily encrusted JJ stent and the patient with a solitary kidney were rendered stone free. No complications were experienced.

**Conclusion:** Our modification to the Valdivia position is safe, time-saving and effective. It allows two surgeons to work simultaneously with better respiratory and cardiovascular function in high risk patients due to the more lateral positioning. It also allows more flexibility for renal access when compared to the Valdivia position.

### VP23-11 BLADDER SPHINCTER VERGE URETHRAL PRESSURE AND IMPACT ON PAIN SCORES IN MEN UNDERGOING FLEXIBLE CYSTOSCOPY

S. Kommu, A. Golash, C. Luscombe, S. Liu, M. Saxby, J. Emtage—United Kingdom

**Background:** Flexible cystoscopy (FC) is the most common endourological procedure and its role is established as a valuable tool for the investigation and treatment of urethral and bladder conditions. The procedure is however noted to be associated with discomfort and, in some instances, significant pain for the patient. In a bid to alleviate pain and discomfort during FC, various concoctions of analgesics and lubricants with varying protocols have been proposed but despite this a considerable number of patients still complain during and/or after the procedure. In a previous study to stratify which patients are likely to have significant pain scores, we found that the quadrad of male gender, LUTS, a (PERP/AV) ratio of <1.0 and first FC renders the highest pain scores at FC. Females who have repeat check cystoscopy for bladder tumours and who have a (PERP/AV) ratio of >1.0 has the least pain scores [Kommu et al. *Journal of Endourology*. 2006: A97–A298]. In a previous study, we found that majority of discomfort and/or pain in males occurs immediately prior to the cystoscope entering the Bladder

Sphincter Verge. The pain is sustained till the scope enters the bladder. When the bladder sphincter verge and the prostatic fossa are kept patent by hydrostatic pressure, pain scores seemed minimal. Herein, we aimed to study the application of Bladder Sphincter Verge Urethral Pressure (BSVUP) for potentially reducing pain scores in high risk for pain strata i.e. males with LUTS undergoing first time flexible cystoscopy. [Per Procedural Score–PERP; After Void–AV; Lower Urinary Tract Symptoms–LUTS]

**Methods:** Males with LUTS undergoing first time FC were prospectively studied. All patients were given a single shot of Instillagel® (prefilled syringe containing lignocaine 2% and chlorhexidine 0.25% in a sterile lubricant gel). The fluid irrigation bag was maintained at a standard height and assistants were asked to apply pressure to the bag such that the surgeon performing the FC would notice the hydrostatic effect at the sphincter verge and across the prostatic fossa. Immediately upon entry into the bladder the surgeon asked the patient regarding the pain score. Pain scores were recorded during the procedure on a scale of 0 to 10 with zero being no pain and 10 being unbearable pain. The results were tallied. A total of 100 patients were studied. Fifty patients had no BSVUP and fifty had BSVUP.

**Results:** The mean pain score among patients who had BSVUP was 2 (range: 2–8) compared with 4 (range: 3–10) for those who had no BSVUP. Four patients in the in the Non-BSVUP arm found the procedure unbearable and the procedure had to be abandoned requiring a further general anaesthetic cystoscopy. There was no correlation between age or ASA grade and pain scores in the two groups.

**Conclusion:** The application of Bladder Sphincter Verge Urethral Pressure by squeezing the irrigation bag during flexible cystoscopy in high risk for pain men (i.e. males with LUTS undergoing first time flexible cystoscopy) leads to a significant reduction of pain scores during FC. The technique potentially halves the pain scores. This is a simple readily applicable technique with no additional morbidity to the patient and at no additional cost.

### VP23-12 FLEXIBLE CYSTOSCOPIC AIDED MINIBALLOON TISSUE DISSECTION–PRELIMINARY EXPERIENCE IN EX VIVO SETTING USING A LAPAROENDOSCOPIC SINGLE-SITE SURGERY (LESS) PLATFORM

S. Kommu, I. Lewis, A. Forde, I. Persad, C. Ramjit, S. (sarg)—United Kingdom

**Background:** The new paradigm of minimal access minimally invasive urological surgery, which incorporates the consensus term of Laparoendoscopic Single-Site Surgery (LESS), has recently been successfully utilised in the performance of several urological procedures. Despite the steady uptake of LESS in urology, there are inherent shortcomings, which include the narrow focus for target tasking, the difficulty of achieving triangulation and real-time avoidance of instrument collision while maintaining a satisfactory view. Tissue dissection and manipulation is more challenging through the current multichannel ports used for LESS. Herein we describe the use of a flexible cystoscope equipped with a miniballoon and test its use for tissue dissection through a multichannel port in the ex vivo setting in a LESS platform.

**Methods:** A LESS platform consisting of a box model (DIY-LTK™) was fitted with an R-Port™ and flexible cystoscope was developed as previously described [Kommu et al. *Journal of Endourology*. November 2008: 1–340]. Autonomy™ Laparo-Angle™ Instruments from Cambridge Endo were used for this

module. A supermarket chicken (thawed once bought from the supermarket shelf) was placed in the box such that the R-Port™ directly entered the subcutaneous plane. The target task was to dissect the entire skin off the supermarket chicken using the port in six exercises by three surgeons. The same task was set using articulating instruments in a similar fashion.

**Results:** The flexible cystoscope was deployed via one of the channels in the R-Port™ and the entire skin of the chicken stripped with the use of the miniballoon that could be inflated and deflated in rapid sequence. The task was successfully completed with relative ease in six exercises by three separate surgeons. Tissue planar dissection via the multichannel port was easier and quicker to perform compared to tissue plane dissection using articulating instruments via the same ports.

**Conclusion:** Flexible Cystoscope Aided Miniballoon Tissue Dissection in the Laparoendoscopic Single-Site Surgery (LESS) platform can be performed with relative ease and in a shorter time frame than with articulating instruments. The technique could potentially act as a useful supplementary tool for tissue planar dissection during LESS in procedures such as radical prostatectomy, nephrectomy and pyeloplasty. The role of this technique should be explored further.

### VP23-13 ENDOUROLOGIC MANAGEMENT OF SEVERELY ENCRUSTED RETAINED URETERAL STENTS

K. Skrepetis, G. Stathouros, I. Efthimiou, E. Trimis, I. Gialas

**Background:** Retained encrusted ureteral stents associated with a stone burden are a difficult and challenging problem for urologists. We report our experience with endourologic management of this severe complication.

**Methods:** The inclusion criterion was a ureteral stent that required some form of intervention to remove it. From October 2006 to May 2009, 12 patients (8 females and 4 males) aged 39 to 76 years (mean 52 years) with severely encrusted retained ureteral stents were treated by endourologic techniques. The average time the stent had been in place was 9.5 months (range 4–26 months). All patients were accessed for stent burden by plain KUB, ultrasonography and intravenous urography. Planning therapy were based on the clinical presentation and imaging findings.

**Results:** The patients required an average of 1.4 endourologic procedures (range 1–2) performed at one session to remove the stent and the associated stone burden. Retrograde ureteroscopy with intracorporeal lithotripsy was performed in nine cases with a large associated stone burden. Cystolitholaxly was required to treat the distal component of stent encrustation in 4 cases. Three ureteral stents with a minimal encrustations were managed with extracorporeal shockwave lithotripsy. All stents and the associated stones were removed without any intraoperative complications. Postoperatively, a patient developed urosepsis that necessitated a prolonged stay in intensive care unit.

**Conclusion:** Encrustation and retention of a ureteral stent is one of the most serious complications. Successful management of encrusted retained ureteral stents requires careful planning, also can involve a combination of endourologic approaches. However, our experience suggests that even extensively encrusted stents can be managed successfully with retrograde ureteroscopy in one session. From the other hand we can avoid the need for more invasive techniques.

## VP24: PEDIATRICS

### VP24-01 RETROGRADE URETERAL ACCESS AFTER CROSS-TRIGONAL URETERAL REIMPLANTATION: A STRAIGHTFORWARD TECHNIQUE

J. Palmer, K. Hubert, R. De castro—USA

**Background:** Retrograde ureteral access after cross-trigonal ureteral reimplantation can be challenging. We present our experience with percutaneous retrograde ureteral catheterization in children status post cross-trigonal ureteral reimplantation.

**Methods:** We evaluated all patients who underwent attempted percutaneous retrograde ureteral catheterization after cross-trigonal ureteral reimplantation. All clinical data, radiographic images and operative reports were reviewed. Ureteral access was obtained by first percutaneously entering the bladder with an intravenous needle/catheter under cystoscopic guidance. The needle was then removed leaving the catheter in place. The ureteral orifice was then accessed through the intravenous catheter by a ureteral access wire and/or ureteral catheter under cystoscopic guidance.

**Results:** From 1978 to 2008, 13 patients (11 boys and 2 girls) with a history of cross-trigonal ureteral reimplantation underwent percutaneous retrograde ureteral catheterization. The procedure was unilateral in twelve patients and bilateral in one. The mean age at

the time of percutaneous retrograde ureteral catheterization was 6 years (range: 6 months to 20 years). Indications for the procedure included: Retrograde pyelography and double-J stent insertion for ureteropelvic junction or ureterovesical junction obstruction (10); removal of dislocated stent (2); and treatment of a ureteral stone (1). The procedure was performed successfully in all patients. There were no complications occurred.

**Conclusion:** Percutaneous retrograde ureteral catheterization is a safe, straightforward, and effective modality for obtaining retrograde ureteral access in children status post cross-trigonal ureteral reimplantation.

### VP24-02 GIANT URETERAL FIBROEPITHELIAL POLYP CAUSING BLADDER OUTLET OBSTRUCTION

A. Chawla, P. Noh

**Background:** Fibroepithelial polyps of the ureter are rare and most often found in adults. Hematuria and flank pain are the most common presenting symptoms. Historically, open surgery has been the treatment of choice. At present, the majority are excised via endourologic intervention. We present a case of a 15 year old female with a giant ureteral fibroepithelial polyp causing inter-

mittent bladder outlet obstruction. She presented with lower urinary tract symptoms, including hesitancy, intermittency, and incomplete emptying.

**Methods:** Ultrasound demonstrated a lesion in the bladder. Cystourethroscopy and retrograde pyelogram revealed a large polyp emanating from the right ureteral orifice with filling defect to the middle ureter. Ureterscopy was performed. The Holmium laser was used to completely excise the polyp. An indwelling ureteral stent was left in place.

**Results:** There were no intraoperative or postoperative complications. The ureteral stent was removed one week postoperatively. A retrograde pyelogram revealed no filling defect. The pathology specimen was consistent with fibroepithelial polyp.

**Conclusion:** Fibroepithelial polyps are rare in the pediatric population. To our knowledge, this is the first report of a ureteral polyp causing bladder outlet obstruction. Endoscopic excision of extremely large fibroepithelial polyps is safe and effective.

### VP24-03 THE VALIDITY OF THE PRACTICAL APPLICATION OF U-LESS (UMBILICAL LAPARO-ENDOSCOPIC SINGLE PORT SURGERY) VARICOCECTOMY FOR PATIENTS WHO HAVE BILATERAL VARICOCELE

S. Park, J. Nam, T. Kim, W. Lee, H. Park

**Background:** We determined the validity of the practical application of U-LESS (Umbilical Laparo-endoscopic Single Port Surgery) bilateral varicocelectomy based on a comparative study between U-LESS and open bilateral varicocelectomy.

**Methods:** We included the 30 consecutive patients who underwent bilateral varicocelectomy. Each 15 patients undergo U-LESS and inguinal approach with two incision bilateral varicocelectomy by two surgeons. Operative time, postoperative satisfaction, operation related pain (10 point—visual analogue pain scale) and catch-up growth of testis, internal spermatic vein diameter, semen parameter and complications after surgery were prospectively examined. An improvised single port system composed of surgical glove, standard laparoscopic ports and Alexis<sup>®</sup> OTM wound retractor [Applied Medical, CA, USA] were used. Using a curved laparoscopic grasper and scissors, an incision was made on the peritoneum on the side of the testicular artery and veins, proximal to the vas deferens following the transaction of the vessels leaving clips both proximally and distally.

**Results:** The mean age was 21.6 years (13~42) and 19.1 years (11~35) in the LESS group and the open surgery group, respectively. The operative times were 43 minutes and 65 minutes ( $p < 0.05$ ) in the LESS group and the open surgery group, respectively. Postoperative satisfaction and pain were more favorable in the LESS group ( $p < 0.05$ ). Only 1 patient in the LESS group experienced wound dehiscence. However, there was no differences in other clinical parameters between the two groups.

**Conclusion:** Bilateral Varicocelectomy using U-LESS needed shorter operative time than a open varicocelectomy. In addition, it resulted in higher patient satisfaction, less postoperative pain and cosmetic benefit. The practical application of U-LESS varicocelectomy for patients who have bilateral varicocele is feasible and promising.

### VP24-04 TRANSUMBILICAL LAPAROENDOSCOPIC SINGLE-SITE NEPHROURETERECTOMY IN A CHILD

Y. Bayazit, I. Aridogan, D. Abat, N. Satar, S. Doran

**Background:** Transumbilical laparoendoscopic single-site surgery (LESS), is one of the newest innovations in the era of laparoscopy. In this report, it has been aimed to present a case of LESS nephroureterectomy (NUx) in a child.

**Methods:** A ten-year-old girl underwent left nephroureterectomy by LESS due to end-stage reflux nephropathy on December 25, 2008. The surgery is performed transperitoneally, through a 2 cm semicircular incision in the left inner curve of the umbilicus by using three 5 mm trocars. NUx with LESS was performed duplicating standard laparoscopic steps with the help of flexible and straight laparoscopic instruments.

**Results:** Operation time was 140 minutes and the blood loss was minimal. There was no intraoperative or postoperative complication. The patient was discharged on the 24th postoperative hour and under follow-up for six months. The postoperative cosmetic result was excellent since the incision scar was hidden inside the belly button.

**Conclusion:** NUx with LESS is a feasible technique with the advantages of less pain, shortened convalescence, improved cosmesis and absence of wound complications in children. However, clear indications of LESS in children remains to be clarified.

### VP24-05 LONG TERM RESULTS OF ENDOSCOPIC SUBURETERAL INJECTION FOR THE TREATMENT OF VESICoureTERAL REFLUX IN CHILDREN—POLYDIMETHYLSILOXAN VS DEXTRANOMER/HYALURONIC ACID COPOLYMER

A. Lusch, F. Wezel, W. Shah, M. Riccabona, M. Michel

**Background:** Endoscopic management of vesicoureteral reflux in children is an accepted alternative to open ureteral reimplantation for treatment of pediatric vesicoureteral reflux. In a retrospective analysis we have evaluated our experience of subureteral injection of Polydimethylsiloxan (Makroplastique) and dextranomer/hyaluronic Acid copolymer (Deflux) in children for vesicoureteral reflux.

**Methods:** During January 2000 and December 2006 119 children, with an average age of 59,6 month, with 181 refluxing ureters underwent endoscopic treatment. 98 children were treated with dextranomer/hyaluronic acid copolymer (Deflux) and 21 children with Polydimethylsiloxan (Makroplastique). Postoperative voiding cystogram and ultrasound was performed after 3 month. The follow up time was from 6 to 48 month. Indication for endoscopic management were breakthrough urinary tract infections, high grade reflux and non resolution reflux.

**Results:** Vesicoureteral reflux was grade IV in 10 (5.5%), III in 58 (32.1%), II in 86 (47.5%) and I in 27 (14,9%) ureter. Overall reflux was corrected in 75.2% of the cases, 24.8% showed a persistent reflux after single injection. A repeat injection was performed in 9 patients with 12 refluxive units with a success rate of 78%. Correction grade after 1 injection in the deflux group was 74%, 73%, 62%, 50% for grade I–IV (overall 64.7%) and in the makroplastique group 100%, 71%, 100%, 50% for grade I–IV (overall 80.25%). There were no surgical complications. 5 children developed a de novo reflux contralateral (4%). 29 (24%) children required surgical reimplantation for failed endoscopic treatment. Results 1 year post operation: Deflux group—70.4%, Makroplastique group 78.8%. Results 3 years post injection: Deflux group—68.8%, Makroplastique group—74.2%. Ultrasound detection of depot was 90% sensitive and 80% specific for correction of reflux.

**Conclusion:** Substrial injection of Polydimethylsiloxan (Makroplastique) and dextranomer/hyaluronic Acid (Deflux) is a safe and effective treatment for vesicoureteral reflux. The operation can be performed as an outpatient visit with a short hospital stay for 4–5 h. In our patient group polydimethylsiloxan shows better results for reflux grade I and III. The presence of bulking agents can be accurately documented by postoperative ultrasound and there is a correlation between depot visibility and correction grade.

#### VP24-06 URETEROSCOPY AND PNEUMATIC LITHOTRIPSY IN TREATMENT OF URETERAL CALCULI IN CHILDREN

M. Tan, U. Karaoglan, S. Sozen, H. Biri, N. Deniz, I. Bozkirli—Turkey

**Background:** Despite the advent of small-sized ureteroscopes, laser technology and growing experience the safety of ureteroscopy in paediatric age group has not been fully established. A retrospective analysis was done to determine the efficacy of ureteroscopy and pneumatic lithotripsy in treatment of paediatric ureteral calculi.

**Methods:** We reviewed the records of 23 (15 boys, 8 girls) children (25 ureters) admitted to our clinic for treatment of ureteral calculi during and subjected ureteroscopy and pneumatic lithotripsy between 1996–2008. All children had lower ureteral calculi except 1 (4%) upper ureteral stone. Ureteroscopy was the initial treatment in 15 patients (16 ureters) while the others were extracorporeal shock wave lithotripsy (ESWL) failures. The indications for ureteroscopy were high stone burden, failure of ESWL, significant obstruction and/or acutely symptomatic patient and urgent treatment request for children referred from urban area. For pneumatic lithotripsy Swiss Lithoclast device was used.

**Results:** The mean age of the patients was  $10.1 \pm 4.4$  (1–16) years. The mean stone diameter and burden were  $5.65 \pm 1.6$  (4–10) mm and  $60.48 \pm 32.6$  (25–128) mm<sup>2</sup> respectively. The stone-free rate was 92%. There were 2 (8%) treatment failures. One was the patient with upper ureteral calculi who had some fragments pushed back to the kidney and later treated with ESWL to become stone-free. The mean follow up period was  $13.2 \pm 14$  (1–53) months. There were no complications related to ureteroscopy, reflux was not assessed.

**Conclusion:** Ureteroscopy-pneumatic lithotripsy is a safe and effective method for treatment of lower ureteral calculi in children.

#### VP24-07 TRANSUMBILICAL LAPAROENDOSCOPIC SINGLE-SITE (LESS) NEPHRECTOMY IN A CHILD WITH CALCULOUS PYONEPHROSIS

Y. Bayazit, I. Aridogan, D. Abat, O. Karsli, N. Satar, S. Doran

**Background:** Recently, it has been shown that laparoendoscopic single-site surgery (LESS) can be used in pediatric cases. However, until now a case of nephrectomy (Nx) for pyonephrosis with LESS has not been reported. Initial case of LESS Nx performed on a child with calculous pyonephrosis is presented.

**Methods:** A ten-year-old girl with non functioning pyonephrotic kidney with stones underwent right Nx by LESS. The surgery is performed transperitoneally, through a 2 cm semicircular incision in the left inner curve of the umbilicus by using three 5 mm trocars. Nephrectomy with LESS was performed duplicating standard laparoscopic steps with the help of flexible and straight laparoscopic instruments. Since a meticulous hemostasis was done, no drain was inserted after the operation.

**Results:** Operation time was 180 minutes and estimated blood loss was 600 mL. A pack of red blood cells was transfused. There was no intraoperative or postoperative complication except intraoperative bleeding. Urethral catheter was removed on the fifth, patient was mobilized on the 17th and oral intake was started on the 18th postoperative hour. The patient was discharged on the second postoperative day. The postoperative cosmetic result was satisfying since the incision scar was hidden inside the belly button.

**Conclusion:** LESS Nx in pyonephrotic kidneys is a feasible technique in children and should be performed with a meticulous dissection in experienced centers and on selected cases in order to prevent important complications like hemorrhage, neighboring organ damage since it is not easier than the standard technique.

#### VP24-08 LAPAROSCOPIC DIAGNOSIS AND TREATMENT OF CRYPTORCHIDISM

M. Baptistussi, M. Morihisa, E. Gewher, A. Martins—Brasil

**Background:** We present our experience in diagnosing and treating non palpable testis by using laparoscopic Surgical techniques, 16 patients have been operated on using these procedures in the urology department of Sao Paulo Hospital, since April 2003 and March 2008. The mean age was 08 years (4–15 years).

**Methods:** - three patients had bilateral intra-abdominal undescended testis. - 6 patients had intra-abdominal undescended testis in the left side and 7 on the right side.

**Results:** Ultrasonography examination was done to all patients before surgery and 6 about 15 was done diagnostic non palpable testis, the treatment was orchidectomy in 2 patients and orchidopexy in one stage in 10 patients, and two stage Fowler-Stephens procedure in 4 patients size and position of the testis were estimated during surgery.

**Conclusion:** Laparoscopy is an excellent method for diagnosis and treatment of cryptorchidism.

#### VP24-09 URETEROSCOPY IN INFANTS AND YOUNG CHILDREN: INDICATIONS AND OUTCOMES

M. Baptistussi, M. Morihisa, E. Gewher, A. Martins—Brasil

**Background:** Ureteroscopy for adolescents and older children, is well documented, but reports of its use in infants and young children is limited. Presented here is data demonstrating the safe use of ureteroscopy in children less than or equal to 8 years of age.

**Methods:** Twenty-one children 12 female, 10 male, age 0.6–8 years (mean 3.1) have undergone ureteroscopy at our institution from 6/96 to 12/06. Either a 6.9 french semirigid (10 patients) or 7.4 french flexible (12 patients) ureteroscope was utilized. There were 13 ureteral (7 distal, 3 mid, 3 proximal) and 4 renal calculi, 4 obstructive uropathies (2 secondary UPJ, 1 primary lower pole UPJ, 1 congenital proximal ureteral stricture), and 1 foreign body removal. The Holmium laser was used for lithotripsy in 9 of 16 stones, and 3 of 4 incisional procedures. When necessary, dilatation was performed with a soft graduated dilator. Three children had prior urinary tract reconstruction (3 UPJ repair). All procedures were performed under general anesthesia. Post-operative radiographic assessment consisted of ultrasound, IVP or renal scan.

**Results:** All ureteral and 3 out of 4 renal stones were successfully treated. One lower pole stone could not be dislodged from the renal papilla. Post-operative drainage from obstructed systems was improved. Active dilatation was necessary in 9/17 (4 presented), and stents were at the conclusion of the procedure in 17/22.

**Conclusion:** A variety of ureteroscopic procedures can be performed safely in infants and young children with minimal morbidity. Post-operative stenting is not always necessary.

**VP24-10 LAPAROSCOPIC CORRECTION OF VESICOURTERAL REFLUX: EXPERIENCE IN 42 PEDIATRIC PATIENTS**

I. Vidal-mora, O. Castillo, R. Campos, G. Rubio, A. Foneron, F. Sepúlveda, F. Sepúlveda

**Background:** The optimal management of vesicoureteral reflux (VUR) is quite controversial. Many surgical antireflux techniques have been described. Open surgery is associated with a high success rate (>95%) regardless of the technique adopted. Laparoscopic technique is less invasive, but have been associated with prolonged surgical times. Objective: Present our experience in laparoscopic extraperitoneal ureteral neoplante with Lich-Gregoir technique.

**Methods:** Between 1994 and 2006, 42 children (34 with unilateral and 8 with bilateral vesicoureteral reflux) were treated with extravesical reimplantation (Lich-Gregoir technique) via a transperitoneal laparoscopic approach. The mean age was 5.8 years (range 9 months to 13 years), and there were 32 females and 10 males.

**Results:** The mean surgical time was 111 minutes. There were no conversions to open surgery. The mean hospital stay was 96 hours. After follow-up 57 months, one patient with previous renal damage and grade IV vesicoureteral reflux, presented renal exclusion and was submitted to laparoscopic nephrectomy, and two developed grade I contralateral veiscoureteral reflux.

**Conclusion:** Laparoscopic extravesical transperitoneal reimplantation for vesicoureteral reflux is an effective approach, with success rates similar to the open technique. In skilled hands does not prolong the surgical time.

**VP24-11 LAPAROSCOPIC MANAGEMENT OF THE ADULT NONPALPABLE TESTICLE**

I. Yildirim, S. Basal, H. Irkilata, M. Zor, E. Oral, M. Dayanc

**Background:** This report describes own experiences with diagnostic laparoscopy and laparoscopic orchiectomy of adult men with non-palpable testis.

**Methods:** Between August 2002 and July 2007, 30 patients underwent laparoscopic procedures due to non-palpable testis diagnosis and treatment. In all patients physical examination, USG and

CT were unable to show the presence of the testicles. Laparoscopy was used to assess the presence and location of the gonad and perform an orchiectomy or orchidopexy.

**Results:** Mean patient age was 19.7 years. Of 30 patients 2 had (6.6%) bilateral non-palpable and 28 (93.3%) had unilateral non-palpable testis. Diagnostic laparoscopy revealed intraabdominal testis in 6 (21.4%) of these 28 patients. Laparoscopic orchiectomy was performed for all these 6 patients. Laparoscopic orchidopexy was performed for one patient with bilateral non-palpable testis, due to low testosterone levels.

**Conclusion:** These results demonstrate the suitability of laparoscopy for the diagnosis and treatment of non-palpable testis in the adult population. In conclusion, laparoscopic management of adult non-palpable testis should be the first line step, as it permits the simultaneous use of additional treatment (e.g. laparoscopic orchiectomy) options and more accurate in determining non-palpable testis.

**VP24-12 APPLICATION OF LAPAROSCOPIC SURGERY IN UROLOGY (A REPORT OF 110 CASES)**

X. Hanbiao, Y. Haichao, T. Shengping, Y. Weizhong—China

**Background:** Objective: To investigate the clinical effects of laparoscopic surgery on the treatment of urologic diseases and summarize the experience.

**Methods:** From March 2006 to February 2008, 110 patients underwent laparoscopic surgery in our department. Among them, 49 cases had varicocele, 20 cases renal cyst deroofing, 15 cases ureterolithotomy, 7 cases high ligation of vaginal process, 5 cases renal hilar lymphatic ligation, 5 cases nephrectomy, 4 cases dismembered pyeloplasty, 3 cases adrenal tumorectomy, 2 cases radical nephrectomy.

**Results:** The operations of 109 cases were accomplished. 1 case was converted to traditional open surgery. No case was converted to open surgery. The operation time was 15 to 270 minutes, mean time  $62.9 \pm 57.5$  min. Hospital stay duration was 2 to 11 days. The mean hospital stay duration was  $5.1 \pm 1.6$  d. No severe complications occurred in this group.

**Conclusion:** Laparoscopic surgery has advantages of minimal invasive, less complications, rapid postoperative recovery and shorter hospital stay, which has satisfactory effect on the treatment of urologic diseases and has a great application value in the urologic clinical practice.

## VP25: LAPAROSCOPY—BLADDER

**VP25-01 A NEW APPROACH FOR OPTIMAL EXPOSURE DURING LYMPH NODE DISSECTION FOR LAPAROSCOPIC RADICAL CYSTECTOMY**

A. Ghazi, R. Zimmermann, A. Schfler, G. Janetschek—Austria

**Background:** Extensive lymph node dissection (LND) for muscle invasive bladder cancer is one of the integral steps of radical cystectomy. In addition to staging, an adequate LND has been found to alter both the prognosis & course of the disease after radical cystectomy. Our objective is to point out several essential steps that

provide an optimal exposure during LND for laparoscopic radical cystectomy (LRC).

**Methods:** 10 LRCs with an extended LND using this approach were performed at our institution. Patient and tumor characteristics, the anatomic extent of the lymph node dissection, the number of lymph nodes examined and postoperative complications encountered were evaluated. An outline of the essential steps include: (1) A modified five trocar arrangement. (2) Use of a 30 degrees telescope during the LND (3) Prior complete mobilization of the sigmoid colon allowing its retraction using an umbilical tape (4)



Accomplishing most of the bilateral LND from the right side (5) Performing the LND after removal of the specimen, providing ample space.

**Results:** Mean total operative time was 512.5 minutes (range 420–660) with a mean operative time of 143 minutes (range 115–165) for the extended LND. Adequate exposure was successful in all 10 patients. The average number of lymph nodes examined was 25.5 (19–32), with 4 nodes positive for metastasis. No patients had pelvic or lymph node metastasis at a mean follow-up of 14.8 months (range 4–30).

**Conclusion:** This new approach provides an optimal exposure for an adequate LND following LRC, which fulfills both oncologic expectations & the present standard of open LND.

### VP25-02 LAPAROSCOPIC RADICAL CYSTECTOMY WITH DETENIAL SIGMOID COLON ORTHOTOPIC NEO-BLADDER: EXPERIENCE WITH 100 CASES

X. Kai—People's Republic of China

**Background:** Radical cystectomy with urinary diversion is the current gold standard procedure for muscle-invasive bladder cancer. Laparoscopic radical cystectomy (LRC) has been described as a feasible procedure. The aim of this study was to describe our experience with this laparoscopic surgical approach and detenial sigmoid colon orthotopic neobladder for urinary diversion.

**Methods:** Between August 2002 and February 2009, 100 patients (mean age 62 years) had LRC with bilateral pelvic lymphadenectomy and detenial sigmoid colon orthotopic neobladder for invasive bladder cancer. Follow up ranged from 22 to 60 months with a mean of 42 months. Data were collected prospectively on patient characteristics, intraoperative parameters, pathologic staging, and postoperative outcomes.

**Results:** The mean operating time was 360 min, the mean blood loss 425 ml, the transfusion rate 7.2%, and the mean hospital stay was 33 days (28–35). All procedures were completed laparoscopically without conversion to open techniques. The bowel recovery time was 3–5 d. The pelvic drainage was removed in 7–10d, the neobladder's drainage was removed in 14–17 d, urethral catheter and ureteral stents were removed in 25–30 d after the leak tightness was confirmed by transurethral cystography. After the operations, the histopathologic analysis of the removed specimen revealed most tumors (90.74%) were transitional cell carcinoma tumours, 3 patients had adenocarcinoma and 2 patients had anaplastic carcinoma. Two patients had a positive surgical margin of urethra. The median number of lymph nodes excised was 12 (8–14), 2 patients had node-positive disease. During the follow up, all the patients achieved automatic micturition in 3 month after operations, and neobladder constructed from detenial sigmoid colon achieves adequate capacity (mean 216 ml, 100–400 ml) with a satisfactory day-time continence rate (95%), mean residual urine volume was 10.5 ml, and mean peak flow rate was 10.15 ml/s. There were 2 patients have occasionally night-time urinary incontinence, 3 have dysuria due to stenosis of bladder neck and were treated by endo-surgery. Perioperation and long-term complications include intestinal fistula (2), infection of incisional wound (2), ileus (1), neobladder calculus (1), ipilateral hydronephrosis (1), and bilateral hydronephrosis (1). At the last follow-up, 3 patients (5.56%) were dead due to metastasis and 51 patients were alive with no evidence of metastasis and recurrence.

**Conclusion:** The results of our study have shown that laparoscopic radical cystectomy is a safe, feasible, and effective alternative

method to bladder cancer. The detenial sigmoid colon orthotopic neobladder for urinary diversion could achieve excellent continence and micturition results. Long-term oncologic control data and functional outcomes should be needed to assess the true benefits of this technique.

### VP25-03 LAPAROSCOPIC-ASSISTED RADICAL CYSTECTOMY: LATE COMPLICATIONS AND ONCOLOGIC RESULTS AT MID-TERM FOLLOW UP

F. Porpiglia, C. Fiori, B. Cavallone, M. Manfredi, M. Lucci chiarissi, R. Scarpa

**Background:** The aim of this study is to present late complications and mid term follow up oncological results of laparoscopic-assisted radical cystectomy (LRC).

**Methods:** We extracted from our Institutional database the data of patients undergone LRC from November 2002 to January 2009.

**Results:** Data of 42 patients were reviewed. In all cases the cystectomy was performed with laparoscopy and reconstructive phase with traditional open approach. Twenty-four patients underwent Bricker intervention technique (group A) and 18 patients underwent bladder reconstruction with Y ileal neobladder (group B). In group A late complications were entero-cutaneous fistula (2 cases) and uretero-hydronephrosis (2 cases). In group B complications were neo bladder-rectal fistula (1 case), neobladder stone (2 cases), unilateral hydronephrosis (1 case), and urethro-neobladder anastomosis stricture (1 case). In group B 13 patients referred urinary incontinence (>1 pad/day). Mean follow up was 24.5 months in group A and 32 months in group B. In group A, 4 patients were lost at follow up, 4 patients died (3 of them for disease progression) whilst at this moment 11 patients are disease-free, 5 patients have disease progression. In group B, 5 patients died (4 of them for disease progression) whilst at this moment 10 patients are disease-free, 3 patients have disease progression.

**Conclusion:** Our data suggest that LRC allows acceptable late complications rate and encouraging oncologic results after mid term follow up. Long term follow up is needed to validate the technique from the oncological point of view.

### VP25-04 LAPAROSCOPIC RADICAL CYSTECTOMY WITH EXTENDED PELVIC LYMPHADENECTOMY(REPORTED OF 25 CASES)

Y. Changjun

**Background:** Pelvic lymph node dissection is an integral part of radical cystectomy, which has been proven to improve the survival of patients in addition to the accurate staging the tumor. We study the technique and evaluate outcomes of laparoscopic radical cystectomy with extended pelvic lymphadenectomy.

**Methods:** From January 2008 to May 2009, 25 patients with bladder carcinoma were performed laparoscopic radical cystectomy and extended pelvic lymphadenectomy. All the patients received general anesthesia and were placed with supine position. Five ports were applied for the laparoscopic procedure. The peritoneum and the vessels sheath were incised along the iliac vessels. Lymph nodes dissection was firstly performed in the right side then the left. The boundaries of lymphadenectomy include root of inferior mesentery artery (proximally), circumiliac vein (distally), genitofemoral nerve (laterally) and obturator nerve (medially). The vessels were skeletoning to remove all the lymphatic tissue. The bladder was then removed laparoscopically and urinary diversion was performed.

**Results:** All the procedures were performed under laparoscope successfully and no open conversion occurred. The time of the operation was 90–185 min (mean 125 min), intra-operative blood loss was 200–800 ml (mean 325 ml) and 5 case received blood transfusion. The pathology studies revealed transitional cell carcinoma and negative margin in all cases. The number of dissected lymph node was 19–53 (mean 30.5). Lymph node metastasis occurred in 7 cases. Pathological studies revealed T1 stage in 5, T2a stage in 7, T2b stage in 7 and T3a stage in 6. Complications include 1 case of ureter injure intraoperative, 3 cases of bowl obstruction and 6 cases of lymphatic leakage postoperative.

**Conclusion:** Laparoscopic radical cystectomy and extended pelvic lymphadenectomy is technically challenging for the operator. The procedure is also feasible with more experience. More lymph nodes can be dissected and higher positive rate can be achieved with laparoscopic extended pelvic lymphadenectomy, which is useful for the tumor staging and benefit to patients.

### VP25-05 LAPAROSCOPIC RADICAL CYSTECTOMY: OUR RESULTS AFTER 91 CONSECUTIVES PATIENTS

O. Castillo, I. Vidal-mora, A. Foneron, G. Rubio, R. Campos, F. Sepulveda

**Background:** Laparoscopic radical cystectomy (LRC) is considered a controversial surgical technique due the lack of extensive oncology follow-up studies. We present our mid-term results of a series consecutives patient.

**Methods:** 91 patients received LRC with intra or extracorporeal urinary diversion between August 2000 and April 2009, using a transperitoneal technique of 5 ports. The laparoscopic surgical technique was assisted in 85 cases and performed completely intracorporeal in 6 cases (Mainz II). Ileal conduit (26), heterotopic reservoir (20) and ortotopic neobladder (45) were used as a urinary diversion. Overall survival and disease associated with were revised in patient records.

**Results:** Average operative time was 283 minutes. (180–420). Bleeding average was 460 cc. (150–1500). Average time of follow-up was 23 months (5–38). 75 patients (93%) did not have local recurrence and 46 (57%) survived free of disease. Overall survival rate was 63%. The histopathological study reported transitional cell carcinoma pT1-4N1-2M0, adenocarcinoma, squamous cell carcinoma, and non-Hodgkin's lymphoma at 84, 3, 2 and 1 patients, respectively. Average number of nodes in the surgical specimen was 16.8 (8–26). The positive surgical margins were 11% throughout the series. Thirteen patients had positive lymph node disease. Fifteen patients were included in combined treatment protocols. Sixteen patients died of bladder cancer. Intraoperative, perioperative and late complications occurred in 7, 5 and 9 patients, respectively.

**Conclusion:** In our experience LRC shows acceptable oncological results. Increased number of patients and monitoring are needed to define objectively the current role of this procedure in the treatment of invasive bladder cancer.

### VP25-06 LAPAROSCOPIC CYSTECTOMY WITH TOTALLY INTRACORPOREAL MAINZ POUCH II RESERVOIR

O. Castillo, R. Campos, I. Vidal-mora, A. Foneron, G. Rubio, M. Feria-Flores

**Background:** The reported experience regarding feasibility of total laparoscopic ureterosigmoid urinary diversions is limited. We present our experience in 9 patients, in whom bladder resection was indicated and totally laparoscopic Mainz II pouch created.

**Methods:** We present 9 female patients with a median age of 65 years (32–76), in whom bladder resection was indicated. Seven of them were diagnosed with a transitional cell carcinoma (TCC) (T1-2, G3) and the other two with chronic pelvic pain conditioned by an interstitial cystitis. The corresponding lymphadenectomy was made in the patient with TCC. The Mainz II pouch reservoir creation was totally performed by laparoscopy mimicking the steps described for the open technique.

**Results:** There were no perioperative complications. Mean operation time was 280 min (240–375). Time breakdown for each step of the operation was 100 min (90–150), 65 min and 135 (120–150) for the cystectomy, the pelvic lymphadenectomy (in the case which was indicated) and the reservoir making respectively. Median blood loss was 110 cc (50–120). Mean hospital stay was 8 days. Ureteral catheters and rectal catheter were removed at 8th and 9th days, respectively. Mean time to start oral intake was 48 hrs. During follow-up were two late postoperative complications: a urinary infection and a uretero-reservoir anastomosis stenosis.

**Conclusion:** The totally laparoscopic Mainz II diversion is a viable and safe option in selected patients for bladder diversion after cystectomy. Extensive functional follow-up is mandatory.

### VP25-07 DIVERSION-RELATED COMPLICATIONS AFTER LAPAROSCOPIC AND OPEN RADICAL CYSTECTOMY

R. Brandina, A. Berger, A. Bosco, I. Gill, S. Campbell

**Background:** Open radical cystectomy (ORC) is the gold standard treatment for muscle-invasive bladder cancer. Laparoscopic radical cystectomy (LRC) with extracorporeal reconstruction is a minimally invasive alternative for the management of this disease. However, relatively short ureteral length and body habitus may make the diversion more challenging and could theoretically predispose to ureteral strictures and other diversion related complications.

**Methods:** A retrospective review was undertaken of 151 patients managed with either LRC (extracorporeal diversion) or ORC performed between August 2005 and November 2008. Diversion related and other clinical parameters were obtained from patient charts and review of the Social Security Death Index.

**Results:** There were no significant differences between the LRC (n = 64) and ORC (n = 87) group with respect to mean patient age (70 vs. 69; p = 0.7), BMI (28 vs. 28; p = 0.9), sex, ASA class, and operative indications. The ORC group had a higher prevalence of CKD and smoking history. The distribution of urinary diversions was similar between LCR (46 ileal conduit, 12 orthotopic neobladder, 6 continent cutaneous) and ORC groups (66 ileal conduit, 13 orthotopic neobladder, 8 continent cutaneous). The pathological findings were organ confined tumor ( $\leq$ pT2 or less) or non-organ confined tumor (pT3-4) in 67% and 33% of the LCR cases and 58% and 42% of the ORC cases, respectively (p = 0.25). The number of nodes retrieved was higher in ORC group (24 vs. 17, p = 0.03). There were no differences between overall intraoperative complications (3% vs. 3%) and postoperative minor (21% vs. 31%, p = 0.21) and major complications (8% vs. 7%, p = 0.8). Seventeen diversion related complications were identified including: LRC (n = 9, 14%) with 7 ureteral stenosis, 1 total incontinence after neobladder requiring AUS, 1 urinary fistula requiring percutaneous bilateral nephrostomy tubes; ORC (n = 8, 9.1%) with 6 ureteral stenosis, 1 neobladder disruption and 1 enteroureteral fistula.

**Conclusion:** Diversion related complications were marginally increased with LRC compared to ORC, although these evaluations did not reach statistical significance.

**VP25-08 LAPAROSCOPIC RADICAL CYSTECTOMY. SINGLE INSTITUTIONAL EXPERIENCE**

D. Nakano, F. Sato, Y. Hirata, H. Mimata—Japan

**Background:** To assess the outcomes of laparoscopic total cystectomy (LTC) and extracorporeal urinary diversion for primary bladder cancer during a 5-year period.

**Methods:** From October 2004 to April 2009, 35 LTCs were performed at Oita university hospital, and a retrospective chart analysis was performed.

**Results:** Median follow-up period was 20 (1–53) months. Thirty five patients underwent LTC with urinary diversion, and 4 patients underwent LTC without urinary diversion. Percutaneous ureterostomy (n = 13), ileal conduit (n = 10) and ileal neobladder (n = 8) were adopted, and mean operative time was 341, 530 and 602 minutes, respectively. Mean intraoperative blood loss was 747 ml in percutaneous ureterostomy, 699 ml in ileal conduit and 1206 ml in neobladder group. Open conversion rate was 2.8% (1 case). Perioperative major complication rate was 8.4% (3 cases: rectal injury 1, retroperitoneal hematoma 1, transient obturator nerve palsy 1), but all patients were recovered conservatively. Three patients died during follow-up period.

**Conclusion:** LTC is safe and useful surgical option for patients with localized bladder cancer unfit for bladder preservation.

**VP25-09 LAPAROSCOPIC RADICAL CYSTECTOMY WITH URINARY DIVERSION THROUGH A 4 CM MINI-INCISION**

Y. Bayazit, I. Aridogan, O. Karsli, D. Abat, N. Satar, S. Doran

**Background:** Ileal conduit urinary diversion (ICUD) following laparoscopic radical cystectomy (LRC) can be performed either with laparoscopic or open surgery. The first option takes longer time while second has the disadvantage of the need for a relatively longer incision. Minimally invasive nature of the LRC is not compromised while it can be completed within similar time to open ICUD if it can be performed through a very small incision that is used for the specimen extraction. LRC and mini-incision ICUD performed on a patient with invasive bladder cancer is presented.

**Methods:** LRC and extended lymph node dissection were performed through 5 trocars. Ureters were dissected free so they can easily reach anterior abdominal wall. Ileum that would be used as a conduit was measured by the help of a ureteral catheter and marked with silk sutures. Left ureter was passed through a hole created in the sigmoid mesocolon. Then a 4 cm sub-umbilical midline incision was made to extract the specimen and the previously marked ileal segment in order to complete the ICUD extracorporeally.

**Results:** Laparoscopy time was 240 minutes and estimated blood loss (EBL) was 50 mL. The patient was discharged on third and ureteral stents were removed on tenth day. The histopathological examination revealed high grade urothelial carcinoma without perivesical invasion and negative surgical margins. The patient is under follow-up for twelve months without any complication.

**Conclusion:** Open surgery is generally the preferred technique for the completion of ICUD following LRC. However, adequate mobilization of the ureters, identification of the ileal segment, contralateral crossing of the left ureter and the extended lymph node dissection by laparoscopy makes the completion of the ICUD possible by the advantages of the minimally invasive surgery through a 4 cm mini-incision.

**VP25-10 LAPAROSCOPIC BOARI FLAP FOR DISTAL URETERAL INJURIES**

J. Diaz, R. Riffo, I. Pinto, A. Pabon, C. Sandoval, A. Hornig—Chile

**Background:** Ureteral injuries are commonly iatrogenic secondary to various pelvic and gynecologic operations. An adequate blood supply, wide lumen and lack of tension are necessary for a successful anastomosis. Occasionally, the ureteral length is inadequate to reach the bladder. In these cases, a Boari flap is required to construct a tension free anastomosis. The laparoscopic technique has been adapted to Boari flap repair with excellent success. We present our experience and results of six patients who underwent a laparoscopic Boari flap procedure.

**Methods:** Since January 2007, six patients with distal ureteral injuries underwent to laparoscopic Boari flap repair procedure. All patients underwent to radiographic evaluation, including excretory urography, computerized tomography and retrograde pyelography. Ureteroneocystostomy was not feasible because the injuries length.

**Results:** Six patients underwent laparoscopic Boari flap, four ureterovaginal fistulas and two ureteral stricture. The procedure was performed in all cases. No complications intraoperative. The mean operative time and blood loss was 200 minutes and less than 50 cc. Mean hospital stay was 6 days. Foley catheter was removed on postoperative day 7, and stent were removed postoperative week 4. There were no long term complications with mean follow up of 14 months.

**Conclusion:** Laparoscopic Boari flap is feasible and maintains all principles of open surgery.

**VP25-11 LAPAROSCOPIC TOTAL CYSTECTOMY IN INTERSTITIAL CYSTITIS: 5 CASES**

O. Castillo, I. Vidal-mora, R. Campos, A. Foneron, G. Rubio, F. Sepulveda

**Background:** Interstitial cystitis is a chronic debilitating condition affecting primarily women. Conservative treatment has unsatisfactory results and the identification of the best surgical treatment is difficult. Our aim is to evaluate the efficacy of laparoscopic total cystectomy with continent reservoir in the treatment of refractory interstitial cystitis.

**Methods:** Five female patients, mean age 43 years, underwent this procedure. Indication was failure to medical therapy. Cystectomy was performed with a 5-trocar technique using modified lithotomy position. A uterine manipulator was used in 3 cases. Three patients were managed with an anterior exenteration and in 2 cases the uterus were preserved. The urinary diversion technique was an intracorporeal Mainz II pouch in 3 cases and an extracorporeal Indiana reservoir in 2 cases. An evaluation of perioperative data, continence and quality of life (qualitative questionnaire) was performed.

**Results:** The mean surgery time in the 3 cases with intracorporeal urinary diversion was 5 hours. In those patients in who Indiana reservoir was performed, surgery time was 6 hours. There were no perioperative complications. With a mean follow up of 9.6 months, no patients reported pain, incontinence and the quality of life achieved is good.

**Conclusion:** For patients with interstitial cystitis refractory to conservative management, laparoscopic total cystectomy and continent reservoir are valid therapeutic options with good results.

### VP25-12 THE MODIFICATION OF LAPAROSCOPIC RADICAL CYSTECTOMY WITH ILEAL CONDUIT

L. Ma, Y. Huang, X. Hou, G. Wang, L. Zhao, C. Xiao

**Background:** To report on the surgical technique improvement of laparoscopic radical cystectomy (LRC) with ileal conduit. Where should the incision be made to remove the organs after radical cystectomy could the ileal conduit be created at the incision where the organs were removed?

**Methods:** A total of 27 patients with invasive bladder carcinoma underwent laparoscopic radical cystectomy with radical lymphadenectomy with ileal conduit from October 2004 to March 2009. Skill improvement: 1. Insert a F22 Foly urethral catheter through the urethra as drainage tube, turgor water sac with 30 ml water, and then draw the urethral catheter in order to decrease capillary hemorrhage around the urethra. 2. The surgical specimens were removed from the incision between the two trocars at the right lower quadrant and the ileal pouch was created here too.

**Results:** All operations were performed successfully. Operating time was 3 to 11 hours, and blood loss was 100 to 2000 ml. 6 of 27 patients needed blood transfusion.

**Conclusion:** With the improvement in the surgical technique, laparoscopic radical cystectomy with ileal conduit, resulting in smaller incision, less blood loss and rapider recovery, may be much more easily accepted by patients with bladder cancer.

### VP25-13 SOME EXPERIENCES OF LAPAROSCOPIC RADICAL CYSTECTOMY WITH ORTHOTOPIC STUDER NEOBLADDER

L. Ma, Y. Huang, X. Hou, L. Zhao, K. Hong, Y. Liu—China

**Background:** To introduce our experiences of Laparoscopic radical cystectomy with orthotopic neobladder.

**Methods:** 42 patients were operated of Laparoscopic radical cystectomy with orthotopic Studer neobladder during July 2005 to June 2009 in our department. Our experiences: 1. Lymphadenectomy first. 2. During lymphadenectomy, find ureter which is in front of iliac vessels and Separate ureter to bladder. Using two HEMO-LOKs to shut ureter where adjacent bladder, and snip off the part of ureter which between the two HEMO-LOKs. We can save time by cleaning Lymph node and Separating ureter at one time. 3. Infusing 100–150 ml saline into the neobladder after Studer neobladder sutured, then observe whether the saline leak out. 4. Using mucosa to mucosa interrupted suture of Ureteroneocystostomy can decrease complications. 5. In order to suture urethra and neobladder easier, we Use 2-0 absorbable Suture to pull the neobladder to the Catheter on the direction of 6 o'clock.

**Results:** 42 Laparoscopic operations were successful, blood loss was between 100–800 ml, operating time was between 5 h–7 h 45 min.

**Conclusion:** After being master of laparoscopic skills, there was little blood loss of Laparoscopic radical cystectomy with orthotopic neobladder, and operating time was no more than laparotomy.

### VP25-14 LAPAROSCOPIC RADICAL CYSTECTOMY WITH ORTHOTOPIC ILEAL NEOBLADDER FOR CANCER: EXPERIENCE OF 164 CASES WITH 6 YEARS

J. Huang, T. Lin, C. Zhang, K. Xu, C. Jiang, H. Huang—China

**Background:** Today laparoscopic radical cystectomy (LRC) has become feasible at selected centers worldwide, but very few long-term follow-up data about oncological outcome is available, es-

pecial data from large series. In this study, we report the oncological outcomes after laparoscopic radical cystectomy and orthotopic ileal neobladder for bladder cancer in a consecutive series of 164 patients with follow-up up to 6 years.

**Methods:** From December 2002 to April 2009, 164 patients (145 men and 19 women; mean age 62.3 years) with bladder cancer underwent laparoscopic radical cystectomy and extracorporeal formation of orthotopic ileal neobladder, standard bilateral pelvic lymph node dissection was performed for 139 patients and extended for 25 patients. Overall and cancer-specific survival data were collected and analysis.

**Results:** Histological examination showed most tumors were transitional cell carcinoma (154, 94%), organ-confined, lymph node-negative tumor for 110 patients (pT1-T3a, 67%), nonorgan-confined, lymph node-negative tumor for 17 patient (pT3b-4a, 10%) and lymph node tumor involvement for 37 patients (23%). Surgical margins were tumor free for all patients. Median no. of removed LN were 14 (5–32), 154 patients were followed-up for 2 to 79 months (average 46.1 months), 9 patients had local recurrence, 1 patient had trocar site seeding, 17 patients had distant metastasis, 21 patients died, 16 from metastasis and 5 from unrelated causes. 133 patients were alive with no evidence of disease, the recurrence-free survival rate was 81.1%.

**Conclusion:** Our data showed LRC has comparable intermediate-term oncological outcome to contemporary series of open RC. Long term follow-up is needed to confirm the cancer control with LRC.

### VP25-15 MANAGEMENT OF POST-OPERATIVE COMPLICATIONS IN LAPAROSCOPIC RADICAL CYSTECTOMY: A REPORT OF 164 CASES

J. Huang, C. Zhang, T. Lin, C. Jiang, K. Xu, Z. Guo—China

**Background:** 164 laparoscopic radical cystectomies (LRC) were analyzed retrospectively in order to evaluate the incidence and cause of post-operative complication. The management and prevention of the complications were discussed.

**Methods:** Between December 2002 and April 2009, 164 patients (145 men and 19 women) aged 27 to 81 years (mean 62.3 years) with bladder carcinoma underwent LRC with orthotopic ileal neobladder in our department. Of the 164 patients, 118 had primary bladder tumor, and 46 patients presented with recurrent disease. The upper urinary tracts were normal with the exception of 8 patients, 5 of whom had unilateral hydronephrosis caused by obstruction of the ureteral orifice and 3 of whom had a solitary kidney caused by previous unilateral nephrectomy. Lymph node metastases were found in 6 patients by evaluation with CT or MRI. No distant metastasis was identified in all patients.

**Results:** Of the 164 cases, the early post-operative major complications were found in 8 cases (4.9%), including 2 pouch-vaginal fistula, 1 ileal anastomotic leakage, 1 colon-pouch fistula, 2 ileo-pouch fistula, 1 uretero-pouch anastomotic obstruction and 1 mesentery vein thrombosis. The early post-operative minor complications were found in 29 cases (17.7%), including 7 vesico-urethral anastomotic leakage, 11 prolonged lymphatic leakage, 5 paralytic ileus, 2 wound infection, 1 pneumonia, 1 pyelonephritis, 1 delirium and 1 incisional hematoma. The late post-operative major complications were found in 16 cases (9.8%), including 6 uretero-pouch anastomotic stricture, 3 vesico-urethral anastomotic stricture, 3 adhesive ileus, 2 pouch stone, and 2 pouchitis. All complication were treated effectively and recovered well, without

post-operative mortalities. 2 pouch-vaginal fistula was managed by repairing through the vagina. 1 ileal anastomotic leakage, 1 colon-pouch fistula, 2 ileo-pouch fistula, 1 uretero-pouch anastomotic obstruction and 1 mesentery vein thrombosis were managed by reoperation. 5 uretero-pouch anastomotic strictures were managed by percutaneous nephrostomy and antegrade double-J stents indwelling for 3 months; another accepted open surgical revision with excision of the strictured ureteral segment and reanastomosis 14 months after LRC. 3 vesicourethral anastomotic strictures were managed by visual internal urethrotomy. 2 pouch stone were treated by therapeutic endoscopy. 1 incisional hematoma was managed by punctured and drained under B ultrasound guided. 7 vesico-urethral anastomotic leakage were cured by prolonging catheter indwelling. 11 lymphatic leakage, 5 cases of paralytic ileus, 3 adhesive ileus, 2 wound infection and 1 delirium were cured by conservative treatment. 1 pneumonia, 1 pyelonephritis and 2 pouchitis were cured by antibiotics treatment.

**Conclusion:** LRC for invasive transitional-cell carcinoma is feasible and can be accomplished with low mortality and acceptable post-operative complications incidence. The majority of the early and late complications were minor and easily managed without significant sequelae.

#### **VP25-16 COMPARISON OF LAPAROSCOPIC AND OPEN RADICAL CYSTECTOMY WITH ORTHOTOPIC ILEAL NEOBLADDER: PRELIMINARY REPORT OF A PROSPECTIVE RANDOMIZED CONTROL STUDY**

J. Huang, T. Lin, C. Zhang, K. Xu, C. Jiang, Z. Guo—China

**Background:** Laparoscopic radical cystectomy (LRC) versus open approach (ORC) has been reported in several retrospective series, however, prospective randomized study has not yet been reported. Basing on the experience of more than one hundred cases of laparoscopic and open radical cystectomy, we performed this prospective randomized control study on comparison of LRC and ORC.

**Methods:** From January 2008 to May 2009, 32 patients with bladder cancer in our center were enrolled and randomly assigned into LRC group (N = 18) and ORC group (N = 14). All patients in both groups were performed by single surgeon (Dr Jian H.) with the same procedures including radical cystectomy, standard pelvic lymphadenectomy and orthotopic ileal neobladder. Data was collected prospectively, including patient demographics, operative and postoperative variables, functional and pathological outcomes.

**Results:** The two groups were demographically comparable. The mean operating time was 347.3 min in the LRC group and 243.5 min in the ORC group ( $P < 0.05$ ). The mean blood loss was 278 ml in the LRC group and 721 ml in ORC group ( $P < 0.01$ ). The rate of transfusion was 5% in LRC group and 50% in ORC group ( $p < 0.01$ ). The mean oral intake after operation was 3.4 days for LRC group and 4.5 days for ORC group ( $P < 0.01$ ). The complication rate was 38.9% in LRC group (7/18), while 42.9% in ORC group (6/14) ( $p > 0.05$ ). Six months after operation, the day-time continence rate were 100% (11/11) and 87.5% (7/8) for the LRC and ORC group respectively ( $p > 0.05$ ), night-time continence rate were 36.4% (4/11) and 37.5% (3/8) respectively ( $p > 0.05$ ), most of the patients achieved night-time continence at 8–9 month after operations. No perioperative death was occurred in both groups. Surgical margin were tumor free for all cases ( $p > 0.05$ ). The mean number of removed lymph node were 15.9 and 14.1 in LRC and ORC group respectively ( $p > 0.05$ ), and the positive lymph nodes were involved in 33.3% LRC cases(6/18), and 35.7% in ORC (5/

14). The patients were follow-up for 1 to 16 months (mean 8.3 months), all the patients were tumor free except one patient with T3aN2G3 tumor in LRC group, who had local and distal metastasis at 4 months and died 5 months after operation.

**Conclusion:** Laparoscopy radical cystectomy offers the benefit of less blood loss, comparable postoperating complications and earlier recovery of bowel function. The neobladder functions are comparable to open surgery in urine continence, However more cases enrollment, and long-term followup are necessary for oncological outcome.

#### **VP25-17 LAPAROSCOPIC URETERO-VESICAL RE-IMPLANTATION WITH “SPLIT-NIPPLE” TECHNIQUE**

J. Huang, X. Li, C. Zhang, T. Lin, K. Xu, X. Yin—China

**Background:** To introduce a technique of uretero-vesical re-implantation by means of “split nipple” technique under laparoscopy and evaluate its feasibility and clinical significance.

**Methods:** From May 2004 to July 2007, 21 cases (25 sides) of lower ureter lesions were operated with laparoscopic “nipple approach” vesico-ureteral reimplantation. In all of these cases, 14 patients were men, 11 were women. Their mean age is 32. 11 sides had ureteral orifice obstruction, 2 sides had endometriosis, 3 sides had mega-ureter, 5 sides had vaginal-ureteral fistula. The ureter was gently dissected circumferentially down to the bladder. It was ligated close to the bladder and divided proximal to it. The free ureteral end was delivered out through the ipsilateral port. The lower end of ureter was made into nipple evaginated mode. Megaureter was tailored over a 16Fr catheter. Later the whole assembly was carefully replaced in the abdomen. The nipple was inserted bladder 1 to 1.5 cm and fixed it, A 6 Fr Double-J stent was placed under laparoscopy.

**Results:** The operations were all successful in 21 cases (25 sides). Mean operating time was 136 min; as 32 ml; The mean hospital stay after surgery was 12 days with a mean follow-up of 15 months. Ultrasound and IVU showed that the hydronephrosis disappeared or decreased and there were no obvious urine reflux and stoma fistula in most cases. Urination through the ureteral nipple can be seen clearly under cystoscopy. Ureteral stenosis recurred in 2 cases postoperatively; Fortunately, the hydronephrosis disappeared after stenosis was dilated by a retrograde dilator which was guided by a zebra guide-wire under PCN ahead of schedule.

**Conclusion:** Ureteral-vesical reimplantation by means of “split nipple” under laparoscopy is a feasible, less blood lose and minimally invasive alternative method for treatment of lower ureteral lesions.

#### **VP25-18 LAPAROSCOPIC RETROPERITONEAL LYMPH NODE DISSECTION WITH THERAPEUTIC INTENT IN MEN WITH CLINICAL STAGE I NONSEMINOMATOUS GERM CELL TUMORS**

T. Guzzo, J. Berkowitz, M. Gonzalgo, M. Allaf

**Background:** Laparoscopic retroperitoneal lymph node dissection (RPLND) as a primary means of therapy for patients with clinical stage I nonseminomatous germ cell tumors (NSGCTs) remains controversial. The object of this study was to assess the outcomes of patients with clinical stage I NSGCTs who underwent a laparoscopic RPLND with therapeutic intent.

**Methods:** We retrospectively reviewed the pathological, perioperative, and early oncological outcomes of 26 patients who underwent a laparoscopic RPLND with therapeutic intent for stage I NSGCT from July 2006 to March 2009. An extended template

dissection was performed on all patients including dissection behind the great vessels. A full bilateral dissection was performed if metastatic disease was detected intraoperatively. Patients found to have pathological N1 disease were counseled regarding omission of chemotherapy.

**Results:** Of the 26 patients, 9 (35%) had pathologic stage II disease. Mean length of hospital stay was 2 days (range 1–4) and the mean number of lymph nodes removed at the time of laparoscopic RPLND was 28 (range: 6–82). No major complications occurred and 25 (96%) patients reported normal ejaculation. Of the 6 patients with N1 disease, 4 (67%) did not receive adjuvant chemotherapy and are without evidence of disease at a mean follow-up of 13 months.

**Conclusion:** Laparoscopic RPLND with therapeutic intent can be performed with low morbidity and acceptable oncological efficacy. Patients found to have low volume metastatic disease can be safely observed although additional follow-up and larger cohorts are required to validate this.

**VP25-19 A SAFE AND EFFICIENT TECHNIQUE FOR INITIAL ACCESS TO INTRAPERITONEAL LAPAROSCOPY**

A. Ghazi a., R. Zimmermann, A. Schfler, G. Janetschek

**Background:** One of the fundamental and critical steps in intraperitoneal laparoscopy is the initial access and creation of pneumoperitoneum, although complications associated with port-site placement are uncommon, the potential for associated morbidity is high. Veress needle and direct trocar insertion are blind techniques used to create pneumoperitoneum and are usually accomplished without incident. However, on rare occasions it can lead to major vascular, bowel or abdominal wall injuries. We herein present our experience with a safe and efficient technique to initiate intraperitoneal laparoscopy.

**Methods:** This technique involves; a skin incision is at the site of Veress needle application. The anterior sheath overlying the muscle of the abdominal wall is adequately exposed. Two hook retractors (Fistula hook retractor; single prong, Aesculap AG) are used to fix the sheath on opposite sides, gentle traction of the hooks causes elevation & stabilization of the abdominal wall during application of the Veress needle & creation of pneumoperitoneum. The trocar harboring the telescope is then placed using the same technique of stabilization, thereby avoiding injury to the underlying intra-abdominal structures by the tip of the trocar due to downward dis-

placement of the abdominal wall during application of this trocar blindly. The remaining trocars can then be applied under vision.

**Results:** This technique has been routinely applied by one of the authors since 1993 & at our institution since 2000 and by which over 1900 cases have underwent intraperitoneal access without any reported complications during initial access.

**Conclusion:** This technique although simple is very efficient & economical method of providing a safe access to intraperitoneal laparoscopy.

**VP25-20 CAN PEROPERATIVE COMPLICATION RATES DICTATE THE DIFFICULTY OF RETROPERITONEOSCOPIC PROCEDURES**

A. Tepeler, A. Tefekli, T. Aktoz, M. Binbay, M. Baykal, A. Müslümanođlu

**Background:** The difficulty of surgical procedures are usually defined by the surgical expertise needed, operative times and potential complication rates. Considering to have achieved a standart surgical expertise, we tried to assess whether peroperative complication rates could dictate the difficulty of retroperitoneoscopic procedures.

**Methods:** Between 2006 and 2009, 258 retroperitoneal procedures were performed at our instution by a single surgeon. Peroperative complications were stratified into 3 grades using Satava classification (Grade I: incidents without consequences, Grade II: incidents repaired intraoperatively, Grade III: incidents requiring open conversion). Retroperitoneoscopic procedures were classified according to ‘European Scoring System for Laparoscopic Operations in Urology’.

**Results:** The mean age of the patients was 43.68 ± 14.55 (range: 12–75) years. The mean operation time was 108.9 ± 44.88 (range: 20–300) minutes. The mean hospital stay was 3.32 ± 2.45 (range: 1–11) days. The procedures were classified as simple in 45 (17.4%), difficult in 172 (66.7%), and very difficult in 41 (15.9%) patients. According to the Satava classification system, Grade I complications were observed in 5 (1.93%), Grade II complications in 20 (7.75%) and Grade III complications in 4 (1.55%) patients. Peropative complications were observed in 4.44% of simple procedures, 7.55% of difficult procedures and in 34.14% of very difficult procedures.

**Conclusion:** Peroperative complications classified according to the Satava system significantly increase as the technical difficulty of procedure increases. Therefore the difficulty of procedure should attract the attention of the surgeon in terms of potential intraoperative complications.

**VP26: PCNL 3**

**VP26-01 SEQUENTIAL FLEXIBLE PERCUTANEOUS AND URETEROSCOPIC APPROACH IN STAGHORN CALCULI**

R. Multescu, B. Geavlete, V. Cauni, V. Mirciulescu, D. Georgescu, P. Geavlete—Romania

**Background:** Percutaneous approach of staghorn calculi may raise some challenges. The aim of our study was to determine the value of sequential flexible nephroscopic and ureteroscopic approach regarding the decrease in morbidity of percutaneous treatment in staghorn calculi.

**Methods:** Between January 2003 and January 2009, the sequential flexible nephroscopic and ureteroscopic approach was applied in 7 cases with restant caliceal stone fragments after percutaneous nephrolithotomy with rigid nephroscopes of staghorn calculi. All cases presented restant stones in 2 caliceal groups. We used a 15 F Storz flexible nephroscope, a 7.5 F Storz flexible ureteroscope, an electrohydraulic lithotripter and various stone extractors (nitinol baskets and triradiate graspers).

**Results:** In 4 cases, the flexible ureteroscope was used due to a narrow infundibulum, which prevented the access of the much

larger nephroscope. In the other 3 cases, the flexible retrograde approach was imposed by the impossible percutaneous approach due to an acute angle between the access tract and the calices containing stones. The combined access was successful in rendering the patients stone-free in 85.7% of cases (6/7 patients). In one case, an additional percutaneous access tract was necessary in order to remove a large middle caliceal stone fragment. No major complications were encountered.

**Conclusion:** Sequential flexible nephroscopic and retrograde ureteroscopic approach may be a safe and efficient method in treating resistant stone fragments after rigid percutaneous nephrolithotomy for staghorn calculi. It may reduce the need for additional access tracts, thus decreasing the associated morbidity of percutaneous surgery.

### VP26-02 OUTCOMES OF COMPLETE SUPINE PCNL AND PRONE PCNL ACCORDING TO BODY MASS INDEX

S. Falahatkar, M. Akbarpour, A. Afshari moghaddam, A. Enshaie

**Background:** Percutaneous nephrolithotripsy (PCNL) usually was performed in the prone Position. Recently PCNL in the complete supine position was performed too. Obesity poses a number of problems in the management, diagnosis, imaging, anesthesia and surgery. To determine whether BMI can predispose the outcome of PCNL in prone and supine position or not.

**Methods:** We retrospectively reviewed files of 110 patients who underwent in prone and supine PCNL between September 2007 and December 2008. All patients underwent PCNL in prone or supine approach. The patients were divided into three BMI categories: BMI <25, 25–30, >30. The patients were compared with regard to stone characteristics, stone free rate, Hb before and after surgery, blood transfusion rate, fever rate, anesthesia time, complications and tubeless PCNL rate were evaluated.

**Results:** Demographic data and stone characteristics were not significantly different between supine and prone PCNL groups. The overall stone-free rate was 78% and 73.3% in prone and supine position respectively ( $p=0.57$ ). No major complications were seen. No statistically significant differences were found except a higher incidence of fever was seen with the prone approach and anesthesia time was significantly shorter in complete supine position. Moreover with increase in BMI, anesthesia time was increased. There was no statistically difference in each subdivided group between prone and supine position in obese and morbidly obese groups.

**Conclusion:** The outcome of PCNL in both prone and supine position is independent of the patient's BMI. Although the anesthesia time was increased with BMI, Prone and supine PCNL in obese and morbidly obese patients were safe and effective.

### VP26-03 COMPARISON OF EFFICACY AND COMPLICATIONS OF GENERAL AND SPINAL ANESTHESIA IN PERCUTANEOUS NEPHROLITHOTOMY

S. Mehrabi, M. Akbartabar—Iran

**Background:** Aim of this study is evaluating efficacy and complications of Spinal anesthesia in comparison to general anesthesia in PCNL.

**Methods:** In a randomized clinical trial 100 patients older than 18 years old that were candidate for PCNL randomly assigned in two groups. In group one Spinal anesthesia was induced with marcaine (15 mg) and Fentanyl (0.25  $\mu$ g) injected intrathecally at the L3-L4 interspaces and head of bed tilted down for 5–10 minutes with

checking level of anesthesia. Conscious sedation, during PCNL was obtained with intravenous midazolam. Then PCNL was done in prone position under guide of fluoroscopy by standard technique. In group two standard general anesthesia was performed and PCNL was performed as first group. Patients are interviewed on first postoperative day regarding the occurrence of any complications, postoperative pain and satisfaction from procedure.

**Results:** Mean stone size in group one and two were  $34.2 \pm 9.8$  and  $31.3 \pm 7.9$  millimeter respectively. Mean time of operation in both groups were  $105 \pm 35.7$  and  $98 \pm 46.3$  minutes ( $p=0.03$ ). In the first part of anesthesia, 9 patients in spinal group and three patients in general group ( $p=.001$ ) developed hypotension that controlled by injecting 10 mg of ephedrine intravenously. Mean Cost of anesthetic drugs in groups 1 and 2 were respectively  $3.2 \pm .6$  and  $17.3 \pm 1.3$  EUR ( $P=.001$ ). satisfaction from operation and postoperative pain in two groups were respectively 88 and 86 percent ( $p>.05$ ).

**Conclusion:** Spinal anesthesia is safe and effective with low cost for performing PCNL and is a good alternative for general anesthesia in adult patients.

### VP26-04 PERCUTANEOUS NEPHROLITHOTOMY (PCNL) FOR RENAL CALCULI OF MORE THAN 5 CM

A. Ashish Patil—India

**Background:** We herewith compare percutaneous nephrolithotomy and open stone surgery for renal calculi more than 5 cms in the largest dimension.

**Methods:** All patients with renal calculi more than 5 cms in the largest dimension attending our out patient department were investigated and offered a percutaneous nephrolithotomy. All initial punctures and rigid tract dilatation were performed using biplanar C-arm fluoroscopy in prone position. Flexible nephroscopy and holmium laser were used when necessary. Blood loss, stone clearance, operative time, postop morbidity, patient compliance, hospital stay, cost effectivity and stone clearance were the parameters used to compare PCNL with the published literature of open stone surgeries.

**Results:** PCNL parameters were found to be better against open surgery for blood loss (30 cc against 100 cc), operative time (1 hr against 2.5 hrs), stone clearance (82% against 60%), hospital stay (3 days against 10 days). PCNL had better patient compliance, cost effectivity and less post operative morbidity as compared to open surgery.

**Conclusion:** The role of open pyelolithotomy is limited in the present day scenario. In good hands PCNL should be the first line of treatment for renal calculi more than 5 cms in dimension.

### VP26-05 PERCUTANEOUS STONE SURGERY UTILIZING TUBELESS TECHNIQUE WITH FIBRIN SEALANT: REPORT OF OUR FIRST 100 CASES

J. Durbin, S. Stroup, J. L'esperance, B. Auge

**Background:** Percutaneous nephrolithotomy (PCNL) is the preferred treatment for large renal stones, and the tubeless technique for select patients has recently gained popularity. Several iterations of the procedure have been described. We report on our first 107 PCNL patients utilizing fibrin sealant as a hemostatic agent within the access tract.

**Methods:** A retrospective review was completed for PCNL performed without nephrostomy tube from January 2002 to July 2008.

We assessed demographics, length of hospital stay, stone size, stone free rates and complications. Stone free results were obtained by post-operative CT scan the morning following the procedure.

**Results:** Fifty-nine men and 48 women with a mean age of 43 years were included in the analysis. Mean stone size was 2.9 cm<sup>2</sup> and the average length of hospital stay was 1.07 days. Immediate targeted stone free rate in the tubeless group was 72% (77/107) which improved to 90% when considering residual fragments  $\leq 4$  mm as stone free. The change in serum creatinine, hemoglobin and hematocrit were all statistically different when comparing preop and postop values, however, the change in creatinine was clinically insignificant (0.92 mg/dl preop to 0.96 mg/dl postop). Complications included seven asymptomatic subcapsular hematomas, one pseudoaneurysm requiring selective embolization, one urine leak and 5 return visits to the emergency room for pain.

**Conclusion:** Tubeless PCNL remains a viable option for select patients. The specific technique utilized is dependent upon physician preference. The application of fibrin sealant to the nephrostomy tract can alleviate drainage in the immediate postoperative period.

#### **VP26-06 ENDOUROLOGICAL TREATMENT OF PYELOGENIC CYST: SELECTION CRITERIA AND TECHNICAL DETAILS FOR SPECIFIC APPROACH**

A. Tasca, F. Paolo, G. Benedetto, E. Bratti, E. Scremin, F. Nigro—Italy

**Background:** Mini-invasive treatment of pyelogenic cyst is recommended since it seems preferable with respect to surgery for a more favourable cost/benefit ratio.

**Methods:** In the last 6 years, 20 patients affected by pyelogenic cyst (in 15 cases containing stones) underwent mini-invasive treatment in our Department. Four different approaches were used: 1) transurethral ureterorenoscopy (6 cases); 2) percutaneous approach (PCN) a) directly to the cyst (7 cases) or b) indirect (3 cases): trough inferior calyx (laser incision of diverticular orifice and lithotripsy); 3) laparoscopy—transperitoneal approach (3 cases)/retroperitoneal approach (1 case): insertion of 4 trocars, marsupialization of cyst (stone removal), cauterisation of epithelial layer, suture of diverticular orifice.

**Results:** Treatment was successful in 18/20 cases (90%). On case of urine leakage following laparoscopic approach was resolved with a nephrostomy drain. 2 transurethral approaches failed (orifice not reachable, underwent PCN; intense local fibrosis and impacted stone required partial nephrectomy). One patient was submitted to open surgery after unsuccessful PCN. Slight reduction of volume and efficient drainage of cyst were evident at 3 month IVP in remaining cases treated conservatively. Postoperative CT scan documented a renal scar in cases approached laparoscopically.

**Conclusion:** Mini-invasive approach to pyelogenic cyst proved to be safe and efficient. Selection criteria for each approach can be defined: 1) small diverticulum of a compliant collecting system reachable with flexible ureterorenoscope; 2a) posterior cyst of medium size (containing stones); 2b) anterior diverticulum not reachable with transurethral approach or containing consistent stone burden; 3) large diverticula covered by thin parenchymal layer.

#### **VP26-07 PCNL IN SINGLE KIDNEY PATIENTS: TEN YEAR EXPERIENCE**

M. Darabi mahboub, R. Taghavi, M. Rahmani—Iran

**Background:** PCNL is one of the effective therapeutic methods for renal stones with a relative high success rate. Single kidney individuals develop renal calculi just the same as people with two kidneys and PCNL in single kidney. Our research is about PCNL in single kidney patients.

**Methods:** Between 1995 and 2005, 11 patients (minimum age was 6 and maximum was 68 years) with single kidney undergone PCNL. 7 patients had a single stone in pelvis, three had stones in inf. Calyces and one patient had multiple stones. Routin laboratory tests and IVP were performed in all patients. Three patients underwent tubless method and seven patients the standard one. Because of narrow infandibulum in one patient access to system was impossible.

**Results:** In 10 patients we got access to the system and after nephroscopy target stone was removed. In one person access to the system was impossible. In two patients because of remained residual calculus Dj catheter was inserted and patients referred for ESWL. In three patients one week after operation ultrasonography showed retroperitoneal hematoma. After the operation three patients became febrile whom were treated medically.

**Conclusion:** Even though in single kidney patients with renal calculus PCNL may be with serious. Complications that may result in loss of the kidney's. If we want to use PCNL in single kidney patient with calculus, Special care should be exerted before the operation.

#### **VP26-08 PERCUTANEOUS NEPHROLITHOTOMY (PNL) IN PATIENTS WITH SPINAL DEFORMITIES**

I. Kartalas Goumas, H. Yasser, P. Bernardini, E. Itri, A. Del nero, E. Montanari

**Background:** To present our experience with PNL in patients with spinal deformities.

**Methods:** PNL was performed in 8 renal units of 7 patients affected by severe scoliosis. The stones were pyelic in 5 cases, caliceal in 1 and staghorn in 2. Mean stone burden was 441 mm<sup>2</sup>. Respiratory function was investigated thoroughly during the anesthesiological evaluation. 3 patients had respiratory dysfunction due to the thoracic deformity. In all patients a preoperative CT scan was performed in order to evaluate accurately the renal anatomy. PNL was performed in the prone position in 4 cases and in the supine position in 4 cases. An ultrasound guided fluoroscopy adjusted puncture was performed in all patients to gain access into the renal cavities. Because of the dysmorphic body habitus special techniques of patient positioning were used.

**Results** 8 PNL were performed. The mean number of the renal access was 1.3. Mean operative time was 121 minutes. There was 1 major complication (14%) due to renal hemorrhage that required embolization. 3 cases required further combination treatment (2 SWL, 1 retrograde intrarenal surgery). 6 cases were stone free (85%) at six months.

**Conclusion:** PNL in patients with spinal deformities is feasible but may be challenging. The difficulty of percutaneous access and patient positioning and the risk of cardio-pulmonary distress due to the dysmorphic body habitus may be of concern for a major risk of complications during PNL. An accurate preoperative evaluation and experience are required in order to perform a safe and efficacious PNL.



### VP26-08 PCNL UNDER REGIONAL ANAESTHESIA-A STUDY OF 750 CASES DR.ULHAS SATHAYE SAHAYOG SPECIALITY HOSPITAL, JAMNAGAR, INDIA

U. Sathaye

**Background:** PCNL for urolithiasis was performed under regional anaesthesia in a single centre. The results are shown to impress the efficacy of this technique.

**Methods:** 750 cases underwent PCNL for stone disease in the past 8 years. The cases were administered either spinal or epidural anaesthesia with or without sedation. All were in prone position. The puncture was either sub or supracostal. Bilateral same stage was performed wherever indicated. The punctures were up to 5 for total clearance in one or 2 stages. Nephrostomy was placed in majority. No patient had a primary urethral catheter. Nephrostomy removal was at 2 or 3 days. Follow up was at 1 week.

**Results:** 710 patients underwent the procedure. M:F ratio was 2:1. Age range was from 11 to 74 years. 22 cases had same sitting bilateral PCNL. 2 or more punctures were needed in 64 cases. Deranged renal function was in 104 patients. The operative time ranged from 14 to 200 minutes. Urethral catheter is not routinely required. Hospital stay was from 2 to 6 days. Stenting was needed in 7%. Residual fragments were seen in 5.5% cases. Transfusion incidence was less than 1%. 6 cases had secondary bleeding and 1 required a nephrectomy. No case needed embolisation. There was 1 death unrelated to the procedure. Patient compliance with regional anaesthesia was satisfactory in the majority.

**Conclusion:** PCNL under spinal or epidural anaesthesia is safe, possible and cost effective. Patient comfort is good and anaesthesia complications are negligible.

### VP26-10 FULL-HD DIGITAL TECHNOLOGY IN PERCUTANEOUS APPROACH OF PYELOCALICEAL LITHIASIS

B. Geavlete, V. Mirciulescu, R. Multescu, P. Geavlete—Romania

**Background:** Introduction of full high definition (full-HD) technology significantly improved the visibility during endoscopic procedures. Our study aimed to determine the practical advantages of using the full-HD video chain during percutaneous approach of pyelocaliceal lithiasis.

**Methods:** We evaluated 21 percutaneous nephrolithotomies using the full-HD video chain. In 15 cases, we used exclusively the rigid nephroscope and in 6 cases this endoscope was associated with the flexible one. The data were compared with the results of 21 standard percutaneous nephrolithotomies. A single urologist noted scores between 1 and 5 points for the overall visibility, the ease to identify some anatomical elements and the speed of catching the stone fragments with various extractors.

**Results:** The success rate was 100% in patients with full-HD PNL and 95.2% in the control group. In 1 case, descendant migration of a stone fragment imposed retrograde ureteroscopic approach. The scores in the study and control group were 4.86 and 4.43 for overall visibility, 4.71 and 4.10 for the ease to identify some anatomical elements and 4.62 and 4.10 for the speed of catching the stone fragments with various extractors.

**Conclusion:** Full-HD video chain offers a superior image quality by comparison to the conventional one. Better visibility improves the ease to identify some anatomical elements and the speed of catching the stone fragments with various extractors, thus directly influencing the method's performances.

### VP26-11 PREVIOUS OPEN NEPHROLITHOTOMY: DOES IT AFFECT TUBELESS PERCUTANEOUS NEPHROLITHOTOMY (PCNL) EFFICACY AND SAFETY?

B. Lojanapiwat—Thailand

**Background:** Tubeless percutaneous nephrolithotomy (PCNL) in selected patients is found to be safe and can reduce postoperative discomfort without increasing complications. The challenges of PCNL in patients who had history of open nephrolithotomy are decrease mobility of the kidney and distorted of renal collecting system, conditions that may increase retained stone and hemorrhagic complications. We compared the efficacy and safety of the tubeless versus the standard PCNL in the patients who had previous open nephrolithotomy.

**Methods:** Percutaneous nephrolithotomy (PCNL) was performed in 104 patients who had previous open nephrolithotomy which was 45 tubeless PCNL (Group I) and 59 PCNL with standard routine postoperative nephrostomy tube (Group II). Inclusion criteria of all patients was the patients with one percutaneous renal access, no significant bleeding and residual stone. The success rate, operative time, hospital stay and ensuing complications were compared between both groups.

**Results:** Patient's demographic data was not different between both groups. Infundibular stenosis and ureteropelvic junction obstruction was found in 2 and 7 cases of group I and group II respectively. The success rate, operative time and complication was not significant different between both groups. Hospital stay was 3.53 day and 5.39 day of group I and group II respectively,  $p < 0.001$ . Analgesic usage was less in tubeless group ( $P < 0.001$ ).

**Conclusion:** Tubeless percutaneous nephrolithotomy in patients with previous open nephrolithotomy is proved to be safe and effective as determination by the decrease hospital stay and analgesic usage.

### VP26-12 COMPARISON THE RESULTS AND COMPLICATIONS BETWEEN STANDARD AND TUBELESS PCNL

M. Darabi Mahboub, R. Taghavi, J. Sadidi, N. Akbari—Iran

**Background:** Renal caculi is the commonest urological disease that needs intervention procedure. Percutaneous nephrolithotomy is the best international treatment choice with lowest side effects. It is an economical method that has been used in Iran. PCNL is done by two methods: 1-Tubeless 2-Standard.

**Methods:** All patients who underwent operation of PCNL by standard or tubeless methods in urology ward of Imam Reza hospital, during the years of 2004–2005, were enrolled into the study. After reviewing the files of these patients, those with incomplete files were excluded. Thus 60 subjects were selected in 2 groups each group included 30 patients.

**Results:** Obtained results indicated that post operation complications in tubeless method such as hematoma, bleeding and fevered infection were 16.6%, 3.3% and 6.7% respectively. The complications for standard method such as fevered infection and pelvic rupture were 13.3%, 16.6% respectively. Also in operation with tubeless method the duration of operation and hospitalization were shorter than the subjects operated by standard method. This, in turn, resulted in less costs for treatment.

**Conclusion:** The tubeless PCNL method is more effective than standard method that surgeon may use it optionally for the patients without pelvic rupture and bleeding.

### VP26-13 MANAGEMENT OF NEPHROLITHIASIS IN AUTOSOMAL DOMINANT POLYCYSTIC KIDNEYS

A. Patel, Baishya, A. Ganpule, M. V, R. Sabnis, M. Desai

**Background:** To evaluate available options for management of nephrolithiasis in patients with autosomal dominant polycystic kidney disease.

**Methods:** Retrospective analysis was conducted in autosomal dominant polycystic kidney disease patients with nephrolithiasis in last 15 yrs.

**Results:** A total of 22 renal units in 18 patients were studied, of which 8 renal units (7 patients) required intervention. Male female ratio was 5:1. The mean age of the patients was 43.3 yrs (range 23 to 60 yrs). The most common presentation was pain and hematuria (27.7% each). Mean serum creatinine was 7.2 mg/dl (range 0.8–18.1 mg/dl) at presentation. Mean stone size was 115 mm<sup>2</sup> (range 36 to 980 mm<sup>2</sup>). Most of the stone were calyceal (40.9%). Treatment offered were open nephrectomy for non functioning infected kidney (n = 1), extracorporeal shock wave lithotripsy (n = 2), ureterorenoscopy (n = 3) and percutaneous nephrolithotomy (n = 2). All URS and PCNL patients had complete clearance while both ESWL had clinically significant residual stone (more than 4 mm). One failed ESWL patient required ancillary procedure (RIRS) and the other was kept on observation. Mean follow up after treatment was 2.2 yrs (1 month–6 yrs). No patient had major complication.

**Conclusion:** Nephrolithiasis in ADPKD is a common association. Small non-obstructing stone in autosomal dominant polycystic kidney diseases can be treated conservatively ESWL offers poor clearance rates in ADPKD. Percutaneous procedure is safe and effective when indicated. RIRS is a viable, effective option alternative to ESWL in such situations.

### VP26-14 LOWER POLE FLUOROSCOPIC-GUIDED PERCUTANEOUS RENAL ACCESS: WHICH CALYX IS POSTERIOR?

B. Eisner, J. Cloyd, M. Stoller—MA

**Background:** Urologic textbooks consistently refer to the most medial lower pole calyx seen on fluoroscopy as being posterior. We undertook this study to determine the orientation of the lower pole calyces to define the optimal site for lower pole percutaneous renal access.

**Methods:** A retrospective review was performed of 101 renal units for patients who underwent routine contrast-enhanced abdomen/pelvic computed tomography (CT) scan. Delayed supine images of the renal collecting system were analyzed for the study. Axial and coronal CT scans were evaluated by two observers. Exclusion criteria were as follows: history of nephrolithiasis, history of renal surgery (open, laparoscopic, endoscopic, percutaneous), CT scan evidence of ipsilateral renal parenchymal or collecting system lesion.

**Results:** CT scans were analyzed for 101 renal units (50 left, 51 right). For the 42 renal units with 2 lower pole calyces, the most medial calyx on coronal imaging was anterior facing in 41 kidneys (95.2%), was the most anterior positioned calyx in 39 kidneys (92.9%), and was the most posterior positioned calyx in 2 kidneys (7.1%). Of the 59 renal units with 3 lower pole calyces, the most medial calyx on coronal imaging was anterior facing in 55 kidneys (93.2%), was the most anterior positioned calyx in 49 kidneys (84%), and was the most posterior positioned calyx in 4 kidneys (6.8%).

**Conclusion:** For percutaneous lower pole renal access, the most medial calyx on coronal CT imaging and therefore retrograde opacification using fluoroscopy is almost always anterior-facing and is the most anterior positioned in the majority of kidneys. Percutaneous lower pole puncture should be directed at the more lateral calyces as their posterior position and orientation provides optimal access to the collecting system for most cases.

### VP26-15 PERCUTANEOUS NEPHROLITHOTOMY (PCNL): COMPARISON OF ALKEN TELESCOPIC AND ONE-SHOT METALIC CONE-TIP DILATOR

M. Hosseini, A. Aminsharifi, A. Aryafar, D. Hosseini Niashiran—Iran

**Background:** Today percutaneous nephrolithotomy become standard treatment for large renal stone. Nephrostomy tract dilation usually perform with Alken telescopic metallic dilators. We compare cone-tip metallic dilator which help to make tract in one-shot method.

**Methods:** Ninety-seven patients, 56 male, 31 female, mean age 43.5 (21–69), mean stone size 32 mm (27–58), who were candidate for PCNL randomly divided in two groups (A, n = 51 and B, n = 46). In both groups after puncture of calyx by chiba needle and sending guide-wire into system ball-tip 9F dilator pushed on it. In group A telescopic (Alken) dilators 9–27 F pushed on it under fluoroscopy, Amplatz sheath 28F put in PCS and PCNL done. In group B a cone-tip 27 F metallic dilator (new device) sent on 9F in one-shot method, and Amplatz pushed on it.

**Results:** Access to system achieved in all cases of both groups. Perforation of renal pelvis occurred in 4 cases of group A and 2 of group B. No any other complications such as severe bleeding or bowel injury. Duration of fluoroscopy and operation was less in group B (Mean: A, 2.3 and B, 1.1 min.).

**Conclusion:** One-shot nephrostomy tract dilation by metallic cone-tip dilator seems safe and as effective as telescopic dilators, with shorter radiation exposure and no more complication.

### VP26-16 RESULTS OF PERCUTANEOUS NEPHROLITHOTOMY (PCNL) OF UPPER CALICES WITH SUBCOSTAL ACCESS

M. Rahmani, M. Darabi Mahboub

**Background:** Intercostal or supracostal access tract is usual access for percutaneous nephrolithotripsy (PCNL) for upper calices stones. But pleural complication of these tracts are high. In this study tried to treat upper calices stone with subcostal access.

**Methods:** 17 patients (12 males, 5 females) with stones limited to upper calices, candidated for PCNL (7 left kidneys, 10 right kidneys). Ultrasonography and intravenous urography were performed for all patients before surgery. Two patients had abnormal upper calices anatomy and malrotation, therefore deleted from study. In 15 patients PCNL performed in prone position and access is made at deep inspiration from subcostal with fluoroscopic guidance. After access to upper calices guide wire inserted and dilatation of tract up to 28 or 30 Fr informed. After insertion of 28 or 30 Fr Amplatz sheath nephroscopy performed.

**Results:** In all patients access to system and nephroscopy is performed in prone position, In 5 patients stones of less than 10 mm extracted with grasps. In 10 patients after pneumatic lithotripsy, particles of tones removed. 6 patients had residual stones of greater that 5 mm in minor calices that in 4 patients after single ESWL resolved. 3 patients needed infandibular dilatation for pyeloscopy.

No infection, transfusion, pneumothorax, hydrothorax, respiratory discomfort in operation and post operation period were seen. In one patient a perirenal collection of liquid with diameter of 5 cm was detected. In post operation sonography control that resolved and in control sonography one week later disappeared 3 weeks later.

**Conclusion:** PCNL with subcostal access for upper calices stones is a feasible safe. With low complication and can be performed in stead of intercontral access tracts that pass pleura and have high pleural and respiratory complications and discomforts.

### VP26-17 WISDOM OF DOING TUBELESS PCNL: RANDOMIZED PROSPECTIVE CONTROLLED STUDY OF EARLY REMOVAL OF EXTERNAL BODY TUBES VS. TUBELESS PCNL

S. Mishra, A. Kurien, A. Ganpule, V. Muthu, R. Sabnis, M. Desai

**Background:** We established the efficacy of early removal of nephrostomy drain after PCNL to challenge the wisdom of tubeless PCNL.

**Methods:** A total of 22 patients were randomized to either group 1 (early nephrostomy removal) or group 2 (tubeless) during a 1 month study period. Inclusion criterions for the study were simple stone less than 3 cm size, no significant bleeding, no perforation, single tract access and on table complete clearance. In group 1, a 20 F nephrostomy, 6 F ureteric catheter and foley catheter while in group 2; only a 6 F ureteric catheter and foley were placed at the completion of the procedure. A non contrast CT scan was done on the morning of post operative day 1 prior to the removal of all body tubes and patient discharged subsequently. The parameters studied were stone clearance, hospital stay, analgesic requirement, post-operative complications and auxiliary procedures.

**Results:** In spite of on table 100% clearance, CT clearance was 81.8% vs. 72.7% in groups 1 and 2, respectively. The analgesic requirement, hemoglobin drop, urine leak and hospital stay in either groups were  $72.2 \pm 51.8$  vs.  $68.2 \pm 46.2$  mg ( $p = 0.25$ ) tramadol,  $1.6 \pm 0.7$  vs.  $1.6 \pm 0.9$  gm% ( $p = 0.39$ ),  $13.9 \pm 6.3$  vs.  $7.1 \pm 14.2$  ( $p = 0.018^*$ ) hours and  $60 \pm 12.8$  vs.  $70.2 \pm 18.5$  hours ( $p = 0.45$ ), respectively. Complications noted were early hematuria in 0 vs. 3 ( $p = 0.21$ ), DJ stenting for residual fragments 0 vs. 1, post operative fever 2 vs. 0, respectively. 1 patient in the early tube removal required check nephroscopy for a residual fragment. Overall clearance including retreatment was 90.9% vs. 72.7% ( $p = 0.009^*$ ), respectively.

**Conclusion:** Early tube removal can be considered as an accepted standard of care with preserved advantages of Tubeless PCNL.

### VP26-18 PERCUTANEOUS NEPHROLITHOTOMY IN PATIENTS WITH THE HORSESHOE KIDNEY

S. Zenkov, A. Nemenova, K. Berestennikov—Russia

**Background:** The selection of the treatment method in patients with the abnormal kidneys is not always simple. At present the open surgery is performed only in the complicated cases. Extracorporeal shockwave lithotripsy has great significance for stone fragmentation but it has limitations due to presence of abnormal anatomical conditions for elimination of the stone fragments in this category of patients. The development of endoscopic technologies led to the fact that in the present century near 25% such patients undergo endoscopic treatment, whereas in 1980–1990 y.y. they were only 5%. This increase is caused by both the improvement of percutaneous technique and by using of flexible ureteroscopy and laser technology, and so laparoscopy technologies. The difficulties

of the percutaneous surgery of horseshoe kidney are caused by atypical structure and arrangement of renal collecting system, abnormal vasculature and by atypical anatomical interrelations with the surrounding organs.

**Methods:** In the last 5 years we performed percutaneous nephrolithotomy (PCNL) in 12 patients with the horseshoe kidney (9 male and 2 female of 45–73 y.o.). The examination, included ultrasound inspection, intravenous urography, computer tomography (in 8 patients) and dynamic nephroscintigraphy (7), confirmed the presence of the stone from 1.0 to 3.5 cm, presence or absence of pelvic and calices dilation and the degree of kidney function reduction. All patients had pyelonephritis in anamnesis. 1 patient had nephrostomy tube, inserted during open operation at which stone was not found. All operations are carried out under the epidural anesthesia and included pneumatic or ultrasonic lithotripsy and lasted from 30 to 120 min. In all cases the puncture of kidney was performed more medially and vertically and directed through calyx towards the stone. In 1 patient puncture from the side opposite to the stone-contained part of the horseshoe kidney was required. In 1 case the existent post-operative nephrostomy access was not adequate for stone visualization, which required additional puncture. In the postoperative period nephrostography was carried out in all patients.

**Results:** In all cases stone was removed completely without residual fragments. Blood transfusion did not required in any case. Impairment of urinary passage in upper urinary tract was not founded in any case. Nephrostomy tube was removed 4–8 days after operation.

**Conclusion:** We consider that PCNL is optimal way for stone removal in patients with the horseshoe kidney. The detailed examination of renal collecting system anatomy in each individual patient makes it possible to select optimal percutaneous access and thus to ensure success and to avoid complications of percutaneous removal of stones from the horseshoe kidney.

### VP26-19 MANAGEMENT OF COMPLETE URETEROPELVIC OBSTRUCTIONS WITH ANTEGRAD PERCUTANEOUS TECHNIQUE

S. Bedir, M. Zor, L. Tahmaz, M. Kilciler, Y. Ozgok, M. Dayanc

**Background:** The traditional treatment of iatrogenic complete ureteral obstruction is open surgery. An easy endourological technique, re-canalization of the ureter by guidewire puncture under fluoro-endoscopic control with antegrade fashion was described.

**Methods:** We presented a 34 years old male patient with complete ureteropelvic junction (UPJ) stenosis after pyeloplasty. The patient was presented with left flank pain. His intravenous urography revealed grade 3 hydronephrosis. Percutaneous nephrostomy was placed to the left kidney. Antegrad and retrograd pyelography was performed and complete UPJ stenosis was confirmed. The stricture was one mm length. Initially the percutaneous access to the left kidney was performed. Under direct vision of the UPJ region, transluminal puncture is performed using the stiff end of a 0.035-inch guide wire, which was introduced through the open-end ureteral catheter with retrograde approach. A true true access was performed. Finally balloon dilatation of the UPJ was performed and an endopyelotomy catheter was placed.

**Results:** Continuity of the ureter was restored. The double J stents were removed 3 months later and antegrade pyelography revealed adequate contrast passage through the UPJ without extravasation

of urine. But 6th month urography revealed hydronephrosis and diuretic scan demonstrated inadequate renal clearance and open surgical repair required.

**Conclusion:** Although a very satisfactory result was not achieved in our case, more cases are needed to show if it can be an alternative to conventional surgical repair. However, we believe that this minimally invasive technique can be used for short obliterated as the first treatment option.

### VP26-20 MINI-INVASIVE TREATMENT OF CALCULOSIS IN URINARY RENO-URETERAL MALFORMATIONS: OUR EXPERIENCE

A. Scavuzzo, M. Puglisi, A. Costa, M. Falsaperla, A. Bonaccorsi, A. Saita—Italy

**Background:** A retrospective evaluation of our experience in mini-invasive treatment for urinary calculosis in patients with reno-ureteral malformations.

**Methods:** From January 2001 to February 2009 we treated 1005 patients with calculosis. 24 of them were affected by congenital anomalies: 1 renal cross ectopia, 2 pelvic ectopic kidney (1 lombo-pelvic, 1 iliac-pelvic) 7 horseshoe kidney, 11 caliceal diverticulum (2 incomplete double district, 1 with complete). Performed procedures were: SWL, RIRL, URS and PCNL. The case with renal cross ectopia, were presenting an inferior caliceal stone >2 cm, and

it was treated by PCNL. The ectopic lombo-pelvic kidney, was treated with RIRL. Among the 7 patients with horseshoe kidney, 2 underwent SWL, 3 were treated with RIRL, 2 with PCNL. Among the 11 patients with caliceal diverticulum (II-III Dretler), 9 presented calculi in middle and upper calicial groups <1.5 cm and were treated with RIRL after balloon dilation of diverticular neck or laser incision, 2 presented lower calicial diverticulum with stones >2 cm and were treated by PCNL. The 3 cases with double district underwent URS.

**Results:** The endoscopic approach were feasible in 91.67% of the cases (PCNL 20%, RIRL 62%, URS 8%). In 8.33% of cases the endoscopic approach failed and required conversion to open surgery. type of anomaly N. casesi Treatment Stone Free failure Renal cross ectopia1PCNL CIRFNoPelvic ectopic kidney1RIRLYesNoIliac-pelvic1RIRLNoTrattamento openHorseshoe kidney 72 SWLNo1 CIRF/ 2 Yes1 Yes/No Trattamento open3 RIRL2 PCNLCaliceal diverticulum 114RIRL5RIRL + ESWL2 PCNLYes3 Yes - 2 CIRFYesNoIncomplete double district 1URSYesNoComplete double district 2URSYesNo

**Conclusion:** Even in cases with urinary malformations the endoscopic approach can lead to complete resolution, except in cases of kidney rotations and considerable ureteral malformations where conversion to open or laparoscopic surgery is unavoidable.

## VP27: LAPAROSCOPY-KIDNEY 4

### VP27-01 OUTCOME OF RENAL FUNCTION IN RETROPERITONEAL LAPAROSCOPIC PARTIAL NEPHRECTOMY WITH ICE SLUSH COOLING

T. Aoyagi, A. Sazawa, T. Harabayashi, S. Maruyama, N. Shinohara, K. Nonomura—Japan

**Background:** Aiming to reduce warm ischemia damage, we routinely perform a 15-minutes ice slush cooling after hilar clamp and thereafter start cutting procedure in retroperitoneal laparoscopic partial nephrectomy (LPN). We reviewed the decrease of renal differential function (RDF) mainly assessed by MAG3 scintigraphy and evaluated the appropriateness of our procedure.

**Methods:** From August 2003 to October 2008, LPNs with retroperitoneal approach were performed in 55 patients with small renal masses. In 46 cases, renal scintigraphy was performed before and 6 months after surgery. The 46 patients were divided into three groups by clamping time [group 1: 30–45 min (n = 15), group 2: 46–60 min (n = 15), group 3: >60 min (n = 16)]. Loss of RDF was compared between the three groups.

**Results:** Patients and tumor characteristics were as follows. Medians for age, tumor size, preoperative creatinine and preoperative RDF were 60 years, 2.4 cm, 0.7 mg/dl, 49.1%. Medians for clamping time, serum creatinine levels at 6 months after surgery and postoperative RDF were 55 min, 0.8 mg/dl and 40.7%. Median loss of RDF was 9.1% (range, 0.4–34%), respectively. Regarding the influence of clamping time, there was not a significant difference in loss of RDF between the three groups (group 1: mean 9.1%, group 2: mean 8.7%, group 3: median 11%, one way ANOVA test, p = 0.57).

**Conclusion:** Our data showed that ice slush cooling would be effective to extend the limits of warm ischemic time in LPN.

### VP27-02 LAPAROSCOPIC NEPHROURETERECTOMY FOR UPPER URINARY TRACT TRANSITIONAL CELL CARCINOMA: LONG-TERM ONCOLOGIC OUTCOMES

S. Ha, Y. Park, J. Ku, H. Jeong, C. Kwak, H. Kim

**Background:** To evaluate the oncologic efficacy of laparoscopic nephroureterectomy for upper urinary tract transitional cell carcinoma.

**Methods:** Between December 1998 and January 2008, 50 patients who underwent laparoscopic nephroureterectomy with transitional cell carcinoma were identified. 106 patients who underwent open nephroureterectomy during the same period were also identified. Medical records were retrospectively reviewed to assess the surgical and oncologic outcomes.

**Results:** Median follow-up periods were 43 months (8–138) in the laparoscopy and 54 months (7–180) in the open group. Mean operative time was 239 and 217 minutes (p = 0.069), mean estimated blood loss was 247 and 418 ml (p = 0.001), number of days of IV patient control anesthesia use was 2.7 and 3.3 days (p = 0.021), and postoperative hospital stay was 6.6 and 8.5 days (p < 0.001) for the laparoscopy and open group, respectively. Postoperative complication happened 3 case (6.0%) in the laparoscopy and 19 cases (17.9%) in the open group (p = 0.313). There was no significant difference in pathologic T stage and nuclear grade in the two groups. No statistically significant difference was found in the

5-year disease-specific (75.2% vs. 83.0%,  $p=0.364$ ) and 5-year metastasis-free (63.1% vs. 72.4%,  $p=0.423$ ) survival rates between the laparoscopy and open group.

**Conclusion:** Laparoscopic nephroureterectomy is a less invasive surgical option with comparable oncologic outcomes with open nephroureterectomy for the treatment of upper urinary tract transitional cell carcinoma.

### VP27-03 LAPAROSCOPIC PARTIAL NEPHRECTOMY BY CLINICAL STAGE: COMPARING OFF-CLAMP VERSUS COMPLETE HILAR-CONTROL

S. Rais-bahrami, A. Herati, A. George, S. Andonian, L. Richstone, L. Kavoussi

**Background:** We aim to show the operative feasibility and oncologic efficacy of performing off-clamp laparoscopic partial nephrectomy (LPN), avoiding warm ischemia, not only for patients with cT1a tumors but also those with a larger tumor burden.

**Methods:** Retrospective review of all LPN between January 2006–June 2009 was performed, stratifying 259 patients by clinical T-stage (cT1a=201, cT1b=42, cT2=16). Perioperative and postoperative parameters were investigated comparing patients who underwent LPN with hilar-control (n=170) versus those who had off-clamp LPN (n=89) collectively and within each clinical stage cohort.

**Results:** There was a significantly higher proportion off-clamp LPN for cT1a tumors (38.3%), compared to cT1b (19.0%) and cT2 (18.8%),  $p=0.012$ . Off-clamp versus hilar-control LPN patients had similar estimated blood loss within each stage cohort: cT1a ( $p=0.76$ ), cT1b ( $p=0.37$ ), and cT2 ( $p=0.06$ ), with no difference in either intraoperative or postoperative transfusions rates. Also, there was no difference in the operative time or length of hospitalization comparing off-clamp to hilar-control LPN by stage: cT1a ( $p=0.21$  and  $p=0.43$ ), cT1b ( $p=0.30$  and  $p=0.08$ ), and cT2 ( $p=0.52$  and  $p=0.56$ ), respectively. In our series, one case had a positive margin on final pathology and one case was converted to open partial nephrectomy, both with cT1a tumors undergoing hilar-control LPN. One case of off-clamp LPN was intraoperatively converted to hilar-control LPN with a hilar tumor measuring 2.6 cm.

**Conclusion:** LPN can be performed off-clamp in patients with organ-confined renal tumors without compromising the operative time, blood loss, or length of hospitalization. Rates of positive margins, blood transfusion, and conversion to open surgery were very low and limited to patients with cT1a disease in our series.

### VP27-04 LAPAROSCOPIC PARTIAL NEPHRECTOMY—LEARNING CURVE FOR INITIAL 87 CASES

Y. Naitoh, A. Kawauchi, K. Kamoi, J. Soh, F. Hongo, T. Miki

**Background:** We hypothesized that the indications, perioperative parameters and complication rates of laparoscopic partial nephrectomy (LPN) may have changed during our experience of initial 87 cases. These LPNs were compared during 2 to 3-year periods.

**Methods:** Contemporary series of 30 LPNs performed from July 2007 to June 2009 (group III) were compared with 30 LPNs from Jan 2003 to Aug 2005 (group I) and 27 LPNs performed from Sep 2005 to June 2007 (group II) with regard to indications, perioperative parameters and complication rates.

**Results:** There were no significant differences among groups I, II and III with regard to age (60, 57 and 62 years), gender (77%, 89%

and 87% male) and tumor size (2.1, 2.1 and 1.8 cm). We used warm ischemia more frequently than cold ischemia with experience (67% for initial 30 cases to 100% for latest 30 cases). Despite increased application, warm ischemia time in the more recent case was shorter (39.5, 34.2 and 29.6 min,  $p=0.0040$ ). Overall complication rate was lower in the recent cases (13%, 18% and 3%,  $p=0.18$ ). Positive surgical margins were not documented throughout our experience. Percent increase of serum creatinine was significantly lower in the recent cases (54%, 43% and 24%,  $p=0.0002$ ).

**Conclusion:** We have treated 87 cases of small renal tumor with LPN. With experience these tumors are being successfully treated, preserving more renal function with shorter warm ischemia time, while achieving low complication rates and excellent short-term oncologic outcome.

### VP27-05 MANAGEMENT OF POSITIVE SURGICAL MARGIN DURING THULIUM LASER ASSISTED LAPAROSCOPIC PARTIAL NEPHRECTOMY

Y. Bayazit, I. Aridogan, D. Abat, A. Aytutuldu, S. Erdogan, S. Doran

**Background:** Laparoscopic partial nephrectomy (LPN) is a developing treatment modality for small renal tumors. Management of positive surgical margins (PSM) following laparoscopic partial nephrectomy (LPN) is still controversial. A Thulium laser assisted LPN case in which an immediate secondary excision performed under warm ischemia because of PSM determined with an intraoperative frozen section examination is presented.

**Methods:** LPN was performed with transperitoneal approach using 4 trocars in a 37 years old male patient with 2 cm. mass in the mid-lateral part of the right kidney. Renal hilum was prepared and a vascular tape was placed loosely around the pedicle. A home-made apparatus was developed for 550  $\mu\text{m}$  laser fiber to use in laparoscopy. Excision was performed with Thulium-YAG laser leaving 3–5 mm of safety margin around the tumor and the specimen extracted. The frozen examination revealed tumor thrombus in the surgical margin. A secondary excision was planned under warm ischemia and the margin was deepened for 5 mm with cold scissors. After closing the collecting system, Floseal<sup>®</sup> was applied and then parenchyma sutured over a Surgicel<sup>®</sup> bolster. At the end of the operation, there was no need for a ureteral stent since no extravasation was found on the retrograde pyelography.

**Results:** Operation and warm ischemia times were 200 and 25 minutes respectively. Estimated blood loss was 350 mL. Urethral catheter and drain were removed at 7th and 18th hours respectively and the patient was discharged at the 24th hour postoperatively. Histopathologic examination revealed Fuhrman grade II papillary renal cell carcinoma, and the surgical margins was negative on the both sides of the second specimen.

**Conclusion:** The use of frozen examination and treatment if it is positive is still controversial during LPN. Although the effect of laser energy on surgical margins in LPN is debatable, the use of laser has the advantage of that it does not necessitate hilar clamping and when a PSM is encountered during LPN, the initial use of laser provides the opportunity of a secondary excision under warm ischemia.

### VP27-06 LAPAROENDOSCOPIC SINGLE-SITE (LESS) PARTIAL NEPHRECTOMY VIA AN UMBILICAL APPROACH WITHOUT ACCESSORY PORTS

S. Rais-bahrami, M. Schwartz, A. Herati, M. Atalla, L. Kavoussi, L. Richstone

**Background:** LaparoEndoscopic Single-site Surgery (LESS) has been adopted for partial nephrectomy as an extension of conventional laparoscopy, minimizing the number of incisions used for operative access. Our aim is to present our technique of transumbilical LESS partial nephrectomy without the use of accessory trocars and perioperative outcomes of our initial experience.

**Methods:** Perioperative data was collected on LESS partial nephrectomy cases performed at our institution between July 2008 and June 2009. A total of 7 LESS partial nephrectomies were performed on 6 patients over this period of time. One patient had LESS partial nephrectomy performed 3 months apart on contralateral kidneys for treatment of bilateral renal masses. All patients underwent transumbilical LESS using one 12 mm and two 5 mm trocars through which a 5 mm flexible-tip laparoscope and a combination of flexible and conventional laparoscopic instruments were used. The 12 mm trocar allowed for bulldog clamp placement for hilar-control, used in 5 cases. The remaining 2 cases were done without clamping the hilar vessels.

**Results:** Of the 6 patients (n = 4, 66% male), undergoing 7 distinct LESS partial nephrectomy operations, the mean age was  $53.1 \pm 7.1$  years with a mean ASA score of  $1.8 \pm 0.8$ . The mean body mass index was  $30.7 \pm 2.9 \text{ kg/m}^2$ . The mean operative time was  $154.0 \pm 32.8$  minutes with a warm ischemia time of  $20.7 \pm 10.9$  minutes. The mean estimated blood loss in this series was  $314.3 \pm 446.9 \text{ mL}$  (median 150 mL), largely skewed by a single off-clamp case with a blood loss of 1300 mL. No cases required intraoperative or postoperative blood transfusions. The mean tumor size resected was  $2.5 \pm 0.6 \text{ cm}$  (range 1.7–3.5), all clear cell variants of renal cell carcinoma on final pathology, pT1a with negative margins. The mean length of hospitalization was  $2.1 \pm 0.4$  days and patients required a mean analgesic requirement of  $25.3 \pm 10.1 \text{ mg}$  of morphine equivalents. There was a notable downtrending of the patient reported visual analog pain scale (0–10) rating with each progressive postoperative day (line of best fit:  $y = -1.02x + 3.9$ ).

**Conclusion:** LESS partial nephrectomy is a feasible and efficacious operation, providing similar oncologic resection compared to conventional laparoscopy. In our early experience with LESS partial nephrectomy for T1a renal tumors, perioperative parameters analyzed were all acceptable, and expected to improve further with progression on the learning curve. Patients had a rapid convalescence with discharge from the hospital most commonly on the second postoperative day. A randomized study comparing LESS to conventional laparoscopy is needed to adequately compare the postoperative pain and analgesic requirements as well as patient satisfaction with cosmesis.

#### VP27-07 LONG TERM EXPERIENCE WITH LAPAROSCOPIC PARTIAL NEPHRECTOMY FOLLOWING SUPERSELECTIVE TRANSARTERIAL EMBOLIZATION

G. Simone, R. Papalia, A. Bove, S. Guaglianone, E. Forastiere, M. Gallucci

**Background:** We report 5 yr oncologic and functional results of 150 consecutive patients treated with laparoscopic partial nephrectomy (LPN) following superselective transarterial embolization (SAE).

**Methods:** Between August 2003 and June 2008 150 consecutive patients underwent LPN following SAE. Inclusion criteria were tumor diameter  $>4 \text{ cm}$  or intraparenchymal depth  $>1.5 \text{ cm}$ . Mean patients age 61 years (range 34 to 80), mean tumor size was 4.4 cm

(2.5 to 6.5 cm). Preoperative serum creatinine levels and renal scintigraphy were compared to 3 and 12 month ones to evaluate the preservation of renal function. CT scan and chest X ray together with abdominal ultrasound were alternatively performed at 6 month intervals.

**Results:** Pathologic analysis found benign tumors in 42 patients and renal cell carcinoma in 108 patients (35 pT1, 62 pT1b, 8 pT2 and 3 pT3a). At a median follow-up of 47 months one patients underwent laparoscopic radical nephrectomy for locally recurrent renal cell carcinoma and one patient died of cancer. Five-yr disease free survival was 97.3%. The median increase of serum creatinine levels was 0.27 mg/dL and no patients experienced chronic kidney disease (defined as  $\text{GFR} < 60 \text{ mL/min/1.73m}^2$ ) during follow-up. When matching preoperative with 3 month and 1-yr renal scintigraphy there was a progressive recovery of renal function, the percent decrease of split renal function being 9% at 3 month and 5% at 1-yr evaluation.

**Conclusion:** SAE provides an effective hemostasis, allowing to perform LPN without hilar vessel clamping and so without warm ischemia threshold time. This technique represents a rationale and effective solution of major technical challenges of LPN which remains bleeding control and warm ischemia time threshold. Oncologic results compare favourably with literature results and renal function can be effectively preserved. SAE may be widely reproduced and could be a starting point to perform LPN out of experienced centres.

#### VP27-08 MULTICENTER EXPERIENCE WITH NON-ISCHEMIC LAPAROSCOPIC PARTIAL NEPHRECTOMY UTILIZING HABIB 4<sup>TM</sup> BIPOLAR RADIOFREQUENCY ABLATION COAGULATOR

I. Derweesh, M. Allaf, J. Berkowitz, H. Atalah, S. Stroup, S. Parekattil

**Background:** Laparoscopic nephron sparing surgery (L-NSS) has gained increasing acceptance with emerging data demonstrating equivalence of oncologic outcomes with open NSS. Concerns continue regarding prolonged warm ischemic times and longer-term renal functional outcomes. We report our initial experience utilizing the Habib 4<sup>TM</sup> laparoscopic radiofrequency ablation coagulator (Angiodynamics, Queensbury, NY) for non-ischemic L-NSS.

**Methods:** 50 cases were performed by transperitoneal or retroperitoneal laparoscopy. L-NSS involved renal dissection and hilar control; prior to specimen excision and renorrhaphy. Non-ischemic hemostasis was achieved utilizing the Habib 4<sup>TM</sup> prior to cold excision. We analyzed patient demographics, tumor/perioperative characteristics, and short term outcomes.

**Results:** Multicenter retrospective review of 50 patients (51 tumors) undergoing L-NSS between 4/2006–5/2009. Mean follow up was 8.0 months. All successfully underwent laparoscopic non-ischemic resection. Average age was 57.5 years (54% M/46% F). Average tumor size was 2.46 cm. Mean operative time was 160.42 minutes and mean estimated blood loss was 133.5 mL. Collecting system entry was made in 12 (24%). Preoperative and postoperative creatinine (mg/dL) were 1.03 and 1.08 ( $p = 0.573$ ). Preoperative and postoperative eGFR ( $\text{mL/min/1.73 m}^2$ ) were 81.0 and 78.1 ( $p = 0.613$ ). Final pathology was Renal Cell Carcinoma-35, and benign-16. All had negative margins. Eleven (22%) patients developed complications. Two (4%) developed urine leaks which resolved with conservative measures. At last follow-up, all patients with RCC were alive and cancer free.

**Conclusion:** Initial experience demonstrates that non-ischemic L-NSS utilizing Habib 4× is safe and efficacious, with excellent short-term preservation of renal function. Long-term data are needed to confirm oncological efficacy of this technique.

### VP27-09 LAPAROSCOPIC PARTIAL NEPHRECTOMY USING A MICROWAVE TISSUE COAGULATOR FOR T1 RENAL CELL CARCINOMA

N. Tanaka, K. Fujimoto, Y. Hirao—Japan

**Background:** The clinical outcomes of laparoscopic partial nephrectomy using a microwave tissue coagulator (MTC) were evaluated in our series of patients with T1a renal cell carcinoma.

**Methods:** Sixteen patients with T1a renal cell carcinoma underwent retroperitoneal laparoscopic non-ischemic partial nephrectomy using an MTC. The patients were 10 men and 6 women with a mean age of  $58 \pm 18$  years (range: 38~77). The mean of tumor diameter was 2.6 cm (range: 1.5~4.0). Laterality of the tumor was right in 5 patients and left in 11. Ten and six tumors were located in the low pole and middle portion of the kidney, respectively. Before the tumor was excised, the normal parenchyma around a tumor was coagulated every 8 mm by a needle antenna of the MTC.

**Results:** The median blood loss was 25 ml (range: 5–750) and the median operation time 182 minutes (range: 120–266). Although transfusion was not required in all patients, blood loss greater than 200 ml was seen in 3 patients among the initial cases. No patients showed intra- and post-operative urine leak from the tumor bed. There was no difference in the serum creatinine and GFR levels between in the preoperative and postoperative measurement including radioisotope examination. No patients showed local recurrence during the median followup of 15 months.

**Conclusion:** Non-ischemic partial nephrectomy using a microwave tissue coagulator (MTC) had the advantage of preserving renal function and decreasing blood loss. This procedure was safe and feasible for laparoscopic partial nephrectomy of small renal cell carcinoma.

### VP27-10 TRANSPERITONEAL LAPAROSCOPIC NEPHRECTOMY FOR GIANT HYDRONEPHROSIS

M. Baptistussi, M. Morihisa, E. Gewher, A. Martins—Brasil

**Background:** We present our experience with laparoscopic nephrectomy for giant hydronephrosis occupying the whole ipsilateral retroperitoneal space.

**Methods:** During the last year 2 men underwent laparoscopic nephrectomy for giant hydronephrosis via a transperitoneal approach. The etiology was congenital ureteropelvic junction obstruction in two patients (aged 54 and 67). All patients were symptomatic due to the hydronephrosis. Renal parameters were normal.

**Results:** Two procedures were successfully completed laparoscopically. The operating time for the other two cases was 190 min and 123 minutes and the blood loss was 150 and 50 ml respectively. No patient required blood transfusion. Postoperative recovery was uneventful and the hospital stay was 2 days and 3 days for the laparoscopic cases.

**Conclusion:** Laparoscopic nephrectomy is a good alternative to open surgery for giant hydronephrosis.

### VP27-11 LAPAROSCOPICALLY ASSISTED PERCUTANEOUS NEPHROLITHOTRIPSY IN SPECIAL CASES

M. Baptistussi, M. Morihisa, E. Gewher, A. Martins—Brasil

**Background:** Ectopic or horseshoe kidney often represents a challenge to the endourologist. The association between laparoscopy and percutaneous surgery, allows a safe, minimally invasive approach to this special cases.

**Methods:** To report 3 cases of pelvic kidneys (2 right and 1 left), and 3 cases of horseshoe kidneys. All the stones were located on the lower pole, and previous ESWL and flexible retrograde ureteroscopy were unsuccessful. A laparoscopic approach was used to displace the bowel, which covered the kidney. A laparoscopically controlled percutaneous approach was performed under total and safe vision, and the stones fragmented and removed. A nephrostomy tube was left in place and removed next day.

**Results:** no results.

**Conclusion:** We believe that laparoscopy is a very important tool in percutaneous management of distopic kidneys.

### VP27-12 THE RESULTS OF LAPAROSCOPIC NEPHRON SPARING SURGERY/NSS/ IN PATIENTS WITH KIDNEY CANCER

M. Baptistussi, M. Morihisa, E. Gewher, A. Martins—Brasil

**Background:** Laparoscopic nephron sparing surgery (LNSS) were introduced into the treatment of small tumours of kidneys to decrease stress related to surgery, limit blood loss, wound healing time and improve cosmetic effect. The aim of the study is to present the technique and results of laparoscopic nephron sparing surgery in patients with renal cancer.

**Methods:** LNSS was performed in 12 patients from transperitoneal access. Patients were qualified for the procedure in the same way as those qualified for the open nephron sparing surgery. Follow-up visits took place every six months according to the EORTC indications

**Results:** LNSS was performed in 12 patients at the age 31–67 years (average 56 years) from may 2003 to December 2008. The size of operated tumors ranged from 1.5–4.0 cm (average 2.5 cm). Postoperative blood loss ranged from 10–140 ml (average 68 ml). The average observation time after the LNSS was 38 months. No local recurrences or distant metastases were noted.

**Conclusion:** 1. LNSS is a safe alternative for open NSS. 2. LNSS result in better cosmetic affects, less blood loss and are better evaluated than open surgeries. 3. Safe intraoperative hemostasis in LNSS in highly specialized centers is the main indication for the procedure.

### VP27-13 CREATING AN OBJECTIVE ASSESSMENT OF SURGEON PROFICIENCY FOR THE HILAR DISSECTION DURING LAPAROSCOPIC NEPHRECTOMY

E. Mcdougall, H. winfield, R. Sweet, C. Sundaram, M. Desai, S. Shichman

**Background:** A reliable assessment device is necessary to objectively assess surgical proficiency. The objective of this study was to create a reliable global rating score (GRS) device for evaluating the key step, renal hilar dissection, during laparoscopic transperitoneal nephrectomy (LTN).

**Methods:** A group of 25 laparoscopic experienced urologists (LEU) determined the keys steps of the LTN procedure and a GRS for the hilar dissection technique in the initial phase of the creation of a dedicated LTN simulator. Preliminary evaluation of this hilar GRS failed to confirm reliability as an assessment device. Therefore, 6 nationally recognized expert laparoscopic urologists (FG) undertook focused discussion and deliberative inquiry to re-create

a specific GRS for the LTN hilar dissection. The GRS device was then submitted to 24 laparoscopic experienced urologists (LEU) to assess the same videotaped left LTN hilar dissection. The results of the LTN hilar dissection GRS were compared for the FG and LEU using the t-test, significance  $p < 0.05$ .

**Results:** The GRS evaluation of the LTN hilar dissection video was available from the 6 FG and 11 additional LEU. The mean total GRS for the FG was  $28 + 1.7$  points and for the LEU was  $29 + 7.6$  points ( $p = 0.72$ ). Comparison of the FG to the LEU showed that overall there was fairly good inter-rater reliability with perfect score matches in 42/65 (65%) for the FG and 55/121 (45%) in the LEU. Allowing for only one point deviation from the modal score for each group, the matches were 60/65 (92%) for the FG and 95/121 (79%) for the LEU. The two groups had the same GRS for exposure and dissection of the renal artery, respect for tissue, adequate hemostasis and choice and application of instruments.

**Conclusion:** Deliberative inquiry by experienced laparoscopic urology educators created a reliable skills assessment device for the critical aspects of the LTN renal hilar dissection with good inter-rater reliability.

#### VP27-14 DOES THE PRESENCE OF URINARY STONE DISEASE AFFECT THE PEROPERATIVE AND POSTOPERATIVE COMPLICATION RATES OF LAPAROSCOPIC SIMPLE NEPHRECTOMY?

A. Tefekli, A. Tepeler, T. Akman, M. Binbay, M. Baykal, A. Müslümanođlu

**Background:** Laparoscopic simple nephrectomy (LSN) has become the gold standard procedure for the nonfunctioning or symptomatic benign kidneys due to renal calculi, obstructive, refluxive and inflammatory nephropathies or renovascular hypertension. We aimed to assess the impact of the presence of stones on the progress and complication rates of the procedure.

**Methods:** A total of 27 patients (Group 1) with non-functioning kidney due to renal calculi, undergone to LSN, were compared to 27 patients (Group 2) with non-functioning kidney due to other reasons treated by LSN who were matched for age and body mass index (BMI). We analyzed the operation time, hemoglobin drop, hospitalization time and per-operative and postoperative complications using Satava and Clavien classification systems.

**Results:** The mean age and the BMI of the groups were similar ( $41.14 \pm 15.13$  vs.  $41.48 \pm 14.62$  years,  $26.45 \pm 2.92$  vs.  $26.84 \pm 4.37$  kg/m<sup>2</sup>). In Group-1, 5 patients had previous open renal surgery while 1 had in Group-2 ( $p: 0.19$ ). The operation and hospitalization time was significantly longer in Group 1 than Group 2 ( $123.55 \pm 38.13$  vs  $98.88 \pm 40.3$  minutes,  $3.14 \pm 1.23$  vs.  $2.55 \pm 0.93$  days) ( $p: 0.024$ ,  $p: 0.001$ ). There was no significant difference between the groups with respect to mean hemoglobin drop postoperatively ( $1.52 \pm 1.46$  vs.  $1.57 \pm 1.42$ ) ( $p: 0.9$ ). The perioperative and postoperative complication rates were higher in Group 1 but not statistically significant ( $p: 0.29$ ).

**Conclusion:** Laparoscopic nephrectomy for benign disease is called a simple procedure but may prove to be very challenging, depending on the indications for surgery. The nephrectomy of non-functioning kidney due to renal calculi is a more complex, difficult procedure with longer operation and hospitalization time, high complication rates and necessitates advanced skills and experience.

#### VP27-15 SELECTIVE ARTERIAL EMBOLIZATION (SAE) PRIOR TO LAPAROSCOPIC PARTIAL NEPHRECTOMY (LPN) AS FIRST-LINE TREATMENT OF SYMPTOMATIC RENAL ANGIOMYOLIPOMA (AML) $\geq 4$ CM: A RETROSPECTIVE ANALYSIS ON 18 CASES

U. Anceschi, A. Amici, C. Torcia, F. Peris, S. Lauretti—Italy

**Background:** The growth rate of the renal AML is associated with an increased rate of bleeding. Despite SAE appears to be safe in the acute settings to control severe complication of AML like spontaneous hemorrhage, as first-line treatment, it is associated with recurrent bleeding, persistent symptoms, lack of regression of the lesion. Nephron sparing surgery (NSS) has been described as a second-line treatment for renal AML. We evaluated the role of SAE + LPN in the treatment of AML  $\geq 4$  cm as first-line therapy. **Methods:** Between 2001–2009 we selected retrospectively 18 patients affected by symptomatic AML (hematuria 5; flank pain 13). Median tumour size was 6 cm (range 4–8). Median age of patients was 48 (31–68). All the patients underwent SAE 24 h prior to LPN. The analysis endpoint was the technical feasibility of SAE + LPN assessed by mean operative time of LPN; mean renal ischemia time; length of hospital stay; complications rate; blood transfusion rate; postoperative renal function; AML recurrence rate. We considered as AML recurrence the appearance of fat containing renal lesions on follow-up imaging with MRI/CT scan. Renal function was assessed by blood creatinine values.

**Results:** Mean operative was 95 mins. Median renal ischemia time was 17 mins. Median estimated blood loss was 80 cc. Mean length of hospital stay was 6 days; % of perioperative complications was 11% (1 case of postoperative bleeding which required blood transfusion; 1 case of urinary leakage). No recurrence in our study was observed at median follow-up of 36 months. No patients experienced symptoms recurrence. Median creatinine level at 3 months follow-up was 1,2 (range 0.8–3.2). We reported one case of chronic renal insufficiency in a patient with a solitary kidney.

**Conclusion:** LPN offers the opportunity for complete tumor resection, allows preservation of renal function and it has a low rate of recurrence. SAE prior to LPN may reduce the rate of perioperative complications related to NSS as intraoperative and postoperative bleeding. As the tumor size increase ( $\geq 4$  cm) a combined approach to the AMLs seems to be feasible and it may be a safe alternative to a single elective treatment.

#### VP27-16 THE ONLY SIGNIFICANT PARAMETER ASSOCIATED WITH DECREASED COMPLICATION RATES IN LAPAROSCOPIC NEPHRECTOMY: SURGEON'S EXPERIENCE

O. Sanli, T. Tefik, T. Mut, S. Karakus, M. Ortac, M. Tunc

**Background:** We present the complications associated with laparoscopic nephrectomies (LRP) performed or mentored by a single consultant surgeon.

**Methods:** Between September 2005 and June 2009, 131 LRP were performed, consisting of 52 simple (SN), 50 radical (RN), 18 nephroureterectomies (NU) and 11 partial nephrectomies (PN). Three patients (1 RN and 2 SN) were excluded from analysis because of requirement of open conversion due to technical reasons. Factors related to perioperative complications, including type of nephrectomy, type of approach (transperitoneal vs. retroperitoneal), BMI, ASA score and surgical experience (initial 64 cases vs. remaining 64 cases) were prospectively recorded on a database



system and then retrospectively analyzed. Complications were graded according to the Clavien grading system.

**Results:** The overall complication rate was 28.9% (37/128). Twenty-six complications (70.3%) were Clavien grade I-II, and 11 (29.7%) were grade III-IV; whereas the most common being grade II (n = 14). Overall, complications were not associated with ASA score, neither BMI nor the type of operation. However, total operative time (Spearman's rank coefficient (rs) = -0.29, p < 0.001), number of trocars used (rs = -0.44, p < 0.001), estimated blood loss (rs = -0.41, p < 0.001), hospital stay (rs = -0.26, p = 0.003) and type of approach (rs = -0.47, p < 0.001) were negatively correlated with experience of laparoscopic surgeon. Moreover, the total complication rates decreased as the experience with laparoscopic nephrectomy increased (rs = -0.19, p = 0.036). Complications were also correlated with increased transfusion (rs = 0.57, p < 0.001) and length of hospital stay (rs = 0.26, p = 0.003).

**Conclusion:** Among contributing factors, complication rates of LRP were not related with factors; such as ASA score, BMI or type of operation. The only parameter that significantly affected the complication rates was surgeon's experience.

#### VP27-17 SINGLE-CENTER COMPARISON OF STANDARD LAPAROSCOPIC SURGERY AND HAND-ASSISTED LAPAROSCOPIC SURGERY IN TREATMENT OF RENAL MASSES

R. Leveille, M. Aziz, J. Bracho ii, J. Shields, V. Bird

**Background:** Radical nephrectomy can be performed by standard laparoscopic surgery (SLS) or hand assisted laparoscopic surgery (HALS). We compare the efficacy, safety and perioperative outcome of both techniques in treatment of renal mass.

**Methods:** All patients who underwent "minimally Invasive" radical nephrectomy from 2002 to 2009 at a single institution are included in this study. Patient demographic and perioperative variables are collected and analyzed. P-Value < 0.05 was considered statistically significant.

**Results:** A total of 425 patients underwent laparoscopic nephrectomy (162 HALS and 263 SLS) by two surgeons. The mean age and Body Mass Index for HALS and SLS were 63.3 + 14 vs. 61.3 + 13 (p-value = .089) and 29.8 + 7.3 vs. 29.1 + 6.7 (p-value = .352) respectively. The Charlson Co-morbidity index was 4.55 + 1.68 and 4.9 + 1.8 (p-value = .038) HALS and SLS respectively. The estimated blood loss was 177 mL + 189 vs. 142.5 mL + 218 (p-value = 0.00) with transfusion rate of 5.6% & 2.3% (p-value = 0.07) in HALS and SLS respectively. The intraoperative complication rate was 4.9% & 7.6% (p-value = .28) for HALS and SLS respectively. The post-operative complications rate was 17.9% vs. 18.6% (p-value = .85) for both respectively. RCC was found in 85.1% and 93.1% in HALS and SLS respectively. In HALS, the mean tumor size was 5.85 + 2.67 (from 1.8 Cm to 15 Cm) and in SLS 4.87 + 2.27 (from 0.8 Cm to 15.5 Cm) (p-value = 0.00). Post-operative length of stay was 3.5day and 3.6day (p-value = 0.064) for HALS and SLS respectively.

**Conclusion:** SLS and HALS compared favorably when treating large renal masses. HALS had slightly higher intra-operative blood loss; however, no perceived clinical impact as there was no significant difference in transfusion rates. Patients undergoing HALS had significantly larger tumor size. Postoperative length of stay and perioperative complications demonstrated no significant differ-

ences suggesting that the pure and hand-assisted techniques result in similar perioperative outcomes.

#### VP27-18 IS IT POSSIBLE TO COMPLETE LAPAROSCOPIC SIMPLE AND RADICAL NEPHRECTOMY WITHOUT OPEN CONVERSION ?

A. Kural, M. Tuna, H. Akpýnar, C. Öbek, F. Atuđ, Ý. Tüfek-Türkiye

**Background:** Open conversion during laparoscopic nephrectomy is quite rare which is less frequent with hand assisted approach in the series. Recently some authors described hand assisted conversion instead of open during standard laparoscopy. Training and mentorship are the most important steps to avoid any conversion.

**Methods:** Between 2002 July and June 2009, 71 Standard laparoscopic radical nephrectomy, 11 hand assisted laparoscopic radical nephrectomy, 20 laparoscopic radical nephroureterectomy, 2 hand assisted laparoscopic radical nephroureterectomy, 52 laparoscopic simple nephrectomy and 1 hand assisted simple nephrectomy were performed consecutively between July 2002 and June 2009. All procedures were performed transperitoneally by ARK himself or by his assistance.

**Results:** We had to convert from standart to hand assisted procedure in 2 LRN and 2 LRNU. No any single open conversion was needed. In our study the mean age of the patients is 60, ASA score is 1,71, BMI is 27, 2, EBL is 334 cc. 4 patients had Clavien II, 1 patient had Clavien III and 1 patient had Clavien V complications.

**Conclusion:** Laparoscopic simple and radical nephrectomy require advanced laparoscopic training to avoid any complication and open conversion. Having experience with hand assisted technique at the beginning of the learning period is useful to prevent any open conversion. This study shows that laparoscopic simple and radical nephrectomy can be performed without open conversion from the beginning.

#### VP27-19 RETROPERITONEAL LAPAROSCOPIC RADICAL NEPHRECTOMY FOR RENAL CELL CARCINOMA: REPORT OF 88 CASES

C. Xiaoming, W. Dongwen, Z. Xuhui

**Background:** To discuss the technique of retroperitoneal laparoscopic radical nephrectomy for renal cell carcinoma, evaluate the clinical value and applied foreground of retroperitoneal laparoscopic radical nephrectomy for renal cell carcinoma.

**Methods:** Retroperitoneal laparoscopic radical nephrectomy for renal cell carcinoma was carried out in 88 cases during December 2001 to June 2008. Of these cases, there were 52 males and 36 females whose ages ranging from 35-76 years old (mean age 58 years). 39 cases had left-sided disease and 49 had right. 88 cases who had tumors from 3 cm to 9 cm in diameter (mean diameter 5.5 cm) were treated by retroperitoneal laparoscopic radical nephrectomy for renal cell carcinoma.

**Results:** In 84 of 88 cases, nephrectomies were undergone successfully by laparoscopic procedure. In 4 cases were convert to open surgery because conglutination. No case was forced to convert to open surgery because serious complications. Operative time ranged from 45-210min (mean operative time 112 min). Intraoperative blood losses were about 20-300 ml (mean blood loss 50 ml). The patients resumed activity 24 hours, began oral intake 2 days and discharged 7 days post operation. 54 cases of 88 cases

were followed-up. No local lesion and port sites metastasis in these patients occurred in 1–2 years follow-up.

**Conclusion:** Retroperitoneal laparoscopic radical nephrectomy for renal cell carcinoma was a safe, effective and efficient surgical procedure, had wide clinical applied foreground.

### **VP27-20 LAPAROSCOPIC-ASSISTED CRYABLATION FOR RENAL CANCER IS NEFRONSPARING**

L. Lund, M. Jønler, L. Pedersen, J. Abrahamsen

**Background:** The development of minimally invasive approaches to renal cell carcinoma over the last 10 years has given rise to newer therapies for these small tumours include nephron sparing surgery performed as partial nephrectomy, RFA (radio frequency ablation) or cryoablation. Cryoablation can be done open, percutaneously or laparoscopic assisted. Patients with significant comorbidities who are not suitable for open surgery may be candidates for this procedure and patients with only one kidney or a tumor in the best functioning kidney. The patient selection is very essential when you decide to offer cryoablation to patients. We present the results after laparoscopic assisted cryoablation for renal carcinoma.

**Methods:** Renal cryoablation was performed in 30 cases in 27 patients with renal carcinoma. Pre-operative work-up included blood samples, GFR, scintigram, ultrasound guided core biopsy

from tumor, and CT/MR scanning of chest and abdomen. Follow-up involved blood samples, evaluation of renal function by GFR, and CT or MRI imaging at 3 months, 6 months, 12 months, 18 months postoperative and then annually. A cryo-lesion biopsy was performed if there was an enhancement in the treated area. All data were prospectively accrued.

**Results:** We included 21 men and 6 women. Mean age was 71 years (range 49–86 years). Three patients had only one kidney. The mean follow-up time was 24 months (3–48 months). Mean tumor size was 3.5 cm (1.6–6.5 cm). Median ASA score was III. Mean operating time 172 min (145–210 min) with a mean hospital stay of 2 days (1–3 days). There was no change in creatinin or cystatine-C after cryo-ablation. The GFR was within normal range after treatment in all but patients with one kidney or one functional kidney where the function declined on average with 10%. The treatment of larger tumors were found to affect the split renogram. Overall, 1 patient developed local recurrence and 2 patient developed a new tumor in the previously treated kidney. One patient developed metastatic disease. There was 5 cancer deaths.

**Conclusion:** Laparoscopic assisted renal cryoablation is an effective oncologic treatment for renal carcinoma in selected patients. Renal function is well preserved in large majority of the patients.

## **VP28: MISCELLANEOUS**

### **VP28-01 TREATMENT OF PARACALYCEAL CYST AND SECONDARY LITHIASIS WITH A SINGLE-SESSION LAPAROSCOPIC AND PERCUTANEOUS APPROACH**

G. Caddeo, P. Usai, A. De lisa

**Background:** Compression of calyceal cavities by renal cysts may lead sometimes to obstruction of them with secondary lithogenesis. We report a case of laparoscopic marsupialization of an intrasinus paracalyceal cyst and subsequent percutaneous lithotripsy of a hydrocalyx-located upper pole renal stone.

**Methods:** A 72 years old man, affected by bilateral cystic renal displasia, complained a recurrent right lumbar pain. After a preliminary ultrasound evaluation, a CT scan was performed showing a 45 mm intrasinus right renal cyst compressing the infundibulum of the upper calyx: this was turned into a hydrocalyx with a 25×12 mm calyceal stone. A single-step endourologic treatment was planned in order to treat both cystic and lithiasic disease. First, the intrasinus cyst was drained, marsupialized and filled with haemostatic agents with a transperitoneal laparoscopic approach. Then a PCNL in supine modified Valdivia position was performed: as retrograde pyelography showed any injury to renal cavities following the laparoscopic procedure, a subcostal lower-pole access was obtained with a 24F “one-shot” dilation. Preliminary removal of cyst compression to the infundibulum allowed its exploration with a flexible nephroscope with Ho:YAG laser fragmentation of the stone and basket retrieval of fragments. A pig-tail 9F nephrostomy tube was placed at the end of procedure.

**Results:** Operative time was 160 minutes. Any intra- or post-operative complication was reported. After 48 hours a nephrostogram was carried out to ensure normal drainage of the collecting system and to allow nephrostomy tube removal. The patient was discharged on 3rd postoperative day. The stone-free status was confirmed by ultrasound and KUB at a 6 month follow-up.

**Conclusion:** Single-session endourologic treatment with an original technique showed to be safe and effective. Limited laparoscopic dissection of the upper pole of the kidney was an essential requirement to perform a subsequent percutaneous procedure with a low risk of kidney hypermobility.

### **VP28-02 LARGE BLADDER STONE: PERCUTANEOUS SUPRAPUBIC CYSTOLITHOTRIPSY (PCCL) OR TRANSURETHRAL CYSTOLITHOTRIPSY (TUCL)?**

M. Hosseini, A. Aryafar, A. Aminsharifi, A. Yousefi, R. Inaloo, A. Hassanpour—Iran

**Background:** To evaluate and compare results of percutaneous suprapubic cystolithotripsy (PCCL) and transurethral cystolithotripsy (TUCL) in management of large bladder stones.

**Methods:** Forty-six patients, all male, mean age 47.5 (18–78) with bladder stone  $\geq 2$  cm were selected and randomly divided in two groups. A: PCCL (n = 23) and B: TUCL (n = 23). In the PCCL group, the stones were removed through a suprapubic 30F Amplatz sheath after pneumatic lithotripsy. In the TUCL group, the

stones were removed after fragmentation through a 24F cystonephroscope sheath and Elik evacuator.

**Results:** Mean stone sizes were larger in the PCCL group (42 vs. 35 mm). The operative time was significantly less in the PCCL group. In the TUCL group, one patients had residual stones in a diverticulum >10 mm necessitating Re-TUCL and another case developed urethral stricture.

**Conclusion:** PCCL and TUCL both are safe and effective for removal of bladder stone, however, the smaller caliber of the working channel during TUCL, necessitates fragmentation of the stones into smaller particles. This elongates the duration of the operation and may increase risk of urethral or bladder trauma. We suggest PCCL even in patients with stone and large prostate or urethral stricture as a combination, PCCL/TURP or PCCL/urethrotomy, respectively.

### VP28-03 MULTIMODAL THERAPEUTIC APPROACHES TO FORGOTTEN URETERAL STENTS

S. Rabani—Iran

**Background:** Ureteral stents are widely used in urologic therapeutic interventions. Although the development of better designs and stent materials has been directed toward decreasing the complications of these foreign bodies and better tolerance by the patients, due to excessive use of these stents we still encounter many complications such as irritative symptoms, infections, and encrustations. Although the majority of these can easily be managed, long forgotten stents as a result of severe encrustation can cause significant morbidities. The aim of this study was to show our multimodal experiences in managing forgotten stents from 2000 till Jan. 2009.

**Methods:** A total of 24 patients (14 females and 10 males) with retained ureteral stents for duration of 6 months to 42 months were treated by multimodal endourologic (in a single or separated sessions) or open surgery in earlier cases in some cases the stent was grasped by foreign body forceps and brought out of the urethra and fixed with a clamp and beside it the ureteroscope was advanced the passively dilated ureter in these patients makes easier endoscopic procedures.

**Results:** In 10 patients TUL solved the problem, in 6 patients the bladder end and ureteral encrustations were managed in one or two sessions pneumatic lithotripsy and the renal end encrustations by ESWL. In 4 patients the bladder and ureteral encrustations were managed by at least 2 sessions lithotripsy and the renal unit by PCNL. 4 patients that were our earlier patients, underwent open nephrolithotomy and cystolitholapaxycystolithotomy.

**Conclusion.** Although endourology has made the management of stone encrustation very easier than before, the best way of therapy is prevention of its occurrence by informing the patient and designing a recall system. Endourologic management in females were easier than in males most of these stones (encrustations) were easily fragile but some were hard.

### VP28-04 A RETROSPECTIVE STUDY FOR UROLOGIC COMPLICATIONS AFTER TRANSURETERAL LITHOTRIPSY (TUL) PROCEDURE IN 100 PATIENTS REFERED TO IMAM REZA HOSPITAL

M. Darabi Mahboub, R. Taghavi, M. Namjoo—Iran

**Background:** A study for urologic complication after transureteral lithotripsy (TUL).

**Methods:** By studying the patient documents in hospital archive, we acquired primary information about variers and intraoperative and short time post operative complications of TUL. After one year we called patients for checking the longterm complications of TUL by urine analysis/urine culture, sonography, IVP, BUN, Cr and VCUG after physical examination.

**Results** 71% of patients were male and 29% were female. The mean age was 40.8 years with standard deviation of 13.6 years. Only 2% of patients had bilateral ureteral stone. 4.9% of stones were less than 5 mm in size, 33.3% were between 6-9 mm and 61.8% were more than 10 mm. 25.5% of stones were in upper ureter, 11.8% in middle ureter and 62.7% in lower ureter. Intraoperative complications happened in 12% of patient: ureteral Avulsion in 1%, ureteral perforation in 3%, failure to infract the stone in 1% and residual stone in 4% of patients were occurred. Acute Pyelonephritis was the only short time postoperative complication that happened longterm post operative complications occurred in 6% of patients: Ureteral stricture in 1%, Urinary tract infection in 3% and residual pain in 2%. Because of no corporation at patients in doing VCUG, Vesicoureteral reflux could not be checked. The TUL procedure was successful in 92% of patients the overal and major complication were 17% and 5%, respectively. There was a statistical relationship between success rate and location of stone (p:0.08), as well as relationship between intraoperative complications and location of stone in the ureter (p : 0.003)

**Conclusion:** The result of overall and major complications in this study was 17% and 5% respectively, and in large series of ureteroscopy have been observed 10% to 20% and 0% to 6%. So we had acceptable results in complication rate of TUL in this study by advanced instruments, expert surgeons and carefully selected candidates for TUL decreasing in complication has been occurred recently and we can name TUL as a safe modality in treating the ureteral stones.

### VP28-05 COMPLICATIONS AND CONVERSIONS OF LAPAROENDOSCOPIC SINGLE-SITE SURGERY (LESS): MULTI-CENTER EXPERIENCE RESULTS FROM THE NOTES WORKING GROUP

B. Irwin, J. Cadeddu, C. Tracy, F. Kim, W. Molina, A. Rane, C. Sundaram, J. Raybourn iii, I. Gill, L. Kavoussi, R. Lee, M. Desai—USA

**Background:** Laparoendoscopic Single-site Surgery (LESS) is a recent extension of laparoscopy whereby a variety of urologic reconstructive and extirpative procedures are performed through a single skin incision. We present complications and rates of conversion from LESS to conventional laparoscopy (CL) as well as the factors leading to those conversions at six high-volume centers pioneering urologic LESS procedures.

**Methods:** Patients undergoing laparoscopic upper tract procedures were identified at each institution. From these patients, those undergoing planned LESS procedures and those requiring conversion to CL with the placement of additional ports were identified. Conversion was defined as the placement of additional 5 or 10/12 mm ports beyond the primary single incision site. A planned 2 mm needle port was not considered as conversion. In each case the operative reports were reviewed, the reason for conversion was determined, and number and types of additional ports were noted.

**Results:** Upper tract LESS procedures were performed in 125 patients comprising 13.3% of the total 937 laparoscopic procedures

performed at the participating institutions between September, 2007 and November, 2008. Conversion to CL was necessary in 7 patients (5.6%) undergoing LESS requiring the addition of 2–5 ports. Reasons for conversion included: facilitate dissection in 3 (43%), facilitate reconstruction in 3 (43%), and control of bleeding in 1 (14%). All patients undergoing LESS surgery were completed laparoscopically without need for open conversion. Complications occurred in 15.2% of patients undergoing LESS surgery. Three of the 7 patients that were converted to CL developed postoperative complications including 1 urine leak, 1 post-operative hemorrhage requiring transfusion, and 1 deep venous thrombosis requiring anticoagulation.

**Conclusion:** LESS surgery may be performed safely for a variety of upper urinary tract reconstructive and ablative procedures. Conversion to CL occurs infrequently and is a reflection of stringent patient selection. At the time of writing, even at high volume centers that have pioneered LESS surgery, the majority of procedures are still performed using conventional laparoscopic techniques. Refinement in technique and technology is likely to increase the scope and application of LESS surgery in urologic practice.

#### VP28-06 PERCUTANEOUS NEPHROSTOMY (PCN) BY UROLOGIST

M. Hosseini, A. Aminsharifi, A. Aryafar, S. Ezatzadegan, M. Pakfetrat—Iran

**Background:** To evaluate safety and efficacy of ultrasound-guided percutaneous nephrostomy by urologist.

**Methods:** Thirty-five patients, 21 male, 14 female, mean age 47.5 (24–82) who need nephrostomy due to obstruction in nephrology or urology emergency wards, underwent percutaneous nephrostomy with local anesthesia and sonography guide.

**Results:** In 24 patients who had severe hydronephrosis (HDN), PCN were done successfully at first attempt, 7 patients with mild to moderate HDN, hydration and 2–4 punctures needed, 3 morbid obese patients failed and after hydration and diuretic PCN done by expert radiologist and one patient who was single kidney refused percutaneous approach after injection of local anesthesia despite of signed informed consent.

**Conclusion:** Ultrasound-guided percutaneous nephrostomy seems feasible, safe and effective by urologist who are familiar with percutaneous surgery such as nephrolithotomy (PCNL).

#### VP28-07 CLIPLESS LAPAROSCOPIC RETROPERITONEAL LYMPH NODE DISSECTION USING BIPOLAR ELECTROCOAGULATION FOR SEALING LYMPHATIC VESSELS; INITIAL SERIES

N. Simforoosh, H. Nasseh, P. Masoudi, M. Asle Zare, S. Ghohestani, R. Eshratkhan—Iran

**Background:** To evaluate the outcome of laparoscopic retroperitoneal lymph node dissection (LRPLND) using bipolar electrocoagulation instead of clipping the lymphatic vessels.

**Methods:** From August 2002 to April 2008, a total of 13 patients (mean age: 24.2 years; range: 19–39) underwent transperitoneal LRPLND for nonseminomatous germ cell tumor of testis were included in this study. In this experience, in contrast to other techniques, we did not use clips for ligation of the lymphatic vessels, instead, we used bipolar cautery for coagulation of the lymphatic vessels. We followed up the patients for lymphocele formation or lymphatic leakage.

**Results:** Six tumors were on the left side and 7 were on the right side. Pathological stage was stage one in 12 patients and stage 2a in 1. The mean follow-up period was 29.9 months (range, 3–70 months). No reoperation was required. There was no prolonged lymphatic leakage or lymphocele formation during the follow-up period.

**Conclusion:** Our study suggests that using bipolar electrocoagulation instead of clips (as a foreign body) for sealing of lymphatic vessels during LRPLND does not seem to have deleterious effects on the outcome of the procedure. This should be further evaluated in randomized clinical trials with more cases.

#### VP28-08 SURGICAL TECHNIQUE OF TRANSURETHRAL ENUCLEATION OF INTRAMURAL BLADDER LEIOMYOMAS

I. Galanos, C. Georgiou, K. Polyzois, I. Fokitis—Greece

**Background:** Although rare (1% of all bladder tumors), leiomyomas are the most common benign soft tissue neoplasms of the bladder. Even in asymptomatic intramural cases, histological confirmation is essential since imaging studies alone cannot safely differentiate them from bladder malignancies. We present our experience of the endoscopic enucleation of these lesions demonstrating the advantages and possible problems of this technique.

**Methods:** Preoperatively intramural leiomyomas should be suspected based on the imaging findings and on cystoscopy revealing a lesion covered by normal mucosa protruding in the bladder lumen. Using a standard resectoscope the overlying mucosa is resected until the neoplasm is recognizable and a safe plane is developed. The tumor is then gradually enucleated, separated from the bladder wall and attracted intravesicically using the loop. Subsequently haemostasis including the neoplasm's blood supply vessels is performed and the enucleated tumor is dissected free and pushed into the bladder. Specimen retrieval technique depends on its size, requiring the use of baskets, stone forceps or morcellator. Postoperatively a Foley catheter is left for 2 days and when haemostasis is adequate no irrigation is needed.

**Results:** Transurethral enucleation minimizes bladder trauma allowing excision of larger leiomyomas with less bleeding. Difficulties can be expected retrieving the specimen endoscopically.

**Conclusion:** When intramural bladder leiomyomas of small to moderate size are suspected, radical surgery can be avoided. We recommend the transurethral enucleation as a simple, minimally invasive and safe technique for the complete excision and diagnosis of these lesions, even when they are located in unfavorable positions in the bladder wall.

#### VP28-09 OUR EXPERIENCE OF ANTEGRADE MINIMUM INCISION ENDOSCOPIC SURGERY OF PROSTATE CANCER

T. Hosoi, H. Uchida, N. Takahashi, F. Murakami, K. Suzuki—Japan

**Background:** Robotic-assisted laparoscopic radical prostatectomy hasn't spread yet in Japan. Alternatively, minimized-incision surgeries are currently conducted in Japan. Minimum incision endoscopic surgery (MIES) (Kihara et al introduced) that is performed through a single small incision, not using trocars and CO<sub>2</sub> insufflation is one of the most minimally invasive surgeries. Since 2005, MIES was introduced into our hospital. We report our experience of antegrade MIES of prostate cancer.

**Methods:** MIES required few special instruments. A 2.5-power loupes and a 5-mm 30-degree laparoscope provided the surgeon with a sufficient view. A Notch pusher and PLES-blade were the

other specialized instruments that should be available. A midline, abdominal incision (6 cm) was made. After ligation of the dorsal vein complex, antegrade approach was performed. First, the surgeon performed the operation under amplifier vision. After dissection of the seminal vesicles and vasa deferentia, the surgeon went ahead with the operation on a video monitor. We used the edge of the incision as a fulcrum for the forceps during the operation on a video monitor.

**Results:** In MIES of prostate cancer using an amplifier together with a laparoscope, antegrade approach utilizing edge of the incision as a fulcrum for the forceps could be performed with the same visualization as laparoscopic surgery, and the surgeon was able to operate, suture, and dissect with the facility as well as in an open surgery.

**Conclusion:** The prostatic apical dissection is the most complex and important step in the operation. In MIES much of the procedure is performed in a narrow view, antegrade approach is advantageous to avoid iatrogenic entry into the apex of the prostate. This technique is a feasible minimally invasive surgical approach for treating prostate cancer.

#### VP28-10 SINGLE PERCUTANEOUS ACCESS UNDER ENDOSCOPIC CONTROL FOR MANAGEMENT OF LARGE BLADDER STONES

E. Erkan, V. Sacak, G. Toktas, S. Ozkan, M. Demiray, E. Unluer

**Background:** Bladder-stone formation is not an uncommon problem, which usually accompanies obstructive urinary diseases. Standard treatment is endoscopic lithotripsy via pneumatic or laser lithotriptors. But in case of large or multiple stones, increased duration of operation and risk for urethral complications such as stricture can be bothersome as a complication. In this aspect, we evaluated a novel minimally invasive technique, single percutaneous access under endoscopic control for management of large bladder stones.

**Methods:** Between November 2008 and February 2009, 7 patients with bladder calculi larger than 1.5 cm in diameter were treated using this technique. The procedure starts with percutaneous placement of a 10 or 12 mm laparoscopic trocar under cystoscopic vision. Then a rigid nephroscope is introduced into bladder. Stones were fragmented with pneumatic lithotripter. Removal of the fragments was done by grasping forceps or basket. At the end, bladder is irrigated vigorously to eliminate residual fragments and a 2 way foley is placed transurethrally for the healing of defect in anterior bladder wall.

**Results:** The technique was successful in all cases, resulting in controlled bladder-stone-free status and no surgical complications. The mean duration of operation was  $56.4 \pm 3.5$  min. and a total of 16 stones with a mean burden of  $11.94$  (range:3–25)  $\text{cm}^2$  were extracted. Mean duration of catheterization was  $4.4 \pm 0.7$  days. In one patient, the stone with a diameter of 3 cm was extracted without lithotripsy by using an endobag. Additionally, one patient underwent transurethral resection of prostate for benign prostatic hyperplasia and another bilateral orchiectomy for advanced prostate cancer. All patients were discharged uneventfully.

**Conclusion:** Percutaneous cystolithotripsy is easy to perform, without being restricted by size and number of calculi. Despite of our initial experience, duration of operation is not longer than standard endoscopic treatment and certainly has decreased risk for urethral complications such as stricture. It should be kept as an alternative, especially for large stones.

#### VP28-11 PERCUTANEOUS RESECTION OF RENAL PELVIS UROTHELIAL CARCINOMA

G. Simone, M. Ferriero, R. Papalia, S. Guaglianone, E. Forastiere, M. Gallucci

**Background:** We report the oncological outcome of patient who underwent percutaneous resection of renal pelvis urothelial carcinoma.

**Methods:** Between March 2000 and June 2003, 48 patients (41 males, 7 females) with urothelial carcinoma primarily occurred into the renal pelvis were selected for percutaneous tumor resection. Urine cytology, CT scan and preoperative endoscopic evaluation was performed in all cases. In 3 patients with solitary kidney the indication was imperative. Mean patients age was 63 yrs (45–81 yrs). Mean tumor size on preoperative CT was 2 cm (range 1.5–3.5 cm). Minimum follow up was 5 years. Overall survival, disease free survival and recurrence sites were reported.

**Results:** Thirty-three patients (68.7%) were G1, 13 (27.1%) were G2 and 2 (4.2%) were G3. Pathological stages were Ta in 37 cases and T1 in 11 cases. Overall survival was 93.7% and 5-yr disease free survival was 58.4%. Recurrences occurred in 28 patients; nineteen relapses were treated with conservative options and nine were treated with laparoscopic nephroureterectomy. Nine bladder recurrences were treated with TURB, four recurrences occurred into the pelvis and were treated with percutaneous resection and 1 was a single ureteral recurrence treated with laser ablation; in 14 cases multiple recurrences were detected, nine of them treated with laparoscopic nephroureterectomy and 5 of them with endoscopic treatments (1 coexistent pelvis and ureteral tumors and 4 multiple ureteral lesions). Pathologic features of recurrences were: Ta G1 in 8 cases (3 percutaneous resections, 5 TURB), Ta G2 in 5 cases (2 percutaneous resections and 3 TURB) and T1G3 in 1 case (TURB). Five ureteral recurrences were treated with laser ablation and tumor grade was G1 in 3 cases and G2 in 2 cases. pT stages of recurrences treated with laparoscopic nephroureterectomy were pTa G2 in two cases, pT1 G2 in three cases, pT2 G3 in four cases. Median time to recurrence was 14 months.

**Conclusion:** Low grade urothelial carcinomas of the renal pelvis can be treated with percutaneous resection with excellent overall survival rates. A strict follow-up is mandatory to early detect and appropriately treat recurrences.

#### VP28-12 IS BACTERIURIA IN PATIENTS WITH NEPHROSTOMY TUBE AND COMPLETE OBSTRUCTION OF THE URETER LIMITED ONLY TO UPPER URINARY TRACT SYSTEM?

C. Toutziaris, P. Gritsios, V. Adamou, A. Giakoumelos, K. Hatzimouratidis

**Background:** To investigate the bacterial colonization of nephrostomy tube and urine from the bladder of patients with total obstruction of the upper urinary tract.

**Methods:** Patients with obstruction of the upper urinary tract system due to pelvic malignancies were followed up prospectively for 6 months. All patients treated with percutaneous nephrostomy tube placement under ultrasonographic guidance. Antegrade pyelography confirmed the complete obstruction of the ureter and urine culture from the renal collecting system during nephrostomy tube implantation was negative. No patient received prophylactic antibiotics. At 3 months, nephrostomy tube was replaced and the

tip of the tube was cultured for aerobic bacteria. At the same time, a bladder sample of urine was also cultured.

**Results:** A total of 135 patients (75 men and 62 women) included in the study (aged 45–76 years, mean: 60.5y). In 21 (15.5%) patients bacteria were cultured from the nephrostomy tube while they had sterile bladder urine (group 1). In 50 (37%) patients, both cultures were positives (group 2). In 31 of these patients, the same bacteria were cultured from both tube and urine samples while in 19 patients different bacteria were identified. The most common bacteria in group 1 were E.Coli, Enterococcus faecalis και Klebsiella oxytoca. In group 2, the most common bacteria were Pseudomonas luteola, Enterococcus faecalis, Staphylococcus aureus, Pseudomonas aeruginosa and E. Coli. No patient had clinical symptoms of infection and no antibiotics were administered without any further clinical implications.

**Conclusion:** About half of the patients had their nephrostomy tube colonized with bacteria after a period of 3 months and in 70% of them bladder cultures were also positive. The fact that 62% of the latter patients had the same bacteria cultured, suggests that the radiological evidence of complete obstruction does not preclude bacterial colonization of the lower urinary tract.

### VP28-13 LAPAROSCOPIC MANAGEMENT OF SYNTHETIC MESH EROSIONS OF THE BLADDER

J. Ma, A.S. Herati, A.K. George, M.A. Atalla, L. Richstone, L.R. Kavoussi—United States

**Background:** Synthetic mesh is used in inguinal hernia repairs (IHR) to reinforce closure and treats stress urinary incontinence (SUI) by preventing urethral/bladder neck descent during activity. Mesh erosion into adjacent viscera is a known complication of synthetic mesh insertion. We present three patients who had mesh erosion into the bladder following IHR and mid-urethral sling placement, and underwent laparoscopic repair.

**Methods:** A retrospective review of three patients with mesh erosion into the bladder after IHR and mid-urethral sling placement was performed. Patient demographics, operative time, perioperative parameters, and postoperative complications are reported.

**Results:** Three patients underwent laparoscopic repair of bladder mesh erosions following IHR/mid-urethral sling. Three females had a mean age of 56.33 (range 48–72) at the time of repair. Kugel patch synthetic mesh was used for a left IHR, and prolene synthetic mesh was employed in two patients for the treatment of SUI. Erosions were diagnosed cystoscopically and repaired laparoscopically at an average of 61.67 months after the mesh was placed. All erosions required laparoscopic partial cystectomy with a mean bladder wall excision volume of 22.3 cm<sup>3</sup>. Calcareous deposits were identified in the two cases involving prolene mesh.

**Conclusion:** The application of synthetic mesh during abdominal wall and pelvic surgery may lead to bladder mesh migration in a small number of patients. Laparoscopic partial cystectomy and mesh excision is a feasible management option for patients with mesh erosion offering a minimally invasive alternative for repair with little morbidity.

### VP28-14 PERCUTANEOUS CYSTOLITHOTOMY FOR CALCULI IN RECONSTRUCTED BLADDERS: THE UCLA EXPERIENCE

A. Breda, M. Mossangen, J. Harper, J. Leppert, P. Schulam, B. Churchill

**Background:** Following bladder augmentation, patients are at significant risk for developing bladder calculi. We present our experience with a minimally invasive treatment approach using endoscopically assisted percutaneous cystolithotomy.

**Methods:** A retrospective chart review identified 78 patients who underwent percutaneous cystolithotomy following bladder augmentation between 2002 and 2009. Using fluoroscopic guidance, a cystogram was performed to determine ideal location for percutaneous bladder access. A bile needle was percutaneously placed into the bladder. A guide wire was inserted and a balloon dilator was used to place a 30 French sheath. Rigid cystoscopy with a 26 French nephroscope allowed stone treatment by basketing and/or ultrasonic lithotripsy. After confirming stone removal by endoscopy, a 22 French catheter was placed. Patients were seen 14 days postoperatively and a KUB was performed. If no significant residual calculi were visualized, the suprapubic tube was removed.

**Results:** All of the cases were completed through a single percutaneous access site as planned. The average patient age was 23 (range of 7–43). There were 41 males and 37 females. The average number of stones per patient was 3.6 (range 1–8). Ultrasonic lithotripsy was performed in 50 cases (64.1%). In 28 cases (35.9%) only stone basketing was performed. 74 (94.8%) patients were thought to be stone free by endoscopic examination, however 70 (89.7%) patients were found to be free of calcifications by imaging at 14 days. The average length of the suprapubic tube was 14.1 days (6–29). 29 cases were performed as outpatients, and 49 as inpatients with an average hospital stay of 1.3 days. There were 6 minor complications (7.6%).

**Conclusion:** Endoscopic percutaneous cystolithotomy offers a safe and effective treatment option for bladder calculi in reconstructed bladders and is the preferred treatment option at our institution.

### VP28-15 LONG-TERM RESULTS OF IMMEDIATE ENDOSCOPIC REALIGNMENT OF COMPLETE POSTERIOR URETHRAL DISRUPTION

M. Sofer, A. Beri, H. Matzkin, I. Kaver

**Background:** The approach to the patient with complete, grade III, posterior urethral injury is challenging and still controversial. Debate continues regarding the advisability of early realignment vs delayed open urethroplasty. We report our experience with early endoscopic realignment in a series of patients followed-up more than 4 years.

**Methods:** The study comprises a series of 12 patients with complete posterior disruption secondary to: pedestrian road accident (n = 9), falling impact (n = 2) and complete anastomotic separation after laparoscopic radical prostatectomy (n = 1). Urethrography, cystography and CT scan served for diagnosis. Ten (83%) patients underwent urgent abdominal and orthopedic interventions to treat concomitant injuries. The endoscopic realignment was performed using simultaneous endoscopic transvesical and transurethral approach under fluoroscopic guidance. At the end of the procedure an 18 FR Foley urethral catheter was left for 6 weeks. All patients were evaluated postoperatively for incontinence, erectile dysfunction and urethral strictures.

**Results:** Patients' average age was 32 years (range 20–62). The realignment average time was 40 minutes (range 30–60) and it was done in average within 48 hours (range 3–72) from the diagnosis. There were no complications related to the procedure. Efficient erection was maintained in 5 (42%) patients and none of the

patients developed incontinence. After an average follow-up of 4.3 years (range 2–7) 6 (50%) patients do not have evidence of stricture on functional and imaging studies. Six (50%) patients developed urethral strictures within an average time of 8 months (range 3–12) from the intervention. Three of them, with strictures <5 mm, underwent internal endoscopic urethrotomy: one with successful outcome and the other 2 needing periodic urethral dilation and refusing the recommendation to undergo urethroplasty. Three patients with strictures >15 mm, one of them with interposition of a fragment of pubic bone, underwent successful urethroplasty.

**Conclusion:** Early endoscopic urethral realignment may provide successful outcome. It represents a valuable alternative to long-term suprapubic drainage and delayed urethroplasty. In this series, realignment failure did not interfere with the results of open urethroplasty. Further search for prognostic factors might help for better selection of patients to either early or delayed approach.

### VP28-16 ANTI-RETROPULSION DEVICES INCREASE STONE FRAGMENTATION EFFICIENCY WITH HOLMIUM:YAG LASER LITHOTRIPSY

B. Chew, L. Jonat, D. Lange, R. Paterson, J. Teichman

**Background:** Increased power using Holmium:YAG laser lithotripsy may cause stone retropulsion that results in higher failure rates and prolonged procedures. We hypothesized that anti-retropulsion devices would increase stone fragmentation efficiency for a given amount of laser energy during lithotripsy.

**Methods:** UltraCal 30 stones (n = 180) were divided into 6 groups: control group (no backstop device), 7 mm and 10 mm Stone Cone (Boston Scientific), N-Trap (Cook Urological), and 7 mm and 10 mm Accordion (PercSys). Each group was further divided into 3 power settings: 0.5 J/10 Hz, 1 J/20 Hz, and 2 J/40 Hz to yield groups with sample sizes of 10. A total of 500 joules of energy was delivered in each trial. Stones were placed in a horizontal 8.5 mm diameter acrylic tube immersed in saline. The primary endpoint was stone fragmentation efficiency as defined by stone mass change for a given unit of energy.

**Results:** At the lowest power setting, only the 7 mm Accordion and 10 mm Stone Cone increased stone fragmentation efficiency over control (p < 0.05). At the higher power settings (20 W and 80 W), all devices increased efficiency over controls (p < 0.001). Stone retropulsion increased significantly with higher power settings in the absence of any devices (p < 0.01).

**Conclusion:** Anti-retropulsion devices increase stone fragmentation efficiency and facilitate high power lithotripsy compared to controls. No device was shown to be clearly superior to any other. Presumably, the improved efficiency was a result of increasing the contact time between the laser fibre and stone. Migration of stone fragments was uncommon and no fragments larger than 2 mm migrated past any device.

### VP28-17 URETEROSCOPICALLY ASSISTED TOTALLY LAPAROSCOPIC APPENDICULOVESICOSTOMY

A. Aminsharifi, R. Niroomand, A. Eslahi

**Background:** To demonstrate the efficacy and feasibility of totally laparoscopic appendicovesicostomy in a 13-year old boy with insulin-dependent diabetes mellitus and flaccid neurogenic bladder.

**Methods:** Through transperitoneal laparoscopic approach, the appendix with a 5-mm cecal cuff was harvested with preservation of the mesoappendix. The cecum was repaired with free-hand in-

tracorporeal laparoscopic suturing and knot-tying techniques in two layers. Before proceeding with appendicovesical anastomosis, on appendicular catheterization, purulent material was drained from the appendix and the feeding tube could not be passed through the appendix. The appendix lumen was evaluated by passing an 8 Fr ureteroscope through a 5-mm laparoscopic port, which revealed a hard fecalith at the base of the appendix which was fragmented with a pneumatic lithotripter under direct vision, and ease of catheterization was then confirmed. Appendicovesical anastomosis was done over a 10Fr catheter using 4-0 polyglycolic acid intracorporeal running stitches. The flush stoma was created in the right upper quadrant area at the site of the 5-mm trocar.

**Results:** Operative time was 240 min. Diagnosis and removal of the appendiceal obstruction was successfully accomplished in a minimally invasive milieu. The hospital stay lasted 7 days. Four weeks after surgery, after removing all catheters, the patient was able to catheterize his bladder via the appendix stoma without difficulty every 4 hours. No urine incontinence or stomal stenosis has occurred up to the time of writing (3 months after surgery).

**Conclusion:** Although laparoscopic appendicovesicostomy is a demanding procedure that requires experience with intracorporeal suturing and tying techniques the clinical outcome is highly rewarding due to its minimally invasive nature. However, its long-term outcome in comparison to alternative approaches has yet to be studied.

### VP28-18 A CONTINUUM BASED APPROACH FOR SKILL ACQUISITION FOR DORSAL VEIN LIGATION USING THE LAPAROENDOSCOPIC SINGLE SITE SURGERY (LESS) PLATFORM

S. Kommu, T. Finnigan, A. Chakravarti, A. Golash, C. Luscombe, S. (sarg)—United Kingdom

**Background:** We previously devised and tested a grading system for continuum based laparoscopic skill acquisition using dorsal vein complex ligation for laparoscopic radical prostatectomy. LESS (Laparo-Endoscopic Single-Site Surgery) has recently been successfully utilised in performance of several urological procedures. The preliminary consensus, however, is resounding in that it requires technical expertise with an even narrower margin for error than conventional laparoscopic urological surgery (LUS). Herein we apply and test the application of the continuum-based approach for Dorsal Vein Ligation skill acquisition using the LESS platform.

**Methods:** A LESS platform consisting of a box model (DIY-LTK™) was fitted with an R-Port™ and flexible cystoscope was developed as previously described (Kommu et al. Journal of Endourology. November 2008: 1–340). Autonomy™ Laparo-Angle™ Instruments from Cambridge Endo were used for this module. The target task was ex vivo Dorsal Vein Ligation (DVC). The continuum based approach for DVC as previously described was used (Journal of Endourology. October 2007: A1–A292). The grading system was for a target model of skill acquisition and was based on degree of resemblance to live human surgery graded Levels 1 to 5. Level-1 represented a basic model consisting of a tubular structure over plasticine in the shape of a prostate, Level-4 represented a prostate gland using supermarket chicken tissue with Dacron® grafts filled with red dye and Level-5 represented a live human prostate at the time of surgery. One candidate was put through the LESS platform using articulating instruments via the multichannel port. The other candidate was allowed to progress in

the conventional route i.e. using straight instruments via conventional ports. The continuum-based model was used for both candidates thus allowing trainees to progress from Level-1 through to Level-4. The time for the trainees to acquire the skill for competence as judged by expert laparoscopic surgeons was tallied and the progress monitored.

**Results:** The trainee who used the LESS platform took 3.2 times longer to acquire competence at performing DVC in the Level-4 Model when compared to the trainee who used the conventional platform. Analysis of video recordings and feedback indicated that the LESS platform trainee had difficulty with instrument clash and struggled with achieving the appropriate interplay to achieve satisfactory triangulation.

**Conclusion:** LESS using the continuum-based approach offers unique challenges in the preliminary period of skill acquisition and takes a considerable longer time to acquire compared to conventional laparoscopy. However, low cost LESS training platforms using a graduated approach such as the continuum based approach, can be built with over the counter materials and utilised to achieve the necessary skills to perform key steps in complex laparoscopic urological cases such as DVC ligation.

### **VP28-19 DRAINAGE OF SYMPTOMATIC HYDRONEPHROSIS IN PATIENTS WITH LOCAL ADVANCED PROSTATE CANCER**

C. Netsch, A. Beeck, T. Bach, A. Gross—Germany

**Background:** Symptomatic hydronephrosis can be relieved by nephrostomy or internal double-J ureteral stent, the latter can be placed either retrograde or antegrade by means of an already established nephrostomy. We evaluated the feasibility of internal double-J ureteral stenting in patients with symptomatic hydronephrosis due to local advanced prostate cancer.

**Methods:** The data of 30 patients, treated between 2006 and 2008, were retrospectively analyzed. Mean gleason score was 8 (range 6–10), PSA 213 (range 0.1–553)  $\mu\text{g/l}$  and preoperative creatinine 4.4 (range 1–18)  $\text{mg/dl}$ , respectively.

**Results:** 23 patients underwent external relief by nephrostomy. Internal double-J ureteral stenting was performed in 7 patients. Primary ureteral stenting with double-j was not successful in 9 patients. In 8 of the 9 patients the double-J was later placed antegrade by an established nephrostomy. Mean PSA was 247  $\mu\text{g/l}$  and gleason score was 9 in patients with nephrostomy. Mean creatinine dropped from 5.3 to 2.8  $\text{mg/dl}$  after relief by nephrostomy. Mean PSA was 183  $\mu\text{g/l}$  and gleason score was 7 in patients with ureteral

## **VS1: BENIGN PROSTATIC HYPERPLASIA/LUTS**

double-j stents. Creatinine decreased from 3.7 to 2.8  $\text{mg/dl}$  after relief by ureteral double-j stenting. 12 patients died during follow up. Mean survival was 5 (range 1–24) months after the first assessment.

**Conclusion:** Ureteral double-J stenting is an option to improve quality of life in patients with symptomatic hydronephrosis due to local advanced prostate cancer. The feasibility of ureteral double-j stenting is potentially limited by patient's preoperative gleason score, PSA, and creatinine levels. Mean survival in patients with symptomatic hydronephrosis due to local advanced prostate cancer is however limited.

### **VP28-20 PROSPECTIVE COMPARISON OF STANDARD VERSUS TUBELESS MINI-PNL**

G. Wendt-Nordahl, F. Wezel, M. Michel, T. Knoll—Germany

**Background:** Percutaneous nephrolithotomy (PNL) is the standard therapy of large urinary tract stones. The introduction of "Mini-PNL" has led to an extension of indication in many centers which is justified with the lower invasiveness of the miniaturized equipment. Aim of our study was to evaluate the perioperative course of standard and tubeless Mini-PNL (tMP).

**Methods:** The perioperative course of 25 patients undergoing standard PNL (ultrasonic and fluoroscopic guided access, 26 F sheath, ultrasonic lithotripsy, 22 F nephrostomy postoperatively) and 25 patients undergoing tMP (ultrasonic and fluoroscopic guided access, 18 F sheath, holmium laser lithotripsy, antegrade placement of ureteral stent and sealing of the tract with thrombine matrix postoperatively) was evaluated prospectively.

**Results:** Patients characteristics including body mass index were similar in both groups. Mean stone diameter was  $18 \pm 8$  mm (tMP) and  $23 \pm 9$  mm (standard PNL;  $p = 0.042$ ). The stone free rate was comparable in both groups (PNL: 23/25; tMP: 24/25). No significant complications were observed. Minor complications including bleeding (PNL: 2/25; tMP: 1/25), perforation (PNL: 1/25; tMP: 0/25) and fever (PNL: 5/25; tMP 3/25) were comparable in both groups. Postoperative pain measured on a visual analogue scale was slightly lower in the tMP group (PNL:  $4 \pm 3$ ; tMP  $3 \pm 3$ ;  $p = 0.048$ ). The length of hospital stay was significantly shorter after tMP (PNL:  $6.9 \pm 3.2$  days; tMP:  $3.8 \pm 2.9$  days).

**Conclusion:** High stone free and low complication rates after standard and tubeless Mini-PNL advocate both procedures as safe and efficient methods for percutaneous stone treatment. Lower perioperative pain and a shorter hospital stay seem to favour tubeless Mini-PNL at least in patients with a smaller stone burden.

## **VS1: BENIGN PROSTATIC HYPERPLASIA/LUTS**

### **VS1-01 THULEP—THULIUM LASER ENUCLEATION OF THE PROSTATE**

F. Imkamp, T. Herrmann

**Background:** Bladder outlet obstruction (BOO) caused by BPH is a common problem in male patients. For large glands (>60 cc) several treatment options are available: open transvesical adenectomy (TA), Holmium laser enucleation (HoLEP) and Green-

light (TM) photoselective vaporization (PVP). These therapies are hampered by invasiveness (TA), tissue disruption with low evaporation (HoLEP) and lack of specimen for both, sidefire techniques as well as single use fibres. With this video we introduce a new technique of a Thulium:YAG laser enucleation (ThuLEP).

**Methods:** A 69 year old male patient with BOO (prostate volume 79 ccm, IPSS 33, PVR 50 cc, verified obstruction) underwent retrograde laser enucleation of the prostate (ThuLEP) using the



Thulium:YAG laser. The plane for anatomical blunt retrograde preparation of the adenoma was entered via incision of the adenoma with 70 Watts. Laser beam was only used for coagulation of perforating vessels and final dissection at the bladder neck (30 W). All crucial steps performed are presented in the video. The specimen was extracted using a morcelator.

**Results:** The OR time was 65 min; the blood loss was 1.2 g/dl. Treatment with an indwelling catheter for one and discharge at the second day.

**Conclusion:** This technique (ThuLEP) offers an easy method of a retrograde prostate enucleation. In contrast to Thulium vapoenucleation, an anatomical enucleation offers similar surgical features like HoLEP. Thulium:YAG is a feasible surgical tool to achieve true enucleation of the prostate. It offers resection, vaporisation and enucleation at the same time as a function of applied power. A sufficient histologic specimen is achieved; potent coagulation and reusable fibers reduce costs due to a short hospitalization. As in HoLEP it is a technical demanding technique.

### VS1-02 HOLMIUM LASER ENUCLEATION OF PROSTATE: TECHNICAL DETAILS FROM A TRAINEE'S PERSPECTIVE

H. Shah, H. Sodha, V. Kumar, M. Bansal

**Background:** Holmium laser Enucleation of prostate is currently accepted as a minimally invasive surgical treatment for treatment of bladder outlet obstruction. Its adoption has been limited by its perceived steep learning curve. We present herewith a video showing the detailed technical description from a trainee's perspective.

**Methods:** Digital video clips from previously recorded HoLEP procedures were edited into a video describing the steps of HoLEP.

**Results:** There are four steps to performing HoLEP: (a) bladder neck incisions at 5 and 70 clock, (b) Enucleation of median lobe, (c) Enucleation of lateral lobe, and (d) transurethral morcellation. All these steps are demonstrated in video.

**Conclusion:** Since the technique of HoLEP is different from transurethral resection of prostate, it is associated with a learning curve.

### VS1-03 TRANSURETHRAL HOLMIUM LASER DEROOOFING OF PROSTATIC ABSCESS

H. Shah, A. Khandkar, H. Sodha, M. Bansal, V. Kumar

**Background:** To evaluate feasibility and safety of transurethral holmium laser derooofing of prostatic abscess.

**Methods:** From May 2003 to June 2008, 4 patients underwent transurethral derooofing of prostatic abscess. Pre-operatively, patients were given broad spectrum antibiotics. All procedures were performed under spinal anaesthesia. Initial incision were taken at 5 & 7-o clock with Holmium laser and deepened till the pus drained from the prostatic abscess. The tissue over the abscess cavity was liberally incised to freely drain the abscess cavity in the prostatic urethra. Urine at that time was collected and send for culture sensitivity. All the loculi inside the abscess cavity were broken mechanically with the resectoscope beak. Haemostasis was achieved by de-focussing the laser beam. A 24 Fr. Foleys catheter was placed per-urethrally with minimal traction and continuous irrigation. After 5 days, these patients were subjected to repeat cystoscopy and excision of the remaining necrotic slough or residual prostatic tissue by holmium laser. The entire procedure and details of all patients are shown in the video. Hospital records of

these patients were reviewed to know the demographic, perioperative parameters and long term outcome of these patients.

**Results:** The procedure was successful in all 4 patients. Intraoperative urine culture isolated E.coli in 2 patients, Proteus in one and was sterile in one patient. There were no major complications except secondary haemorrhage in one patient on 1st post-operative day. This patient needed Cystoscopic clot evaluation.

**Conclusion:** Transurethral holmium laser de-roofing of prostatic abscess is feasible and safe in patients presenting with prostatic abscess.

### VS1-04 HOLMIUM LASER INCISION OF BLADDER NECK FOR POST-PROSTATECTOMY BLADDER NECK STENOSIS

H. Shah, A. Khandkar, V. Kumar, M. Bansal

**Background:** Bladder neck stenosis is an inherent long term complication of prostatectomy for bladder outlet obstruction. We present herewith a video showing the detailed technical description of Holmium laser incision of stenosed bladder neck after prior prostatectomy and its early results.

**Methods:** Digital video clips from previously recorded Holmium laser incision of post-prostatectomy bladder neck stenosis were edited into a video describing the steps of procedures. Retrospective review of 11 bladder neck incision performed at our institute from May 2003 to June 2008 was performed. Patients demographic and perioperative data was analyzed to know the safety and efficacy of the procedure.

**Results:** The primary procedure for prostatectomy was open prostatectomy (1); TURP (7) and HoLEP (3). All patients presented with recurrent bladder outlet obstruction after initial prostatectomy. The mean interval between prior prostatectomy and presentation was 1.9 years (3 months—9 years). The mean pre-prostatectomy prostate size (available in 8 patients) was 34.8 gm (11–72 gm). The mean preoperative AUA symptom score, maximum uroflow rate and post-void residual urine were 24, 7.2 ml/sec and 112 ml respectively. There were no major intraoperative or post-operative complications. At mean follow-up of 21 months, no patients had recurrent bladder neck stenosis. The mean postoperative AUA symptom score, maximum uroflow rate and post-void residual urine during last available follow-up were 7, 19.8 ml/sec and 33 ml respectively.

**Conclusion:** Holmium laser bladder neck incision is associated with favorable early postoperative outcome.

### VS1-05 REMOVAL OF THE BROKEN CERAMIC BEAK OF TUR-RESECTOSCOPE FROM URETHRA—AN AMAZING AND TROUBLESOME EVENT

H. Ersoy, L. Sagnak, M. Ates, N. Karakoyunlu, U. Ozok, H. Topaloglu—Turkey

**Background:** Case: A 60 year-old man with BPH symptoms was taken into surgery as TUR after failing of previous drug therapies. Under general anesthesia, we planned the operation with 26 F continuous-flow resectoscope. Before starting the resection, resectoscope's ceramic beak was broken in bulbar urethra without any forcing. In a contrast, as the company; also in it's cataloges; declared that the beak was very robust it was broken suddenly and pierced to the urethra very deeply. After taking out the broken resectoscope, we inserted a 21 F cystoscope and a grasper forceps to the urethra and tried to remove the broken beak. First of all, we settled an 5 F urethral catheter through the urethra to the bladder for localization but as it was unavailable to catch the ceramic beak with small-size two-nail

grasping forceps we decided to use 24F nephroscope and a sharp-toothed grasping forceps. Then we rotate the broken ceramic beak as to capture it easily but this was very troublesome. The operation time was nearly 20 minutes and after the extraction, a residue false route was observed at the effected area which will cure in a months time.

**Methods:** -

**Results:** -

**Conclusion:** We think this complication was the first in literature and it was surprising for urologists and also for industry.

### **VS1-06 ENDOSCOPIC REALIGNMENT AND SUBSEQUENT SURGICAL REPAIR OF TOTAL MEMBRANOUS URETHRA RUPTURE FOR PELVIC TRAUMA**

R. Scarpa, M. Poggio, C. Scoffone, C. Cracco, M. Cossu, S. Grande—Italy

**Background:** In this video we present a case of a 30-year-old man, who underwent a serious accident (collapse of a brick wall), receiving multiple fractures including that of the pelvis. The pelvic fracture was multiple and complex, and involved both ischiopubic branches.

**Methods:** A complete urethral abruption was clinically diagnosed, since at the digital rectal examination the prostate was not palpable. Therefore, a suprapubic cystostomy was applied in other hospital. Using a semirigid ureteroscope, a preliminary retrograde urethroscopy was performed. The anterior urethra was regular. The membranous urethra was interrupted immediately before the sphincter. It was not possible to reach the veru montanum. The retrograde urethrography confirmed the complete urethral rupture, additionally evidentiating the elevation of both bladder and prostate. The retrograde application of a guide wire was tried unsuccessfully. Then, the cystostomy tract was dilated, and an Amplatz sheath was applied in place. A flexible cystoscope was then introduced. The bladder neck was identified, and it was possible to reach the veru montanum and the interrupted urethral stump. After few attempts a guide wire was applied anterogradely, finally reaching the anterior urethra. Using the anterogradely placed guide wire, in the end it was possible to reach retrogradely the bladder by means of the semirigid ureteroscope. A second safety guide wire was applied. An intravesical catheter was placed, under the direct visual control of the flexible cystoscope. After one week the patient was submitted to the surgical procedure. A perineal incision was made. The spongious body was reached, and the urethral damaged stumps were isolated. The prostatic apex was elevated. By means of a flexible cystoscope the urethral lumen was preliminarily evaluated in the two directions. Then a termino-terminal anastomosis between the two urethral stumps was performed, applying single stitches on a silicon catheter.

**Results:** After one month the catheter was removed. Urinary continence and sexual potency are preserved. The endoscopic control confirmed the normal sphincter function, without urethral stenosis.

**Conclusion:** In our opinion, in case of partial or total urethral rupture, it is important to perform an immediate endoscopic alignment, followed by a short-term surgical repair.

### **VS1-07 LAPAROSCOPIC TRANSVESICAL ADENOMECTOMY**

B. Oktay, H. Vuruskan—Turkey

**Background:** To present the initial operative outcomes and describe the technique of laparoscopic transvesical adenomectomy.

**Methods:** Since October 2007 laparoscopic transvesical adenomectomy has been performed in 16 patients with symptomatic prostate enlargement (80 gm or greater, mean 147). After preparation of extraperitoneal space 5 ports were used. A transvers cystostomy near to the prostatovesical junction, subcapsular plane development, prostatic adenomectomy, prostatic fossa trigonization and cystostomy repair were standart steps of laparoscopic procedure. Demographic, perioperative and outcome data were recorded.

**Results:** Mean operative time was 133 minutes (range 75 to 210), blood loss was 134 ml (range 50 to 300), hospital stay was 3.9 days (range 2 to 7), and catheter duration was 6.3 days (range 6 to 7). Only one patient required blood transfusion. Complication occurred in one patient that is postoperative hemorrhage and catheter clot obstruction. Considerable improvement was noted in IPSS (preoperative vs postoperative 25.4 vs 9.2) and Qmax (preoperative vs postoperative 4.0 vs 24.7).

**Conclusion:** Laparoscopic transvesical adenomectomy for large benign prostate hyperplasia is feasible.

### **VS1-08 SIGNIFICANT ADVANCEMENTS IN THE TREATMENT OF BPH (BENIGN PROSTATE HYPERPLASIA): PHOTOSELECTIVE VAPORIZATION OF THE PROSTATE USING TREATMENT MODE LFD 3000 VS. 80 W PVP GREENLIGHT**

J. Neymeyer, T. Wülfing, W. Abdul-wahab al-ansari, A. Apostolidis, M. Beer

**Background:** Photoselective vaporization of BPH by using laser technology has established itself as an efficient and valid alternative to TURP in recent years. Still, a range of limitations remains that relates to the appropriate selection of patients, the effective conditions during treatment and outcome for the patient. Our goal was to demonstrate that the innovative, multi-disciplinary laser DIOLAS LFD 3000 using the Leveled Field Density (LFD) 3000 treatment mode is an effective solution to all mentioned aspects.

**Methods:** The comparative clinical trial undertaken included a total of 50 patients (n=25 with LFD 3000; n=25 with PVP GreenLight) who suffered from BPH. 42 of those patients took blood thinning drugs and therefore would be considered high-risk patients for traditional methods such as TURP. The clinical evaluation of the outcome of the treatments included in particular indicators such as IPSS, QoL, PSA, maximal flow rate (Qmax) and post-voiding residual volume (Vres).

**Results:** For the photoselective vaporization of prostate tissue, results have shown that the DIOLAS LFD 3000 achieves much better results than the compared 80 W PVP GreenLight especially regarding handling and outcome for the patient. For the latter, attention has been drawn in particular to aspects such as inflammations, pain or residual urine which all have improved significantly using the LFD 3000 treatment mode. Further advantages include the cost-effective usage for a variety of indications (destruction of stones, removal of condylomata, etc.), lower installation requirements, conditions during treatment and outcome for the patients. Neither high voltage nor external water supply is required, and vaporization efficacy as well as the excellent coagulation effect during treatment help conducting an improved treatment. No special optical filters were required and free sight was available during the whole procedure.

**Conclusion:** Comparing the results of the new LFD 3000 treatment mode with what can be achieved using the 80 W PVP, significant improvements were noticed in particular regarding

reaching a minimum penetration depth and excellent coagulation. At the same time, further important aspects such as multi-use for various indications, installation and handling made the DIOLAS LFD 3000 the more effective system for daily clinical use at lower costs.

### VS1-09 SINGLE-PORT LAPAROSCOPIC TRANSVESICAL ADENOMECTOMY

B. Oktay, H. Vuruskan—Turkey

**Background:** To present the initial operative outcomes and describe the technique of single-port laparoscopic transvesical adenomectomy.

**Methods:** Two patients in whom an open adenomectomy was indicated underwent single-port laparoscopic transvesical adenomectomy. Following the preparation of extraperitoneal space the Olympus Triport system was used. No additional extraumbilical instruments or ports were inserted. A transverse cystotomy adjacent to the prostatovesical junction, subcapsular plane development, prostatic adenomectomy, prostatic fossa trigonization and cystotomy repair were standard steps of laparoscopic procedure.

**Results:** Both cases were completed successfully without conversion to a standard laparoscopy. Operative times were 120 and 100 minutes, blood losses were 200 and 134 ml. Hospital stay was 4 days and catheter duration was 6 days for both patients. No complication occurred.

**Conclusion:** Single-port laparoscopic transvesical adenomectomy for large benign prostate hyperplasia is feasible.

### VS1-10 A NOVEL TECHNIQUE FOR IDENTIFICATION OF DIVERTICULUM DURING ROBOT ASSISTED BLADDER DIVERTICULECTOMY

A. Kural, F. Atug, I. Tufek, H. Akpınar, S. Aksit—Turkey

**Background:** Open surgery, laparoscopic and robot assisted laparoscopic techniques are the surgical options for management of bladder diverticulum. In this video, we present a novel technique for identification of diverticulum during robot-assisted laparoscopic bladder diverticulectomy (RALBD).

**Methods:** A 64 years old patient with benign prostatic hyperplasia (BPH), large bladder diverticulum and bladder stones underwent sequential endoscopic cystolithotripsy, photoselective vaporization of the prostate (PVP) and RALBD. The prostate volume was 75 cc. on transrectal ultrasound. Urethrocytoscopy revealed the obstructing prostate lobes, large diverticulum at the posterolateral bladder wall and multiple stones in the bladder and diverticulum. Endoscopic cystolithotripsy and PVP were followed by a double J ureteral stent placement into the left ureter. The optical internal urethrotome with its outer catheter insertion sheath was introduced into the bladder diverticulum under direct vision. The inner sheath, working element and the lens were taken out and the outer sheath was left in place. Under fluoroscopic guidance a 16F urethral catheter was inserted into the diverticulum via outer sheath. Another 16F urethral catheter was left in place for urinary drainage. The patient was repositioned, the abdominal cavity was insufflated and the robot was docked. The diverticulum was distended with saline infusion via the Foley catheter inside it and identified easily. Following dissection of the diverticulum from surrounding tissue, the left ureter was identified. The diverticulum was transected at its neck. The bladder was closed in two separate layers and the peritoneum was oversewn with continuous suture. A novel fixation knot was used during all continuous sutures.

**Results:** Total operative time and console time was 141 minutes and 120 minutes, respectively. Length of stay was 2 days.

**Conclusion:** Robot assisted laparoscopic bladder diverticulectomy is a feasible and safe procedure. The novel technique for identifying the bladder diverticulum may ease the procedure.

## VS2: FEMALE UROLOGY AND INCONTINENCE

### VS2-01 LAPAROSCOPIC TREATMENT OF OVARIAN VEIN SYNDROME

A. Celia, G. Zeccolini, G. Breda

**Background:** Ovarian vein syndrome is an infrequent disorder due to the ureteral obstruction by the ovarian vein. It is more frequent on the right side. The initial symptoms may be related to recurrent urinary infections; most patients report right lumbar pain. We present a case of ovarian syndrome vein in a young woman complaining right kidney colic for several months, who is subjected to laparoscopic surgical management.

**Methods:** A 42-years old woman without antecedents of interest presents with pain in right renal fossa. Intravenous urography shows right idronephrosys. CT scan shows right ureter compressed between ovarian vein and right iliac artery. Surgery is programmed: ovarian vein ligation with ureterolysis via a trans-abdominal laparoscopic approach. The patient is placed in slight left lateral decubitus and 3 trocars are placed: 2 measuring 5 mm and one 10 mm for the optic. Following incision on the line of Toldt, the lumbar ureter is identified and followed until seen to pass

between the iliac artery and the ovarian vein. The ovarian vein is freed and the ligated and sectioned. A drain is positioned.

**Results:** Operative time is 75 min. The postoperative course is uneventful and the patient is discharged the second day after the intervention. The subsequent control after 3 months shows the patient to be completely asymptomatic, and follow-up IVU shows disappearance of the ectasia of the right ureter. The patient is asymptomatic.

**Conclusion:** In the treatment of ovarian vein syndrome, surgery with ureterolysis is indicated and the laparoscopic approach is the management option of choice.

### VS2-02 LAPAROSCOPIC SACROCOLPOPEXY FOR GRADE IV PELVIC ORGANS PROLAPSE WITH ASSOCIATED BILATERAL PYELOCALICIAL DILATATION

L. Curcio, R. Guida, F. Bastos, A. Cunha, J. Renteria, G. Di Biase—Brazil

**Background:** The main structures responsible for uterus sustentation like uterosacral ligamentum, pubocervical fascia and

paracervical tissue when are weakened, allow that pelvic organs like bladder, uretra and return going down through pelvic diaphragm. The reconstructives techniques, using meshes and laparoscopic route aim intestinal, sexual and voiding preservation. We show a video of a pelvic organ prolapse (POP) female patient with bilateral pyelocaliceal dilatation, that was corrected through a laparoscopic sacrocolpopexy mesh procedure.

**Methods:** A 56 yo female, complained of vaginal ball and just evacuated fezes with aid of the fingers introduced inside the vagina. Her fisic exam evidenced a grade 4 pelvic prolapse, bringing down return, bladder and uretra and probably kinking bilaterally ureters, since KUB exam showed a dilatated right kidney, almost without function, and the left with a slow contrast elimination. A laparoscopic correction of your POP was proposed. A 4 ports pneumoperitoneum was confecioned. We dissected the retovaginal and bladder vaginal spaces. The mesh was sutured posterolaterally to the distal levator ani muscles, and centrally to central perineum tendon. Anteriorly, the mesh was sutured to the anterior vaginal wall and then passed through the broad ligaments. Both meshes were trimmed and sutured to the anterior longitudinal ligaments of the sacral promontory. The Douglas pouch and peritoneal incision were closed and a transobturator suburethral sling was positioned.

**Results:** The surgery last 240 minutes, with a minimum blood loss and just paracetamol was used for postoperative pain. She was discharged in 3 days and her 2 months KUB exam showed pelvic organs in a correct location and better contrast elimination of kidneys. After a follow up of 6 months, she is continent and no prolapse recurrence occurred.

**Conclusion:** Laparoscopic mesh approach for sacrocolpopexy is feasible, with a minimum morbidity, indeed for bilateral kidney dilatation secondary to POP.

### VS2-03 ROBOTIC-ASSISTED LAPAROSCOPIC SACROUTEROPEXY FOR PELVIC ORGAN PROLAPSE IN CLASSICAL BLADDER EXSTROPHY

A. Benson, B. Kramer, P. Mckenna, B. Schwartz—United States

**Background:** Classical bladder exstrophy is a rare congenital anomaly with male predominance. When occurring in females, the accompanying anatomical and functional abnormalities, including pelvic organ prolapse, may cause significant problems in both childhood and adulthood. Success with the robotic surgical approach for repair of pelvic organ prolapse in otherwise normal women has been reported. This approach has not yet been documented in cases of bladder exstrophy. We report our technique and experience with the first robotic-assisted laparoscopic sacrouteropexy for grade four pelvic organ prolapse in a classical bladder exstrophy patient.

**Methods:** Using video format in a step-wise fashion, we present our technique on robotic-assisted laparoscopic sacrouteropexy for repair of grade four pelvic organ prolapse in an 18-year-old female classical bladder exstrophy patient.

**Results:** The procedure was completed in three hours without complication with an estimated blood loss of 20 milliliters. The hospital stay was 36 hours. At 10 months follow up, the patient did not report any post-operative issues or symptoms of pelvic organ prolapse. Physical examination demonstrates complete resolution of pelvic organ prolapse.

**Conclusion:** Pelvic organ prolapse occurs frequently in female bladder exstrophy patients, but is difficult to manage. To our knowledge, this is the first reported minimally invasive approach to

pelvic organ prolapse in a previously repaired bladder exstrophy case. Robotic-assisted laparoscopic sacrouteropexy is a viable option in these patients.

### VS2-04 TECHNIQUE OF ROBOT ASSISTED VEISCOVAGINAL FISTULA REPAIR (NOTE: THIS ABSTRACT IS ACCOMPANIED BY A VIDEO)

H. Atalah, C. Vincent, L. Morgan, L. Su—USA

**Background:** Post-hysterectomy vesicovaginal fistula is a rare complication with an incidence of 0.1–0.2%. This iatrogenic complication, however, has significant quality of life consequences. Options for repair include urethral catheter drainage, endoscopic cauterly, and open, transvaginal, and laparoscopic repair. Recently robotic surgery has expanded to address both upper and lower urinary tract pathology including complex reconstructive surgery. Herein we present a case of a vesicovaginal fistula discovered following robot assisted hysterectomy and salpingo-oophorectomy managed successfully by robot assisted repair. The step by step details of this technique will be highlighted.

**Methods:** This video presentation is of a 64 year old female who sustained a vesicovaginal fistula following a robot assisted hysterectomy and bilateral salpingo-oophorectomy for cysadenofibroma of the ovaries. Despite urethral catheter drainage for two months, she has continued to have persistent and constant leakage of urine per vagina. After all options were discussed, the patient proceeded with robot assisted repair of her vesicovaginal fistula. A vaginal approach to repair was deemed impossible due to the proximal location of the fistula as well as the patient's extremely narrow vaginal introitus. A four armed robotic repair was performed with the da Vinci S system after placement of bilateral urethral stents as well as placement of a guidewire through the fistula to aid in identification. The fistula was excised and omentum was mobilized and interposed between the bladder and vaginal closures.

**Results:** Total operative time was 3.5 hours with minimal blood loss and a one day hospital stay. The urethral catheter was left in place for two weeks after which it was removed following a cystogram which demonstrated no leak. The patient experienced no complications and has remained pad free ever since her surgery.

**Conclusion:** Robotic surgery has expanded to address both upper and lower urinary tract pathology including complex reconstructive urologic surgery. Despite its rare occurrence, post-terectomy vesicovaginal fistulas can have a significant effect on quality of life. Robot assisted repair is useful in addressing proximally located fistulas and is an alternative to open or laparoscopic surgical repair with low morbidity.

### VS2-05 OPTIMIZING RESULTS OF SUBURETHRAL SLING OPERATIONS AMONG FEMALES USING SUBURETHRAL HYALURONIC ACID INJECTIONS

J. Neymeyer, W. Abdul-wahab Al-ansari, S. Kassin, M. Beer—Berlin

**Background:** Suburethral sling procedures have become the gold standard therapy for female stress urinary continence. So far, this technique has succeeded in reducing involuntary loss of urine by anywhere between 80 to 90%. Our aim was to further improve these results by the administration of hyaluronic acid injections in the suburethral region proximal to the external urethral sphincter.

**Methods:** This study included a total of 21 female patients who continued to suffer from SUI despite undergoing a suburethral

sling procedure. The number of pads required per day by each patient was documented. All of these patients were then given suburethral hyaluronic acid injections at the site of the external urethral sphincter in order to reduce the magnitude of their SUI. Clinical assessment was then based upon the number of pads required after the Hyaluronic Acid injections in comparison to the number of pads used before this treatment modality was instituted.

**Results:** Current literature has shown that male urethral sling procedures improve SUI by anywhere between 80 to 90%. However, by administering an additional treatment of suburethral hyaluronic acid injections we are able to enhance these results by a further 20%. This means that grade I & II SUI use an average of 0 to 1 pads per day after instituting this additional therapy.

**Conclusion:** Suburethral injections of Hyaluronic Acid administered to our study group of post-operative sling procedures have succeeded in reducing the average daily use of pads from 5 pads to anywhere between 0 to 1 pad per day.

### VS2-06 SILK LIGATURE TECHNIQUE OF SPERMATIC VESSEL MASS LIGATION-DIVISION DURING BILATERAL LAPAROSCOPIC VARICOCELECTOMY FOR INFERTILITY

E. Arada, P. Fausto, R. Arada—Philippines

**Background:** Laparoscopic varicocelectomy is generally done using titanium or polyethylene clips. In developing countries, clips are expensive and not affordable to many indigent patients compared to cheaper and readily available Silk ligatures. We present our technique of ligating bilaterally dilated spermatic vessels using Silk 1-O ligatures on infertile males.

**Methods:** Ports used were: 12 mm at umbilicus for 10 mm laparoscope; 10 mm at right lower quadrant for scissors or needle driver and 5 mm at left lower quadrant for dissector. The left spermatic vessels were identified and exposed through a small posterior peritoneal window at level of iliac fossa. The vessels were isolated, grasped with right-angle dissector and mass ligated using Silk 1-O intracorporeal knots tied with “flamingo-jaw” needle driver. Two Silk 1-O mass ligatures were placed proximally and one distally on the vessels followed by division using laparoscopic Metzenbaum scissors between ligatures. The same procedure was then performed on the right spermatic vessels. After ascertaining adequate hemostasis, trocars were removed, fascia and skin sutured.

**Results:** Our technique of bilateral varicocelectomy using Silk 1-O ligatures was performed on seven male patients, ages 23 to 44 years (mean = 35.3 years) with left-sided Grade III varicoceles and right-sided Grade I or II varicoceles. All patients were infertile with abnormal sperm parameters. Average total operative time was 141 minutes (range = 125 to 173 minutes) for Silk 1-O ligation. This was 16 minutes more than the average of 125 minutes (range = 115 to 135 minutes) for our previous patients undergoing clip ligation. All patients were discharged on the day after laparoscopy. No significant complications or recurrences of varicoceles were noted up to nine months of follow-up.

**Conclusion:** We demonstrate our technique of bilateral laparoscopic varicocelectomy for infertile males with bilateral varicoceles using Silk 1-O mass ligation-division of spermatic vessels. Silk ligation is effective and safe. Silk ligatures are readily available and affordable to indigent patients in developing countries.

### VS2-07 SPLENOGONADAL FUSION: AN UNUSUAL CAUSE OF AN ASCENDING TESTIS AND LAPAROSCOPIC SOLUTION

O. Ziyilan, O. Sanli, A. Atar, T. Tefik, M. Karadeniz, H. Ander

**Background:** Splenogonadal fusion is a rare entity allowing fusion of the unrelated organs. The continuous type of splenogonadal fusion describes the gonad attached to the anatomic spleen whereas in discontinuous type to an accessory spleen or ectopic splenic tissue. In our clinic, laparoscopy-assisted orchidopexy has been described in a case with continuous type splenogonadal fusion.

**Methods:** In a 6 years old patient presented us with a complaint of highly located left testicle, operation was decided upon left high scrotal testis on examination but was postponed because of other medical problems. After 1 year of delay, laparoscopy was decided according to the unpalpable testis on the left side.

**Results:** The left testis was in 2 cm distance, near the deep inguinal ring and an attachment was detected between spleen and superior pole of the testis on laparoscopic exploration. Hemostasis was achieved with titanium clips applied between spleen and testis and the fibrous band was transected. Dissection of the testicular vessels and vas deferens was completed laparoscopically while the testis retrieved, placed and fixed into the scrotum. Laparoscopy time was 95 minutes and the patient was discharged on the same day.

**Conclusion:** In the patient undergoing surgery with ascending testis, splenogonadal fusion was detected as an etiologic factor. In picture of ascending testis and left-sided unilateral nonpalpable testis, splenogonadal fusion probability should be considered in differential diagnosis. Laparoscopy is the most appropriate and daily-applicable method for the solution of problem.

### VS2-08 OPTIMIZING RESULTS OF SUBURETHRAL SLING OPERATIONS AMONG MALES USING SUBURETHRAL HYALURONIC ACID INJECTIONS

J. Neymeyer, W. Abdul-wahab al-Ansari, S. Kassin, M. Beer—Berlin

**Background:** Suburethral sling procedures have become the gold standard therapy for male stress urinary continence resulting after radical prostatectomy or trans urethral prostatectomy operations. So far, this technique has succeeded in reducing involuntary loss of urine by anywhere between 50 to 80%. Our aim was to further improve these results by the administration of hyaluronic acid injections in the suburethral region proximal to the external urethral sphincter.

**Methods:** This study included a total of 24 male patients who continued to suffer from SUI following radical prostatectomy or TURP despite undergoing suburethral sling procedures. The number of pads required per day by each patient was documented. All of these patients were then given suburethral hyaluronic acid injections at the site of the external urethral sphincter in order to reduce the magnitude of their SUI. Clinical assessment was then based upon the number of pads required after the Hyaluronic Acid injections in comparison to the number of pads used before this treatment modality was instituted.

**Results:** Current literature has shown that male urethral sling procedures improve SUI by anywhere between 50 to 80%. However, by administering an additional treatment of suburethral hyaluronic acid injections we are able to enhance these results by a further 20%. This means that grade II & III SUI use an average of 0 to 1.5 pads per day after instituting this additional therapy.

**Conclusion:** Suburethral injections of Hyaluronic Acid administered to our study group of post-operative male sling procedures have succeeded in reducing the daily use of pads from 5 pads to anywhere between 0 to 1.5 pads per day.

**VS2-09 BLADDER EROSION OF TENSION-FREE VAGINAL TAPE: REMOVAL BY STANDARD TRANSURETHRAL RESECTION**

M. Baykara, O. Celik, S. Yucel, T. Erdogru

**Background:** Although Tension-free vaginal tape (TVT) in the treatment of stress urinary incontinence has gained a large popularity among urologists and uro-gynecologists due to its low morbidity and high success rates, complications have been reported to be increasing as more and more patients have undergone this procedure. Some specific complications to TVT procedure are bowel perforation, bladder perforation, major vessel injury, retro-pubic hematoma and erosion of the tape into urethra or bladder. There are many surgical treatment methods for bladder erosions including endoscopic and open intervention or a combination of both. In this video, we present the standard transurethral resection of bladder erosion of TVT with postoperative follow-up period.

**Methods:** A 53-year-old lady presented to our clinic with severe persistent cystitis, dysuria and hematuria complaints for the last 2 years. In her past-medical history, there was a TVT procedure for stress urinary incontinence in 2003 at an outside health center. Her physical examination revealed some tenderness on suprapubic area. Her introitus and vagina was normal on inspection and palpation. She denied any stress urinary incontinence since surgery. Her urinalysis revealed significant pyuria with no bacterial growth in the urine culture. Plain KUB showed an irregularly shaped 2-cm radiodensity in the bony pelvis. Cystoscopy showed a stone fixed to her right bladder wall. When the stone was removed transurethraly the underlying tape in the bladder was seen. A standard monopolar transurethral resection to the tape was performed until all material was removed and perivesical fat was observed. Her postoperative period was uneventful and she was discharged next day. Urethral catheter was removed at the post-operative 15th day.

**Results:** As the urethral catheter was removed, a filling cystogram and pelvic USG was performed revealing no extravasation. She reported a complete relief of symptoms. On the third month, a check cystoscopy was done and no residual tape was observed in the bladder and bladder mucosa appeared healthy except scar tissue at the resection site.

**Conclusion:** Transurethral resection of TVT is a plausible treatment method in bladder erosion cases if an aggressive and complete removal of the tape could be performed.

**VS2-10 TAPE RESECTION FOLLOWING TRANSOB-TURATOR TAPE (TOT) OPERATION FOR STRESS URINARY INCONTINENCE**

C. Gurbuz, S. Gungor, B. Guner, O. Arikan, T. Caskurlu—Turkey

**Background:** Sling materials for treatment of urinary stress incontinence have a high success rate of achieving continence. The transobturator approach is gradually replacing the retropubic approach for the treatment of female stress urinary incontinence. The major argument in favour of this approach is the decreased risk of bladder injury. We report a case the sling material was observed in the bladder after transobturator tape (TOT) procedure.

**Methods:** Sixty one year old woman admitted our clinic with a severe dysuria. She had anti incontinence surgery six months ago and denied urinary incontinence. Her medical record showed Gynaecare TOT (inside—out) material was applied. She was listed on cystoscopy and found the mesh material behind the bladder neck level. There was no vaginal erosion. The mesh resected from starting the healthy tissue just few centimeter above the mesh material by using monopolar transurethral resection loop.

**Results:** She was eventually discharged postoperative day 1. Her symptomatology improved within 3 weeks after the tape resection. She is still dry and denies dysuria or voiding symptoms in her 12 weeks follow up. Cystoscopy was performed and healthy wound healing was observed.

**Conclusion:** Although developed to minimize surgical morbidity, the TOT procedure is not risk-free. This case illustrates that TOT is not devoid of risks to the bladder; with sometimes even serious consequences. Intraoperative cystoscopy should be considered only in selected cases. Resection of tape material in the bladder is a safe method for problem solving without affecting the continence status. After the resection of intravesical part of mesh, epithelisation can occur in short time and healthy tissue seen in 12 weeks control.

## VS3: RECONSTRUCTIVE LAPAROSCOPY 1

**VS3-01 LAPAROSCOPIC URETERO-URETEROSTOMY FOR RETROCAVAL URETER**

P. Ranjan, K. Shah, A. Ganpule, M. Virmani, R. Sabnis, M. Desai

**Background:** Retrocaval ureter is an uncommon venous anomaly, in which the right ureter course posterior to the inferior vena cava (IVC) and partially encircle it. This can cause varying degrees of ureteral obstruction and surgical intervention is often necessary.

**Methods:** A 19-year old male detected to have right Retrocaval ureter while he was evaluated for recurrent right flank pain of 3-months duration. Laboratory investigations were normal. USG, IVP and CECT revealed type 1 retrocaval ureter. Laparoscopic transperitoneal ureteroureterostomy with DJ stenting was done. Ureter was transected proximally and lateral to IVC, Retrocaval ureter

mobilized in interaortocaval region and brought anterior to IVC. Using intracorporeal suturing ureteroureterostomy was done with vicryl 4-0 sutures. Duration of surgery was 140 minutes. Drain was removed after 48 hours.

**Results:** Patient was discharged on 3 rd postoperative day. There was no major or minor complication.

**Conclusion:** Immediate postoperative period was uneventful. Patient was discharged after 72 hours. DJ stent removed after one month. The classical treatment for Retrocaval ureter consists of separating the ureter, re-anastomosing its stumps and replacing the ureter in its usual position while maintaining its patency. Open ureteroureterostomy has remained the gold standard treatment for Retrocaval ureter. Clearly shown the advantages of minimally invasive approaches like less intraoperative bleeding, a shorter

post-operative hospital stay, reduced post operative pain, earlier return to daily activities and a significant superior aesthetic effect, while preserving therapeutic efficacy.

### VS3-02 LAPAROSCOPIC ANDERSON-HYNES PYELOPLASTY USING CONTOUR INJECTION STENT IN URETEROPELVIC JUNCTION (UPJ) OBSTRUCTION

G. Franco, S. Antonio, R. Ai Ling, G. Antonio Maria, P. Francesco, I. Giacomo Piero—Italy

**Background:** This video shows our experience in laparoscopic Anderson-Hynes pyeloplasty performed by Contour Injection Stent in UPJ obstruction.

**Methods:** Once performed the retrograde pyelography a Contour stent is placed with its kidney coil in the pelvis or just below the stenosis. The bladder coil suture to the injection positioner is kept sterile to be used during the operation. A transperitoneal access with the patient on his side (90 degree) is performed with 5 trocars. After pneumoperitoneum's induction the kidney pelvis is enlarged by injection of saline through the stent. This manoeuvre allows an easy pelvis identification and a very little incision. The ureter and the abnormal vessel, when present, are then identified and isolated. After positioning the reference stitches, pelvis and ureter are sectioned respectively above and below the stenosis. The abnormal vessel is placed back to the pelvis and the ureter is sectioned longitudinally. The anastomosis is performed by two 4/0 running sutures. The water tight anastomosis is tested by injection of solution through the distal end coil. A retroperitoneal drainage is placed and the peritoneum is sutured.

**Results:** Laparoscopic pyeloplasty is the gold standard in the treatment of UPJ obstruction. The use of the Contour Stent allows to improve the exposure of the pelvis during each step of the operation. In the post operational time it offers a good drainage of the escretory system, it gives the opportunity to wash out clots and to perform pielography in the suspect of an urinary fistula. The modification in a Double J catheter can be made directly at the patient's bed, avoiding endoscopic and anesthetic procedures and X ray exposure.

**Conclusion:** Based on our experience the Contour System Injection offers in laparoscopic pyeloplasty multiple advantages compared to the other stents.

### VS3-03 URETERIC REIMPLANTATION BY LESS: COSMESIS MAINTAINED!

S. Mishra, M. Desai, A. Kurien, A. Ganpule, R. Sabnis, M. Desai—India

**Background:** To demonstrate the surgical technique, instrumentation, and perioperative outcomes of LESS ureteroneocystostomy.

**Methods:** 22 yrs female was evaluated for the complaints of recurrent mild to moderate left flank pain associate with low grade fever, nausea and vomiting of seven days duration. She was febrile at presentation. On evaluation she was found to have left obstructed megaureter. Left PCN was placed initially, followed by retrograde 6/28 fr DJ stenting and the PCN was removed. Later A Laparoscopic single port uretroneocystostomy was performed placing a triport transumbelically which contained one 10 mm and two 5 mm integrated access sites. A two mm port was placed later in the left iliac fossa to assist in the suturing. The 6/28 fr DJ stent was repositioned across the anastomosis. A 16 fr Nelaton tube was placed from the port site at the end of the procedure.

**Results:** The procedure was completed uneventfully. Operative time was 140 minutes. The hemoglobin drop was found to be 1.1 gm%. The drain was removed on second post operative day and the foley catheter was removed on fifth postoperative day. Total Hospital stay was 6 days. There were no perioperative port-related or surgical complications noted and the postoperative recovery was uneventful.

**Conclusion:** LESS is emerging fast in the field of laparoscopic reconstructive urologic surgery. Ongoing refinement in technique and instrumentation is likely to expand its future role.

### VS3-04 LAPAROSCOPIC CIRCUNCAVAL URETERAL REPAIR CONCOMITANT WITH LAPAROSCOPIC- GUIDED NEPROSCOPY FOR CALCULI EXTRACTION

L. Curcio, B. Caçado, A. Cunha, J. Renteria, F. Gusmão, G. Di biase

**Background:** The preureteral vena cava anomaly, erroneously called of retrocaval or circumcaval ureter, is a relative rare condition of extrinsic ureteral obstruction. Despite of be more common on right, when present on left side, is usually associated with situs inversus. The laparoscopic approach, with your all known advantages, has good results when used to treat this congenital anomaly. Our video shows a ureteral transposition with ureteropyelostomy, associated with a nephroscopy and calice calculi extraction.

**Methods:** A 45 yo man, with eventual discomfort in right flank and ecography showing a pyelocalicial dilatation of this side and a calculi of 1.5 cm in a lower calice. KUB contrast radiograph and tomography showed a S-shaped (Atkinson classification) preureteral vena cava besides a midureteral stricture. There are no comorbidities and a PCNL was done 4 years ago in the right kidney. A transperitoneal laparoscopic approach was carried through, with 4 trocars, the ureter sub and supracaval was gently dissected, sectioned near pelvis, transposed and a spatulated. Ureteropyelostomy was done after placement of Double J stent in a antegrade way. Before posterior anastomosis wall suture, we did a nephroscopy trough left hand trocar and the stone was removed by a Dormia extractor.

**Results:** The surgery last 250 minutes, with a minimum blood loss, diet was given in the first postoperative (PO) day and he was discharged at third PO day. After 8 months of follow up, the patient is asymptomatic and excretory urography shows a good draining of right kidney besides a pyelocalicial dilatation reduction and no more calculus.

**Conclusion:** Laparoscopic approach for circumcaval ureter anomaly is feasible and endourologic procedures could be used associated, with good result.

### VS3-05 EXTRAPERITONEAL LAPAROSCOPIC PIELOPASTY (ELP) FOR URETEROPELVIC JUNCTION OBSTRUCTION (UPJO) IN HORSESHOE KIDNEY

U. Anceschi, G. Grosso, A. Amici, C. Torcia

**Background:** Ureteropelvic junction (UPJ) obstruction is often associated with the horseshoe kidney. Transperitoneal Laparoscopic pyeloplasty has been reported as an effective treatment alternative for UPJO associated with renal anomalies. We report our experience with extraperitoneal laparoscopic pyeloplasty technique in the treatment of UPJ associated to horseshoe kidney.

**Methods:** A 38-year-old man presented with asymptomatic right UPJO in a horseshoe kidney. The CT scan showed a horseshoe kidney with an hydronephrotic right moiety. Baseline creatinine

was 1.6 mg/dL. A diuretic renal scan demonstrated accumulation of radiotracer in the right moiety (46% total function) with slow emptying. A ELP was performed. The patient was positioned in a modified left flank position with a slight rotation. Previously, no ureteral catheter was positioned. The working space was created with blunt finger dissection. For the UPJ reconstruction we performed a modified Anderson-Hynes technique with 2 running sutures (Monocryl 3-0). Before starting the anterior suture a double J ureteral catheter was inserted by an anterograde way.

**Results:** The procedure was performed successfully with no conversion to open surgery. Mean operative time was 150 mins. No complication occurred intraoperatively and postoperatively. The ureteral stent was removed in postoperative week. At 3 month-follow up the excretory urography confirmed no extravasation and the diuretic renal scan showed properly emptying of tracer.

**Conclusion:** ELP for UPJO is feasible in patients with upper urinary tract anomalies such as horseshoe kidney. The extraperitoneal route may reduce the incidence of intraperitoneal urine leakage. However, this approach is uncommon to most of the urologic surgeons who routinely perform laparoscopic surgery by a transperitoneal way.

### VS3-06 CAN OUR NEW TECHNIQUE LAPAROSCOPIC STEPWISE-CUT DOUBLE INITIAL KNOT PYELOPLASTY OVERCOME SOME DIFFICULTIES OF PYELOPLASTY?

Y. Ozgok, M. Ates, M. Hoscan, S. Basal, M. Zor, M. Dayanc—Turkey

**Background:** We performed a new modified pyeloplasty technique named laparoscopic stepwise-cut double initial knot pyeloplasty (LASDIKP) for uretero-pelvic junction obstruction (UPJO) treatment and we evaluated the efficiency, safety and short-term outcome of this technique.

**Methods:** Four UPJO with impaired drainage on diuretic renal scan were included the study. Performing this technique, a “T shape cut” is made to the dilated pelvis and ureter. Before cutting the ureter, first initial knot is placed between lower edge of pelvis and spatulated anterolateral part of ureter. Pelvis is narrowed with continuous suture starting from opened superior edge of the pelvis, till leaving enough space for ureteric anastomosis. This second initial knot is placed at longer edge of ureter opposite to the spatulated part, just distal to the stenotic segment of ureter. Thereafter second initial knot is placed after passing ureter and pelvis second time. At this step, dilated part of renal pelvis and stenotic segment are excised and two times passed sutures are pulled one by one by using pulley system for not losing tension. The remaining space between two initial sutures is closed with these continuous sutures.

**Results:** All cases were successfully completed using LASDIKP technique. Median operating time was 197 minutes (100–290 minutes). All patients had improvement in symptoms and the nuclear scan showed non-obstructive drainage postoperatively.

**Conclusion:** As Anderson-Hynes pyeloplasty is hampered by difficulties during some steps, LASDIKP can overcome these difficulties safely that it can be an option in the surgical treatment of UPJO with intrinsic stenosis.

### VS3-07 LAPAROSCOPIC URETERAL REIMPLANTATION FOR THE MANAGEMENT OF URETEROVAGINAL FISTULA AFTER TOTAL ABDOMINAL HYSTERECTOMY WITH BILATERAL SALPINGO-OOPHORECTOMY

V. Tugcu, E. Sonmezay, N. Gurbuz, A. Tasci—Turkey

**Background:** In this video presentation we showed a laparoscopic right ureterovesical reimplantation using Lich-Gregoir technique in a forty four aged woman patient with a total incontinence clinic who had a past medical history of total abdominal hysterectomy with bilateral salpingo-oophorectomy. On the fourteenth day of gynecologic operation we performed a retrograde urography and saw that ureteral catheter was not in the system and radioopaque dye was spreading to the genital tract. Then we planned an operation for diagnosis of ureterovaginal fistula.

**Methods:** The parietal peritoneum is incised from the lateral side with bipolar cautery and scissors. The right plane is dissected with sharp and blunt dissection. Then dissection started lateral to the right iliac vessels and continued medially. Due to fibrosis dissection is done carefully to avoid an injury of an adjacent structure. For hemostasis we used bipolar coagulation and harmonic scalpel in this part of the operation. After exposing the dilated ureter and iliac vessels, for better visualization, we hanged the bladder up to the anterior abdominal wall using 2 separated Vicryl 2/0 sutures. Then ureter dissected distally and become completely free. Before reimplantation, perivesical fat tissue and muscle layer dissected sharply. The bladder is dissected up to the mucosal layer. We cut the ureter from a distal place. Then a posterior stitch is passed from the bladder to the posterior ureteral stump in an in-out style and a double J catheter is placed on the proximal ureter and bladder. Afterwards, anastomosis completed with separate sutures. Finally detrusorraphy is performed and operation ended.

**Results:** One month later double J catheter is removed. On the follow-up term there is no findings about the disease.

**Conclusion:** This operation and results show us that laparoscopic ureteroneocystostomy is safe and effective method as open technique.

### VS3-08 DISMEMBERED RETROPERITONEOSCOPIC PYELOPLASTY FOR THE TREATMENT OF SYMPTOMATIC URETEROPELVIC JUNCTION OBSTRUCTION WITH CROSSING VESSELS. TRANSPOSITION OF URETER NECESSARY?

S. Subotic, A. Gözen, T. Bayer, R. Gumpinger, J. Rassweiler—Germany

**Background:** Traditionally open pyeloplasty has been the gold standard treatment of UPJO in children and adults with success rates being quoted at over 90%. Specifically due to confined working conditions and difficulties with anastomotic suturing, open access was required. However during the last decade the management has been revolutionized with the introduction of laparoscopy and endourology yielding not only comparable results but also less morbid outcomes.

**Methods:** A 66 yr old female patient presented with acute left side pyelonephritis. Ultrasonographic examination identified a massive dilatation of the renal hilum. While stent insertion a UPJO was diagnosed. After acute treatment with ureteral stent insertion and antibiotics she underwent one week later a retroperitoneoscopic dismembered pyeloplasty. Due to aberrant vessels (anterior, dorsal), as the extrinsic cause of the UPJO, the ureter was transposed.

**Results:** The operation time including ureteral stent reinsertion was 148 min. Intra- and postoperative course was uneventful and the patient was discharged 5 days postoperatively. The female patient was pain free after DJ stent removal and complete drainage of the collecting system 4 weeks later.

**Conclusion:** Aberrant vessels are the main cause for UPJO when treated by laparoscopic pyeloplasty. Optimal results can be



achieved by complete isolation of the ureter and the aberrant vessels, transposition of the ureter if required and adequate suturing technique.

### **VS3-09 LAPAROSCOPIC BILATERAL DISMEMBERED PYELOPLASTY IN CHILDREN: 3-PORT TECHNIQUE**

A. Basiri, M. Asl Zare, S. Hosseini, H. Djaladat

**Background:** The classic option of treatment for ureteropelvic junction obstruction (UPJO) is open dismembered pyeloplasty. Laparoscopic pyeloplasty for management of UPJO in the pediatric patients is comparable to open technique in success rate. We report our technique with a transperitoneal 3-port laparoscopic dismembered Pyeloplasty.

**Methods:** Two children with bilateral UPJO underwent simultaneous bilateral laparoscopic dismembered pyeloplasty. We started the procedure in semi-flank position via 3-ports in midline and after changing the position we continued procedure on another side with the same 3 midline ports, without need to contralateral trocar placement. Both of children were followed with diuretic renogram.

**Results:** The procedures were done without complication. Total operative time was 245 minutes and 225 minutes for the 3-month-old and the 5-year-old, respectively. The Double J stents were removed at 4 weeks after surgery under sedation. Renal scans in both patients at 6 months post operatively revealed no evidence of obstruction.

**Conclusion:** The transperitoneal laparoscopic approach will allow us to perform a bilateral repair with the benefits of minimally invasive surgery.

### **VS3-10 ROBOT ASSISTED LAPAROSCOPIC PYELOPLASTY FOR RIGHT RENAL DOUBLE SYSTEM**

F. Porpiglia, C. Fiori, I. Morra, R. Bertolo, R. Scarpa

**Background:** Laparoscopic pyeloplasty has gained in the last years always more consensus thanks to its mini-invasiveness and its functional results comparable to those of traditional surgery. More recently the DaVinci robot appeared useful in this type of procedure even if only few data with short follow-up is available in literature. We report the case of a patient with a right renal double system, and affected with ureteral joint disease of the inferior district treated with robot assisted laparoscopic pyeloplasty with a latero-lateral anastomosis of both systems.

**Methods:** (Operative technique): patient is placed with a 45° left lateral decubitus. After induction of pneumoperitoneum with a Verres needle, retroperitoneum is accessed by pushing down the posterior down at level of the right ureteral joint. Pelvis, joint ureters from both systems are progressively isolated. A longitudinal section of pelvis, joint and of the first tract of lumbar ureter and of proximal ureter of the superior system is performed. A latero-lateral suture of both hemisystems is performed with running Vicril 5/0 suture taking care in obtaining extraluminal knots. Once completed the posterior plan of anastomosis, a ureteral JJ stent is applied with an ascending technique and controlled by pneumocystoscopy. The anterior suture is completed.

**Results:** Operative time was 150', blood loss was insignificant and no complications were registered. Post operative renography evidenced regular figures.

**Conclusion:** Laparoscopy endorses a strategic role in the treatment of functional disease such as joint disease. Da Vinci robot makes suture easier and more precise in confront to traditional laparoscopy and appears in some particularly complexed situations just as this one irreplaceable.

## **VS4: LAPAROSCOPY—KIDNEY 1**

### **VS4-01 SINGLE INCISION LAPAROSCOPIC RENAL CRYOSURGERY**

U. Boylu, M. Oommen, R. Thomas, B. Lee—USA

**Background:** To evaluate the feasibility and safety of the single incision laparoscopic cryosurgery.

**Methods:** A 65-year-old male with a solitary kidney presented with a 2.5 cm enhancing solid mass in the lower pole of the left kidney. A 3 cm vertical skin incision was made inferior to the umbilicus. After placement of the single port trocar, the R-Port (Advanced Surgical Concepts, Wicklow, Ireland) and subsequent insufflation, pneumoperitoneum was maintained at a pressure of 15 mm Hg. The R-Port is a multichannel access device, which allows simultaneous passage of up to 3 instruments. Articulating laparoscopic instruments such as flexible needle driver, grasper, dissector, and scissors (CambridgeEndo, Framingham, MA) and a 5 mm flexible laparoscope with a range of motion of 90 degrees in X- and Y-axis (Olympus Surgical, Orangeburg, NY) were utilized. After mobilization of the lower pole, the tumor was identified and localized using the laparoscopic ultrasound. Three 17 G percutaneous cryosurgery needles were inserted into the mass. Subse-

quently, 2 cycles of freeze/thaw were performed in standard fashion.

**Results:** Operative time was 150 minutes. The surgery was accomplished without any complications. Estimated blood loss was 75 ml. The patient was discharged within 24-hours. The simultaneous use of two articulating instruments and a 5 mm flexible laparoscope through the Single Port (R-Port) device allowed for excellent tissue dissection and mobilization of the lower pole of the kidney for subsequent cryosurgery.

**Conclusion:** The addition of single incision laparoscopy to cryosurgery adds to the armamentarium and options for treatment of small renal masses.

### **VS4-02 ROBOTIC-ASSISTED LAPAROSCOPIC PARTIAL NEPHRECTOMY FOR HILAR LESIONS: LESSONS LEARNED**

L. Dulabon, P. Mufarrij, E. Hyams, M. Stifelman—USA

**Background:** Renal hilar tumors often pose additional technical challenges for the surgeon performing laparoscopic nephron-sparing surgery. It has been suggested that robotic-assisted lapa-

roscopic partial nephrectomy (RAPN) may facilitate surgical resection and improve outcomes in patients with renal hilar tumors. **Methods:** We prospectively collected data on 60 consecutive patients who underwent RAPN over the past 14 months (April 2008–June 2009) at our institution by a single surgeon (MS). We then identified 6 patients with renal hilar tumors, defined as tumor in direct contact with the renal artery and/or vein, as seen on pre-operative imaging and confirmed by intra-operative findings. This narrated video illustrates the surgical technique of three particular cases of RAPN for renal hilar tumors, and highlights the salient lessons learned for the surgical resection of these challenging kidney lesions.

**Results:** Successful surgical outcomes were noted in all three cases. Mean tumor size was 2.67 cm. Average blood loss was 250 mL, and mean warm ischemia time was 29 minutes. We highlight important lessons learned from our experience including: the utilization of laparoscopic ultrasound for the resection of endophytic tumors, employment of the endoscopic Doppler probe to confirm ischemia after arterial clamping, and the application of renal vein occlusion to prevent excessive back bleeding during resection of endophytic tumors. Additionally, we highlight the fact that surgical bolsters do not routinely need to be utilized during robotic-assisted renorrhaphy.

**Conclusion:** Robotic assistance may be used successfully for the resection of renal hilar tumors. We highlight important lessons learned from our experience.

#### VS4-03 USE OF COLD SCALPEL IN LAPAROSCOPIC PARTIAL NEPHRECTOMY

R. Sotelo, E. Di grazia, R. De andrade, D. Ramirez, O. Carmona, D. Canes—Venezuela

**Background:** Energy-based tumor resection techniques for partial nephrectomy may be ineffective in coagulating larger vessels and sinuses while altering and distorting tissue appearance of the resection margin. These may prevent a clear evaluation of margin status, and obscure the exact location of bleeding vessels and collecting system entry. Scissors may leave an uneven resection surface for renorrhaphy, and dissection along a chosen resection path can be slow. The scalpel has been used effectively during open partial nephrectomy. In this video we demonstrate the technique of cold scalpel resection during laparoscopic partial nephrectomy, and report our preliminary results.

**Methods:** We performed a laparoscopic partial nephrectomy with cold scalpel in 4 patients with incidental small renal masses. After having clamped the artery, cold scalpel mass resection was accomplished with a purpose-built laparoscopic scalpel. Cut edges of individual transected vessels were grasped and Hem-o-lock clips placed for hemostasis (Weck Closure System, Research triangle Park NC). Interrupted absorbable sutures were also placed where appropriate. Renal parenchyma was repaired over surgical bolsters applying sutures secured with Hem-o-lock clips.

**Results:** Results, clinical and tumors features are reported in the following table

PATIENT	1	2	3	4
Gender	Male	Female	Male	Male
Comorbidities	None	None	Hypertension	None
Previous abdominal surgery	Herniorrhaphy	Suprapubic prostatectomy	Ovarian cyst resection	None
Incidental finding	None	None	Symptoms	Incidental finding
Incidental finding	Incidental finding	Incidental finding	Tumor side	Left
Incidental finding	Incidental finding	Incidental finding	Operative time (min)	24
Incidental finding	Incidental finding	Incidental finding	Pre-post operative Hct variation	3,3
Incidental finding	Incidental finding	Incidental finding	Pre-post operative Hb variation	1,1
Incidental finding	Incidental finding	Incidental finding	Pre-post operative Hct variation	1,3
Incidental finding	Incidental finding	Incidental finding	Pre-post operative Hb variation	2,5
Incidental finding	Incidental finding	Incidental finding	Pre-post operative Hb variation	1,5
Incidental finding	Incidental finding	Incidental finding	Pre-post operative Hb variation	8,1
Incidental finding	Incidental finding	Incidental finding	Pre-post operative Hb variation	5,9

timated blood loss (cc) 400 300 600 300 Transfusion rate 1 unit  
Tumor size (cm) 3.5×2.5 3.5×3 4.5×3 3.1×3.1 Tumor weight (gr)  
26 31 40 29 Pathology Clear renal cell Furhman II Clear renal cell  
Furhman III Clear renal cell Furhman I Clear renal cell Furhman I  
Margins Negative Negative Negative Negative.

**Conclusion:** Our preliminary impression is that laparoscopic cold scalpel partial nephrectomy is feasible, allows a very precise and smooth cut, expeditious resection, reliable gross detection of tumor margins, and optimal visualization of open vessels and entry in collecting system. In the future, application of the scalpel to robotic wristed instrumentation may allow a contouring dissection akin to curved scissors, broadening the applicability to tumors in challenging or hilar locations.

#### VS4-04 LAPAROSCOPIC PARTIAL NEPHRECTOMY FOR FOREIGN BODY SIMULATING RENAL CANCER

R. Sanseverino, G. Napodano, O. Intilla, U. Di mauro, M. Iacone—Italy

**Background:** We report the case of a 61 year old male presenting with an upper pole right renal mass suggestive of renal cell carcinoma which resulted to be a retained surgical gauze.

**Methods:** The case of a patient with a history of previous nephrolithotomy 30 years before, with subsequent Percutaneous nephrolithotomy and ESWL, who presented with flank pain. Abdominal Ultrasound and CT-scan were suggestive of malignant renal mass of right upper pole kidney. A right transperitoneal laparoscopic radical nephrectomy was planned. After performing renal biopsy, we noticed a gauze oozing out from lesion. So we decided to perform a partial nephrectomy. The renal vessels are carefully dissected and isolated; mannitol is given intravenously before pedicle clamping. The renal artery and vein are clamped with a self made tourniquet. The lesion is excised with Ligasure™. Renal parenchyma was repaired with Vicryl™ sutures secured with Hem-O-lock clips™. The vein and the artery are unclamped. The lesion is extracted in Endobag. After controlling the peritoneal cavity, a drain is placed into the abdomen.

**Results:** No perioperative complications occurred. The patient was discharged on day 4.

**Conclusion:** A retained surgical gauze should always be suspected in all patient with an abdominal mass and with history of previous renal surgery without caring the time lapsed between surgery and the discovery.

#### VS4-05 SIMPLIFICATION OF THE LAPAROSCOPIC PARTIAL NEPHRECTOMY TECHNIQUE

M. Baptistussi, E. Gewher, M. Morihisa

**Background:** For renal tumors smaller than 4 cm, there is currently a world trend to perform a nephron-sparing surgery, thus preserving as much renal mass as possible. We have performed the surgery with 4 punctures (two 10 mm, one 12 mm, and one 5 mm), with isolation of the renal hilum and release of the whole kidney's Gerota, thus preserving it over the tumoral area. We used vascular clamp for the renal artery, 10 mm scissors to cut the renal lesion with safety margin and quickly. We previously placed the renal suture stitches inside de cavity, one end with a Vicryl 2.0 knot and hemolock clip to secure it, and the needle placed to be threaded, attached to the parietal peritoneum. Hot ischemia time with this change was 18 min + 1.5 min versus 24 min + 2 min, by placing stitches one by one in a row, without being within the cavity.

**Methods:** None.

**Results:** None.

**Conclusion:** This slight technical change facilitates the procedure and significantly decreases the hot ischemia time.

#### VS4-06 EVOLUTION OF LAPAROSCOPIC PARTIAL NEPHRECTOMY

A. Berger, R. Brandina, M. Aron, R. Stein, M. Desai, I. Gill

**Background:** In this video we demonstrate the evolution of laparoscopic partial nephrectomy (LPN) in 5 different techniques employed by our team.

**Methods:** From September 1999 until June 2008, we have performed 1000 LPN. Standard LPN was applied in 820 cases. In this technique, renal parenchyma and collecting system reconstruction and hemostasia are performed with a clamped renal hilum. In 2006, a new early unclamping technique was introduced. In this contemporary technique, the renal hilum is unclamped after the first line of suture is applied to the partial nephrectomy excision bed. Robotics have also been applied to partial nephrectomy. So far, thirty-five cases have been performed robotically. In a pilot clinical trial, a special robotic instrument for the da Vinci System was developed and KTP laser was used to excise renal tumors leaving the renal hilum unclamped. Recently, 10 LPN were successfully performed through a novel multi-channel single port device.

**Results:** Standard LPN technique was applied in 820 patients. Mean tumor size was 2.7 cm, Mean operative time, mean warm ischemia time (WIT) and estimated blood loss (EBL) were, respectively, 204 min, 30 min and 258 ml. The early unclamping technique was used in 180 patients. Mean tumor size was 3.1 cm. Mean OR time and WIT were 220 min and 14 min, respectively. EBL was 346 ml. Robotic partial nephrectomy was performed in 35 patients. Mean tumor size was 3 cm. Mean OR time and WIT were 215 min and 14 min, respectively. EBL was 300 ml. In 5 cases where KTP laser was used, mean tumor size was 1.8 cm. Mean OR time was 310 min and EBL 400 ml. The hilum was left unclamped in all but 1 case. In the single-port LPN group, mean tumor size was 3 cm. Mean OR time and WIT were, respectively, 270 min and 20 min. EBL was 150 ml. Surgical navigation and augmented reality during LPN are still under development.

**Conclusion:** All over the years, our technique of LPN has changed and new technologies have been and will be continuously employed.

#### VS4-07 LAPARO-ENDOSCOPIC SINGLE SITE (LESS) NEPHRECTOMY FOR BENIGN AND INFLAMMATORY CONDITIONS

S. Permpongkosol, C. Leenanupunth

**Background:** To report a contemporary series of patients with surgical management for benign and inflammatory conditions with Laparo-endoscopic single site (LESS) nephrectomy.

**Methods:** During August 2008 to May 2009, 6 patients (mean age 60.8 years, range 37–91) underwent transumbilical single port laparoscopic (SPA) nephrectomy and confirmed with chronic pyelonephritis and non functional kidney; information on the mode of presentation, surgical management, and complications were analyzed. All procedures were performed through a single intraumbilical multichannel laparoscopic port.

**Results:** LESS is feasible and safe approach in 66.7% of patient underwent SPA nephrectomy. Histology of Xanthogranulomatous pyelonephritis was confirmed in one case. In an additional proce-

dure during the operation, two cases were required fluid aspiration to decrease the kidney size. Two (33.3%) SPA nephrectomies with higher waist circumference were converted to standard laparoscopic nephrectomy due to failure to progress. The postoperative complication rate was 16.7% (1 case) since umbilical hernia.

**Conclusion:** Laparo-endoscopic single site (LESS) of Laparoscopic nephrectomy can be performed safely in most patients with benign inflammatory conditions that require surgical extirpation. In highly selected patients this approach can be offered, with acceptable morbidity, allowing for lower blood loss and shorter convalesce times.

#### VS4-08 LAPAROSCOPIC REPAIR OF NEPHROPTOSIS WITHOUT KNOT USE

L. Curcio, A. Cunha, J. Renteria, R. Freire, F. Gusmão, G. Di biase—Brazil

**Background:** The patient with kidney ptosis, when in orthostatic position, can feel troublesome symptoms, mainly lumbar pain (probably in face of renal transitory ischemia) demanding surgical fixation of this organ to psoas and quadratus lumborum muscles. Laparoscopic approach is very efficient in this case, through trans as well as retroperitoneal route, taking many already reported benefits to the patient. We report a case, in video, where was used a renal fixation technique just with polymers clips.

**Methods** 65 y o, female, complaining of right lumbar pain. Excretory urography showed a kidney fall, whenever changing the position from supine to orthostatic, beside of ipsilateral ureteral kinking. A transperitoneal nephropexy was carried trough with four ports and interrupted monofilamentar sutures with polymers clips (Hem-O-Lok<sup>®</sup>-Pilling Weck) arrested in the tip was used to set up the kidney in certain position.

**Results:** There was a minimum blood loss, surgery last 190 minutes and the patient was discharged at third post-operative day. She presented pain and paresthesia in right inferior limb that ameliorated with gabapentin use for 1 month. Her urography, three months later, showed the kidney in a L2 body vertebrae position.

**Conclusion:** Despite of no random prospective studies comparing both techniques, laparoscopic nephropexy has reach acceptables overcomes, contrasting with the bad longer follow up results with open procedures. The polymer clip fixation (like is used in partial nephrectomy), can be a good alternative to avoid complications and failures in renal ptosis treatment.

#### VS4-09 COMBINED LAPAROSCOPIC TRANSPIELIC BALLISTIC LITHOTRIPSY AND RENAL CYST ABLATION

G. Pini, S. Micali, M. Sighinolfi, F. Annino, S. De stefani, G. Bianchi

**Background:** Laparoscopic pyelolithotomy could be challenging in case of pyelocaliceal staghorn stones trapped by a narrow caliceal neck. The video describes a laparoscopic transpielic ballistic and ultrasound lithotripsy through a rigid nephroscope.

**Methods:** A 55 years old man had a complex cyst (12 cm-Bosniak II) of the left kidney and 5 stones: 4 pelvic (1–2 cm) and one pyelocaliceal (2.5 cm). Patient in 45° flank position; 4 transperitoneal trocars. We exposed the retroperitoneum and the kidney. Visualized the cyst it was drained and unroofed, than we performed a pyelotomy. A flexible cystonephroscope inserted trough a 10–12-mm trocar make easy removal of all pelvic stones but not the pyelo-caliceal one, because of a narrow caliceal neck. We intro-

duced, through a trocar, a rigid nephroscope directly into pyelotomy and we attempted a ballistic lithotripsy splitting the stone (Swiss LithoClast Master®, EMS). Largest fragments were extracted with grasper. Antegrade double-J stent was positioned and pelvis was repaired with 3-0 running suture.

**Results:** Operative time 155 minutes, intraoperative bleeding <25 ml; discharge in 4th day; histological findings: negative for cancer. JJ stent removed in 20th postoperative day. Follow-up excluded hydronephrosis, residual stones and cyst relapse.

**Conclusion:** Introduction of a rigid nephroscope through pyelotomy is safe: it offers best water flow, better visualization and big working channel. LithoClast Master® (PCNL modality) could be useful to treat big stones trapped by a narrow caliceal neck. Laparoscopic approach avoids damage of both urothelium and renal parenchyma and offers advantage to treat quickly more concomitant disease.

**VS4-10 URETEROSCOPIC MANAGEMENT FOR SYMPTOMATIC PARAPELVIC RENAL CYST**

A. Basiri, S. Hosseini, V. Najjaran Tousi, M. Mohammadi sichani, M. Asl Zare

**Background:** Parapelvic cyst could be managed with various challenging techniques. Due to the proximity of parapelvic renal

cyst and the renal pelvis, we have performed endourologic technique that is both effective and less invasive.

**Methods:** Two men (53 and 56 years old )with parapelvic cyst on CT scan (5×6 cm and 6.5×7.5 cm) that had compressed and displaced the collecting system with moderate to severe Hydronephrosis were referred to us. We decided to incise the cyst by a ureteroscope to make internal drainage of parapelvic renal cyst into the renal pelvis possible. Therefore, we started ureteroscopy with a 8.5Fr semi-rigid ureteroscope to inspect pelvicaliceal system at first. Lateral renal pelvis wall was bulged because of the cyst. Using the tip of the ureteroscope, the urothelium was stripped away to identify the cyst wall. Then, the cyst wall was incised extensively by electrocautery hook in the first patient, and by holmium laser in the second one. At the end of the procedure, a ureteral catheter was inserted in the unroofed cyst to ensure a wide patency between the cyst and the renal pelvis in retrograde pyelography.

**Results:** Our patients were discharged on the day of operation. Until 6 month follow up symptoms and images showed significant improvements. There were no complications in these two cases.

**Conclusion:** Ureteroscopic management is a less invasive outpatient procedure in comparison with the other techniques in the selected patients with large parapelvic renal cysts.

## VS5: PERCUTANEOUS SURGERY 1

**VS5-01 TUBELESS PERCUTANEOUS NEPHROLITHOTOMY: OPERATIVE STEPS AND RESULTS**

A. Elnahas, I. Eraky—Egypt

**Background:** This video will present operative steps for safe nephrostomy-free percutaneous nephrolithotomy.

**Methods:** Under the effect of general anesthesia and after insertion of a ureteral catheter, the patient was placed in prone position. The percutaneous tract was established to a posterior calyx under fluoroscopic guidance using multidirectional C-arm. The tract was dilated using coaxial dilators, and then a rigid nephroscope was passed through an Amplatz sheath. Ultrasonic lithotripsy was used for large stones. Fixation of a nephrostomy tube was omitted in patients with no obvious residuals, no perforation or excessive bleeding. The ureteral catheter was removed in the next day after unenhanced CT confirmed absence of significant residuals.

**Results:** From January 2008 through January 2009, Tubeless PCNL was performed for 25 patients (11 males and 14 females) with mean age 54 years (15–71). Two cases had a solitary kidney. The stone burden was single large pelvic stone in 17 patients, multiple stones in 5 and partial staghorn stones in 3. Supracostal puncture was needed in 7 cases. Stone disintegration was required in 15 cases (60%) and flexible nephroscopy was used in 5 patients (20%) with radiolucent stones to confirm stone-free status. Postoperative hematuria developed in 2 patients (8%) and was managed conservatively. Postoperative CT showed small peri-renal hematoma in 3 patients (12%) and a small insignificant residual in one patient (4%).

**Conclusion:** Tubeless PCNL in selected patients is a secure and less morbid procedure that does not compromise patient safety.

**VS5-02 A NOVEL 5 PART PERCUTANEOUS ACCESS NEEDLE WITH GLIDEWIRE (5-PANG) TECHNIQUE FOR FASTER PERCUTANEOUS NEPHROLITHOTOMY: OUR INITIAL EXPERIENCE**

A. Ashish patil—India

**Background:** Percutaneous nephrolithotomy (PCNL) is a routinely performed procedure. We describe the use of an innovative 5 part Percutaneous Access Needle with Glidewire (5-PANG) a novel technique in an attempt to make percutaneous nephrolithotomy (PCNL) tract establishment a fast, safe and less cumbersome procedure.

**Methods:** An access needle (5-PANG needle) was fabricated and used for percutaneous renal access during PCNL. The results of the first 57 cases are presented herewith.

**Results:** The 5-PANG technique was used in 65 cases (67 renal units). The male to female ratio was 1.5:1. The technique was used for all calyceal punctures, all kind of stones, renal anatomies and for second time surgeries (11 cases). The mean time required was 44.47 secs and was calculated from the time of the successful entry into the pelvicalyceal system till the placement of the Alken’s rod. The radiation exposure was a mean of 3.46 secs. The puncture was successful at the first attempt in 83.58% cases. Punctured calyx and tract size did not affect the results. There were no intraoperative or

postoperative complications. Conversion to conventional method was not needed in any instance.

**Conclusion:** We find the 5-PANG technique safe, fast, effective and cheap. It is easy to learn and master. We recommend this technique over the standard initial tract dilatation techniques.

### VS5-03 X-RAY FREE PERCUTANEOUS NEPHROLITHOTOMY IN SUPINE POSITION WITH ULTRASOUND GUIDANCE

A. Basiri, M. Mohammadi Sichani, A. Moradi Vadjargah

**Background:** Supine PCNL has numerous benefits compared to the prone position including lower anesthesia risk, shorter operating time, and better ergonomic position for the surgeon. This study was conducted to add some more benefits by omitting X-ray in PCNL in a supine position.

**Methods:** Nineteen consecutive adult patients including one staghorn stone and one horseshoe kidney underwent ultrasound-guided PCNL in supine position. Anesthesia was general in sixteen and spinal in three patients. All patients were placed under ultrasound guidance in supine position. The desired calyx was punctured through lumbar notch. The tract was dilated over a guidewire in a single shot technique under ultrasound guidance from anterior abdominal wall. Once the procedure ended, residual stone was controlled using ultrasound with anterior abdominal wall window. No X-ray was used in any setting of the procedure.

**Results:** The pelvicaliceal system could be successfully approached in all patients. The posterior calices were the most common sites of entry. Mean hospital stay was  $3.56 \pm 1.42$  days and the median of operation time was 100minutes. Only one patient required blood transfusion. Mean sodium change during operation was less than 1 mEq/dl. Mean  $\pm$  SD creatinine before PCNL was  $1.03 \pm 0.24$  and after procedure was  $1.11 \pm 0.22$ . None of the patients suffered visceral injury. The total stone free rate was 84%.

**Conclusion:** Even in our first report with limited experiences it seems that the efficacy of PCNL with ultrasonography in supine position is comparable to PCNL in prone position with fluoroscopy with no more complication.

### VS5-04 SETTING NEW FRONTIERS IN PEDIATRIC PCNL LESS THAN 2 YEARS: MINIPERC, MINI INSTRUMENT TECHNIQUE

R. Patel, S. Mishra, A. Ganpule, R. Sabnis, M. Desai

**Background:** The disadvantages of standard pediatric percutaneous nephrolithotomy (PCNL) include increased blood loss and intra-operative complications due to large size access sheath and instrument negotiated through smaller infundibular width in toddlers. A “miniperc, mini instrument” technique using a maximum 16Fr Amplatz and a miniature 12Fr nephroscope (Wolf) was developed in an attempt to address these drawbacks.

**Methods:** We present a video to describe the above technique. Initial percutaneous access was USG guided. Tract was dilated with Alken dilators and a 16Fr Amplatz sheath was placed. 12Fr nephroscope was used for stone fragmentation and retrieval. Ultrasound burr for intracorporeal lithotripsy and mini stone retrieving forceps were used through the 6Fr working channel of the nephroscope. 1 patient required 12Fr nephrostomy at the completion of the procedure.

**Results:** Four “miniperc, mini instrument PCNL” were performed in toddlers less than 2 years with stone burdens of  $\leq 2 \text{ cm}^2$ . The mean total procedure time, estimated blood loss, and hemoglobin

drop were 46 min, 80 ml, and 0.6%, respectively. There was no procedure-related complication or transfusion. Both the patients were stone-free on follow-up at 4 weeks.

**Conclusion:** As compared with standard PCNL, the “miniperc, mini instrument” technique has similar early success rates in selected patients and may offer advantages with respect to easy maneuverability and blood loss while maintaining similar efficacy.

### VS5-05 SUPINE PERCUTANEOUS NEPHROLITHOTOMY IN HORSESHOE KIDNEY

M. De sio, R. Autorino, C. Quattrone, D. Sorrentino, M. D’armiento—Italy

**Background:** First described by Valdivia Uria, supine percutaneous nephrolithotomy (sPCNL) has gained wide popularity in the last years and it is routinely performed at our Institution. Aim of this video is to show the safety and efficacy of sPCNL also in the stone treatment of patients with horseshoe kidney.

**Methods:** We report a case of right-side kidney stones (overall diameter 4cm) in a 33 years old male patient with horseshoe kidney undergoing sPCNL at our Center. The procedure is carried out under general anesthesia. Under cystoscopic control, a ureteral catheter is introduced, and a retrograde ureteropyelography done. The puncture is done by the urologist on the posterior axillary line and the renal access achieved under fluoroscopic guidance after opacification of the pelvicaliceal system through the ureteral catheter. A superior calyx is punctured to achieve an optimal access to the pelvis and the inferior calyces. Alken coaxial dilators are used for tract dilation. An Amplatz sheath is positioned, allowing the introduction of a 26F nephroscope. Stones are fragmented with an ultrasonic lithotripsy device. A stone retrieval basket is used for fragment retrieval. A flexible nephroscopy is performed to ensure no stone residuals. A nephrostomy and a JJ stent are inserted at the end.

**Results:** Percutaneous access has been performed without complications. The operative time has been 50 minutes. No perioperative complications have occurred. The nephrostomy tube has been removed on 2nd postoperative day, after an antegrade pyelogram showing a good ureteral drainage. At postoperative radiologic assessment no significant residual fragments have been detected.

**Conclusion:** Supine position allows a safe and effective PCNL also in the treatment of patients with horse shoe kidney.

### VS5-06 PERFORMING PERCUTANEOUS NEPHROLITHOTOMY IN THE PRONE-FLEXED POSITION: TECHNIQUE AND BENEFITS

A. Ray, K. Pace, R. Honey—Canada

**Background:** Percutaneous nephrolithotomy (PCNL) is commonly performed for the treatment of large renal calculi and staghorn stones. Knowledge of renal anatomy is essential to ensure a bloodless field as well as to minimize patient morbidity and iatrogenic organ injury. We describe our technique in detail and demonstrate a prone-flexed modification which has several advantages over conventional prone positioning.

**Methods:** At our institution, PCNL is routinely performed with the patient in the prone position with an additional 30–40° flexion at the hip. Following the retrograde injection of contrast, we performed selective puncture through the centre of a posterior calyx using the bullseye technique.

**Results:** Conventional prone positioning for PCNL has several advantages over other patient positions including a wide field for posterior puncture, a wide space for instrument manipulation, easy access to the upper pole and a dependent renal pelvis where mobile stones collect, facilitating removal. A simple prone-flexed modification further flattens the flank, increasing the area available for puncture and decreasing instrument conflict with the buttocks during lower pole access. This modification also results in caudal movement of the kidneys, potentially decreasing the need for supracostal punctures during upper pole access in up to 45% of cases.

**Conclusion:** Prone-flexed positioning is a simple modification that provides improved access to the upper pole and more mobility for lower pole PCNL. This position is well tolerated and has several advantages over conventional prone positioning.

#### **VS5-07 HEMOSTATIC GELATIN MATRIX SANDWICH: AN EFFECTIVE AND MINIMALLY INVASIVE TECHNIQUE TO CONTROL BLEEDING FOLLOWING PERCUTANEOUS NEPHROLITHOTOMY**

G. Lamberton, C. Tenggardjaja, F. Jellison, G. Huang, W. Millard II, D. Baldwin—USA

**Background:** A significant cause of morbidity following percutaneous nephrolithotomy (PCNL) is blood loss from the nephrostomy tract. This bleeding may result in anemia, need for transfusion in 5–18% and may require intervention in 0.8% of patients. Angio-embolization and open exploration place patients at risk for temporary and permanent kidney damage. The purpose of this study is to describe a novel technique for controlling refractory percutaneous tract hemorrhage using gelatin matrix sandwich.

**Methods:** This video demonstrates a novel technique to control percutaneous tract bleeding. This technique employs two balloon catheters used in conjunction with gelatin matrix to form a hemostatic sandwich. A 22 Fr Council-tip catheter is placed into the collecting system, inflated with 2–3 cc of water, and gently pulled back to occlude the inner surface of the nephrostomy tract. This prevents blood or hemostatic gelatin matrix from entering the renal collecting system. The outer surface of the tract is occluded with an additional 16 Fr council-tip catheter placed just below the skin. The hemostatic sandwich is completed by injecting 5 cc of hemostatic gelatin matrix into the tract between the two balloons followed by inflation of the outer balloon to occlude the outer surface of the tract.

**Results:** The hemostatic gelatin matrix sandwich has successfully employed in 4 patients with post-PCNL tract bleeding. In each case the sandwich completely controlled bleeding and there were no complications related to this technique. Only one patient required a transfusion of two units due to intraoperative bleeding and no patient required angio-embolization or open exploration.

**Conclusion:** The use of hemostatic gelatin matrix sandwiched between two balloon catheters successfully controlled refractory post-PCNL tract bleeding avoiding the need for angio-embolization or open exploration. This technique is simple and inexpensive. The success of the hemostatic technique in this series suggests that it should be considered in all patients with refractory tract bleeding following PCNL.

#### **VS5-08 THE USE OF HOLMIUM LASER DURING PERCUTANEOUS NEPHROLITHOTRIPTY**

A. Kural, H. Akpinar, I. Tufek, F. Atug, S. Aksit—Turkey

**Background:** Holmium laser has been rarely used during percutaneous nephrolithotripsy because of difficulty in manipulating the probe through the working channel of rigid nephroscope. In this video we present the usage of continuous flow resectoscope together with laser working element with 300 lens for percutaneous lithotripsy.

**Methods:** The laser fiber is fixed on the working element of 26 F Wolf continuous flow resectoscope which allows movement in every direction. The probe can be directed right on to the stone by using the handle of the working element. The first patient had left staghorn stone. Lower calyx access was preferred and holmium laser lithotripsy (HLN) was performed. Once enough space was obtained, holmium laser was switched to pneumatic lithotripsy. The fragments were removed and a nephrostomy tube was placed. The second patient had a 2.5 cm. single stone in the right renal pelvis who had an unsuccessful SWL treatment before. HLN was performed successfully in this patient, too.

**Results:** In the first patient lower calyceal and pelvic part of the stone was removed. The patient was referred to SWL and a second percutaneous session was performed successfully. There was no mucosal injury and bleeding during both procedures. At the end, both patients were completely stone-free.

**Conclusion:** Holmium laser can be used effectively and safely during percutaneous nephrolithotripsy. The use of continuous flow resectoscope and laser working element in conjunction with 300 lens allows free movement of the holmium laser probe under direct vision continuously during the procedure.

#### **VS5-09 THE TECHNIQUE OF PERCUTANEOUS NEPHROLITHOLAPAXY IN SUPINE POSITION**

V. Bucuras, R. Bardan, C. Jude, C. Comsa, M. Georgiadis—Romania

**Background:** The film presents the steps of percutaneous nephrolitholapaxy in supine position—the Valdivia technique, by using intraoperative video sequences, combining exterior, endoscopic and fluoroscopic aspects. The advantages of this technique are shown, including its feasibility in difficult cases, in obese patients, offering easier access to the collecting system, with a high therapeutic success rate.

**Methods:**

**Results:**

**Conclusion:**

#### **VS5-10 SUPINE PERCUTANEOUS NEPHROLITHOTOMY**

A. Hoznek, S. Esquivel, K. De laet, A. De la taille, L. Salomon, C. Abbou

**Background:** The standard treatment of stones bigger than 2 cm is percutaneous nephrolithotomy. Classically, this intervention requires a first installation in the lithotomy position, to place a ureteral catheter for retrograde pyelography, followed by a second installation in the prone position for the percutaneous surgery. With the upcoming use of flexible instruments, a unique installation in the supine position has recently been proposed.

**Methods:** This didactic film describes this new installation and the way we adapted it in our department. Its advantages and drawbacks are presented.

**Results:** Installation of the patient becomes a one step procedure. Besides the gain in operative time, anesthesiologic risk is diminished because of the absence of prone position. This new approach has also the advantage of offering a simultaneous anterograde and

retrograde access to the urinary track allowing to combine percutaneous nephroscopy and retrograde flexible ureteroscopy.

**Conclusion:** Supine position for percutaneous nephrolithotomy, has several advantages and some limitations. It is likely that this

position will become routine, but the precise indications have to be determined.

## VS6: LAPAROSCOPY—KIDNEY 2

### VS6-01 USE OF A NOVEL HEMOSTATIC AGENT IN LAPAROSCOPIC PARTIAL NEPHRECTOMY

I. Yavascaoglu, F. Gasanov, H. Dogan, H. Vuruskan, B. Oktay—Turkey

**Background:** Several hemostatic agents have been used for different surgical procedures. We describe the use of a novel hemostatic agent (Ankaferd Blood Stopper™ = ABS) in laparoscopic partial nephrectomy. ABS is completely vegetal and shows homostatic effect in a protein network environment through vital physiological erythrocyte aggregation independent of the classic coagulation cascade system and the process takes place in a matter of split seconds.

**Methods:** Laparoscopic partial nephrectomy by using this agent has been performed in 2 patients. Patient 1 had 15 mm lesion in lower pole of the left kidney and patient 2 had 50 mm exophytic lesion in posterior aspect of left kidney. In both patients, following the placement of laparoscopic pedicle clamps, the mass lesions have been excised and parenchymal defects were closed with interrupted hem-o-lok clip aided intracorporeal hemostatic sutures after placing oxidized cellulose within the defect and 2 ml of ABS has been injected and sprayed over the excision line. No significant bleeding has been observed after releasing the pedicle clamps.

**Results:** No intraoperative complication has been experienced. Bleeding was minimal and ABS was shown to be effective in stopping the bleeding. Pathological examination revealed renal cell carcinoma limited to kidney (pT1a, Fuhrmann grade 2) in both patients. Patients had no local recurrences after a 3 months follow-up.

**Conclusion:** Use of ABS for local intraoperative hemostasis has been shown to be safe and effective in laparoscopic partial nephrectomy.

### VS6-02 KNOTLESS INTRAPERITONEAL LEFT LAPAROSCOPIC PARTIAL NEPHRECTOMY

M. Kilciler, L. Tahmaz, S. Bedir, H. Guler, E. Oral, M. Dayanc

**Background:** In a selected group of patients with small exophytic renal tumors laparoscopic partial nephrectomy became an alternative to open partial nephrectomy. A lot of techniques and materials were described for closing calyceal system and renal parenchyma in this laparoscopic method.

**Methods:** 56-year-old female applied to our clinic with left lumbar pain. Radiological interventions showed approximately 3.5 cm in diameter left exophytic solid renal mass. We performed laparoscopic partial nephrectomy. At the operation, while renal parenchyma was closing Hem-o-lok clips were placed to distal and proximal of the suture. No knot was used for parenchymal closing.

**Results:** Operation time and warm ischemia time were 150 and 25 minutes, respectively. Blood loss was 230 cc. Pathology revealed as grade 2 renal cell carcinoma and surgery margins were negative.

**Conclusion:** Hem-o-lok clips using at the parenchyma closing step is a safe and alternative technique during the partial nephrectomy.

### VS6-03 LAPAROSCOPIC PARTIAL NEPHRECTOMY FOR TUMORS NEAR THE RENAL HILUM: A TECHNIQUE FOR PRE-EMPTIVE ANATOMIC DISSECTION AND VASCULAR CONTROL

A. Goh, S. Matin—USA

**Background:** Nephron-sparing surgery has become standard practice in treating small renal lesions. Laparoscopic partial nephrectomy for tumors near the renal hilum can be especially challenging to approach. Vascular injury and prolonged warm ischemia time are significant concerns. Early anatomic dissection and prospective control of perforating vessels emanating from the renal hilum prior to vascular clamping may be used as a technique to minimize warm ischemia time.

**Methods:** We present two cases of laparoscopic partial nephrectomy for tumors near the renal hilum demonstrating this technique. Case 1 is an 80 year-old male with a 3.4 centimeter left renal tumor located inferior to the renal hilum. Case 2 represents a 55 year-old female with a 4 centimeter tumor near the renal hilum with a significant intraparenchymal component.

**Results:** Laparoscopic partial nephrectomy with pre-emptive anatomic dissection was performed successfully in both patients. Warm ischemia time for case 1 and case 2 was 13 minutes and 33 minutes, respectively. There were no intraoperative complications for these two cases. In both cases, blood loss was less than 100 milliliters. Margins of resection were negative for both cases. Compared to pre-operative indexes of glomerular filtration rate (MDRD), renal function was unchanged on post-operative follow-up.

**Conclusion:** Pre-emptive anatomic dissection and vascular control can be accomplished safely and is feasible when approaching tumors near the renal hilum during laparoscopic nephron-sparing surgery. This technique may help to limit time needed for tumor resection and simplify reconstruction during warm ischemia.

### VS6-04 LAPAROSCOPIC PARTIAL NEPHRECTOMY FOR HILAR TUMOUR

F. Porpiglia, C. Fiori, R. Bertolo, M. Manfredi, M. Lucci, R. Scarpa

**Background:** Partial nephrectomy for hilar tumours represents a challenge for urologists both in open and laparoscopic surgery. The

complexity of this procedure is linked to the high proximity of lesion, vessels and excreting system. The aim of this video is to present a case of laparoscopic partial nephrectomy (LPN) for a voluminous hilar tumour.

**Methods:** (Operative technique): Once the anterior area of the emuntor is put aside, elements of the pedicle and ureter are dissected. Gerota capsule around the tumour is removed exposing the margins of tumour. One the renal artery clamped with bull-dog a progressive enucleo-resection is performed. During this step, a perforating artery and a segmental vein contiguous to tumour are sectioned. Once tumour resection completed, we proceed to ligation of the previously sectioned vessels with clips. We then proceed to the reconstruction of the anterior edge of the renal sinus with a double running suture fixed with lapraTy, including the branch of the sectioned vein and carefully avoiding the ureter in the suture. Renal artery is declamped after 25 minutes of warm ischemia. Haemostasis is completed using local application of Flo-seal and Tachosil. At the end of procedure, all elements of the renal sinus appear unaltered

**Results:** Operative time was 120', blood loss was insignificant and no complications were recorded. Pathology evidenced a renal cell carcinoma with a pT1 stage.

**Conclusion:** LPN for the treatment of hilar tumours is feasible and effective but technically complex.

#### VS6-05 LAPAROSCOPIC PARTIAL NEPHRECTOMY WITH PARENCHYMAL HAEMOSTASIS WITH TACHOSIL APPLICATION

R. Sanseverino, O. Intilla, G. Napodano, U. Di mauro, T. Realfonso—Italy

**Background:** Bleeding is one of the most fearful complication of Laparoscopic partial nephrectomy (LPN). We report our preliminary experience of LPN using Tachosil™ sponge as adjuvant haemostatic agent.

**Methods:** The video shows two cases of LPN. In the first case the indication for surgery is a small renal tumour: the renal vessels are carefully dissected and isolated; mannitol is given intravenously before pedicle clamping. The tumour is identified. The renal artery and vein are clamped with a self made tourniquet. The tumour is excised with cold endoshears. The collecting system is repaired with 2-0 Vicryl™ sutures secured with absorbable clips while renal parenchyma repair is performed with 1-0 Vicryl™ sutures secured with Hem-O-lock clips™. The vein and the artery are unclamped. A Tachosil™ sponge is applied on the resected renal surface by dedicated laparoscopic applicator. In the second case we show a transperitoneal laparoscopic heminephrectomy for lower pole dysplasia in a complete renal duplication. The two ureters are identified and isolated; renal vessels are isolated. Two self made tourniquets are placed around renal artery and vein without clamping. Heminephrectomy is performed using Ligasure™ device. The lower pole ureter is clamped and then cut. The renal parenchyma is repaired with running sutures secured with Hem-O-lock clips™. A Tachosil™ sponge is applied on the resected renal surface by dedicated laparoscopic applicator.

**Results:** Tumour size was 32mm. Warm ischemia time was 24 minutes. No postoperative complications occurred.

**Conclusion:** LPN remains a technically challenging procedure. In our experience use of Tachosil™ sponge helped to obtain a complete and adequate haemostasis.

#### VS6-06 LAPAROENDOSCOPIC SINGLE SITE (LESS) PARTIAL NEPHRECTOMY WITH COMPLETE HILAR CONTROL

A. George, M. Atalla, S. Andonian, A. Srinivasan, L. Richstone—USA

**Background:** Laparoscopic partial nephrectomy has been shown to have comparable outcomes to open partial nephrectomy. In an effort to advance minimally invasive techniques and improve patient outcomes, we describe the technique and explore the feasibility of LaparoEndoscopic Single Site (LESS) partial nephrectomy.

**Methods:** A 59 year old lady was diagnosed with a 2.5 cm lower pole left renal mass that had both exophytic and endophytic components with the latter abutting the lower pole collecting system. In a modified right lateral position pneumoperitoneum was established. Through a single periumbilical 3 cm skin incision, three fascial port sites were created. A flexible-tipped laparoscope (LTF-Series, Olympus; Orangeburg, NY) was used to visualize the operative field by staying above the working plane of the instruments. Rigid and flexible instruments (Realhand, Novare; Cupertino, CA) were used for the dissection. Laparoscopic partial nephrectomy technique was duplicated with full hilar control using laparoscopic bulldogs. Specimen extraction was performed by joining two of the fascial incisions and the third was utilized for drain placement.

**Results:** Operative time was 148 minutes. Renal hilar clamp time was 38 minutes. Estimated blood loss was 150 ml. Final pathology was cystic clear cell carcinoma, Fuhrman grade 2 with negative margins. Post operative creatinine was 0.6 mg/dl. There was minimal drain output. The time to recovery of bowel function was 24 hours and hospital stay was 2 days. Patient did not suffer any complications. Thirty day follow up was uneventful.

**Conclusion:** LESS partial nephrectomy is a feasible technique to perform partial nephrectomy by largely duplicating laparoscopic partial nephrectomy techniques and use of flexible instruments and laparoscopes. Prospective studies can determine how outcomes compare with laparoscopic and open partial nephrectomy.

#### VS6-07 A COMPLETE LAPAROSCOPIC NEPHROURETERECTOMY WITH BLADDER CUFF EXCISION

A. Ghazi, R. Zimmermann, A. Schfler, G. Janetschek—Austria

**Background:** The dilemma in dealing with the distal ureter and bladder cuff during nephroureterectomy (NU) for urothelial carcinoma of the upper urinary tract has led to the development of numerous minimal invasive techniques for their management. However they are not without drawbacks; the needed for patient repositioning, complex endoscopic procedures either prior or following nephrectomy & leaving the bladder cuff defect to heal spontaneously are some of them. Our goal is to demonstrate a complete laparoscopic approach for management of urothelial carcinoma of the upper urinary tract without the present drawbacks.

**Methods:** Patient positioning & trocar arrangement are as radical nephrectomy. The addition of a 5 mm trocar in the lower abdomen allows the surgeon to dissect the distal ureter, excise an adequate bladder cuff & suture the bladder defect in a watertight manner without the need for transurethral and intraureteral instrumentation as well as intraoperative repositioning of the patient. Since August 2006 8 cases with urothelial carcinoma were approached using this technique. 5 tumors resided in the renal pelvicalyceal system, 1 in



the ureter & 2 in multiple locations. Tumor stage of the disease were pT1 in 3, pT2 in 1, pT3 in 3 & pT4 in 1 patient.

**Results:** All were successfully treated. The OR time ranged from 110–200 min (mean: 157). The Median time for catheter removal was 7 days; in one patient catheter removal was delayed to 15 days due to bladder extravasation. Average hospital stay was 10.2 days. During a mean follow-up period of 12.1 months, three patients had Ta bladder recurrence and one patient suffered from local recurrence.

**Conclusion:** A complete NU with bladder cuff excision can be accomplished using this approach, with early results comparable to the gold standard of open surgery by the simple addition of a trocar.

#### VS6-08 LAPAROSCOPIC HEMINEPHROURETERECTOMY (HNUT) FOR URETERAL DUPLICATION WITH VAGINAL ECTOPY

U. Anceschi, A. Amici, C. Torcia, L. La vecchia, F. Peris

**Background:** A 21 years-old female patient was admitted to our department complaining an history of recurrent urinary tract infections and continuous urinary incontinence. The diagnostic evaluation by ultrasonography (US) visualized an hydronephrotic upper pole of the right kidney with an abnormal dilatation of the proximal ureter. Further investigations by CT scan and MRI showed an ectopic ureter of the upper pole draining in the vagina. Renal scan evaluation revealed an hypofunctionality of the upper pole of the right kidney.

**Methods:** A transperitoneal laparoscopic right HNUT was performed. The patient was positioned in a modified left flank position with the thorax rotated back slightly at 30° and a break in the table on flexion to optimize exposure of the kidney. Before the procedure a ureteral cateter was inserted endoscopically in the right inferior ureter. The enlarged ectopic ureter and the hydronephrotic upper pole of the right kidney were resected en bloc.

**Results:** The procedure was performed successfully with no conversion to open surgery with a mean operative time of 130 mins. Blood loss was minimal (80 cc) and no intraoperative complications occurred. Despite chronic inflammation in the resected specimen, the patient showed no clinical signs of infection post-operatively and she was discharged in 5 days. The patient was followed using US. Mean follow up at 6 months showed no hydronephrosis and complete remission of the urinary incontinence.

**Conclusion:** Laparoscopic HNUT for complete ureteral duplication is feasible. In experienced hands it has an acceptable operative time compared to open surgery. It is a technically challenging procedure and should be performed only by surgeons with large experience in laparoscopic renal surgery.

#### VS6-09 RETROPERITONEAL LAPAROSCOPIC LEFT RADICAL NEPHRECTOMY INVOLVING RENAL VEIN TUMOR THROMBUS

W. Lv, G. Hao, J. Xiao—China PR

**Background:** Venous involvement is generally considered a relative contraindication to laparoscopic radical nephrectomy. The existence of renal vein tumor thrombus presents a technical challenge in securing hilar control during the resection of a renal mass. We present our single-surgeon experience with laparoscopic nephrectomy in patients with tumor extension into the left renal vein. **Methods:** From April 2009 to May 2009, 3 patients were diagnosed with renal masses with left renal vein thrombus at our institution. The retroperitoneal laparoscopic approach is used with the patients in the lateral position and the usual 4 laparoscopy trocars. This approach involved laparoscopic dissection of the kidney and renal vasculature. After renal artery ligation, the left renal vein is dissected to the level of the vena cava. Venous control was achieved solely by the Hem-o-lok clips where at least two clips were applied on the patient side.

**Results:** The mean age and tumor size were 55.8 years (range 39 to 68) and 6.5 cm (range 5 to 8), respectively. The mean operative time and estimated blood loss were 125 minutes (range 90 to 140) and 110 mL (range 70 to 160), respectively. The mean hospital stay was 7.5 days (range 7 to 9), and no complications occurred. The final stage was T3b with negative margins in all cases.

**Conclusion:** Although it is an advanced procedure, laparoscopic radical nephrectomy in patients with left renal vein thrombus is feasible, safe and follows established oncological principles.

#### VS6-10 LASERVAPORISATION: TREATMENT OF AN AV-MALFORMATION IN THE RENAL PELVIS

A. Saljoughi, M. Kuczyk, S. Waalkes, T. Bach, A. Groos, T. Herrmann

**Background:** We present a case of a 19 years old female patient, suffering from painless macrohematuria of the lower renal calices. An AV-malformation was observed in the lower calices of the left kidney and was treated with laservaporization.

**Methods:** Physical examination didn't reveal a cause. Macrohematuria and no leukocytes were detected in urine analysis. Blood levels of creatinine, urea and electrolytes were within normal limits. The ultrasound of the kidney and the bladder was normal. Former MRT-scan was without a pathology. A bleeding of the left ureter could be observed in a cystoscopic examination. In retrograde ureteropyelogram the ureter and the pelvis of the left kidney were normally configured. Cytology findings collected from the ureter were negative for atypical cells. Flexible ureterorenoscopy was performed in general anaesthesia. An AV-malformation was observed in the lower calices of the left kidney during this procedure. This finding couldn't be verified in an angiography examination.

**Results:** Successful laservaporisation of an av-malformation in the lower calices of the left kidney.

**Conclusion:** An av-malformation was observed in the lower calices of the left kidney and was successfully treated with laservaporisation.

## VS7: NEW TECHNOLOGY

### VS7-01 NATURAL ORIFICE TRANSLUMENAL ENDOSCOPIC SURGERY (NOTES) PARTIAL NEPHRECTOMY IN PORCINE MODEL

B. Lee, U. Boylu, M. Oommen, R. Thomas, V. Joshi—USA

**Background:** This study evaluates the feasibility of NOTES (Natural Orifice Transluminal Endoscopic Surgery) transgastric partial nephrectomy using thulium laser without hilar clamping in the porcine model.

**Methods:** After achievement of general anesthesia, the pig was placed in the supine position. A therapeutic gastroscope was introduced through the esophagus. A 2 cm gastrotomy at the junction of the fundus and the proximal body was performed using electrocautery. The left kidney's upper pole was excised using the thulium laser without hilar dissection or clamping. The specimen was extracted throughout the stomach and esophagus with a wire loop. The gastrotomy was closed with endoscopic metal clips.

**Results:** The NOTES transgastric partial nephrectomy was completed in 240 minutes. Use of the therapeutic double channel gastroscope allowed for scarless natural orifice transgastric endoscopic surgery. The available 3.7 mm and 2.8 mm gastroscope ports were utilized for gastrotomy, excision and removal of the specimen, and endoscopic clip application. With utilization of thulium laser, the procedure was accomplished in a non-ischemic fashion. Estimated blood loss was 200 ml.

**Conclusion:** NOTES partial nephrectomy with thulium laser is feasible. Further studies will provide additional data regarding practical applications of this novel technique.

### VS7-02 NATURAL ORIFICE TRANSLUMENAL ENDOSCOPIC SURGERY (NOTES) ACCESS: TRANSVESICAL, TRANSVAGINAL, TRANSCOLONIC, AND TRANSGASTRIC

G. Haber, J. Talarico, S. Crouzet, K. Litwak, S. Brethauer, J. Kaouk—USA

**Background:** One of the biggest challenges of NOTES is the access technique and the closure of the port of entry. In this video we present the technical requirements and specifications to reproducibly enter and close each access site in the animal model.

**Methods:** Transvesical access was performed at the dome using a flexible cystoendoscope, needle knife cautery and a coronary dilator. For transvaginal procedures, a posterior colpotomy is created and the endoscope is advanced over the SWIFT balloon dilator. Instruments used during access in transcolonic and transgastric cases include an over tube with dilator, dual (160/180) and single channel (T130) endoscopes, needle knife cautery, and balloon dilator. Similar techniques are employed to enter the peritoneum after balloon dilation.

**Results:** Transvesical approach is safe, feasible and reproducible. Complete peritonoscopy is possible through this approach. Specimen extraction is limited to the size of the urethra. Transvaginal access is feasible and reproducible with a theoretical risk of rectal/bowel injury. Transgastric and Transcolonic access are technically challenging with an average time for access greater than 90 minutes. Closure of entry point is necessary and not reliable with current instrumentation.

**Conclusion:** Industry support and physician acceptance are required to continue developing new dedicated NOTES instruments. All four types of access are feasible. From our experience and for urological applications we believe that the transvaginal approach is the route of choice in the female patient. However, the transvesical approach is a safe route, but specimen extraction is limited to the size of the urethra.

### VS7-03 HISTOTRIPSY ABLATION OF THE PROSTATE

J. Wheat, T. Hall, C. Hempel, J. Fowlkes, C. Cain, W. Roberts—United States

**Background:** Histotripsy is a non-invasive ultrasound technology which produces non-thermal, mechanical fractionation of biologic tissues. High intensity ultrasound energy is delivered to a small focal volume causing formation, oscillation and collapse of microbubbles—a process called cavitation. This video demonstrates our technique of histotripsy ablation of the prostate in a chronic canine model.

**Methods:** A total of 18 intact male canine subjects were treated with histotripsy. The subjects were anesthetized and treatment was delivered from an extracorporeal 16-element phased array positioned in a degassed water bath above the subject's abdomen. Treatment was monitored in real time with transrectal diagnostic ultrasound and was deemed adequate when a hypoechoic region was identified within the targeted region. Complete blood count, serum chemistry, and validated veterinary pain scores were obtained before and after treatment. Prostate, bladder and rectum were harvested up to 28 days following treatment, fixed in formalin and stained for histologic analysis.

**Results:** Following histotripsy treatment, there were transient elevations in white blood cell count and liver enzymes which normalized by the time of harvest. Pain scores also normalized within 24 hours of catheter removal. There were no treatment related complications. On harvest ultrasound, a large hypoechoic region was seen within the prostate corresponding to the treated region in all subjects. Four weeks following treatment, the lining of the treated cavity was re-urothelialized.

**Conclusion:** Histotripsy is a safe and effective non-invasive technology for prostate tissue ablation in the canine model. Research to translate this to humans is in progress.

### VS7-04 NOTES TRANSVAGINAL NEPHRECTOMY: INITIAL CLINICAL EXPERIENCE

J. Kaouk, W. White, R. Goel, S. Crouzet, S. Brethauer, G. Haber—USA

**Background:** To present the first clinical experience with Natural Orifice Transluminal Endoscopic Surgery (NOTES) transvaginal nephrectomy.

**Methods:** A prospective, IRB-approved study was performed to evaluate the feasibility and safety of NOTES transvaginal nephrectomy. Operative candidates included females with a non-functioning kidney and a compelling indication for removal. All patients underwent complete history/physical examination, serologic testing, and appropriate imaging studies. Following consent, a 3 cm posterior colpotomy was made to access the peritoneal

cavity. Standard and articulating instruments were employed to perform pelvic adhesiolysis, reflect the colon, and expose the renal hilum. An endovascular stapler was deployed transvaginally to divide the renal hilum. Upper pole attachments were divided using a 65 cm articulating monopolar hook. The kidney was entrapped in a laparoscopic retrieval bag and removed.

**Results:** NOTES transvaginal nephrectomy was successfully completed in 2 patients. Mean patient age was 57.5 years. Mean BMI was 30.57 kg/m<sup>2</sup>. Mean operative time was 405 minutes. Mean EBL was 75 mL. Mean length of hospitalization was 18.5 hours. Mean visual analog pain scale score at discharge was 1/10. No perioperative complications occurred. A 5 mm umbilical port was placed in one patient who had undergone prior pelvic surgery to direct safe vaginal entry. The second case was completed transvaginally without any abdominal instruments or ports.

**Conclusion:** NOTES transvaginal nephrectomy is safe and technically feasible. In patients with prior pelvic surgery, access to the peritoneal cavity should be performed under visual guidance. Future study is needed to better define patient selection criteria and indications for NOTES transvaginal urologic surgery.

#### VS7-05 TRANSVAGINAL HYBRID NOTES NEPHRECTOMY USING A MULTI-CHANNEL PORT

R. Sotelo, O. Carmona, D. Ramirez, D. Canes, Desai, I. Gill—Venezuela

**Background:** Pure NOTES (Natural Orifice Transluminal Endoscopic Surgery) transvaginal radical nephrectomy has been performed only in cadavers and animal models because of technical difficulties in humans. Few cases of hybrid NOTES transvaginal radical nephrectomy (using 2 extraumbilical abdominal ports) have been reported with success in humans. In this video we present a novel technique of hybrid transvaginal NOTES radical nephrectomy using transvaginal trocars (multi-channel in one case, single 12 mm trocar in the other), and a transumbilical multi-channel single port.

**Methods:** Transvaginal radical nephrectomy was performed in two patients with left sided kidney tumors. Triports (Advanced Surgical Concepts, Dublin, Ireland) were inserted in the umbilicus, and the vagina in case 1. For the second case, presence of the uterus allowed space for a transvaginal conventional 12 mm trocar only. Visualization was performed interchangeably from umbilical and transvaginal views using the 5 mm flexible-tip endoeye camera (Olympus, Tokyo, Japan). Dissection, using straight or bent instruments, was performed predominantly transvaginally with the exception of hilar dissection and control. Specimen extraction was accomplished by the vagina access by an extended colpotomy.

**Results:** Mean operative time was 157.5 minutes (range 220 to 95 minutes) and mean estimated blood loss was 125 cc. The patients had an uneventful postoperative course and were discharged 2 days after the procedure. The first case was complicated by abscess in the renal fossa requiring percutaneous drainage. Pathology revealed clear cell carcinoma of 6.5 cm in with no local infiltration in one patient, and chromophobe in the other.

**Conclusion:** Pure NOTES transvaginal nephrectomy is still technically demanding because of the absence of adequate instruments and surgical expertise in performing a safe and effective dissection. However our hybrid transvaginal technique assisted by a umbilical single port is an appealing alternative to further reduce morbidity, obtain a virtually scarless outcome, and safely develop increasingly complex transvaginal dissection techniques.

#### VS7-06 ISOBARIC LAPAROSCOPIC RADICAL CYSTECTOMY IN WOMEN WITH THE “LAPARO-TENSER” ABDOMINAL WALL LIFTING SYSTEM

A. Granata, F. Pietrantonio, G. Incarbone, A. Gregori, A. Romanò, F. Gaboardi—Italy

**Background:** Laparoscopic radical cystectomy (LRC) is a therapeutic option for the treatment of muscle-invasive bladder cancer even though in literature are described possible complications due to the use of pneumoperitoneum, such as increased risk of cardiopulmonary, immunological, endocrine and metabolic complications. Moreover, oncological safety of the procedure is still under investigation and some studies postulate a role of pneumoperitoneum in micrometastasis implant. In order to avoid possible side effects due to pneumoperitoneum we planned a feasibility study on LRC without the use of pneumoperitoneum (isobaric). We used a mechanical system that lifts the abdominal wall (Laparo-Tenser<sup>TM</sup>, Lucini Surgical Concept, Milan, Italy). To our knowledge this system has never been used for LRC in women.

**Methods:** This video shows the surgical technique of LRC in women without the use of pneumoperitoneum, using the Laparo-Tenser system. This consists in two parallel knees placed subcutaneously in the abdominal wall, lifted by a mechanical arm, creating an operative space in the abdominal cavity. Between February 2008 and March 2009 we performed 4 isobaric LRCs in women. The urinary diversion was an orthotopic neobladder in one case after a LRC with uterus preservation and ileal conduit in 3 cases after LRC with anterior pelvic exenteration.

**Results:** The isobaric LRC was successfully performed in all four cases in a mean operative time of 275 min (425 min. with the urinary diversion). Mean blood loss was 300 ml. These data compare favourably with those of traditional LRC with pneumoperitoneum. Actually number of patients and the follow up are too low to discuss the oncologic results.

**Conclusion:** The isobaric LRC is feasible but difficult, and represents a very interesting technological improvement for its oncological and anesthesiological advantages. The laparotenser is a reliable and a secure system that earn to be valued in a larger number of patients with a longer follow up. Actually we consider the abdominal wall lifting without or with low pneumoperitoneum inflow as our standard option for the selected patients that can be candidated to LRC.

#### VS7-07 VIDEO PRESENTATION: STEREOTACTIC PERCUTANEOUS CRYOABLATION FOR RENAL TUMORS

G. Haber, S. Crouzet, E. Remer, K. Kamoi, W. White, J. Kaouk—USA

**Background:** Precise cryoprobe placement is essential for successful ablation. CT-Nav<sup>®</sup> (Koelis, France) is a novel stereotactic surgical navigation system that has the potential to achieve precise percutaneous cryoprobe placement while reducing radiation exposure compared to conventional CT-guided procedures.

**Methods:** A prospective pilot study was performed to evaluate the technical feasibility, safety, and accuracy of the CT-Nav<sup>®</sup> system during renal cryoablation. Patients with enhancing renal masses amenable to renal cryoablation underwent preoperative CT scan with a pre-placed tracking sensor taped to the body of the patient. Using a stereoscopic infrared camera, the tracking sensor is located three-dimensionally and a tracking handle used to guide the cryoprobe percutaneously based on the preoperative preloaded

CT-scan. Demographic and perioperative data were obtained prospectively into an IRB approved database. Immediately following cryoprobe placement, a CT-scan is repeated to confirm cryoprobe placement accuracy.

**Results:** A total of 13 tumors in 10 patients successfully underwent cryoablation using the novel navigational system. Mean tumor size was 2.2 cm. Preoperative biopsy demonstrated renal cell carcinoma in 9 cases. Mean operative time was 155 min. No intraoperative or postoperative complications were noted. Mean length of stay was 9.5 hrs. A mean decrease in CT fluoroscopy duration of 18.3 sec was noted for each cryoprobe placed. Mean targeting registration error was 4.2 mm.

**Conclusion:** Stereotactic percutaneous cryoablation of renal tumors offers the potential for safe and precise needle placement while reducing radiation exposure compared to traditional CT-guided probe placement.

### VS7-08 UPPER URINARY TRACT ENDOUROLOGICAL TRAINING ON EX-VIVO PORCINE MODEL

A. Celia, G. Zeccolini, G. Breda

**Background:** Simulators have gained wide acceptance as an important tool in the surgeon's learning process. Some types of simulators are currently available: plastic models, virtual digital models and animal models. Italian law forbids the use of living animals. Ex vivo-models are the closest ones to reality and therefore the most useful ones in the training of surgeons, to cover the gap between theoretical learning and real practice. We introduced porcine models in upper urinary tract endourological training, in order to improve learning curve of unskilled urologists.

**Methods:** The video shows the steps to create "ex-vivo model" by porcine urinary tract for endourological training: Ex-vivo porcine upper urinary tract is really close to human urinary tract and, therefore, is better than plastic models. It is also cheap to build and easy to use.

**Results:** All the instruments required for diagnostic or operative endourological procedure, including disposable instruments, may be trained on such a model. The video shows standard endourological procedures on the model. Rigid and flexible cystoscopy Retrograde Ureteropyelography Introducing guide wire up to the kidney The use of ureteral access sheath Rigid and flexible ureterorenoscopy, explaining tricks to overcome stenosis or ureteral kinkings Operative procedures on caliceal, ureteral or bladder stones by baskets, ballistic lithotripsy or laser Percutaneous lithotripsy of a stone.

**Conclusion:** In conclusion, the video aims to offer to the training urologist the possibility to learn the steps of endourological procedures and to build by himself an easy ex-vivo porcine model to train on endourological techniques. Such a training will improve learning curve and will improve results during endourological procedures on human patients.

### VS7-09 A NOVEL URETERIC STENT FOR TUBELESS PCNL: AN INITIAL CLINICAL EXPERIENCE

H. Shah, S. Kharodawala, H. Sodha, V. Kumar, A. Khandkar, M. Bansal

**Background:** To report our initial experience with a novel double pigtail ureteric stent after tubeless PCNL.

**Methods:** From September 2007 to February 2008, 32 patients underwent tubeless PCNL with placement of double pigtail ureteric stent with 3 Fr lumenless vesical end and a tether attached to renal end. Antegrade stent placement was done under fluoroscopic guidance by intussuscepting the 3 Fr lumenless vesical end of the stent into perurethrally placed 7 Fr ureteric catheter. The stent tether existed from the flank wound and was used for stent removal. Stent morbidity was assessed by validated ureteral stent symptoms questionnaire. The data (study group) was compared with similar number of patients who underwent tubeless PCNL with placement of normal double pigtail ureteric stent (control group).

**Results:** Patient's demographics and perioperative data were comparable. The mean urinary symptom index score was 14.6 in study group and in 28.6 control group. Stent-related pain was higher in control group (64.28% vs. 35.71%). The mean pain index score was 9.4 in study group and 18.8 in control group. The mean general health index score and global quality of life score were statistically greater in control group compared with study group (13.1 vs. 8.3 and 5.5 vs. 3.4). Office stent removal was uneventful in 29 patients. Three patients who came after 1 week needed cystoscopy for stent removal.

**Conclusion:** Our novel ureteric stent decreases stent related morbidity and obviated the need for cystoscopy after tubeless PCNL.

### VS7-10 COMPUTER ASSISTED LAPAROSCOPIC SIMULATOR (UROBOX) WITH SELF ADJUSTABLE TRAINING PROGRAM DEPENDING ON TRAINEE'S PROGRESSION ON THE LEARNING CURVE—PRELIMINARY RESULTS

B. Petrut, F. Nechita, B. Tintila, A. Man, A. Muresan, I. Coman

**Background:** Our aim was to develop a fully functional laparoscopic mechanical simulator that can assess objectively the progression of each trainee on the learning curve and redesign the training session according to the trainee's skills.

**Methods:** The simulator is connected to a computer that runs the software that monitors and scores the exercises needed for progression in the laparoscopic technique. The same software adjusts the fore coming training sessions based on the actual skills of the trainee. 10 medical students without prior experience in laparoscopy performed on "Urobox" trainer a 20 reiterations of a specific task of following two-dimensional tracks of different difficulty level. Accuracy, time and depth perception were assessed by the computer and were included in a scoring system with 2 components: one for accuracy and one for speed.

**Results:** An improvement of the overall score, from first to the 20th reiteration, was achieved correlated with the learning curve. The average score of the group was set to be the inferior limit above which the future trainee's will have to perform each exercise in order for the computer to advance him to the next level of training.

**Conclusion:** We constructed a computerized laparoscopic simulator with an objective self adjustable monitoring program depending on the native skills of the trainee. The scoring system we designed is a valid tool for assessment of progression on the learning curve. The UROBOX simulator provides us with a quantified objective score that can state the accuracy of each exercise.

## VS8: LAPAROSCOPY—PROSTATE

### VS8-01 LAPAROSCOPIC RADICAL PROSTATECTOMY USING LOW ENERGY SOURCE GIVING EARLY CONTINENCE AND BETTER POTENCY: INITIAL EXPERIENCE OF 52 CASES S. Shah

**Background:** We present our initial experience of laparoscopic radical prostatectomy with classical transperitoneal technique. We also compared the results of surgery in Group I (16 cases) done in initial part of our series between november 2003 and March 2007 using the routine technique with Group II (31 Cases) done in latter half of our experience between April 2007 and November 2008 using low energy source.

**Methods:** From November 2003 to November 2008 a total of 47 cases of radical prostatectomy were operated by laparoscopic technique of these the initial 16 patients were operated with the routine technique and 31 patients operated in the later part (Group II) were operated using minimal energy source. Both groups were largely similar with respect to mean patient age, Gleason score, general comorbid conditions and T stage.

**Results:** Mean operative time for Group I (Routine LRP) was 231 min and for Group II (LRP with Low energy usage) was 228 min. Continence was evaluated at 1, 3, 6 and 12 months. 11 of 16 patients in Group I were continent as compared to 23 of 28 patients in Group II. In Group I only 8 patients of the 16 were potent preoperatively and 4 of them remained potent 3 month after LRP. In Group II 20 patients of 31 were potent preoperatively and 11 remained potent 3 months after LRP, the last five cases the potency status at three months is awaited.

**Conclusion:** The use of low energy source at bladder neck and neurovascular bundle, sparing of seminal vesicle and preservation of healthy urethra during dissection is associated with better continence and potency is encouraging. Nevertheless, longer follow-up and more mature data are needed definitively to establish the fact.

### VS8-02 LAPAROSCOPIC RADICAL PROSTATECTOMY (LRP) PERFORMED BY MINIMUM EFFECTIVE TREATMENT (MET)

G. Franco, S. Antonio, R. Ai Ling, G. Antonio Maria, G. Andrea—Italy

**Background:** Recently Kaouk et al. reported their experience in LESS radical prostatectomy (Urology 2008 Dec;72(6):1190–1193). They used a single port with three operative channels and dedicated flexible instruments. The vesico-urethral anastomosis was made by interrupted stitches tied in extracorporeal fashion. The technique was considered feasible, although 2/4 patients had positive surgical margins and 1/4 had a rectum urethral fistula. Having the opportunity of a flexible camera and a Triport<sup>®</sup> system we tested the feasibility of a modified LESS technique, using an additional 5 mm trocar as Minimum Effective Treatment.

**Methods:** Aim of the technique was to reduce the invasiveness of the common 5 ports LRP, keeping a low risk about oncological and functional results. The idea of a 5 mm trocar placed in left iliac fossa allowed us to obtain a good working angle for instruments, during the critical steps of surgery. The video shows “step by step”

a transperitoneal nerve sparing LRP with iliac-obturator lymphadenectomy performed just by two operative sites.

**Results:** The surgical procedure showed in this video was performed without complications in 195 minutes (the anastomosis in 25 minutes), with an intra-operative blood loss of 150 cc. The drainage was pulled out during the second day after surgery. The patient was discharged 3 days and the catheter removed 7 days after the operation. The pathologic examination confirmed the presence of a Gleason 7 (3+4) adenocarcinoma with negative surgical.

**Conclusion:** LRP performed by 2 operative trocars is a difficult procedure, above all for the movement limitations of instruments, although flexible. The 5 mm operative trocar, during critical steps, permits a good working angle and anyway that incision is often necessary for the drainage placement. Until now we performed two procedures with this technique with comparable results and both with negative margins, so we are going to conduct a feasibility study with more patients. Actually we consider only patients with clinical localized stage and low body mass index. We believe that this technique is an improvement to reduce the surgical invasiveness. We need to confirm if the oncological and functional results are comparable to the traditional approach.

### VS8-03 HAEMOSTASIS DURING NERVE-SPARING ENDOSCOPIC EXTRAPERITONEAL RADICAL PROSTATECTOMY (EERPE)

J. Stolzenburg, M. Do, P. Kallidonis, G. Hellawell, T. Haefner, E. Liatsikos

**Background:** Postoperative bleeding complications have been encountered in 0.7% of EERPE cases and require endoscopic or open re-intervention. Thus, bleeding complications represent a significant factor of intra- and post-operative morbidity. The requirement to avoid the use of cautery during the nerve-sparing EERPE (nsEERPE) represents an additional risk factor for bleeding.

**Methods:** We review our experience with nsEERPE regarding the methods to efficiently prevent and manage intra- and post-operative bleeding complications. Haemostatic techniques for energy free nsEERPE are also extensively presented.

**Results:** Cases of bleeding from the epigastric vessels and prostatic pedicles can be controlled by clips and sutures. Bleeding from the Santorini's plexus could be avoided by suturing or stapling of the plexus before dissection. Uncontrolled haemorrhage of the Santorini's plexus and urethral stump could be controlled by inflation of the catheter balloon and retraction of the catheter for several minutes. Any neurovascular bleeding should be addressed by the use of haemostatics and/or suturing while avoiding the use of cautery.

**Conclusion:** Bleeding events during nsEERPE are commonly encountered and in the majority of the cases are easily controllable. In the case of uncontrolled bleeding, several methods could be used to manage the problem. The surgeon should be confident but also careful and especially to be familiar with all appropriate techniques to control the haemorrhage without compromising the outcome of the procedure.

#### VS8-04 NATURAL ORIFICE TRANSLUMENAL ENDOSCOPIC SURGICAL RADICAL PROSTATECTOMY (NOTES-RP) IN THE CANINE MODEL

A. Krambeck, M. Humphreys, P. Andrews, J. Lingeman—USA

**Background:** The goal of this study is to demonstrate the feasibility of transurethral radical prostatectomy (NOTES-RP) in the canine model.

**Methods:** NOTES-RP was performed on 6 non-survival male canines. The 100 Watt holmium:YAG laser, 550  $\mu$ m end-firing fiber, 28 Fr laser resectoscope, 7 Fr stabilizing catheter, and continuous irrigation were used to radically resect the prostate. A vest vesicourethral anastomosis was performed utilizing a laparoscopic suture device delivered through the nephroscope. In the initial cases the prostate was removed manually; for the last 2 cases the prostate was removed endoscopically with a tissue morcellator.

**Results:** NOTES-RP was successfully executed in all canines. Visualization was not obscured by bleeding. Dissection times ranged from 40 to 120 minutes. Fluid absorption was problematic in cases over 1 hour, due to the intraperitoneal location of the canine prostate and bladder.

**Conclusion:** The feasibility and technique of NOTES-RP was successfully demonstrated in the living canine model.

#### VS8-05 NERVE-SPARING LAPAROENDOSCOPIC SINGLE SITE (LESS) RADICAL PROSTATECTOMY

M. Atalla, S. Andonian, L. Kavoussi, L. Richstone

**Background:** As laparoscopy becomes a standard approach in many urologic procedures, research strives to make minimally invasive surgery less invasive. Our objective was to apply recent innovations in equipment and surgical approaches to develop the technique and perform Nerve-Sparing LaparoEndoscopic Single Site (LESS) Radical Prostatectomy. To our knowledge this is the first true Nerve-Sparing LESS Radical Prostatectomy.

**Methods:** A 49 year-old gentleman presented cT1c prostate cancer. Prostate biopsy revealed Gleason 3 + 4 adenocarcinoma. The patient elected radical prostatectomy. The patient was positioned in a low lithotomy position with the arms tucked. A single 3 cm transverse infraumbilical incision was made. Pneumoinflation was obtained using a Veress needle. A flexible-tip laparoscope (LTF Series, Olympus Surgical; Orangeburg, NY) Two 5 mm Anchorports (Surgique; Orange, CT) and one 12 mm trocar were placed through separate fascial punctures in the single infraumbilical incision site. Flexible instruments (Realhand, Novare; Cupertino, CA) were used in addition to standard laparoscopic instruments. Laparoscopic prostatectomy technique was replicated via a single operative site.

**Results:** Operative time was 424 minutes. Hospital stay was 10 days because of a vesicourethral leak and ileus. The anastomotic leak resolved and the foley catheter was removed four weeks postoperatively. Final pathology revealed negative margins and Gleason 3 + 4 pT2c adenocarcinoma. The patient was continent and potent at three months postoperatively.

**Conclusion:** Nerve-sparing LESS Radical Prostatectomy is feasible by replicating laparoscopic prostatectomy techniques with the advent of flexible-tip laparoscopes and flexible instruments. After a learning curve has been overcome, this should be further tested to compare oncologic and functional outcomes with laparoscopic prostatectomy in a prospective fashion.

#### VS8-06 SEEING THE LIGHT-ENDOSCOPIC-ASSISTED LAPAROSCOPIC RADICAL PROSTATECTOMY—A NOVEL TECHNIQUE TO AID IN BLADDER NECK AND APICAL DISSECTION?

M. Preston, J. Wiesenthal, A. Abuhajar, D. Hickling, J. Watterson, B. Blew—Canada

**Background:** Bladder neck and apical dissection planes can be difficult to identify, with competing goals of achieving negative surgical margins while maintaining neurovascular bundles and continence mechanisms. We theorized that endoscopic visualization of the verumontanum, urethral sphincter and the bladder neck during laparoscopic or robotic radical prostatectomy may facilitate identification of ideal tissue dissection planes to optimize oncologic and functional outcomes.

**Methods:** Laparoscopic radical prostatectomy was performed using an antegrade, intraperitoneal technique. Using concomitant laparoscopic and cystoscopic visualization and video-recording capabilities, we performed bladder neck and urethral dissection after intermittently positioning the cystoscope at the bladder neck and just distal to the verumontanum. During dissection, the laparoscopic light source was dimmed such that the cystoscopic light was well visualized and used to help demarcate dissection margins.

**Results:** With the laparoscopic light dimmed, identification of the prostatovesical junction was aided by movement of the cystoscope across the bladder neck, resulting in transillumination of the bladder but not the prostate. Similarly the location of the urethral sphincter, verumontanum and prostatic apex relative to the apical dissection was aided by cystoscopic visualization and transillumination of the membranous urethra. This has the potential to aid in difficult cases such as those with prior urethral procedures (TURPs), poor visualization, median lobes or aberrant apical anatomy.

**Conclusion:** This video demonstrates a novel approach to aid dissection of the bladder neck and apex during laparoscopic radical prostatectomy, which may aid in improving surgical margin rates and post-operative continence.

#### VS8-07 RANDOMIZED STUDY AND SURGICAL TECHNIQUE ON ISOBARIC LAPAROSCOPIC RADICAL PROSTATECTOMY WITH THE “LAPARO-TENSER” SYSTEM

A. Granata, F. Scieri, A. Salvaggio, G. Incarbone, F. Pietrantuono, F. Gaboardi—Italy

**Background:** Laparoscopy with pneumoperitoneum may cause several pathophysiologic changes, such reduction of pulmonary function, visceral vasoconstriction, increased dead space, ventilation-perfusion mismatch, increase of total peripheral resistance, increased pulmonary wedge pressure, effects on cardiac output and rise in PaCO<sub>2</sub>. The video shows step by step an isobaric (gasless) transperitoneal laparoscopic radical prostatectomy (iLRP) with the LaparoTenser system (Lucini Surgical Concept, Milan, Italy). We evaluated with a prospective, randomized study comparing the intraoperative effects on central haemodynamics, intraoperative and postoperative respiratory functions and surgical outcomes of iLRP versus traditional pneumoperitoneum (13 mmHg) radical prostatectomy (LRP), in patients with prostate cancer.

**Methods:** Subcutaneous lifting of the anterior abdominal wall is obtained by using the LaparoTenser device. This is composed by two curved “pluriplan” needles with blunt tips that are introduced subcutaneously through 2 pubic skin incision and suspended from a mechanical arm attached to a rigid pillar. The arm is elevated as far

as necessary to obtain optimal exposure of the peritoneal cavity. A 12 mm paraumbilical trocar is inserted with the Hasson's technique. Four additional trocars are placed under direct vision in a V-shape manner. The Retzius's space is developed after incision of umbilical arteries and urachus close to the umbilicus. Endopelvic fascia and pubo-prostatic ligaments are bilaterally incised with prostate apex exposure. The bladder neck is prepared and incised. Denonvilliers' fascia and vasa deferentia are incised and seminal vesicles are isolated. Neurovascular bundles are incised with the harmonic scalpel. After ligation of the Santorini's venous plexus the urethra is incised and prostatectomy is completed. After bilateral pelvic lymph node dissection the posterior reconstruction of the rhabdomyosphincter and the vesico-urethral anastomosis are performed with interrupted sutures.

**Results:** Between October 2007 and February 2008 18 patients were operated on. Eight patients received the isobaric (gasless) transperitoneal laparoscopic radical prostatectomy with the LaparoTensor TM system. Operative times (mean 183 min, range 160–200 in group 1 and 187.5 min, range 150–220 in group 2) and blood losses (mean 166 cc, range 100–300 in group 1 and mean 180 cc, range 100–320 in group 2) were comparable in the 2 groups of patients. Suction of blood and smoke produced by electrocautery and harmonic scalpel may be performed without loss of surgical space, differently if pneumoperitoneum is present. Operative times and blood losses do not appear increased with the absence of pneumoperitoneum. Data of the study show a better trend of haemodynamics and respiratory parameters, with low statistical significance. Oncological surgical outcomes are still not mature to draw any conclusions on the potential benefits of gasless technique.

**Conclusion:** The isobaric (gasless) transperitoneal laparoscopic radical prostatectomy is feasible following all the surgical steps of laparoscopic radical prostatectomy with pneumoperitoneum. The prospective, randomized trial conducted at our Institution show some advantages of the gasless technique in pulmonary and cardiac function. Moreover, mechanical anterior abdominal wall traction reduces the risk of visceral lesions during trocar positioning, and during the procedure it is possible the suction of smokes without losing the surgical space and with reduction of contacts between the laparoscope and tissues, minimizing the need of clearing the

optic. Thus, the iLRP procedure could be reserved to patients with haemodynamic or pulmonary dysfunctions or for the initial procedures, for the technical advantages mentioned and for the absence of ipercapnia effects in prolonged procedures. Actually we don't use the isobaric technique as a standard option but it was a good training to perform isobaric laparoscopic radical cystectomies, where the oncological risks of pneumoperitoneum are in our opinion much consistent.

### VS8-08 BLADDER NECK CONTRACTURES RELATED TO THE USE OF HEM-O-LOK CLIPS IN LAPAROSCOPIC RADICAL PROSTATECTOMY

C. Gurbuz, S. Gungor, B. Guner, T. Caskurlu

**Background:** Bladder neck contracture (BNC) after laparoscopic radical prostatectomy (LRP) has been reported to occur in 0% to 3%. The use of Hem-o-Lok clips is well described for control of the lateral pedicles in laparoscopic prostatectomy. There are limited number of report in the literature relationship to the use of Hem-o-lok Clips (HOLC) and BNC. We report one case of urethral erosion of Hem-o-Lok clips after laparoscopic prostatectomy in patient who presented with symptoms of voiding difficulty.

**Methods:** Sixty four year old gentleman who had undergone a laparoscopic radical prostatectomy and returned 13 months later for follow-up investigations due to intractable urinary symptoms. A urethrogram revealed a tight bladder neck. The patient was listed for a rigid cystoscopy and bladder neck dilatation under general anesthesia. During the urethrocystoscopic procedure, four HOLC (R) (Weck Surgical Instruments, Teleflex Medical, Durham, NC) were found in the urethrovesical anastomosis, and was successfully removed by transurethral resection loop.

**Results:** Catheterisation time was 2 days. Patient eventually discharged on postoperative second day. In his 3 months follow, he has no urinary symptoms and denies to leak with physical activities. Uroflowmetry showed good urine flow.

**Conclusion:** When BNC or unexplained urinary symptoms occurs after LRP, one should have a high index of suspicion for migration of HOLC to urethrovesical anastomosis site. Successfully removal of HOLC was achieved with the aid of a transurethral resection loop.

## VS9: RETROPERITONEOSCOPY

### VS9-01 EXPERIMENTAL HYBRID TRANSVAGINAL RETROPERITONEOSCOPIC NEPHRECTOMY

M. Hisano, F. Hondo, J. Giordano-nappi, R. Duarte, P. Sakai, M. Srougi—Brazil

**Background:** Nephrectomy is a major urologic procedure that can be done by open or laparoscopic means. Recently, there has been increasing enthusiasm in NOTES because of its minimally invasive attraction. Retroperitoneal access to kidney offers ready access to hilum and avoids peritoneal entrance and its complications. We describe the feasibility of left transvaginal retroperitoneoscopic nephrectomy (TRN) using hybrid techniques in a porcine model.

**Methods:** Under general anesthesia, a 25 kg female pig was positioned in right-lateral decubitus. With a 30 degree laparoscopic optic at umbilicus, we guided anterior vaginal incision. We introduced a single channel endoscope through colpotomy and started insufflation to create retroperitoneal space. Endoscope achieve left kidney by both endoscopic and laparoscopic view. A lombar trocar was introduced to help dissection. Renal vessels were dissected, isolated and controlled with endoscopic clips. Ureter was dissected, clipped and sectioned. Kidney was dissected and we performed vaginal specimen extraction.

**Results:** The procedure was performed in 90 minutes; space creation took 15 minutes, retroperitoneum navigation 30 minutes, vascular control 30 minutes, kidney dissection 15 minutes. We had

no major complications, such as vascular or visceral injuries. Blood loss was minimal. At the end of procedure, the animal was sacrificed.

**Conclusion:** Hybrid TRN is feasible and simultaneous intraperitoneal view immensely helped the procedure. This can be a first step to pure TRN. Some critical points to develop are: vaginal landmarks to correctly access retroperitoneal space; pelvic retroperitoneal orientation; and iliac vessels passage. TRN has the benefits of no scar surgery, the potential use for all kidney procedures and can be useful for adrenal and pancreatic procedures.

### VS9-02 TIPS AND TRICKS OF RETROPERITONOSCOPIC URETEROLITHOTOMY: SHOULD BE DONE FOR IMPACT URETER STONES:VIDEO

E. Huri, T. Akgül, T. Karakan, C. Germiyanoglu—Turkey

**Background:** EAU/AUA Guidelines were restricted indication of laparoscopic ureterolithotomy for impact ureter stones. Video has been designed to stress importance of surgery focus on tips and tricks.

**Methods:** Forty-six years old man patient was evaluated with compliance related left loin pain. Intravenous urography confirmed left mid-ureteral stone, 2.5 cm, and late functioned kidney.

**Results:** Retroperitoneoscopic ureterolithotomy protect the patient from the long flank incision with preserve iliohypogastric and subcostal nerve, provide short hospitalization period and less pain. Following the placing three ports (5–10–10 mm), first aim exploring the ureter with guidance of psoas muscle and genitofemoral nerve lying on psoas. Opening the Gerota fascia than periureteral inflammation detected around stone area. Tricky point of awareness of stone is palpation with tip of endograsper or j-hook. Shake ureter on stone, rigid manœura of ureter seen at time. Incision of ureter done with cold-scissor. Bleeding on ureteral serosa could be cauterized with biopolar carefully. Retrieval of stone is not too easy to deal with. Generally, adhesion to ureteral mucosa should be dissected with blunt dissector. Stone should be extracted compactly; control of upper and lower part of ureter should be done with feeding tube. Suturing in narrow area could be performed with 4/0 polyglycolic acid. Restricted factor during operation is fibrosis and periureteral inflammation due to impact stone, no clear anatomy.

**Conclusion:** Retroperitoneoscopic ureterolithotomy is fully replication of open procedure with minimal co-morbid fashion. Tips and tricks of operation should be guideline to surgeons to act this technically difficult session due to increased inflammation.

### VS9-03 SINGLE PORT LAPAROSCOPIC RETROPERITONEAL RADICAL NEPHRECTOMY

Y. Ozgok, S. Basal, S. Bedir, M. Hoşcan, A. Gur, A. Avci

**Background:** We present the initial clinical experience with single port laparoscopic radical nephrectomy.

**Methods:** An 44-year-old man presented with a solid mass in the lower pole of right kidney. The patient elected to undergo a laparoscopic radical nephrectomy. A 2-cm incision was made and single port was inserted into the incision. Three trocars (12 mm, 10 mm, and 5 mm) were placed through the access port. The kidney was mobilized in the standard fashion. Controlling the renal artery with nonabsorbable polymer clips and the renal vein with a stapling device, the specimen was removed intact. Hemostasis was confirmed, single port was removed, and the incision was closed.

**Results:** The procedure was completed in 130 minutes without complications. Blood loss was estimated to be 300 mL. Postoperatively, the patient was treated with intermittent intravenous and oral analgesics. He was discharged on postoperative day 2 and tolerated a regular diet.

**Conclusion:** This represents the initial report of a single port laparoscopic radical nephrectomy, with intact specimen extraction. Using standard laparoscopic instrumentation, the procedure was performed safely and effectively, and short hospitalization.

### VS9-04 NOTES TRANSVAGINAL RETROPERITONEOSCOPY—A NEW FLEXIBLE RETROPERITONEAL ACCESS FOR RENAL AND ADRENAL SURGERY—REPORT OF THE FIRST CASE

L. Curcio, R. Zorron, D. Leal, E. Kanaan, I. Cabral—Brazil

**Background:** Surgical progress, as seen in laparoscopic techniques and evolution in interventional radiology and endoscopy, reduced the indications for laparotomy and has been associated with less pain, shorter hospital stays, and fewer complications. The recent concept of Natural Orifice Transluminal Endoscopic Surgery (NOTES) is evolving with the aim of avoiding incision related complications of standard laparoscopic and open surgery. We show a video in a 67-yr-old woman presenting obstructive symptoms for urinary outlet due to a progressive growth of a left kidney cystic mass, then with 9.5 × 8 cm diameter, as measured by computer tomography.

**Methods:** Patient was submitted to general anesthesia, and was positioned in supine position, legs open, initially in a Trendelenburg inclination. Intra-abdominal insufflation with CO<sub>2</sub> was achieved by connecting one of the working channels of the endoscope to a laparoflator. A 2-channel videocolonoscope was introduced and insufflation using CO<sub>2</sub> by a laparoflator connected to one working channel of the endoscope allowed blunt dissection of the retroperitoneal space. After sharp opening of left Gerota's fascia using electrocautery by polipectomy snare, dissection of the inferior pole of the left kidney was performed, with identification and dissection of the renal cyst. At this point, significant leakage of CO<sub>2</sub> to the abdominal cavity was noticed, due to a tear in the peritoneum, and final resection of the cyst was performed with the assistance of 2 laparoscopic graspers inserted in the left flank.

**Results:** There was no significant bleeding during the procedure, estimated to be less than 50 ml. Total operative time was 210 min, and anesthesiology time of 300 min. Colpotomy access time was 8 min, and no fascial closure was needed. Intraoperative abdominal pressure oscilated between 12 and 16 mmHg of CO<sub>2</sub>, and end-tidal expiratory CO<sub>2</sub> ranged from 35–40 mmHg. Postoperative course needed hospital stay observation of 4 days because of study-protocol. Immediately after the procedure, the patient presented facial and cervicofascial emphysema, and due to previous pulmonary function. Postoperative radiology showed a small pneumomediastinum, which disappeared in the next 3 days with conservative management. At 30-days follow up, the patient was asymptomatic, with total regression of the emphysema and good laboratorial routine.

**Conclusion:** This new technique requires further development in the field of instruments, and surgical expertise, before it can be routinely applied to clinical series. NOTES might be a real option to approach the retroperitoneal space. Retroperitoneal natural orifice surgery—NOTES Retroperitoneoscopy—may provide



additional benefits related to postoperative pain, recovery, and cosmetic results in the future

### VS9-05 LAPAROSCOPIC BILATERAL RPLND IN STAGE 2B TESTIS TUMOR

A. Basiri, H. Djaladat, M. Mohammadi Sichani, M. Asl Zare

**Background:** Laparoscopic bilateral RPLND in stage pB testis tumor is a challenging procedure. We have done such a procedure on four cases of which two were postchemotherapy (All were under 28 for BMI).

**Methods:** The presenting case is a 28 years old man with history of left testis teratocarcinoma, stage IIB. Chemotherapy was done without significant change in retroperitoneal tumor size (mainly in left para-aortic area). Laparoscopic bilateral RPLND was performed. Left semi-flank position was chosen with three midline trocars and two pararectal ones. Mobilizing the colon from left white line to right ureter, we did a classic bilateral retroperitoneal lymphadenectomy and tumorectomy using split and roll technique through left para-aortic, right paracaval, precaval, interaortocaval and preaortic area preserving inferior mesenteric artery. Spermatic vessels were removed from orchiectomy ligature to renal vein.

**Results:** The procedure was done uneventfully without any peri-operative complication. The demanding part was right paracaval lymphadenectomy which was accomplished with the help of a bowel retractor. Repositioning and right side trocar placement was not necessary. Surgical pathology showed that 1/6 nodes in paracaval, 9/16 nodes in interaortocaval and 3/15 nodes in para-aortic area were involved with mature teratoma.

**Conclusion:** To our best knowledge this is the first report of laparoscopic bilateral RPLND in stage pB testis tumor. Up to now, in stage pB testis tumor, laparoscopic modified RPLND plus chemotherapy was a treatment option. This experience showed that laparoscopic bilateral RPLND in stage p can be done efficiently and safely without need to repositioning and contralateral trocar placement.

### VS9-06 SINGLE TROCAR SURGERY—PRELIMINARY RETROPERITONEOSCOPIC EXPERIENCE

G. Pini, S. Micali, M. Sighinolfi, M. Rivalta, S. De stefani, G. Bianchi

**Background:** Recent papers have been shown feasibility of Laparo Endoscopic Single-Site Surgery (LESS). We present a new LESS technique: a single port with help of operative laparoscope.

**Methods:** A 70 years old mononephric man have been shown nephrosic proteinuria for 12 months. He underwent retroperitoneal renal biopsy and peripheral cyst ablation. Surgical technique: Retroperitoneal access (Visiport<sup>®</sup>) and kidney exposition. Introduction of 10-mm operative laparoscope, equipped by a 5-mm operative channel (Karl Storz GmbH & Co. Kg, Tuttlinge, Germany). Visualization and resection of the cyst wall and bipolar edge coagulation. Triple parenchyma biopsy with toothed grasper (5-mm). Cyst bed coagulation (Argon beam) and application of oxide cellulose (Tabotamp<sup>®</sup>). Drainage.

**Results:** Operative time 20 minutes. Intraoperative bleeding <25 ml. Removals of bladder catheter, drainage, discharge in 1st post operative day; come back to usual activities after 5 days. The patient referred nopostoperative pain, quicker convalescence and better cosmetic result. Histological diagnosis: minimal lesion glomerulonephritis.

**Conclusion:** LESS, introduced by gynaecologists 40 years ago, has been recently refashioned by urologist as a minimal invasive alternative to traditional laparoscopy. Many urological indications (ablative and reconstructive) have been described, anyway limited to few clinical cases. From our experience LESS is feasible, safe and effective. Comparing this case with traditional retroperitoneoscopy the patient seems to have lesser pain, shorter convalescence and better cosmetic results. Prospective and randomized studies are necessary. Finally, LESS it's an evolution of laparoscopy and obliges urologist to work in a narrow space: does retroperitoneum could be its ideal environment?

### VS9-07 RETROPERITONEOSCOPIC HYBRID-LESS URETEROLITHOTOMY

G. Pini, S. Micali, M. Sighinolfi, F. Cianci, F. Annino, G. Bianchi

**Background:** Laparo-endoscopic Single-Site Surgery (LESS) obliges urologist to work in a narrow space. Retroperitoneum could be the ideal environment. The video shows advantages and inconveniences of retroperitoneoscopic LESS ureterolithotomy.

**Methods:** A 38 years old man, presenting uroepisis for a left radiopaque ureteral (L3-L4) stone (2×1 cm), underwent to JJ ureteral stent in urgency. 3 months later we performed a retroperitoneal LESS ureterolithotomy. Surgical technique: retroperitoneal access (Visiport<sup>®</sup>). Introduction of multichannel TripPort (ASC, Wickled, Ireland) and flexible videolaparoscope (HD EndoEYE LFT-VH, Olympus). Gerota incision and ureter exposition. Identification of stone with fluoroscopy. Ureterotomy and extraction of stone. An auxillary 2 mm grasper (anterior axillary line) was ineffective to complete the ureteral suture and the substitution with a 5 mm needle driver was necessary. Retroperitoneal Drainage.

**Results:** Operative time 240 minutes. Intraoperative bleeding <25 ml. In the postoperative day (pod) 1st urine leakage was reported and catheter and drainage were left in place for 15 days. JJ stent were removed in pod 30th. Followup at pod 30th and 45th exclude hydronephrosis at ultrasound. The patient have been always asymptomatic.

**Conclusion:** Retroperitoneal hybrid LESS ureterolithotomy is feasible, safe and effective. Cosmetic result and lesser pain are principal advantages. Absence of real triangulation still remain its main drawback. Port leakage, instrument crashing are constant. Current instruments need to be improved. Hybrid approach in reconstructive LESS should be preferred for unskilled surgeon, but the procedure still remains challenging.

### VS9-08 VIDEO ABSTRACT: LAPAROSCOPIC RETROPERITONEAL LYMPH NODE DISSECTION (LRPLND) FOR HIGH RISK PEDIATRIC PATIENTS WITH PARA-TESTICULAR RHABDOMYOSARCOMA

J. Tomaszewski, D. Sweeney, A. Mohamed, L. Kavoussi, M. Ost

**Background:** Retroperitoneal lymph lode dissection (RPLND) is recommended in children 10 years or older with para-testicular rhabdomyosarcoma. Primary tumors >5 cm are an additional risk factor for disease recurrence in the retroperitoneum. We report on our experience with laparoscopic RPLND (LRPLND) in high risk pediatric para-testicular rhabdomyosarcoma patients.

**Methods:** Three patients, mean age 13.6 years (range 10–16 years), underwent modified template LRPLND following radical orchiectomy for pre-operative rhabdomyosarcoma stage T1aN0M0, T1bN0M0, and T2bN0M0 respectively. Primary para-

testicular masses measured a mean 7.5 cm (range 4–10 cm). LRPLND was carried out a mean 8.6 days (range 7–12 days) following radical orchiectomy utilizing four trocars placed equidistant in the midline.

**Results:** Average OR time was 382 minutes (range 245–656 minutes). Mean estimated blood loss was 53 cc (range 10–75 cc), and mean post-operative hospital stay was 2.5 days (range 2–3 days). There were no post-operative complications. Retroperitoneal nodes were negative for microscopic disease in two patients and positive in one patient. All patients received adjuvant chemotherapy with vincristine, dactinomycin, and cyclophosphamide (VAC). **Conclusion:** LRPLND for high risk pediatric para-testicular rhabdomyosarcoma patients is a safe diagnostic and therapeutic procedure with the benefit of rapid convalescence enabling early commencement of adjuvant chemotherapy.

### **VS9-09 RETROPERITONEOSCOPIC APPROACH IN THE TREATMENT OF URINARY FISTULA AFTER RIGID ENDOSCOPIC URETEROLITHOTRIPSY FOR UPPER URETERAL STONE**

M. Tobias-machado, E. Starling, C. Gromatzki, C. Bautzer, F. Ferro, E. Wroclawski

**Background:** Ureteral lesions after endoscopic ureterolithotripsy are generally treated with ureteral stent. When a re-operation was necessary a large conventional incision is employed and the minimally invasive nature of procedure is lost. The aim of this video was to describe the retroperitoneal endoscopic approach as an option to treat this complication and maintain less invasive nature of the procedure.

**Methods:** A 60 years old man developed a large retroperitoneal urinary leakage after a rigid ureteroscopic procedure with ureteral laceration that fail to ureteral stenting. Three trocars retroperitoneoscopic approach promoted urinoma aspiration, identification of ureteral laceration and definitive treatment with running absorbable suture.

**Results:** Operative time was 1.5 h. There was resolution of urinary drainage and no complication was observed. Hospital stay was 3 days and return to normal activities was 4 weeks.

**Conclusion:** With experienced team the retroperitoneal approach can be performed safely with excellent results after complications

related to ureterolithotripsy. This is probably less invasive than conventional open procedure and should be encouraged.

### **VS9-10 A SYSTEMATIC TECHNIQUE FOR LAPAROSCOPIC SUPERFICIAL INGUINAL LYMPH NODE DISSECTION—DEVELOPING THE POSTERIOR AND ANTERIOR PLANES INDIVIDUALLY**

J. Montgomery, A. Weizer—USA

**Background:** Inguinal lymph node dissection by an open technique is a morbid procedure fraught with complications and significant patient recovery time. The laparoscopic approach limits wound complications without compromising oncologic principles. Few centers have reported on this technique and it has not gained wide acceptance. We present a novel, systematic technique for laparoscopic inguinal lymph node dissection.

**Methods:** The patient remains in the supine position with his leg flexed at the hip and knee and externally rotated. A 2 cm incision is made at the inferior aspect of the femoral triangle and we dissect down to the fascia lata. A 12 mm camera port is placed, and blunt and pneumo-dissection begins the posterior dissection. Two 5 mm working ports are placed and a harmonic dissector is used free the remaining attachments between the fascia lata and the node packet. The saphenous vein is spared. The ports are removed and the anterior space between the node packet and Scarpa's layer is developed bluntly. The ports are replaced and the anterior dissection is completed with the harmonic dissector. An inguinal drain is left in place until drain output is less than 30 cc for a 24 hour period.

**Results:** This technique has been used for staging of T2 penile cancer in 5 groins. The average operative time is 94 minutes; average length of stay is 1.7 days; average drain time is 13.2 days; average node count per groin is 4.8. Complications include left groin swelling after trauma in one patient and a lower extremity deep vein thrombosis in a 2nd patient.

**Conclusion:** Laparoscopic inguinal lymph node dissection using this systematic technique can facilitate the adoption of this approach. Patients would benefit from a minimally invasive approach without compromising oncologic effectiveness.

## **VS10: LAPAROSCOPY BLADDER**

### **VS10-01 RETAINED PROSTATE CAPSULE AND EJACULATORY FUNCTION TOTAL BLADDER RESECTION OF LAPAROSCOPIC, ILEAL NEOBLADDER SURGERY**

C. Lin—China

**Background:** discussion total bladder resection of laparoscopic retained prostate capsule, seminal and vas deferens on postoperative quality of life.

**Methods:** Laparoscopic bilateral pelvic lymphadenectomy, separate between the seminal—bladder gap, resect bladder. Resect prostate along the prostatic capsule. sewing reserve allantoic with “N” type ileal loop, reimplantation by insert ureteral 1 cm. Ana-

stomosis allantoic reserve with the prostate capsule under the laparoscopic.

**Results:** We have 5 cases, 4 cases of T2N0M0. 1 case of T3N1M0. Age 59–72 years old. 5 cases were successfully, The average operation time of 5 hours and 40 minutes. follow-up 1–9 months, 1 case of mild incontinence, others have good continence. 2 cases can complete sexual intercourse.

**Conclusion:** Retained prostate capsule and ejaculatory function total bladder resection of laparoscopic, ileal neobladder surgery is feasible. 1, retains the functions of erection and ejaculation. 2, we have fewer cases, Older patients sexual function are worthy of further exploration.

### VS10-02 LAPAROSCOPIC RESECTION OF BLADDER DIVERTICULUM IN FEMALE WITH PREPERITONEAL APPROACH

R. Sanseverino, U. Di mauro, G. Napodano, O. Intilla, T. Realfonso—Italy

**Background:** We report a case of 47 years old female affected by a large posterolateral bladder diverticulum with a history of UTI and LUTS.

**Methods:** We perform a transurethral and extraperitoneal laparoscopic combined approach. After creating the preperitoneal space by balloon trocar dissection, five trocars (2 × 5 mm and 3 × 10 mm port) are placed in hypogastrium. Identification of the diverticulum is made easier by bladder filling and cystoscope lighting. Bladder diverticulum is completely isolated. An absorbable suture is passed around diverticulum neck; so it is clamped with suture and Hem-O-lock clip. Resection of the diverticulum. Bladder is repaired with absorbable suture. A drain is placed into the pelvis. The procedure ends with extraction of the diverticulum.

**Results:** Operative time was 180 minutes. No complications were observed. The patient was discharged after 6 days.

**Conclusion:** Laparoscopic bladder diverticulum resection seems to be a safe and feasible procedure.

### VS10-03 SINGLE PORT LAPAROSCOPIC AUGMENTATION ENTEROCYSTOPLASTY

R. Sotelo, B. Cuomo, O. Carmona, R. De andrade, D. Canes, I. Gill—Venezuela

**Background:** To report on the initial case and surgical technique of laparoendoscopic single site (LESS) subtotal cystectomy and augmentation enterocystoplasty performed through a single multichannel transumbilical port.

**Methods:** LESS subtotal cystectomy and augmentation ileocystoplasty was performed in a 20-year-old female with neurogenic bladder. The patient had long history of urinary incontinence, frequent and urgent urination, and repeated urinary infections. Imaging studies and urodynamics revealed 100 cc bladder capacity with thickened walls, countless diverticules and low compliance. The procedure was performed exclusively via a novel multichannel access port that had four 12 mm access channels (QuadPort). Additional instruments included a 5 mm videolaparoscope, Sono-Surge, and flexible scissors. Subtotal cystectomy was initially performed by resecting 70% of the bladder. The ileal loop was exteriorized through the single-port by detaching the valve and the ileal pouch and bowel continuity were restored extracorporeally. The vesico-ileal anastomosis was performed laparoscopically.

**Results:** Operating time was 300 minutes and blood loss was less than 100cc. There were no intraoperative or postoperative complications. Hospital stay was 6 days. The drain and the Foley catheter were removed 7 and 21 days after surgery, respectively. Postoperative cystogram confirmed a watertight anastomosis and increased bladder capacity. Patient is performing intermittent self-catheterization to ensure complete emptying.

**Conclusion:** Our initial experience with LESS subtotal cystectomy and ileo-cystoplasty through a single port is encouraging, indicating technical feasibility of this approach. Use of the larger diameter QuadPort significantly facilitates extracorporeal bowel reconstruction.

### VS10-04 ISOBARIC LAPAROSCOPIC RADICAL CYSTO-PROSTATECTOMY WITH THE LAPARO-TENSER SYSTEM

A. Granata, A. Gregori, F. Scieri, A. Salvaggio, A. Romanò, F. Gaboardi

**Background:** Laparoscopic radical cystoprostatectomy (LRC) is a therapeutic option for the treatment of muscle-invasive bladder cancer even though in literature are described possible complications due to the use of pneumoperitoneum, such as increased risk of cardiopulmonary, immunological, endocrine and metabolic complications. Moreover, oncological safety of the procedure is still under investigation. Some studies postulate an effect of gas inflow in micrometastasis implant. In order to avoid possible side effects due to pneumoperitoneum we planned a feasibility study on LRC without the use of pneumoperitoneum (isobaric). We used a mechanical system that lifts the abdominal wall (Laparo-Tenser™, Lucini Surgical Concept, Milan, Italy). To our knowledge this system has never been used in Europe for LRC.

**Methods:** This video shows the surgical technique of LRC without the use of pneumoperitoneum, using the Laparo-Tenser system. This consists in two parallel knees placed subcutaneously in the abdominal wall, lifted by a mechanical arm, creating an operative space in the abdominal cavity. Between February 2008 and March 2009 we performed 6 isobaric LRCs. The urinary diversion was an orthotopic neobladder in one case and ileal conduit in 5 cases.

**Results:** The isobaric LRC was successfully performed in all the cases in a mean operative time of 232 min (308 min. with the urinary diversion). Mean blood loss was 416 ml. These data compare favourably with those of traditional LRC with pneumoperitoneum.

**Conclusion:** The isobaric LRC is feasible and represents a very interesting technological improvement for its oncological and anesthesiological advantages. The Laparo-Tenser is a reliable and secure system that need to be evaluated in a larger number of patients with a longer follow up. Actually we consider the isobaric technique as our standard option when we decide to perform a LRC, due to the theoretical positive oncologic results.

### VS10-05 LAPAROSCOPIC RADICAL CYSTECTOMY WITH EXTRACORPOREAL URINARY DIVERSION:

S. Shah—India

**Background:** We report our experience with laparoscopic radical cystectomy in a consecutive series of 19 patients with creation of MAINZ II pouch with extracorporeal technique in 18 patients and ileal conduit in one patient.

**Methods:** Between Nov 2003 and December 2008, 17 males and 4 females aged 23 to 70 years (mean 53.4) underwent laparoscopic radical cystectomy with open MAINZ II pouch urinary diversion for muscle-invasive carcinoma bladder in 21 cases. In one case ileal conduit was performed.

**Results:** Mean laparoscopic operating time was 185 min. Average blood loss was 650 ml. Mean post operative stay was 7.5 days. The mean follow-up was 20 months (range 1–38 months). No local recurrences, peritoneal carcinosis or trocar-site metastases occurred. 1 of 21 cases presented with pulmonary metastasis (of stage pT2bN0 TCC G2-3) after 7months. This patient was subjected to chemotherapy.

**Conclusion:** In this small series, laparoscopic radical cystectomy appears to have benefits in terms of less postoperative discomfort and a shorter hospital stay. However, long-term oncological

equivalence of this technique remains to be determined. Larger prospective studies will be needed to answer these questions.

### VS10-06 EXTENDED LYMPHADENECTOMY IN BLADDER CANCER IN A WOMAN

A. Celia, G. Zeccolini, G. Bredasan bassiano hospital—Italy

**Background:** During radical cystectomy, pelvic lymphadenectomy is an important step and, according to many authors, it increases survival in 30% of patients. Laparoscopic extended pelvic nodes dissection is technically challenging for urologists even with a long experience in laparoscopy. This technique was proved to be feasible and now is approaching standardization. This video shows the main steps of extended pelvic node dissection in a woman affected by transitional cell carcinoma of the bladder, with special concern to the technical points that may make the procedure more feasible and reproducible.

**Methods:** Patient is placed in the supine position, with the legs apart to allow free access to the perineal space. The table is tilted head-down in a pronounced Trendelenburg position. A small incision is made above the umbilicus, and deepened till the peritoneum is opened, then a 10-mm Hasson trocar is inserted through which a 0-degree optic is introduced, the peritoneal cavity is inspected, and the other 4 trocars are introduced under direct vision. Extended pelvic lymphadenectomy is performed according to the open template with the genitofemoral nerve presenting the lateral boundary, the perivesical tissue presenting the medial boundary, the aortic bifurcation presenting the cranial limit, the obturator nerve presenting the posterior limit, and the node of Cloque presenting the caudal limit.

**Results:** The operating time for laparoscopic extended node dissection was 100 min. The procedure was free from intraoperative complications. The number of removed nodes was 21. The histopathological analysis revealed no residual malignancy; one metastatic node.

**Conclusion:** Laparoscopic pelvic node dissection is a feasible, safe, and reproducible procedure. However, it is technically challenging and should be performed in centers with long experience in laparoscopy. A long-term follow up is needed to assess the oncological and functional outcome.

### VS10-07 LAPAROSCOPIC RADICAL CYSTECTOMY: ULUDAG UNIVERSITY EXPERIENCE

I. Yavascaoglu, K. Gokcen, H. Dogan, Y. Kordan, H. Vuruskan, B. Oktay—Turkey

**Background:** To present our laparoscopic radical cystectomy (LRS) experience.

**Methods:** Twenty-three patients who underwent LRS between May 2006 and November 2008 have included for evaluation.

**Results:** Mean age of patients was 61.5 (40–75) years and 22 were male. Mean total operative time was 388 (270–510) minutes, whereas mean time for laparoscopic cystectomy and lymph node dissection was 225 (180–310) minutes. Simultaneous nephroureterectomy was performed in two patients. Ileal conduit was performed in 20 patients as urinary diversion and orthotopic neobladder was constructed in 3. Mean blood loss was 130 ml (40–300) and intraoperative blood transfusion was not necessary in any of the patients. Mean postoperative hospitalization was 11.1 (7–24) days. No intraoperative complication was experienced and conversion to open surgery has never happened. Superficial wound infection and dehiscence have happened in 2 patients and pro-

longed ileus was encountered in 1 patient. Histological examination revealed organ confined (pT0/pT1/pT2/pT3a) disease in 21 (91.3%), extravesical (pT3b/pT4) disease in 2 (8.7%) and lymph node involvement in 4 (17%) patients. Four patients with lymph node involvement, 1 patient with squamous cell cancer and 1 patient with neuroendocrin carcinoma received adjuvant chemotherapy. Within a mean time period of 13.1 (1–26) months, 95.6% (22/23) of patients including patients who were given adjuvant chemotherapy are alive. No port site metastasis has been reported during the follow-up period.

**Conclusion:** LRS seems to be associated with minimal postoperative morbidity. Our clinical experience reveals that LRS can be performed safely without compromising the oncological principles.

### VS10-08 VIDEO TECHNIQUE OF THE NOTES APPROACH TO MANAGEMENT OF INADVERTENT SPLENIC, ENTERAL AND BLADDER INJURIES

S. Parekattil, Sijo J., C. Fyock, H. Atalah, L. Su, C. Forsmark, M. Wagh—USA

**Background:** Visceral organ injury during Natural Orifice Transluminal Endoscopic Surgery (NOTES) can be life threatening. Conversion to standard laparoscopy or laparotomy is needed in these circumstances. This study presents the video technique of managing inadvertent intra-operative splenic, enteral and bladder injuries utilizing a NOTES approach in a porcine model.

**Methods:** 14 female pigs underwent either transgastric or transcolonic NOTES under general anesthesia. Lacerations of varying length were made in the spleen, small bowel and bladder. The injuries were managed as such: 1) endoscopic cautery for splenic lacerations, 2) endoscopic clips for enteral and bladder closure. Acute cases underwent immediate post-operative euthanasia and necropsy. Survival studies were performed in 4 animals. These pigs underwent euthanasia and necropsy one week after surgery per protocol. At necropsy, the peritoneal cavity and access sites were inspected for abscesses, bleeding or damage to surrounding structures. Leak test was performed to assess successful closure of the enterotomies.

**Results:** Successful management of the injuries was achieved in all cases. Survival animals had an uneventful post-operative course without any complications. Food intake and bowel movements were not compromised. At necropsy, all injury and access sites were well healed without evidence of necrosis, adhesions, abscess, bleeding or spillage of intestinal contents in the peritoneal cavity. There was no evidence of small bowel luminal obstruction.

**Conclusion:** Inadvertent splenic, enteral and bladder injuries can be managed in a NOTES approach using currently available endoscopes and accessories without the need for laparoscopy or laparotomy.

### VS10-09 LAPAROSCOPIC RADICAL CYSTECTOMY WITH EXTRACORPOREAL ILEAL CONDUIT FOR MUSCLE INVASIVE BLADDER CANCER IN KASHMIR

M. Khan—India

**Background:** Radical cystectomy is the gold standard treatment for invasive bladder cancer. However, it is a major surgical procedure and may incur significant operative blood loss. Laparoscopic cystectomy has been described and it has been proven to be feasible. Nevertheless, its role, advantages and potential complications should be defined. We present our experience in laparo-

scopic radical cystectomy with extracorporeal urinary diversion for treatment of muscle invasive bladder cancer in Kashmir.

**Methods:** Between August 2006 and April 2009, 12 men and 2 women with organ-confined muscle-invasive transitional cell carcinoma of the bladder underwent laparoscopic radical cystectomy with the Bricker-type urinary diversion. The age range was 35–70 years. Laparoscopic radical cystectomy and bilateral pelvic lymphadenectomy were performed using five fan-shaped ports by a transperitoneal approach. An ileal conduit diversion was created through the site of specimen retrieval which was the second port at the region of the right pararectus.

**Results:** 14 Laparoscopic Radical cystectomies were performed. No conversion to open surgery was necessary. Mean operating time was 160 min (range 120–210 min) for laparoscopic radical cystectomy and 90 min (range 65–140 min) for creating the ileal conduits. Mean estimated blood loss was 300 ml (range 160–550 ml). Five of the 14 patients needed blood transfusion (400 ml each). Mean days to ambulation and oral intake was 2 (range 2–5 days) and 4.2 (range 3–6 days), respectively. Mean hospital stay was 14 days (range 12–23 days). Mean follow-up was 6.1 months (range 3–20 months). Histopathological examination of the specimens revealed stage T2N0M0 in 10 cases, T3aN0M0 in 03, and T3bN1M0 in 1 (TNM staging). WHO grading: G2 in 09 cases and G3 in 05 cases. Complications were as follows- Rectal perforation in 1 pt, enterocutaneous fistula in 1 pt and post operative ileus in 2 pts. All are alive and free of disease. Intravenous pyelogram at 3 weeks postoperatively shows no evidence of upper urinary obstruction.

**Conclusion:** Despite technical difficulties, laparoscopic radical cystectomy with Bricker-type urinary diversion is feasible. With more experience in the surgical technique, laparoscopic radical cystectomy with extracorporeal urinary diversion can become an

alternative treatment of choice in the selected patients with organ-confined bladder cancer in Kashmir.

### VS10-10 LESS TRANSVESICAL BLADDER CUFF EXCISION

R. Sotelo, D. Ramirez, O. Carmona, Z. Pascal, B. Irwin, I. Gill—Venezuela

**Background:** The main challenge at the same time controversial aspect of laparoscopic nephroureterectomy is the management of distal ureter, as it has a major impact on cancer outcomes. We describe a new endoscopic approach for the dissection of the distal ureter and bladder cuff en bloc. Using an “R-Port” transvesical with Pneumovesicum.

**Methods:** Male patient, 80 years old with history of gross hematuria and suspicion of left upper tract transitional cell carcinoma, without a history of bladder problems or transurethral resection of bladder tumor (TURV). After nephroureterectomy the ureter was exposed and dissected above the iliac vessels down to the bladder. Hem-o-lock is placed in the distal ureter and the management of bladder cuff starts. We used transvesically R-Port device.

**Results:** The operating time (LESS radical nephroureterectomy, RPLND and bladder cuff excision) was 6 hour and 15 minutes. The bladder cuff time is 45 minutes, no complications intra or post-operative, the catheter was removed after 7 days. The oncological outcomes was satisfactory. Histopathologic analysis showed kidney invasive papillary urothelial cancer pT3 pN0 (0/7) G3.

**Conclusion:** The technique of the distal ureter and bladder cuff has not been standardized yet. The management of bladder cuff with a single port is feasible and is a minimally invasive technique that adheres to basic principles cancer. Additional studies are needed to identify the best approach for managing the distal ureter at the time of Laparoscopic nephroureterectomy.

## VS11: TRANSURETHRAL SURGERY

### VS11-01 STUBBORN STRICTURES- IS LASER ABLATION THE ANSWER? DR. ULHAS SATHAYE SAHAYOG SPECIALITY HOSPITAL JAMNAGAR 361001 INDIA

U. Sathaye

**Background:** There is a subgroup of urethral strictures which keep on recurring in spite of the best treatments. Laser ablation of these strictures is being offered to decrease recurrence and improve quality of life (QOL). This video shows the various techniques of the operation.

**Methods:** 6 cases have been included in this series. Age ranged from 20 to 72 years. 2 were urethroplasty failures with complete obliterative strictures, 2 had post TURP bladder neck strictures and there were 2 having recurrent bulbous strictures who had undergone 3 or more urethrotomies within 1 year. All had a complete preoperative workup including urethrograms. The treatment offered was laser ablation of the bladder neck, corethro’ with ablation of the fibrosis and urethrotomy and ablation using a 30 watt holmium laser. All had a post opt. 16Fr per urethral catheter for 3 days. The follow-up is up to 1 year. It comprises of uroflometry and

a urethral calibration under LA at 6 weeks, 3 months and 6–9 months.

**Results:** At all follow-ups the patients were subjectively happy with their QOL and flow rates. The peak flow rate ranged from 15 to 27 ml/sec and the average flow rate from 5 ml to 11 ml/sec. Calibration was possible easily in all at 6 weeks and in 3 at 3 months. 2 needed urethral dilatation under LA up to 26Fr. At 9 months 1 is lost for follow up.

**Conclusion:** Strictures which keep on recurring are a therapeutic challenge for the urologist. Laser ablation is attractive and shows promising results in a short term follow-up.

### VS11-02 FLUORESCENCE CYSTOSCOPY WITH HEXAMINOLEVULINATE IN THE DIAGNOSIS OF BLADDER CANCER: OUR EXPERIENCE

M. Poggio, C. Scoffone, C. Cracco, M. Cossu, S. Grande, R. Scarpa—Italy

**Background:** Since the early 1990s, 5-aminolaevulinic acid (5-ALA) has been investigated for the fluorescent detection of

urothelial bladder cancer, especially for CIS. ALA is a precursor in the heme biosynthesis pathway and induces an accumulation of fluorescent endogenous porphyrins, mainly protoporphyrin IX (PPIX), in tissues of epithelial origin. Recently, it has been shown that the esterification of ALA into more lipophilic derivatives, such as Hexaminolevulinate (HAL), results in up to 25-fold increase of the fluorescence compound Protoporphyrin IX. In this video we present the utility and efficacy of fluorescence cystoscopy using Hexaminolevulinate.

**Methods:** Fluorescence cystoscopy is performed, using a particular instrument allowing the switch from white to fluorescent light and vice versa. It is possible to visualize flat urothelial lesions, such as CIS or urothelial dysplasia.

**Results:** In our experience we treated 32 patients with fluorescence cystoscopy performing 52 bioptic bladder samples and 4 simple cystoscopy. The cancer detection by white light and fluorescence cystoscopy was respectively 62% and 61%. Using fluorescence cystoscopy with Hexaminolevulinate we obtain a gain in cancer detection of 18%.

**Conclusion:** Fluorescence cystoscopy with hexaminolevulinate is well tolerated, and is a useful adjunct to white light cystoscopy, improving its sensitivity. Better therapeutic outcomes are expected at long term follow up, due to more complete transurethral bladder resections and correct histological responses.

### VS11-03 GREEN LIGHT HPS 120 W LASER IN BPH—ROMANIAN EXPERIENCE

B. Geavlete, G. Nita, V. Mirciulescu, P. Geavlete—Romania

**Background:** KTP laser photoselective vaporization prostaticectomy (PVP) is a relatively new technology for the management of benign prostatic hyperplasia (BPH). We reviewed our experience, the first in Romania, regarding the efficacy and safety of this technique.

**Methods:** During the last year, 48 patients with age between 53 and 80 years with symptomatic BPH were treated by laser prostatectomy using KTP/532 laser energy at 120 W. All patients underwent standard urologic evaluation using the IPSS, peak urinary flow rate (Qmax), ultrasound measurement of the prostate volume and residual urine volume, assay of prostate specific antigen and digital rectal examination. The mean prostatic volume was 45 cc (range 30–70 cc). The patients were reassessed postoperatively at 3 and 6 months.

**Results:** KTP PVP was successfully performed in 45 patients, with a mean operating time of 57 minutes. In most cases we used just one fibre, the mean energy released being 170,000 Joules. The mean hospital stay was 24 hours. No major complications occurred intraoperatively or postoperatively. At 3 and 6 months, the mean urinary peak flow increased from the preoperative value of 8.5 ml/sec to 23.7 ml/sec and 21.2 ml/sec, respectively. The mean post-voiding residual volume decreased from 90.5 to 30.5 ml and 15.0 ml, respectively. Two patients were admitted for secondary hematuria, respectively urinary infection, and 9 patients presented irritative low urinary tract symptoms during their first postoperative check-up.

**Conclusion:** BPH photoselective vaporization using 120 W Green Light laser is a safe and easy to learn technique, with good functional results and a low rate of complications.

### VS11-04 HOLMIUM:YAG LASER EPILATION OF URETHRAL DIVERTICULAR HAIR

D. Beiko, S. Pierre, M. Leonard—Canada

**Background:** Urethral hair is a known complication following hypospadias repair. Treatment options for this complication in-

clude open surgical revision and endoscopic ablation using various energy sources. However, there are very few reports of laser epilation in the literature to date. This video demonstrates the role of holmium:YAG laser epilation of urethral hair follicles within a urethral diverticulum following hypospadias repair in an adolescent presenting with recurrent urinary tract infections.

**Methods:** Under general anesthesia and in lithotomy position, cystourethroscopy was performed on a 16-year-old male using a rigid 17F cystoscope. Endoscopic examination of the penile urethra revealed several strands of hair located within a urethral diverticulum. A 400-micron holmium:YAG laser fiber was used to ablate the base of all hair follicles. Laser settings of 0.8 joules and 8 hertz were used, for a total power of 6.4 watts.

**Results:** Urethral diverticular hair epilation was performed successfully. At the end of the procedure there were no remaining strands of hair and the follicle bases were completely ablated. There were no intraoperative or postoperative complications. At 3-year follow-up, the patient was symptom-free and infection-free.

**Conclusion:** In the treatment of urethral hair follicles following hypospadias repair, holmium:YAG laser epilation represents a minimally invasive approach that uses equipment and techniques that are familiar to the endourologist. Our effective technique can be safely used as a first-line surgical option in this patient population.

### VS11-05 OPTICAL URETHROTOMY UNDER CORPUS SPONGIOSUM BLOCK

M. Ather, A. Zehri, Z. Alam

**Background:** Optical urethrotomy (OU) is generally performed with the patient under general or major regional anaesthesia. We determined the safety and efficacy of optical urethrotomy using a spongiosum block with sedation for anterior urethral stricture.

**Methods:** OU was performed under general or major regional anaesthesia (group 1) or under spongiosum block (group 2). 10 ml of Lidocaine jelly was instilled and penile clamp was applied for 10 minutes in all patients in group 2. Patients were placed in dorso-lithotomy position, a rubber penile clamp was applied over the base of the penis and 2.5 to 3 ml of 1% lidocaine solution was slowly injected in the glans penis over 1 minute with the help of a 27 G hypodermic needle. Standard optical urethrotomy was performed immediately with a cold cut knife.

**Results:** The two groups were matching in terms of age and etiology and length. OU was successfully completed in all patients in group 1 and 15 of 16 in group 2. In group 2, 15 patients (94%) had no pain. One patient reported moderate discomfort and procedure abandoned. In group 2 one patient required parental analgesia post procedure. The first year recurrence was not significantly different in the two groups ( $p = 0.192$ ). Pain score on the visual analog scale was not different in the two groups.

**Conclusion:** OU using a spongiosum block with sedation is as safe and effective as using regional or general anesthesia, particularly in sicker patients. The shorter operative time in the local anesthesia group could also make it cost-effective.

### VS11-06 ENDOSCOPIC MANAGEMENT OF ADULT ORTHOTOPIC URETEROCELE AND ASSOCIATED CALCULI WITH HOLMIUM LASER: EXPERIENCE WITH 23 PATIENTS OVER 6 YEARS

H. Shah, V. Kumar, A. Khandkar, S. Kharodawala, H. Sodha, M. Bansal

**Background:** To retrospectively evaluate the safety and effectiveness of holmium laser endoscopic incision and laser lithotripsy in adults with orthotopic ureterocele and associated calculi.

**Methods:** From May 2003 to April 2009 at our center, 23 adults underwent transurethral incision of an ureterocele and intracorporeal holmium laser lithotripsy for associated calculi. The perioperative data of these patients were retrospectively analyzed. The video demonstrates the surgical technique in details.

**Results:** Ureterocele was associated with a single system in 20 patients. Three patients had bilateral ureteroceles. Six patients had associated upper tract stones. The procedure was uneventful in all patients. The average postoperative hospital stay was 21.3 hours. All patients were stone free after the procedure. Sixteen patients were available for follow-up at 3 and 6 months. None of these patients had any evidence of residual ureterocele and/or hydronephrosis when evaluated with intravenous urography at 3 months. Micturating cystourethrography (MCU) at 3 months revealed low-grade vesicoureteral reflux (VUR) in five patients; no reflux was found with MCU at 6 months.

**Conclusion:** Laser endoscopic management of adult orthotopic ureterocele and associated calculi effectively decompressed ureterocele and removed stones in all patients without any significant postoperative morbidity. Low-grade VUR that may occur postoperatively resolved at 6 months.

#### VS11-07 EX VIVO MODELS FOR TRAINING IN ENDOUROLOGY

A. Celia, G. Zeccolini, G. Breda

**Background:** Simulators have gained wide acceptance as an important tool in the surgeon's learning process. Some types of simulators are currently available: plastic models, virtual digital models and animal models. Italian law forbids the use of living animals. Ex vivo-models are the closest ones to reality and therefore the most useful ones in the training of surgeons, to cover the gap between theoretical learning and real practice. We introduced porcine models in upper urinary tract endourological training, in order to improve learning curve of unskilled urologists.

**Methods:** The video shows standard endourological procedures on the model. Rigid and flexible cystoscopy Retrograde Ureteropyelography Introducing guide wire up to the kidney The use of ureteral access sheath Rigid and flexible ureterorenoscopy, explaining tricks to overcome stenosis or ureteral kinkings Operative procedures on caliceal, ureteral or bladder stones by baskets, ballistic lithotripsy or laser Percutaneous lithotripsy of a stone.

**Results:** The video shows the steps to create "ex-vivo model" by porcine urinary tract for endourological training: Ex-vivo porcine upper urinary tract is really close to human urinary tract and, therefore, is better than plastic models. It is also cheap to build and easy to use.

**Conclusion:** In conclusion, the video aims to offer to the training urologist the possibility to learn the steps of endourological procedures and to build by himself an easy ex-vivo porcine model to train on endourological techniques. Such a training will improve learning curve and will improve results during endourological procedures on human patients.

#### VS11-08 A NEW SELF-EXPANDING FULLY COVERED REMOVABLE URETERAL STENT IN IRRADIATION INDUCED BILATERAL URETERAL OBSTRUCTION R. BAISHYA, P. RANJAN, V. MUTHU, G. BADLANI, D. YACHIA, M. R. DESAI MULJIBHAI PATEL UROLOGICAL HOSPITAL. NADIAD—INDIA D. Yachia

**Background:** Ureteric obstruction after irradiation for malignancy is not uncommon. Repeated double-J (DJ) stenting is palliative and surgery can be problematic. A newly developed self expandable, large caliber fully covered metal stent [Allium Ureteral Stent (URS)] was used in such a patient with bilateral lower ureteral strictures, to check its efficacy.

**Methods:** 55-years old patient after Wertheim's hysterectomy and irradiation for Grade 3 Ca. of Cervix developed bilateral lower ureteral stricture and subsequent Stage 2 chronic kidney disease and was on repeated DJ. Despite the DJs serum creatinine was 3.1 mg/dl, which increased to 3.8 mg/dl the day of the procedure. DJs were removed and after balloon dilation of the strictures, exchanged to bilateral URS (24F×100 mm at the Lt. side, 30F×100 mm at the Rt. Side). The URS were inserted under cystoscopic and fluoroscopic guidance.

**Results:** The bilateral URS were left indwelling 12 months, patient being followed every 3 months. No stent related complications occurred during the follow-up period. At 1-year there was a moderated residual bilateral ureterohydronephrosis and serum creatinine decreased to 2.7 mg/dl. The URS were removed endoscopically 1 year after insertion using an alligator forceps to unravel them. No stent deformation, stone formation or polymeric cover disintegration was observed. 6-months after removal of the URS the patient remained asymptomatic and her serum creatinine stabilized at 2.4 mg/dl.

**Conclusion:** The self-expanding, fully covered large caliber URS seems to offer a novel and effective treatment in remodeling irradiation induced ureteric stricture in a minimally invasive way. It can become a safe alternative to conventional DJ and open surgery. However, more prospective studies and longer follow-up is needed.

#### VS11-09 URETEROSCOPIC HOLMIUM LASER ENDOPYELOTOMY FOR URETEROPELVIC JUNCTION STENOSIS AFTER PYELOPLASTY

M. Baptistussi, E. Gewher, M. Morihisa

**Background:** 8-year-old child subjected to video pyeloplasty one year before due to anomalous vessel. The child evolved well, but on the 6th month PO presented pain in the left lumbar region; exams showed restenosis of UPJ. An endoscopic surgery was performed using flexible ureteroscope and laser (1.0-Joule energy, 8-Hertz frequency, with broad 700 pulse), opening the restenosed area laterally until fatty tissue was found and contrast overflowed during ascending pyelography.

**Methods:** none.

**Results:** Patient remained with 7 Fr double pigtail stent for 6 weeks and upon radiological control showed good renal drainage at 6 months PO.

**Conclusion:** laser endopyelotomy is an excellent solution for recurring cases of UPJ stenosis.

## VS12: LAPAROSCOPY—KIDNEY 3

### VS12-01 COMBINED ENDOSCOPIC AND LAPAROSCOPIC TREATMENT OF BILATERAL STAGHORN UROLITHIASIS IN A HORSESHOE KIDNEY

M. Poggio, C. Scoffone, F. Porpiglia, M. Cossu, C. Cracco, R. Scarpa—Italy

**Background:** In this video we present the case of a tetraplegic patient, affected by bilateral staghorn urolithiasis in a horseshoe kidney. The renal stone of the left branch was 4 centimeters in diameter, while that of the right branch was a complete staghorn lithiasis of the pelvis, upper and lower calyx. The patient came to our attention with fever and acute renal failure. Because of hyperthermia, the urinary tract needed bilateral urgent drainage. Two nephrostomies were immediately applied into the left renal branch, and a single, retrograde double J ureteral stent within the right renal branch. Purulent urines were sent for bacterial colture.

**Methods:** Because of the complexity of the case, we decided to treat the patient in two different steps: the left side by percutaneous nephrolithotripsy first, subsequently the right side by laparoscopic approach (on this side the collecting system was anatomically prohibitive for a percutaneous approach).

**Results:** After one week of specific antibiotic therapy, with disappearance of the hyperthermia and normalization of the haematologic parameters (leukocytosis, C reactive protein, serum creatinine), the patient was submitted to left percutaneous nephrolithotomy in the Valdivia supine position. The inferior calyx was reached by the percutaneous ultrasound-guided renal puncture; Alken progressive dilators were used, and a 30F Amplatz sheath was applied. Ultrasound-ballistic lithotripsy was then carried out, using a 26 F rigid nephroscope. The larger stone fragments were extracted with a Nitinol basket. A second percutaneous access was gained, and another Amplatz sheath was applied in a superior calyx, to complete lithotripsy. Final flexible nephroscopy was employed to identify residual stone fragments, extracted with the Nitinol basket. One month after left PCNL, with negative urine culture and normal haematologic parameters, a combined procedure was performed, using simultaneous retrograde flexible ureteroscopy and laparoscopy to treat the staghorn stone within the right renal branch. The first step was the removal of the right double J stent and the application of a ureteral sheath on a 0.035 inches hydrophilic guidewire. Flexible ureteroscopy was then performed, and the morphology of the staghorn stone evaluated (it was shaped like a dog's bone). After inducing pneumoperitoneum, three trocars were applied. After identifying the exact location of the right renal pelvis with the stone inside by means of a laparoscopic ultrasound probe, the overlying mesocolon was incised. After an accurate preparation and dissection of the right renal pelvis, a pyelic incision was performed under direct ureteroscopic guidance, exploiting the retrograde transillumination. The tip of the flexible ureteroscope became then visible near the staghorn stone. Using laparoscopic forceps the large staghorn stone was extracted. All renal cavities were then explored retrogradely and anterogradely, removing small residual stones and fibrin. After retrograde endoureteral stent application, the renal pelvis was sutured. Finally, the mesocolon was sutured as well, after application of a retroperitoneal drainage.

**Conclusion:** Combination of endorenal surgery and laparoscopy allows to solve complex urolithiasis of the upper urinary tract in a one-step procedure. The possibility to use high-performing rigid and flexible instruments allows to obtain very good clinical results, which were unconceivable even few years ago.

### VS12-02 LAPAROSCOPIC RENAL CYST RESECTION AND PERCUTANEOUS NEPHROLITHOTRIPSY IN RENAL CYST AND NEPHROLITHIASIS IN THE SAME KIDNEY

V. Yalcin, E. Coskuner, B. Ozkan—Turkey

**Background:** In routine urology practice as a urologist we often meet with renal cysts and nephrolithiasis in the same kidney. Generally we use different kind of procedures for both of them. In this video presentation we want to share our experience in this kind of patient.

**Methods:** 58 year old man referred to our service because of hematuria and flank pain. He had double collecting system in his left kidney. At the initial position of them there was a renal cyst with a 7 cm size and nephrolithiasis in his lower calyx (10 mm). We offered him laparoscopic cyst resection and percutaneous nephrolithotripsy procedure in the same time. We started with open-end stent inserting of the left ureter in lithotomy position. Then four-port transperitoneal technique was used for cyst resection in modified lombotomy position. We opened the renal pelvis but couldn't reach the stone laparoscopically. After dilating the hipocondrial port entrance percutaneous nephrostomy sheath was placed. We used another endoscopic system and nephroscope to reach the calyx stone and the stone was removed by stone forceps. The pelvic openness was closed with 3/0 vicryl suture material laparoscopically. We didn't use double-j stent but a drain for parapelvic space.

**Results:** Post-op course was unremarkable with starting the oral nutrition in the 1st day, removing the open-end and urethral catheters in the 2nd day and removing the drain and discharging the patient in the 3th day. The patient remains cyst and stone free on CT follow-up in the 3th month.

**Conclusion:** If there is an anatomical or any other difficulty in laparoscopic cyst resection and nephrolithotomy procedure, laparoscopic assisted percutaneous nephrolithotripsy procedure can be done in a shorter operation time and without complication.

### VS12-03 NEPHROURETERECTOMY WITH ENDOSCOPIC URETERAL DESINSERTION IN THE TREATMENT OF UPPER URINARY TRACT TUMORS—EXPERIENCE ON 150 CASES

P. Geavlete, E. Constantinescu, D. Georgescu, G. Nita, V. Cauni, B. Geavlete—Romania

**Background:** Our goal was to establish in significant series the value of the endoscopic distal ureteral approach as part of nephroureterectomy for upper urinary tract carcinoma (UUTC).

**Methods:** Between June 1995 and January 2008, 150 nephroureterectomies with endoscopic distal ureteral approach for UUTC have been performed (51 T1, 72 T2 and 27 T3) in our clinical department. 112 patients underwent "pluck" transurethral detachment of the intramural ureter and 38 cases underwent ureteral stripping (31 cases with primeatal ureteral resection and in



12 cases using 12 o'clock incision). The mean follow-up period was 52 months (range 6–72 months) and the protocol was represented by CT, IVP and cystoscopy.

**Results:** 148/150 cases (98%) were successfully treated. In 2 patients (both with failed ureteral stripping) open surgery was imposed. The complications' rate was 2.6% for the transurethral detachment and 4% for the ureteral stripping. 36 patients had recurrences: 31 with superficial bladder tumors, 2 with renal fossa tumors, 1 with contralateral UUTC and 2 with asynchronous liver metastases. The mean rate of bladder carcinoma recurrence was 18.4% (7/38 cases) for ureteral stripping and 21.4% (24/112 cases) for "pluck" technique. No extravesical recurrences were found. The disease-specific mortality rate was 9%. Differences between techniques with regard to operative time, complications and oncologic outcome were not significant.

**Conclusion:** According to our experience, the endoscopic terminal ureteral approach is safe and effective as complementary proceeding to the one step nephroureterectomy.

#### VS12-04 PURE LAPAROSCOPIC RADICAL NEPHRECTOMY WITH RENAL VEIN TUMOR THOMBECTOMY

B. Chung

**Background:** Although indications for the performance of laparoscopic radical nephrectomy have widened with increasing experience and technical advances, the removal of tumor thrombus has remained a relative contraindication. In this video, the presentation of a simple method for pure laparoscopic extirpation of a renal vein tumor thrombus is presented.

**Methods:** The patient is a 76 year old male with an episode of hematuria, and a large 8 cm right renal mass and renal vein thrombus were confirmed on cross sectional imaging. Metastatic workup was otherwise negative. The patient elected for laparoscopic right radical nephrectomy with renal vein thrombectomy.

**Results:** The procedure was successfully completed purely laparoscopically. There was one right renal artery and one renal vein. The artery was ligated and divided first. The renal vein thrombus was visible within the lumen of the vein, extending just proximal to the insertion on the vena cava. A vessel loop was doubly looped around the renal vein and "milked" back towards the kidney. As an endovascular stapler was closed around the vein, the stapler actually pushed the vessel loop back towards the kidney ensuring a negative margin. Final pathology revealed a stage T3b clear cell renal cell carcinoma, Fuhrman grade 3, with negative surgical margins. Total operative time was 180 minutes. Estimated blood loss was 100 cc. The patient was discharged to home on postoperative day #2 and there were no intraoperative or postoperative complications.

**Conclusion:** Pure laparoscopic radical nephrectomy with renal vein thrombectomy is safe and feasible. The use of a vessel loop and endovascular stapler allow for a secure and reproducible method to ensure a complete resection and negative surgical margin.

#### VS12-05 PURE LAPAROSCOPIC MANAGEMENT OF RENAL CELL CARCINOMA WITH INFERIOR VENA CAVAL THROMBUS

W. Lv, G. Hao, J. Xiao—China PR

**Background:** Laparoscopic nephrectomy in patients with known venous involvement is an emerging technique. The goal of this study was to describe our experience and outcomes with laparoscopic nephrectomy for patients with preoperatively diagnosed inferior vena caval tumor thrombus.

**Methods:** From Dec 2008 to Feb 2009, 2 patients were diagnosed with renal masses with inferior vena caval thrombus at our institution. Retroperitoneal laparoscopic right radical nephrectomy and inferior vena caval thrombectomy were performed, including vascular control and intracorporeal reconstruction of the vena cava. Intraoperative, postoperative and pathological parameters were assessed.

**Results:** Complete removal of the caval thrombus was successful in each case without intraoperative or postoperative complications. The tumor size was 8 cm and 10 cm, respectively, with the thrombus extending 2 cm into the IVC in both cases. The mean operative time was 130 minutes (120 and 140, respectively). The mean estimated blood loss was 130 mL (110 and 150, respectively). The mean hospital stay was 7 days (6 and 8, respectively). Pathologic examination of the tumor specimens demonstrated negative resection margins in both patients.

**Conclusion:** In carefully selected patients, pure laparoscopic retroperitoneal nephrectomy for patients with vena cava tumor thrombus is safe and effective in experienced hands. Additional series are needed to examine the long-term oncologic outcomes.

#### VS12-06 PEDIATRIC ROBOTIC ASSISTED LAPAROSCOPIC NEPHROURETERECTOMY

A. Chawla, P. Noh—USA

**Background:** The objective of the video was to demonstrate a robotic assisted laparoscopic right nephroureterectomy in a pediatric patient.

**Methods:** The patient was a 2 year old boy with a poorly functioning right kidney with high grade vesicoureteral reflux. The da Vinci S Surgical System was implemented. Two 5 mm working robotic trochars and an 8.5 mm robotic camera trochar with a 30-degree down lens were utilized. The specimen was retrieved via the umbilical trochar site.

**Results:** Operative time was 4 hours. There was no blood loss or complication. The entire procedure, including complete excision of the refluxing ureter, was completed without repositioning of the robot. The patient was discharged after overnight stay.

**Conclusion:** Pediatric robotic assisted laparoscopic nephroureterectomy is safe and technically feasible. This minimally invasive approach allows complete excision of a refluxing ureter and minimizes the risk of a secondary procedure due to a residual ureteral stump.

#### VS12-07 ROBOTIC-ASSISTED NEPHROURETERECTOMY WITHOUT PATIENT REPOSITIONING

A. Weizer, J. Montgomery—USA

**Background:** Distal ureteral and bladder cuff management continue to be a challenge with nephroureterectomy. Limits on the robotic platform prevent management of the distal ureter and the kidney using the same position. We demonstrate a positioning technique for robotic-assisted nephroureterectomy that avoids patient repositioning but instead allows easy repositioning of the robot to complete the procedure without compromising oncologic principles.

**Methods:** The patient is positioned on a bean bag support with the ipsilateral arm secured to the chest. The upper body is placed in the modified flank position, with the patient at a 30 degree angle to the operating table. The lower body is placed in the modified dorsal lithotomy position with the ipsilateral leg straight and the contralateral leg bent at the knee. The robot is first docked over the patient's ipsilateral shoulder, and the nephrectomy and proximal ureteral dissection is completed. The robot is then undocked, brought be-

tween the patient's legs, redocked and the distal ureteral dissection and bladder cuff is completed. A water-tight closure of the bladder is completed in 3 layers, and a bladder catheter is left in place for 7 days.

**Results:** We have completed 5 robotic-assisted nephroureterectomies using this positioning technique. Our average operative time was 236 minutes. The average blood loss was 204 cc, and the average length of stay was 1.7 days. All margins have been negative. There have been no patient complications associated with positioning.

**Conclusion:** Robotic-assisted nephroureterectomy can be completed safely without repositioning the patient. Management of the distal ureter and bladder cuff is greatly enhanced by the magnified vision and mobility of the robot. A water-tight bladder closure can be achieved. The oncologic effectiveness of this technique is likely similar to laparoscopic nephroureterectomy.

#### **VS12-08 FIVE-PORT COMPLETE ROBOTIC-ASSISTED LAPAROSCOPIC NEPHROURETERECTOMY WITH BLADDER CUFF REMOVAL**

G. Wu, D. Golijanin, E. Singer, E. Erturk, J. Joseph, H. Rashid—USA

**Background:** A variety of techniques have been described in minimally invasive surgery for upper tract urothelial carcinoma. Laparoscopic nephroureterectomy generally requires 6 to 8 ports and repositioning of the patient to both maximize hilar dissection during the nephrectomy, as well as ureteral dissection and suturing of the bladder cuff during distal ureterectomy. Robotic-assisted laparoscopic approach offers the ability to effectively perform this procedure with minimal ports and repositioning. This video demonstrates our current 5-port strategy and robotic technique for nephroureterectomy with bladder cuff removal.

**Methods:** From December 2007 through June 2009, 12 robotic nephroureterectomies were performed in patients with both low and high grade urothelial carcinoma in our medical center. Six of these cases were performed using the same 5-port approach. Ports were optimized for dissection of the renal hilum and the robot was redocked to achieve appropriate axis for completion of the distal ureterectomy with bladder cuff removal. Para/pre aortic and ipsilateral pelvic lymphadenectomy was performed for patients with high-grade tumors. All specimens were removed through an extended paraumbilical port incision.

**Results:** Our 5-port approach was feasible and convenient for non obese patients. However, for obese patients with large abdomens, additional ports and reposition to supine position are necessary. Average operative and robotic times were 247.5 (175–271) and 195.5 min (150–253) respectively. No intraoperative complications occurred. All surgical margins were negative for malignancy. Average estimated blood loss was 131 cc (50–250 cc) and average hospital stay 3.3 days (2–6 days). Average lymph node number was 9 (5–14). At a median follow-up of 11 months, all patients are alive without signs of local or port recurrence.

**Conclusion:** Our five-port approach allowed safe minimally invasive access to both nephrectomy and distal ureterectomy with bladder cuff excision ± lymphadenectomy. This approach is feasible and convenient for non obese patients.

#### **VS12-09 RENAL CELL CARCINOMA DWELLING UPON A SIMPLE RENAL CYST WALL**

Y. Ozgok, M. Ates, M. Hoscan, O. Istanbuluoglu, S. Basal, M. Zor—Turkey

**Background:** Some cystic RCC are known to arise from simple renal cysts. Transformation of a simple renal cyst into RCC, however, is extremely rare. In this video laparoscopic treatment of 2.5 cm diameter renal tumor dwelling upon a right lower pole 6 cm simple cyst is presented.

**Methods:** The cyst has been followed as a simple renal cyst. Thereafter a cystic lesion with a contrast enhancing solid focus was revealed by CT 4 years after the first diagnose. Patient was operated laparoscopically by performing retroperitoneal access. After flank position, balloon dissector was placed to retroperitoneal area by using mid axillar line. After balloon dilatation another 2 trocar were placed to retroperitoneal working space. Firstly lower pole of the kidney with tumor and cyst were mobilized. Thereafter, tumor and the wall of the cyst were exit with having security surgical margin minimally 2 cm, using bipolar coater.

**Results:** Operation period was 50 minutes. Blood loss was 100 ml. any complication did not occurred during or after operation. Drain was removed postoperative 2nd day and patient was discharged. Pathological examination confirmed the diagnosis of RCC 2.5 cm in diameter, clear cell subtype, grade I (T1N0M0) with negative surgical margin. CT revealed no cystic lesion or tumoral recurrence 6 months after the operation.

**Conclusion:** We presented laparoscopically treatment of an unusual localization of renal cell carcinoma with bipolar coater.

#### **VS12-10 A SAFE AND EFFICIENT TECHNIQUE FOR INITIAL ACCESS TO INTRAPERITONEAL LAPAROSCOPY**

A. Ghazi, R. Zimmermann, A. Schfler, G. Janetschek—Austria

**Background:** One of the fundamental and critical steps in intraperitoneal laparoscopy is the initial access and creation of pneumoperitoneum, although complications associated with port-site placement are uncommon, the potential for associated morbidity is high. Veress needle and direct trocar insertion are blind techniques used to create pneumoperitoneum and are usually accomplished without incident. However, on rare occasions it can lead to major vascular, bowel or abdominal wall injuries. We herein present our experience with a safe and efficient technique to initiate intraperitoneal laparoscopy.

**Methods:** This technique involves; a skin incision is at the site of Veress needle application. The anterior sheath overlying the muscle of the abdominal wall is adequately exposed. Two hook retractors (Fistula hook retractor; single prong, Aesculap AG) are used to fix the sheath on opposite sides, gentle traction of the hooks causes elevation & stabilization of the abdominal wall during application of the Veress needle & creation of pneumoperitoneum. The trocar harboring the telescope is then placed using the same technique of stabilization, thereby avoiding injury to the underlying intra-abdominal structures by the tip of the trocar due to downward displacement of the abdominal wall during application of this trocar blindly. The remaining trocars can then be applied under vision.

**Results:** This technique has been routinely applied by one of the authors since 1993 & at our institution since 2000 and by which over 1900 cases have underwent intraperitoneal access without any reported complications during initial access.

**Conclusion:** This technique although simple is very efficient & economical method of providing a safe access to intraperitoneal laparoscopy.

## VS13: ROBOTICS—KIDNEY

### VS13-01 ROBOTIC-ASSISTED PARTIAL NEPHRECTOMY FOR TREATMENT OF RENAL TUMORS (VIDEO)

R. Ferreira coelho, K. J palmer, S. Chauhan, B. Rocco, M. Patel, V. Patel—US

**Background:** This video presents our technique to perform partial nephrectomy using the Da Vinci Surgical system (Intuitive Surgical, Sunnyvale, CA, USA).

**Methods:** The procedure was performed using a transperitoneal approach. After the overlying colon has been mobilized, the Gerota's fascia was opened and carefully dissected over the surface of the kidney. The next step was hilar control. Renal artery and vein were clamped using Bulldog clamps. We use intraoperative ultrasound to precise delineation of the tumor. Dissection of the tumor was carried out using cautery. Once the specimen has been removed, the reconstruction the remaining kidney was performed using deep hemostatic sutures along with Lapra-Ty absorbable suture clips (Ethicon EndoSurgery). The surface of the tumour bed was covered with FloSeal Floseal (Baxter Healthcare, Deerfield, IL) to improve hemostasis. Reconstruction was completed with sutures in the renal parenchyma and bolsters for additional hemostasis.

**Results:** The operative time and warm ischaemia time were 80 min and <20 minutes, respectively. The estimated blood was <150 ml. There were no intraoperative or postoperative complications. Histopathological evaluation of the surgical specimen showed clear renal cell carcinoma, pT1, negative margins, Furhman grade II.

**Conclusion:** Robotic-Assisted Partial Nephrectomy is a safe and feasible option in the management of renal tumours eligible to nephron-sparing procedure.

### VS13-02 ROBOTIC PARTIAL NEPHRECTOMY FOR COMPLEX AND HILAR LESIONS

A. Bowen, B. Lee, M. Oommen, M. Raynor, U. Boylu—USA

**Background:** Following the recent release of new AUA guidelines for the management of Stage I renal masses in combination with broadening use of the daVinci robotic platform, many tumors are now treated with minimally invasive, extirpative techniques. Advances in techniques may allow hilar and complex renal masses to be treated with minimally invasive, nephron-sparing surgery.

**Methods:** Utilizing the daVinci robot with a 5-trocar configuration, the renal vessels are identified, dissected using the robotic Maryland bipolar forceps and monopolar scissors with a 30° down camera lens. Mass localization is performed with laparoscopic ultrasound. A 1 cm margin is scored on the capsule using monopolar scissors. Warm ischemia is achieved using vascular clamping. Excision of the mass is conducted with cold scissors. Collecting system reconstruction is performed using 2-0 Vicryl with clips to decrease time of reconstruction. Suturing of the renal capsule is performed with placement of 0-Vicryl sutures on a CT-1 needle, and surgical clips. Adequate hemostasis is achieved with use of the Satinsky clamp, argon beam, Floseal and Surgicel bolsters.

**Results:** All procedures were completed without conversion to laparoscopic or open surgery. Added depth perception aided in isolation of the renal artery and vein to allow for complete dis-

section and mobilization. Shifting of the inferior trocar laterally, helps optimize port placement to increase the working space and assist with the upper pole. Placement of a hitch stitch improves visualization of posterior lesions and helps align the kidney to produce more optimal angles for suturing and capsular reconstruction.

**Conclusion:** Initial experience with robotic partial nephrectomy for complex and hilar masses demonstrates technical feasibility in conjunction with enhanced visualization.

### VS13-03 ROBOT ASSISTED LAPAROSCOPIC PARTIAL NEPHRECTOMY (RALPN) AND DOUBLE SLIDING WECK-CLIP RENORRAPHY TECHNIQUE : A CASE PRESENTATION

H. Akpinar, I. Tufek, F. Atug, S. Aksit, A. Kural—Turkey

**Background:** Robotics has been utilized to perform partial nephrectomies for small and incidentally detected renal tumors. In this video, we present a robotic assisted laparoscopic partial nephrectomy and double sliding weck clip renorrhaphy technique.

**Methods:** Asymptomatic 4 cm exophytic mass on upper pole of left kidney was diagnosed in a 75 year old male. Transperitoneal approach was used. Renal vein and artery were isolated laparoscopically and daVinci S HD system robot was docked subsequently. A 3 arm approach was used. First the tumor was scored and excised by cold scissors. The tumor bed was sutured with 3/0 monofilament poliglecaprone on SH needle in a running fashion using sliding weck technique. No.1 polyglactin sutures on CT needle with weck clip at the free end were prepared on the bench. These sutures with weck clips at the end were then placed through renal parenchyma from posterior to anterior at 1 cm. intervals. After completion of the final throws, large weck-clip was placed on the loose end of the suture by bedside surgeon. The tension of the treads was adjusted when necessary. Then additional set of large weck-clips were placed on top of the first ones to prevent back sliding of the first ones.

**Results:** All steps of RALPN were successfully completed. Warm ischemia and total operation times were 24 and 175 minutes respectively. Estimated blood loss was 150 cc. and length of stay was 2 days. Pathology was reported to be Fuhrman Grade 2 Chromophobe adenocarcinoma with negative surgical margins.

**Conclusion:** Robot assisted laparoscopic partial nephrectomy is an effective and feasible method for T1 renal tumors. Renorrhaphy with double sliding weck-clip technique can be performed without using other hemostatic agents. However laparoscopically skilled and experienced patient site surgeon is essential.

### VS13-04 ROBOTIC PARTIAL NEPHRECTOMY: EARLY UNCLAMPING TECHNIQUE

B. Lee, M. Oommen, M. Raynor, U. Boylu—USA

**Background:** Our purpose was to describe the technique of robotic assisted-laparoscopic partial nephrectomy with early unclamping.

**Methods:** Utilizing the da Vinci robot with a 5-trocar configuration, the renal artery and vein identified, dissected and exposed using the robotic Maryland bipolar forceps and monopolar scissors with a 30-degree-down camera lens. Localization of the mass is performed with laparoscopic ultrasound. A 1 cm margin is scored

on the renal capsule using monopolar scissors. Warm ischemia is achieved using either Satinski or bulldog clamps after inducing a diuresis with mannitol and furosemide. Excision of the renal mass is conducted with cold scissors. Reconstruction of the collecting system and hemostasis of the tumor bed was performed using 2–0 Vicryl with LapraTy clips to decrease time of reconstruction. After coagulation of the tumor bed with Argon beam, hilar clamps were removed. Following the placement of Surgicel bolsters and injection of the hemostatic sealant, suturing of the renal capsule is performed with placement of 0-Vicryl sutures on a CT-1 needle and surgical clips.

**Results:** All robotic partial nephrectomies were completed without conversion to laparoscopic or open surgery. Early unclamping of the hilar clamps significantly reduced the warm ischemia time. Optimization of port placement by shifting the inferior trocar laterally increases the working space and helps in the upper pole dissection. Placement of a hitch stitch improves visualization of posterior lesions and helps align the kidney to produce more optimal angles for suturing and capsular reconstruction.

**Conclusion:** Robotic partial nephrectomy with early unclamping is technically feasible. Further studies are needed to demonstrate the preservation of renal function with early unclamping.

### VS13-05 INJURY OF RENAL ARTERY DURING ROBOTIC PARTIAL NEPHRECTOMY

Y. Yoon, D. Kim, J. Lee, S. Park, H. Moon, T. Lee

**Background:** Laparoscopic partial nephrectomy is becoming the standard of care for small, incidentally discovered renal tumors. Recently, robotic has been used to perform partial nephrectomies. However, robotic surgeries are still challenging because of complete elimination of tactile feedback. Herein we present our experience of renal arterial injury during robotic partial nephrectomy.

**Methods:** Robotic partial nephrectomy was planned on 47 year old male with a 4 cm right renal mass, which was discovered incidentally at the health promotion center. Pre-operative imaging revealed that the mass was confined renal parenchyma. After standard bowel mobilization, the renal hilum was carefully dissected. Then renal vessels were found and skeletonized. When renal artery was going to be secured using vessel loop, lower posterior branch of renal artery was injured. Then enormous bleeding was started, and it was very difficult to find renal artery again. Additional suction was needed and the renal artery was barely clipped with Hem-o-Lok clip. The surgery was converted into radical nephrectomy after all.

**Results:** Radical nephrectomy was successfully performed. Estimated blood loss was about 2,000 ml. 4 pints of packed red cell were transfused intra-operatively and post-operative hemoglobin was 12.6 g/dl. There were no other perioperative complications.

**Conclusion:** Complication during robotic partial nephrectomy can occur. The surgeon should know that the robotic arms are very powerful and it can injure major vessels very easily. In addition to that, it seems that experienced and eligible assistant is essential to complete robotic partial nephrectomy.

### VS13-06 ROBOTIC-ASSISTED PARTIAL NEPHRECTOMY FOR PRESUMPTIVE T1B RENAL CELL CARCINOMA

A. Weizer, J. Montgomery

**Background:** Recent guidelines recommend the use of partial nephrectomy for increasingly larger tumors. Robotic partial nephrectomy has the potential to allow surgeons to manage these

tumors via a minimally invasive approach avoiding a large open or hand-port incision with similar precision as open surgical partial nephrectomy. We present 4 robotic partial nephrectomies on tumors >4 cm (upper pole posterior, endophytic upper pole, broad based renal hilar tumor, and deeply penetrating renal hilar tumor) to demonstrate the comparable results that can be achieved with this approach.

**Methods:** Of the 41 patients undergoing robotic assisted partial nephrectomy at our institution, we identified 18 patients with tumors >4 cm in maximal tumor diameter (mean 4.8 cm). Patient and tumor characteristics, peri-operative data, and complications were abstracted from our institutional laparoscopic database. Four cases representing the complexity of these renal masses are presented to demonstrate the management of lesions thought to be T1b on pre-operative three-dimensional axial imaging.

**Results:** Of the 18 presumptive T1b lesions, only 1 required a completion robotic-assisted nephrectomy based on intra-operative findings of an extensively infiltrative tumor. The mean operative time was 218 minutes with an average estimated blood loss of 375 cc. The mean length of hospital stay was 1.9 days. Two patients required blood transfusion; however there were no patients with urine leak. Final pathology confirmed a T1b lesion in all but 4 patients (2 patients T3a; 2 patients T1a). There was 1 positive margin in a patient with a T1b tumor who is 1 year out from surgery without evidence of recurrence.

**Conclusion:** Robotic partial nephrectomy is an addition to the armamentarium to manage small renal masses. Early results suggest that T1b lesions, upper pole tumors, and hilar tumors can be managed through a robotic approach decreasing the morbidity of managing these patients. However, precise suturing of individual vessels is required and longer follow-up is required to evaluate cancer control. Ultimately, robotic assistance may provide more surgeons and patients access to minimally invasive extirpative renal surgery.

### VS13-07 SELECTIVE SEGMENTAL ARTERIAL CLAMPING FOR ROBOT-ASSISTED PARTIAL NEPHRECTOMY: ILLUSTRATION OF TECHNIQUE

B. Benway, S. Bhayani, R. Figenshau

**Background:** Though minimally-invasive partial nephrectomy has been established as a standard of care for nephron-sparing surgery, there remain concerns about the impact of warm ischemia upon the affected kidney. As such, there has been recent interest in exploring techniques which may serve to limit the extent or duration of warm ischemia. In this video, we illustrate a technique for selective segmental arterial clamping for robot-assisted partial nephrectomy (RAPN).

**Methods:** The patient is a 72 year-old female with a 2 cm left lower pole renal mass. Using standard robotic techniques, the bowel is reflected and the hilum is identified. One of two main renal arteries is identified and dissected in full, exposing a segmental arterial branch serving the lower pole. This segmental branch is clamped, leaving the remainder of the kidney perfused. The tumor is excised without difficulty, and reconstruction provides a secure and hemostatic repair.

**Results:** Selective segmental arterial clamping is successfully employed during RAPN.

**Conclusion:** In select patients, selective segmental arterial clamping is a safe and effective means of vascular control during RAPN. This technique is capable of providing a relatively blood-

less field for tumor excision while effectively limiting the extent of ischemic insult by maintaining perfusion throughout the remainder of the kidney.

### **VS13-08 SINGLE-INCISION ROBOTIC SURGERY (SIRS) FOR RADICAL NEPHRECTOMY: ILLUSTRATION OF TECHNIQUE**

B. Benway, R. Figenschau, S. Bhayani—USA

**Background:** There is increasing interest in techniques which further minimize the footprint of minimally-invasive nephrectomy, including natural orifice and single-site laparoscopy. However, these approaches are technically demanding, often providing odd working angles and restricted movement. Recently, we investigated the use of single-incision robotic surgery (SIRS) for radical nephrectomy, with hopes that robotic technology would greatly reduce the challenge of a single-site approach.

**Methods:** SIRS radical nephrectomy is performed in a 69 year old male with a 6 cm right renal mass. A periumbilical extraction site measuring 7 cm is identified; along this line, 3 trocars are evenly spaced. In the middle, a 12 mm camera port is placed, with a standard 8 mm robotic trocar placed cephalad. At the caudad port site, we use an 8 mm robotic trocar telescoped through a 12 mm standard trocar. This allows for simple undocking of the robotic arm to allow the assistant to pass instruments. No specialized ports are used.

**Results:** SIRS radical nephrectomy is successfully performed. Instrument collisions are minimal, and do not hinder the ability to safely and effectively dissect.

**Conclusion:** SIRS radical nephrectomy is a safe and feasible alternative to standard minimally-invasive techniques. However, it is unclear at present whether SIRS provides any tangible benefit for patients over other minimally-invasive approaches. Further studies will be necessary to determine the role of SIRS in the management of renal malignancy.

### **VS13-09 T1b PARTIAL NEPHRECTOMY: ROBOTIC APPROACH WITH THE WASHINGTON UNIVERSITY TECHNIQUE**

A. Wang, R. Figenschau, B. Benway, S. Bhayani

**Background:** Open partial nephrectomy has been the historical gold standard of nephron-sparing surgery, but minimally invasive techniques have emerged. In this video, a robotic assisted partial nephrectomy (RAPN) is performed to remove a T1b cystic renal mass. The Washington University technique is demonstrated.

**Methods:** A 51-year-old Caucasian male with microhematuria is found to have a T1b Bosniak III renal mass. The multicystic mass has enhancing septations, extends into the renal sinus fat, and is in the left midpole region. He elects for a nephron-sparing procedure.

**Results:** The patient undergoes a robotic assisted partial nephrectomy. The mass is carefully manipulated to prevent tumor spillage. Both the renal artery and vein are clamped to minimize blood loss, improving visualization of the dissection. Extensive reconstruction, including pelvicaliceal repair, is needed to repair the large defect. Sliding Weck clips are used for parenchymal reapproximation. Warm ischemia time totaled 30 minutes and total operative time was 2 hours and 14 minutes. Estimated blood loss was 150 ml. Pathology findings were of a 7 cm × 4 cm renal cell carcinoma, Fuhrman Grade 1. Resection margins were free of tumor.

**Conclusion:** RAPN can be utilized to perform nephron-sparing procedures for large T1b masses. Despite the lack of haptics in robot assisted surgery, a cystic tumor can nonetheless be resected with great delicacy. Reconstructive efforts may also be enhanced with robotic assistance, and in turn, shorten warm ischemia times.

### **VS13-10 ROBOTIC PARTIAL NEPHRECTOMY FOR RENAL HILAR MASSES**

M. Patel, R. Laungani, A. Shrivastava, E. Kheterpal, M. Menon, C. Rogers—USA

**Background:** Tumors located near the renal hilum are a particular challenge for a minimally invasive approach. We describe techniques for robotic partial nephrectomy (RPN) for renal hilar tumors.

**Methods:** Patients were placed in flank position with the camera in a lateral position. Assistant ports were placed medially. The robot was docked and the bowel was reflected medially. The renal vessels, pelvis, and ureter were dissected away from the tumor. Branches of the renal artery and vein entering the tumor were dissected and ligated. Intraoperative ultrasound was used to delineate tumor margins. The renal hilum was occluded with bulldog clamps or a statinsky clamp and the tumor was excised sharply. Enucleation of the base of the tumor was performed in select cases to preserve adjacent hilar structures. The resection bed was repaired with 3–0 vicryl sutures on an RB-1 needle with care taken not to take deep bites near critical structures. Capsular sutures were secured using the sliding hemolock clip technique.

**Results:** We successfully performed RPN for renal hilar tumors in 8 patients. All patients had a warm ischemia time less than 30 minutes and all demonstrated organ confined RCC with negative surgical margins.

**Conclusion:** RPN is safe and feasible for select patients with renal hilar tumors and may facilitate the technical challenges of a minimally invasive approach.

## **VS14: ROBOTIC—PROSTATE**

### **VS14-01 TECHNIQUES FOR POTENCY PRESERVATION DURING ROBOTIC-ASSISTED RADICAL PROSTATECTOMY (RALP)—VIDEO**

K. J Palmer, R. Ferreira Coelho, S. Chauhan, B. Rocco, M. B Patel, V. Patel—US

**Background:** Adequate identification of the neurovascular bundle (NVB) during nerve sparing radical prostatectomy is a critical component to the preservation of potency. In RALP the approach to nerve sparing can be antegrade, retrograde, or a combination of two. It can be athermal or with the use of energy (monopolar,

bipolar, harmonics). In this video, we present our preferred approach to neurovascular bundle dissection during RALP.

**Methods:** Based upon our experience with open and standard laparoscopic prostatectomy we developed a combined technique for nerve preservation during RALP. Our approach to RALP is the standard antegrade prostatectomy. However, prior to controlling the vascular pedicles we release the NVB from the prostate beginning at the apex and extending back toward the base of the gland. We evaluate the potency outcomes in 397 patients with preoperative SHIM >21 who underwent RALP with bilateral nerve sparing using this technique.

**Results:** The potency rates (capable of intercourse with or without the use of oral medications) immediately after the surgery and at 1, 3, 6 and 12 months after the procedure were 17.3%; 35.7%; 79.5%; 87.7% and 91%, respectively.

**Conclusion:** Our approach to the nerve sparing during RALP is athermal with early retrograde release of the NVB with minimal traction; inter-fascial dissection is the preferred approach. Our technique allows complete neurovascular bundle sparing with excellent potency rates in the early postoperative period.

#### VS14-02 MODIFIED POSTERIOR RECONSTRUCTION OF THE RHABDOSPHINCTER: APPLICATION TO ROBOTIC ASSISTED LAPAROSCOPIC PROSTATECTOMY (VIDEO)

B. Rocco, R. Ferreira Coelho, K. J Palmer, S. Chauhan, V. Patel, G. Coughlin

**Background:** Rocco F et al described, in 2001, a technique for posterior reconstruction of the rhabdosphincter. The authors found that this technique shortened the time to recovery of urinary continence following open radical prostatectomy. In this video, we describe our modification of the technique for posterior reconstruction of the rhabdosphincter performed with robotic assistance and our preliminary outcome data.

**Methods:** The reconstruction is performed utilizing a continuous suture of two 3–0 monocryl sutures (RB1 needles) of different colours that are tied together with each individual length being 12 cms. The free edge of the remaining Denovilliers' fascia is identified following prostatectomy and approximated to the posterior aspect of the rhabdosphincter and the posterior median raphe using one arm of the continuous monocryl suture. Typically four bites of Denovilliers' fascia and the rhabdosphincter/posterior median raphe are taken. The second layer of the reconstruction is then commenced with the other arm of the monocryl suture. The running suture takes three bites of each; the posterior rhabdosphincter/Denovilliers' complex and the bladder base are approximated and the suture is tied

**Results:** Our complete 'early continence' rate (defined by use of no pads) of 58% at one week is encouraging. If the definition of continent is broadened to 0 or 1 pad per day the rate is 72%. We felt there was a learning curve of approximately 20 cases to perform this modification optimally.

**Conclusion:** The posterior reconstruction of the rhabdosphincter is a safe and effective procedure. No complications have been observed because of its employment and our preliminary outcome data showed encouraging continence rates.

#### VS14-03 ROBOTIC-ASSISTED LAPAROSCOPIC RADICAL PROSTATECTOMY: TIPS AND TRICKS

K. J Palmer, S. Chauhan, R. Ferreira Coelho, B. Rocco, G. Coughlin, V. Patel—US

**Background:** The task of learning robotic prostatectomy can be quite challenging for both novice and experienced open and laparoscopic surgery. After performing 3000 cases, it is our opinion that no single learning curve exists and there is a continual process of education and refinement of the technique. In this video we present our approach to various challenges found during robotic prostatectomy and provide tips and tricks based upon our experience.

**Methods:** The essential steps required for completion of robotic prostatectomy and the technical innovations that have allowed us to perform some of these steps in a more efficient manner are presented.

**Results:** Technical refinements presented include periurethral suspension stitch, athermal retrograde release of the neurovascular bundle, athermal seminal vesicle dissection, apical dissection.

**Conclusion:** Robotic radical prostatectomy continues to evolve. As our series continues to increase we have found new technical innovations that allow us to perform the procedure in a more efficient manner with improved outcomes.

#### VS14-04 MANAGEMENT OF A LARGE MEDIAN LOBE DURING ROBOT ASSISTED RADICAL PROSTATECTOMY

R. Dickstein, A. Weinberg, D. Wang, R. Babayan—USA

**Background:** Robot Assisted Radical Prostatectomy (RALRP) is a frequently utilized treatment for prostate cancer where difficulties with a median lobe are encountered. Literature indicates that large median lobes do not alter continence and surgical margin status after RARP. Yet, patients have significantly longer operative times, a larger need for bladder neck reconstruction, higher blood loss, and longer hospital stays. We present a video describing one technique for successfully managing a large median lobe during RARP.

**Methods:** A 62 year old man with moderately bothersome urinary symptoms, adequate potency, and PSA of 6.2 ng/mL was diagnosed with stage T2a, Gleason 3 + 3 prostate adenocarcinoma. His 59 cc prostate had a large, pedunculating median lobe. During RARP a suture helped elevate the median lobe significantly aiding in dissection. The anastomosis utilized a standard modified van Velthoven suturing technique.

**Results:** The uncomplicated operation yielded 300 cc of blood loss. Total operative, bladder neck dissection, and anastomotic times were 210, 20, and 31 minutes respectively. Pathology revealed bilateral, Gleason 3 + 3 cancer confined to 15% of the gland with negative margins. He was discharged on postoperative day (POD) 1. There was no anastomotic leak with catheter removal on POD 12. Two months postoperatively, his PSA was <0.1 ng/mL, he used two pads daily for urinary incontinence, and he continued penile rehabilitation for erections.

**Conclusion:** Early identification of and preparation for a large median lobe during RARP is essential and surgeons must be aware of potential pitfalls. One technique to aid in dissection includes elevating the median lobe with a retracting suture.

#### VS14-05 DOUBLE PIG-TAIL STENTING OF THE URETERS: TECHNIQUE FOR SECURING THE URETERAL ORIFICES DURING ROBOTIC-ASSISTED RADICAL PROSTATECTOMY FOR LARGE MEDIAN LOBES

Y. El douaihy

**Background:** Patients with large median prostate lobes undergoing robotic-assisted radical prostatectomy present unique technical

challenges to their surgeons such as ureteral orifice injury during bladder neck resection. We describe our technique of stenting to preserve the ureteral orifices.

**Methods:** Following anterior bladder neck dissection Anterior traction is applied to the large median lobe using the robotic forceps. Occasionally, we employ an 0-vicryl suture on a GS-21 needle placed through the median lobe for improving anterior traction by the assistant. Intravenous furosemide and indigo carmine are then administered for accurate identification of both ureteral orifices, and posterior bladder neck transection is completed under optical magnification, and radical prostatectomy proceeds in the standard fashion. To avoid distal ureteral injury, we perform in situ ureteral intubation with 6-French double-pigtail ureteral stents (Sof-Flex<sup>®</sup> Stent, Cook Medical Inc, Bloomington, IN) at this point prior to constructing the anastomosis. The soft-tipped guide-wire is introduced through the lumen of the suction trocar. The introducer tip is then grasped using both left and right robotic forceps and gently passed through the ureteral orifice. The radio-opaque 6-French double pigtail Sof-Flex<sup>®</sup> Stent is then driven over the guidewire in a retrograde fashion using a modified Seldinger technique. The guidewire is then removed after correct positioning of the stent, and the procedure repeated on the contralateral side.

**Results:** Over 30 cases were achieved successfully with this technique. Uretral injury was not recorded and urinary was not reported. No symptoms irritation were noticed. Finally our preliminary data showed similarity in all three outcomes (Cancer control, urinary continence and sexual potency) with the rest of our cohort.

**Conclusion:** The added steps of in situ robotic-assisted bilateral ureteral stenting take less than 10 minutes to perform and serve as valuable landmarks during anastomosis construction. We hope other robotic surgeons will also find this technique a useful and effective addition to their operative repertoire for dealing with patients with large median lobes.

#### VS14-06 PRESERVATION OF ACCESSORY PUDENDAL ARTERY IN ROBOT ASSISTED LAPAROSCOPIC RADICAL PROSTATECTOMY OPERATION

A. Kural, F. Atug, I. Tufek, H. Akpinar, S. Aksit—Turkey

**Background:** The introduction of minimally invasive surgery for radical retropubic prostatectomy has increased the detection and hence incidence of accessory pudendal arteries. Their preservation depends on their size and location. In this video, we present the identification, dissection and preservation technique of APAs in two different patients during robot assisted laparoscopic radical prostatectomy (RALP).

**Methods:** First patient was 65 year old patient with prostate adenocarcinoma. The patient underwent RALP operation with bilateral nerve sparing procedure. During the dissection of left side a lateral prostatic APA running over the endopelvic fascia was seen. The APA was preserved by meticulous dissection. The second patient was 62 year old patient with prostate adenocarcinoma with a preoperative IIEF score of 25. The preoperative MRI angiography revealed complete obstruction of right pudendal artery. The patient underwent RALP operation with bilateral nerve sparing procedure. Due to MRI findings we carefully dissected right side and an apical APA was detected on right side with meticulous dissection.

**Results:** APAs were preserved successfully in both patients. The APA was carefully protected during the dorsal venous plexus suturing and anastomosis of urethra. Surgical margins were negative in both patients. The first patient had spontaneous erection after 6 weeks surgery. And also the second patient achieved successful intercourse.

**Conclusion:** APAs can be easily identified during RALP. Moreover, their preservation is feasible in RALP with the help of magnified 3D vision of surgical field, the pneumoperitoneum which minimizes venous bleeding hence provides a clear vision. Developing a strategic approach to robotic dissection allows APAs to be successfully preserved in most cases. It is very well known that postoperative erectile dysfunction does not depend only to the preservation of the nerves of the penis, but also to the preservation of the arteries supplying blood to the penis. On this basis, we think that APAs should be explored and preserved as much as possible in all cases.

#### VS14-07 TENSION- AND ENERGY-FREE ROBOTIC ASSISTED LAPAROSCOPIC RADICAL PROSTATECTOMY: APPLICATION DURING THE LEARNING CURVE

F. Annino, A. Beato, C. De carne, S. Micali, S. De stefani, G. Bianchi

**Background:** To describe our technique of application of the Tension Energy free dissection of the neurovascular bundles during Robotic Assisted Laparoscopic Radical Prostatectomy (RALP) during the learning curve.

**Methods:** Since october 2007 to june 2009 we performed 98 RALP. We analyzed the first 58 patients in order to observe the application of the technique during the learning curve. Patients selected for the Tension-free procedure had PSA < 10 ng/ml, Gleason score  $\leq 7(3+4)$ , clinical stage T1c. The Tension Energy free dissection has been first described by the group of Richard Gaston on European Urology september 2007 (Eur Urol 2007;52:687–695). The aim of this technique is to dissect the vesicles-prostatic junction before to mobilize the seminal vesicles and the bladder neck in order to avoid damage to the nerves at this level. We use a four arms da Vinci system. The procedure consist in a transperitoneal approach. The bladder neck is dissected from the prostate base and preserved. The endopelvic fascia is incised at 2 and 10 o'clock on the anterior surface of the prostate. The dissection of the neurovascular bundles begin by an antero-lateral approach at the base of the prostate until the implant of the seminal vesicles is reached. The vascular prostatic pedicles are controlled with hemostatic clips and the Denonvillier fascia is identified lateral to the bladder neck. The bladder neck is divided and the seminal vesicles are dissected once their junction to the prostate base is freed from the bundles. The procedure continue with the dissection of the apex, a sharp transection of the Santorini plexus and urethra. Hemostasis of the dorsal vein complex is achieved and the urethro-vesical anastomosis is obtained by running suture.

**Results:** All the procedures were completed robotically. Mean operative time (console time) was 198 min (range 135–380). The tension- energy-free dissection was obtained in 56% of cases. The nerve sparing has been achieved in 57 cases: bilateral in 72.8% and mono-lateral in 25.4% of cases. The bladder neck was preserved in the 90% of cases. We achieved the tension free dissection after the first 10 cases of pure antegrade dissection.

**Conclusion:** The dissection of the implant of the seminal vesicles before bladder neck division and before the seminal vesicles dis-

section is feasible and it allows to reproduce a Tension-free dissection even during the learning curve. Further randomized studies, on larger series, could define the functional outcome of this kind of dissection of the neurovascular bundles.

#### **VS14-08** TECHNIQUE OF ROBOTIC- ASSISTED LAPAROSCOPIC SIMPLE PROSTATECTOMY (VIDEO)

V. Patel, R. Ferreira Coelho, K. J Palmer, S. Chauhan, M. B Patel—US

**Background:** The aim of this video is to describe our technique of Robotic-Assisted Laparoscopic Simple Prostatectomy (RASP) for treatment of lower urinary tract symptoms (LUTS) caused by large prostatic adenomas.

**Methods:** A 6 port transperitoneal approach was used. The port configuration was similar to the pattern used during our technique of Robotic-Assisted Radical Prostatectomy (RARP). The space of Retzius was accessed and the anterior prostate capsule was dissected from the overlying fatty tissue. A horizontal incision was made in the bladder, proximal to the transition between the prostate and the bladder neck. After that, a horizontal incision was made in the mucosa overlying the prostate and the posterior plane between the adenoma and the prostatic capsule was dissected. The subcapsular plane was completely dissected using cautery and blunt dissection. The same plane was dissected anteriorly and laterally and the adenoma was entirely removed. A 24 Fr foley catheter was inserted and the anterior incision in the bladder neck was closed using running absorbable suture. A JP drain was inserted.

**Results:** RASP was performed in 60 years-old male patient complaining of LUTS for 5 years. Preoperative International Prostate Symptom Score was 29. Prostate size on transrectal ultrasound was 250 gm and transrectal prostate biopsy showed absence of cancer. The operative time was 100 minutes, estimated blood loss was <250 ml and the hospital stay time was 2 days. Specimen weight on pathological examination was 220 gm. No blood transfusion

was necessary. Postoperative period was uneventful. Foley catheter was removed on postoperative day 4 with improvement of the baseline symptoms (postoperative AUA-IPSS = 5).

**Conclusion:** RASP is a safe and feasible option in the management of LUTS caused by large prostatic adenomas

#### **VS14-09** ROBOT-ASSISTED EXCISION OF A MULLERIAN CYST WITH ANASTOMOSIS OF THE VAS DEFERENS TO THE SEMINAL VESICLE

R. Sotelo, R. De andrade, O. Carmona, J. Astigueta, O. Moreira—Venezuela

**Background:** Mullerian cyst of the vas deferens with ipsilateral renal agenesis is a rare condition. The choice of treatment depends on symptoms, which in turn are related to cyst size and location. Only two cases of robotic excision of seminal vesical cysts have been reported, with successful relief of symptoms and minimal morbidity. We report a case of symptomatic mullerian cyst of the vas deferens and ipsilateral renal agenesis that was successfully managed by surgical excision.

**Methods:** A 19 year old man presented with lower urinary tract irritative symptoms. Ultrasonography and abdominopelvic magnetic resonance imaging (MRI) showed a 4 cm right pelvis cystic mass between the bladder and rectum that was associated with an absent right kidney. Semen analysis revealed oligospermia. We use 3 arms, and one additional port suction, total 4 incision. Transperitoneal approach right mullerian cyst of the vas deferens was resected.

**Results:** Operative time was 90 minutes. The procedure was technically accessible and minimal blood loss being less than 100 cc and a drain was placed for 48 hours. The patient was discharged the next day and he is currently asymptomatic.

**Conclusion:** Minimally invasive robotic-assisted excision of a mullerian cyst of the vas deferens is technically feasible, and should be considered for the treatment of this rare condition.

## VS15: RECONSTRUCTIVE LAPAROSCOPY 2

#### **VS15-01** ROBOTIC URETEROILEAL ANASTOMOSIS REVISION

R. Abaza—USA

**Background:** We present the application of robotic surgery in the correction of a complication after robotic cystectomy with conduit diversion. A ureteroileal anastomotic stricture was treated robotically with video illustration of the technique.

**Methods:** A 54 YO male underwent robotic radical cystectomy with ileal conduit urinary diversion fashioned extracorporeally through the 3 inch specimen extraction site. Five months later, he presented with pyelonephritis and left hydronephrosis. A percutaneous nephrostomy tube was placed and used to identify a short but complete obstruction. A robotic ureteroileal anastomosis revision was planned.

**Results:** A robotic ureteroileal anastomosis revision was performed through 3 robotic ports (12 mm, 8 mm, 8 mm) at a new site on the conduit using interrupted sutures with bowel mucosal

eversion. A stent was placed and removed after 3 weeks. The operative time was 178 minutes, and the patient was discharged on the first postoperative day. A nephrostogram 2 weeks after the stent was removed revealed patency, and the nephrostomy tube was removed. There has been no recurrence of stricture after six months.

**Conclusion:** We report a robotic ureteroileal anastomosis revision performed successfully for a ureteroileal stricture after robotic cystectomy with urinary diversion. Longer followup will be necessary to definitively assess success.

#### **VS15-02** ROBOTIC NEPHROURECTOMY WITH PARTIAL DUODENECTOMY FOR INVASIVE URETERAL TUMOR

R. Abaza—USA

**Background:** As with all minimally-invasive procedures, conversion to open surgery can be necessary when unexpected intraoperative findings are encountered in robotic surgery, but



robotic instrumentation may allow even complex situations to be successfully managed. We report a case of successful completion of right robotic nephroureterectomy for upper tract TCC with invasion of the duodenum.

**Methods:** A 70 year old male with a history of open right partial ureterectomy for a ureteral tumor one year previously was treated with adjuvant chemotherapy. He then presented to our institution after a CT scan revealed a mass within the renal pelvis and around the proximal ureter with hydronephrosis. A nephroureterectomy was recommended. A four-port robotic approach was used. After reflection of the colon, the third portion of the duodenum was found to be adherent to a mass extrinsic to the ureter. The involved portion of the duodenal wall was resected. The defect was then closed in two layers. The remainder of the ureter was then excised from the bladder intact along with the kidney.

**Results:** A nasogastric tube was left overnight and clear liquids then begun. A regular diet was initiated and the patient discharged on the second postoperative day. Pathology revealed high grade TCC in the renal pelvis and the proximal ureter invading the duodenal serosa. All surgical margins were free of cancer, but unfortunately; the patient was found to have nodal involvement.

**Conclusion:** A robotic approach allowed for successful treatment of a ureteral TCC invading the duodenum. While this extent of disease might otherwise have required open conversion, this initial such report was successfully completed in minimally-invasive fashion.

### VS15-03 ROBOTIC URETERAL MITROFANOFF: A MINIMALLY INVASIVE ALTERNATIVE TO TRADITIONAL APPENDICOVESICOSTOMY

E. Kheterpal, M. Patel, R. Laungani, N. Pokala, M. Menon, E. Jack

**Background:** We demonstrate a robotic technique for intracorporeal tapered ureteral reimplantation, transureteroureterostomy and ureteral catheterizable stoma in a pediatric patient with end-stage renal disease undergoing peritoneal dialysis.

**Methods:** A 10-year-old male with Hinman syndrome, severe bilateral vesicoureteral reflux, end-stage renal disease, peritoneal dialysis, and inability to void was scheduled for a Mitrofanoff appendicovesicostomy. However, the appendix was too short, and instead he underwent a robotic ureteral Mitrofanoff and transureteroureterostomy. Given the patient's severe bilateral reflux, we performed an extravesical excisional ureteral tapering without dividing the ureterovesical junction and performed a detrusorrhaphy to create a nonrefluxing system. The ureter was divided at the level of the iliac vessels and was brought out through the umbilicus as a continent catheterizable stoma. A right-to-left transureteroureterostomy was performed after the proximal transected ureter was brought posterior to the sigmoid and to the left ureter. The anastomosis was unstented.

**Results:** Total operative time was 270 minutes. Estimated blood loss was 30 cc. Peritoneal dialysis was resumed on postoperative day 2. His hospital course was prolonged secondary to pneumonia and he was discharged home on postoperative day 7. At 3 months, the patient was dry and was performing intermittent catheterization every 4 hours. He is scheduled for living-related renal transplantation.

**Conclusion:** We demonstrate the technical feasibility of a robotic-assisted non-refluxing tapered ureteral Mitrofanoff and transureteroureterostomy as an alternative to appendicovesicostomy.

### VS15-04 LAPARO-ENDOSCOPIC SINGLE SITE (LESS) LAPAROSCOPIC SURGERY IN RE-OPERATIVE PYELOPLASTY

S. Permpongkosol, C. Leenanupunth

**Background:** We assessed the feasibility of adult redo- laparoscopic pyeloplasty via transumbilical single-port access in a patient with ureteropelvic junction obstruction.

**Methods:** A 39 year old female presented with urinary tract infection and had a history of laparoscopic transmesenteric pyeloplasty one year ago. Her intravenous pyelography demonstrated Ureteropelvic junction obstruction which was confirmed on diuretic renal nuclear scintigraphy. She underwent re-operative single port transumbilical pyeloplasty using the R-Port system (Advanced Surgical Concepts, Wicklow, Ireland), inserted through a transumbilical incision. Specialized bent instruments and Endostich were used in addition to standard laparoscopic instrumentation. A rigid 5 mm 30-degree digital laparoscope with integrated camera head was used and Starion for dissection and to stop bleeding.

**Results:** Redoing LESS laparoscopic pyeloplasty, with no extra-umbilical skin incisions, was technically successful. The total operative time was 5.30 hours; the estimated blood loss was 100 mL. However, the Endostich was accidentally broken and needed an additional port for intracorporeal suturing. There were no complications during or after surgery. To date, the patient has remained free of symptoms for ten months postoperatively and no urinary tract infection. Intravenous pyeloplasty confirmed that there was no obstruction at UPJ junction.

**Conclusion:** To Redo pyeloplasty by transumbilical LESS laparoscopic pyeloplasty is feasible. In experienced hands redo single port laparoscopic pyeloplasty can be performed safely with a success rate similar to that of open surgery, and it may provide faster recovery with decreased narcotic requirements and less morbidity.

### VS15-05 ROBOT-ASSISTED TAPERED URETERAL RE-IMPLANTATION FOR CONGENITAL MEGAURETER

A. Goh, R. Link—USA

**Background:** Robotic assistance has enabled a minimally invasive approach to increasingly complex reconstructive surgery of the genitourinary tract.

**Methods:** We present a case of a 51 year old male with a long-standing history of symptomatic congenital megaureter illustrating an approach for robot-assisted tapered ureteral reimplantation. For the procedure, the patient was placed in dorsal lithotomy position. The port setup for this reconstruction consisted of a 12 mm camera port at the umbilicus and two 8 mm robotic ports on the left each spaced 8 cm apart. An additional 8 mm robotic port was placed medially and inferiorly in the right lower quadrant to yield access to the distal left ureter and bladder. A 12 mm assistant port was placed in the right lateral abdomen for suction and retraction. Ureteral dissection, tapering, and non-refluxing reimplantation were all completed using robotic assistance.

**Results:** Total operative time was 262 minutes with an estimated blood loss of 150 ml. The patient's hospital course was uneventful with discharge on post-operative day 4 without a foley or drain. The ureteral stent was removed at 1 month post-operatively. A diuretic renal scan was performed at 5 months showing good preservation of renal function with rapid clearance of tracer on the

reconstructed side. The patient is currently pain-free without any symptoms.

**Conclusion:** We demonstrate a technique for robot-assisted tapered non-refluxing ureteral reimplantation for congenital mega-ureter. Robotic assistance provides a safe and effective approach for complex ureteral reconstruction while minimizing morbidity.

### VS15-06 ROBOT ASSISTED LAPAROSCOPIC PYELOPLASTY FOR RIGHT RENAL DOUBLE SYSTEM

F. Porpiglia, C. Fiori, R. Bertolo, I. Morra, R. Scarpa

**Background:** Laparoscopic pyeloplasty has gained in the last years more consensus thanks to its mini-invasiveness and its functional results comparable to those of traditional surgery. More recently the DaVinci® robot appeared useful in this type of procedure even if only few data with short follow-up is available in literature. We report the case of a patient with a right renal double system, and affected with ureteral joint disease of the inferior district treated with robot assisted laparoscopic pyeloplasty with a latero-lateral anastomosis of both systems.

**Methods:** (Operative technique): patient is placed with a 45° left lateral decubitus. After induction of pneumoperitoneum with a Verres needle, retroperitoneum is accessed by pushing down the posterior down at level of the right UPJ. Pelvis, joint ureters from both systems are progressively isolated. A longitudinal section of pelvis, UPJ and of the first tract of lumbar ureter and of proximal ureter of the superior system is performed. A latero-lateral suture of both hemisystems is performed with running Vicril 5/0 suture taking care in obtaining extraluminal knots. Once completed the posterior portion of anastomosis, a ureteral JJ stent is applied with an ascending technique and controlled by pneumocystoscopy. The anterior suture is then completed.

**Results:** Operative time was 150', blood loss was insignificant and no complication were registered. Post operative renography was normal.

**Conclusion:** Laparoscopy endorses a strategic role in the treatment of functional disease such as joint disease. Da Vinci robot makes suture easier and more precise in confront to traditional laparoscopy and appears in some particularly complexed situations just as this one irreplaceable.

### VS15-07 ROBOT ASSISTED DISTAL URETERECTOMY AND PSOAS HITCH FOR BENIGN AND MALIGNANT URETERAL DISEASE (THIS ABSTRACT IS ACCOMPANIED BY A VIDEO)

H. Atalah, C. Vincent, L. Su—USA

**Background:** Robotic surgery has expanded to address both upper and lower urinary tract pathology. Wristed robotic technology provides the ability to efficiently accomplish complex reconstructive urologic surgery. Herein we present two cases of distal ureterectomy, psoas hitch and ureteral reimplantation performed for benign and malignant ureteral disease respectively.

**Methods:** This video presentation provides step by step details on the technique of robot assisted distal ureterectomy, psoas hitch and ureteral reimplantation in two patients. Patient #1 is a 53 year old man with a 3 cm distal ureteral stricture arising from a history of an impacted 1.5 cm ureteral stone. This stricture has failed previous endoscopic management. Patient #2 is a healthy 83 year old man with a 1 cm distal ureteral tumor discovered during evaluation of a positive urine cytology. Ureteroscopic biopsy revealed a high grade transitional cell carcinoma with invasion into the lamina

propria. After extensive consultation and review of treatment options, both patients proceeded with robot assisted distal ureterectomy with psoas hitch reconstruction and reimplantation. A three armed robotic technique using the da Vinci S system was performed in both cases. The distal ureter was clipped and divided in patient #1 and a formal bladder cuff was excised in patient #2. Both underwent psoas hitch and tension free ureteral reimplantation.

**Results:** Operative time was 3.5 and 4.5 hours in patient #1 and #2 respectively. Both experienced minimal blood loss and no complications. Patient #1 was discharged on postoperative day 1 and patient #2 on day 2. Pathology revealed fibrosis in the first patient and carcinoma in situ with negative margins in the second patient. The ureteral stent was removed in both patients at 4 weeks with no complications and with preserved renal function.

**Conclusion:** Robotic surgery has expanded to address both upper and lower urinary tract pathology. Lower ureteral pathology, both benign and malignant, can be addressed successfully by robot assisted distal ureterectomy, psoas hitch and ureteral reimplantation with low morbidity.

### VS15-08 TRANSMESOCOLIC ROBOT-ASSISTED PYELOPLASTY

G. Bianchi, G. Pini, F. Annino, S. Micali, A. Beato, S. De stefani

**Background:** Robot-Assisted pyeloplasty results are comparable to those of open pyeloplasty, the standard option for ureteropelvic junction obstruction (UPJO) and it shows a less steep learning curve in comparison with laparoscopy. After 9 transperitoneal standard retrocolic procedure, the video shows our first approach with a transmesocolic robot-assisted left dismembered pyeloplasty.

**Methods:** Patient: 22 years old man with primary UPJO. Lombotomic position. Robot da Vinci® on the back side of patient. Verres pneumoperitoneum and 5 transperitoneal trocar (3 robotic and 2 laparoscopic for assistant). Exposition and incision of the left mesentero-colic space. Exposition and dissection of ureter. Identification and free dissection of the renal pelvis in order to obtain an adequate length to perform a tension free-repair. Transection of the renal pelvis above the UPJ. The redundant renal pelvis is transected and the UPJ is removed. Lateral ureter spatulation. Closure of the excess pyelotomy incision in running suture. Antegrade insertion of DJ stent. Anastomosis in multiple running 4/0 Monocryl suture.

**Results:** Operative time 115 minutes, blood loss <25 ml; catheter removal post operative day (pod) 1; drain removal in pod 2, discharge pod day 3; DJ removal after 20 days. At 2 month the patient is still asymptomatic and US shows absence of hydronephrosis.

**Conclusion:** The transmesocolic robot-assisted pyeloplasty is safe and feasible. The direct approach to the left UPJ provides a good operative field, lower bowel manipulation and decreasing in operative time. Above all, robotic system make easier reconstructive and suturing time and it raise surgeon capabilities to work in a narrow space as the transmesocolic window.

### VS15-09 VIDEOLAPAROSCOPIC CORRECTION OF RETRO-CAVA URETER

M. Baptistussi, E. Gewher, M. Morihisa

**Background:** 18-year-old patient with right lumbar pain since 12 years of age, undiagnosed. Underwent ultrasound exam, which showed proximal and right pyelocaliceal ureteral dilation. Excretory urography showed right pyelocaliceal dilation, with image suggesting a retro-cava ureter, confirmed by ct scan.

**Methods:** Subjected to videolaparoscopic surgery, where 3 punctures were made, two 5 mm and one 10 mm long. The ureter was dissected above and below the retrocava site, totally released, with a retrocava segment being cut, repositioning the ureter anterior to the vena cava and suturing with continuous Vicryl 4.0 suture. Prior to this, a double pigtail antegrade catheter was placed.

**Results:** Surgery time: 1 h 30 min/bleeding –30 mL.

**Conclusion:** Discharged on second day PO/Suction drain removed on first day PO. Catheter left in place for 6 weeks; at 3 months, an excretory urography control showed normal kidney and ureter.

### VS15-10 ROBOTIC ASSISTED LAPAROSCOPIC RESECTION OF A PELVIC MASS INVADING THE LEFT DISTAL URETER

F. Atug, A. Kural, H. Akpinar, S. Aksit, I. Tufek—Turkey

**Background:** Robot assisted laparoscopic approach for complex urologic oncology surgery is evolving however its' role has not been established yet. Here, we present our video demonstrating robot assisted laparoscopic distal ureterectomy with ureteroneocystostomy.

**Methods:** This patient is a 40 years old woman who presented with left flank pain. She was found to have left distal ureteral obstruction

and mild left hydronephrosis. Abdominopelvic CT examination revealed a mass surrounding the distal left ureter. The patient underwent robot assisted laparoscopic resection of left distal ureter together with pelvic mass and subsequent ureteroneocystostomy.

**Results:** A four arm approach was preferred. Ports were configured in a manner similar to robotic pelvic operations. The left ureter was identified and isolated above the obstructed area. The dissection was continued down the ureter and once the mass was identified it was dissected out from the surrounding structures. The distal part of the left ureter was excised together with the mass. After mobilizing the bladder and spatulating the ureter, anastomotic sutures were placed between the ureter and the bladder. A double-J ureteral stent was placed before the completion of anastomosis. The total operation time was 180 min and the console time was 120 min. Estimated blood loss was 300 cc and the length of stay was 3 days. The final pathology report showed adenocarcinoma with unknown origin.

**Conclusion:** This case demonstrates that the robotic approach facilitates oncologic and reconstructive surgeries in lower urinary tract diseases.

## VS16: ROBOTICS—BLADDER

### VS16-01 ROBOT-ASSISTED LAPAROSCOPIC RADICAL CYSTOPROSTATECTOMY: TOTALLY INTRACORPOREAL STUDER NEOBLADDER

N. Pardalidis, N. Andriopoulos, E. Kosmaoglou—Greece

**Background:** To describe da Vinci laparoscopic radical cystoprostatectomy and intracorporeal ileal Studer neobladder formation.

**Methods:** We performed robot-assisted laparoscopic radical cystoprostatectomies and intracorporeal construction of orthotopic Studer neobladder in 5 patients.

**Results:** The mean operative time was 7.5 hours. The mean blood loss was 140 ml. There were no intraoperative or postoperative complications and the patients hospital stay was 5 days. Good oncological and functional results were encountered at early follow up.

**Conclusion:** Our initial experience with robotic-assisted laparoscopic radical cystoprostatectomy appears to be favorable with acceptable operative, pathologic and short-term clinical outcomes.

### VS16-02 EXTRAPERITONEAL RETROGRADE ROBOT ASSISTED RADICAL PROSTATECTOMY: DUPLICATION OF THE OPEN GOLD STANDARD

M. Lux, J. Joseph—USA

**Background:** The open radical retropubic prostatectomy, often referred to as the gold standard, is generally performed in the extraperitoneal space, using a retrograde approach. The majority of surgeons performing robot assisted radical prostatectomy however,

use a transperitoneal antegrade approach. Herein, we present a robot assisted radical prostatectomy performed extraperitoneally, in a retrograde manner.

**Methods:** The extraperitoneal space is created using the Space-maker Plus balloon dilating system. Once the space is adequately developed, a total of six trocars are placed in the extraperitoneal space. A 4-arm Davinci system is used, with two additional trocars placed for assistance purposes. The endopelvic fascia is first taken down, followed by ligation of the dorsal venous complex (DVC). The DVC and urethra are transected freeing the prostatic apex. The prostatic pedicle dissection is carried out in a cephalad direction, followed by bladder neck and seminal vesicle dissection.

**Results:** All procedural steps were carried out successfully. The patient had an uneventful postoperative course and was discharged home the next day.

**Conclusion:** The extraperitoneal retrograde robot assisted radical prostatectomy duplicates the gold standard open retropubic radical prostatectomy.

### VS16-03 ROBOTIC-ASSISTED TOTAL-INTRACORPOREAL LAPAROSCOPIC RADICAL CYSTECTOMY AND ILEAL CONDUIT URINARY DIVERSION

G. Wu, D. Golijanin, E. Singer, H. Rashid—USA

**Background:** Robotic-assisted laparoscopic radical cystectomy has been reported in many small series. Ileal conduit diversion following the cystectomy through a mini laparotomy was performed by most surgeons. However, when longer distal ureteral segments need to be removed in order to obtain negative margins,

or patients are obese, a “mini laparotomy” is not practical and a “medium” sized laparotomy is often required for ileal conduit construction. In this video, we present our strategy for robotic-assisted total-intracorporeal laparoscopic radical cystoprostatectomy and ileal conduit diversion.

**Methods:** A total of 6 ports were placed, including one 12-mm camera port, three 8-mm robotic arm ports, one 5-mm suction port and one 15-mm accessory port. A 15-cm ileal conduit was harvested and ileoileal anastomosis performed first laparoscopically using staplers. The da Vinci Surgical Robotic System S was then docked for the rest of the procedure. Cystectomy and extended bilateral pelvic lymphadenectomy up to the aortic bifurcation was carried out. Stents were delivered via a laparoscopic suction tip passed through the ileal conduit then placed into the ureters followed by Bricker-type ureteroileal anastomoses. The distal ileal conduit was then pulled through. The specimen was then extracted through an enlarged umbilical trocar site for male and through the vagina for female patients.

**Results:** From January 2007 to June 2009, a total of 49 cases (42 male and 7 female) were performed using the above strategy, including patients with a BMI > 35 and requiring >10-cm distal ureterectomy. No case was converted to an extracorporeal ileal conduit diversion. Operative time ranged from 250–468 minutes (median 338 minutes) with the smallest specimen extraction incision measuring 4 cm. Hospital stay ranged from 4–32 days (median 7 days). No patient developed a urine leak.

**Conclusion:** The procedure described in this video provides a true minimally-invasive approach and avoids “medium” laparotomy for ileal conduit construction. This approach is feasible for selected patients undergoing radical cystectomy and ileal conduit diversion.

#### VS16-04 ROBOT ASSISTED ANTERIOR EXENTERATION FOR INVASIVE BLADDER CANCER IN A FEMALE PATIENT

M. Sangalli, G. De naeyer, P. Schatteman, P. Carpentier, E. Fonteyne, A. Mottrie

**Background:** To describe our technique of total intracorporeal robotic-assisted radical cystectomy (RARC) in female patients.

**Methods:** The procedure was performed using a 4-arm DaVinci-S System (DVS). Under general anaesthesia at first a 12 mm port is placed 3–5 cm above the umbilicus, two 8 mm ports are placed on the umbilicus level on the pararectal line bilaterally 8 cm from the camera, a 5 mm port at the right side between the optic and the 8 mm port, a 12 mm port 3 cm up to the iliac crest on the right side and an extra 8 mm port symmetrically on the left side. The patient is placed in a steep trendelenburg position. The procedure is performed with Monopolar Hot Shears<sup>TM</sup>, Gyros<sup>TM</sup> and the ProGrasp Forceps<sup>TM</sup> on the 4th arm. In the video we describe our technique of robotic assisted radical cystectomy performed in a female patient. The urinary diversion is performed intracorporeally and the specimen is packed in a large Endocatch bag<sup>®</sup> and is removed through the vagina.

**Results:** Up-to-date, we performed robotic cystectomy in 56 patients, 7 of them being female. No major complications occurred. Oncologically, all margins were negative.

**Conclusion:** Our experience demonstrates that RARC in female patients is safe and reproducible. It can be performed totally intracorporeal and we are convinced that the DVS helps to decrease the steep learning curve of traditional laparoscopic radical cystectomy.

#### VS16-05 RARE INDICATIONS OF ROBOTIC SURGERY SYSTEM IN UROLOGY

S. Mattia Nicola, G. De naeyer, P. Schatteman, P. Carpentier, E. Fonteyne, A. Mottrie

**Background:** During the past years the numbers of indications for robotic surgery in urology has dramatically increased. In this video we describe some rare indications for robotic surgery in urology that can be performed in a minimally invasive way. Due to more degrees of freedom, three-dimensional visualisation and elimination of physiologic tremors, the Da Vinci Robotic Surgery System (DRSS), in our experience, has found also applications in rare indications, with many advantages over traditional open or laparoscopic surgery.

**Methods:** In this video three cases are shown: a young female patient complex cyst (11 cm diameter) at the level of right adrenal gland dissected with a “non-touch” technique, a female patient with a previous transvaginal prolapse surgery and erosion of the bladder by the mesh put transveically and a man with a solitary metastasis of colic cancer between rectum and prostate seminal vesicles after previous right emicolectomy and robotic partial nephrectomy in a solitary kidney.

**Results:** All procedures are performed in a minimally invasive way without any intraoperative complications and with excellent results in terms functional outcomes.

**Conclusion:** These cases show that DRSS, is a transformation of traditional surgery in a minimally invasive fashion but more degrees of freedom, three-dimensional visualisation, excellent ergonomic movement of the instruments and stabilization of surgical movements allows a very meticulous and precise handling over traditional open and laparoscopy surgery.

#### VS16-06 ROBOT-ASSISTED LAPAROSCOPIC INTRACORPOREAL ILEAL CONDUIT

S. Mattia Nicola, G. De naeyer, P. Schatteman, P. Carpentier, E. Fonteyne, A. Mottrie

**Background:** To describe our technique of total intracorporeal robotic-assisted ileal conduit urinary diversion after cystectomy utilizing the Da Vinci Robotic Surgical System (DRSS).

**Methods:** After the incision of the posterior peritoneum, both ureters are identified and freed up to the crossing with the iliac vessels. The left ureter is crossed to the right side under the meso of the sigmoid. A 12–15 cm segment of small bowel is selected about 15 cm proximal to the ileocaecal valve and fixed up to the abdominal wall with three Vicryl stitches. With a 30° laparoscope brought in through the assistant trocar, its mesentery is illuminated to observe the mesenteric vessels and incised over ca 5 cm. Vessels are coagulated with the Gyros<sup>®</sup>. The EndoGIA<sup>®</sup> is used to cut and to re-establish bowel continuity by side-to-side with a mechanical anastomosis. The ureters are spatulated and Wallace ileal-ureteral anastomosis is performed using Monocryl 4/0. The two 8F feeding tubes are brought through the ileal conduit and introduced into the ureters. The Bricker diversion is brought out through the right arm port site.

**Results:** With the DRSS the operation can be performed intracorporeally without any intraoperative complications.

**Conclusion:** The total intracorporeal ileal conduit is a safe a feasible alternative procedure to the open diversion and DRSS gives us the possibility to overcome the limitations of classic laparoscopy with satisfactory functional and anesthetic outcomes.

**VS16-07 ROBOTIC ASSISTED EXTENDED LYMPH NODE DISSECTION**

R. Goel, C. Sebastien, W. White, G. Haber, S. Campbell, J. Kaouk—Ohio

**Background:** Minimally invasive approaches to urothelial carcinoma of the bladder is gaining momentum. Early results indicate reduced blood loss, pain and shortened convalescence. The extent of lymphadenectomy is crucial for both prognostic and therapeutic variables. The robotic application offers a new paradigm in the treatment of bladder cancer. Its ability to safely and effectively perform an extended lymphadenectomy has been scrutinized. Here we present a case of a robotic assisted extended lymph node dissection for urothelial carcinoma of the bladder.

**Methods:** A 70 year old gentleman with refractory T1 high grade urothelial carcinoma presented for definitive treatment. Pre-operative evaluation reveals no evidence of locally advanced or disseminated disease. A robotic assisted radical cystoprostatectomy was performed followed by lymphadenectomy as shown.

**Results:** A total of 26 lymph nodes were successfully cleared in the patient. The lymph node dissection was carried to the level of the inferior mesenteric artery thereby skeletonizing the external, internal, common iliac arteries and aorta. Presacral nodal tissue were also removed with robotic assistance. Estimated blood loss during robotic lymph adenectomy was 200 cc, with operative time of 90 minutes.

**Conclusion:** Robotic assistend extended lymph node dissection for urothelial carcinoma of the bladder is safe and effective in select patients. Operative time and blood loss are minimal while offering extensive clearance of nodal tissue following extirprative surgery. Proper patient selection for any minimally invasive approach to urothelial carcinoma is paramount.

**VS16-08 ROBOTIC-ASSISTED LAPAROSCOPIC EXTENDED LYMPH NODE DISSECTION FOR BLADDER CANCER**

A. George, M. Atalla, A. Srinivasan, M. Vira, L. Richstone—USA

**Background:** Radical cystectomy with pelvic lymph node dissection (LND) is the standard of care for muscle-invasive urothelial carcinoma of the bladder. Node dissection has been demonstrated to be feasible via laparoscopic techniques. Some studies have suggested value to extended lymph node dissections and associated number of lymph nodes retrieved. Eleven patients underwent robot-assisted radical cystectomy with LND, 1 of which had an extended LND. We demonstrate that robot-assisted extended pelvic lymph node dissection is a feasible technique, and increases node yield at the time of pathologic evaluation.

**Methods:** Our patient was a 46 year-old male diagnosed with muscle-invasive urothelial carcinoma of the bladder. Robotic-assisted extended lymph node dissection was completed. A six-port, transperitoneal approach was used with the da Vinci Surgical System (Intuitive Surgical; Sunnyvale, CA, USA) to perform the robotic-assisted radical cystectomy and LND. LND was completed proximally up to the aortic bifurcation, posteriorly to the hypogastric vessels, and laterally to the genitofemoral nerve. Right and left lymph node packets were sent for pathologic evaluation to determine node yield.

**Results:** The mean number of nodes retrieved during robotic-assisted LND at our institution was 14, with a range of 10–23 nodes. The patient underwent a robotic-assisted radical cystectomy with orthotopic neobladder. Operative time was 48 minutes for the LND

portion of the procedure. Postoperative course and 30-day followup were uneventful. Pathology revealed carcinoma in-situ of the bladder with a node count of 19, negative for urothelial carcinoma.

**Conclusion:** Robotic-assisted extended lymph node dissection is a feasible technique and may increase node yield for pelvic LND. Additional studies are needed to determine the ideal node count during LND to impact survival and further evaluate this technique.

**VS16-09 A TECHNIQUE FOR INTRACORPOREAL BOWEL HARVESTING AND STAPLED ANASTOMOSIS FOR URINARY DIVERSION AFTER CYSTECTOMY**

J. Montgomery, A. Weizer—USA

**Background:** Robotic-assisted laparoscopic cystectomy is being performed more commonly as urologists gain robotic experience. Bowel harvesting and reanastomosis are major obstacles to intracorporeal urinary diversion. We demonstrate a technique for intracorporeal bowel harvesting and stapled enteroenterostomy that can facilitate progress toward intracorporeal urinary diversion after robotic cystectomy.

**Methods:** After completing robotic cystectomy, the robot is undocked, the patient is taken out of the Trendelenberg position and the robot is redocked. The terminal ileum is identified. 15 cm from the terminal ileum, the distal aspect of the proposed ileal loop is marked with a stay suture. A 15 cm length of small bowel is measured, and a stay suture is placed at the proximal end of the ileal loop. A third stay suture is placed in the center of the loop. These 3 stay sutures are then brought through the anterior abdominal wall with a Carter-Thomason device, fixing the bowel in place. The proximal and distal loop is transected and mesenteric windows are made with a 60 mm laparoscopic stapler. Bowel continuity is then re-established with a stapled side-to-side enteroenterostomy using 2 60 mm laparoscopic staple loads. Urinary diversion is then completed.

**Results:** In this representative case, robotic cystoprostatectomy, pelvic lymph node dissection, bowel harvest and stapled enteroenterostomy were completed followed by an open ileal loop urinary diversion. Our operative time was 610 minutes and blood loss was 1000 cc. The patient had return of bowel function on post-operative day 3 and was discharged home on post-operative day 7.

**Conclusion:** Intracorporeal bowel harvest and stapled enteroenterostomy can be performed safely after robotic cystectomy. Using this simple yet effective technique for managing the small bowel will facilitate the progression toward performing intracorporeal urinary diversions.

**VS16-10 ROBOTIC ASSISTED RADICAL CYSTECTOMY**

R. Goel, S. Crouzet, W. White, G. Haber, J. Kaouk

**Background:** Radical cystectomy for muscle invasive urothelial carcinoma of the bladder remains the gold standard therapeutic option. However, open technique can be associated with significant perioperative morbidity. New minimally invasive procedures are evolving to provide sound oncological outcomes while minimizing postoperative sequelae. Use of the robotic platform has improved laparoscopic ergonomics during various challenging laparoscopic procedures. Its application to radical cystectomy is highlighted here in this video.

**Methods:** A 70 year old male with refractory T1 high grade urothelial carcinoma who failed BCG was selected to undergo radical cystectomy, bilateral pelvic lymphadenopathy and urinary diver-

sion. Preoperative investigations reveal no evidence of locally advanced or metastatic disease. Upon gaining intra-abdominal access and patient in steep Trendelenburg, a 5-port configuration was utilized for the cystectomy. Key steps of the procedure are highlighted in the video.

**Results:** Time to complete the radical cystectomy was 1 hour and 30 minutes. Estimated blood loss was 200 cc. The entire procedure was performed robotically without complication or conversion to an open technique. Following cystectomy, an extended lymph node dissection was completed followed by urinary diversion in the form of an ileal conduit via a mini-laparotomy incision. Postoperatively, the patient was ambulating on POD#1, tolerating a full

diet on POD#3 and was eventually discharged on POD#5. Pathology confirmed his preoperative diagnosis of T1 high grade urothelial carcinoma. Ureteral and urethral margins for urothelial carcinoma were negative. The prostate contained foci of high grade pin and all lymph nodes removed during surgery were negative.

**Conclusion:** Robotic assisted radical cystectomy in select patients can offer sound oncological outcomes while minimizing perioperative morbidity. A minimally invasive approach can minimize blood loss, expedite early ambulation and offer quicker return of bowel function. Proper patient selection is paramount when a minimally invasive approach is considered.

## VS17: LAPAROSCOPY—UROLITHIASIS

### VS17-01 ROBOTIC PYELOPLASTY WITH PYEOLITHOTOMY

R. Brandina, M. Lee, A. Berger, J. Kaouk, A. Monish, R. Stein

**Background:** To present a combined robotic approach in a patient with UPJ obstruction and multiple kidney stones.

**Methods:** In this video we demonstrate pyeloplasty with pyelolithotomy in a 69 yo female who presented with urosepsis. A CT scan showed severe UPJ obstruction bilaterally with greater than 50 renal stones in each collecting system (Figure 1). A staged robotic pyeloplasty with pyelolithotomy was performed with the right side demonstrated in this video. Intraoperative flexible nephroscopy was also used to remove any remaining stones.

**Results:** Total operative time was 4 hours 20 minutes and estimated blood loss was 50ml. Approximately 55 stones were extracted from the right side. Stones were composed largely of calcium oxalate monohydrate and dihydrate. Final pathology of the UPJ revealed moderate acute and chronic inflammation.

**Conclusion:** Use of the Da Vinci robotic system for pyeloplasty with pyelolithotomy provides optimal conditions for complete pelvic inspection and stone collection. A concomitant approach with flexible nephroscopy can be considered for patients with UPJ obstruction and an unusually large stone burden.

### VS17-02 LAPAROSCOPIC ANATROPHIC NEPHROLITHOTOMY FOR THE MANAGEMENT OF COMPLEX STAGHORN CALCULI

K. Kijvikai

**Background:** To date, most of staghorn calculi can be managed by endoscopic approaches, however, they may require several endoscopic sessions. Our patients with low socioeconomic setting need single operation for their stone management. We demonstrate the efficacy and safety of a laparoscopic approach for complex staghorn renal calculi.

**Methods:** Laparoscopic transperitoneal anatomic nephrolithotomy was performed by duplicate open surgical technique in two patients with large staghorn renal stones unsuitable for single session percutaneous nephrolithotomy. Both the renal artery and vein were clamped, using a laparoscopic Satinski's clamp. Renal hypothermia was performed with freezing 1-L bag of normal

saline through a laparoscopic suction/irrigation device. The stone was removed through a nephrotomy incision on the Brodel line. The segmental arteries and nephrotomy incision were closed with laparoscopic suturing.

**Results:** The mean patient age was 46 (40 and 52) years, and the cold ischemia and operative duration were 60 (55 and 65) and 250 (220 and 280) min, respectively. No blood transfusion was needed during or after surgery. All of the procedures were uneventful and there was no urine leakage after surgery. The renal scan demonstrated comparable renal function with the preoperative level. Only a 10-mm residual stone remained in one patient. Subsequently, it was treated with shock wave lithotripsy.

**Conclusion:** Laparoscopic anatomic nephrolithotomy is a feasible alternative for patients who have complex staghorn stones, with an acceptable stone-free rate. It can minimize the need for multiple endoscopic operations or the need for invasive open interventions. However, larger number of the patients and a longer follow-up are needed before this is considered as the preferred method in selected patients.

### VS17-03 REMOVAL OF DISRUPTED NEPHROSTOMY TUBE AND URETERAL STENT VIA PERCUTANEOUS WAY IS A SAFE AND EFFICIENT METHOD

A. Kural, S. Aksit, H. Akpinar, I. Tufek, F. Atug—Turkey

**Background:** In this video, we present removal of disrupted segments of a JJ ureteral stent and a nephrostomy tube via percutaneous way.

**Methods:** First patient was 54 years old male. He had nonfunctioning right kidney and 2 cm. left ureteropelvic junction stone causing complete obstruction. Left percutaneous nephrostomy tube was placed because of anuria, but removed later because of not working properly. He was referred to our clinic with a left double J stent. The stone was managed with retrograde intrarenal surgery (RIRS). During RIRS the tip of the disrupted nephrostomy tube was realized, but could not be pulled-out. Percutaneous access was used in another session and the disrupted tip was removed successfully. The second patient was a 47 years old female. She underwent right double J ureteral stenting due to hydronephrosis caused by a gynecological tumor. The double J stent was

removed, but the proximal part was missing. She was referred to our clinic. In plain X-ray film, missing part was below the 12th rib. During flexible ureterorenoscopy the stent was not seen in the collecting system. It was realized that the missing part was outside the renal parenchyma. A percutaneous intervention was planned. An upper calyceal access was performed in prone position. The missing part of the stent was removed nephroscopically.

**Results:** Both patients were discharged on the postoperative 1st day without any complication.

**Conclusion:** Percutaneous way to remove the missing part of the nephrostomy tubes or ureteral stents is a safe and efficient procedure.

#### VS17-04 LAPAROSCOPIC PYELOLITHOTOMY

G. Franco, P. Francesco, G. Antonio Maria, R. Ai Ling, S. Antonio—Italy

**Background:** The laparoscopic surgery of the kidney and of the urinary tract is in continuous evolution and the indications are becoming larger due to its safety and mini-invasivity in comparison with the “open” technique. The video shows “step by step” a laparoscopic pyelolithotomy of a 2.5 cm pelvic stone.

**Methods:** A patient 35 years old joined to our observation with ecographic and urographic diagnosis of right renal pelvic stone. In February 2008 the patient has been submitted to transperitoneal laparoscopic pyelolithotomy. Before the procedure we positioned an ureteral stent (Contour VL Variable Length Percuflex®, Boston Scientific). After a wide isolation and the incision of the renal pelvis, we proceeded to the removal of the stone. The following step was the suture of the pelvis with vicryl 3/0 stiches.

**Results:** The procedure lasted 175 minutes. Bleeding was irrelevant; after four days we transformed the Contour catheter in a double-J stent previous ascending pyelography and we removed the perianastomotic drain; in the 5th postoperative day the vesical catheter was removed. No perioperative complications were observed and the patient was discharged in the 6th post-operative day. The ureteral stent was removed 28 days after the surgical procedure. A 1 year follow-up didn't show hydronephrosis neither residual lithiasis.

**Conclusion:** The transperitoneal laparoscopic pyelolithotomy can be considered an effective and minimally invasive option for selected cases of renal lithiasis.

#### VS17-05 BACKSTOP™ TO PREVENT RETROPULSION DURING THE TREATMENT OF URETERAL CALCULI

A. Ray, K. Pace, R. Honey—Canada

**Background:** Stone retropulsion can be problematic during ureteroscopy, increasing surgical complexity and adversely affecting stone-free rates. Backstop™, a novel reverse thermosensitive polymer, has recently been approved for the prevention of stone retropulsion during intracorporeal lithotripsy. This compound exhibits an increase in viscosity over a narrow temperature range, converting from a liquid to a gel at 16–18°C. We demonstrate the use of this technology in three distinct clinical scenarios.

**Methods:** Backstop™ was used in 2 clinical cases including a patient with an obstructing distal ureteric stone and a dilated proximal ureter, as well as a patient with an impacted upper ureteral stone preventing passage of a guidewire. Finally, in a third case, we demonstrate the addition of methylene blue to the gel matrix, enhancing visibility of the polymer during stone manipulation.

**Results:** Semi-rigid ureteroscopy for the treatment of urolithiasis was successfully performed in both the upper and lower ureter using Backstop™ to prevent stone retropulsion. Despite prolonged pressurized irrigation, the polymer was persistent and effective. Backstop did not affect stone fragmentation with the Ho:YAG laser. Clearance of stones by ureteral peristalsis was enhanced due to formation of a coagulum. No complications from Backstop™ have been observed to date.

**Conclusion:** Backstop™ has clinical utility in the prevention of stone retropulsion during intracorporeal lithotripsy. In addition, the gel may act as a coagulum, enhancing peristaltic clearance of stone from the ureter. Further studies are warranted to validate these observations.

#### VS17-06 LAPAROSCOPIC PYELOPLASTY WITH RENAL STONES EXTRACTION WITH FLEXIBLE NEPHROSCOPY

R. Sanseverino, G. Napodano, O. Intilla, U. Di mauro, T. Realfonso

**Background:** We report a case of symptomatic Ureteropelvic Junction obstruction with secondary urinary lithiasis. The video shows a transperitoneal laparoscopic pyeloplasty combined with renal stones extraction with flexible nephroscopy.

**Methods:** A transperitoneal laparoscopic approach is used to perform a dismembered pyeloplasty according to the Anderson-Hynes technique. After incision of parietal peritoneum, the ureter and pelvis are isolated and then cut; the ureter is spatulated. A flexible nephroscope is inserted through 10/12 mm trocar into the pyelocaliceal cavity to explore it. Three caliceal stones are extracted with a tipless basket. We introduce a percutaneous 18G trocar needle to insert an hydrophilic guidewire into the ureter. A double J stent is placed running on the guidewire. Ureteropelvic anastomosis is performed with a continue 4/0 water-tight sutures. The procedure ends with positioning of drain.

**Results:** Operative time and blood loss were 180 minutes and 100 ml, respectively. No complications occurred. The patient was discharged after 6 days.

**Conclusion:** In selected cases, laparoscopic approach performing pyeloplasty combined with renal stones extraction seems to be a safe, feasible and time saving procedure.

#### VS17-07 LAPAROENDOSCOPIC SINGLE SITE PYELOLITHOTOMY IN HORSESHOE KIDNEY USING A HOMEMADE SINGLE-PORT DEVICE

D. Kim, Y. Yoon, S. Park, J. Lee, T. Lee, H. Park

**Background:** Traditionally Laparoendoscopic pyelolithotomy has been performed with three or four trocar sites. However, laparoendoscopic single site surgery is challenging surgical tool in Urology. Herein, we present our experience of laparoendoscopic single site pyelolithotomy in horseshoe kidney using a homemade single-port device.

**Methods:** 66 year old male known to have horseshoe kidney presented with initial painless gross hematuria. Pre-operative imaging revealed horseshoe kidney with 1.5 cm Rt. renal pelvis calculus. The procedure was carried out at the umbilicus as the port of entry by using homemade single-port device. On transperitoneal approach ureter was identified and traced proximally to renal pelvis. Pyelotomy was performed by scissors and stone was removed. Pyelotomy site was closed in continuous 4-0 Vicryl suture.

**Results:** Laparoendoscopic single site pyelolithotomy in horseshoe kidney using a homemade single-port device was successfully

performed. Operation duration was 205 minutes. Estimated blood loss was about 300 ml. Drain was removed at post operative day #2 and hospital stay was 3 days. Post operative intravenous pyelogram showed no dye leakage and the stent was removed on post operative day #14. There were no other postoperative complications.

**Conclusion:** Laparoendoscopic single site pyelolithotomy in horseshoe kidney is feasible, safe and minimal invasive treatment alternative to conventional laparoscopic pyelolithotomy. However, it can be technically challenging and adequate previous experience is necessary.

**VS17-08 LAPAROSCOPIC PYELOLITHOTOMY IN THE TREATMENT OF PELVIC CALCULI WITHIN A HORSESHOE KIDNEY**

A. Tepeler, A. Tefekli, T. Aktoz, M. Baykal, A. Muslumanoglu

**Background:** Large and complex calculi within horseshoe kidneys can usually be challenging. But transperitoneal laparoscopic approach may be feasible because of the anteriorly located renal pelvis. We present laparoscopic pyelolithotomy in the treatment of large pelvic calculi within horseshoe kidney.

**Methods:** A 52 year-old man was investigated for repeated left-flank pain. Renal ultrasonography showed large pelvic calculi within horseshoe kidney. Poor drainage of the renal pelvis and dilation was observed on the intravenous urography. A 5 cm left pelvic calculi and fused inferior poles by an isthmus was reported on computed tomography. A left-sided ureteric open end ureteral catheter was inserted under fluoroscopy just preceding the operation. Three laparoscopic ports were used for the transabdominal approach. The dilated pelvis and upper ureter were mobilized, than pelvis was dissected and the stone was extracted, placed in a laparoscopy sac. Pyelotomy was closed with a running 4-zero polydioxanone suture over the double-J stent.

**Results:** The operation time was 160 minutes. There were no intra/post operative complication. The patient had an uneventful recovery and was discharged on the third day. The analgesic requirement was minimally.

**Conclusion:** Laparoscopic pyelolithotomy can be beneficial in patients who are poorly compliant, have renal anomalies, and have a large single renal pelvic calculus and can be done safely and effectively with proper patient selection and adherence to standart laparoscopic surgical principles.

**VS17-09 TREATMENT OF URETERAL LITHIASIS IN PREGNANT WOMEN AND USE OF LONG-TERM CATHETER**

M. Baptistussi, E. Gewher, M. Morihisa

**Background:** The presence of a ureteral calculus during pregnancy is a risk situation for both mother and child, thus the need for correct diagnosis and proper treatment.

**Methods:** A 32-year-old pregnant patient, at 24 weeks of pregnancy, presented persistent colic for one week, recurring urinary infection and uterine contractions. Due to the emergency and possible birth labor, she was subjected to an ultrasound exam, which showed a 1 cm calculus in right middle ureter and ureterohydronephrosis. Surgery was indicated, which was carried out on an emergency basis.

**Results:** A transureteroscopic ureterolithotripsy was performed using a laser with 0.4-Joule energy and 7-Hertz frequency, with good fragmentation (Cook's Odyssey 30), leaving a Radiance catheter (Cook, Spencer) until the child's birth. The child was born in good health at term and there was no intercurrance. Seven similar additional cases were operated on with good results from October 2008 to June 2009.

**Conclusion:** During pregnancy, laser ureterolithotripsy is feasible and safe for both pregnant mothers and babies.

**VS17-10 ROBOTIC-ASSISTED PYELOLITHOTOMY**

R. Figenshau, T. Roytman, B. Benway, A. Desai, T. Christensen, M. Gardner

**Background:** Explore an alternative treatment option for a 30 year old man with 4 cm right, obstructing renal pelvis stone.

**Methods:** We discussed with the patient treatment options for the right renal stone which included ureteroscopy, percutaneous nephrolithotomy, ESWL and robotic-assisted pyelolithotomy. Pt elected to undergo robotic-assisted pyelolithotomy.

**Results:** The renal stone was extracted without difficulty in its entirety. Total operative time was 108 minutes. Estimated blood loss for the case was less than 50 mL. Patient was discharged home on post operative day #1.

**Conclusion:** Robotic-assisted pyelolithotomy is a safe and effective alternative for management of large renal pelvis stones in carefully selected patients. Operative time and blood loss are comparable or better to existing treatment options and no additional procedures or imaging are needed to render patient stone free.

**VS18: LAPAROSCOPY—KIDNEY**

**VS18-01 LAPAROSCOPIC DONOR NEPHRECTOMY: OUR PRELIMINARY RESULTS**

I. Yavascaoglu, H. Dogan, E. GURSOY, Y. KORDAN, H. VURUSKAN, B. OKTAY—Turkey

**Background:** To present preliminary results of laparoscopic donor nephrectomy.

**Methods:** The results of 18 laparoscopic donor nephrectomy cases those performed between March 2008 and April 2009 are pre-

sented. In all patients but one, left kidneys have been removed via transperitoneal approach. In all patients, hem-o-lok clips were used for the renal pedicle control.

**Results:** Nine patients were male and 9 were female with a mean age of 56 (42–73) years. All of the cases were successfully completed laparoscopically. Mean operative time was 155 ± 37 (90–240) minutes. Mean follow-up period was 6.3 (1–12) months. Mean warm-ischemia period was 175 ± 57 (90–320) seconds. Mean postoperative hospital stay was 2.8 ± 0.7 (2–4) days. No



intraoperative and postoperative complications occurred. Two transplantation patients were reoperated because of ureteral complications.

**Conclusion:** LDN is an effective and safe procedure with graft survival results comparable to open approach besides the well known advantages such as decreased postoperative pain, shorter hospital stay and recovery period and better esthetic appearance.

### VS18-02 BRIDGING TECHNIQUE FOR LESS DONOR NEPHRECTOMY

D. Puder, K. Ebrahimi, C. Tenggardjaja, F. Jellison, L. Nicolay, D. Baldwin—USA

**Background:** Despite the increase in living kidney donation since the advent of laparoscopic donor nephrectomy, many patients die while waiting to receive a transplant. To address this concern, laparoendoscopic single-site surgery (LESS) has been successfully applied to renal procurement in an attempt to further decrease the morbidity of kidney donation. However, concerns have been raised about the increased surgical complexity, longer learning curve, and increased warm ischemia times. The purpose of this video is to demonstrate a novel surgical technique for kidney procurement that allows the surgeon to develop experience with single incision surgery while having the security and familiarity of traditional laparoscopy.

**Methods:** A retrospective review was conducted of three patients that underwent left kidney donation using the bridging technique LESS donor nephrectomy. Preoperative demographics, perioperative parameters, and postoperative outcomes were analyzed. The video also demonstrates this novel technique.

**Results:** The mean postoperative stay was 1.3 days. There was immediate graft function in all three recipients and there were no complications in either the donor or recipients. Mean donor warm renal ischemia time was 2 minutes and 21 seconds. The mean EBL was minimal at 27 ml. Mean donor creatinine at one week was 1.23 mg/dl. At one month mean recipient creatinine was 0.97 mg/dl.

**Conclusion:** This video presents a simple bridging technique for LESS donor nephrectomy. This novel approach allows the surgeon to develop experience with single incision surgery while increasing the margin of safety for the donor and shortening the warm renal ischemia times.

### VS18-03 LAPROENDOSCOPIC SINGLE SITE(LESS) DONOR NEPHRECTOMY

G. Arvind, D. Dhawan, A. Kurien, V. Muthu, R. Sabnis, M. Desai—India

**Background:** To demonstrate the technical consideration and modifications in LESS donor nephrectomy

**Methods:** In this video we demonstrate the technique of laparoendoscopic single site (LESS) donor nephrectomy. Through an umbilical incision a single access port (R-port, Advanced surgical concepts Ireland) was placed into the abdomen. Straight standard instruments were used, Bent instruments were used for upper pole dissection. The standard steps of donor nephrectomy were employed which will be demonstrated in the video. At our centre an extra 3/5 mm port was inserted, which helped graft retrieval. The graft was retrieved manually with hand by extending the incision on either side by 1.5 cm.

**Results:** 22 live donors were operated. The procedure was technically feasible on the right side side (n = 2), donors with double vessels (n = 1) and retroaortic renal veins (n = 2). The mean BMI

was 21.35 + 3.2. Mean OR time was 170 + 33.6. The mean warm ischemia time was 6.98 + 2.1, the mean incision length 4.7 + 0.8. The pain score at discharge was 3.2 + 0.6, the pain score at 14 days was zero. The recipient creatinine at day one was 1.9 + 0.8 and at one week 1.1 + 0.3 and at 3 months 1.04 + 0.2. The final appearance of the scar was cosmetically pleasing.

**Conclusion:** Our experience of 22 cases till date suggests laparoendoscopic single site (LESS) donor nephrectomy to be safe, efficient and feasible option. It is technically feasible in patients with double vessels, right side and cases with retroaortic renal vein.

### VS18-04 LAPAROENDOSCOPIC SINGLE SITE (LESS) PFANNENSTIEL DONOR NEPHRECTOMY

S. Andonian, M. Atalla, A. Herati, S. Rais-bahrami, L. Richstone, L. Kavoussi—USA

**Background:** Laparoscopic donor nephrectomy has become the standard approach in harvesting kidneys from live donors. This is usually performed with three ports placed in a triangular fashion in addition to the Pfannenstiel incision where the kidney is removed. With advancements in technology, Laparoendoscopic Single Site (LESS) Pfannenstiel Donor Nephrectomy has become possible. In this video, we describe our technique and initial results.

**Methods:** After establishing pneumoperitoneum using the veres needle at the umbilicus, a 5 cm Pfannenstiel incision is performed and a flap of skin is dissected on top of the anterior rectus sheath till the umbilicus. Three 5 mm Anchor ports by SurgiQuest (Orange, CT) are placed in a triangular fashion under the skin flap. Two ports in the midline and the lateral port about 5 cm from the midline. The flexible 5 mm LTF Olympus laparoscope (Orangeburg, NY) is used. The colon is mobilized at the white line of Toldt. Gerota's fascia is then identified and used to pull the kidney laterally to aid in traction. The ureter is identified and dissected down to common iliac vessels. The gonadal vein is followed to lead to the left renal vein. Lumbar veins are doubly ligated and divided. The gonadal vein is doubly ligated and divided. The left renal vein is dissected all the way to the inter-aortocaval junction. The left renal artery is freed up. After dissecting hilar structures, the lateral and supero-medial adhesions of the kidney are freed up. Once the kidney is completely free except for the hilar structures, the ureter is ligated and divided. At this point, the superior midline port is upsized to 12 mm port. An Endo-GIA (Covidien, Mansfield, MA) is used to divide the renal artery and then the renal vein. A 15 mm Endocatch bag (Covidien, Mansfield, MA) is used through the inferior midline port site. The anterior rectus fascia between the two midline ports is then incised and the kidney is removed. The midline fascia is closed in addition to the lateral port site rent in the fascia. After ensuring hemostasis, the Pfannenstiel incision is closed in a subcuticular fashion.

**Results:** In this video, we present our first 4 LESS Pfannenstiel Donor Nephrectomies with median operating time of 157 minutes (138–231), average blood loss of 100, and median warm ischemia time of 5 minutes (3–6 minutes). The median length of hospital stay was 2 days. No patients received transfusions and none had complications.

**Conclusion:** LESS Pfannenstiel Donor Nephrectomy offers the benefits of improved cosmesis over the standard laparoscopic donor Nephrectomy. Prospective randomized trials are needed to compare the post-operative pain levels in between these two techniques.

### VS18-05 LAPAROENDOSCOPIC SINGLE SITE (LESS) DONOR NEPHRECTOMY: ALTERNATIVE USE OF THE GEL-PORT DEVICE

A. Patel, W. White, G. Haber, R. Goel, S. Crouzet, J. Kaouk

**Background:** To present our institution's experience with LESS donor nephrectomy using the GelPort® laparoscopic system as an access platform.

**Methods:** A prospective observational study was performed to assess perioperative outcomes among patients undergoing LESS donor nephrectomy with use of a standard GelPort® as the operative platform. Appropriate candidates were placed in the flank position and an approximate 5 cm periumbilical incision made. A commercially available GelPort® was deployed and the abdomen insufflated. Standard laparoscopic ports were placed through the GelPort® and the donor nephrectomy performed. The allografts were then extracted through the existing incision. Demographic and peri-operative data were obtained.

**Results:** From October 2008 to November 2008, 2 patients underwent laparoscopic live donor nephrectomy as described. Mean age was 37.5 years. Mean BMI was 24. One patient demonstrated 2 renal arteries and 1 vein with the remaining patient having 1 artery and 1 vein. Mean operative time was 240 minutes. Mean blood loss was 50 mL. Mean length of the incision was 6.65 cm. Mean warm ischemia time was 6 minutes, 40 seconds. There were no perioperative complications. Mean length of hospitalization was 3 days. Mean visual analog pain scale score at discharge was 0/10. Mean recipient creatinine at discharge was 1.2.

**Conclusion:** Use of the GelPort® during LESS donor nephrectomy offers versatility and improved spacing of instruments as compared to standard multichannel single ports. In addition, the design of the GelPort® is more accommodating for allograft extraction and requires neither use of a laparoscopic retrieval bag nor unnecessary compression of the kidney.

### VS18-06 LAPAROSCOPIC RENAL TRANSPLANTATION (LRT): A NEW CHALLENGE

A. Rosales, J. Salvador, G. Urdaneta, S. Esquena, M. Montlleó, H. Villavicencio—Spain

**Background:** Laparoscopic surgery approach has evolved significantly in the last decade. The acquired skills in different urologic procedures and the possibility to practice in experimental and animal models, has allowed us to apply this experience in the renal transplantation field.

**Methods:** We present the first living-related donor kidney laparoscopic transplantation (LRDLT). Using transperitoneal approach, vascular control is performed using endoscopic bulldog clamps. Terminolateral venous and arterial anastomoses were done with 5-0 Polypropylene continuous and discontinuous suture, respectively. Ureteral reimplantation was done by Taguchi technique.

**Results:** Surgical time was 240 minutes (60 minutes for vascular suture and 25 minutes for the ureteral reimplantation) with a blood loss of 300 cc and a hospital stay of 14 days. Creatinine at discharge was 73 mmol/l.

**Conclusion:** LRT is a long execution complex technique, with enormous development possibilities, like the rest of laparoscopic techniques. It's subjected to technical modifications in order to formalize its use and compare it with standard procedures.

### VS18-07 ROBOTIC RADICAL NEPHRECTOMY FOR COMPLEX RENAL MASSES

M. Patel, R. Laungani, E. Khetarpal, A. Pichurko, M. Menon, C. Rogers—USA

**Background:** Radical nephrectomy for complex situations such as vascular or nodal involvement often requires an open approach. We present our technique of robotic nephrectomy and include select patients with advanced renal disease.

**Methods:** Patients were placed in flank position with the camera in a lateral position and assistant ports placed medially. The robot was docked and the bowel was reflected medially. The renal hilum was dissected and ligated. In the event of tumor thrombus, the renal artery was ligated followed by milking of the tumor distally using a hemolock clip and ligation of the renal vein. In patients with adenopathy, retroperitoneal lymph node dissection was performed using complete robotic assistance with use of hemolock clips to isolate lymph nodes prior to dissection.

**Results:** To date, we have performed 62 nephrectomies with a median operative time of 240 min (iqr 205–320), median blood loss of 100 cc (iqr 50–200) and median hospital stay of 2 days (iqr 2–4). No evidence of recurrence at mean 19 months follow-up.

**Conclusion:** In conclusion, robotic radical nephrectomy is a feasible and safe procedure which can be performed even in patients with advanced regional disease.

### VS18-08 LAPAROENDOSCOPIC SINGLE-SITE (LESS) RADICAL NEPHRECTOMY: INITIAL CLINICAL EXPERIENCE

S. Jung, J. Park, E. Hwang, C. Im, D. Kwon—South Korea

**Background:** We present the initial clinical experience with laparoendoscopic single-site (LESS) nephrectomy for renal tumor using a homemade single-port device.

**Methods:** A 59-year-old woman presented with an 8 cm central enhancing right renal lesion. Under general anesthesia, the patient was placed in the flank position with the affected right side elevated 70°. We used an extra-small Alexis wound retractor and a surgical glove as the homemade single-port device. The Alexis wound retractor was inserted through a 5 cm paramedian incision that was made just lateral to the umbilicus. A homemade single-port device was made by securing the fingers of a size 7 surgical glove to the end of the trocars (two 5-mm trocars and one 12-mm trocar) with a silk and fixed to the outer ring of the wound retractor. A 5-mm rigid tracheoscope with integrated camera head (Hopkins telescope; Karl Storz, GmbH & CO. KG Tuttlingen) was inserted through the 5-mm trocars. The kidney was mobilized in the standard fashion using the flexible and standard laparoscopic instruments.

**Results:** The procedure was completed in 150 minutes without complications. Blood loss was estimated to be 100 mL. The post-operative course of the patient was uneventful.

**Conclusion:** Using a homemade single-port device, radical nephrectomy was performed safely and effectively, with minimal blood loss. Additional evaluation and development of this type of approach and instrumentation may allow for further expansion of a LESS surgery in the future.

### VS18-09 TECHNIQUE OF LAPAROSCOPIC ENDOSCOPIC SINGLE SITE SURGERY (LESS) RADICAL NEPHRECTOMY

J. Stolzenburg, P. Kallidonis, G. Hellawell, M. Do, A. Dietel, E. Liatsikos

**Background:** Laparoscopic-endoscopic single site surgery (LESS) represents the closest surgical technique to scar-free surgery. We evaluate the feasibility of LESS radical nephrectomy (LESS-RN).

**Methods:** Ten patients with BMI  $\leq$  30 underwent LESS-RN for renal tumour by two experienced laparoscopists. TriPort (Olympus, Germany) was inserted through a transumbilical incision. Combination of standard laparoscopic instruments and flexible grasper and scissors was used. A 5 mm 30° camera was also used. Standard laparoscopic transperitoneal nephrectomy technique was performed. Patient demographics, operative details and final pathology were prospectively recorded. Post-operative evaluation of pain and use of analgesic medication were recorded.

**Results:** Ten cases were successfully accomplished (2 right-sided and 8 left-sided, tumour diameter ranges 4–8 cm). The mean patient age was 63.5 years (22–77 years) and median BMI was 23.56 (18.2–26.6). The mean operative time was 146.4 minutes (120–180 minutes) and the mean blood loss was 202 ml (50–900 ml). Pathological examination observed organ confined T1 renal cell carcinoma in nine cases and pT3b tumour in one case. A bleeding complication occurred. Limitations regarding the intraoperative instrument ergonomics and the requirement for ambidexterity of the surgeon were noted.

**Conclusion:** LESS-RN proved to be safe and feasible. Further clinical investigation in comparison to the established techniques should take place for the evaluation of the outcome of LESS-RN.

### VS18-10 SINGLE PORT ACCESS FOR SIMPLE NEPHRECTOMY IN NON FUNCTIONING RENAL UNITS—AN EVOLVING CONCEPT

P. Ranjan, D. Dhawan, R. Baishya, A. Ganpule, M. Desai, M. Desai

**Background:** E-NOTES is an evolving concept in laparoscopy. So we are reporting an initial clinical urological experience of simple nephrectomy for non functioning renal units.

**Methods:** 4 patients underwent therapeutic laparoscopic simple nephrectomies for end-stage kidney disease consequent to stone disease (n = 2), PUJ obstruction (n = 1), and vesicoureteral reflux disease (n = 1). In all cases a 5-mm 30 degrees telescope and two 5-mm working instruments were inserted through the port. In the case of the nephrectomies, hemostasis and pedicle control was obtained with the Harmonic Scalpel and Hem-o-lok/Weck clips; no drain was kept.

**Results:** All procedures were completed uneventfully. Operative time averaged 135 + 68.4 minutes (60 to 240 min). Average blood loss was 108 + 44.4 ml (40 to 150 ml) and average hemoglobin drop of 0.83 gm%. Hospital stay was 2.75 + 0.69 days (range 3.5–2 days). There were no perioperative port-related or surgical complications in these cases.

**Conclusion:** Though the single port with multiple access channels for laparoscopic nephrectomy appears to have a steeper learning curve, it is a safe alternative to conventional laparoscopic surgery. Decreased morbidity and associated good cosmesis support its use as a viable option. Further studies are warranted.

## VS19: LAPAROSCOPY—ADRENAL

### VS19-01 LAPAROSCOPIC ADRENALECTOMY: ULUDAG UNIVERSITY EXPERIENCE

I. Yavascaoglu, Y. Kordan, H. Dogan, M. Danisoglu, H. Vuruskun, B. Oktay—Turkey

**Background:** To present our laparoscopic surgical experiences on the treatment of adrenal masses.

**Methods:** We retrospectively evaluated the results of 33 laparoscopic transperitoneal adrenalectomies performed in 21 female and 12 male patients with a mean age of 49.3  $\pm$  11.8 (21–72) years between March 2004 and March 2009. Surgery side was right in 15, left in 17 and bilateral in 1 patients. Mean mass size was 35.9  $\pm$  13.8 (23–80) mm.

**Results:** No conversion to open surgery has happened. Mean operative time was 151  $\pm$  50.8 (80–330) minutes and mean blood loss was 47  $\pm$  15.4 (30–100) ml. In one case distal pancreatic injury has been experienced as a perioperative complication. No other major complication has happened. Mean postoperative hospital stay was 3.2  $\pm$  1.8 (1–10) days and mean follow-up period was 14.1  $\pm$  10.9 (1–46) months. No postoperative complication has been experienced. Pathological evaluation revealed adenoma in 23, adrenocortical hyperplasia in 2, pheochromocytoma in 5, adrenocortical cancer in 1, metastatic adenocarcinoma in 1 and oncocytoma in 1 patients.

**Conclusion:** Transperitoneal laparoscopic adrenalectomy for the treatment of adrenal masses with its low morbidity is a safe and minimal invasive method.

### VS19-02 LAPAROSCOPIC ADRENALECTOMY FOR LARGE ADRENAL MASSES

R. Sotelo, A. Branco, M. Miranda, R. De andrade, O. Carmona, D. Canes—Venezuela

**Background:** Laparoscopic adrenalectomy (LA) as the gold standard for small adrenal masses. However, the role of LA for large masses (typically considered size >6 cm) has been reported, but is less widely accepted. Current controversies include the appropriateness of LA for large or malignant tumors, particularly when retrocaval dissection is anticipated. We present our contemporary experience with LA in this setting.

**Methods:** Three patients underwent laparoscopic adrenalectomy between 2006 and 2008, for adrenal lesions larger than 8 cm. Intraoperative data were collected retrospectively.

**Results:** Mean tumor size was 10.6 cm (range 8.3 to 14 cm). Mean operative time was 180 minutes (range 120 to 300 minutes), and mean estimated blood loss was 183 ml. There were no intraoperative complications or conversions to open surgery. Surgical margins were negative in one patient with adrenocortical carcinoma. The video demonstrates complete suprarenal inferior vena caval mobilization in one case.

**Conclusion:** LA for adrenal masses larger than 8 cm is safe and feasible. Open surgical principles are replicated. The inferior vena cava can be mobilized, allowing safe escisión when retrocaval dissection is required.

### VS19-03 LAPAROSCOPIC RESECTION OF PERIADRENAL PARANGLIOMA

A. Tuncel, Y. Aslan, O. Han, S. Seckin, A. Atan

**Background:** In this video presentation, we report a transperitoneal laparoscopic resection of right periadrenal paraganglioma.

**Methods:** A 64 y-old female was referred from our Endocrinology Clinic for right adrenal mass. In her medical history, there was localized right lower back pain for 2 years. Malignant hypertension was not described. In Magnetic Resonance Imaging (MRI), T2 images suggested that 47 mm in diameter lesion in center of the right adrenal gland. The radiographic features included an irregular hyperintense central margin, thickened septa, centrally located cystic component, and contrast enhancing peripheral portions. The lesion was not suppressed out-of-phase images. The adrenal cystic component could not be excluded due to centrally located cystic component in MRI. In serum and 24 hr. urine analyses, all catecholamine and its metabolites were in normal ranges. Also, serum aldosterone and renin levels were normal. Cystic agglutination test result was suspiciously positive. In the light of the above findings, after the oral treatment of Albendazole of the patient for 15 days, laparoscopic transperitoneal excision of the adrenal mass is decided.

**Results:** The patient was placed in a modified flank position. After creating the pneumoperitoneum, 4 ports were placed. Initially we retracted the liver by using fan retractor. The peritoneal attachments between the liver and the mass were mobilized. Then, we observed that thickened right adrenal vein. The vein was clipped and divided. The attachments between the mass and the adrenal were dissected by using 5 mm. Ligasure sealing device. The mass is dissected from the V. Cava Inferior by using Ligasure sealing device. Later, the remainder of the tissues was dissected. We placed the specimen in a retrieval bag. We placed Jackson Pratt drain. The operative time and blood loss were 100 minutes and 60 cc, respectively. The drain was removed on the first postoperative day. We discharged the patient on her second postoperative day without any complication. Histopathological examination consisted of periadrenal paraganglioma.

**Conclusion:** Laparoscopic approach for the periadrenal paraganglioma is a safe, applicable method with less morbidity and rapid recovery.

### VS19-04 LAPAROSCOPIC ADRENALECTOMY OF LARGE (>7 CM), HYPERVASCULAR PHEOCHROMOCYTOMA

N. Hamilton, S. Savage—United States

**Background:** Laparoscopic adrenalectomy is the standard of care for many adrenal masses. Larger, hypervascular pheochromocytomas pose a particular challenge for urologic surgeons. We present a case of a transperitoneal, laparoscopic adrenalectomy for a 9 cm hypervascular pheochromocytoma.

**Methods:** A 4-port, transperitoneal laparoscopic adrenalectomy was performed after appropriate preoperative medical therapy. Three-phase helical CT scan was utilized preoperatively in order to identify the significant adrenal vasculature. Standard laparoscopic methods utilizing clips and harmonic scalpel for vascular control were planned.

**Results:** The significant, large-caliber phrenic and renal branches precluded standard dissection with the harmonic scalpel. Judicious use of the vascular stapler allowed for continued dissection. Friable

tumor vessels pose a particular challenge. There were no adverse hemodynamic events.

**Conclusion:** Hypervascular, large, pheochromocytoma pose a difficult challenge for urologic surgeons. Availability of multiple vascular control devices allow for safe excision and minimal morbidity.

### VS19-05 LAPAROSCOPIC MANAGEMENT FOR EXTRA-ADRENAL PHEOCHROMOCYTOMA IN FOUR DIFFERENT CASES

T. Pinheiro, E. Metrebián, F. Sepúlveda, F. Messeti, V. Ortiz, C. Andreoni

**Background:** Laparoscopic surgery for extra-adrenal pheochromocytoma is challenging because of its relationship to adjacent organs and major vessels in addition to location variability and the complexity of the disease itself. Herein, we report on four procedures for extra-adrenal pheochromocytoma tumors performed by laparoscopic approach.

**Methods:** Four laparoscopic excision of extra-adrenal pheochromocytoma were performed from 2002 to 2008. All cases presented with hypertension and one patient was pregnant; the tests revealed high level of serum norepinephrine. The tumor location was identified by either CT or MRI. First patient presented with a 3 cm interaortocaval tumor, just underneath the Porta vein tumor; Second patient had a 5 cm tumor below the renal hilum between the vena cava and right; third case was a 7 cm left tumor below the renal hilum between the aorta and left ureter; the last case was a pregnant 22 year old woman with 4 cm underneath the vena cava and adrenal gland.

**Results:** Laparoscopic resection was successfully performed in all four patients with different trocar placement and approaches. The mean operative time was 142 minutes (range to 120–180). The estimated blood loss range to 150 a 350 ml and two patients need place 4 trocars and the other two 5 trocars to performed the surgery. No complications occurred.

**Conclusion:** Laparoscopic resection of extra-adrenal pheochromocytomas can be safely performed by experienced surgeons. Preoperative plan is important to decide trocar placement, patient position and surgical approach according to tumor site.

### VS19-06 ROBOTIC ADRENALECTOMY: SURGICAL TECHNIQUE AND OUTCOMES (THIS ABSTRACT IS ACCOMPANIED BY A VIDEO)

H. Atalah, L. Yeung, P. Sijo, L. Su—USA

**Background:** Robotic surgery for upper urinary tract pathology including the adrenal gland and kidney have become more common in the last few years. Herein we present our institution's experience and technique of robotic adrenalectomy.

**Methods:** This video presentation is of a 80 year old female who presented with an enhancing 5 cm right adrenal mass. Biochemical testing revealed that this adrenal mass was nonfunctioning. The patient underwent a three armed robotic technique using the da Vinci S system. The OR setup and step by step technique is detailed in this video presentation along with perioperative outcomes.

**Results:** To date we have performed seven robot assisted adrenalectomies. Mean tumor size was 4.3 cm (range 2–9.6 cm), OR time 2.5 hours (range 1–4 hrs), and length of hospital stay 1.4 days (range 1–2 days). Blood loss was minimal in all cases with no complications.

**Conclusion:** Robotic adrenalectomy offers the benefits of elimination of tremor and improved ergonomics with the wristed instrumentation, which is especially useful in addressing adrenal tumors located in deep and confined locations such as the case we presented. The robotic approach may prove to be an alternative for surgeons with limited experience with conventional laparoscopic techniques.

### VS19-07 SYNCHRONOUS TWIN TRACK PCNL

R. Sabnis, G. Arvind, A. Shetty, V. Muthu, M. Desai—India

**Background:** PCNL is the standard technique for management of large renal calculi. Our main goal is to achieve complete stone clearance which can be achieved in single stage or multiple stages. Large bulk stone clearance by PCNL has considerable morbidity namely prolonged operative times, increased intraoperative blood loss and need for secondary procedures. Therefore to further attempt to minimize the morbidity and to achieve maximal stone clearance for these difficult stones we investigated the feasibility of a synchronous twin track approach.

**Methods:** 36 year old male, presented with right ureteric and left complete staghorn calculus. He underwent right pushbang for the ureteric stone earlier and underwent synchronous twin track PCNL for the left complete staghorn calculus. Initial ultrasound guided localization and puncture was achieved in the upper and lower calyx and both the tracts were dilated synchronously. PCNL was performed by two operative surgeons simultaneously.

**Results:** Complete stone clearance was achieved. Total operative time was 80 minutes and haemoglobin drop was 1.5 gm%. There were no intra or peri-operative complications noted. Post operative x-ray confirmed complete clearance.

**Conclusion:** Synchronous twin tract PCNL is a potentially ideal operation for complete clearance of large bulk renal calculi with minimal morbidity. There is a need for two experienced operating teams working in tandem with two sets of endoscopic equipment, energy sources and television monitors which would limit this technique to hospitals where these logistics can be met.

### VS19-08 PERCUTANEOUS CHOLECYSTOLITHOTOMY: A CASE FOR FULGURATION OF THE GALL BLADDER WALL

S. Andonian, A. Rastinehad, A. Smith, D. Siegel—USA

**Background:** The gold standard for symptomatic cholelithiasis is laparoscopic cholecystectomy. Percutaneous cholecystolithotomy (PC) has been described previously as an alternative to laparoscopic cholecystectomy in high risk patients. This video describes a case of PC with fulguration of the gall bladder mucosa to scar the gall bladder and prevent recurrence of stones.

**Methods:** A 70-year old woman, who presented with acute cholecystitis, was treated with antibiotics and underwent attempted laparoscopic cholecystectomy. The gall bladder, containing a solitary 5 cm stone, was found to be severely adherent. Therefore, the procedure was terminated by inserting a cholecystostomy tube and the mucosa was biopsied to ensure benign disease. Two weeks later, PC was performed. A 30F Amplatz sheath was inserted after dilating the tract using Amplatz dilators. Cyberwand ultrasonic lithotripter with a Storz indirect nephroscope was used. A cholangiogram at the end of lithotripsy revealed that there were no distal obstructing common bile duct stones. Irrigation fluid was then changed to sterile water and a 28F continuous flow resectoscope was used to fulgurate the cystic mucosa. At the end of the

procedure, a 16F cholecystostomy pigtail tube was inserted into the gall bladder.

**Results:** Two weeks later, she underwent Endoscopic retrograde cholangiopancreatography (ERCP) and sphincterotomy to prevent recurrent cholecystitis. A cholangiogram revealed minimal opacification of the obliterated gall bladder lumen with free flow of contrast into the duodenum. Cholecystostomy tube was removed. After 12 months of follow up, she remains asymptomatic.

**Conclusion:** PC and fulguration of the mucosa is a minimally invasive alternative in patients who fail attempted laparoscopic cholecystectomy. This video demonstrates this technique.

### VS19-09 COMBINED PERCUTANEOUS ANTEGRADE & URETEROSCOPIC RETROGRADE APPROACH IN THE TREATMENT OF TOTAL URETERAL DISRUPTION AND URETEROVAGINAL FISTULA AFTER TOTAL LAPAROSCOPIC HYSTERECTOMY

H. Shah, A. Khandkar, H. Sodha, S. Kharodawala, M. Bansal

**Background:** To describe the technique of combined percutaneous antegrade & ureteroscopic retrograde approach in endourological management total ureteral disruption with ureterovaginal fistula (UVF).

**Methods:** From January 2000 to June 2003 four diagnosed cases of post laparoscopic hysterectomy ureterovaginal fistula had complete ureteric discontinuity on retrograde pyelography. They were managed endourologically with a combined percutaneous antegrade & ureteroscopic retrograde approach for ureteric stenting. After initial ureteroscopic confirmation of complete ureteric discontinuity, a glide wire was negotiated through the percutaneous renal puncture so as to reach the site of ureteric trauma. These glide wire was retrieved retrogradely with the ureteroscopic grasping forcep under combined ureteroscopic and fluoroscopic guidance. A ureteric stent was placed over this glide wire for realignment of disrupted ureter. At the end of procedure, an 8Fr. Pigtail nephrostomy catheter was placed for performing nephrostogram a week later. The ureteric stent was left insitu for 3 months. Follow-up intravenous urogram (IVU) was performed at 6 months and than yearly to look for development of ureteric stricture.

**Results:** Endoscopic realignment of traumatic complete ureteric disruption was successful in all four patients. None of the patients had extravasation of contrast or leakage of methylene blue in vagina during follow-up nephrostogram. Postoperative IVU was normal in 3 patients at 6 & 12-month followup. One patient required balloon dilatation for stricture that was diagnosed at 6-month followup. At follow-up ranging from 6–48 months, all patients are asymptomatic.

**Conclusion:** Present approach represents a feasible, minimally invasive alternate for treatment of the total ureteral disruption and ureterovaginal fistula. However, a longer follow-up with more number of patients is necessary to substantiate our results.

### VS19-10 ROBOTIC DIVERTICULECTOMY IN A PEDIATRIC PATIENT (THIS IS ACCOMPANIED BY A VIDEO)

M. Erhard, N. Le—USA

**Background:** Bladder diverticula are uncommon in children and can be congenital, acquired, or genetic in origin. Despite their etiology, all types of bladder diverticula present with similar manifestations, including infection, hematuria, perforation, or urethral obstruction from prolapse. Laparoscopic diverticulectomy has been described in children, but the surgery is technically dif-

ficult due to the intracorporeal suturing and limited work space. For these reasons, we recently performed laparoscopic diverticulectomy with the assistance of a robot. Herein we present this novel approach for performing a diverticulectomy in a pediatric patient. **Methods:** Our patient is an 11 month-old circumcised boy who presented with a febrile urinary tract infection. Voiding cystourethrogram (VCUG) demonstrated a right bladder diverticulum which retained urine after voiding. Due to the fact that he already had one episode of pyelonephritis, we recommended proceeding with a robotic-assisted laparoscopic diverticulectomy. The patient first underwent cystoscopy and the opening of the diverticulum was noted to be just superomedial to the right ureteral orifice. Due to the diverticulum's close proximity to the right ureteral orifice, a stent was placed in order to prevent unrecognized injury to the right ureter. We performed the robotic diverticulectomy with the 3-arm technique using the Intuitive Surgical Da Vinci S system. The 12 mm camera port was placed in a supraumbilical incision and the 8 mm ports were in the Left and Right upper quadrants of the abdomen. A 5 mm assistance port as placed in the left lower quadrant, just lateral to the epigastric vessels. The robot was docked at the foot of the bed. The bladder was retracted anteriorly and we easily identified the diverticulum, right ureter, and vas deferens. The peritoneum was incised and reflected off of the bladder. We dissected the diverticulum down to the level of the mucosa without compromising the adjacent ureter. Once the neck of the diverticulum was skeletonized, we only incised the anterior

portion, leaving the posterior lip intact. This allowed us to use the attached diverticulum as a handle for tissue manipulation. We then closed the mucosal layer of the bladder with a 4-0 running Monocryl suture with interlocking stitches. Once the first layer was closed, we amputated the diverticulum and passed it off for pathology through an 8 mm port. The seromuscular layer was closed and then we placed imbricating sutures. After all three layers of closure were completed, we filled the bladder to verify that it was watertight. Finally, we closed the peritoneal defect.

**Results:** Total operative time, from port incision to closure, was 1 hour and 49 minutes. Estimated blood loss was less than 10 ml. Our patient experienced no complications and was discharged the following day after overnight observation. We performed a VCUG 1 week after surgery and that revealed an intact repair. Renal ultrasound was negative for right hydronephrosis. The foley catheter was then removed. Our patient has not developed any urinary tract infections since his diverticulectomy.

**Conclusion:** With robotic assistance, a surgeon can perform a diverticulectomy on a child through a small incision with improved ergonomics and range of motion. Therefore, the robot affords the surgeon the dexterity to place intracorporeal sutures deep in the pelvis with ease and precision. Placement of a ureteral catheter is strongly recommended if the diverticulum lies adjacent to the ureteral orifice. This will aid in the safe dissection and excision of the diverticulum and avoid ureteral compromise.

## VS20: RECONSTRUCTIVE LAPAROSCOPY 3

### VS20-01 DISMEMBERED RETROPERITONEOSCOPIC PYELOPLASTY FOR THE TREATMENT OF SYMPTOMATIC URETEROPELVIC JUNCTION OBSTRUCTION IN A 12 YEAR OLD BOY WITH DUPLICATED COLLECTING SYSTEM

S. Subotic, A. Gözen, T. Bayer, R. Gumpinger, J. Rassweiler—Germany

**Background:** Traditionally open pyeloplasty has been the gold standard treatment of UPJO in children with success rates being quoted at over 90%. Specifically due to confined working conditions and difficulties with anastomotic suturing, open access was required. However during the last decade the management has been revolutionized with the introduction of laparoscopy and endourology yielding not only comparable results but also less morbid outcomes.

**Methods:** A 12 yr old boy was admitted with recurrent right flank pain since one year. Ultrasonographic a duplicated collecting system with dilatation of the lower renal hilum on the right side was detected. Using a furosemide renogram a significant UPJO of the lower collecting system was found. During preoperative stent insertion a UPJO and additional high ureter fissus were diagnosed. The patient underwent a retroperitoneoscopic dismembered pyeloplasty. After dissection of the renal hilum an anterior aberrant vessel was detected as the extrinsic cause of the UPJO.

**Results:** The operation time was 182 min. Intra- and postoperative course was uneventful and the patient was discharged 3 days postoperatively.

**Conclusion:** The open dismembered pyeloplasty is still the gold standard treatment for UPJO in children. However with increasing improvement of suturing techniques, the laparoscopic pyeloplasty represents in experienced hands an alternative method with comparable success rates to the open technique. Even in challenging cases as mentioned, the retroperitoneoscopic approach is save and feasible.

### VS20-02 STENTLESS ROBOT ASSISTED LAPAROSCOPIC DISMEMBERED PYELOPLASTY

M. Lerner, C. Sundaram—USA

**Background:** A ureteral stent can cause significant post-operative symptoms during in patients undergoing a robot assisted laparoscopic pyeloplasty (RALP) for ureteropelvic junction obstruction (UPJO). We have performed 16 RALP's without an indwelling ureteral stent. We present a surgery in which the ureteral catheter is removed at the completion of the procedure.

**Methods:** In a stentless pyeloplasty, a retrograde pyelogram is performed in order to delineate the anatomy. A 5 french ureteral catheter is placed to assist with reconstruction of the UPJ. A standard RALP is performed. The anastomosis is irrigated at the end of the surgery with diluted indigo carmine to evaluate for an anastomotic leak. Once a water tight anastomosis is achieved, the ureteral catheter is removed and a drain is placed.

**Results:** The patient in this presentation had no recurrent pain episodes and had normal drainage curves on a post-operative re-

nogram. This case is representative of a series of 16 patients that underwent a stentless RALP at our institution. 94% had no evidence of obstruction of post-operative lasix renogram and 94% were pain free on the last follow-up visit. 2 patients had a post-operative urine leak but only one patient required placement of a retrograde stent 24 hours after surgery. Both patients were pain-free without evidence of obstruction at follow-up.

**Conclusion:** Stentless RALP can be an effective management option for patients with UPJO and eliminates post-operative stent symptoms.

### VS20-03 INDIVIDUALIZED MANAGEMENT OF URETEROPELVIC JUNCTION OBSTRUCTION DURING ROBOT ASSISTED LAPAROSCOPIC DISMEMBERED PYELOPLASTY

M. Lerner, C. Sundaram—USA

**Background:** The surgeon performing robot assisted laparoscopic dismembered pyeloplasties (RALDP) must have adaptability and knowledge of various pyeloplasty techniques. The surgery should be tailored to an individual patient's specific anatomy. We present 3 illustrative cases of a RALP.

**Methods:** Digital video capturing is performed during all laparoscopic procedures. Video segments determined by the surgeon to have educational value are archived and later used to create educational videos.

**Results:** The video highlights the standard maneuvers used for RALDP using contemporary laparoscopic and robotic techniques. Laparoscopic devices such as bipolar electrocautery, ultrasonic shears, and Hem-o-lok polymer ligating clips are featured. Nephroscopy for the management of nephrolithiasis at the time of RALDP is highlighted. Variations in the management of lower pole crossing vessels are demonstrated using techniques of cephalad transposition and posterior transposition. In 41 patients undergoing RALDP, lower pole crossing vessels were transposed posteriorly in 13 patients and cephalad in 4 patients. 95.1% of the patients had a normal drainage curve on post-operative lasix renogram. All patients with cephalad transposition of the lower pole vessels had no evidence of obstruction post-operatively. 97.6% had resolution of their flank pain. The patient who had persistent flank pain had no evidence of obstruction on a post-operative lasix renogram.

**Conclusion:** This video clarifies the essential steps involved in a standard RALDP and the need for individualized management for patients with ureteropelvic junction obstruction.

### VS20-04 LAPAROSCOPIC REPAIR OF RETROCAVAL URETER

O. Sanli, T. Tefik, O. Aytac, E. Salabas, M. Karadeniz, C. Özsoy

**Background:** Retrocaval ureter is a rare congenital abnormality that results due to developmental abnormality of vena cava inferior. The anomaly usually becomes symptomatic in the third or fourth decade of life. Surgery is the mainstay of treatment of this congenital abnormality. In the last decade, laparoscopic procedures have replaced many open surgeries because of well-documented advantages of minimal invasive surgery. In addition, there is growing body of evidence in the literature that laparoscopic repair of retrocaval ureter should be considered as first line treatment for the treatment of this rare congenital abnormality.

**Methods:** We present a case of 32-year-old female patient presented with a history of intermittent rightside flank pain. Her urography revealed right hydronephrosis and suspicion of retrocaval

ureter. Meanwhile, a MR urography demonstrated a retrocaval ureter at the level of L4 with a shape of reverse J that established this anomaly as type 1 retrocaval ureter. The clinical manifestation is discussed first followed by radiographs utilized for the diagnosis. Treatment to resolve the ureteral obstruction by laparoscopic ureteroureterostomy is shown.

**Results:** The preoperative radiographic evaluation of retrocaval ureter includes intravenous pyelography and diuretic renography. Laparoscopic ureteroureterostomy entails mobilization of the dilated ureteral segment, followed by ureteral transection. The retrocaval segment is brought anterior and lateral to the inferior vena cava, and the continuity of the ureter is re-established by ureteroureterostomy. The patient's postoperative course is discussed.

**Conclusion:** The laparoscopic approach should be considered to be first-line treatment for this anatomic anomaly due to quick convalescence, cosmetic advantage and relative technical ease. End-to-end anastomosis without excision of the retrocaval segment is found to be a reliable procedure. Controlling the water tightness of the anastomosis with the aid of preoperatively placed ureteral catheter may be beneficial. Case series are needed to confirm these conclusions obtained from the presented case.

### VS20-05 ROBOT ASSISTED PYELOPLASTY FOR URETEROPELVIC JUNCTION OBSTRUCTION

I. Tufek, H. Akpinar, F. Atug, S. Aksit, A. Kural—Turkey

**Background:** Robot assisted pyeloplasty (RAP) is evolving as a treatment alternative for ureteropelvic junction obstruction (UPJO) and currently is the second most common urologic procedure performed with the robot. Here we present RAP operation in 2 patients.

**Methods:** A 20 years old female patient with right UPJO underwent Anderson-Hynes RAP. After mobilization of the colon and dissection of the renal pelvis, ureter and ureteropelvic junction (UPJ) were identified. The renal pelvis was cut and transected and afterward the ureter was cut and spatulated. Initially the posterior wall anastomosis was completed. Once the posterior aspect of the anastomosis was completed, a ureteral stent was placed in an antegrad fashion. After placing the ureteral stent the anterior wall anastomosis was completed. Second patient was a 21 years old male with left UPJO. A crossing vessel coursing through lower pole of left kidney was the reason for UPJO. After mobilization of the colon and dissection of the renal pelvis, ureter and UPJ were identified. The UPJ was under the crossing vessels. The ureter was transected and repositioned over crossing vessels. Ureteropelvic anastomosis was completed in the same manner with the previous patient.

**Results:** Total operative time was 150 minutes in both patients and estimated blood loss was 150 and 10ml in the first and second patient, respectively. Postoperative period was uneventful.

**Conclusion:** Robot assisted pyeloplasty is a feasible treatment modality for ureteropelvic junction obstruction. Robotic assistance simplifies dissection and suturing.

### VS20-06 IATROGENIC DIAPHRAGMATIC LESION: LAPAROSCOPIC REPAIR

A. Celia, G. Zeccolini, G. Breda

**Background:** Inadvertent diaphragmatic injury during transperitoneal laparoscopic surgery in urology is a rare occurrence. With the widespread use of laparoscopy and the increasing surgical pathologies managed by this technique, this infrequent complica-

tion has become a potential risk. This video shows the main steps of the laparoscopic management of a iatrogenic diaphragmatic injury during laparoscopic transperitoneal nephrectomy in a patient affected by infected hydronephrosis with a staghorn stone.

**Methods:** A 66 years old woman is admitted to our department because of left infected hydronephrosis with a staghorn stone. Laparoscopic transperitoneal nephrectomy is planned. After opening the retroperitoneum, the dissection of renal pedicle and kidney is hard because of strong adhesions between renal fat and surrounding tissues. After removing the kidney, an increase in end inspiratory pressure and carbon dioxide levels is noted. This prompts the inspection of the operative field and a 4 cm lesion is found on the left diaphragm. For diaphragmatic repair, non extra trocar is needed. The defect is repaired with separate 0-polyglactine sutures while pneumoperitoneum is decreased. Before the stitches are secured, anaesthesiologist administers a large inspiratory breath to prove the suture to be watertight. A chest tube is placed.

**Results:** The operating time is 240 min. The time of diaphragmatic repair is 45 minutes. Follow-up chest x-ray shows no residual pneumothorax.

**Conclusion:** Iatrogenic injury of the diaphragm during laparoscopic management of the pathology of the upper urinary tract is rare, but possible. Inflammatory pathologies can facilitate the occurrence of such a lesion. Surgeon needs to be trained to resolve it. Intracorporeal repair of a diaphragmatic injury is a feasible, reproducible and reliable technique.

#### VS20-07 TRANSPERITONEAL LAPAROSCOPIC RETROCAVAL URETER CORRECTION

G. Franco, P. Francesco, G. Andrea, S. Antonio, I. Giacomo piero—Italy

**Background:** The retrocaval ureter is a congenital abnormality in which the right ureter passes behind the inferior vena cava, leading to varying degrees of ureteral compression. Surgery is required for the treatment of the hydronephrosis or related symptoms. The video shows “step by step” a transperitoneal laparoscopic transection of a retrocaval ureter with transposition and reanastomosis.

**Methods:** A 14 years-old girl presented to our institution with right lumbar pain and hydronephrosis. The CT showed a retrocaval ureter. We performed a transperitoneal laparoscopic transection of the retrocaval ureter with transposition and reanastomosis with 2 uninterrupted absorbable sutures (Vicryl 3.0). A mono-J ureteral stent (Contour VL™ Variable Length Percuflex®, Boston Scientific) is placed just before starting the laparoscopic approach.

**Results:** Operative time was 260 minutes, blood losses were negligible; on postoperative day 3 after a retrograde pyelography excluded contrast medium extravasation and the Contour stent was converted in a double J stent. Bladder catheter and the drain were respectively removed on postoperative day IV and V. The patient had no perioperative complications and was discharged on postoperative day IX. The ureteral stent was removed 28 days after surgery. The urography at 3 months showed regular patency of the anastomosis.

**Conclusion:** The transperitoneal laparoscopic correction of the right retrocaval ureter is a feasible and minimally invasive.

#### VS20-08 TRANSUMBILICAL LAPAROSCOPIC (NOTUS) PYELOPLASTY WITH STANDARD INSTRUMENTATION

B. Dauster, L. Dorea, C. Pugas, P. Furtado, M. Fucs—Brazil

**Background:** Laparoscopic dismembered pyeloplasty is the gold standard for the treatment of UPJ stenosis. Reducing the number of skin incisions may decrease the postoperative pain and benefit the cosmesis. Most reports with this intent use Natural Orifice Transumbilical Surgery (NOTUS) with single trocars and flexible instruments, what increase the costs for the laparoscopic access. This video shows laparoscopic single incision pyeloplasty using standard instruments with no increments to the costs keeping the benefits of NOTUS.

**Methods:** One patient underwent single incision transumbilical pyeloplasty using standard trocars and instrumentation. A double-J catheter was inserted antegradely through one trocar. Operative and recovery data was recorded and presented during the video.

**Results:** The procedure was technically successful with no extra-umbilical incision. The total operative duration was 170 minutes, the estimated blood loss was 50 ml, and the hospital stay was 2 days. The total analgesic requirement was 6 g of sodium dipyrone, and visual analogue scale was 3/10 and 2/10 at 1st and 2nd day after surgery respectively.

**Conclusion:** Transumbilical single incision pyeloplasty without the aid of special instruments is feasible, although it requires advanced laparoscopic skills. Further investigation is necessary to determine the advantages of this new technique.

#### VS20-09 MANAGEMENT OF CROSSING VESSELS (AND OTHER FINDINGS) DURING ROBOTIC PYELOPLASTY

U. Boylu, B. Lee, R. Thomas—USA

**Background:** Crossing vessels are reported to be present in 38% to 71% of patients with ureteropelvic junction. Despite advances in imaging and surgical techniques, controversies remain about the etiological significance and surgical management of crossing vessels.

**Methods:** A total of 130 patients with ureteropelvic junction obstruction underwent RALP. A decision to transpose the ureteropelvic junction was made after extensive pelviolysis and meticulous angiolysis. After transection of the ureter, the renal pelvis and ureter brought together anterior and posterior to the crossing vessel. If the ureter appeared to be stretched or kinked at the anterior of the crossing vessel, the ureteropelvic junction was not transposed.

**Results:** Anterior crossing vessels were encountered in 48 patients and transposed in 18 patients. No transposition was performed in 30 patients. Postoperative differential function and half-time drainage significantly improved both in transposed and non-transposed groups. With no open conversion and recurrence, the radiographic and symptomatic success rate was 100%.

**Conclusion:** Transposition should not be mandatory and the decision to transpose should be made intra-operatively. Extensive pelviolysis and meticulous angiolysis are key factors to determine the necessary reconstructive technique.

#### VS20-10 ROBOTIC REDO PYELOPLASTY IN THE PEDIATRIC POPULATION (ACCOMPANIED BY A VIDEO)

M. Erhard, N. Le—USA

**Background:** Ureteropelvic junction (UPJ) obstruction is a common diagnosis in the pediatric population. The dismembered pyeloplasty is a preferred approach for repair, and was traditionally performed through an open incision. Despite undergoing repairs which were technically sound, some children have developed recurrent flank pain and urinary obstruction. At our institution, we



have performed five redo dismembered pyeloplasties using the Da Vinci robot in such a patient. Herein we present the technique of the robotic-assisted redo dismembered pyeloplasty.

**Methods:** Our patient is a 16 year-old male with a history of UPJ obstruction status post open dismembered pyeloplasty 8 years ago. He developed left recurrent flank pain that was relieved after stent placement, so he underwent an endopyelotomy 3 years ago. Unfortunately, his flank pain returned earlier this year, causing him to miss school. Due to his symptomatology, we recommended robotic-assisted laparoscopic pyeloplasty. We performed robotic redo pyeloplasty with the 3-arm technique using the Intuitive Surgical Da Vinci S system. The 12 mm port was placed in the infraumbilical position, and the 8 mm ports were placed in the subxiphoid area and left lower quadrant. A 5 mm assistant port was placed between the umbilicus and pubic symphysis. We accessed the renal pelvis via a transmesenteric approach. The lower renal pelvis and UPJ were mobilized and scar tissue from the previous repair was excised. The ureter was then transected without compromising the ureteral stent. The ureter was spatulated on the lat-

eral border for a length of 1 cm. Reconstruction of the renal pelvis commenced with placement of 2 apical stitches and proceeded with closure of the posterior, then anterior anastomosis. During the closure, the ureteral stent was placed back into the renal pelvis. We excised the stenotic segment of the UPJ and sent it to pathology. Once a watertight closure was achieved, the mesenteric defect was closed.

**Results:** Total operative time, from port incision to closure, was 2 hours and 16 minutes. Estimated blood loss was less than 10 ml. Our patient experienced no complications and was discharged the following day after overnight observation. The foley catheter was removed on postoperative day 1 and the stent was removed 4 weeks later. Since his reoperation, the patient has had no recurrent flank pain.

**Conclusion:** From our institutional experience, we conclude that redo dismembered pyeloplasties can be performed safely and effectively with the robot, despite scar tissue from previous repairs. The transmesenteric approach is a viable option in the pediatric population and decreases operative time and bowel manipulation.



## Author Index *by abstract number*

### A

- Abat, D., MP2-10, MP10-14, VP21-09, VP24-04, VP24-07, VP25-09, VP27-05  
Abaza, R., MP5-04, MP5-06, MP11-08, MP17-12, MP17-13, MP17-19, VS15-01, VS15-02  
Abbaraju, J., VP18-07  
Abbou, C., VS5-10  
Abdelbaky, T., MP9-03  
Abdi, M., VP6-16  
Abolbashari, M., VP13-14  
Aboseif, S., MP23-05  
Abrahamsen, J., VP27-20  
Abuhajar, A., VS8-06  
Abusamra, A., VP2-15  
Acevedo, C., BR5-03  
Acosta-Miranda, Alex, MP10-11  
Adamopoulos, V., VP18-05  
Adamou, V., VP28-12  
Addidle, M., MP7-16  
Adonian, S., VP21-08  
Afshari, J. Tavakol, MP18-01  
Agarwal, G., MP8-04  
Agarwal, M., BR4-04, MP21-08, VP13-12  
Aguilar, Y., MP8-14, VP3-10, VP4-10, VP6-14  
Ahlering, T., MP15-16, VP20-02, VP20-03  
Ahmadnia, H., MP10-01, MP16-01, MP18-01  
Ahn, H., MP13-08, MP15-08, MP17-14  
Ai Ling, R., VS3-02, VS8-02, VS17-04  
Aizawa, M., VP17-17  
Akbari, N., VP26-12  
Akbarov, I., MP12-19  
Akbarpour, M., MP5-01, MP9-02, VP26-02  
Akbartabar, M., VP26-03  
Akduman, B., BR5-06, VP18-02  
Akgül, T., BR1-03, O3-06, O6-09, VP17-06, VP23-02, VS9-02  
Akhavan, A., MP15-07  
Akin, Y., MP16-20  
Akman, T., BR3-08, O5-07, MP8-12, MP21-20, VP4-14, VP15-13, VP27-14  
Akpýnar, H., VP27-18  
Akpınar, H., MP15-13, VP14-16, VS1-10, VS5-08, VS13-03, VS14-06, VS15-10, VS17-03, VS20-05  
Aksit, F., VP14-16  
Aksit, S., VS1-10, VS5-08, VS13-03, VS14-06, VS15-10, VS17-03, VS20-05  
Aksoy, E., VP22-18  
Aktoz, T., VP25-20, VS17-08  
Al-ansari, W. Abdul-wahab, BR4-05, VP14-04, VS1-08, VS2-05, VS2-08  
Al Aown, A., MP9-15, MP13-14, MP24-16, MP24-17, VP10-13  
Al-sayad, A., VP2-15  
Alam, Z., VS11-05  
Alanee, S., BR3-07, VP3-05, VP16-13  
Alaown, A., VP16-06  
Albala, D., BR2-07, O2-04, MP6-12, MP6-13, VP10-11, VP19-19, VP20-11  
Alessandra, B., VP20-05  
Alexandrescu, E., MP9-01  
Alexandrov, I., VP7-05  
Alhamadie, H., VP20-17  
Ali, H., VP15-07  
Ali, R., VP23-06  
Aliyev, E., MP5-03, MP14-09  
Alken, P., BR3-01, MP4-03, MP12-08, MP12-09  
Allaf, M., MP13-07, MP14-17, VP25-18, VP27-08  
Allam, C., MP24-07  
Allen, D., MP2-14  
Almaguel, F., MP13-05  
Almeida, M. Malta, MP16-05  
Aloisi, A., VP3-02  
Alqahtani, S., BR8-01, BR8-02, O5-10, VP3-20  
Altunova, S., O1-04  
Altamar, H., BR7-09, MP3-03, MP4-07, VP1-05, VP2-20, VP22-19  
Althoefer, K., BR7-10  
Altug, U., MP20-17, VP2-03, VP11-09  
Álvaro, Mr., O2-11  
Alvi, K., MP7-19  
Amici, A., VP27-15, VS3-05, VS6-08  
Amin, H., VP7-09  
Aminsharifi, A., MP8-03, MP10-01, VP6-16, VP26-15, VP28-02, VP28-06, VP28-17  
Amirhassani, S., MP4-01  
Anafin, T., O4-10  
Anceschi, C., O5-03, VP10-03, VP15-02  
Anceschi, U., O5-03, VP10-03, VP15-02, VP27-15, VS3-05, VS6-08  
Ander, H., VS2-07  
Andonian, S., MP12-07, MP18-16, VP8-03, VP10-18, VP27-03, VS6-06, VS8-05, VS18-04, VS19-08  
Andrea, G., VS8-02, VS20-07  
Andreoni, C., BR1-04, MP20-08, MP20-15, VP8-12, VS19-05  
Andrews, P., O2-10, VP14-18, VP19-13, VS8-04  
Andriopoulos, N., VP9-12, VS16-01  
Angeli, A., MP6-09  
Angrisani, R., VP19-20  
Anjum, F., VP18-07  
Annino, F., BR5-09, VP5-15, VP20-05, VS4-09, VS9-07, VS14-07, VS15-08  
Ansari, M., VP2-05, VP17-07  
Antonio, S., VS3-02, VS8-02, VS17-04, VS20-07  
Antwerpen, C., VP2-18, VP13-09  
Aoyagi, T., VP27-01  
Apostolidis, A., BR2-03, BR4-05, VP14-04, VS1-08  
Apostolis, B., VP15-06  
Araújo, J. Callijão, MP16-05  
Arab, D., MP7-05  
Arada, E., VS2-06  
Arada III, E., VP13-15  
Arada, R., VS2-06  
Arai, Y., MP6-08, VP22-02  
Araki, I., VP9-11  
Araki, M., MP8-07  
Arata, R., MP1-19  
Araujo, J. Rosales, MP6-11, MP6-16, MP12-14, MP18-10  
Araza, F., MP22-16  
Arguiñarena, F. Trueba, VP23-03  
Arguiñarena, J. Trueba, MP19-14  
Argun, B., VP6-09  
Aridogan, I., MP4-14, MP9-14, MP9-17, VP4-09, VP21-09, VP24-04, VP24-07, VP25-09, VP27-05  
Arikan, O., VS2-10  
Aron, M., VP8-01, VP17-04, VP17-08, VP17-11, VP17-15, VP19-07, VP19-11, VS4-06  
Arora, A., MP12-04, MP12-05, VP10-06, VP10-07, VP10-14  
Arslan, M., MP14-10, VP7-12, VP7-13, VP21-10, VP21-14, VP22-14, VP22-18  
Arsovska, O., MP9-07, VP4-06  
Arvanitakis, T., MP1-03

- Arvind, G., VP22-01, VS18-03, VS19-07  
Aryafar, A., MP8-03, VP26-15, VP28-02, VP28-06  
Asadi, S., MP5-01  
Asakura, H., O6-03  
Aslan, R., VP15-13  
Aslan, Y., MP12-16, VS19-03  
Asplin, J., MP21-06  
Asquith, J., VP11-03, VP19-12  
Assimos, D., MP3-14  
Assubayev, A., O4-10  
Astarci, M., BR1-03, O6-09  
Astigueta, J., VS14-09  
Atalah, H., MP5-19, MP13-16, MP17-20, VP5-10, VP5-12, VP5-13, VP5-14, VP5-16, VP27-08, VS2-04, VS10-08, VS15-07, VS19-06  
Atalla, M., MP18-16, VP2-16, VP8-03, VP10-18, VP19-16, VP27-06, VS6-06, VS8-05, VS16-08, VS18-04  
Atalla, M.A., VP28-13  
Atan, A., MP12-16, VS19-03  
Atar, A., MP14-09, MP20-19, VS2-07  
Ates, M., VP14-19, VS1-05, VS3-06, VS12-09  
Ather, M., MP2-05, MP2-19, VS11-05  
Atuð, F., VP27-18  
Atug, F., MP15-13, VP14-16, VS1-10, VS5-08, VS13-03, VS14-06, VS15-10, VS17-03, VS20-05  
Au, W., VP9-15  
Auge, B., MP1-18, MP6-02, MP10-02, MP13-19, VP17-05, VP26-05  
Augustine, A., BR1-09  
Autenrieth, M., BR8-04, VP21-07  
Autorino, R., MP12-13, MP18-19, VS5-05  
Avci, A., VS9-03  
Averch, T., MP21-16, VP2-06, VP2-11  
Ayalew, M., MP17-04  
Ayder, A., MP14-10, VP7-12, VP7-13, VP21-10, VP21-14, VP22-14, VP22-18  
Aydin, M., MP22-18, VP15-04  
Aydin, O., MP12-16  
Aydur, E., VP15-09  
Aydýn, H., BR3-09  
Aytac, O., MP5-03, VS20-04  
Aytutuldu, A., VP27-05  
Azadvari, M., BR3-06, BR3-10  
Aziz, M., MP13-13, MP17-08, VP27-17
- B**  
Baba, S., VP2-17, VP7-03  
Babaian, K., MP10-18  
Baban, N., MP22-11  
Babanin, I., O4-01  
Babayán, R., MP8-09, VP1-06, VP9-03, VS14-04  
Babjuk, M., MP7-10  
Babolhaejí, H., MP21-15  
Baca, G., BR3-02, MP13-20  
Bach, T., BR4-03, O4-06, VP3-16, VP4-18, VP9-17, VP9-18, VP9-19, VP14-03, VP14-11, VP14-12, VP16-07, VP28-19, VS6-10  
Bachmann, A., MP21-12, MP23-14, VP7-07  
Bäcker, C., BR2-03, BR4-05  
Badani, K., O6-07, MP6-11, MP6-15, MP6-16, MP11-14, MP12-14, MP15-01, MP15-06, MP18-10, MP18-13, MP21-09, VP7-06, VP22-17  
Bader, M., BR6-07  
Badreldin, M., MP9-03  
Bae, J., VP14-07  
Baek, M., MP21-03  
Bag, S., MP3-20  
Bagheri, F., VP17-18  
Bagley, D., O3-10, MP5-15, MP22-07, VP6-08, VP9-10, VP16-09  
Bailey, M., VP18-09  
Baishya, R., MP9-09, VS18-10  
Baishya, VP26-13  
Bakolas, D., BR4-08  
Balarie, C., MP9-19  
Balci, M., MP12-16  
Baldwin, D., BR2-01, MP6-04, MP6-04, MP6-05, MP8-04, MP13-04, MP13-05, VP17-01, VP19-08, VS5-07, VS18-02  
Ballesteros, C., VP6-17  
Bansal, B., VP3-14  
Bansal, M., VS1-02, VS1-03, VS1-04, VS7-09, VS11-06, VS19-09  
Bansal, R., VP2-05  
Baptistussi, M., MP8-20, MP9-20, MP10-09, MP23-07, VP10-01, VP10-02, VP12-20, VP13-16, VP15-12, VP18-10, VP24-08, VP24-09, VP27-10, VP27-11, VP27-12, VS4-05, VS11-09, VS15-09, VS17-09  
Bardan, R., MP9-19, VS5-09  
Bardide, A., VP19-09  
Barret, E., O1-06, O3-02, O6-04, MP1-05, VP6-20, VP12-02, VP12-08  
Barrie, J., MP14-08  
Basal, S., MP9-12, MP22-09, MP22-10, VP11-17, VP14-19, VP15-01, VP23-08, VP23-09, VP24-11, VS3-06, VS9-03, VS12-09  
Basar, R., VP6-04  
Basiri, A., BR3-06, BR3-10, MP10-01, VP2-07, VP3-07, VS3-09, VS4-10, VS5-03, VS9-05  
Basli, M., MP9-18, MP22-20  
Basok, E., O3-06  
Bassi, P., MP7-06, MP10-06, MP10-07, MP23-01  
Bastos, F., VS2-02  
Baumgartner, M., O6-05  
Bautista, T., VP20-08  
Bautzer, C., VS9-09  
Bayazit, Y., MP4-14, MP9-14, MP9-17, VP4-09, VP21-09, VP24-04, VP24-07, VP25-09, VP27-05  
Bayer, T., BR4-06, BR5-05, VS3-08, VS20-01  
Bayindir, M., MP10-03, MP19-06  
Baykal, M., VP25-20, VP27-14, VS17-08  
Baykara, M., O1-04, MP16-20, VP6-15, VS2-09  
Bayzhanov, A., O4-10  
Bazzi, W., VP8-13, VP21-15  
Beato, A., VP5-15, VP18-08, VS14-07, VS15-08  
Bercowsky U, E., VP6-17, VP9-01, VP12-10  
Becht, E., O4-08, O4-09  
Beck, A., MP23-11  
Beck, C., MP23-11  
Beck, S., MP22-06  
Bedir, S., MP4-15, MP9-10, MP22-09, VP10-10, VP12-12, VP15-01, VP23-08, VP26-19, VS6-02, VS9-03  
Bedke, J., MP7-14, MP24-11  
Beeck, A., VP28-19  
Beemster, P., VP19-15  
Beer, M., BR2-03, BR4-05, VP14-04, VS1-08, VS2-05, VS2-08  
Beiko, D., MP8-16, VP4-06, VS11-04  
Bell, D., VP14-13  
Bellamy, E., MP22-01  
Beltrame, F., VP8-12  
Beltrami, P., VP3-02, VP15-05  
Benchikh, A., MP1-05  
Benedetto, G., VP26-06  
Benjamin, S., MP22-16  
Benoist, N., O1-06, VP1-20  
Benson, A., BR1-07, O1-05, MP23-18, VP19-14, VS2-03  
Benson, M., MP5-16  
Bentas, W., MP13-17  
Benway, B., MP6-19, VP21-18, VS13-07, VS13-08, VS13-09, VS17-10  
Beom, K. Yun, MP23-12, MP24-15  
Berent, A., VP6-08  
Berestennikov, K., VP26-18  
Berger, A., VP8-01, VP11-10, VP17-04, VP17-08, VP17-11, VP17-15, VP19-07, VP19-11, VP25-07, VS4-06, VS17-01  
Bergsdorf, T., VP18-20  
Bergstein, D., VP12-13  
Beri, A., VP28-15  
Berkowitz, J., MP3-16, MP13-07, MP14-17, MP21-06, VP11-01, VP25-18, VP27-08  
Bermudez, Hugo, VP21-20  
Bernardini, P., VP26-08  
Bernier, Pablo, VP21-20  
Bertolo, R., MP12-15, VP1-10, VP1-17, VP1-18, VP17-10, VS3-10, VS6-04, VS15-06

- Bertolotto, F., BR8-03, VP23-01  
 Bertti, R., VP17-19  
 Bessa, J. Teixeira, MP16-05  
 Bhalani, V., MP10-12  
 Bhalla, R., MP16-13, MP24-04  
 Bhandari, A., MP17-01  
 Bhat, S., MP18-03, MP18-06, VP2-12, VP22-05  
 Bhavsar, R., VP1-07  
 Bhayani, S., MP6-19, MP17-17, VP21-18, VS13-07, VS13-08, VS13-09  
 Bianchi, G., BR5-09, VP5-15, VP18-08, VP20-05, VS4-09, VS9-06, VS9-07, VS14-07, VS15-08  
 Bianco, F., O6-04, VP12-02  
 Bianco, Jr, F., VP12-02  
 Bibbo, M., MP5-15  
 Bilen, C., VP4-15  
 Binbay, M., BR3-08, O5-07, O5-09, MP8-12, MP21-20, VP4-14, VP15-06, VP15-13, VP25-20, VP27-14  
 Birch, M., MP16-17  
 Bird, V., MP6-14, MP13-13, MP17-08, MP19-02, VP27-17  
 Biri, H., VP24-06  
 Bisas, A., O5-09, MP21-19  
 Bischoff-kalb, P., BR4-08  
 Bitkin, A., MP22-08  
 Biyabani, S., MP2-05  
 Blacker, A., VP3-17, VP15-11  
 Blana, A., O2-07, MP1-04, VP11-08  
 Blas, M., VP6-12  
 Blew, B., VS8-06  
 Blomgren, P., BR5-10  
 Blumberg, J., MP1-12  
 Bo, J., BR8-07, O4-02, VP3-12  
 Bodiwala, D., MP4-06  
 Boehler, M., O1-05  
 Boehme, H., VP20-04  
 Bohlman, M., VP11-01  
 Bohris, C., BR5-05  
 Bolenz, C., O2-08  
 Boll, D., BR2-07  
 Bonaccorsi, A., VP26-20  
 Bongiovanni, L., MP10-06  
 Bonkat, G., MP21-12, MP23-14  
 Borges, L., MP16-04  
 Borisenko, E., MP8-06, VP9-14, VP14-15  
 Bornemann, J., BR8-07, O4-02  
 Borok, A., MP18-01  
 Borzouei, B., MP4-01, MP21-15  
 Bosco, A., VP25-07  
 Bosl, M., BR4-09  
 Bove, A., MP20-06, MP20-16, VP12-11, VP27-07  
 Bowen, A., VP5-05, VS13-02  
 Bowens, R., MP15-04  
 Bowman, R., BR2-01, MP6-05, MP8-04, VP17-01  
 Box, G., MP22-06  
 Boylu, U., MP5-10, MP5-11, MP11-04, MP11-10, MP11-11, MP13-06, MP15-05, MP17-15, MP17-16, MP20-07, MP20-09, VP2-19, VP5-05, VS4-01, VS7-01, VS13-02, VS13-04, VS20-09  
 Bozkirli, I., VP24-06  
 Bozkurt, I., MP23-15  
 Bracho II, J., MP13-13, MP17-08, VP27-17  
 Bramwell, S., MP16-03  
 Branco, A., VS19-02  
 Brandina, R., VP8-01, VP11-10, VP17-04, VP17-08, VP17-11, VP17-15, VP19-07, VP19-11, VP25-07, VS4-06, VS17-01  
 Bratti, E., VP26-06  
 Breda, A., VP7-01, VP11-12, VP22-16, VP28-14  
 Breda, G., VS2-01, VS7-08, VS10-06, VS11-07, VS20-06  
 Bredasan, G., VS10-06  
 Brethauer, S., VP6-11, VP19-04, VS7-02, VS7-04  
 Brewer, M., MP2-04  
 Brewster, S., MP18-13  
 Brites, R., VP3-06, VP12-15  
 Brito, A., MP16-04, VP6-03  
 Bromberger, G., VP2-18, VP13-09  
 Brown, C., MP18-20, VP11-11  
 Brown, S., O2-07  
 Bruhn, A., MP3-07  
 Brüning, F., BR6-04  
 Bryant, L., O3-05, VP21-13  
 Bubeck, J., VP14-09  
 Buchholz, N., MP2-11, MP8-19, MP16-16, MP16-17, MP24-13, VP23-10  
 Bucuras, V., MP9-19, VS5-09  
 Burchardt, M., O2-09, VP17-09  
 Burger, M., VP16-12  
 Burnapp, L., VP9-08  
 Butterworth, P., MP4-06  
 Buzogány, I., VP17-18  
 Byun, S., MP15-02, MP20-10
- C**  
 Cabello, J., VP21-18  
 Cabral, I., VS9-04  
 Caddeo, G., VP28-01  
 Cadeddu, J., BR1-05, MP6-03, MP16-11, MP18-14, VP8-02, VP28-05  
 Cadieux, P., BR7-05, MP22-05, MP22-12  
 Cain, C., MP19-20, VP18-01, VS7-03  
 Caire, A., O2-04, VP10-11  
 Cakam, M., VP11-09  
 Camargo, I., MP13-12  
 Campbell, S., VP25-07, VS16-07  
 Campitelli, A., VP19-20  
 Campos, R., O3-01, O6-01, O6-02, VP9-16, VP13-08, VP13-10, VP17-03, VP17-12, VP22-08, VP22-09, VP22-10, VP22-11, VP22-12, VP24-10, VP25-05, VP25-06, VP25-11  
 Canales, B., MP13-16  
 Cançado, B., VS3-04  
 Canes, D., MP5-17, MP19-09, VS4-03, VS7-05, VS10-03, VS19-02  
 Cangunen, O., VP15-10  
 Canvasser, N., MP5-09  
 Cao, M., MP16-15  
 Cardin, A., VP23-04  
 Carey, R., VP7-08, VP20-07, VP20-13  
 Carlo, B., MP1-07, MP1-08  
 Carlucci, J., MP11-16, MP15-07, VP20-06, VP20-10, VP20-14  
 Carmona, O., VS4-03, VS7-05, VS10-03, VS10-10, VS14-09, VS19-02  
 Carpentier, P., VP5-01, VP20-19, VS16-04, VS16-05, VS16-06  
 Cartledge, J., MP14-08  
 Cartlidge, D., BR1-01, O1-02, MP12-18, VP6-01, VP10-20, VP21-01  
 Casanova, N., MP23-06  
 Caskurlu, T., VS2-10, VS8-08  
 Castillo, O., O3-01, O6-01, O6-02, VP9-16, VP13-08, VP13-10, VP17-03, VP17-12, VP22-08, VP22-09, VP22-10, VP22-11, VP22-12, VP24-10, VP25-05, VP25-06, VP25-11  
 Castle, E., O2-10, VP20-02  
 Cathelineau, X., O1-06, O3-02, O6-04, MP1-05, VP1-20, VP6-20, VP12-02, VP12-08  
 Cauberg, E., MP7-10  
 Cauda, F., MP10-14  
 Cauni, V., MP9-01, VP26-01, VS12-03  
 Cavallone, B., MP12-15, VP12-18, VP25-03  
 Çelik, H., BR2-06  
 Celia, A., MP14-19, VS2-01, VS7-08, VS10-06, VS11-07, VS20-06  
 Celik, O., O1-04, VS2-09  
 Cellarius, C., O2-05, VP20-04, VP20-09  
 Cetti, R., MP8-02  
 Chachashvili, A., MP2-12  
 Chae, Y., MP19-10  
 Chaib, M., VP10-19  
 Chakravarti, A., BR1-02, BR1-10, O1-08, VP10-20, VP21-01, VP21-02, VP21-04, VP21-05, VP28-18  
 Challacombe, B., BR7-10, VP21-11  
 Chamberlin, J., MP13-04, VP19-08  
 Chan, S., VP14-10, VP19-03  
 Chandrasekar, T., MP11-15  
 Chang, A., MP15-16, VP20-03  
 Changjun, Y., MP20-02, VP1-08, VP12-05, VP25-04  
 Chaozhao, L., MP9-13, MP12-01  
 Chapin, B., MP10-19  
 Chappell, B., MP7-18  
 Charalambas, D., VP15-06

- Chatterton, K., MP7-18  
Chauhan, S., O2-02, MP11-02, MP11-03, VP20-01, VS13-01, VS14-01, VS14-02, VS14-03, VS14-08  
Chaussy, C., BR4-09, BR8-06, O1-01, O2-06, MP1-16, MP17-07, VP18-20  
Chawla, A., VP24-02, VS12-06  
Cheetham, C., MP1-12  
Cheetham, P., O6-07, MP1-09, MP1-10, MP1-11, MP11-14, MP15-01, MP15-06, MP18-13  
Chen, C., MP6-19  
Chen, H., MP16-15, MP19-07, MP23-08  
Chen, Q., MP7-11, MP19-07, MP23-08  
Chen, V., MP6-13, VP19-19  
Chen, Y., MP16-15, MP19-07, MP23-08  
Chepurov, A., MP19-08  
Cheung, H., VP14-06  
Chew, B., BR7-05, BR7-06, MP4-02, MP8-16, MP13-09, MP24-18, VP4-06, VP28-16  
Chiarissi, M. Lucci, VP12-03, VP12-04, VP12-09, VP25-03  
Chien, G., MP1-12, MP24-14, VP20-08, VP21-13  
Chiruvella, M., VP1-15  
Chiu, Y., VP14-10, VP19-03  
Cho, J., O6-08, MP4-17, MP7-09, MP13-08, VP2-16, VP8-06  
Cho, M., VP14-07  
Cho, W., MP5-14, MP6-10, MP11-13  
Choe, C., VP17-05  
Choi, E., MP11-18, MP15-09  
Choi, H., MP21-03  
Choi, J., O6-08, MP4-17, MP7-09, MP13-08, VP8-06  
Choong, S., MP5-07, VP3-13  
Chrisanthacopoulos, G., MP19-05  
Christensen, T., VS17-10  
Christoulakis, I., MP19-05  
Chu, S., VP9-15  
Chuanliang, X., BR7-01  
Chun, L., MP23-13  
Chung, B., VS12-04  
Chung, D., BR6-03  
Chung, H., VP12-16  
Chung, J., MP5-08, MP5-13, MP6-10, MP20-05  
Churchill, B., VP28-14  
Cianci, F., VS9-07  
Cicccone, P., MP24-04  
Cicek, T., MP21-11, VP4-08, VP4-20  
Cicekbilek, I., VP4-01, VP4-11  
Ciftcioglu, A., VP6-15  
Clark, D., MP12-06  
Clarke, H., O3-03, VP1-07  
Clayman, R., MP4-18, MP5-09, MP6-07, MP6-17, MP7-17, MP18-04, MP18-15, MP22-06, MP23-16, MP24-09, VP11-14  
Cloyd, J., VP26-14  
Coe, F., MP16-10  
Coelho, R. Ferreira, MP11-02, MP19-02, O2-02, VP20-01, VP20-02, VS13-01, VS14-01, VS14-02, VS14-03, VS14-08  
Coelho, R., MP11-03  
Cohen, M., VP5-12, VP5-13, VP5-14, VP5-16  
Colombo, Jr, J., VP6-03, VP6-06  
Colon, A., MP11-15, VP16-09  
Colon-herdman, A., VP16-09  
Colquhoun, A., MP4-06  
Coman, I., VS7-10  
Comsa, C., MP9-19, VS5-09  
Comunoglu, N., BR3-09  
Connor, L., MP7-08  
Connors, B., BR5-10  
Conradie, M., VP2-04  
Constantinescu, E., VS12-03  
Cooper, A., MP2-12  
Cordima, G., MP3-19  
Cordivari, C., MP23-04  
Coronato, E., MP15-03  
Correia, H., MP1-13, MP18-05  
Corvin, S., VP2-18, VP13-09  
Coskuner, E., VS12-02  
Cossu, M., MP7-15, MP24-10, VS1-06, VS11-02, VS12-01  
Costa, A., VP26-20  
Coughlin, G., O2-02, MP11-03, VS14-02, VS14-03  
Cracco, C., MP7-15, MP24-10, VS1-06, VS11-02, VS12-01  
Crenshaw, T., MP16-19  
Crosby, A., BR1-09  
Crouzet, S., MP17-11, MP19-04, VP1-03, VP1-04, VP1-14, VP6-07, VP6-11, VP8-05, VP8-08, VP8-11, VP19-04, VP20-12, VP20-16, VS7-02, VS7-04, VS7-07, VS16-10, VS18-05  
Crowe, A., BR7-06  
Crum, L., VP18-09  
Cunha, A., VP6-18, VS2-02, VS3-04, VS4-08  
Cunitz, B., VP18-09  
Cunningham, I., MP13-18  
Cuomo, B., VS10-03  
Curcio, L., VP6-18, VS2-02, VS3-04, VS4-08, VS9-04
- D**  
D'addressi, A., MP7-06, MP10-06, MP10-07, MP23-01  
D'amico, F., VP10-03  
D'armiento, M., VS5-05  
Da-zhi, L., O3-09  
Da-zhi, VP3-12  
Daels, P., MP4-19  
Daffara, F., MP6-09  
Dahmani, A., VP13-17  
Dakwar, G., MP13-03  
Damiano, R., MP12-13  
Danilovic, A., VP4-03  
Danisman, A., MP16-20  
Danisoglu, M., VS19-01  
Das, N., BR3-02, MP13-20  
DasGupta, P., BR7-08, BR7-10, MP23-04, VP6-02, VP21-11  
Dasgupta, R., VP15-03  
Dash, A., MP6-07  
Daskalopoulos, G., VP18-06  
Dauster, B., VS20-08  
Davenport, D., MP12-03  
David, R., MP24-06  
David, S., MP7-14  
Davis, J., MP11-09, VP5-17  
Dayanc, M., MP4-15, MP9-10, MP9-12, MP22-09, MP22-10, VP10-10, VP12-12, VP14-19, VP15-01, VP23-08, VP23-09, VP24-11, VP26-19, VS3-06, VS6-02  
De andrade, R., VS4-03, VS10-03, VS14-09, VS19-02  
De carne, C., VP5-15, VP20-05, VS14-07  
De castro, R., VP24-01  
De juan, K., VP3-06, VP12-14, VP12-15  
de Juan, Mrs. Kelly, O2-11  
de la Rosette, J., BR3-01, MP4-03, MP7-10, VP14-01, VP19-15  
De la taille, A., VS5-10  
De la torre, J., MP22-16  
De laet, K., VS5-10  
De lima favaretto, R., MP16-07  
de lima, M. Lopes, VP17-19  
De lisa, A., VP28-01  
de lorca, A. Pérez-lanzac, MP6-15  
De lorca, A., VP22-06  
De marco, F., BR4-06  
de Mattos, M. Augusto Elias, MP16-07  
De naeyer, G., VP5-01, VP20-19, VS16-04, VS16-05, VS16-06  
Dénes, F., MP10-13  
De reijke, T., MP7-10  
De sio, M., MP12-13, MP18-19, VS5-05  
De stefani, S., BR5-09, VP5-15, VP18-08, VP20-05, VS4-09, VS9-06, VS14-07, VS15-08  
Deane, L., MP12-17, VP21-12  
Decastro, J., MP5-16  
Degirmenci, T., MP14-10, VP7-12, VP7-13, VP21-10, VP21-14, VP22-14  
Deklaj, T., MP11-06, VP1-01, VP1-13  
del busto, E. Fernandez, VP23-03  
del busto, E. Fernández, MP19-14  
Del cura, J., MP13-12  
Del nero, A., VP26-08  
Delgado, M., VP6-10, VP6-12, VP6-19  
Deliveliotis, C., O5-09, MP21-19  
Delman, K., MP5-12  
DeLong, J., MP17-18  
Demesmeaker, M., VP3-20  
Demiray, M., VP28-10  
Demirel, F., MP20-17, VP2-03, VP11-09

- Deniz, N., VP24-06  
 Denstedt, J., MP13-18  
 Denzinger, S., VP16-12  
 Deok-hyun, N., VP17-16  
 Derweesh, I., VP8-13, VP17-05, VP21-15, VP22-20, VP27-08  
 Desai, A., VS17-10  
 Desai, M., MP2-20, MP4-13, MP8-18, MP9-09, MP13-11, VP2-01, VP4-17, VP8-01, VP8-02, VP11-10, VP14-02, VP17-02, VP17-04, VP17-08, VP17-11, VP17-15, VP19-07, VP19-11, VP21-08, VP22-01, VP23-07, VP26-13, VP26-17, VP27-13, VP28-05, VS3-01, VS3-03, VS3-03, VS4-06, VS5-04, VS18-03, VS18-10, VS18-10, VS19-07  
 Desai, V., MP11-05  
 Desai, VP3-12, MP11-05  
 Devaraju, S., VP13-04, VP13-07  
 Dhawan, D., VS18-03, VS18-10  
 Di biase, G., VP6-18, VS2-02, VS3-04, VS4-08  
 Di grazia, E., VS4-03  
 Di mauro, U., VP19-20, VS4-04, VS6-05, VS10-02, VS17-06  
 di mauro, U., VP19-20, VS4-04, VS6-05, VS10-02, VS17-06  
 Diaz, J., VP11-13, VP13-11, VP16-11, VP21-06, VP25-10  
 Dich, J., O3-08  
 Dickstein, R., MP8-09, VP1-06, VP9-03, VS14-04  
 Dietel, A., O6-06, MP12-12, VP10-04, VP10-08, VP10-13, VP10-15, VP12-07, VS18-09  
 Ding, Q., MP7-12, VP3-11, VP9-04, VP9-05  
 Dinney, C., VP5-17  
 Dipak, R., MP22-15, VP18-14  
 Distasio, A., VP2-02  
 Ditrolio, J., MP16-13, MP24-04  
 Djaladat, H., VS3-09, VS9-05  
 Do, M., BR1-08, O6-06, MP12-12, MP18-09, VP10-04, VP10-08, VP10-13, VP10-15, VP12-07, VS8-02, VS18-09  
 Dogan, H., BR6-02, VS6-01, VS10-07, VS18-01, VS19-01  
 Doherty, A., MP3-13  
 Dom, P., VP1-12  
 Dominguez, J., VP1-02  
 Donahue, S., MP21-06  
 Dong-deuk, K., VP17-16  
 Dongwen, W., MP23-13, VP13-13, VP16-03, VP27-19  
 Dönmez, M., O5-01  
 Donnally, C., MP3-10, MP6-03  
 Doo, S., MP15-02  
 Doran, S., MP9-17, VP21-09, VP24-04, VP24-07, VP25-09, VP27-05  
 Dorea, L., VS20-08  
 dos santos, F. Chagas, VP3-06, VP12-15  
 Doulton, T., MP3-13  
 Duarte, R., VP6-03, VP6-06, VS9-01  
 Duffey, B., BR3-07  
 Dulabon, L., MP10-08, VP5-06, VS4-02  
 Duman, I., O1-04  
 Dunn, R., MP18-12, MP23-06  
 Duran-castro, O., VP3-05  
 Durbin, J., MP1-18, MP6-02, MP13-19, VP26-05  
 Durt, K., MP7-07  
 Duryea, A., VP18-01  
 Dusseault, B., MP12-03  
 Dvoynikov, S., O1-01
- E**  
 E-lusseiny, T., MP16-17  
 Ebaid, G., MP10-13, VP4-03  
 Ebrahimi, K., BR2-01, MP6-04, MP6-04, MP6-05, MP8-04, VP17-01, VP19-08, VS18-02  
 Eden, C., BR1-02, MP12-04, MP12-05, MP19-12, VP10-06, VP10-07, VP10-14, VP12-19, VP20-18  
 Eder, F., VP16-12  
 Efthimiou, I., MP19-05, MP19-11, VP23-13  
 Eisner, B., MP9-07, MP10-10, MP16-18, VP26-14  
 El douaihy, Y., MP11-20, VS14-05  
 El-husseiny, T., MP2-11, MP8-19, MP16-16, MP24-13, VP23-10  
 Elhage, O., VP6-02, VP21-11  
 Elhaj, S., VP4-15  
 Elnahas, A., VS5-01  
 Elwood, C., BR7-05, BR7-06  
 Emtage, J., VP12-19, VP23-11  
 Engel, N., VP12-13  
 Enshaie, A., VP26-02  
 Eraky, I., VS5-01  
 Ercolani, M., MP15-09, MP15-12  
 Erdogan, S., VP27-05  
 Erdogru, T., O1-04, MP16-20, VP6-15, VS2-09  
 Erhard, M., VS19-10, VS20-10  
 Erkan, E., VP28-10  
 Erol, B., BR2-08, BR5-06, VP18-02  
 Ersoy, H., VS1-05  
 Ersoy, O., BR2-06  
 Erturhan, S., VP15-10  
 Erturk, E., MP1-02, VS12-08  
 Esch, E., BR5-01  
 Esen, T., MP5-03, MP14-13  
 Eshratkhab, R., VP28-07  
 Eslahi, A., VP28-17  
 Esquena, S., VS18-06  
 Esquivel, S., VS5-10  
 Eswara, J., MP10-19  
 Etafy, M., MP21-17  
 Eto, M., MP13-02
- Eun, D., MP15-10  
 Evan, A., BR5-10, MP2-10, MP16-10  
 Eversman, W., VP16-04  
 Ezatzadegan, S., VP28-06
- F**  
 Fabrizio, M., VP22-20  
 Falahatkar, S., MP5-01, MP9-02, VP26-02  
 Falsaperla, M., VP26-20  
 Fareed, K., VP20-16  
 Farkas, L., MP2-07, VP17-18  
 Fatikhov, R., MP8-06, VP9-14, VP14-15  
 Fausto, P., VP13-15, VS2-06  
 Fehr, J., VP12-13  
 Feicke, A., VP7-07  
 Feike, A., MP21-12  
 Feng, T., MP13-07  
 Feria, M., O3-01, O6-02, VP9-16, VP17-03, VP22-10, VP22-11, VP22-12, VP25-06  
 Feria-Flores, M., VP9-16, VP22-11, VP22-12, VP25-06  
 Feria-floresl, M., VP22-10  
 Fernandez, I. Gomez, VP9-01  
 Ferrandino, M., BR2-07, BR5-01, BR6-10, O2-04, MP3-10, VP19-19  
 Ferraro, M., VP11-05  
 Ferriero, M., BR8-08, VP1-11, VP2-14, VP11-07, VP11-15, VP22-07, VP28-11  
 Ferrigni, R., VP20-02  
 Ferro, F., VS9-09  
 Feussner, H., O1-03  
 Figenschau, R., BR3-02, MP6-19, MP13-20, VS13-07, VS13-08, VS13-09, VS17-10  
 Figueiredo, Á.M., VP3-06, VP12-14, VP12-15  
 Figueiredo, M., O2-11, O2-11  
 Figueroa, A., O3-05, VP21-13  
 Finkelstein, J., VP5-06  
 Finley, D., MP15-16, VP20-03  
 Finnigan, T., BR1-01, BR1-02, BR1-10, O1-08, MP12-18, VP6-01, VP21-01, VP21-05, VP28-18  
 Fiori, C., MP6-09, MP12-15, VP1-10, VP1-17, VP1-18, VP2-02, VP12-03, VP12-04, VP12-09, VP12-18, VP17-10, VP25-03, VS3-10, VS6-04, VS15-06  
 Fischer, B., VP12-13  
 Fitouri, Z., VP13-17  
 Flinspach, B., O2-03  
 Flores, J., BR5-03  
 Fokitis, I., VP28-08  
 Foneron, A., O3-01, O6-01, O6-02, VP9-16, VP13-08, VP13-10, VP17-03, VP17-12, VP22-08, VP22-09, VP22-10, VP22-11, VP22-12, VP24-10, VP25-05, VP25-06, VP25-11

Fonteyne, E., VP5-01, VP20-19, VS16-04, VS16-05, VS16-06  
 Forastiere, E., BR8-08, MP20-06, MP20-16, VP1-11, VP11-07, VP11-15, VP12-11, VP22-07, VP27-07, VP28-11  
 Forde, A., VP21-03, VP23-12  
 Fornara, P., O1-07, O3-04, VP12-01  
 Forsmark, C., MP5-19, VS10-08  
 Fortes, M., MP16-05  
 Foschi, N., MP10-07  
 Fowler, C., MP23-04  
 Fowlkes, J., VS7-03  
 Fracchia, J., VP13-19  
 Frampton, C., MP7-16  
 Francesco, P., VS3-02, VS17-04, VS20-07  
 Francis, R., MP18-14  
 Franco, G., VS3-02, VS8-02, VS17-04, VS20-07  
 Franke, E., MP23-05  
 Franz, T., BR1-08, MP18-09  
 Fraundorfer, M., MP7-16, VP14-13  
 Freire, R., VP6-18, VS4-08  
 Fritsche, H., MP1-04, VP11-08, VP16-12  
 Froheberg, D., O1-10  
 Frohme, C., MP23-02, MP23-03  
 Frush, D., BR6-10  
 Fu-lin, L., BR2-05, BR6-01  
 Füller, S., VP3-08  
 Fucs, M., VS20-08  
 Fujimoto, K., VP27-09  
 Fukatu, A., MP14-02  
 Funahashi, Y., MP14-20  
 Furtado, P., VS20-08  
 Fyock, C., MP5-19, VS10-08

**G**

Gaboardi, F., VS7-06, VS8-07, VS10-04  
 Gaffi, M., VP10-03  
 Galanos, I., VP28-08  
 Galiano, M., O1-06, VP1-20, VP6-20, VP12-08  
 Galloway, R., BR7-09, VP22-19  
 Gallucci, M., BR8-08, O5-03, MP20-06, MP20-16, VP1-11, VP2-14, VP11-07, VP11-15, VP12-11, VP15-02, VP22-07, VP27-07, VP28-11  
 Gamal, A., MP9-03  
 Ganapathy, A., VP3-14, VP23-05  
 Ganick, S., VP1-06  
 Ganpule, A., MP9-09, VP2-01, VP4-17, VP14-02, VP17-02, VP21-08, VP26-13, VP26-17, VS3-01, VS3-03, VS5-04, VS18-10  
 Ganzer, R., O2-07, MP1-04, VP11-08, VP16-12  
 Gao, P., MP7-12, VP3-11, VP9-04, VP9-05  
 Gao, X., BR7-02, BR8-10, MP22-14, VP10-05, VP10-12, VP13-20, VP18-15  
 Garcia-ripoll, J. Torrecilla, VP23-03  
 Garcia-roig, M., O3-10

García-ripoll, J. Torrecilla, MP19-14  
 Gardi, M., MP23-01  
 Gardner, M., MP6-19, VS17-10  
 Gardner, T., MP17-05  
 Gargouri, M., VP9-09  
 Gasanov, F., VS6-01  
 Gash, J., MP10-05  
 Gasser, T., MP21-12, MP23-14  
 Gayed, B., MP21-04  
 Geavlete, B., BR8-02, MP7-01, MP7-02, MP7-03, MP8-05, MP9-01, MP16-02, MP24-01, MP24-02, VP9-13, VP26-01, VP26-10, VS11-03, VS12-03  
 Geavlete, P., MP7-01, MP7-02, MP7-03, MP8-05, MP9-01, MP16-02, MP24-01, MP24-02, VP9-13, VP26-01, VP26-10, VS11-03, VS12-03  
 Gelman, J., MP23-16  
 Geltzeiler, M., VP1-06  
 Geng, J., VP3-11  
 George, A. K., MP14-06, VP17-14  
 George, A.K., VP28-13  
 George, A., MP23-19, VP7-09, VP7-10, VP27-03, VS6-06, VS16-08  
 Georgescu, D., MP7-01, MP7-02, MP7-03, MP8-05, MP16-02, MP24-01, VP9-13, VP26-01, VS12-03  
 Georgiadis, M., MP9-19, VS5-09  
 Georgiou, A., O2-09  
 Georgiou, C., VP28-08  
 Georgiou, M., MP13-13  
 Georgoulas, D., MP8-11  
 Germinale, F., BR8-03, VP23-01  
 Germiyanoglu, C., BR1-03, BR2-06, O6-09, VP6-04, VP17-06, VP23-02, VS9-02  
 Gewher, E., MP8-20, MP9-20, MP10-09, MP23-07, VP10-01, VP10-02, VP12-20, VP13-16, VP15-12, VP18-10, VP24-08, VP24-09, VP27-10, VP27-11, VP27-12, VS4-05, VS11-09, VS15-09, VS17-09  
 Ghanbari, VP7-05, MP5-01  
 Ghanbarifard, E., BR7-04  
 Ghazi, A., VP12-06, VP19-02, VP25-01, VP25-19, VS6-07, VS12-10  
 Ghazi, A. a., VP19-02, VP25-19  
 Ghiculete, D., MP2-06, MP4-04, MP14-03, VP4-02  
 Ghochani, A. Malaek, MP18-01  
 Ghohestani, S., VP28-07  
 Giakoumelos, A., VP28-12  
 Gialas, I., VP23-13  
 Gil, M., MP5-08, MP5-13, MP20-05  
 Gill, I., MP14-15, VP1-04, VP1-14, VP8-01, VP17-04, VP17-08, VP17-11, VP17-15, VP19-07, VP19-11, VP21-08, VP25-07, VP28-05, VS4-06, VS7-05, VS10-03, VS10-10  
 Gilleard, O., MP2-14  
 Gilling, P., MP7-16, VP14-13

Gillitzer, R., MP2-15, MP11-19, MP24-19  
 Ginsberg, P., MP15-03  
 Giordano-nappi, J., VS9-01  
 Glaritis, D., VP18-06  
 Glass, J., MP3-13, VP3-18, VP15-03  
 Gleason, J., MP1-12, MP23-05, MP24-14  
 Glisson, C., BR7-09, VP22-19  
 Gnade, B., MP16-11  
 Gnessin, E., MP3-17, MP4-11, MP4-12, VP9-02  
 Godebu, E., VP21-15  
 Goel, R., MP17-03, MP17-11, MP19-04, VP6-07, VP8-05, VP8-08, VP8-11, VP13-05, VP19-04, VP20-12, VP20-16, VS7-04, VS16-07, VS16-10, VS18-05  
 Goh, A., MP19-03, VS6-03, VS15-05  
 Gohel, D., MP2-08, MP22-04  
 Gohel, M., MP3-08, MP21-07  
 Gokcen, K., VS10-07  
 Goktas, C., VP15-10  
 Goktas, S., VP23-09  
 Gokten, O., BR6-02  
 Golash, A., BR1-01, BR1-02, BR1-09, BR1-10, O1-02, O1-08, MP12-18, MP19-12, VP10-20, VP11-03, VP12-19, VP19-12, VP20-18, VP21-01, VP21-02, VP21-04, VP21-05, VP23-11, VP28-18  
 Golestan, B., BR3-06  
 Golijanin, D., VP8-10, VP20-20, VS12-08, VS16-03  
 Golombos, D., MP1-14, MP1-15, MP1-17, MP15-18, MP15-20, MP20-12  
 Gonen, M., VP4-08  
 Gonzalez, R. Calvo, VP23-03  
 Gonzalez, V., MP11-05, VP6-19  
 Gonzalgo, M., VP25-18  
 Goo, L. Young, MP20-11, VP5-18  
 Goossens, B., VP3-08  
 Gordetsky, J., VP20-20  
 Goto, K., MP1-06  
 Gotoh, M., MP14-20, MP20-04  
 Gotto, M., VP10-19  
 Goumas, I. Kartalas, MP3-19, VP26-08  
 Gözen, A., MP18-11, VP7-11, VS3-08, VS20-01  
 Graham, S., MP5-07, VP3-13  
 Granata, A., VS7-06, VS8-07, VS10-04  
 Grande, S., MP7-15, MP24-10, VP1-10, VP1-17, VP2-02, VP12-03, VP12-04, VP12-09, VP12-18, VS1-06, VS11-02  
 Grange, P., MP18-20, VP11-11  
 Gratzke, C., BR6-07  
 Gravas, S., MP2-16  
 Greco, F., O1-07, O3-04, VP12-01  
 Green, T., MP1-02, VP3-17, VP15-11  
 Greene, D., BR7-07, MP8-04, MP13-04, VP19-08  
 Greene, T., MP1-02  
 Greenstein, A., VP3-03



- Greenwood, J., MP22-11  
 Gregori, A., VS7-06, VS10-04  
 Gritsch, A., VP7-01, VP22-16  
 Gritsios, P., VP28-12  
 Grocela, J., MP7-19  
 Gromatzki, C., VS9-09  
 Gromatzky, C., MP10-13  
 Groos, A., VS6-10  
 Gross, A., BR4-03, BR4-10, O2-05, O4-06, O4-07, VP9-17, VP9-18, VP9-19, VP14-03, VP14-11, VP16-07, VP20-04, VP20-09, VP28-19  
 Gross, E., VP20-04  
 Gross, M., MP1-14, MP1-15, MP1-17, MP15-18, MP15-20, MP20-12  
 Gross, O., MP23-10, VP14-14  
 Grossman, B., VP5-17  
 Grosso, G., VS3-05  
 Gschwend, J., BR8-04, O1-03, VP16-10, VP21-07  
 Guaglianone, S., BR8-08, MP20-06, MP20-16, VP1-11, VP2-14, VP11-07, VP11-15, VP12-11, VP22-07, VP27-07, VP28-11  
 Guazzoni, G., MP14-19  
 Guida, R., VS2-02  
 Guler, H., VP10-10, VP12-12, VS6-02  
 Gumpinger, R., BR5-05, VS3-08, VS20-01  
 Günay, L., VP4-15  
 Guner, B., VS2-10, VS8-08  
 Gungor, S., VS2-10, VS8-08  
 Gunlusoy, B., MP14-10, VP7-12, VP7-13, VP21-10, VP22-14  
 Guntaka, A., VP13-04, VP13-07  
 Guo, Z., VP25-15, VP25-16  
 Gupta, H., MP16-03  
 Gupta, M., MP4-16, MP9-08, MP19-16, MP22-19, MP24-20, VP3-04, VP7-06, VP22-17  
 Gur, A., VS9-03  
 Gurbuz, C., MP18-11, VS2-10, VS8-08  
 Gürbüz, C., O3-06  
 Gurbuz, N., MP22-08, VS3-07  
 Gursoy, E., VS18-01  
 Gurung, P., MP5-07  
 Gusmão, F., VS3-04, VS4-08  
 Gustafson, D., MP13-15  
 Gutierrez-Aceves, J., MP4-20, MP22-13  
 Guven, S., MP18-11, MP21-14, VP11-17  
 Guzzo, T., VP25-18
- H**  
 Ha, J., MP5-08, MP5-13, MP15-03, MP20-05, VP4-12, VP7-01, VP11-12, VP22-16, VP28-14  
 Ha, S., MP2-10, MP3-17, MP4-11, MP4-12, MP16-09, MP16-10, MP20-11, VP5-18, VP6-01, VP27-02  
 Ha, U., MP12-20  
 Ha, Y., MP3-05, MP5-18, VP24-12  
 Haber, G., MP14-15, MP17-03, MP17-11, MP19-04, VP1-03, VP1-04, VP1-14, VP6-07, VP6-11, VP8-05, VP8-08, VP8-11, VP13-05, VP19-04, VP20-12, VP20-16, VS7-02, VS7-04, VS7-07, VS16-07, VS16-10, VS18-05  
 Habuchi, T., MP14-04, VP7-04  
 Häcker, A., BR4-03, O4-06, MP12-08, MP12-09, VP3-16  
 Haecker, A., VP4-18, VP14-03, VP14-11, VP14-12  
 Haefner, T., MP12-12, VP10-08, VP10-15, VS8-02  
 Haferkamp, A., MP2-09  
 Hafez, K., VP5-08  
 Haichao, Y., MP5-18, VP24-12  
 Ha jeong, S., MP20-11, VP5-18  
 Hakky, T., VP7-08, VP20-07, VP20-13  
 Haleblian, G., MP9-11  
 Hall, J., VP4-12  
 Hall, T., BR4-02, MP19-20, VS7-03  
 Hamawy, K., MP19-09  
 Hamid, S., VP6-01  
 Hamilton, N., O3-03, VP1-07, VP2-13, VP18-04, VS19-04  
 Hammerl, H., VP2-18, VP13-09  
 Hammes, C., VP3-16, VP4-18  
 Hampel, C., MP2-15, MP11-19, MP24-19  
 Hamza, A., O1-07, O3-04, VP12-01  
 Han, D., MP4-17, MP10-15, MP19-10, MP23-17, VP8-04, VP8-06  
 Han, K., VP6-05  
 Han, M., MP2-13, MP2-14, MP15-14, MP22-17  
 Han, O., VS19-03  
 Han, W., MP14-14, VP22-15  
 Hanbiao, X., MP5-18, VP24-12  
 Hanci, V., BR5-06, VP18-02  
 Handa, R., BR5-10  
 Handa, S., MP2-10, MP3-17, MP4-11, MP4-12, MP16-09, MP16-10  
 Hanna, M., MP2-13, MP2-14, MP22-17  
 Hao, G., VS6-09, VS12-05  
 Haq, A., MP18-20  
 Harabayashi, T., VP27-01  
 Harada, H., MP5-02  
 Haramis, G., MP18-10, VP7-06  
 Hareh, T., MP3-18, MP21-10, MP22-03, MP23-09, MP24-08, VP4-07, VP9-07, VP11-16  
 Harmon, J., MP15-03  
 Harnisch, B., VP9-03  
 Harper, J., VP7-01, VP11-12, VP22-16, VP28-14  
 Harrer, K., O4-06  
 Hashemi, M., VP6-16  
 Hashim, Z., BR1-09, O1-02, MP12-18, MP19-12, VP6-01, VP20-18  
 Hasner, F., BR8-06, MP1-16  
 Hassanpour, A., MP8-03, VP28-02  
 Hatiboglu, G., MP2-09  
 Hattori, R., MP14-20  
 Hattori, R., MP20-04  
 Hatzimouratidis, K., VP28-12  
 Hautmann, R., O1-10  
 Havranek, E., MP2-13, MP7-20  
 Hawkes, D., BR7-08  
 Hayashi, M., MP1-06  
 Hayashi, T., MP1-06  
 Hedgepeth, R., MP15-15, MP18-12  
 Hedican, S., MP13-01, MP14-07  
 Hee jong, J., VP9-06, VP17-13  
 Hefermehl, L., MP23-10, VP14-14  
 Hegarty, N., VP3-18  
 Hegele, A., MP22-02, MP23-02, MP23-03  
 Heinrich, E., O2-08, VP14-12  
 Heldwein, F., VP6-20  
 Hell, J., MP12-09  
 Hellawell, G., VS8-02, VS18-09  
 Hempel, C., VS7-03  
 Hendlin, K., BR6-08  
 Hentschel, H., MP4-09  
 Hentschel, M., MP4-09  
 Herati, A.S., VP7-10  
 Herati, A., MP12-07, MP14-06, MP18-16, MP23-19, VP2-16, VP8-03, VP10-18, VP17-14, VP19-16, VP27-03, VP27-06, VS18-04  
 Herati, A.S., VP28-13  
 Heretis, J., VP18-05, VP18-06  
 Herguedas, E. Valsero, VP23-03  
 Hermanns, T., O6-05, MP23-10, VP7-07, VP14-14  
 Hermes, B., BR8-07  
 Hernandez, J., MP24-07  
 Herrell, D., VP2-20  
 Herrell, S., BR7-09, MP3-03, MP4-07, VP1-05, VP22-19  
 Herrmann, T., O2-09, O5-06, VP14-03, VP14-11, VP17-09, VS1-01, VS6-10  
 Herzog, K., MP1-16  
 Hickling, D., VS8-06  
 Higashihara, E., MP19-15  
 Hill, B., BR2-01  
 Hinck, B., BR3-07  
 Hinshaw, L., MP13-01  
 Hirahara, N., VP17-20  
 Hirai, K., MP14-16  
 Hirao, Y., VP27-09  
 Hirata, Y., VP25-08  
 Hisano, M., MP20-14, VP6-03, VP6-06, VP10-19, VS9-01  
 Ho, H., VP16-07  
 Ho, K. Seok, VP5-20  
 Hocaoglu, Y., BR6-07  
 Hoda, M., O1-07, O3-04, VP12-01  
 Hofmann, C., O5-05  
 Hofmann, R., BR6-04, MP22-02, MP23-02, MP23-03  
 Hohenfellner, M., MP2-09  
 Holland, R., VP9-02

- Hollenbeck, B., MP15-15, MP18-12, MP18-17
- Hondo, F., VS9-01
- Honeck, P., MP7-13, VP13-02
- Honey, R., BR6-03, MP2-06, MP4-04, MP14-03, VP4-02, VP4-06, VS5-06, VS17-05
- Hong, J., MP3-06, MP15-08, MP17-14
- Hong, K., O3-07, MP5-20, VP10-09, VP10-16, VP21-16, VP21-17, VP25-13
- Hong, S., MP12-20, MP15-02
- Hongo, F., VP27-04
- Hoon, C. Sang, MP20-11, VP5-18
- Hopkins, M., MP13-06, MP17-15, MP17-16, MP20-07, MP20-09
- Horasanli, K., MP21-05
- Horchani, A., MP9-18, MP22-20, VP9-09, VP11-18, VP13-17, VP18-18, VP18-19
- Horgan, S., VP8-13
- Horikawa, Y., MP14-04, VP7-04
- Horinaga, M., O6-03
- Horn, T., VP16-10
- Hornig, A., VP11-13, VP13-11, VP16-11, VP21-06, VP25-10
- Hoscan, M., VP14-19, VS3-06, VS12-09
- Hoşcan, M., VS9-03
- Hosek, W., VP11-01
- Hosoi, T., VP28-09
- Hosseini, M., MP8-03, VP26-15, VP28-02, VP28-06
- Hosseini, S., VP3-07, VP9-20, VS3-09, VS4-10
- Hou, S., VP14-06
- Hou, X., O3-07, MP5-20, VP10-09, VP10-16, VP21-16, VP25-12, VP25-13
- Hou, Y., BR8-05, MP7-11, VP22-13
- Hoznek, A., VS5-10
- Hrouda, D., MP7-20
- Hruby, G., MP5-16
- Hruza, M., O2-03
- Hsiao, W., MP5-12
- Hu, J., BR8-05, MP3-02, MP7-11, VP25-14, VP25-15, VP25-16, VP25-17
- Hu, W., O5-02, VP6-17
- Huang, G., VS5-07
- Huang, H., VP25-14
- Huang, J., VP25-14, VP25-15, VP25-16, VP25-17
- Huang, X., O5-02
- Huang, Y., MP5-20, MP16-15, MP19-07, MP23-08, VP10-09, VP10-16, VP21-17, VP25-12, VP25-13
- Hubert, K., VP24-01
- Hubosky, S., MP22-07, VP9-10
- Huck, N., BR4-03
- Huh, J., MP3-02
- Hui, X., VP4-05
- Humphreys, M., O2-10, MP13-09, VP14-18, VP16-04, VP19-13, VS8-04
- Hunter, D., VP3-05
- Huri, E., BR1-03, BR2-06, O3-06, O6-09, VP6-04, VP17-06, VP23-02, VS9-02
- Husband, W., VP6-17
- Hushmand, M., BR3-10
- Huynh, K., MP13-04
- Hwang, E., MP10-15, MP23-17, VP12-16, VS18-08
- Hwang, T., MP12-20, MP20-10
- Hwii, K. Young, VP5-19
- Hyams, E., MP3-07, MP8-01, MP9-07, MP10-08, VP11-06, VS4-02
- Hyo, K. Tae, MP11-13
- I**
- Iacone, M., VS4-04
- Ikejiri, D., VP6-06
- Ill sang, K., VP9-06, VP17-13
- Ill young, S., VP9-06, VP9-06, VP17-13
- Im, C., MP2-01, VP12-16, VS18-08
- Im, H., MP13-08
- Im, R., VP21-15
- Imagawa, M., MP14-16
- Imani, M., MP16-01
- Imbimbo, C., MP2-01
- Imkamp, F., O5-06, VS1-01
- Inaloo, R., VP28-02
- Incarbone, G., VS7-06, VS8-07
- Inci, K., VP4-15
- Inderbir, G., VP1-03
- Inferrera, A., O3-04
- Inneo, E., MP3-19
- Inoue, Miyabi, O1-09
- Inoue, Y., MP1-06
- Intilla, O., VP19-20, VS4-04, VS6-05, VS10-02, VS17-06
- Introini, C., BR8-03, VP23-01
- Ioritani, N., VP17-17
- Ip, K., MP22-04
- Ipekci, T., O1-04
- Irani, D., BR7-03, BR7-04
- Iriarte, I., MP13-12
- Irimie, A., VP3-01
- Irkilata, H., VP15-09, VP23-09, VP24-11
- Irwin, B., MP17-03, VP11-10, VP28-05, VS10-10
- Isfahani, F. Farahini, O5-08
- Ishibashi, T., MP6-08
- Ishidoya, S., MP6-08, VP22-02
- Ishii, Ayano, O1-09
- Ishii, D., VP2-17, VP7-03
- Ismail, F., VP21-11
- Issever, H., MP14-05, VP6-13
- Istanbulluoglu, M., MP21-11, VP4-08, VP4-20
- Istanbulluoglu, O., VS12-09
- Ito, A., MP6-08, VP22-02
- Itoh, N., VP2-08
- Itri, E., VP26-08
- Iwamura, M., VP2-17, VP7-03
- Izol, V., MP4-14, MP9-14, VP4-09
- J**
- J., Sijo, MP5-19, MP13-16, MP17-20, VP5-16, VS10-08
- Jack, E., VS15-03
- Jackman, S., MP21-16
- Jackson, M., MP16-12, MP21-13
- Jackson, R., MP23-06
- Jaffe, J., MP15-03
- Jain, A., VP3-17, VP15-11
- Jain, N., MP22-06
- Jain, V., VP2-01
- Jakobsen, M., O3-08
- Jakse, G., BR8-07, O4-02, MP7-07
- Jamal, J., VP13-19
- Jamshaid, A., MP2-05, MP2-19
- Janetschek, G., VP12-06, VP19-02, VP25-01, VP25-19, VS6-07, VS12-10
- Janitzky, V., MP4-09
- Jansen, R., VP2-13
- Jecu, M., MP7-03
- Jellison, F., MP6-05, MP13-04, MP13-05, VP17-01, VS5-07, VS18-02
- Jeon, H., MP14-14, VP1-16, VP5-18, VP10-17, VP22-15, VP22-15
- Jeon, S., O6-08, MP4-17, MP7-09, MP15-02, MP19-17, MP21-01, VP6-05, VP8-04, VP8-06
- Jeon, Y., MP3-05
- Jeong, B., O6-08, MP4-17, MP7-09, VP8-04, VP8-06
- Jeong, C., VP10-17, VP14-07
- Jeong, H., VP1-16, VP5-18, VP10-17, VP22-15
- Jeong, J., MP11-18, MP15-09, MP15-12
- Jeong, S., MP15-02
- Jeongki, L., MP23-12, MP24-15
- Jiang, C., VP25-14, VP25-15, VP25-16
- Jiang, H., MP7-12, VP3-11, VP9-04, VP9-05
- Jiang, L., MP13-10
- Jinxi, G., VP13-13
- Jitendra, A., MP3-18, MP22-03, MP22-15, VP18-14
- Joachim, G., BR8-07, O4-02, MP7-07
- Jocham, D., BR3-01
- Johannes, J., MP5-15, MP22-07
- Johansen, T., BR7-07
- John, H., VP12-13
- Johnson, P., VP1-02
- Jonas, D., MP13-17
- Jonat, L., MP4-02, MP24-18, VP28-16
- Jones, L., MP12-17, VP21-12
- Jones, R., MP18-02
- Jønler, M., O3-08, VP27-20
- Jorda, M., BR1-06, MP18-08
- Jordan, R., O6-10, VP18-13
- Jorge, M., MP21-09
- Joseph, J., MP1-02, VS12-08, VS16-02
- Joshi, H., MP22-11
- Joshi, V., MP21-10, VS7-01
- Jude, C., VS5-09

- Jun, L. Fu-lin, BR2-05  
 Jun, Z., MP9-13, MP12-01  
 Jung, H., MP11-01, MP14-01, VP8-09, VP18-16, VP20-08  
 Jung, S., MP5-08, MP5-13, MP20-05, VP12-16, VS18-08  
 Jung, W., MP3-05
- K**  
 Kabakci, A., VP18-11  
 Kabbani, W., BR1-05  
 Kabia, M., MP3-13  
 Kadi, N., MP12-06  
 Kadihasanoglu, M., MP9-16, MP21-05, MP22-18, VP15-04  
 Kadirov, Z., MP12-10  
 Kafka, I., MP10-17  
 Kai, X., MP5-05, VP25-02  
 Kailasam, K., VP3-14, VP23-05  
 Kallel, Y., VP13-17  
 Kallidonis, P., MP9-15, MP12-12, MP13-14, MP18-09, MP24-16, MP24-17, VP10-04, VP10-08, VP10-13, VP10-15, VP16-06, VS8-02, VS18-09  
 Kalogeropoulos, T., VP7-11  
 Kalogeropoulou, C., MP13-14, MP24-17  
 Kalomiris, P., MP19-11  
 Kalsi, V., MP23-04  
 Kamat, A., VP5-17  
 Kamihira, O., MP14-02, MP14-20, MP20-04  
 Kamoi, K., MP14-15, VP1-03, VP1-04, VP1-14, VP17-04, VP17-15, VP17-20, VP19-07, VP27-04, VS7-07  
 Kamranmanesh, M., MP16-06  
 Kanaan, E., VS9-04  
 Kane, C., VP8-13  
 Kang, D., MP11-18  
 Kang, S., MP12-20, MP20-10  
 Kang, T., MP3-06, MP15-08, MP17-14  
 Kanout, M., BR4-07  
 Kaouk, J., MP12-13, MP14-15, MP17-03, MP17-11, MP18-19, MP19-04, VP1-03, VP6-07, VP6-11, VP8-05, VP8-08, VP8-11, VP13-05, VP19-04, VP20-12, VP20-16, VS7-02, VS7-04, VS7-07, VS16-07, VS16-10, VS17-01, VS18-05  
 Kaplan, A., MP7-17, MP22-06, MP24-09  
 Kaplon, D., MP10-18, MP13-01, MP14-07, MP16-19  
 Kapoor, R., VP2-05, VP4-16, VP17-07  
 Kara, B., VP11-09  
 Kara, C., MP4-10, MP8-10, MP9-06, MP10-03, MP19-06, VP4-01, VP4-11  
 Karabuga, I., MP9-12, MP22-09, VP23-08  
 Karadeniz, M., VS2-07, VS20-04  
 Karagounis, T., VP18-05  
 Karakan, T., BR2-06, VP17-06, VS9-02  
 Karakoyunlu, N., VS1-05  
 Karakus, S., MP14-05, MP14-13, VP27-16  
 Karami, H., VP19-09  
 Karaoglan, U., VP24-06  
 Karatzas, A., MP2-16  
 Kargin, K., VP7-05  
 Karnabatidis, D., MP24-16  
 Karsli, O., MP4-14, VP21-09, VP24-07, VP25-09  
 Kashi, A., BR3-10, MP4-08, MP9-04, MP16-06  
 Kassim, S., VS2-05, VS2-08  
 Katsanos, K., MP24-16  
 Katz, A., MP1-09, MP1-10, MP1-11  
 Katz, M., VP1-01, VP1-13, VP20-17  
 Kaufmann, O., MP7-17  
 Kaver, I., VP28-15  
 Kavoussi, L., MP18-16, MP20-13, MP23-19, VP2-16, VP7-09, VP7-10, VP8-03, VP10-18, VP17-11, VP19-16, VP27-03, VP27-06, VP28-05, VS8-05, VS9-08, VS18-04  
 Kavoussi, L.R., VP28-13  
 Kavoussi, L.R., MP12-07, VP17-14  
 Kawa, G., MP14-18, VP12-17  
 Kawakita, M., VP12-17  
 Kawasaki, Y., MP6-08, VP22-02  
 Kawachi, A., VP1-04, VP17-20, VP27-04  
 Kaya, E., VP14-19  
 Kaygisiz, O., O5-01  
 Kazanskaya, I., O4-01  
 Kazoulis, S., MP19-05  
 Keane, T., O3-03, VP18-04  
 Keber, S., MP24-19  
 Keil, C., BR6-04, MP22-02  
 Kelly, T., MP13-05  
 Kendirci, M., MP9-16, MP22-18, VP15-04  
 Kent, P., VP5-11  
 Keoghane, S., MP8-02  
 Khafagy, R., MP14-08  
 Khaki, N., MP5-01, MP9-02  
 Khan, M., VS10-09  
 Khan, N., MP16-12, MP21-13  
 Khan, S., VP21-11  
 Khandkar, A., VS1-03, VS1-04, VS7-09, VS11-06, VS19-09  
 Kharodawala, S., VS7-09, VS11-06, VS19-09  
 Kheterpal, E., MP17-01, MP17-02, VS13-10, VS15-03, VS18-07  
 Khorrami, M., O5-08  
 Kiel, H., BR4-09, MP17-07  
 Kijvikai, K., VS17-02  
 Kikuchi, E., VP16-05  
 Kilani, H., VP2-07  
 Kilciler, M., MP22-10, VP10-10, VP12-12, VP15-09, VP26-19, VS6-02  
 Kilic, O., MP21-14  
 Kilicarslan, H., BR6-02  
 Kilinc, M., MP21-14, VP11-17  
 Kim, C., MP15-14  
 Kim, D., MP2-17, MP3-05, MP6-10, MP15-19, VS13-05, VS17-07  
 Kim, E., MP3-05, MP23-17  
 Kim, F., VP28-05  
 Kim, H., O6-08, MP4-17, MP7-09, MP15-17, MP20-03, MP21-03, VP1-16, VP8-04, VP10-17, VP22-15, VP27-02  
 Kim, I., MP11-18, MP15-09, MP15-12  
 Kim, J., MP15-17, MP19-17, MP20-03, MP21-01  
 Kim, K., MP14-02, VP18-16  
 Kim, M., MP6-12, MP19-03, VP19-18  
 Kim, S., MP5-08, MP5-13, MP13-08, MP13-08, MP20-05  
 Kim, T., MP5-14, MP6-10, MP11-12, MP15-17, MP20-03, VP18-16, VP24-03  
 Kim, W., O6-08, MP7-09  
 Kim, Y., MP2-17, MP3-05, MP10-15, MP10-15, MP13-08, MP23-17  
 Kimura, K., MP14-02  
 Kimura, M., MP6-12, VP19-18  
 Kinoshita, H., MP14-18, VP12-17  
 Kinukawa, T., MP20-04  
 Kira, S., VP9-11  
 Kiriluk, K., VP19-05  
 Kit, L. Chang, VP3-09  
 Klein, F., MP2-04, MP10-05  
 Klippstein, E., MP12-08  
 Kloen, S., MP7-10  
 Knichel-clarke, R., BR8-07, O4-02  
 Knoll, T., BR3-01, MP7-13, VP4-04, VP13-02, VP28-20  
 Knudsen, B., BR2-02, BR6-05, BR6-09, VP3-04, VP11-05  
 Kobayashi, Y., MP1-19, MP19-13  
 Kobayashi, Yasuyuki, O1-09  
 Koch, M., MP15-04  
 Koffman, G., VP9-08  
 Kolla, S., MP7-17, MP18-15, MP23-16, VP6-09  
 Komai, Y., MP14-18  
 Kommu, S., BR1-01, BR1-02, BR1-09, BR1-10, BR2-09, O1-02, O1-08, MP12-18, MP19-12, VP3-17, VP6-01, VP10-20, VP11-03, VP12-19, VP15-11, VP19-12, VP20-18, VP21-01, VP21-02, VP21-03, VP21-04, VP21-05, VP23-11, VP23-12, VP28-18  
 Kongchareonsombat, W., VP7-02  
 Kono, H., VP16-05  
 Koo, K., MP14-14  
 Koo, V., VP21-04  
 Kooby, D., MP5-12  
 Kooistra, A., VP1-12  
 Kordan, Y., BR6-02, VS10-07, VS18-01, VS19-01  
 Korets, R., MP9-08, MP19-16

Kosmaoglou, E., VP9-12, VS16-01  
 Kouriefs, C., MP18-20, VP11-11  
 Koutsiaris, E., MP1-03  
 Koyuncu, H., BR3-09, VP15-10  
 Kozinn, S., MP19-09  
 Kozomara, M., VP11-02  
 Krah, X., O1-10  
 Krambeck, A., O2-10, MP2-10, MP4-12, MP16-09, MP16-10, MP16-12, MP21-13, VS8-04  
 Kramer, B., O1-05, MP23-18, VS2-03  
 Kriedberg, C., BR3-07, MP3-11, MP3-12, MP3-15, MP10-16, VP16-13  
 Krombach, P., VP3-16  
 Kruck, S., MP7-14, MP24-11, VP17-09  
 Krupp, N., BR2-01, VP19-08  
 Ku, J., VP1-16, VP10-17, VP27-02  
 Kuandykov, E., O4-10  
 Kübler, H., O1-03, VP21-07  
 Kucukdurmaz, F., MP14-13  
 Kuczyk, M., VP17-09, VS6-10  
 Kudo, T., VP17-17  
 Kulkarni, M., MP22-01  
 Kulkarni, R., MP8-13, MP22-01  
 Kumar, G., MP18-03, MP18-06, VP2-12, VP22-05  
 Kumar, P., MP8-13, MP22-01  
 Kumar, S., MP3-20  
 Kumar, V., VS1-02, VS1-03, VS1-04, VS7-09, VS11-06  
 Kumazawa, T., MP14-04  
 Kumon, H., MP1-19, MP8-07, MP8-08, MP19-13  
 Kumon, Hiromi, O1-09  
 Kunishima, Y., VP2-08  
 Kural, A., MP15-13, VP14-16, VP27-18, VS1-10, VS5-08, VS13-03, VS14-06, VS15-10, VS17-03, VS20-05  
 Kuranov, R., BR2-04  
 Kurien, A., MP2-20, MP4-13, MP8-18, MP9-09, MP13-11, VP4-17, VP14-02, VP17-02, VP22-01, VP23-07, VP26-17, VS3-03, VS18-03  
 Kuroiwa, K., MP13-02  
 Kurosch, M., MP2-09  
 Kurtz, M., MP9-07  
 Kwak, C., VP1-16, VP10-17, VP27-02  
 Kwangsung, P., VP17-16  
 Kwon, D., VP12-16, VS18-08  
 Kwon, E., VP13-19, VP20-08  
 Kwon, J., VP8-09  
 Kwon, T., MP15-17, MP20-03, MP20-10  
 Kyoungtaek, L., MP2-17  
 Kyriazis, I., MP13-14, MP24-16, MP24-17, VP16-06  
 Kyung-jin, O., VP17-16

**L**

Labarbera, S., BR3-02, MP13-20  
 Lacey, D., MP13-19  
 Lagerveld, B., MP6-18

Lagrange, C., MP12-03  
 Laguna, M., VP14-01, VP19-15  
 Lahme, S., O5-05, MP8-14, MP8-15, VP3-10, VP4-10, VP4-13, VP6-14, VP20-15  
 Lal, A., MP21-08  
 Lallas, C., MP11-15  
 Lam, S., MP15-12, VP19-03  
 Lamba, S., MP15-12  
 Lambert, E., MP3-03, MP4-07, VP1-05, VP2-20  
 Lamberton, G., VS5-07  
 Lampel, A., VP3-08  
 Landman, J., MP6-06, MP6-11, MP6-15, MP6-16, MP6-19, MP12-14, MP14-11, MP14-12, MP15-01, MP18-10, MP21-09, VP3-04, VP7-06, VP11-14, VP22-06, VP22-17  
 Lang, E., MP2-12  
 Lange, D., BR7-05, BR7-06, MP4-02, MP24-18, VP4-06, VP28-16  
 Large, M., MP20-01  
 Lasalle, M., MP16-13, MP24-04  
 Laungani, R., MP17-02, VS13-10, VS15-03, VS18-07  
 Lauretti, S., VP27-15  
 La vecchia, L., VS6-08  
 Lavery, H., MP5-04, MP11-16, VP5-03, VP20-06, VP20-10, VP20-14  
 Lawrence, C., VP18-04  
 Le, N., O3-10, MP2-08, MP18-18, MP22-07, VP9-10, VS19-10, VS20-10  
 Leal, D., VS9-04  
 Ledesma, Rodrigo, VP21-20  
 Ledezma, R., MP4-05  
 Lee, B., MP5-10, MP5-11, MP11-04, MP11-10, MP11-11, MP13-06, MP15-05, MP17-15, MP17-16, MP20-07, MP20-09, MP21-03, VP2-19, VP5-05, VS4-01, VS7-01, VS13-02, VS13-04, VS20-09  
 Lee, D., O6-07, MP11-14, MP12-14, MP15-06, MP15-10, MP15-11, MP18-13, VP22-06  
 Lee, F., MP11-15, MP13-01  
 Lee, H., MP4-18, MP19-17, VP8-06  
 Lee, J., BR3-03, MP19-10, MP19-17, MP21-01, VP11-14, VP22-06, VS13-05, VS17-07  
 Lee, K., VP18-16  
 Lee, M., MP14-15, MP19-16, VP1-03, VP1-14, VS17-01  
 Lee, N., MP2-08, MP18-18  
 Lee, R., VP28-05  
 Lee, S., MP14-14, MP15-02, MP19-17, VP1-16  
 Lee, T., MP2-17, VS13-05, VS17-07  
 Lee, W., MP11-13, VP24-03  
 Leenanunth, C., VP8-07, VS4-07, VS15-04  
 Leeser, C., O2-06

Legervand, D., BR8-01  
 Legraverand, D., O5-10, VP3-20  
 Lehnhardt, M., MP12-19  
 Leibovitch, I., MP10-17  
 Leistner, R., MP2-18  
 Leitão, T., MP18-05  
 Lentini, M., VP10-03  
 Leonard, M., VS11-04  
 Leonardo, C., VP2-14  
 Leonardopoulos, L., MP8-11  
 Leone, N., O3-10, MP22-07, VP9-10  
 Leontis, S., MP8-11  
 Lepchuk, B., MP5-15  
 Leppert, J., VP7-01, VP11-12, VP28-14  
 Lerner, M., MP15-04, MP17-04, MP17-05, MP20-18, VS20-02, VS20-03  
 Leschaka, S., VP11-02  
 L'esperance, A., VP17-05  
 L'esperance, J., MP1-18, MP6-02, MP10-02, MP13-19, VP17-05, VP22-20, VP26-05  
 Leveilee, R., MP19-02  
 Leveillee, R., BR1-06, MP6-14, MP13-13, MP13-15, MP17-08, MP18-08, VP27-17  
 Leventis, A., MP8-11  
 Lewis, G., MP14-08  
 Lewis, I., VP21-03, VP23-12  
 Lho, Y., MP21-03  
 Li, J., BR5-10, O2-10, O5-02, MP2-10, MP3-17, MP4-11, MP4-12, MP5-17, MP10-15, MP16-09, MP16-10, MP16-12, MP21-13, MP23-17, VP6-05, VS8-04  
 Li, R., MP4-18, MP6-17, MP19-03, VS15-05  
 Li, X., VP25-17  
 Liatsikos, E., BR1-08, O6-06, MP9-15, MP12-12, MP13-14, MP18-09, MP24-16, MP24-17, VP10-04, VP10-08, VP10-13, VP10-15, VP12-07, VP16-06, VS8-02, VS18-09  
 Libertino, J., MP5-17  
 Lidawi, G., VP3-03  
 Lifshitz, D., MP11-05, MP11-06, MP11-07, MP14-12, MP20-01, MP24-03, VP1-01, VP1-13, VP9-02, VP19-05  
 Lim, J., MP10-15, MP23-17, VP6-05  
 Lima, E., MP12-13  
 Lima, F., BR1-04, MP20-08, VP8-12  
 Lin, C., VS10-01  
 Lin, T., O2-08, VP25-14, VP25-15, VP25-16, VP25-17  
 Lin, Y. Siang, MP7-04, VP11-04  
 Lingeman, J., BR5-10, O2-10, MP2-10, MP3-17, MP4-11, MP4-12, MP16-09, MP16-10, MP16-12, MP21-13, VS8-04  
 Lingensfelder, T., O2-08  
 Link, R., MP19-03, VS15-05

- Lipkin, M., BR2-07, BR5-01, BR5-04, BR6-10, O2-04, MP3-07, VP5-06, VP10-11, VP20-11
- Liske, P., O5-05, MP8-14, MP8-15, VP3-10, VP4-10, VP4-13, VP6-14
- Litwak, K., VS7-02
- Liu, H., BR7-10
- Liu, S., VP23-11
- Liu, Y., O3-07, VP21-16, VP25-13
- Livne, P., VP9-02
- Lo, A., MP2-08, MP3-08, MP13-12, MP18-18, MP21-07, MP22-13, VP12-10
- Lockhart, M., MP7-16
- Loebelenz, M., BR4-08
- Loizaga, A., MP13-12
- Lojanapiwat, B., VP26-11
- Löhr, M., VP13-03
- Longhorn, S., MP5-07, VP3-13
- Longo, F., MP3-19
- Longo, N., MP2-01
- Lopez, A., VP12-10
- Loske, A., MP22-13
- Louie, M., MP4-18, MP5-09, MP6-07, MP6-17, MP18-04, MP18-15, MP23-16, MP24-09, VP6-09, VP11-14
- Lowry, P., VP11-19, VP18-17
- Lu, J., BR8-05, MP7-11, VP10-16, VP21-17
- Lu, M., MP1-02, MP22-14, VP12-03, VP12-04, VP12-09, VP25-03, VS6-04, VS16-02
- Lu, W., VP18-09
- Lucas, S., MP15-04, MP17-04, MP20-18
- Lucci, M., VP12-03, VP12-04, VP12-09, VP25-03, VS6-04
- Luciani, L., MP14-19
- Lund, L., O3-08, VP27-20
- Lusch, A., VP24-05
- Luscombe, C., BR1-01, BR1-02, BR1-09, BR1-10, O1-02, O1-08, MP12-18, MP19-12, VP10-20, VP11-03, VP12-19, VP19-12, VP20-18, VP21-01, VP21-02, VP21-04, VP21-05, VP23-11, VP28-18
- Lux, C., VP16-10
- Lux, M., MP1-02, VS16-02
- Lv, W., VS6-09, VS12-05
- Lyne, C., VP19-18
- M**
- Ma, J., BR1-04, MP2-11, MP5-17, MP6-20, MP8-09, MP8-19, MP16-16, MP16-17, MP17-18, MP19-09, MP24-13, VP8-10, VP16-02, VP19-18, VP20-20, VP22-20, VP23-04, VP23-10, VP28-13
- Ma, L., BR5-08, O3-05, O3-07, MP5-20, VP10-09, VP10-16, VP21-16, VP21-17, VP25-12, VP25-13
- Maan, Z., MP2-11, MP8-19, MP16-16, MP16-17, MP24-13, VP23-10
- Macdonald, D., MP18-02
- Macejko, A., MP10-12
- Madaan, S., VP18-07
- Maghsoudi, R., VP13-18
- Mahboub, M. Darabi, MP3-04, MP9-05, MP16-14, VP18-03, VP26-07, VP26-12, VP26-16, VP28-04
- Mahdavi, K. Nouri, O5-08
- Mahdavi, P., MP6-04, MP6-04, VP17-01, VP19-08
- Maheshwari, R., VP2-05, VP4-16, VP17-07
- Mak, S., VP14-06
- Makatounaki, K., VP18-06
- Makris, A., MP7-07
- Malcolm, J., VP22-20
- Maldonado, E., MP22-16
- Maletta, A., MP2-01
- Mamaev, I., MP19-08
- Mamoulakis, C., MP4-03, VP14-01, VP19-15
- Man, A., BR4-04, MP3-20, MP21-08, VP2-05, VP4-12, VP4-16, VP13-12, VP17-07, VS7-10
- Mandal, A., BR4-04, MP3-20, MP21-08, VP13-12
- Mandeville, J., MP5-17, MP17-18, MP19-09, VP16-02
- Mandhani, A., VP2-05, VP4-16, VP17-07
- Manfredi, M., VP12-03, VP12-04, VP12-09, VP25-03, VS6-04
- Manger, J., MP8-09
- Mangera, A., VP4-12
- Mangiapia, F., MP2-01
- Mangiarotti, B., MP3-19
- Maniadakis, N., VP16-06
- Mantu, G., MP5-16
- Manzano, J., BR1-04
- Marchant, F., BR5-03, MP4-05
- Marchiñena, P. Garcia, MP4-19
- Marcovich, R., MP24-07
- Maria, G. Antonio, VS3-02, VS8-02, VS17-04
- Mariani, A., VP9-10
- Marinho, M., VP6-18
- Mark, R., VP5-03
- Marketakis, A., MP1-03
- Marnes, M., MP4-20
- Marsh, H., MP8-17, VP18-07
- Marsh, R., VP1-02
- Marshall, J., VP8-10, VP20-20, VP23-04
- Martin, H., MP11-08, VP13-03
- Martin, S. Martin, VP23-03
- Martinez-suarez, H., MP11-08
- Martinho, D., MP1-13, MP18-05
- Martins, A., MP8-20, MP9-20, MP10-09, MP23-07, VP10-01, VP10-02, VP12-20, VP13-16, VP15-12, VP18-10, VP24-08, VP24-09, VP27-10, VP27-11, VP27-12
- Martín, S. Martín, MP19-14
- Maruyama, S., VP27-01
- Masood, J., MP2-11, MP8-19, MP16-16, MP16-17, MP24-13, VP23-10
- Masoudi, P., VP28-07
- Massimiliano, P., MP7-15, MP24-10
- Master, V., MP5-12
- Masumori, N., VP2-08
- Mathes, G., BR5-08
- Mathes, L., BR5-08
- Matheus, R., VP12-10
- Mathew, A., MP4-13, MP13-11, VP17-02, VP23-07
- Matin, S., MP14-12, VS6-03
- Matlaga, B., MP3-16, MP9-07, MP13-09, MP21-06, VP11-01
- Matsuda, T., MP14-18, VP12-17
- Matsukawa, Y., MP20-04
- Matsushima, M., O6-03
- Matsuura, S., VP17-17
- Mattioli, S., VP14-05
- Matuura, O., MP14-02
- Matzkin, H., VP3-03, VP28-15
- Maurer, T., VP21-07
- Mavuduru, R., BR4-04, MP21-08, VP13-12
- Maxwell, A., VP18-01
- Mayes, J., MP6-20, VP19-18
- Maynes, L., O3-05
- Mazzucchi, E., MP16-04, VP4-03
- Mcateer, J., BR5-10, MP2-10
- Mccarthy, J., MP3-01
- Mccue, P., MP11-15
- Mcdougal, W., MP7-19
- Mcdougall, E., MP4-18, MP5-09, MP6-07, MP6-17, MP7-17, MP18-04, MP18-15, MP22-06, MP23-16, MP24-09, VP6-09, VP11-14, VP27-13
- Mcelroy, A., BR2-04
- Mcintyre, M., VP18-04
- Mckenna, P., VS2-03
- Mckiernan, J., MP5-16, MP6-11, MP6-16, MP21-09, VP22-17
- Mcleroy, S., MP16-11
- Medhat, M., MP22-17
- Meeks, J., MP15-19
- Mehmedovic, S., VP19-15
- Mehr, N., MP6-05
- Mehrabi, S., VP26-03
- Mehravaran, K., VP13-18
- Mehrotra, P., VP1-02
- Mehta, S., VP4-12
- Meining, A., O1-03
- Melekos, M., MP2-16
- Melo, M., MP18-05
- Mendes, A. Vommaro, MP16-05
- Mendonça, T., MP1-13
- Menon, M., MP17-01, MP17-02, VS13-10, VS15-03, VS18-07
- Menéndez, S. Alonso, MP19-14

- Meredith, B., MP15-10, MP15-11  
Merinov, D., MP8-06, VP9-14, VP14-15  
Merlet, B., BR8-01, O5-10  
Messeti, F., VS19-05  
Messetti, F., MP20-08  
Metaxari, M., VP18-06  
Mete, U., MP3-20  
Metrebián, E., VS19-05  
Metrebian, E., MP20-08, VP8-12  
Meyer, T., VP14-12  
Micali, S., BR5-09, VP5-15, VP18-08, VP20-05, VS4-09, VS9-06, VS9-07, VS14-07, VS15-08  
Michel, M., BR4-03, O2-08, O4-06, MP4-03, MP12-08, MP12-09, VP3-16, VP4-04, VP4-18, VP14-03, VP14-11, VP14-12, VP24-05, VP28-20  
Mikhail, A., O3-05, VP21-13  
Miki, T., VP1-04, VP17-20, VP27-04  
Milfont, J., MP16-05  
Millard ii, W., VS5-07  
Miller, D., VP5-08  
Miller, J., BR1-07  
Miller, K., O1-10  
Miller, N., MP3-03, MP4-07, MP13-09, VP1-05, VP2-20  
Milner, T., BR2-04  
Mimata, H., MP14-16, VP25-08  
Min, L., VP4-05  
Minareci, S., MP14-10, VP7-12, VP7-13, VP21-10, VP21-14, VP22-14, VP22-18  
Mir, M. Gascon, VP9-01  
Miranda, M., VS19-02  
Mirciulescu, V., MP9-01, MP24-02, VP26-01, VP26-10, VS11-03  
Miroglu, C., MP9-16, MP21-05, MP22-18, VP15-04  
Mirone, V., MP2-01  
Mishra, S., MP8-18, MP9-09, MP13-11, VP4-17, VP14-02, VP17-02, VP26-17, VS3-03, VS5-04  
Mitre, A., MP10-13  
Miura, M., MP5-02  
Miyajima, A., VP16-05  
Miyaoaka, R., BR6-08, BR6-09, BR7-06, MP3-11, MP3-12, MP3-15, MP10-16, VP3-05, VP16-13  
Moanack, J., VP6-17  
Mobley iii, J., MP2-04  
Mochiduki, T., VP9-11  
Mochizuki, T., MP5-02  
Modi, A., VP3-04  
Modi, P., VP21-19  
Moeckel, G., VP1-05  
Moeding, A., BR3-07, MP3-11, MP3-12, MP3-15, MP10-16  
Moghaddam, A. Afshari, VP26-02  
Mohamadi, L., VP13-14  
Mohamed, A., MP21-04, VS9-08  
Mohamed, B., VP18-19  
Mohamed, H., VP11-18, VP15-07  
Mohamed, M. Weld sidi, VP18-18  
Mohammadi, Y., MP20-18  
Mohan, S., O6-10, VP18-13  
Moinzadeh, A., MP5-17, MP17-18, MP19-09  
Molina, W., VP28-05  
Molina-torres, M., MP22-13  
Molinari, C., O5-03, VP10-03, VP15-02  
Monden, K., MP8-08  
Monga, M., BR3-07, BR6-08, BR6-09, BR7-06, MP3-11, MP3-12, MP3-15, MP10-16, VP3-05, VP16-13  
Monish, A., VS17-01  
Montag, S., VP20-13, VP19-16  
Montanari, E., MP3-19, VP26-08  
Montgomery, J., VP5-08, VS9-10, VS12-07, VS13-06, VS16-09  
Montlleó, M., VS18-06  
Moon, H., VS13-05  
Moon, K., MP5-14  
Moore, C., BR1-06, MP6-14, MP13-15, MP18-08  
Moradi, M., VP19-09  
Moraitis, K., MP2-11, MP16-16, MP16-17, VP23-10  
Moreira, O., VS14-09  
Moreno, J., MP6-11, MP6-16, MP12-14, MP18-10  
Morgan, L., VS2-04  
Morihsa, M., MP8-20, MP9-20, MP10-09, MP23-07, VP10-01, VP10-02, VP12-20, VP13-16, VP15-12, VP18-10, VP24-08, VP24-09, VP27-10, VP27-11, VP27-12, VS4-05, VS11-09, VS15-09, VS17-09  
Moriya, Y., MP14-02  
Moro, J., VP17-19  
Morra, I., VP1-10, VP1-17, VP17-10, VS3-10, VS15-06  
Mortazavi, N., VP13-01  
Mortezavi, A., O6-05  
Mossangen, M., VP28-14  
Moteria, S., MP3-18, MP22-03  
Mottrie, A., MP15-13, VP5-01, VP20-19, VS16-04, VS16-05, VS16-06  
Moul, J., VP10-11, VP20-11  
Mouraviev, V., MP6-12, MP6-20, VP19-18  
Mourtzinou, A., VP16-02  
Mousavi-bahar, S., MP4-01, MP21-15  
Moustafa, A., O4-04  
Ms, B., VP15-07  
Mueller, T., MP15-09  
Mufarrij, P., VP11-06, VS4-02  
Multescu, R., MP7-01, MP7-03, MP8-05, MP9-01, MP16-02, MP24-01, MP24-02, VP9-13, VP26-01, VP26-10  
Müller, G., VP7-07  
Mumtaz, F., VP12-19  
Mun, I., MP19-10  
Mungan, A., BR5-06  
Muntner, P., MP15-07  
Müntener, M., VP11-02  
Munver, R., MP1-14, MP1-15, MP1-17, MP8-01, MP13-03, MP15-18, MP15-20, MP17-06, MP17-10, MP19-02, MP20-12, VP2-11, VP5-07, VP22-03, VP22-04  
Murakami, F., VP28-09  
Murat, C., VP2-03  
Muresan, A., MP9-19, VS7-10  
Murugesan, J., VP3-14, VP23-05  
Musienko, V., MP12-10  
Muslumanoglu, A., BR3-08, O5-07, O5-09, MP8-12, MP21-19, MP21-20, VP4-14, VP15-06, VP15-13, VS17-08  
Müslümanođlu, A., VP25-20, VP27-14  
Mut, T., MP14-09, MP20-19, VP1-09, VP6-13, VP27-16  
Muthu, V., MP13-11, VP2-01, VP4-17, VP22-01, VP26-17, VS18-03, VS19-07  
Mutlu, N., BR3-09  
**N**  
Naami, A., O4-02  
Nabizada-pace, F., MP11-16, MP15-07, VP20-06, VP20-10, VP20-14  
Naderi, A., MP3-04  
Nadler, R., MP10-12, MP15-19, MP19-18, VP5-11  
Nagata, H., VP16-05  
Nagele, U., O5-06, MP24-11, VP17-09  
Naito, S., MP13-02  
Naitoh, Y., VP17-20, VP27-04  
Nakada, S., MP10-18, MP13-01, MP14-07, MP16-19  
Nakagawa, K., VP16-05  
Nakahira, Y., O6-03  
Nakano, D., VP25-08  
Nalcacioglu, V., MP12-16  
Nam, J., VP24-03  
Namjoo, M., VP28-04  
Nane, MP10-05, VP1-09  
Nanieva, R., O2-06, MP1-16  
Napodano, G., VP19-20, VS4-04, VS6-05, VS10-02, VS17-06  
Narita, S., MP14-04, VP7-04  
Naselli, A., BR8-03, VP23-01  
Nash, S., MP23-05  
Nasseh, H., VP28-07  
Nasu, N., MP14-16  
Nasu, Y., MP1-19, MP8-07, MP19-13  
Nasu, Yasutomo, O1-09  
Natalin, R., MP20-15  
Nathaniel, C., VP3-13  
Nawfel, B., VP18-19  
Nayeemuddin, M., VP11-03, VP19-12  
Ndoye, M., O5-10, VP3-20  
Nechita, F., VP3-01, VS7-10  
Negrete-pulido, O., MP4-20, MP22-13  
Neisius, A., MP2-15, MP11-19, MP24-19

- Nelson, E., MP5-15, MP23-18  
 Nelson, R., MP6-13, VP19-19  
 Nemenova, A., VP26-18  
 Nerli, R., VP13-04, VP13-07  
 Nesar, S., MP8-19  
 Neto, E. Chedid, MP16-04, VP4-03  
 Netsch, C., BR4-10, O2-05, O4-06, O4-07, VP9-17, VP9-18, VP9-19, VP14-03, VP14-11, VP16-07, VP20-04, VP20-09, VP28-19  
 Netto, Jr., N. Rodrigues, MP16-07, VP17-19  
 Netto, M. Jose bruschini rodrigues, MP16-07  
 Neumayr, A., BR4-09, O1-01, O2-06, MP17-07  
 Neymeyer, J., BR2-03, BR4-05, VP14-04, VS1-08, VS2-05, VS2-08  
 Ng, C., MP2-08, MP3-08, MP18-18, MP21-07, MP22-04  
 Ng, M., MP15-10, MP15-11, VP14-06  
 Nguyen, M., MP15-10, MP15-11  
 Niashiran, D. Hosseini, VP26-15  
 Nicklas, A., VP2-18  
 Nicola, S. Mattia, VS16-05, VS16-06  
 Nicolaus, M., O6-06, VP12-07  
 Nicolay, L., MP6-04, MP6-04, MP6-05, VP17-01, VS18-02  
 Nigro, F., VP26-06  
 Niroomand, R., VP28-17  
 Nishi, M., VP2-17  
 Nishinaka, K., VP2-08  
 Nita, G., VS11-03, VS12-03  
 Nizar, D., VP18-18  
 Noh, P., VP24-02, VS12-06  
 Nomura, T., VP9-11  
 Nonomura, K., VP27-01  
 Noor-alizadeh, A., VP9-20  
 Norman, R., MP3-01, MP7-08  
 Nott, L., MP2-18, MP8-16, MP13-18  
 Nouira, Y., MP22-20, VP9-09, VP11-18, VP13-17, VP18-18, VP18-19  
 Nouraliadeh, A., MP16-06  
 Nouralizadeh, A., VP2-07  
 Nunez, R., VP14-18, VP16-04  
 Nutahara, K., MP19-15  
 Nuttall, M., VP15-03
- O**  
 Ober, P., MP8-14, MP8-15, VP3-10, VP4-13, VP6-14, VP20-15  
 Oberhagemann, K., BR4-10, O4-07, VP9-17, VP9-18, VP9-19, VP16-07  
 Öbek, C., VP27-18  
 O'brien, T., O4-03, MP7-18  
 Ocantos, J., MP4-19  
 Ogan, K., MP3-09, MP5-12  
 Oguchi, N., MP14-18  
 Oguz, U., MP9-06  
 Oh, P., MP6-02  
 Oh, S., VP14-07  
 Oh, T., VP8-09  
 Ohmann, E., VP2-06  
 Okegawa, T., MP19-15  
 Okhunov, Z., MP6-06, MP6-15, MP12-14, MP14-11, MP18-10, MP21-09, VP7-06, VP22-06  
 Oktay, B., VS1-07, VS1-09, VS6-01, VS10-07, VS18-01, VS19-01  
 Olbert, P., BR6-04, MP22-02, MP23-02, MP23-03  
 Oliveira, L., VP6-06  
 Olsburgh, J., VP9-08  
 Olweny, E., MP16-18  
 Omidvar, M., VP19-09  
 Ong, R., BR7-09, VP22-19  
 Ono, Y., VP6-05  
 Oommen, M., MP5-10, MP5-11, VP2-19, VS4-01, VS7-01, VS13-02, VS13-04  
 Oral, E., VP24-11, VS6-02  
 Ordonez, M., MP14-11  
 Ortac, M., MP14-05, MP14-13, VP1-09, VP27-16  
 Ortiz, V., BR1-04, MP20-08, MP20-15, VP8-12, VS19-05  
 Ortiz-alvarado, O., MP3-11, MP3-12, MP3-15, MP10-16, VP16-13  
 Osann, K., MP15-16, VP20-03  
 Oskay, K., MP23-15  
 Ossandon, E., BR5-03, MP4-05  
 Ost, M., MP21-04, VS9-08  
 Oya, M., VP16-05  
 Ozcan, F., MP14-05, VP1-09  
 Özcan, S., VP23-02  
 Ozdemir, U., MP21-14  
 Ozden, E., VP4-15  
 Ozgok, Y., O3-06, MP18-11, MP22-10, VP11-17, VP14-19, VP15-01, VP26-19, VS3-06, VS9-03, VS12-09  
 Ozgor, F., MP21-20  
 Ozkan, B., VS12-02  
 Ozkan, S., VP28-10  
 Ozkardes, H., VP4-08, VP4-20  
 Ozok, U., VS1-05  
 Özsoy, C., MP20-19, VS20-04  
 Ozturk, A., MP21-14  
 Ozturk, B., MP21-11, VP4-08, VP4-20  
 Ozyuvali, E., MP4-10
- P**  
 Pabon, A., VP13-11, VP21-06, VP25-10  
 Pace, K., BR6-03, MP2-06, MP4-04, MP14-03, VP4-02, VP4-06, VS5-06, VS17-05  
 Pace, S., VP4-02  
 Page, J., MP9-07, MP12-02, MP12-03, MP19-19  
 Pagotto, C., MP10-13  
 Pagotto, V., MP10-13  
 Pahernik, S., MP2-09  
 Pai, M. Ganapathy, VP2-10  
 Pai, M., VP13-06, VP19-06, VP19-10  
 Paick, S., MP21-03  
 Pais, jr, V., MP9-07  
 Paiva, C., MP20-15  
 Pakfetrat, M., VP28-06  
 Pakmanesh, H., BR3-10  
 Pal, B., VP21-19  
 Palese, M., VP5-03  
 Palma, P. César rodrigues, VP17-19  
 Palmer, J., MP8-17, VP24-01  
 Palmer, K. J., MP11-02, O2-02, VP20-01, VS13-01, VS14-01, VS14-02, VS14-03, VS14-08  
 Palmer, K., MP11-03  
 Palmieri, A., MP2-10  
 Pamplona, M., VP6-10, VP6-19  
 Pan, J., MP16-15, MP19-07, MP23-08  
 Panahandeh, Z., MP9-02  
 Paolo, F., VP26-06  
 Papalia, R., BR8-08, MP20-06, MP20-16, VP1-11, VP2-14, VP11-07, VP11-15, VP12-11, VP22-07, VP27-07, VP28-11  
 Papas, A., MP1-03  
 Papatsoris, A., MP2-11, MP8-19, MP24-13, VP23-10  
 Pardalidis, N., VP9-12, VS16-01  
 Pareek, G., MP9-11  
 Parekattil, S., MP5-19, MP13-16, MP17-20, VP5-10, VP5-12, VP5-13, VP5-14, VP5-16, VP27-08, VS10-08  
 Park, H., MP2-17, MP3-06, MP15-02, MP15-08, VP24-03, VS17-07  
 Park, J., MP3-02, MP3-06, MP3-06, MP15-08, VP12-16, VS18-08  
 Park, S., BR3-03, MP2-17, VP24-03, VS13-05, VS17-07  
 Park, Y., MP15-17, MP20-03, VP1-16, VP8-04, VP10-17, VP22-15, VP27-02  
 Parma, P., MP14-19  
 Parvin, M., BR3-06  
 Pascal, Z., VS10-10  
 Passerotti, C., VP6-03  
 Paszek, M., MP12-03  
 Patel, A., MP8-18, MP24-12, VP2-01, VP26-13, VS18-05  
 Patel, D., MP24-13  
 Patel, H., MP18-20, VP11-11  
 Patel, M. B., MP19-02, VP20-01, VP20-02, VS14-01, VS14-08  
 Patel, M., MP11-02, MP11-03, MP17-01, MP17-02, VS13-01, VS13-10, VS15-03, VS18-07  
 Patel, N., VP22-03  
 Patel, R., VP14-02, VS5-04  
 Patel, S., MP9-11, VP3-17, VP15-11  
 Patel, V., O2-02, MP11-02, MP11-03, MP15-13, MP19-02, VP20-01, VP20-02, VS13-01, VS14-01, VS14-02, VS14-03, VS14-08  
 Paterson, R., VP4-06, VP28-16  
 Patil, A. Ashish, MP2-03, MP16-08, VP19-01, VP26-04, VS5-02

Patil, K., MP8-13  
 Patino, G., MP13-19  
 Pattaras, J., MP3-09  
 Patterson, R., MP9-07  
 Paulson, E., BR6-10  
 Peairs, S., MP13-15  
 Pearle, M., MP3-10, MP16-11  
 Pedersen, L., VP27-20  
 Pedreira, M. López, MP19-14  
 Pedro, R., BR6-09  
 Peine, W., MP17-04  
 Penney, G., BR7-08  
 Penniston, K., MP16-19  
 Pereira, S., MP1-13, MP18-05  
 Peres, N. Billordo, MP4-19  
 Perez-lanzac, A., MP6-11, MP6-16  
 Peris, F., VP27-15, VS6-08  
 Perlin, D., VP7-05  
 Perlmutter, M., VP11-06  
 Permpongkosol, S., VP8-07, VS4-07, VS15-04  
 Perry, K., MP15-19, MP19-18  
 Persad, I., VP21-03, VP23-12  
 Petrisor, D., MP15-14  
 Petrut, B., VP3-01, VS7-10  
 Pfeiffer, D., O2-05, VP20-04, VP20-09  
 Pfost, B., BR8-04  
 Phelan, M., MP6-01  
 Philp, T., MP5-07, VP3-13  
 Picard, J., VP1-07  
 Pichurko, A., MP17-01, VS18-07  
 Picinotti, A., VP14-05  
 Pick, D., MP4-18, MP5-09, MP6-07, MP18-04, MP18-15, MP23-16, MP24-09, VP6-09, VP11-14  
 Piero, I. Giacomo, VS3-02, VS20-07  
 Pierre, S., VS11-04  
 Pietrantuono, F., VS7-06, VS8-07  
 Pinheiro, M., VP10-19  
 Pinheiro, T., MP20-08, VP8-12, VS19-05  
 Pini, G., VP18-08, VS4-09, VS9-06, VS9-07, VS15-08  
 Pinsky, M., MP11-04, MP11-10, MP11-11, MP13-06, MP17-15, MP17-16, MP20-07, MP20-09  
 Pinto, F., MP7-06, MP23-01  
 Pinto, I., VP11-13, VP13-11, VP16-11, VP21-06, VP25-10  
 Piskin, M., MP21-14  
 Poggio, M., VS1-06, VS11-02, VS12-01  
 Poh, B., MP4-02, MP24-18  
 Pokala, N., VS15-03  
 Polascik, T., MP6-12, MP6-13, MP6-20, VP10-11, VP19-18, VP19-19, VP20-11  
 Polyzois, K., VP28-08  
 Poon, N., MP3-08, MP22-04  
 Popeneciu, V., MP2-09  
 Popescu, S., VP3-01  
 Popp, S., MP17-05  
 Porfiri, E., BR8-09

Porpiglia, F., MP6-09, MP12-15, MP14-19, VP1-10, VP1-17, VP1-18, VP2-02, VP12-03, VP12-04, VP12-09, VP12-18, VP17-10, VP25-03, VS3-10, VS6-04, VS12-01, VS15-06  
 Porres, D., MP11-17  
 Prapotnich, D., MP1-05  
 Prem, R., MP22-17  
 Preminger, G., BR2-07, BR5-01, BR5-04, BR6-10, MP3-10  
 Prescher, M., BR4-07  
 Preston, M., VS8-06  
 Priti, G., BR8-09  
 Probst, C. Mendez, MP2-18, MP8-16, MP13-18, MP22-05, MP22-12  
 Pronkin, E., MP19-08  
 Psutka, S., MP7-19, VP16-01  
 Pu, X., MP22-14, VP10-05, VP10-12, VP13-20  
 Puder, D., VS18-02  
 Pueh, L. Heow, MP7-04, VP11-04  
 Pugas, C., VS20-08  
 Puglisi, M., VP26-20  
 Puppo, P., BR8-03, VP23-01  
 Pusztai, C., MP2-07, VP17-18

**Q**

Qinsong, Z., BR7-01  
 Qiu, J., BR2-04, VP10-12, VP13-20  
 Quattrone, C., MP18-19, VS5-05

**R**

R, L., VP21-08  
 R, S., VP17-07  
 Rabani, S., BR6-06, O5-04, MP21-18, VP28-03  
 Rabenalt, R., O2-09, VP10-04  
 Racioppi, M., MP7-06, MP10-07  
 Rackley, R., VP13-05  
 Rahmani, M., MP9-05, VP26-07, VP26-16  
 Rais-bahrami, S., MP12-07, MP18-16, VP8-02, VP8-03, VP10-18, VP19-16, VP27-03, VP27-06, VS18-04  
 Ramakrishnan, V., VP3-14, VP23-05  
 Ramalingam, M., VP2-09, VP2-10, VP13-06, VP19-06, VP19-10  
 Raman, J., MP3-10, MP6-03  
 Ramirez, D., VS4-03, VS7-05, VS10-10  
 Ramjit, C., VP21-03, VP23-12  
 Rammamurthy, S., VP23-05  
 Ramos, P., MP10-12  
 Ramsay, J., MP2-13, MP2-14, MP7-20  
 Rane, A., VP21-02, VP21-05, VP28-05  
 Ranjan, P., BR4-04, VS3-01, VS18-10  
 Rao, P., MP22-01  
 Rashid, H., VP8-10, VP20-20, VP23-04, VS12-08, VS16-03  
 Rassweiler, J., BR3-01, O2-03, VP6-13, VP7-11, VP16-08, VS3-08, VS20-01  
 Rastinehad, A., MP20-13, VS19-08  
 Ray, A., BR6-03, MP2-06, MP4-04, VP4-02, VS5-06, VS17-05  
 Ray, E., MP7-18  
 Raybourn iii, J., VP28-05  
 Raynor, M., MP5-10, VP2-19, VP5-05, VS13-02, VS13-04  
 Razmaria, A., MP11-05, MP11-06, MP11-07, MP20-01, MP24-03, VP20-17  
 Razvi, H., MP2-18, MP8-16, MP22-05, MP22-12  
 Realfonso, T., VS6-05, VS10-02, VS17-06  
 Rébillard, X., O2-07  
 Rebuck, D., MP10-12, MP15-19, MP19-18, VP5-11  
 Recabal, P., BR5-03, MP4-05  
 Reddy, M., VP13-04, VP13-07  
 Reese, A., MP10-10  
 Regensburg, R., VP1-12  
 Reich, O., BR6-07, VP12-01  
 Reichelt, O., VP12-01  
 Remer, E., VS7-07  
 Rempelakos, A., MP1-03, MP8-11  
 Renteria, J., VP6-18, VS2-02, VS3-04, VS4-08  
 Resorlu, B., MP4-10, MP8-10, MP9-06, MP10-03, MP19-06, VP4-01, VP4-11  
 Reuther, R., MP7-16, VP14-13  
 Rezaie, M. Mohamad Zadeh, MP10-04  
 Rha, K., MP20-10  
 Rheinwald, M., BR4-06  
 Rhouma, S. Ben, MP22-20, MP9-18, VP11-18, VP18-18  
 Ri-hai, BR6-01  
 Ri-hai, X., MP21-02  
 Riccabona, M., VP24-05  
 Richard, H., MP6-01  
 Richardson, B., MP11-04, MP11-10  
 Richestone, L., VP21-08  
 Richstone, L., MP12-07, MP18-16, MP20-13, MP23-19, VP7-09, VP7-10, VP8-02, VP8-03, VP17-14, VP19-16, VP27-03, VP27-06, VP28-13, VS6-06, VS8-05, VS16-08, VS18-04  
 Rico, R., MP15-19  
 Rieken, M., MP21-12, MP23-14  
 Riffo, R., VP13-11, VP21-06, VP25-10  
 Rim, J., BR3-03, MP19-10  
 Rimington, P., VP21-11  
 Rinehart, J., MP6-17  
 Rioja, J., MP4-03  
 Rioja, L., VP6-12  
 Ritch, C., MP15-01, VP3-04  
 Ritenour, C., MP3-09  
 Rivalta, M., BR5-09, VS9-06  
 Rizvi, J., VP21-19  
 Roberts, W., BR4-02, MP19-20, VP5-08, VP18-01, VS7-03  
 Robertson, C., O2-07, MP6-12



- Rocco, B., O2-02, MP11-02, VP20-01, VS13-01, VS14-01, VS14-02, VS14-03
- Rode, J., O5-10
- Roder, M., VP16-08
- Rodrigues, R., MP1-13
- Rogers, C., MP17-01, MP17-02, VS13-10, VS18-07
- Roman, J., MP4-05
- Romanò, A., VS7-06, VS10-04
- Romão, A., MP18-05
- Romero, V., MP3-14
- Rosales, A., VS18-06
- Rosales, J., MP6-11, MP6-15, MP6-16, MP12-14, MP14-11, MP18-10, MP21-09, VP7-06
- Roshani, A., MP5-01
- Roth, R., VP16-02
- Rothberg, M., MP4-16, MP15-01, MP22-19, MP24-20, VP22-17
- Rottenberg, G., MP3-13
- Roytman, T., VS17-10
- Rozet, F., O3-02, O6-04, VP1-20, VP12-02, VP12-08
- Rubio, G., O3-01, O6-01, O6-02, VP9-16, VP13-08, VP13-10, VP17-03, VP17-12, VP17-12, VP22-08, VP22-09, VP22-10, VP22-11, VP22-12, VP24-10, VP25-05, VP25-06, VP25-11
- Ruddell, T., VP18-17
- Ruggera, L., VP3-02, VP15-05
- Ryu, D., VP8-09
- S**
- Sabatino, M., VP14-05
- (sarg), S., BR1-01, BR1-10, O1-02, MP19-12, VP6-01, VP10-20, VP20-18, VP21-02, VP21-03, VP21-04, VP23-12, VP28-18
- Sabirzianova, Z., BR2-10, O4-01
- Sabler, I., MP2-12
- Sabnis, R., MP2-20, MP4-13, MP8-18, MP9-09, MP13-11, VP2-01, VP4-17, VP14-02, VP17-02, VP22-01, VP23-07, VP26-13, VP26-17, VS3-01, VS3-03, VS5-04, VS18-03, VS19-07
- Sacak, V., VP28-10
- Sacco, D., MP10-19
- Sacco, E., MP10-06, MP23-01
- Sadidi, J., VP26-12
- Safak, M., VP18-11
- Saglam, R., VP18-11
- Sagnak, L., VS1-05
- Sahadevan, K., VP1-02
- Sahai, A., MP8-17, MP23-04, VP18-07
- Sahin, E., MP8-10
- Said, S., MP18-04
- Saika, T., MP1-19, MP8-07, MP8-08, MP19-13
- Saika, Takashi, O1-09
- Saita, A., VP26-20
- Saito, M., MP14-04, VP7-04
- Sakai, P., VS9-01
- Sakamoto, H., O6-03
- Sakamoto, K., VP21-15
- Sakamoto, Kyoko, MP10-11
- Sakelariou, G., MP8-11
- Sakhaee, K., MP3-10
- Sakhai, S., VP19-09
- Salabas, E., MP5-03, VS20-04
- Salah, K., MP9-03
- Salas, N., BR1-06, MP6-14, MP13-15, MP18-08
- Salim, F., VP4-12
- Saljoughi, A., VS6-10
- Sallami, S., MP9-18, MP22-20, VP9-09, VP11-18, VP13-17, VP18-18, VP18-19
- Salomon, L., VS5-10
- Saluja, S. S., MP14-06, VP17-14
- Saluja, S., VP7-09, VP7-10, VP9-09
- Salvador, J., VS18-06
- Salvaggio, A., VS8-07, VS10-04
- Sam, K., VP18-17
- Samadi, D., MP11-16, MP15-07, VP5-03, VP20-06, VP20-10, VP20-14
- Samadzade, B., VP19-09
- Sami, B., VP18-19
- Sanchez, F., VP6-10, VP6-12, VP6-19
- Sanchez-salas, R., O3-02, O6-04, MP1-05, VP6-20, VP12-02, VP12-08
- Sandoval, C., VP11-13, VP13-11, VP16-11, VP21-06, VP25-10
- Sangalli, M., VP5-01, VP20-19, VS16-04
- Sangster, P., MP23-04
- Sankin, G., BR5-04
- Sanli, O., MP5-03, MP14-05, MP14-09, MP14-13, MP20-19, VP1-09, VP6-13, VP27-16, VS2-07, VS20-04
- Sanseverino, R., VP19-20, VS4-04, VS6-05, VS10-02, VS17-06
- Santos, R., MP15-16, VP20-03
- Saracoglu, F., MP18-11
- Sargon, M., VP6-04
- Sari, E., O5-07, MP21-19, VP4-14, VP15-13
- Sarkar, D., MP21-08
- Sarrafiyan, M., O5-08
- Sartor, O., MP15-05
- Sarýca, K., BR3-09, VP15-10
- Sasaki, H., MP5-02
- Sasaki, Katsumi, O1-09
- Sasamoto, H., VP2-17
- Sassani, P., MP1-12, MP23-05
- Satar, N., MP4-14, MP9-17, VP21-09, VP24-04, VP24-07, VP25-09
- Sathaye, U., VP14-17, VP26-08, VS11-01
- Sato, F., MP6-08, MP14-16, VP25-08
- Satoh, F., MP6-08
- Satoh, S., VP7-04
- Sauer, J., O2-10, VP19-13
- Saunders, P., MP16-16
- Sausville, J., MP6-01
- Savage, S., O3-03, VP1-07, VP2-13, VP18-04, VS19-04
- Savitsky, N., MP12-10
- Sawczuk, I., MP1-14, MP1-15, MP1-17, MP13-03, MP15-18, MP15-20, MP20-12
- Saxby, M., VP23-11
- Sazawa, A., VP27-01
- Sbragi, M., VP14-05
- Scarpa, R., MP6-09, MP7-15, MP12-15, MP24-10, VP1-10, VP1-17, VP1-18, VP2-02, VP12-03, VP12-04, VP12-09, VP12-18, VP17-10, VP25-03, VS1-06, VS3-10, VS6-04, VS11-02, VS12-01, VS15-06
- Scavuzzo, A., VP26-20
- Schütte, A., VP5-09
- Schacter, L., VP1-05
- Schatteman, P., VP5-01, VP20-19, VS16-04, VS16-05, VS16-06
- Scheffel, H., VP11-02
- Schfler, A., VP12-06, VP19-02, VP25-01, VP25-19, VS6-07, VS12-10
- Schilling, D., O5-06, MP24-11
- Schneider, A., O1-03, O1-10
- Schnitzer, J., MP6-02
- Schoeppler, G., MP12-08, MP12-09
- Schrader, A., MP22-02, MP23-02, MP23-03
- Schuette, A., MP11-17
- Schulam, P., VP7-01, VP11-12, VP22-16, VP28-14
- Schulze, M., O2-03, VP16-08
- Schuster, T., VP2-06, VP2-11
- Schwab, C., MP15-11
- Schwartz, B., BR1-07, O1-05, MP23-18, VP19-14, VS2-03
- Schwartz, M., VP8-02, VP27-06
- Schwentner, C., MP7-14
- Schwind, C., O1-05
- Scieri, F., VS8-07, VS10-04
- Scoffone, C., MP7-15, MP24-10, VS1-06, VS11-02, VS12-01
- Scolarikos, A., VP16-08
- Scremin, E., VP26-06
- Searle, P., BR8-09
- Sebastian, G. Mariano, MP4-19
- Sebastien, C., VS16-07
- Seckin, B., VP15-09
- Seckin, S., VS19-03
- Segui, A. Garcia, VP6-17, VP9-01, VP12-10
- Seideman, C., MP20-13
- Seidl, C., BR8-04
- Seifert, H., O6-05, MP1-20, MP23-10, VP14-14
- Seki, T., MP5-02
- Semins, M., MP3-16, MP13-09, MP21-06, VP11-01
- Senekowitsch-schmidtke, R., BR8-04
- Seneviratne, L., BR7-10

- Seney, S., BR7-05  
Senthil, K., VP2-10, VP13-06, VP19-06, VP19-10  
Seo, I., BR3-03, MP19-10, MP20-10, VP6-05  
Seo, S., O6-08, MP4-17, MP7-09, VP8-06  
Seo, Y., MP3-02  
Seong, L. Yong, MP20-11, VP5-18  
Sepúlveda, F., VP13-10, VP24-10, VP24-10, VS19-05  
Sepulveda, F., O6-01, VP13-08, VP22-08, VP22-09, VP25-05, VP25-11  
Sercelik, M., MP23-15  
Sethi, A., MP20-18  
Seungok, Y., MP23-12, MP24-15  
Sfakianakis, G., MP13-13  
Shadpour, P., VP13-18  
Shah, A., VP18-09  
Shah, H., VS1-02, VS1-03, VS1-04, VS7-09, VS11-06, VS19-09  
Shah, K., BR6-09, MP2-20, MP21-04, MP21-16, VP2-06, VP2-11, VP11-05, VS3-01  
Shah, O., MP3-07, MP8-01, MP9-07, MP10-08, MP13-09  
Shah, S., MP1-01, VP11-10, VS8-01, VS10-05  
Shah, W., VP24-05  
Shahrour, K., MP21-04, MP21-16, VP2-06, VP2-11  
Shakeri, M., VP13-14  
Shakeri, S., VP6-16  
Shakhssalim, N., BR3-06, BR3-10  
Shalekenov, B., O4-10  
Shalekenov, S., O4-10  
Shalhav, A., MP11-05, MP11-06, MP11-07, MP14-12, MP20-01, MP24-03, VP1-01, VP1-13, VP19-05, VP20-17  
Shamsa, A., VP13-14  
Shamsa, S., VP13-14  
Shamsuddin, A., MP2-14, MP7-20  
Shamusddin, A., MP2-13  
Shan, Y., VP14-08  
Sharifiaghdas, F., MP10-01, VP13-01  
Sharma, D., MP18-20, VP11-11  
Sharma, R., VP22-01  
Sharma, S., MP15-10, MP15-11  
Shelkovnikov, S., MP5-09, MP24-09  
Shengping, T., MP5-18, VP24-12  
Sheth, S., MP10-10  
Shetty, A., VS19-07  
Shichman, S., VP27-13  
Shields, J., BR1-06, MP6-14, MP18-08, VP27-17  
Shikanov, S., MP11-05, MP11-06, MP11-07, MP14-12, MP20-01, MP24-03, VP1-01, VP1-13, VP19-05  
Shim, K., MP3-02  
Shin, D., MP1-15  
Shin, R., VP10-19  
Shingleton, B., MP6-06, MP6-15, MP6-20, MP14-11  
Shinohara, N., VP27-01  
Shishido, T., MP19-15  
Shokohian, M., MP16-01  
Shortland, A., VP6-02  
Shrewsbury, A., MP3-09  
Shrivastava, A., MP17-02, VS13-10  
Shrotri, N., MP24-12  
Sibony, M., BR8-01  
Sichani, M. Mohammadi, MP4-08, MP9-04, MP16-06, VP3-07, VS4-10, VS5-03, VS9-05  
Siddiqui, M., MP7-19, VP16-01  
Siegel, D., VS19-08  
Siegel, Y., MP2-12  
Sierra, M., BR1-06, MP18-08  
Siefert, K., MP7-14, MP24-11  
Sighinolfi, M., BR5-09, VP18-08, VS4-09, VS9-06, VS9-07  
Sijo, P., VS19-06  
Silberstein, J., VP8-13, VP21-15  
Simforoosh, N., VP2-07, VP28-07  
Simmons, M., VP17-08  
Simone, G., BR8-08, MP20-06, MP20-16, VP1-11, VP2-14, VP11-07, VP11-15, VP12-11, VP22-07, VP27-07, VP28-11  
Sinclair, M., MP4-19  
Singer, E., VP8-10, VP20-20, VS12-08, VS16-03  
Singer, J., VP22-16  
Singh, A., BR3-08, MP8-12  
Singh, J., MP15-03  
Singh, S., BR4-04, MP3-20, MP21-08, VP13-12  
Sinha, L., MP8-18  
Sirin, H., MP21-05, MP22-18  
Skarecky, D., MP15-16  
Skarekcy, D., VP20-03  
Skolarikos, A., O5-09, MP21-19, VP15-06  
Skolarus, T., MP15-15, MP18-17  
Skrepetis, G., MP19-05  
Skrepetis, K., MP19-11, VP23-13  
Skrobek, L., BR6-04  
Slutsky, J., MP23-05  
Smaldone, M., MP21-04, MP21-16  
Small, A., VP5-03  
Smith, A., MP9-15, VS19-08  
Smith, J., BR2-01, MP6-04, MP6-04, MP13-05, MP18-14, VP9-08  
Smith, N., BR5-04, MP18-07, MP19-18, VP3-18, VP5-11, VP15-03  
Smith, R., MP5-07, VP3-13  
Snow, D., MP14-15, VP1-14  
So, S., MP12-11, MP20-20, MP23-17, VP24-06  
Soares, C., MP1-13  
Soderdahl, D., MP24-07  
Sodha, H., VS1-02, VS1-03, VS7-09, VS11-06, VS19-09  
Soergel, T., MP2-10  
Sofer, M., VP3-03, VP28-15  
Sofras, F., VP18-05, VP18-06  
Soh, J., VP17-20, VP27-04  
Sohn, M., VP13-03  
Soleymani, S., MP12-11, MP20-20  
Solovov, V., O1-01  
Soltani, M., VP2-07  
Somani, B., MP12-06, MP16-03  
Sommer, J., VP20-15  
Song, C., MP15-08, MP17-14  
Song, F., MP9-13, MP12-01  
Sonmezay, E., VS3-07  
Sönmezay, E., MP22-08  
Soo-bang, R., VP17-16  
Sood, H., VP11-11  
Sorcini, A., MP5-17, MP19-09  
Sorensen, M., VP18-09  
Soria, F., VP6-10, VP6-12, VP6-19  
Sorrentino, D., MP18-19, VS5-05  
Sosa, R., VP13-19  
Sotelo, R., VP8-01, VP19-11, VS4-03, VS7-05, VS10-03, VS10-10, VS14-09, VS19-02  
Sountoulides, P., MP6-07, MP18-04  
Sountoulidis, P., MP7-17  
Sourati, MP9-02  
Sozen, S., VP24-06  
Spaliviero, M., MP17-09, VP14-20  
Spiliopoulos, S., MP24-17  
Spöler, F., BR8-07, O4-02  
Srinivasan, A. K., MP12-07, MP14-06, VP17-14  
Srinivasan, A., MP23-19, VP7-09, VP7-10, VS6-06, VS16-08  
Sriprasad, S., MP8-17, VP18-07  
Srivastava, A., VP2-05, VP17-07  
Srougi, M., MP16-04, VP4-03, VP6-03, VP6-06, VS9-01  
Stakhovskiy, O., O1-06, VP1-20  
Starling, E., VS9-09  
Stathouros, G., MP19-11, VP23-13  
Steele, K., MP21-06  
Steil, W., BR4-09, O2-06  
Stein, Conrado, VP21-20  
Stein, R., MP12-13, MP17-03, MP18-19, MP19-04, VP11-10, VP13-02, VS4-06, VS17-01  
Steinberg, G., VP19-05  
Steiner, R., VP13-02  
Stenzl, A., MP7-14, MP24-11  
Stern, J., MP15-10, MP15-11  
Sternberg, I., MP10-17  
Sternberg, K., MP21-04, VP2-06, VP2-11  
Stessman, M., MP3-11, MP3-12, MP3-15, MP10-16  
Stewart, A., MP2-04, MP14-08  
Stief, C., BR6-07  
Stifelman, M., VP5-06, VP11-06, VS4-02  
Stoianovici, D., MP15-14  
Stoller, M., MP10-10, MP16-18, VP26-14

- Stolzenburg, J., BR1-08, O2-09, O6-06, MP9-15, MP12-12, MP13-14, MP18-09, VP10-04, VP10-08, VP10-13, VP10-15, VP12-07, VS8-02, VS18-09
- Stolzmann, P., VP11-02
- Storme, O., BR5-03, MP4-05
- Storme, Oscar, VP21-20
- Straub, M., VP16-10
- Strebel, D., MP23-10, VP14-14
- Strebel, R., VP7-07
- Strohmaier, W., BR4-07
- Strom, K., MP17-09, VP14-20
- Stroup, K., MP10-02
- Stroup, S., MP1-18, MP6-02, MP10-02, MP13-19, VP17-05, VP22-20, VP26-05, VP27-08
- Strup, S., MP12-02, MP12-03, MP19-19
- Su, L., MP5-19, MP13-16, MP17-20, MP24-20, VP5-10, VP10-11, VP20-11, VS2-04, VS10-08, VS15-07, VS19-06
- Subotic, S., VS3-08, VS20-01
- Subramonian, K., O6-10, VP18-13
- Sudhir, S., MP3-18
- Suh, L., MP24-20
- Sul, C., MP10-15
- Sulser, T., O6-05, MP1-20, MP23-10, VP7-07, VP14-14
- Sumfest, J., MP19-01, VP11-20
- Summers, K., BR7-05
- Sun, L., VP10-11, VP20-11
- Sun, Y., BR7-02, BR8-10, VP18-15
- Sundaram, C., MP15-04, MP17-04, MP17-05, MP20-18, VP27-13, VP28-05, VS20-02, VS20-03
- Sung, G., MP5-14, MP6-10, MP11-12, MP11-13
- Sushi, K., MP3-18, MP22-03
- Sushil, K., MP22-03
- Suson, K., MP6-01
- Suzuki, K., VP28-09
- Suzuki, T., MP5-02
- Swartz, M., VP13-05
- Sweeney, D., VS9-08
- Sweet, R., VP6-09, VP27-13
- Syed, H., MP18-02
- Sýlay, M., MP9-16, MP21-05, VP15-04
- Szabó, Z., VP17-18
- Székely, J., MP2-07, VP17-18
- T**
- Ta, V., MP19-18
- Tabassi, K. Tavakkoli, MP3-04, MP16-14, VP18-03
- Tabata, K., VP7-03
- Tabatabaei, S., MP7-19, VP16-01
- Tabibi, A., MP4-08, MP10-01, VP2-07, VP9-20
- Tadaion, F., O5-08
- Tadayun, A., VP6-16
- Tae young, J., MP23-12, MP24-15
- Taghavi, R., MP16-14, VP18-03, VP26-07, VP26-12, VP28-04
- Taghechian, S., MP3-09
- Tahmaz, L., MP4-15, MP9-10, MP9-12, MP22-09, MP22-10, VP10-10, VP12-12, VP15-01, VP23-08, VP26-19, VS6-02
- Tailly, G., MP2-02
- Takahashi, N., VP28-09
- Takao, A., MP8-08
- Takeda, M., VP9-11
- Takeuchi, A., VP17-17
- Takizawa, N., MP14-18
- Talamini, M., VP8-13
- Talarico, J., VP6-07, VP6-11, VS7-02
- Tam, P., VP9-15
- Tamaddon, K., O3-05, MP8-03, VP21-13
- Tan, B., VP4-15
- Tan, M., VP24-06
- Tanaka, N., VP27-09
- Tanaka, T., VP2-08
- Taneja, N., MP3-20
- Tanriverdi, O., MP9-16, MP21-05, MP22-18, VP15-04
- Tansug, Z., MP9-14, MP9-17, VP4-09
- Tarhan, T., MP22-08
- Tarmidzi, H. Mohd, O6-10, VP18-13
- Tarquini, A., MP23-01
- Tarter, T., BR1-07
- Tasaki, Y., MP14-16
- Tasca, A., VP26-06
- Tasci, A., MP22-08, VS3-07
- Taskiran, M., MP9-16
- Tatar, I., BR2-06, VP6-04
- Tatsugami, K., MP13-02
- Tawfik, E. Ehab Rifat, O4-04, VP3-15, VP3-19, VP18-12
- Tawfik, A., BR3-02, MP13-20
- Teber, D., O2-03, VP6-13, VP7-11
- Tefekli, A., BR3-08, O5-07, O5-09, MP8-12, MP21-19, MP21-20, VP4-14, VP15-06, VP15-13, VP25-20, VP27-14, VS17-08
- Tefik, T., MP5-03, MP14-05, MP14-09, MP14-13, MP20-19, VP1-09, VP6-13, VP27-16, VS2-07, VS20-04
- Teichman, J., BR2-02, BR2-04, VP3-09, VP28-16
- Tekgül, S., O5-01
- Tenggardjaja, C., MP6-04, MP6-04, MP8-04, MP13-04, MP13-05, VS5-07, VS18-02
- Tepeler, A., MP8-12, VP25-20, VP27-14, VS17-08
- Tepeler, K., VP4-14
- Terrone, C., MP14-19
- Terzolo, M., MP6-09
- Teyeb, M., VP9-09
- Thanos, A., MP1-03
- Thomas, K., O4-03, MP3-13, MP18-07, VP3-18, VP9-08, VP15-03
- Thomas, R., O2-04, MP5-10, MP5-11, MP11-04, MP11-10, MP11-11, MP15-05, MP17-15, MP20-07, VP2-19, VS4-01, VS7-01, VS20-09
- Thompson, S., BR7-08
- Thompson, W., MP10-05
- Thueroff, S., BR4-09, BR8-06, O1-01, O2-06, MP1-16, MP17-07, VP18-20
- Thüroff, J., MP2-15, MP11-19, MP24-19
- Tienforti, D., MP23-01
- Tintila, B., VP3-01, VS7-10
- Tiong, H. Chin, MP7-04, VP11-04
- Tobias-machado, M., VS9-09
- Todd, A., MP16-03
- Tokatli, Z., VP18-11
- Tokgoz, H., BR2-08, BR5-06, VP18-02
- Toktas, G., VP28-10
- Tomaszewski, J., MP21-16, VS9-08
- Tongson-ignacio, J., MP18-15
- Topac, H., MP4-15, MP9-10, MP9-12
- Topaloglu, H., VS1-05
- Toparli, S., BR2-08
- Topcuoglu, M., MP20-17, VP2-03
- Torcia, C., VP27-15, VS3-05, VS6-08
- Tousi, V. Najjaran, VP3-07, VS4-10
- Toutziaris, C., VP28-12
- Townell, N., MP12-06
- Trabulsi, E., MP11-15
- Tracey, A., MP13-06, MP17-15, MP17-16, MP20-07, MP20-09
- Tracy, C., BR1-05, MP6-03, MP16-11, MP18-14, VP8-02, VP28-05
- Trang, V., VP2-13
- Travassos, J., VP3-06, VP12-14, VP12-15
- Travassos, Mr. José, O2-11
- Traxer, O., BR8-01, BR8-02, O5-10, MP9-15, VP3-20
- Tremp, M., MP1-20
- Trimis, E., VP23-13
- Trimmer, C., MP6-03
- Trock, B., MP15-14
- Trojan, L., O2-08, MP12-08, MP12-09
- Truesdale, M., O6-07, MP11-14, MP15-06, MP18-13
- Tsai, S., MP5-17
- Tsivian, M., MP6-12, MP6-13, MP6-20, VP19-18, VP19-19
- Tsuchiya, N., MP14-04, VP7-04
- Tsukamoto, T., VP2-08
- Tsushima, T., MP1-19
- Tufek, I., MP15-13, VP14-16, VS1-10, VS5-08, VS13-03, VS14-06, VS15-10, VS17-03, VS20-05
- Tüfek, Ý., VP27-18
- Tugcu, V., MP22-08, VS3-07
- Tuna, M., VP27-18
- Tunc, L., MP18-11, VP7-11, VP11-17
- Tunc, M., MP20-19, VP27-16
- Tuncel, A., MP12-16, VS19-03
- Turk, T., BR6-09
- Turk, Thomas, MP10-11

Turker, G., BR6-02  
Turki, F., VP9-09  
Turksoy, O., BR2-08, BR5-06, VP18-02  
Turner, K., BR1-08, MP18-09  
Tzelepis, K., MP19-11  
Tzortzis, V., MP2-16

**U**

Ubbink, D., VP14-01  
Uberoi, J., MP1-14, MP8-01, MP15-20,  
MP17-06, MP17-10, MP20-12,  
VP5-07, VP22-03, VP22-04  
Ucar, M., O1-04  
Uchida, H., VP28-09  
Uehara, S., MP8-07, MP8-08, MP19-13  
Uehara, Shinya, O1-09  
Uematsu, Katsutoshi, O1-09  
Ugurlu, Ö., O3-06  
Uhlman, M., VP20-11  
Ulbrich, M., VP13-09  
Umranikar, S., MP8-13, MP22-01  
Unal, I., BR2-08  
Unda, M., MP13-12  
Unluer, E., VP28-10  
Unnikrishnan, R., MP12-02  
Unsal, A., MP4-10, MP8-10, MP9-06,  
MP10-03, MP19-06, VP4-01, VP4-11  
Urdaneta, G., VS18-06  
Usai, P., VP28-01  
Uson, J., VP6-10, VP6-12, VP6-19  
Üstün, H., BR1-03, O6-09  
Utida, C., MP20-15

**V**

V, M., O1-01, MP7-10, MP10-06,  
MP10-07, MP20-13, MP22-05,  
MP22-12, MP23-19, VP18-05,  
VP26-13, VS3-01, VS16-08  
Vaccino, D., MP12-15  
Vadjargah, A. Moradi, VS5-03  
Valdevenito, P., MP22-16  
Valdevenitol, Mr. Raul, VP21-20  
Valero, R., VP6-17, VP12-10  
Vallancien, G., O1-06, O3-02, O6-04,  
MP1-05, VP1-20, VP6-20, VP12-02,  
VP12-08  
Vallo, S., MP13-17  
Van der zee, H., MP6-18  
Van wynsberge, L., VP3-08  
Vanjecek, M., MP22-05, MP22-12  
Vardi, I., MP10-17  
Varga, Z., MP23-02, MP23-03  
Vargas, F., MP22-16  
V d j, J., MP22-03  
Veale, J., VP7-01, VP22-16  
Venieri, M., VP18-05  
Venkatesh, R., BR3-02, MP9-07,  
MP13-20  
Vergetaki, U., VP18-05  
Verma, P., O4-05  
Vicari, E., BR1-04

Vicentini, F., MP16-04, MP20-14,  
VP4-03, VP10-19  
Vidal-mora, I., O3-01, O6-01, O6-02,  
VP9-16, VP13-08, VP13-10, VP17-03,  
VP17-12, VP22-08, VP22-09,  
VP22-10, VP22-11, VP22-12,  
VP24-10, VP25-05, VP25-06,  
VP25-11  
Villányi, K., MP2-07  
Villavicencio, H., VS18-06  
Vincent, C., VS2-04, VS15-07  
Viney, R., BR8-09  
Viprakasit, D., VP5-11  
Vira, M. A., MP14-06  
Vira, M., MP20-13, MP23-19, VS16-08  
Virmani, M., VS3-01  
Visser, M., MP7-10  
Vittori, M., MP10-06, MP10-07  
Vivek, J., MP3-18  
Vöge, D., VP13-03  
Vögeli, T., MP12-19  
Von klot, C., O5-06  
Voss, G., O4-08, O4-09  
Vozdvishensky, M., O1-01  
Vuruskan, H., VS1-07, VS1-09, VS6-01,  
VS10-07, VS18-01, VS19-01

**W**

Waalkes, S., VS6-10  
Wagh, M., MP5-19, VP28-05  
Wagner, C., MP11-17, VP5-09  
Wagner, S., O1-07, O3-04, VP12-01  
Wake, R., VP22-20  
Walcher, U., O5-06  
Wallner, L., MP23-06  
Walsh, R., MP9-08, VP3-04  
Walther, S., BR6-07  
Wang, A., MP17-17, VS13-09  
Wang, C., BR8-05, MP7-11, VP22-13  
Wang, D., MP8-09, VP1-06, VP9-03,  
VS14-04  
Wang, G., O3-07, MP5-20, VP10-09,  
VP10-16, VP15-08, VP21-16,  
VP21-17, VP25-12  
Wang, L., MP5-16  
Wang, T., BR2-04  
Wang, X., O5-02  
Ward, J., O2-07  
Watanabe, T., MP8-07, MP8-08,  
MP19-13  
Watanabe, Toyohiko, O1-09  
Watson, G., O4-05, VP23-06  
Watson, J., O3-02, MP3-09  
Watterson, J., VS8-06  
Weber, M., O1-10  
Wehner, E., MP18-14  
Wei, J., MP18-12, MP23-06  
Weinberg, A., VS14-04  
Weirich, T., MP4-09  
Weise, E., VP5-02, VP5-04  
Weisse, C., VP6-08

Weizer, A., VP5-08, VS9-10, VS12-07,  
VS13-06, VS16-09  
Weizhong, Y., VP24-12  
Wenbin, L., BR7-01  
Wendt, G., BR3-01, MP7-13, VP4-04,  
VP13-02, VP14-12, VP28-20  
Wendt-Nordahl, G., BR3-01, MP7-13,  
VP13-02, VP14-12, VP28-20, VP4-04  
Wenz, F., O2-08  
Wess, O., BR5-07  
West, D., VP11-03, VP19-12  
Wezel, F., BR4-03, MP4-03, VP3-16,  
VP4-04, VP4-18, VP24-05, VP28-20  
Wheat, J., BR4-02, MP19-20, VP18-01,  
VS7-03  
White, A., MP5-06, MP11-08  
White, M., VP8-05, VP8-08, VP8-11  
White, W., MP2-04, MP10-05, MP17-03,  
MP17-11, MP19-04, VP6-07, VP6-11,  
VP8-05, VP8-08, VP8-11, VP13-05,  
VP19-04, VP20-12, VP20-16, VS7-04,  
VS7-07, VS16-07, VS16-10, VS18-05  
Wieland, W., MP1-04, VP11-08, VP16-12  
Wiesenthal, J., VS8-06  
Wijkstra, H., VP19-15  
Wilby, D., O4-03, MP7-18, MP18-07  
Wilhelm, D., O1-03  
Will, Thomas, MP10-11  
Wille, M., MP20-01  
Williams, Jr, J., MP16-12, MP21-13  
Williams, S., MP1-12, VP20-08  
Willis, S., VP3-18  
Winfield, H., VP27-13  
Witt, J., O2-09, MP11-17, VP5-09  
Witzsch, U., BR7-07, O4-08, O4-09  
Wojno, K., MP19-20  
Wolf, Jr., J., MP14-12, VP5-08  
Wolf, S., MP18-12  
Wollin, T., MP8-16  
Wöllner, G., MP11-19  
Wöllner, J., MP2-15, MP11-19  
Wong, A., MP6-17, VP14-06  
Wong, C., MP17-09, VP14-20  
Wong, K., MP21-07  
Wosnitzer, M., MP4-16, MP22-19  
Wroclawski, E., VS9-09  
Wu, G., VP8-10, VP20-20, VP23-04,  
VS12-08, VS16-03  
Wu, S., MP19-18, VP5-11  
Wu, Z., MP7-12, VP3-11, VP9-04,  
VP9-05  
Wuerstle, M., MP24-14  
Wülfing, T., BR2-03, BR4-05, VP14-04,  
VS1-08  
Wyler, S., MP21-12, MP23-14  
Wynia, B., MP6-20

**X**

Xavier, A., VP3-06, VP12-14, VP12-15  
Xavier, K., MP19-16  
Xavier, Mr. Augusto, O2-11

- Xiansheng, Z., MP9-13, MP12-01  
 Xiao, C., MP23-13, VP10-09, VP13-13, VP16-03, VP25-12, VP27-19  
 Xiao, J., VS6-09, VS12-05  
 Xiao-feng, Z., BR2-05, BR6-01, O3-09, MP21-02, VP3-12, VP4-05, VP4-19  
 Xiao-ning, VP4-19  
 Xiaoming, C., MP23-13, VP13-13, VP16-03, VP27-19  
 Xiaoqing, W., VP1-19  
 Xu, K., VP25-14, VP25-15, VP25-16, VP25-17  
 Xu, Z., VP18-01, VP27-19  
 Xue, B., VP14-08  
 Xue, W., MP16-15, MP19-07, MP23-08  
 Xuezhai, L., VP13-13  
 Xuhui, Z., VP27-19
- Y**  
 Yachia, D., VS11-08  
 Yaime, H., VP12-10  
 Yalcin, V., VS12-02  
 Yalcinkaya, F., MP20-17, VP2-03, VP11-09  
 Yamamoto, T., MP14-20  
 Yamato, Toyoko, O1-09  
 Yanaihara, H., O6-03  
 Yang, B., O5-02  
 Yang, D., VP14-08  
 Yang, S., MP14-14, VP22-15  
 Yarmohamadi, A., MP16-01, MP18-01  
 Yasser, H., VP26-08  
 Yassine, N., MP9-18, VP15-07  
 Yates, J., MP1-14, MP1-15, MP1-17, MP13-03, MP15-18, MP15-20, MP17-06, MP17-10, MP20-12, VP5-07, VP22-03, VP22-04  
 Yavascaoglu, I., VS6-01, VS10-07, VS18-01, VS19-01  
 Yee, C., VP14-06  
 Yencilek, F., BR3-09, VP7-11, VP15-10  
 Yeung, L., VP5-10, VS19-06  
 Yew, J., O3-05, VP21-13  
 Yigitbasi, O., MP23-15  
 Yildirim, E., MP21-11  
 Yildirim, I., VP15-09, VP23-09, VP24-11  
 Yildiz, A., BR2-08
- Yin, X., VP25-17  
 Yinghao, S., BR7-01  
 Yiu, M., VP14-10  
 Yohannan, J., MP13-07  
 Yokomizo, A., MP13-02  
 Yongwei, Y., BR7-01  
 Yoo, E., MP15-17, MP20-03  
 Yoo, K., MP21-01, VP6-05  
 Yoon, S., MP5-08, MP5-13, MP20-05, VP18-16  
 Yoon, Y., VS13-05, VS17-07  
 Yoost, T., O3-03, VP1-07  
 Yoshida, K., VP7-03  
 Yoshikawa, Y., MP14-02  
 Yoshino, Y., MP20-04  
 Yossepowitch, O., VP9-02  
 Young-jung, K., VP17-16  
 Youp, H. Dong, VP9-06, VP17-13  
 Yousefi, A., MP8-03, VP28-02  
 Yousri, K., VP15-07  
 Yuan-hu, Y., MP21-02, VP4-19  
 Yucel, O., O6-09  
 Yucel, S., MP16-20, VS2-09  
 Yuksel, D., VP11-17  
 Yuksel, M., VP7-12, VP7-13, VP21-10, VP21-14  
 Yun-feng, L., O3-09  
 Yunfa, X., VP13-13, VP13-13  
 Yurtlu, S., VP18-02  
 Yuruk, E., BR3-08, O5-07, MP21-20
- Z**  
 Zabala, R., MP13-12  
 Zafarghandi, M. Mahdavi, MP7-05, MP10-20, MP24-05  
 Zafarghandi, R. Mahdavi, MP7-05, MP10-20, MP16-14, MP24-05, VP18-03  
 Zagaja, G., MP11-05, MP11-06, MP11-07, VP20-17  
 Zaias, J., MP6-14  
 Zaki, H., BR3-06  
 Zakoji, H., VP9-11  
 Zakri, R., MP24-12  
 Zang, Y., VP14-08  
 Zangos, S., MP13-17  
 Zare, M. Asl, VS3-09, VS4-10, VS9-05
- Zare, M. Asle, VP28-07  
 Zare, S., MP10-01, MP13-17  
 Zattoni, F., VP3-02, VP15-05  
 Zbyszewski, D., BR7-10  
 Zeccolini, G., VS2-01, VS7-08, VS10-06, VS11-07, VS20-06  
 Zehri, A., VS11-05  
 Zeng, R., BR8-10  
 Zengin, K., MP23-15  
 Zenkov, S., MP19-08, VP26-18  
 Zeren, S., MP4-14, MP9-14, MP9-17, VP4-09  
 Zhang, C., VP25-14, VP25-15, VP25-16, VP25-17  
 Zhang, K., BR4-01  
 Zhang, L., MP13-15  
 Zhang, S., MP15-15, MP18-17  
 Zhang, Y., MP7-12, VP3-11, VP9-04, VP9-05  
 Zhao, L., O3-07, MP5-20, VP21-16, VP21-17, VP25-12, VP25-13  
 Zhensheng, Z., BR7-01  
 Zhong, P., BR5-01, BR5-02, BR5-04  
 Zhou, T., BR7-02, VP18-15  
 Zhu, G., BR4-01  
 Ziaee, S., MP9-04  
 Zilberman, D., BR2-07, BR5-01, BR5-04, BR6-10, O2-04, MP6-13  
 Zimmermann, R., VP12-06, VP19-02, VP25-01, VP25-19, VS6-07, VS12-10  
 Zimmermanns, V., O5-05, MP8-15, VP3-10, VP4-10, VP4-13, VP6-14, VP20-15  
 Zisengwe, G., MP18-07  
 Zite, N., MP10-05  
 Ziylan, O., VS2-07  
 Zolotarev, G., VP7-05  
 Zongyao, H., MP9-13, MP12-01  
 Zor, M., MP4-15, MP9-10, MP9-12, MP22-09, MP22-10, VP15-01, VP23-08, VP23-09, VP24-11, VP26-19, VS3-06, VS12-09  
 Zorn, K., MP11-07, MP24-03, VP1-01, VP1-13, VP19-05, VP20-17  
 Zorron, R., VS9-04  
 Zouhair, F., VP15-07  
 Zugor, V., MP11-17  
 Zuzak, K., MP18-14

